

We are IntechOpen, the world's leading publisher of Open Access books Built by scientists, for scientists

6,900

Open access books available

186,000

International authors and editors

200M

Downloads

Our authors are among the

154

Countries delivered to

TOP 1%

most cited scientists

12.2%

Contributors from top 500 universities



WEB OF SCIENCE™

Selection of our books indexed in the Book Citation Index
in Web of Science™ Core Collection (BKCI)

Interested in publishing with us?
Contact book.department@intechopen.com

Numbers displayed above are based on latest data collected.
For more information visit www.intechopen.com



Bronchial Atresia

Lirios Sacristán Bou and Francisco Peña Blas
*Hospital General de Tomelloso & Centro de Salud de Monforte del Cid
 España*

1. Introduction

Bronchial atresia is an interesting congenital abnormality because of its variable appearance and its semblance to certain acquired diseases. It is characterized by a branching mass formed by mucus that dilates the proximal bronchi to the atretic segment. The distal lung to atresia can develop normally but it shows a paucity of blood vessels and is hyperinflated due to unidirectional collateral air drift through intraalveolar pores of Kohn, bronchoalveolar channels of Lambert and interbronchiolar pores of Martin from the adjacent normal lung. These collateral communications act as a check-valve mechanism allowing the air to enter but not to leave the distal lung.

More than 150 cases of bronchial atresia have been reported since 1953, when it was first described by Ramsay & Byron. The exact mechanism that ends in bronchial atresia is still unknown, but there are two hypotheses about the pathogenesis which have in common that they should occur before birth because the bronchial pattern to the site of stenosis is entirely normal. Many of the most relevant case reports and published series of cases are reviewed in this chapter to update our knowledge of bronchial atresia. They have been obtained as the result of a bibliographical research at Pubmed; ninety five articles were found using the Medical Subject Headings (MeSH) thesaurus descriptors congenital and bronchial atresia.

2. Pathogenesis

Bronchial buds appear in the fifth week of gestation and then complete branching takes place in the sixteenth week. Although bronchial atresia is associated with a decreased amount of alveoli, the number of airways is not reduced.

Congenital bronchial atresia pathogenesis is not completely understood, but there are two pathogenic hypotheses. The first one proposes that proliferating cells at the distal tip of the developing bud are disconnected from the normal branch at any time from the fifth to the sixteenth weeks by a still unknown agent (Bucher et al., 1961; Kuhn et al., 1992).

The other one postulates that focal ischemic insults at the fifth week or later result in necrosis and obliteration of the already completed bronchus (Reid, 1977 or Waddell et al., 1965). The experiment of Louw & Barnard (1955), in which they tied off a mesenteric arterial branch in puppies two weeks before birth, showed that atresia may result from a vascular occlusion and develop late in intra-uterine life. Their findings favour vascular occlusion rather than a failure of growth as the cause.

The pulmonary arterial development is closely associated with the developing lung bud. The primitive pulmonary artery is already present as a major branch and grows toward the lung bud. Subsequently, it gives off a branch to accompany each airway branch in the preacinar region. Pulmonary vascular abnormalities have been documented in bronchial atresia (Ko et al., 1998; Lacquet et al., 1971).

3. Respiratory symptoms and epidemiology

Bronchial atresia has a male predominance, with an estimated prevalence of 1.2 cases per 100,000 males and 0.6 cases per 100,000 females - a male: female ratio of 2:1.

About two thirds of the reported patients were asymptomatic before diagnosis and occurred as an incidental radiological discovery. It is usually diagnosed in the second or third decade of life, and the diagnosis is infrequent during childhood. One third of patients may present with cough, shortness of breath and recurrent infections and less frequently with refractory wheezing, haemoptysis, chest pain, or pneumothorax (Agarwal et al., 2005; Kameyama et al., 2006; Morikawa et al., 2005 (Table 1).

Asymptomatic	58.00%
Recurrent Infection	21.00%
Dysnea	14.00%
Coughing	6.00%

Table 1. Frequency of symptoms from more to less frequent (Jederlinic et al., 1987).

The bronchi involved in this congenital anomaly are the apico-posterior segment of left upper lobe, right upper lobe, right middle lobe and right lower lobe, in decreasing order of frequency (Acosta Gordillo et al., 2005; Psathakis et al., 2004).

4. Imaging techniques for the diagnosis

Currently clinicians have lot of many imaging techniques at their disposal for the investigation of patients with this congenital anomaly.

4.1 Plain Chest Radiography

The radiographic findings mirror the pathologic changes.

On chest radiography the typical finding of a mucocoele is that of a nodule or a shadow-like mass close to the hilum, with well-defined margins, presenting as a tubular, round, ovoid or branching structure (Sacristán Bou et al., 2010) (Fig 1). A mucocoele with an air-fluid level is considered by some authors as a variance of congenital bronchial atresia (Matsushima et al., 2003).

The branching bronchocele mimics a glove-finger shadow, but is not pathognomonic of bronchial atresia.

It has been proposed that the impacted mucous can also liquefy producing the radiological sign of an air-fluid level-mimicking a cavitatory lesion. When the hyperinsuflated area gets

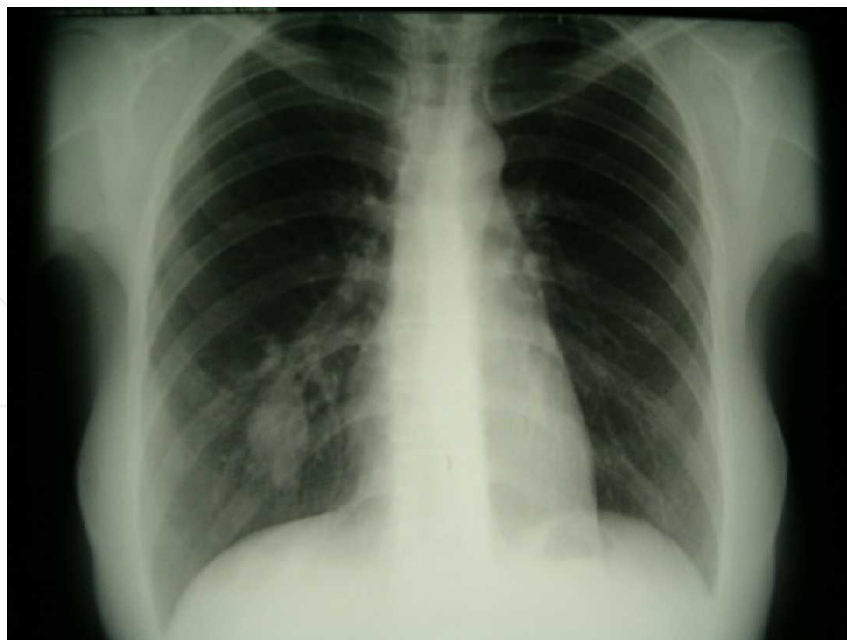


Fig. 1. Polylobulated round mass near to the hilum in the right lower lobe (Sacristán Bou et al., 2010).

infected and presents as a pneumonia, the walls of bronchoceles develop tiny breaks that enables the air to enter in its lumen (Psathakis et al., 2009; Rahalkar et al., 2005).

Occasionally, the dilated bronchi may appear as purely air-filled, lucent bands of odd shapes (Nussbaumer-Ochsner & Kohler, 2011; Van Klaveren et al., 1992).

The distal lung is always distended, forming the apex of a roughly triangular zone of hyperlucency of the lung parenchyma (due to oligoemia and hyperinflation). On radiography obtained at expiration, obstructive emphysema is obvious, however, the synchronous appearance of both the mucocoele and lung hyperlucency is only seen in 69% of cases (Jederlinic et al., 1987).

Sometimes bronchial atresia is associated with other congenital anomalies like pectum excavatum (Van Klaveren et al., 1992).

4.2 Computed Tomography (CT) and High-Resolution Computed Tomography

Computed tomography is the procedure of choice for the diagnosis and study of congenital bronchial atresia.

The bronchocele presents as a round/ovoid/branching structure near the hilum, with or without a fluid level, without contrast enhancement and it exhibits a density between 10 to 25 Hounsfield Units due to mucoid material. Computed tomography allows characterization of the lack of communication between the mucocoele and hilum (Fig. 2).

High resolution techniques can display the characteristic features of the mucocoele, being more sensitive than the plain chest radiography to show oligoemia, reduced caliber of the pulmonary vessels, hyperinflation of the lung parenchyma (Fig. 2), small mucocoeles invisible to conventional radiography, associated mass effect and even calcification (Kinsella et al., 1992 and Primetis et al., 2011).

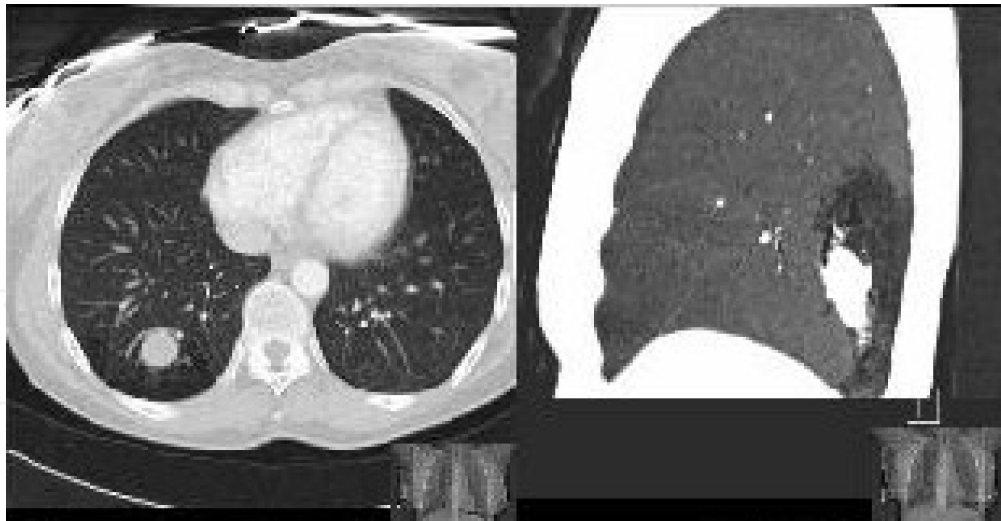

Fig 2. Polilobulated round mass located in the posterobasilar right subsegmental bronchi with a distal segmental area of radiolucency and lack of communication between the mucocoele and hilum on high-resolution computed tomography (Sacristán Bou et al., 2010).

4.3 Magnetic Resonance Imaging (MRI)

MRI shows a very high signal intensity within the bronchocele on T1W and T2W modes due to mucoid contents; however, it cannot depict regional air-trapping (Matsushima et al., 2003) and it does not have the same sensitivity as computed tomography to evaluate the lung parenchyma (Naidich et al., 1988). So this technique has a limited role in the diagnosis of congenital bronchial atresia, although a small number of case reports have dealt specifically with differential diagnosis and have established its value.

Magnetic resonance imaging seems to be useful for the evaluation of either anomalous vessels or fluid collections that are usually associated with pulmonary abnormalities (Cohen et al., 1987).

5. Bronchoscopy

Before the advent of computed tomography, the diagnosis of bronchial atresia was made by bronchography, which allowed confirmation of the atretic segmental bronchus showing non-filling of the involved bronchus.

Flexible-bronchoscopy identifies blind-ending bronchi. In clinical practice however, any absence of a segmental or sub-segmental bronchus that is found by chance during bronchoscopy in the absence of the characteristic radiographic features may be considered as a normal anatomic variance of the bronchial tree rather than a bronchial atresia.

In the majority of the cases therefore, congenital bronchial atresia remains a radiological diagnosis.

Some authors suggest that similar findings could be found in other disorders as well, such as lung cancer or bronchial adenoma (Jeung et al., 2002; Woodring, 1990). The role of bronchoscopy is to exclude these disorders and demonstrate the patency of the central bronchi, especially in doubtful cases (Daoud et al., 2001; Ward & Morcos, 1999).

6. Lung function tests

Pulmonary function tests do not aid in diagnosis. They are normal in comparison with the magnitude of the radiological abnormality. The most interesting point is the normal physiological dead space that implies air trapping in the emphysematous area as a result of collateral ventilation that causes the inflation.

7. Differential diagnosis

The singular finding of a dilated bronchus due to mucoid impaction (bronchocele) can be seen in a variety of conditions apart from bronchia atresia. It is important to differentiate between congenital and acquired causes of obstruction (Table 2).

7.1 Congenital obstructive illnesses

7.1.1 Lung Aplasia

Pulmonary agenesis refers to undeveloped pulmonary vessels, bronchi, and parenchyma. It may be unilateral or bilateral. In unilateral aplasia, the remaining lung contains twice as much alveoli as normal, but has normal bronchi. Although aplasia does not have the same structures, it has a rudimentary bronchus.

Pulmonary aplasia (agenesis) is thought to result from the negative effects that occur in the 4th week of fetal life. Although its etiology is not fully understood, Vitamin A or folic acid deficiency or the use of salicylates may be responsible. The incidence in males and females and the occurrence of the anomaly in the right or left lung are about the same. Hypoplasia and aplasia are often observed together with other malformations (diaphragm defects, kidney anomalies, extrapulmonary sequestration, muscular or skeletal system defects). Nearly one-third of the patients have congenital heart diseases. Although the most common is the atrial septal defect, ventricular septal defect, patent ductus arteriosus, or aorta coarctation can also be observed. Clinical findings change with the presence of comorbid anomalies and their severity. Recurrent infections can increase respiratory dysfunction. Although patients with unilateral lung aplasia (agenesis) are believed to die usually in the neonatal period, there are patients who live up to adulthood, some of whom are completely asymptomatic. In the diagnosis of this condition, methods such as contrast-enhanced CT, bronchography, bronchoscopy, pulmonary angiography, and magnetic resonance imaging are also employed.

7.1.2 Congenital Lobar Emphysema

A congenital lobar emphysema (CLE) refers to an over inflation of one or more lung lobes presumably due to various factors including a possible obstructive check valve mechanism at the bronchial level. It is more common in males and often detected in neonates or identified during in utero ultrasound. Anomalies are rather infrequent. Patients will typically have respiratory distress within the first 6 months of life.

CLE almost always involves one lobe, with rates of occurrence as follows: 41% left upper lobe, 34% right middle lobe, 21% right upper lobe. Congenital lobar emphysema has two forms of presentation: hypoalveolar: fewer than the expected number of alveoli, and polyalveolar: greater than the expected number of alveoli.

There are many presumed mechanisms for progressive overdistension of a lobe including obstruction, cartilage deficiency, dysplasia, immaturity and idiopathic. It can be associated with cardiac anomalies such as: a ventricular septal defect, patent ductus arteriosus and tetralogy of Fallot. Congenital lobar emphysema appears in the immediate postpartum period.

Radiography of the chest in anteroposterior and lateral projections identifies the involved lobe, the degree of involvement, and the effect on surrounding structures. If a decubitus position radiograph is obtained, the involved lung does not collapse. Computed tomography scanning can provide details about the involved lobe and its vascularity, as well as information about the remaining lung. MRI can be used as an adjunctive modality to evaluate vascular supply and distribution to the involved lobe but is not routinely employed. In congenital lobar emphysema, the abnormal lobe usually has a normal vascular supply.

7.1.3 Congenital Cystic Adenomatoid Malformation (CAM)

The first cystic adenomatoid malformation (CAM) was described as a distinct entity by Ch'in and Tang in 1949. CAM is a developmental hamartomatous abnormality of the lung, with adenomatoid proliferation of cysts resembling bronchioles. CAM represents approximately 25% of all congenital lung lesions (Colin et al., 2006).

CAM is subdivided into three major types:

- Type I lesions, the most common, are composed of 1 or more cysts measuring 2-10 cm in diameter. Larger cysts are often accompanied by smaller cysts, and their walls contain muscle, elastic, or fibrous tissue. Cysts are frequently lined by pseudostratified columnar epithelial cells, which occasionally produce mucin. Mucinogenic differentiation is unique to this subtype of CAM.
- Type II lesions are characterized by small, relatively uniform cysts resembling bronchioles. These cysts are lined by cuboid-to-columnar epithelium and have a thin fibromuscular wall. The cysts generally measure 0.5-2 cm in diameter.
- Type III lesions have the appearance of solid masses without obvious cyst formation although adenomatoid cysts can be detected microscopically.

CAM receives its blood supply from pulmonary circulation and is not sequestered from the tracheobronchial tree. However, type II and III lesions can occasionally coexist with extralobar sequestration, and in such cases, they may receive a systemic arterial supply. CAM may also occur in combination with a polyalveolar lobe. This is a form of congenital emphysema with an increased number of alveoli with normal bronchi and pulmonary vasculature. CAM usually occurs early in fetal life, whereas the polyalveolar lobe occurs later.

Prenatal ultrasonography is accurate in diagnosing CAM. Prenatally diagnosed lesions may be asymptomatic at birth (71%), and they have normal radiographic findings (57%). A concurrent sequestration may not be identified. Usually, radiographic findings are apparent in a symptomatic individual, but they may not be as apparent in an asymptomatic child.

Most often, the diagnosis can be made by using plain radiographs. CT scans may be used for confirmation and when planning surgery. Overlapping CT features exist among cases of CAM, pulmonary sequestration, bronchogenic cyst, and other foregut malformations.

7.1.4 Bronchogenic cysts

Bronchogenic cysts are part of a spectrum of congenital abnormalities of the lung including pulmonary sequestration, congenital cystic adenomatoid malformation and congenital lobar hyperinflation (emphysema). There exists a predilection in all of them for the left upper lobe that could be due to the embryologic instability of this area (Sadler, 1990).

Although relatively rare, cysts represent the most common lesion of the mediastinum. In infants and small children, these cysts can be life threatening when they compress vital structures. In particular, subcarinal cysts can pose life-threatening airway compromise. In infants, the initial presentation may be respiratory distress. More than one half of patients are asymptomatic.

These are usually found using antenatal ultrasonography or routine chest radiography and during evaluations for gastro-intestinal or cardiac symptomatology. Bronchogenic cysts are the result of anomalous development of the ventral foregut; they are usually single but may be multiple and can be filled with fluid or mucus. They have been found all along the tracheoesophageal course, in perihilar or intraparenchymal sites, with a predilection for the area around the carina. Those in the mediastinum frequently attach to, but do not communicate with, the tracheobronchial tree. Bronchogenic cysts have also been described in more remote locations, including the interatrial septum, neck, abdomen, and retroperitoneal space. Chest pain and dysphagia are the most common symptoms in adults with bronchogenic cysts; in infants, symptoms are most often produced as a result of airway or esophageal compression.

Bronchogenic cysts are usually an incidental finding, and differentiating them from other pathologic conditions is important. On conventional radiographs, the appearances of mediastinal or lung masses are nonspecific and should be evaluated further using computed tomography (CT) scanning or magnetic resonance imaging (MRI). Intrapulmonary cysts are difficult to diagnose and must usually be aspirated to confirm the diagnosis.

7.1.5 Anomalous pulmonary venous return

Abnormal development of the pulmonary veins may result in either partial or complete anomalous drainage back into the systemic venous circulation. Three major clinical patterns of total anomalous pulmonary venous return (TAPVR) are seen: severe pulmonary venous obstruction; early heart failure; mildly symptomatic or asymptomatic.

7.1.6 Pulmonary sequestration

Pulmonary sequestration is a cystic or solid mass composed of nonfunctioning primitive tissue that does not communicate with the tracheobronchial tree and has an anomalous systemic blood supply rather than the pulmonary circulation. In 15-20% of cases multiple feeding vessels may be present. The two forms of pulmonary sequestration are intrapulmonary, which is surrounded by normal lung tissue, and extrapulmonary, which has its own pleural investment. Demonstration of a dominant feeding vessel, usually from the aorta or its major vessels, and venous drainage to the pulmonary veins suggests the diagnosis. Other congenital malformations may be present.

Chest radiographs can provide a reasonable diagnostic clue to pulmonary sequestration. A mass in the posterobasal segment of the lung in young patients with recurrent, localized pulmonary infections is suggestive of pulmonary sequestration. Computed tomography scanning, angiography, magnetic resonance imaging or bronchography may be helpful in excluding other diagnoses. CT scans have 90% accuracy in the diagnosis of pulmonary sequestration. Arteriography is helpful in differentiating the lesion from other abnormalities of the lung, such as pulmonary arteriovenous fistulae. Magnetic resonance angiography can provide information similar to that on CT scans.

7.1.7 Cystic Fibrosis (CF)

The name cystic fibrosis refers to the characteristic scarring (fibrosis) and cyst formation within the pancreas, first recognized in the 1930s. Difficulty breathing is the most serious symptom and results from frequent lung infections that are treated with, though not cured by, antibiotics and other medications. A multitude of other symptoms, including sinus infections, poor growth, diarrhea, and infertility result from the effects of CF in other parts of the body.

CF is caused by a mutation in the gene for the protein: the cystic fibrosis transmembrane conductance regulator (CFTR). This gene is required to regulate the components of sweat, digestive juices, and mucus. Although most people without CF have two working copies of the CFTR gene, only one is needed to prevent cystic fibrosis. CF develops when neither gene works normally and therefore has autosomal recessive inheritance.

Individuals with cystic fibrosis can be diagnosed before birth by genetic testing, or by a sweat test in early childhood. Ultimately, lung transplantation is often necessary as CF worsens. CF mainly affects the lungs, pancreas, liver, intestines, sinuses, and sex organs.

7.2 Acquired obstructive illnesses

7.2.1 Allergic bronchopulmonary aspergillosis (ABPA)

Allergic bronchopulmonary aspergillosis (ABPA) can be classified as an eosinophilic hypersensitivity disease. It appears concomitantly in patients with long standing asthma, and occasionally in patients with cystic fibrosis. Rarely, it can appear in patients with no other identifiable pulmonary illness. In general, patients are diagnosed before the age of 40 years.

Clinically, patients have atopic symptoms and they present with recurrent chest infection. A clinical staging system has been developed: Stage I Acute, Stage II Remission, Stage III Recurrent Exacerbation, Stage IV Steroid-Dependent Asthma and Stage V Pulmonary Fibrosis.

Laboratory findings include elevated *Aspergillus* specific IgE, elevated precipitating IgG against *Aspergillus*, peripheral eosinophilia and positive skin test.

In patients with ABPA radiological findings will be reversible after appropriate treatment or may show progression from multi-focal and non-segmental consolidations to pulmonary fibrosis and central varicose type of bronchiectasis (stage V).

7.2.2 Other causes

Bronchial obstruction may be due to many acquired conditions including inflammatory diseases (broncholithiasis and foreign body aspiration), benign neoplastic processes (bronchial hamartoma, lipoma, and papillomatosis) and malignancies (bronchogenic carcinoma, carcinoid tumor, and metastases) (Gipson et al., 2009; Wilson et al., 2009). They can even take place after a segmentectomy as a surgical complication (Okuda et al., 2006).

All these situations can produce an appearance of a round, oval or branching (glove-finger shadow) type of bronchocele. Most of these conditions can be differentiated by appropriate history (as all will be symptomatic), the progressive nature of the disease, imaging techniques, bronchoscopy and biopsy.

Congenital obstructive illnesses	Bronchopulmonary anomalies: Lung Aplasia Bronchial atresia Lobar emphysema Cystic adenomatoid malformation Bronchogenic cysts Vascular anomalies: Anomalous pulmonary venous return Combined lung and vascular anomalies: Brochopulmonary sequestration Genetic diseases: Cystic fibrosis
Acquired obstructive illnesses	Infectious diseases: Allergic bronchopulmonary aspergillosis (ABPA) Tuberculous bronchostenosis Inflammatory diseases: Broncholithiasis, foreign body aspiration Benign neoplastic processes: Bronchial hamartoma, lipoma, papillomatosis. Malignancies: Bronchogenic carcinoma, carcinoid tumor, metastases Surgery complication: Lung segmentectomy

Table 2. The differential diagnosis of bronchial atresia.

8. Treatment of bronchial atresia

Treatment of bronchial atresia is controversial. The majority of patients are asymptomatic and therefore no treatment is necessary. It is currently felt that surgical excision should be reserved for patients with secondary complications to the atretic bronchus, such as infection or significant compromise of adjacent lung parenchyma. However, some physicians advocate performing surgery on all patients because a definitive diagnosis could only be made by exeresis of the lung (Cohen et al., 1987). Lobar resection and segmentectomy have

been used to preserve as much normal lung parenchyma as possible to maintain pulmonary function (Miyahara et al., 1999; Pamer et al., 2008).

9. Prenatal bronchial atresia

Antenatal ultrasonography can raise the suspicion of bronchial atresia in the prenatal period by the presence of a hyperechogenic mass at the hilum of the lung which corresponds to a mucocele (Kamata et al., 2003; McAlister et al., 1987). Those hyperechogenic lesions are more likely to regress compared with cystic or mixed lesions (Hadchouel et als. 2011a, 2011b).

The routine use of prenatal steroids for microcystic congenital cystic adenomatoid malformation seemed to enhance regression (Curran et al., 2010). There are no documented cases on regression of bronchial or lobar bronchial atresia. Despite the lack of evidence, it would be advisable to follow an expectant management (Bonnefoy et al., 2011).

10. Diagnostic algorithm

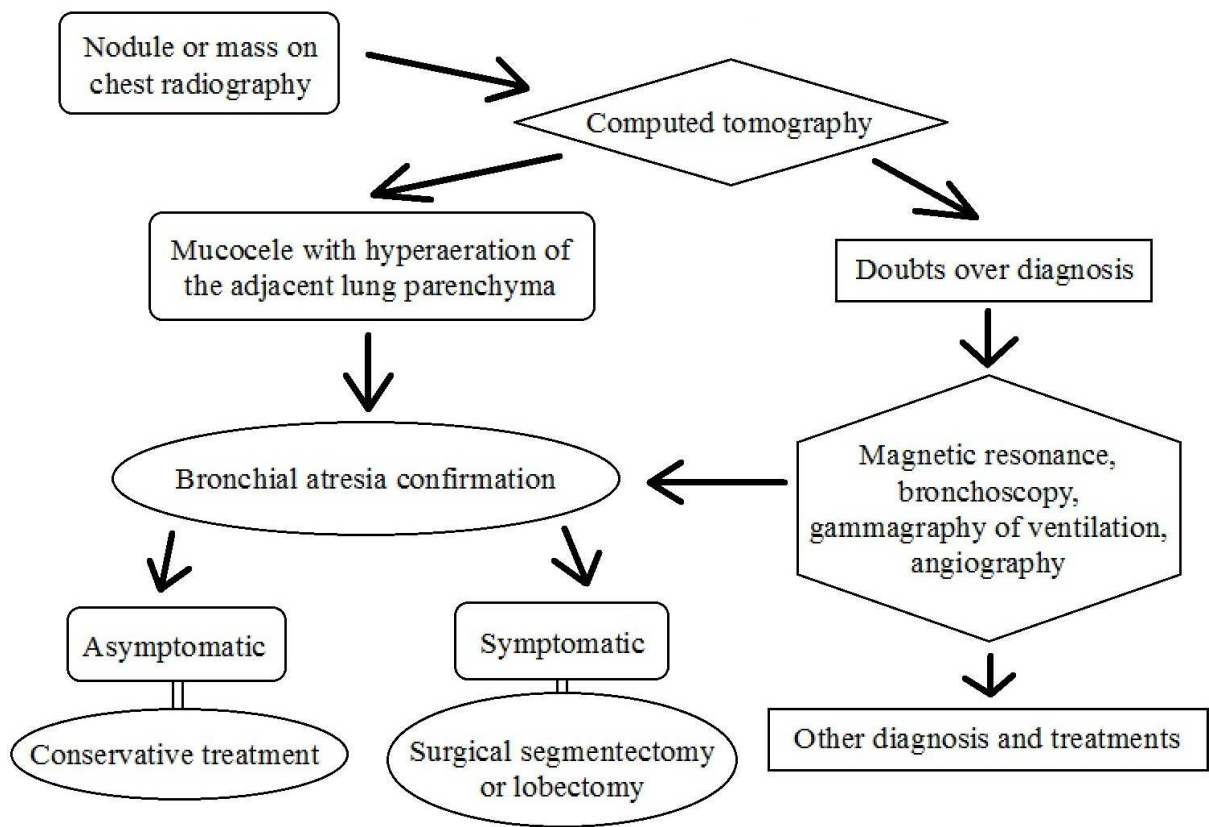


Fig. 3. Diagnostic algorithm in suspected bronchial atresia.

11. State of art during the last three years

Due to a wave of new interest in bronchial atresia among clinicians, there have been many more articles and case descriptions published in the last three years than previously. The aim of this section is to summarize the main aspects of these reports.

- In asymptomatic patients the bronchial atresia is usually found by chance on a radiographic image as described by Psathakis et al. (2009) and Sacristán Bou et al. (2010), or sometimes because a patient refers to a shoulder ache, as Hooker & Hendriksz (2011) show.
- Nussbaumer-Ochsner & Kohler (2011) report a 31-year-old HIV-positive man who presented with a history of chronic dry cough. They describe the finger-in-glove sign, a radiographic feature that refers to mucoid impaction in central airways.
- Some surgeons like Cappeliez et al. (2009) or Zribi et al. (2011) think that bronchial atresia may lead to infectious complications and, in the long term, to damage to the adjacent lung parenchyma. Therefore, a surgical resection may be necessary. The first group of surgeons reported their experience with three patients (two lobectomies and one segmentectomy) and the second group with six.
- Niimi & Gotoh (2010) present the rare case of pneumothorax due to the perforation of bullae associated with congenital bronchial atresia in a 25-year-old woman that complained of right chest pain and shortness of breath. A lateral segmentectomy was successfully performed by thoracoscopy-assisted limited thoracotomy. Diagnosis of congenital bronchial atresia and subpleural bullae were confirmed by pathological examination.
- Discioscio et al (2010), Shimizu et al (2010) and Siddiqui et al. (2011) describe several anomalies associated with bronchial atresia like anomalous pulmonary venous return, congenital cystic adenomatoid malformation or right-sided descending aorta.
- Jung et al. (2011) published a case report of a woman with diagnosis of bronchial atresia in whom the conversion of epidural analgesia to epidural anesthesia for cesarean delivery failed during labor, needing the application of general anesthesia for a successful delivery.

12. Conclusions

Bronchial atresia is a congenital abnormality with characteristic radiological features: a nodule or a mass like a shadow close to the hilum, with well-defined margins, presenting as a tubular, round, ovoid or branching structure and distal oligoemia and hyperinflation.

When it is required to do differential diagnosis over bronchial obstruction, bronchial atresia should be kept in mind.

Knowledge of this condition in patients with suspected bronchial obstruction would avoid unnecessary surgery. Currently, surgical excision is reserved only for patients with secondary complications to the atretic bronchus. Most surgeons try to preserve as much normal lung parenchyma as possible to maintain pulmonary function, whilst others prefer to resect the atretic segment.

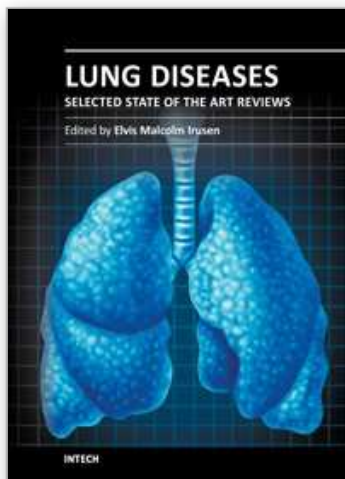
13. References

- Acosta Gordillo, L.; Márquez Fernández, J. & Medina Gil, M.C. Asymptomatic congenital bronchial atresia in a 10-year-old boy. *Anales de Pediatría*, Vol. 62, No.4, (April 2005), pp. 386-388, ISSN 1695-4033
- Agarwal, P.P.; Matzinger, F.R. & Seely, J.M. An unusual case of systemic arterial supply to the lung with bronchial atresia. *American Journal of Roentgenology*, Vol.185, No.1, (July 2005), pp. 150-153, ISSN 0361-803X

- Amin, M.U.; Rahim, A. & Nafees, M. Mucocoele formation due to congenital bronchial atresia-a rare cause of solitary pulmonary nodule. *Journal of the Pakistan Medical Association*, Vol.57, No.2, (February 2007), pp. 98-101, ISSN 0030-9982
- Bonnefoy, C.; Blanc, P. & Coste, K. Prenatal diagnosis of lobar bronchial atresia. *Ultrasound in Obstetrics & Gynecology*, Vol.37, No.1, (January 2011), pp. 110-112, ISSN 0960-7692
- Bucher, U. & Reid, L. Development of the intrasegmental bronchial tree: the pattern of branching and development of cartilage at various stages of intra-uterine life. *Thorax*, Vol.16, (September 1961), pp. 207-218, ISSN 0040-6376
- Cappeliez, S.; Lenoir, S. & Validire, P. Totally endoscopic lobectomy and segmentectomy for congenital bronchial atresia. *European Journal of Cardio-Thoracic Surgery*, Vol.36, No.1, (July 2009), pp. 222-224, ISSN 1010-7940
- Ch'in, K.T. & Tang, M.Y. Congenital adenomatoid malformation of one lobe of lung with general anasarca. *Archives of Pathology*, Vol.48, No.3, (September 1949), pp. 221-229, ISSN 0361-7017
- Cohen, M.D.; Scales, R.L. & Eigen, H. Evaluation of pulmonary parenchymal disease by magnetic resonance imaging. *The British Journal of Radiology*, Vol.60, No.711, (March 1987), pp. 223-230, ISSN 0007-1285
- Colin, A.A.; Reid, L.M. & Kozakewich, H.P. Bronchial atresia is common to extralobar sequestration, intralobar sequestration, congenital cystic adenomatoid malformation, and lobar emphysema. *Pediatric and Developmental Pathology*, Vol.9, No.5, (September-October 2006), pp. 361-373, ISSN 1093-5266
- Curran, P.F.; Jelin, E.B. & Rand, L. Prenatal steroids for microcystic congenital cystic adenomatoid malformations. *Journal of Pediatric Surgery*, Vol.45. No.1, (January 2010), pp. 145-150, ISSN 0022-3468
- Daoud, B.; Moncada, R. & Ali, J. Lung mass in a smoker. *Chest*, Vol.119. No.3, (March 2001), pp. 947-949, ISSN 0012-3692
- Cohen, A.M.; Solomon, E.H. & Alfidi, R.J. Computed tomography in bronchial atresia. *American Journal of Roentgenology*, Vol.135, No.5, (November 1980), pp. 1097-1099, ISSN 0361-803X
- Discioscio, V.; Feraco, P. & Bazzocchi, A. Congenital cystic adenomatoid malformation of the lung associated with bronchial atresia involving a different lobe in an adult patient: a case report. *Journal of Medical Case Reports*, Vol.28, No.4, (May 2010), pp. 164, ISSN 1752-1947
- Gipson, M.G.; Cummings, K.W. & Hurth, K.M. Bronchial atresia. *Radiographics*, Vol.29, No.5, (September-October 2009), pp. 1531-1535, ISSN 0271-5333
- Hadchouel, A.; Benachi, A. & Delacourt, C. Outcome of prenatally diagnosed bronchial atresia. *Ultrasound in Obstetrics & Gynecology*, Vol.38, No.1, (July 2011), pp. 119-120. ISSN 0960-7692
- Hadchouel, A.; Benachi, A. & Revillon, Y. Factors associated with partial and complete regression of fetal lung lesions. *Ultrasound in Obstetrics & Gynecology*, Vol.38, No.1, (July 2011), pp. 88-93, ISSN 0960-7692
- Hooker, I.D. & Hendriksz, T.R. A woman with an abnormality in the lung. *Nederlands Tijdschrift voor Geneeskunde*, Vol.155, No.8, (June 2011), pp. A1170, ISSN 0028-2162
- Jederlinic, P.J.; Sicilian, L.S. & Baigelman, W. Congenital bronchial atresia. A report of 4 cases and a review of the literature. *Medicine*, Vol.66. No.1, (January 1987), pp. 73-83, ISSN 0025-7974

- Jeung, M.Y.; Gasser, B. & Gangi, A. Bronchial carcinoid tumors of the thorax: spectrum of radiologic findings. *Radiographics*, Vol.22, No.2, (March-April 2002), pp. 351-365, ISSN 0271-5333
- Jung, H.J.; Kim, J.B. & Im, K.S. Failure of epidural analgesia converted to epidural anesthesia for cesarean delivery in a patient with bronchial atresia in labor. *The Journal of Obstetrics and Gynaecology Research*, Vol.37, No.6, (June 2011), pp. 613-616, ISSN 1341-8076
- Kamata, S.; Sawai, T. & Usui, N. Case of congenital bronchial atresia detected by fetal ultrasound. *Pediatric Pulmonology*, Vol.35, No.3, (March 2003), pp. 227-229, ISSN 8755-6863
- Kameyama, K.; Okumura, N. & Kokado, Y. Congenital bronchial atresia associated with spontaneous pneumothorax. *The Annals of Thoracic Surgery*, Vol.82, No.4, (October 2006), pp. 1497-1499, ISSN 0003-4975
- Kinsella, D.; Sissons, G. & Williams, M.P. The radiological imaging of bronchial atresia, *The British Journal of Radiology*, Vol.65, No.776, (August 1992), pp. 681-685, ISSN 0007-1285
- Ko, S.F.; Lee, T.Y. & Kao, C.L. Bronchial atresia associated with epibronchial right pulmonary artery and aberrant right middle lobe artery. *The British Journal of Radiology*, Vol.71, No.842, (February 1998), pp. 217-220, ISSN 0007-1285
- Kuhn, C. & Kuhn, J.P. Coexistence of bronchial atresia and bronchogenic cyst: diagnostic criteria and embryologic considerations. *Pediatric Radiology*, Vol.22, No.8, (June 1992), pp. 568-570, ISSN 0301-0449
- Lacquet LK, Fornhoff M, Dierickx R & Buysens N (1971). Bronchial atresia with corresponding segmental pulmonary emphysema. *Thorax*, Vol.26, No.1, (January 1971), pp. 68-73, ISSN 0040-6376
- Louw, J.H. & Barnard, C.N. Congenital intestinal atresia; observations on its origin. *Lancet*, Vol.269, No.6899, (November 1955), pp. 1065-1067, ISSN 0140-6736
- Matsushima, H.; Takayanagi, N. & Satoh, M. Congenital bronchial atresia: radiologic findings in nine patients. *Journal of Computer Assisted Tomography*, Vol.27, No.1, (January-February 2003), pp. 103, ISSN 0363-8715
- McAlister, W.H.; Wright, J.R. Jr. & Crane, J.P. Main-stem bronchial atresia: intrauterine sonographic diagnosis. *American Journal of Roentgenology*, Vol.148, No.2, (February 1987), pp. 364-366, Vol.135, No.5, (November 1980), pp. 1097-1099, ISSN 0361-803X
- Miyahara, N.; Eda, R. & Makihara, S. Bronchial atresia with transient spontaneous disappearance of a mucocoele. *Internal Medicine*, Vol.38, No.12, (December 1999), pp. 974-978, ISSN 0918-2918
- Morikawa, N.; Kuroda, T. & Honna, T. Congenital bronchial atresia in infants and children. *Journal of Pediatric Surgery*, Vol.40, No.12, (December 2005), pp. 1822-1826, ISSN 0022-3468
- Murat, A.; Ozdemir, H. & Yildirim, H. Bronchial atresia of the right lower lobe. *Acta Radiologica*, Vol.46, No.5, (August 2005), pp. 480-483, ISSN 0001-6926
- Naidich, D.P.; Rumancik, W.M. & Ettenger, N.A. Congenital anomalies of the lungs in adults: MR diagnosis. *American Journal of Roentgenology*, Vol.151, No.1, (July 1988), pp. 13-19, ISSN 0361-803X
- Niimi, T. & Gotoh, M. Pneumothorax secondary to congenital bronchial atresia. *Kyobu Geka*, Vol.63, No.4, (April 2010), pp. 324-327, ISSN 0021-5252
- Nussbaumer-Ochsner, Y. & Kohler, M. Finger-in-glove sign in bronchial atresia. *Thorax*, Vol.66, No.2, (February 2011), pp. 182, ISSN 0040-6376
- Okuda, M.; Huang, C.L. & Masuya, D. Lobar bronchial atresia demonstrating a cystic lesion without overinflation. *European Journal of Cardio-Thoracic Surgery*, Vol.30, No.2, (August 2006), pp. 391-393. ISSN 1010-7940

- Pamer, M.J. & Lenhardt, R. Bronchial Atresia With Mucocoeles and Concurrent Sinus Mucocoeles: First Reported Case and a Review of the Literature. *Clinical Pulmonary Medicine*, Vol.15, No.2, (March 2008), pp. 122-125, ISSN 1068-0640
- Pedicelli, G.; Ciarpaglini, L.L. & De Santis, M. Congenital bronchial atresia (CBA). A critical review of CBA as a disease entity and presentation of a case series. *La Radiologia Medica*, Vol.110. No.5-6, (November-December 2005), pp. 544-553, ISSN 0033-8362
- Primetis, E.; Koureas, A. & Dalakidis, A. Congenital bronchial atresia with a calcified mucocoele. *Respiration*, Vol.81, No.6, (June 2011), pp. 511-522, ISSN 0025-7931
- Psathakis, K.; Lachanis, S. & Kotoulas, C. The prevalence of congenital bronchial atresia in males. *Monaldi Archives for Chest Disease*, Vol.61, No.1, (January-March 2004), pp. 28-34, ISSN 1122-0643
- Psathakis, K.; Eleftheriou, D. & Boulas, P. Congenital bronchial atresia presenting as a cavitary lesion on chest radiography: a case report. *Cases Journal*, Vol.2, No.1, (January 2009), pp. 17, ISSN 1757-1626
- Rahalkar, A.M.; Rahalkar, M.D. & Rahalkar, M.A. Pictorial Essay: All About Bronchial Atresia. *The Indian Journal of Radiology and Imaging*, Vol.15, No.3, (June 2005), pp. 389-393, ISSN 0971-3026
- Ramsay, B.H. & Byron, F.X. Mucocoele, congenital bronchiectasis, and bronchogenic cyst. *The Journal of thoracic surgery*, Vol.26, No.1, (July 1953), pp. 21-30, ISSN 0096-5588
- Reid, L. 1976 Edward B.D. Neuhauser lecture: The Lung: Growth and Remodeling in Health and Disease. *American Journal of Roentgenology*, Vol.129, No.5, (November 1977), pp. 777-788, ISSN 0361-803X
- Sacristán Bou, L.; Martín Serrano, C. & Romero Candeira, S. Bronchial atresia together with a gonadal teratoma: what is the relationship? *Archivos de Bronconeumología*, Vol.46, No.5, (May 2010), pp. 278-279, ISSN 0300-2896
- Sadler, T.W. & Langman, J. (1990). *Langman's medical embryology* (6th edition), Williams & Wilkins, ISBN 978-068-3074-93-2/0683074938, Baltimore, United States.
- Shimizu, K.; Masuda, K. & Hebisawaa, A. A surgical case of congenital bronchial atresia with right-sided descending aorta. *Nihon Kokyuki Gakkai Zasshi*, Vol.48, No.3, (March 2010), pp. 210-213, ISSN 1343-3490
- Siddiqui, T.S.; Ul Haq, I. & Rehman, B. Bronchial atresia with partial anomalous pulmonary venous return. *Journal of the College of Physicians and Surgeons--Pakistan*, Vol.21, No.6, (June 2011), pp. 362-363, ISSN 1022-386X
- Van Klaveren, R.J.; Morshuis, W.J. & Lacquet, L.K. Congenital bronchial atresia with regional emphysema associated with pectus excavatum. *Thorax*, Vol.47, No.12, (December 1992), pp. 1082-1083, ISSN 0040-6376
- Waddell, J.A.; Simon, G. & Reid, L. Bronchial Atresia of the left upper lobe. *Thorax*, Vol.20, (May 1965), pp. 214-218, ISSN 0040-6376
- Ward, S. & Morcos, S.K. Congenital bronchial atresia--presentation of three cases and a pictorial review. *Clinical Radiology*, Vol.54, No.3, (March 1999), pp. 144-148, ISSN 0009-9260
- Wilson, E.P.; Patel, J. & Logalbo, F. An Adult Case of Bronchial Atresia Mimicking Pulmonary Embolism. *Clinical Pulmonary Medicine*, Vol.16, No.1, (January 2009), pp. 57-59, ISSN 1068-0640
- Woodring, J.H. Unusual radiographic manifestations of lung cancer. *Radiologic Clinics of North America*, Vol.28, No.3, (May 1990), pp. 599-618, ISSN 0033-8389
- Zribi, H.; Brian, E. & Lenoir, S. Congenital bronchial atresia in adults. *Revue des Maladies Respiratoires*, Vol.28, No.5, (May 2011), pp. 672-676, ISSN 0761-8425



Lung Diseases - Selected State of the Art Reviews

Edited by Dr. Elisegran Malcolm Irusen

ISBN 978-953-51-0180-2

Hard cover, 690 pages

Publisher InTech

Published online 02, March, 2012

Published in print edition March, 2012

The developments in molecular medicine are transforming respiratory medicine. Leading clinicians and scientists in the world have brought their knowledge and experience in their contributions to this book. Clinicians and researchers will learn about the most recent advances in a variety of lung diseases that will better enable them to understand respiratory disorders. This treatise presents state of the art essays on airways disease, neoplastic diseases, and pediatric respiratory conditions. Additionally, aspects of immune regulation, respiratory infections, acute lung injury/ARDS, pulmonary edema, functional evaluation in respiratory disorders, and a variety of other conditions are also discussed. The book will be invaluable to clinicians who keep up with the current concepts, improve their diagnostic skills, and understand potential new therapeutic applications in lung diseases, while scientists can contemplate a plethora of new research avenues for exploration.

How to reference

In order to correctly reference this scholarly work, feel free to copy and paste the following:

Lirios Sacristán Bou and Francisco Peña Blas (2012). Bronchial Atresia, Lung Diseases - Selected State of the Art Reviews, Dr. Elisegran Malcolm Irusen (Ed.), ISBN: 978-953-51-0180-2, InTech, Available from: <http://www.intechopen.com/books/lung-diseases-selected-state-of-the-art-reviews/bronchial-atresia>

INTech
open science | open minds

InTech Europe

University Campus STeP Ri
Slavka Krautzeka 83/A
51000 Rijeka, Croatia
Phone: +385 (51) 770 447
Fax: +385 (51) 686 166
www.intechopen.com

InTech China

Unit 405, Office Block, Hotel Equatorial Shanghai
No.65, Yan An Road (West), Shanghai, 200040, China
中国上海市延安西路65号上海国际贵都大饭店办公楼405单元
Phone: +86-21-62489820
Fax: +86-21-62489821

© 2012 The Author(s). Licensee IntechOpen. This is an open access article distributed under the terms of the [Creative Commons Attribution 3.0 License](https://creativecommons.org/licenses/by/3.0/), which permits unrestricted use, distribution, and reproduction in any medium, provided the original work is properly cited.

IntechOpen

IntechOpen