

We are IntechOpen, the world's leading publisher of Open Access books Built by scientists, for scientists

6,900

Open access books available

186,000

International authors and editors

200M

Downloads

Our authors are among the

154

Countries delivered to

TOP 1%

most cited scientists

12.2%

Contributors from top 500 universities



WEB OF SCIENCE™

Selection of our books indexed in the Book Citation Index
in Web of Science™ Core Collection (BKCI)

Interested in publishing with us?
Contact book.department@intechopen.com

Numbers displayed above are based on latest data collected.
For more information visit www.intechopen.com



Nocardia Infection in Lung Transplantation

Pilar Morales¹, Ana Gil-Brusola² and María Santos²

¹Lung Trasplant Unit, ²Microbiology Department,
Hospital Universitario La Fe, Valencia
Spain

1. Introduction

Organ transplant recipients (OTR) in general and, in particular, lung transplant recipients (LTx) – due to their underlying disease, extensive surgery, and the continual and profound immunosuppression to which they are subjected – become perfect targets for the development of infections. These are more frequent and severe than in the non-transplanted population, and may be caused by either common or less frequent opportunistic pathogens such as the *Nocardia* species.

Nocardia are ubiquitous bacteria found mainly in soil, organic matter and water (Lerner, 1996). Based on the available literature and on our own experience, we know that they can cause infections in both immunocompetent (40%) and immunocompromised patients (B.L. Beaman & L. Beaman, 1994), with a low frequency in transplantations in general, which is somewhat higher in LTx. Onset of disease is generally insidious and it is difficult to diagnose and treat. It produces mainly respiratory symptoms, but complications can occur, spreading to other organs and causing high mortality. In this chapter, we intend to review various epidemiological, clinical, diagnostic, therapeutic and prophylactic aspects of *Nocardia* infections in adult LTx.

2. Epidemiology and pathogenesis

2.1 General aspects

The genus *Nocardia* includes aerobic, gram-positive, weakly acid-fast bacteria of the order Actinomycetales. Other microorganisms that belong to this order are *Corynebacterium*, *Rhodococcus*, *Gordonia*, *Tsukamurella*, *Actinomadura* and *Mycobacterium*, particularly rapidly growing nontuberculous mycobacteria (Sorrell et al., 2005), which can also cause infections in humans. More than 50 species of *Nocardia* have been defined either phenotypically or by molecular methods (Brown-Elliott et al., 2006). Originally, only 10-12 species were known to cause disease in humans, the most frequently described being *N. asteroides*, *N. nova*, *N. farcinica*, *N. transvalensis*, *N. brasiliensis*, *N. pseudobrasiliensis*, *N. otitidiscaviarum* and *N. brevicatena* complex, with variations according to different environments and authors. Nowadays, taxonomy of this genus has undergone considerable changes due to modern molecular techniques, such as identification by 16S ribosomal RNA gene sequencing. New species have been described, such as *N. cryacigeorgica* (Schlaberg et al., 2008), *N. veterana* (Pottumarthy et al., 2003), *N. abscessus* (Yassin et al., 2000), *N. paucivorans* (Eisenblatter et al.,

2002) and *N. kruczakiae* (Conville et al., 2004), which should be taken into account in case of isolation in LTx samples.

Immune response to *Nocardia* is T-cell mediated (Deem, 1983). Therefore, the reduced cellular immune response of solid OTR is one of the major factors predisposing a patient to infection; in fact, 60% of cases occurs in immunocompromised patients.

2.2 Frequency

Estimated frequency of *Nocardia* infection among solid OTR globally ranges from 0.1 to 3.5 (Peleg et al., 2007a). In the past, these cases were more frequent in kidney, heart and liver transplantations, and less in LTx (Husain et al., 2002), but recently infections in the latter have been described as the most frequent (3.5%, Peleg et al., 2007a; 1.8%, Santos et al., 2011; 1.9%, Ponyagariyagorn et al., 2008). This increased risk of *Nocardia* infection in LTx may be due to several factors: a) the graft may have anatomical deficiencies, including lung denervation, reduced cough reflex and poor mucociliary clearance (Kramer et al., 1993; Husain et al., 2002); b) the organ has been continuously exposed to the atmosphere, with constant stimulation of the lung by environmental antigens and an increased risk of rejection; and, therefore, c) a need for more intense immunosuppression than in other solid OTR. Moreover, high average levels of calcineurin inhibitors 30 days prior to infection have been independently associated with subsequent infection by *Nocardia* (Hewagama et al., 2011).

The most frequently reported species of *Nocardia* in LTx, with variations in percentage in different studies, are *N. nova*, *N. farcinica*, *N. asteroides* and *N. brasiliensis*.

2.3 Risk factors

There are two multivariate studies (Peleg et al., 2007a; Martinez-Tomás et al., 2007) which investigate the influence of several variables as risk factors for *Nocardia* infection in solid OTR. Among them, three have been described as independent: a) the doses of immunosuppressive therapy, as already mentioned; b) chronic use of corticosteroids; and c) cytomegalovirus disease in the previous 6 months (Paya, 1999).

The relationship between opportunistic infections, including nocardiosis, and alemtuzumab, a monoclonal antibody that targets the antigen CD52 and is used to prevent graft rejection (Basu et al., 2005; Peleg et al., 2007 b) by causing profound lymphopaenia, has been also reported. Moreover, the use of rituximab (Kundranda et al., 2007), another immunomodulator that targets the CD20 protein found on B cells and used in solid OTR to prevent or treat antibody-mediated rejection, has also been described.

Finally, hypogammaglobulinaemia, combined with immunosuppression, may favour the development of *Nocardia* infections (Corales et al., 2000), as has been observed in heart transplantation.

Renal failure, prolonged respiratory support and early graft rejection may also be risk factors but have not yet been demonstrated in multivariate analysis.

2.4 Transmission

The main route for *Nocardia* infection is inhalation of aerosolised microorganisms. From the respiratory tract, bacteria can then move to other organs, the most commonly and seriously

affected being the central nervous system (CNS). Involvement of skin and subcutaneous tissue, bones and joints, retina and, less frequently, other organs or structures (heart, kidney, peritoneum, endocardium, testicles, etc.) is also possible. Primary cutaneous infection can occur by direct inoculation in both immunocompetent and immunocompromised patients (Brown-Elliott et al., 2006). There is no evidence for human-to-human transmission and disease presents mainly as isolated cases, although an outbreak related to contamination by dust pollution (Sahathevan et al., 1991) in a liver transplantation unit and some spread by contamination of hands in a cardiovascular surgery unit (Wenger et al., 1998) have been documented based on molecular data.

3. Symptoms and radiology

Time of onset of infection after transplantation is variable, but tends to be late. It rarely occurs in the first month and may range from 1 to 28 years (Santos et al., 2011). The greatest risk is within the first year (Peleg et al., 2007a, Clark, 2009), but later cases have also been described (Peraira et al., 2003, Oszoyoglu et al., 2007). Pulmonary presentation is the most common, with subacute and insidious pneumonia. Less frequent is the cutaneous form, following a minor injury or by direct inoculation (Ambrosioni et al., 2010). Symptoms are usually non-specific and include fever, fatigue, dyspnoea, cough and pleuritic pain (Patel & Payá, 1997; Minero et al., 2009). Common radiographic abnormalities include irregular nodular lesions which may cavitate, diffuse interstitial infiltrates and lung consolidation with parapneumonic pleural effusion (Balikian et al., 1978; Morales et al., 2011) (Figure 1). Both lungs are usually affected, without significant anatomical or zonal distribution (Oszoyoglu et al., 2007). In the case of single-lung transplantation, *Nocardia* can infect both the native and the transplanted organ (Husain et al., 2002).

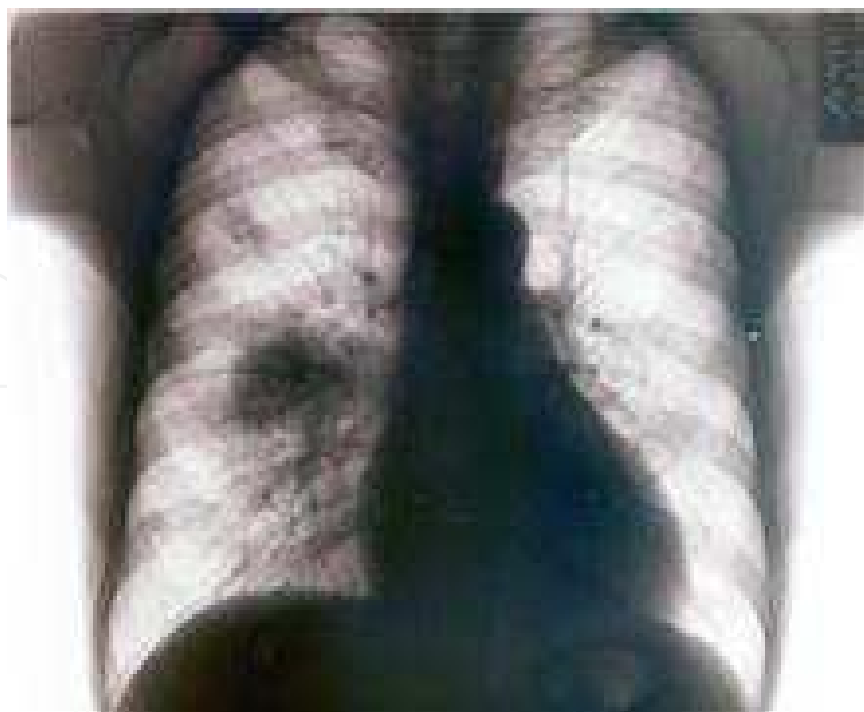

Fig. 1. Radiographic changes associated with Nocardia infection.

Haematogenous spread has been reported in up to 50% of cases (Clark, 2009), so it is important to exclude *Nocardia* clinically and/or radiologically in other organs, especially in the CNS (Singh & Husain, 2000). Moreover, and especially when the patient has a central venous catheter, blood should be cultured to rule out *Nocardia*. Cerebral involvement may be asymptomatic, therefore requiring neuroimaging with magnetic resonance or high resolution computed tomography (Ambrosini et al., 2010), or symptomatic, with headache, vomiting, altered level of consciousness, focal signs and seizures. Multiple radiographic cerebral lesions are observed in 40% (Singh & Husain, 2000). Meningitis is uncommon. Other forms of presentation of dissemination are cutaneous, ocular, intestinal, testicular and bone and joint disorders. Primary as well as disseminated cutaneous forms may present as subcutaneous nodules, cellulitis, abscess, mycetoma and sporotrichoid skin changes (Merigou et al., 1998). In this location, *N. brasiliensis* is the most common. The presence of the cutaneous form in organ transplant recipients should be followed by the exclusion of other forms of presentation of nocardiosis.

We must take into account the possible and frequent co-infections that occur with common and opportunistic bacteria, viruses, especially CMV, and fungi, mainly *Aspergillus* (Cabada et al., 2010) that make the patient's clinical and therapeutic management difficult (Santos et al., 2011). Differential diagnosis of pulmonary infection and brain nodule must include *Nocardia*, *Aspergillus* spp., *Cryptococcus neoformans*, *Mycobacteria*, *Rhodococcus equi*, post-transplant lymphoproliferative disease and primary lung cancer with metastasis.

4. Microbiological diagnosis

Definitive diagnosis of nocardiosis requires microscopic observation, isolation or nucleic acid detection of *Nocardia* in one or more samples from a suspected site. Specimen collection can be spontaneous, such as in the case of sputum (which is useful in up to 53% of cases), superficial such as in the case of a skin smear, or may require deeper samples such as bronchoaspirate, bronchoalveolar lavage or tissue biopsies. Smear staining with Gram stain, Ziehl-Neelsen (ZN) and modified ZN is the most useful and fastest diagnostic method. It can provide a diagnosis within the first few hours, showing abundant gram-positive or partially acid-fast branched bacilli (Figure 2), which are very characteristic of *Nocardia*, with moderate or abundant leukocytes resulting from the inflammatory response.

Differential diagnosis with *Rhodococcus*, *Gordonia* and rapidly growing mycobacteria must be considered, as discussed above. This information provides a reliable presumptive diagnosis and may guide empiric antibiotic therapy. Although *Nocardia* may grow in non-selective culture media, samples that can be contaminated with normal flora, such as those from the respiratory tract, should also be cultured in selective media such as Thayer-Martin agar with antibiotics (Shawar et al., 1990). Typical colonies appear chalky white (Figure 3) with aerial hyphae. Its growth is aerobic and may take from 2 to 5 days, sometimes even a week.

Species identification may be by phenotypic, at least for the most common *Nocardia*, but genotypic methods such as polymerase chain reaction (PCR), restriction endonuclease analysis and sequencing of a portion of the 16S rRNA gene provide a safer and more accurate diagnosis. These techniques, however, are carried out by a limited number of laboratories (Brown-Elliott et al., 2006).

Identification of the species can be useful to guide treatment, since some have intrinsic resistance to several antibiotics, or to predict prognosis, since some species, such as *N.*

farcinica, are more virulent. In cases in which disseminated nocardiosis is suspected, *Nocardia* can also be isolated from a blood culture, although this is rare.

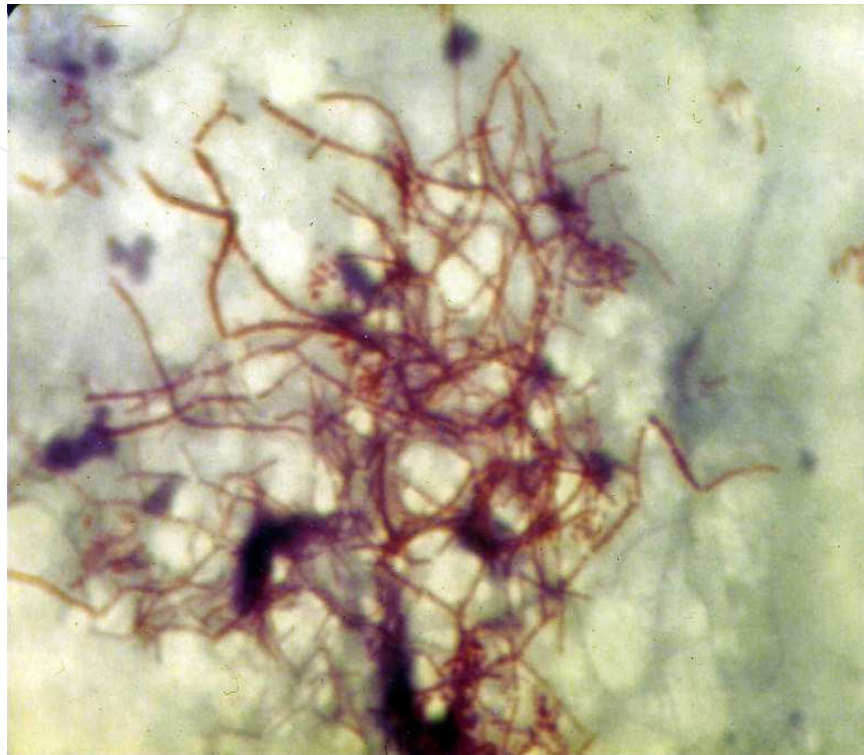


Fig. 2. Nocardia ZN stain.

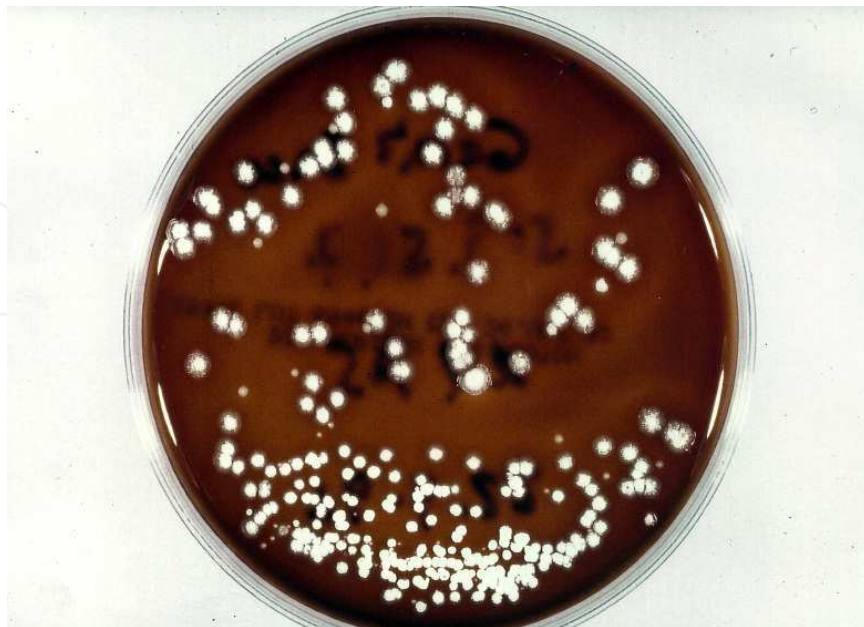

Fig. 3. Colonies of Nocardia.

Antimicrobial susceptibility testing of the *Nocardia* isolate is strongly recommended by the Clinical Laboratory Standard Institute (CLSI), which published the first approved methods in 2003 (Wayne, 2003). Primary susceptibility testing must include amikacin, amoxicillin/clavulanic acid, ceftriaxone, ciprofloxacin, clarithromycin, imipenem, linezolid, minocycline, trimethoprim-sulfamethoxazole (TMP/SMX) and tobramycin. Secondary recommendations include cefepime, cefotaxime, doxycycline, gentamicin and moxifloxacin. Some species of *Nocardia* have more predictable susceptibility patterns or, in other words, there are patterns of known resistance, such as *N. otitidiscaviarum* to imipenem, or the multi-resistance of *N. farcinica*, so it is sometimes necessary to perform *in vitro* synergy studies. The susceptibility patterns of the most common *Nocardia* can be seen in table 1.

	<i>N. asteroides</i>	<i>N. nova</i>	<i>N. farcinica</i>	<i>N. brasiliensis</i>
TMP/SMX	S (91-100)	S (89-100)	S (89-100)	S (100)
AMC	R (0-70)	R (3-50)	S (40-100)	S (65-100)
CEF	S (75-100)	S (70-100)	S (70-100)	V (50-100)
IMP	S (70-100)	S (100)	S (100)	V (0-100)
AMK	S (85-100)	S (100)	S (100)	S (100)
LZD	S (100)	S (100)	S (100)	S (100)
MIN	V (25-100)	V (29-100)	V (12-96)	S (0-100)
CIP	R(0-98)	R (0)	S (50-100)	R (0-30)
MXF	(50)	-	(88)	-

Table 1. Expected and reported antimicrobial susceptibility of selected *Nocardia* species (% of isolates susceptible in various series). Composite data from references (Clark, 2009; Hewagama et al., 2011; Brown-Elliott et al., 2001). TMP/SMX, trimethoprim-sulfamethoxazole; AMC, amoxicillin/clavulanic acid; CEF, ceftriaxone; IMP, imipenem; AMK, amikacin; LZD, linezolid; MIN, minocycline; CIP, ciprofloxacin; MXF, moxifloxacin; S, sensitive; R, resistant; V, variable.

5. Treatment and evolution

5.1 General aspects

Treatment of *Nocardia* infections in LTx is based primarily on antibiotics. In some cases, such as brain or cutaneous abscesses that do not respond to initial antibacterial therapy, surgical drainage is also required and, whenever possible, especially in more severe cases, a reduction of immunosuppressive therapy should be applied. The best treatment has not yet been determined. In the past, the antimicrobial of choice was TMP/SMX, but since the development of new antibiotics, *in vitro* synergy studies, the insidious nature of the disease and its high mortality, the recommendation is a combination of two or three drugs (Clark, 2009).

There are few studies correlating susceptibility data with clinical outcome (Sorrell et al., 2005), so the best combination is uncertain. Nevertheless, it is often chosen on the basis of: a)

the species of *Nocardia* isolated; b) its sensitivity to antibiotics and possible interactions with the complex medication of transplanted patients; c) the location, extent and severity of the infection; and d) the experts' opinion and documented experience in the literature.

5.2 Empiric therapy

According to clinical experience, TMP/SMX remains the antimicrobial agent of choice for many *Nocardia* infections (Hewagama et al., 2011), supported by the *in vitro* synergy of its two components, the fact that it reaches high levels in lung, brain, skin and bone (Smego et al., 1983) and that it can be used as intravenous or oral maintenance therapy (Table 2). The main side effects include rash, nausea, vomiting, erythema multiforme, bone marrow suppression, hyperkalaemia and crystalluria, which may limit its use. Some species – *N. farcinica*, *N. otitidiscaviarum* and *N. nova* – may be resistant to sulphonamides, so it is important to determine the species and its *in vitro* susceptibility. These resistances and possible allergies to sulphonamides promoted the search for alternative antibiotics. Amikacin is universally active against most *Nocardia* species, except for *N. transvaliensis* and *N. brasiliensis*. The main limitations for its use are optical and renal toxicity. The combination of imipenem and amikacin is accepted as initial therapy in patients with severe nocardiosis (Minero et al., 2009) while the antibiogram is pending. This antibiotic combination is additive and synergic *in vitro* (Kanemitsu et al., 2003), maintains synergy when associated with sulphonamides (Gombert et al., 1986) and is effective in humans, so this triple combination has also been recommended as first-line treatment in patients with severe disease including dissemination to the CNS, where it is always better to use at least two drugs with good intracranial diffusion and, when severe, a triple combination (Ambrosioni et al., 2010). During the administration of amikacin and imipenem, doses should be adjusted according to renal function and auditory function should be monitored. In addition, in LTx, co-administration of cyclosporine or tacrolimus with amikacin may enhance the nephrotoxicity of aminoglycosides.

INFECTION	PRIMARY THERAPY	ALTERNATIVE THERAPY
Primary cutaneous	TMP/SMX*	TMP/SMX+ Fluoroquinolone
Pulmonary stable	TMP/SMX iv or po	Imipenem+amikacin or minocycline or linezolid
Pulmonary critical	Imipenem+amikacin or TMP/SMX	Linezolid
Cerebral	Imipenem+amikacin or TMP/SMX	Linezolid or ceftriaxone or cefotaxime or minocycline
Disseminated	Imipenem+amikacin or TMP/SMX	Ceftriaxone, cefotaxime, linezolid or minocycline

Table 2. Antibiotics suggested for *Nocardia* infections in organ recipients (Clark, 2009, Ambrosioni et al., 2010, modified). TMP/SMX, trimethoprim-sulfamethoxazole.

As regards the carbapenems, imipenem and meropenem have a similar spectrum of activity and effectiveness and, although the latter is somewhat less effective against *N. asteroides complex* (NAC) and more effective against *N. brasiliensis* and *N. otitidiscaviarum*, it is preferred in cases with CNS involvement, since imipenem has been associated with

seizures. Ertapenem has slightly less activity against several species of *Nocardia* and doripenem, with a similar spectrum of antibiotic activity to meropenem (Lai et al., 2009) but without CNS penetration, has not been tested.

Other beta-lactam antibiotics such as the third-generation cephalosporins ceftriaxone or cefotaxime, due to their good CNS penetration, may be combined with other antimicrobials for treatment of intracranial infections with good results, depending on the species of *Nocardia*, since some may be intrinsically resistant (Garlando et al., 1992; Durmaz et al., 2001).

5.3 Other alternatives

The literature includes experiences of varying degrees of success with other antibiotic treatments, including minocycline and tigecycline, macrolides, ampicillin, piperacillin/tazobactam, fluoroquinolones (ciprofloxacin, moxifloxacin and gatifloxacin), but experiences are limited and there is not enough scientific basis to include them in general recommendations. With moxifloxacin, which is active against *N. farcinica* (Hanse et al., 2008), good results have been obtained in some cases; however, in others there has been recurrence in the CNS, despite its activity and having achieved high levels of drug in the abscess material (Dahan et al., 2006).

In recent years, the oxazolidinone linezolid has been gathering attention due to its excellent activity against all species of *Nocardia*, including *N. farcinica* (Brown-Elliott et al., 2001). It has been used successfully, even in monotherapy, in six patients with disseminated nocardiosis (Moylett et al., 2003) and also in combination with other antimicrobials (Lewis et al., 2003; Rivero et al., 2008). It has extensive intravenous and oral bioavailability, crosses the blood-brain barrier, does not require renal or liver dose adjustments and has few interactions with immunosuppressive agents (Jodlowski et al., 2007), which makes it a very reasonable alternative as first- or second-line treatment of *Nocardia* infections in LTx (especially in cases of kidney involvement). Limitations on long-term use are conditioned by its high cost and possible toxicity, since, in addition to its minor adverse effects such as rash, nausea and vomiting, it may also induce, less frequently, thrombocytopaenia, aplastic anaemia, peripheral neuropathy, lactic acidosis and serotonin syndrome (Beekmann et al., 2008).

5.4 Duration of treatment

The optimal duration of treatment has not been standardised, but should be several months due to the difficulty of eradicating *Nocardia* and frequency of relapse (Sorrell et al., 2005). Most patients begin to improve in 1-2 weeks, but more severe cases must follow an additional 3 to 4 weeks of intravenous therapy before switching to oral treatment. Cerebral nocardiosis requires at least 9-12 months of treatment, whereas soft tissue and lung presentations require 6-12 months, depending on the clinical course and response to treatment (Clark, 2009). If the infection is associated with a central venous catheter, this must be removed and followed by administration of antibiotic treatment for several months.

5.5 Consolidation therapy

When the patient improves and intravenous treatment can be withdrawn, oral alternatives may include amoxicillin-clavulanate, TMP/SMX, linezolid, clarithromycin, ciprofloxacin and moxifloxacin as consolidation therapy. There are no trials comparing the effects of these

antibiotics. Some studies recommend a dual oral combination after severe infections, such as those involving the CNS (Sullivan & Chapman, 2010).

After discontinuation of treatment, the patient should be monitored for a minimum of one year to detect possible relapses. In some hospitals, prophylaxis is maintained for as long as the patient remains immunosuppressed (King et al., 1993; Poonyagariyagorn et al., 2008).

5.6 Evolution

Despite combined treatment, the prognosis is variable and depends heavily on: the extent of infection, the underlying conditions of the organ recipients and co-infections that precede or coincide with *Nocardia* infection (Peleg et al., 2007b). Overall mortality is around 40% (Husain et al., 2002). In CNS infections it is 30-55% (Mamelak et al., 1994) and in the lung about 14-18% (Poonyagariyagorn et al., 2008; Morales et al., 2011). The prognosis is better in isolated skin lesions, in which some studies report up to 90% healing.

Delayed diagnosis and discontinuation of treatment has also been associated with poor prognosis. There is little information on the crude mortality rate, because in many cases the patient died due to multiple causes and it is difficult to determine the impact of *Nocardia* infection on the final outcome.

6. Prevention/Prophylaxis

Given the low incidence of *Nocardia* infection in LTx and that its onset tends to be late, primary chemoprophylaxis is not indicated. However, in patients with solid organ transplant in general, TMP/SMX is administered daily for at least six months post-transplant and then on alternate days indefinitely to prevent infection by *Pneumocystis jiroveci* (Hewayama et al., 2011). Some works suggest that this prophylaxis reduces infection by *Nocardia* and this benefit extends to other microorganisms. Nevertheless, there is an increasing number of reports of TMP/SMX susceptible *Nocardia* isolations in transplant recipients taking this antibiotic as prophylaxis (Roberts et al., 2000; Husain et al., 2002; Poonyagariyagorn et al., 2008; Khan et al., 2008; Minero et al., 2009). This fact raises doubts concerning the prophylactic role of TMP/SMX to prevent nocardiosis. The lack of efficacy may be due to different protocols in SOT recipients. Relapse has also been documented in LTx (Poonyagariyagorn, 2008; Roberts et al., 2000) after one cycle of antibiotic treatment, possibly due to short-term duration or interruption, but the data are controversial with regard to recommending secondary prophylaxis. Long-term prophylaxis to prevent these relapses is only suggested in a few hospitals.

Moreover, considering that *Nocardia* is a ubiquitous microorganism, it is important to teach LTx to alter their lifestyle and adopt a careful and alert attitude in order to reduce their high epidemiological risk of exposure, especially in the community. Recently, Avery and Michaels have published an excellent guide to strategies for avoiding infection following solid organ transplantation (Avery & Michaels, 2009).

7. Peri-Transplant considerations

7.1 Pre-Transplant

The future LTx may have had an infection that has already been treated or that is still active during the pre-transplant evaluation period. In fact, this happens with some frequency in

patients with cystic fibrosis (CF). Neither situation, according to most experts and to our own experience, is an absolute contraindication for transplantation. Nevertheless, the patient must be monitored closely, being aware of possible relapses, complications or dissemination of infection, and ensuring full compliance with treatment.

7.2 Post-Transplant

Considerations are similar when nocardiosis occurs after transplantation, as we have previously discussed in the text, paying special attention to possible relapses.

7.3 Donor

Even though there is no documented case of *Nocardia* infection in the organ donor, nocardiosis would hypothetically be a relative contraindication for transplantation. In any case, treatment would be obligatory.

8. Final considerations

The practice of organ transplantation in general and lung transplantation in particular is a growing technique in the clinical setting and transplant recipients inevitably need immunosuppressive treatment. Therefore, the appearance of opportunistic infections, specifically nocardiosis, is expected. Given the nonspecific clinical and radiological signs, diagnosis of these infections is based on high clinical suspicion, proper sample collection and rapid microbiological diagnostic methods to confirm it and properly orient the antibiotic treatment as early as possible. The future challenge seems to be the application of molecular methods directly on the sample (Couble et al., 2005) and perhaps fewer but more effective and less toxic antibiotics, less aggressive immunosuppressive therapy and, overall, to try to avoid infection with a healthy lifestyle.

9. References

- Avery, RK., Michaels, MG., & AST Infectious Diseases Community of Practice. 2009. Strategies for safe-living following solid organ transplantation. *Am J Transplant*, Vol 9, No 4 Suppl, (December 2009), pp. S252-S257.
- Ambrosioni, J., Lew, D., Garbino, J. 2010. Nocardiosis: updated clinical review and experience at a tertiary center. *Infection*, Vol 38, No 2, (April 2010), pp. 89-97.
- Balikian, JP., Herman, PG., & Kopit, S. 1978. Pulmonary nocardiosis. *Radiology*, Vol 126, No 3, (Mars 1978), pp. 569-573.
- Basu, A., Ramkumar, M., Tan, HP., Marcos, A., Fung, JJ., Starzl, TE., Shapiro, TE., Khan A, & McCauley J. 2005. Reversal of acute cellular rejection after renal transplantation with Campath-1H. *Transplant Proc*, Vol 37, No 2, (Mars 2005), pp. 923-926.
- Beaman, BL., & Beaman, L. 1994. *Nocardia* species: host-parasite relationships. *Clin Microbiol Rev*, Vol 7, No 2, (April 1994), pp. 213-264.
- Beekmann, SE., Gilbert, DN., & Polgreen, PM. 2008. Toxicity of extended courses of linezolid: results of an Infectious Diseases Society of America Emerging Infections Network survey. *Diagn Microbiol Infect Dis*, Vol 62, No 4, (December 2008), pp. 407-410.

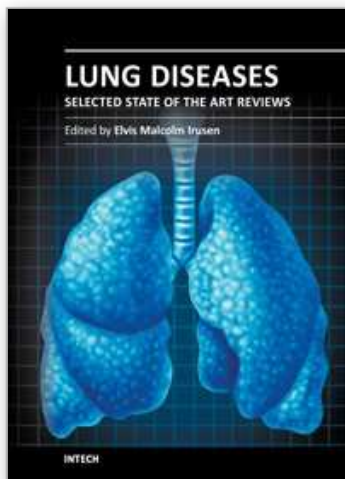
- Brown-Elliott, BA., Ward, SC., Crist, CJ., Mann, LB., Wilson, RW., & Wallace, RJ, Jr. 2001. In vitro activities of linezolid against multiple *Nocardia* species. *Antimicrob Agents Chemother*, Vol 45, No 4, (April 2001), pp. 1295-1297.
- Brown-Elliott, BA., Brown, JM., Conville, PS., & Wallace, RJ Jr. 2006. Clinical and laboratory features of the *Nocardia* spp. based on current molecular taxonomy. *Clin Microbiol Rev*, Vol 19, No 2, (April 2006), pp. 259-282.
- Cabada, MM., Nishi, SP., Lea, AS., Schnadig, V., Lombrad, GA., Lick, SD., & Valentine, VG. 2010. Concomitant pulmonary infection with *Nocardia transvalensis* and *Aspergillus ustus* in lung transplantation. *J Heart Lung Transplant*, Vol 29, No 8, (August 2010), pp. 900-903.
- Clark, NM., and the AST infectious diseases community of practice. 2009. *Nocardia* in solid organ transplant recipients. *Am J Transp*, Vol 9, No 4 Suppl, (December 2009), pp. S70-S77.
- Conville, PS., Brown, JM., Steigertwalt, AG., Lee, JW., Anderson, VL., Fishbain, JT., Holland, SM., & Witebsky, FG. 2004. *Nocardia kruczakiae* sp. nov., a pathogen in immunocompromised patients and a member of the "*N. nova* complex". *J Clin Microbiol*, Vol 42, No 11, (November 2004), pp. 5139-5145.
- Corales, R., Chua, J., Mawhorter, S., Young, JB., Starling, R., Tomford, JW., McCarthy, P., Braun, WE., Smedira, N., Hobbs, R., Haas, G., Pelegri, D., Majercik, M., Hoercher, K., Cook, D., & Avery, RK. 2002. Significant post-transplant hypogammaglobulinemia in six heart transplant recipients: An emerging clinical phenomenon? *Transpl Infect Dis*, Vol 2, No 3, (September 2002), pp. 133-139.
- Couble, A., Rodriguez-Nava, V., de Montclos, MP., Boiron, P., & Laurent F. 2005. Direct detection of *Nocardia* spp. In clinical samples by a rapid molecular method. *J Clin Microbiol*, Vol 43, No 4, (April 2005), pp. 1921-1924.
- Dahan, K., El Kabbaj, D., Venditto, M., Pastural, M., & Delahousse, M. 2006. Intracranial *Nocardia* recurrence during fluorinated quinolones therapy. *Transpl Infect Dis*, Vol 8, No 3, (September 2006), pp. 161-165.
- Deem, RL., Doughty, FA., & Beaman, BL. 1983. Immunologically specific direct T lymphocyte-mediated killing of *Nocardia asteroides*. *J Immunol*, Vol, 130, No 5, (May 1983), pp. 2401-2406.
- Durmaz, R., Atasoy, MA., Durmaz, G., Adapinar, B., Arslantas, A., Aydinli, A., & Tel E. 2001. Multiple nocardial abscesses of cerebrum, cerebellum and spinal cord, causing quadriplegia. *Clin Neurol Neurosurg*, Vol 103, No 1, (April 2001), pp. 59-62.
- Eisenblätter, M., Disko, U., Stoltenburg-Didinger, G., Scherübl, H., Schaal, KP., Roth, A., Ignatius, R., Keitz, M., Hahn, H., & Wagner, J. 2002. Isolation of *Nocardia paucivorans* from the cerebrospinal fluid of a patient with relapse of cerebral nocardiosis. *J Clin Microbiol*, Vol 40, No 9, (September 2002), pp. 3532-3534.
- Garlando, F., Bodmer, T., Lee, C., Zimmerli, W., & Pirovino, M. 1992. Successful treatment of disseminated nocardiosis complicated by cerebral abscess with ceftriaxone and amikacin. Case Report. *Clin Infect Dis*, Vol 15, No 6, (December 1992), pp. 1039-1040.
- Gombert, ME., Aulicino, TM., duBouchet, L., Silverman, GE., & Sheinbaum, WM. 1986. Therapy of experimental cerebral nocardiosis with imipenem, amikacin, trimethoprim sulfamethoxazole and minocycline antimicrob agents chemother. *Antimicrob Agents Chemother*, Vol 30, No 2, (August 1986), pp. 270-273.

- Hansen, G., Swanzy, S., Gupta, R., Cookson, B., & Limaye, AP. 2008. *In vitro* activity of fluoroquinolones against clinical isolates of *Nocardia* identified by partial 16S rRNA sequencing. *Eur J Clin Microbiol Infect Dis*, Vol 27, No 2, (February, 2008), pp. 115-120.
- Hewagama, S., Langan, K., Nishi, SP., Valentine, VG., & Peleg AY. Chapter 17. Elsevier Inc.. ISHLT Monographseries. Diagnosis and management of infectious diseases in cardiothoracic transplantation and mechanical circulatory support. ed. Mooney ML, Hannan MM, Husain S, Kirklin JK. 2011, vol 5. pp 175-186. ISSN 1930-2134. Philadelphia.
- Husain, S., McCurry, K., Dauber, J., Singh, N., & Kusne, S. 2002. *Nocardia* infection in lung transplant recipients. *J Heart Lung Transplant*, Vol 21, No 3, (March 2002), pp. 354-359.
- Jodlowski, TZ., Melnychuk, I., & Conry, J. 2007. Linezolid for the treatment of *Nocardia* spp. infections. *Ann Pharmacother*, Vol 41, No 10, (October 2007), pp. 1694-1699.
- Kanemitsu, K., Kunishima, H., Saga, T., Harigae, H., Ishikawa, S., Takemura, H., & Kaku, M. 2003. Efficacy of amikacin combinations for nocardiosis. *Tohoku J Exp Med*, Vol 201, No 3, (November, 2003), pp. 157-163.
- Khan, BA., Duncam, M., Reynolds, J., & Wilkes, DS. 2008. *Nocardia* infection in lung transplant recipients. *Clin Transplant*, Vol 22, No 5, (September-October 2008), pp. 562-566.
- King, CT., Chapman, SW., & Butkus, DE. 1993. Recurrent nocardiosis in a renal transplant recipient. *South Med J*, Vol 86, No 2, (February 1993), pp. 225-228.
- Kramer, MR., Marshall, SE., Starnes, VA., Gamberg, P., Amitai, Z., & Theodore, J. 1993. Infectious complications in heart lung transplantation. Analysis of 200 episodes. *Arch Intern Med*, Vol 153, No 17, (September 1993), pp. 2010-2016.
- Kundranda, MN., Spiro, TP., Muslimani, A., Gopalkrishna, KV., Melaragno, MJ., & Daw, HA. 2007. Cerebral nocardiosis in a patient with NHL treated with rituximab. *Am J Hematol*, Vol 82, No 11, (November, 2007), pp. 1033-1034.
- Lai, CC., Tan, CK., Lin, SH., Liao, CH., Chou, CH., Hsu, HL., Huang, YT., & Hsueh, PR. 2009. Comparative in vitro activities of nemonoxacin, doripenem, tigecycline, and 16 antimicrobials against *Nocardia brasiliensis*, *Nocardia asteroides* and unusual *Nocardia* species. *J Antimicrobial Chemother*, Vol 64, No 1, (July 2009), pp. 73-78.
- Lerner, PI. 1996. Nocardiosis. *Clin Infect Dis*, Vol 22, No 6, (June 1996), pp. 891-903.
- Lewis, KE., Ebdon, P., Wooster, SL., Rees, J., & Harrison, GA. 2003. Multisystem infection with *Nocardia farcinica*-therapy with linezolid and minocycline. *J Infect*, Vol 46, No 3, (April 2003), pp. 199-202.
- Mamelak, AN., Obana, WG., Flaherty, JF., & Rosenblum ML. 1994. Nocardial brain abscess: treatment strategies and factors influencing outcome. *Neurosurgery*, Vol 35, No 4, (October 1994), pp. 622-631.
- Martinez-Tomás, R., Menéndez-Villanueva, R., Reyes-Calzada, S., Santos-Durantez, M., Vallés-Tarazona, JM., Modesto-Alapont, M., & Gobernado-Serrano, M. 2007. Pulmonary Nocardiosis: risk factors and outcomes. *Respirology*, Vol 12, No 3, (May 2007), pp. 394-400.
- Merigou, D., Beylot-Barry, M., Ly, S., Doutre, MS., Texier-Maugein, J., Billes, P., & Beylot, C. 1998. Primary cutaneous *Nocardia asteroides* infection after heart transplantation. *Dermatology*, Vol 196, No 2, pp. 246-247.

- Minero, MV., Marín, M., Cerenado, E., Rabadán, PM., Bouza, E., & Muñoz, P. 2009. Nocardiosis at the turn of the century. *Medicine (Baltimore)*, Vol 88, No 4, (July 2009), pp. 250-261.
- Morales, P., Gil-Brusola, A., & Santos, M. 2011. *Nocardia* infection in lung transplant recipients: Twenty years review. *Am J Crit Care Med*, Vol 183, No 1, (May 2011), A4648.
- Moylett, EH., Pacheco, SE., Brown-Elliott, BA., Perry, TR., Buescher, ES., Birmingham, MC., Schentag, JJ., Gimbel, JF., Apodaca, A., Schwartz, MA., Rakita, RM., & Wallace, RJ Jr. 2003. Clinical experience with linezolid for the treatment of *Nocardia* infection. *Clin Infect Dis*, Vol 36, No 3 (February 2003), pp. 313-318.
- Oszoyoglu, AA., Kirsch, J., & Mohammed, TL. 2007. Pulmonary nocardiosis after lung transplantation: CT findings in 7 patients and review of literature. *J Thorac Imaging*, Vol 22, No 2, (May 2007), pp. 143-148.
- Patel, R., & Payá, CV. 1997. Infections in solid-organ transplant recipients. *Clin Microbiol Rev*, Vol 10, No1, (January 1997), pp. 86-124.
- Paya CV. 1999. Indirect effects of CMV in the solid organ transplant patient. *Transpl Infect Dis*, Vol 1, (suppl 1), pp. 8-12.
- Peleg, AY., Husain, S., Qureshi, ZA., Silveira, FP., Sarumi, M., Shutt, KA., Kwak, EJ., & Paterson, DL. 2007. Risk factors, clinical characteristics, and outcome of *Nocardia* infection in organ transplant recipients: a matched case-control study. *Clin Infect Dis*, Vol 44, No 10, (May 2007), pp. 1307-1314.
- Peleg, AY., Husain, S., Kwak, EJ., Silveira, FP., Ndirangu, M., Tran, J., Shutt, KA., Shapiro, R., Thai, N., Abu-Elmagd, K., McCurry, KR., Marcos, A., & Paterson, DL. 2007. Opportunistic infections in 547 organ transplant recipients receiving alemtuzumab, a humanized monoclonal CD-52 antibody. *Clin Infect Dis*, Vol 44, No 2, (January 2007), pp. 204-212.
- Peraira, JR., Segovia, J., Fuentes, R., Jiménez-Mazuecos, J., Arroyo, R., Fuertes, B., Mendaza, P., & Pulpon, LA. 2003. Pulmonary nocardiosis in heart transplant recipients: treatment and outcome. *Transplant Proc*, Vol 35, No 5, (August 2003), pp. 2006-2008.
- Poonyagariyagorn, HK., Gershman, A., Avery, R., Minai, O., Blazey, H., Asamoto, K., Alster, J., Murthy, S., Mehta, A., Petterson, G., Mason, DP., & Budev M. 2008. Challenges in the diagnosis and management of *Nocardia* infections in lung transplant recipients. *Transpl Infect Dis*, Vol 10, No 6, (December 2008), pp. 403-408.
- Pottumarthy, S., Limaye, AP., Prentice, JL., Houze, YB., Swanzy, SR., & Cookson, BT. 2003. *Nocardia veterana*, a new emerging pathogen. *J Clin Microbiol*, Vol 41, No 4, (April 2003), pp. 1705-1709.
- Roberts, SA., Franklin, JC., Mijch, A., & Spelman, D. 2000. Nocardia infection in heart-lung transplant at Alfred Hospital, Melbourne, Australia, 1989-1998. *Clin Infect Dis*, Vol 31, No 4, (October, 2000), pp. 968-972.
- Rivero, A., García-Lázaro, M., Pérez-Camacho, I., Natera, C., del Carmen Almodovar, M., Camacho, A., & Torre-Cisneros J. 2008. Successful long-term treatment for disseminated infection with multiresistant *Nocardia farcinica*. *Infection*, Vol 36, No 4, (August 2008), pp. 389-391.
- Sahathevan, M., Harvey, FA., Forbes, G., O'Grady, J., Gimson, A., Bragman, S., Jensen, R., Philpott-Howard, J., Williams, R., & Casewell, MW. 1991. Epidemiology,

- bacteriology and control of an outbreak of *Nocardia asteroides* infection on a liver unit. *J Hosp Infect*, Vol 18, Suppl A, (June 1991), pp. 473-80.
- Santos, M., Gil-Brusola, A., & Morales, P. 2011. Infection by *Nocardia* in solid organ transplantation: thirty years of experience. *Transplant Proc*, (in press).
- Schlaberg, R., Huard, RC., & Della-Latta, P. 2008. *Nocardia cyriacigeorgica*, an emerging pathogen in the United States. *J Clin Microbiol*, Vol 46, No 1, (January 2008), pp. 265-273.
- Shawar, RM., Moore, DG., & LaRocco, MT. 1990. Cultivation of *Nocardia* spp on chemically defined media for selective recovery of isolates from clinical specimens. *J Clin Microbiol*, Vol 28, No 3, (Mars 1990), pp. 508-512.
- Singh, N., Husain, S. 2000. Infections of the central nervous system in transplant recipients. *Transpl Infect Dis*, Vol 2, No 3, (September 2000), pp. 101-11.
- Smego, RA Jr., Moeller, MB., & Gallis, HA. 1983. Trimetoprim-sulfamethoxazole therapy for *Nocardia* infections. *Arch Intern Med*, Vol 143, No 4, (April, 1983), pp. 711-718.
- Sorrell, TC., Mitchell, DH., & Iredell, JR. In: Mandel GL, Bennett JE, Dolin R, eds. Principles and Practice of Infectious Diseases. 6th Ed. Philadelphia, PA: Churchill Livingstone 2005, pp. 2916-2914.
- Sullivan, DC., & Chapman, SW. 2010. Bacteria that masquerade as fungi: actinomycosis/nocardia. *Proc Am Thorac Soc*, Vol 7, No 3, (May 2010), pp. 216-221.
- Wayne, PA. 2003. Susceptibility testing of mycobacteria, nocardiae and other aerobic actinomycetes. M24-A. Clinical and Laboratory Standards Institute (CLSI/NCCLS).
- Wenger, PN., Brown, JM., McNeil, MM., & Jarvis, WR. 1998. *Nocardia farcinica* sternotomy site infections in patients following open heart surgery. *J Infect Dis*, Vol, 178, No 5, (November, 1998), pp. 1539-1543.
- Yassin, AF., Rainey, FA., Mendrock, U., Brzezinka, H., & Schaal, KP. 2000. *Nocardia abscessus* sp. nov. *Int J Syst Evol Microbiol*, Vol 50, No 4, (July, 2000), pp. 1487-1493.

IntechOpen



Lung Diseases - Selected State of the Art Reviews

Edited by Dr. Elvisgran Malcolm Irusen

ISBN 978-953-51-0180-2

Hard cover, 690 pages

Publisher InTech

Published online 02, March, 2012

Published in print edition March, 2012

The developments in molecular medicine are transforming respiratory medicine. Leading clinicians and scientists in the world have brought their knowledge and experience in their contributions to this book. Clinicians and researchers will learn about the most recent advances in a variety of lung diseases that will better enable them to understand respiratory disorders. This treatise presents state of the art essays on airways disease, neoplastic diseases, and pediatric respiratory conditions. Additionally, aspects of immune regulation, respiratory infections, acute lung injury/ARDS, pulmonary edema, functional evaluation in respiratory disorders, and a variety of other conditions are also discussed. The book will be invaluable to clinicians who keep up with the current concepts, improve their diagnostic skills, and understand potential new therapeutic applications in lung diseases, while scientists can contemplate a plethora of new research avenues for exploration.

How to reference

In order to correctly reference this scholarly work, feel free to copy and paste the following:

Pilar Morales, Ana Gil-Brusola and María Santos (2012). Nocardia Infection in Lung Transplantation, Lung Diseases - Selected State of the Art Reviews, Dr. Elvisgran Malcolm Irusen (Ed.), ISBN: 978-953-51-0180-2, InTech, Available from: <http://www.intechopen.com/books/lung-diseases-selected-state-of-the-art-reviews/nocardia-infection-in-lung-transplantation>

INTECH
open science | open minds

InTech Europe

University Campus STeP Ri
Slavka Krautzeka 83/A
51000 Rijeka, Croatia
Phone: +385 (51) 770 447
Fax: +385 (51) 686 166
www.intechopen.com

InTech China

Unit 405, Office Block, Hotel Equatorial Shanghai
No.65, Yan An Road (West), Shanghai, 200040, China
中国上海市延安西路65号上海国际贵都大饭店办公楼405单元
Phone: +86-21-62489820
Fax: +86-21-62489821

© 2012 The Author(s). Licensee IntechOpen. This is an open access article distributed under the terms of the [Creative Commons Attribution 3.0 License](#), which permits unrestricted use, distribution, and reproduction in any medium, provided the original work is properly cited.

IntechOpen

IntechOpen