

# We are IntechOpen, the world's leading publisher of Open Access books Built by scientists, for scientists

6,900

Open access books available

186,000

International authors and editors

200M

Downloads

Our authors are among the

154

Countries delivered to

TOP 1%

most cited scientists

12.2%

Contributors from top 500 universities



WEB OF SCIENCE™

Selection of our books indexed in the Book Citation Index  
in Web of Science™ Core Collection (BKCI)

Interested in publishing with us?  
Contact [book.department@intechopen.com](mailto:book.department@intechopen.com)

Numbers displayed above are based on latest data collected.  
For more information visit [www.intechopen.com](http://www.intechopen.com)



# Lung Parenchyma Sparing Resection for Pulmonary Malignancies

Arpad Pereszlenyi

*Department of Thoracic Surgery,  
Vivantes Klinikum Neukölln, Berlin,  
Germany*

## 1. Introduction

It is well-known that the incidence of lung malignancies increases. The increase of primary lung cancer is especially alarming. But the lung is also a target organ for other secondary malignancies, such as metastases of different origins. For the primary lung cancer, the therapy of choice is its radical resection (together with systematic lymphadenectomy). For pulmonary metastases, less radical resections are necessary. Both could be challenging for thoracic surgeons in case of limited lung function and in the case of multiple bilateral lung nodules – metastases. Furthermore, the newly detected lung tumor is in most cases diagnosed in elderly, active smokers with a limited lung function and significant comorbidity. Therefore, the above-mentioned planned radical resection in these “limited” patients is not possible. Thoracic surgeons face apparently a dead-lock situation having to operate radically and sparing enough functional lung parenchyma at the same time.

This paper is dedicated to the topic of lung parenchyma sparing resection. It's first part describes a laser resection of multiple lung lesions – metastases. The laser segmental lung resection and the sleeve bronchoplastic (angioplastic) resection are introduced in it's second and third part, respectively.

## 2. Laser resection for lung metastases

### 2.1 History

Already in 1786, John Hunter reported the first case report in history of pulmonary metastases. The primary cancer was a malignant tumor of the femur and the patient died of widespread pulmonary metastazing only 7 weeks after the leg was amputated (Allen et al., 1993; Van Schil et al. 2008). In 1927, the first surgeon who performed a lung resection of pulmonary metastasis was Jan Divis from Prague (Divis, 1927). Barney and Churchill could note the real success after the surgery, removing a lung metastasis by a lobectomy. The renal-cell carcinoma was removed by nephrectomy, subsequently. The patient survived for over 20 years without any signs of recurrence (Barney & Churchill, 1939).

Finally, a retrospective analysis of 205 patients after resection of pulmonary metastases should be mentioned. This report was published by Thomford in 1965 with a 5 Years-Survival-Rate (Y-S) of 30.3% (Thomford 1965).

2.2 Introducing the laser in thoracic surgery

In 1985, after establishing a 1064 nm Nd:YAG laser for standard endobronchial interventions (Häusinger et al, 1984), LoCicero reopened the debate on the use of lasers in open thoracic surgery as well (LoCicero, 1985, 1989). However, since his CO<sub>2</sub> laser was a pure absorption or cutting laser, it proved inadequate for lung surgery and thus could not establish itself in this medical discipline. As a result, a number of medical centers in the United States, Japan and Europe began experimenting with 1064 nm Nd:YAG lasers, using bare fibers and sapphire tips to perform superficial resections (Branscheid, 1992; Kodama 1991, 1992; Lo Cicero 1985, 1989; Mineo, 1998; Moghissi, 1988; Rolle, 1988). As it follows, all of these teams achieved only low patient-loads and published no further results, mainly because the technical difficulties posed by the available 1064 nm lasers could not be overcome without further basic research. Table 1.

The new era began by introducing the 1318 nm wavelength Nd:YAG laser system of 40 W power output. This high performance Nd: YAG laser system consisted of the thin flexible quartz fibres (400 µm) with low water content and of a four lens focusing handpiece. This new laser system was exclusively used in all patients undergoing a lung parenchyma sparing resection in our study. The next Section presents the description of this laser system.

Author	Article	Laser	Wave Length (nm)	Laser Application
LoCicero	1985 Ann Thorac Surg	CO <sub>2</sub>		Hemostasis, Sealing of Air Leaks
Rolle	1988 Laser in Med and Surg	Nd:YAG	1064/1318	Experimental/ clinical n=47 Wedge and Segmental Resections
Moghissi	1988 J Thoracic Cardiovasc Surg	Nd:YAG	1064	Local Excision, “Coin Lesions”
LoCicero	1989 J Thoracic Cardiovasc Surg	Nd:YAG	1064	Laser assisted pulmonary resections
Kodama	1991 J Thoracic Cardiovasc Surg	Nd:YAG	1064	Resection of Lung Metastases n=25
Branscheid	1992 Eur J Cardiothorac Surg	Nd:YAG	1064	Resection of Lung Metastases n=14 Laser only n=51 comb. with with Lobectomy
Kodama	1992 Kyobu Geka	Nd:YAG	1064	Resection of Lung Metastases n=25 Segmental Resection (NSCLC) n=25
Mineo	1988 Chest	Nd:YAG	1064	Resection of Lung Metastases n=23
Rolle	2006 J Thorac Cardiovasc Surg	Nd:YAG	1318	Lobe-Sparing Resection of Multiple Pulmonary Metastases n=328

Table 1. Literature Survey: Nd:YAG/CO<sub>2</sub> Laser resection in thoracic surgery.

### 2.2.1 Scientific background, description of 1318 Nd:YAG Laser

Due to its parenchymal tissue having a typical water content of 80% but a very low tissue density (just a fifth of the liver parenchyma), a very low heat capacity and a variable air content, the lung is an ideal organ for photothermal laser applications. Therefore, resecting lung parenchyma requires a laser with a powerful coagulation capability in addition to excellent cutting properties, given the high vessel density. After all, the surgeon must always expect fistulae and increasing bronchopulmonary leaks, particularly when dissecting lung parenchyma, the more so the deeper one works down in central direction. The absorption behavior of different lasers in water differs a lot (Bayly, 1963; Bramson, 1968; Dinstl, 1981).

The 1318 nm wavelength Nd:YAG laser significantly differs from the standard (1064 nm) wavelength by its ten times higher absorption in water but still offers sufficient laser light scatter, due its proximity to the beginning infrared spectrum, to satisfy the vital coagulation requirement as well. In fact the 1318 nm wavelength provided the intended combination effect - cutting capability plus coagulation capability - so perfectly as it could not be achieved with the 1064 nm wavelength (Rolle, 1988, 1989). As a welcome side-effect, we also found strong lung tissue shrinkage, which provides two additional advantages: mechanical reinforcement of the coagulation effect, and fistula sealing far into the central lobe region. In fact, the surfaces coagulated and sealed off through defocused irradiation with the 1318 nm laser withstand artificial ventilation pressures of up to 25 cm H<sub>2</sub>O.

As for the founding and developing of the above mentioned laser system, the name of Professor Axel Rolle has to be mentioned in this place (Rolle, 1988, 1989, 1999).

The following design features were incorporated to develop a 1318 nm commercial design Triumph (formerly Hüttinger Medizintechnik, Umkirch, Germany) and Martin companies. The second wavelength is first generated by adapted reflection of the laser mirrors. High beam quality allows coupling into thin (less than 0.6 mm) optical quartz fibers with minimum losses. For flexible transmission to the area of application, special water-free quartz fibers are required as laser light absorption in water is 10 times higher at the 1318-nm wavelength (Bayly, et al., 1963; Stokes et al., 1981).

A four-lens focusing handpiece was developed to concentrate the laser light and allow manual manipulation of the beam onto lung tissue to keep the working-point focus in the tissue at 4 mm while avoiding heat generation in the focusing handpiece. The extremely high laser power density of 24kW/cm<sup>2</sup> allows fast and precise cutting with simultaneous coagulation and sealing of lung tissue. A high performance smoke evacuation system eliminates the vaporization fumes, which are unavoidable during parenchyma dissection with this laser (Fig.1).

### 2.3 Surgical technique

Laser metastasectomy is performed via an anterolateral thoracotomy (staged 3 to 4 weeks, if bilateral) after fulfilling the standard indication criteria for pulmonary metastasectomy (histologically confirmed primary tumor after its radical resection or its fully controlled stage). Preoperative evaluations are the same as a for routine thoracic intervention; including a history and physical examination, chest computed tomography (CT), pulmonary function tests, and a bone scan. If the signs or symptoms are suggestive, a head CT is also obtained. Patients with identified extrapulmonary metastases are excluded from surgery.

The technique, indication and possibility to save lobes are demonstrated on a case report. A 59-years-old female patient with a history of radically resected colorectal carcinoma



Fig. 1. Components of modern Laser equipment for the application on lung tissue (1318 nm wavelength, 40 W power output, beam quality, energy efficiency, high performance smoke evacuation system, 0.4 mm diameter of fibre, focusing handpiece, flexible quartz fibres /low water content/).

(Adenocarcinoma of rectosigmoid pT4 pN1 pM1 (Liver), G3, Status post hemihepatectomy, chemotherapy and radiation) was referred to our Institute. A significant progress of (isolated) lung metastases was reported. The chest CT demonstrates the situation after the successful laser resection of pulmonary metastases on the right side and just before the procedure on left (Fig. 2).

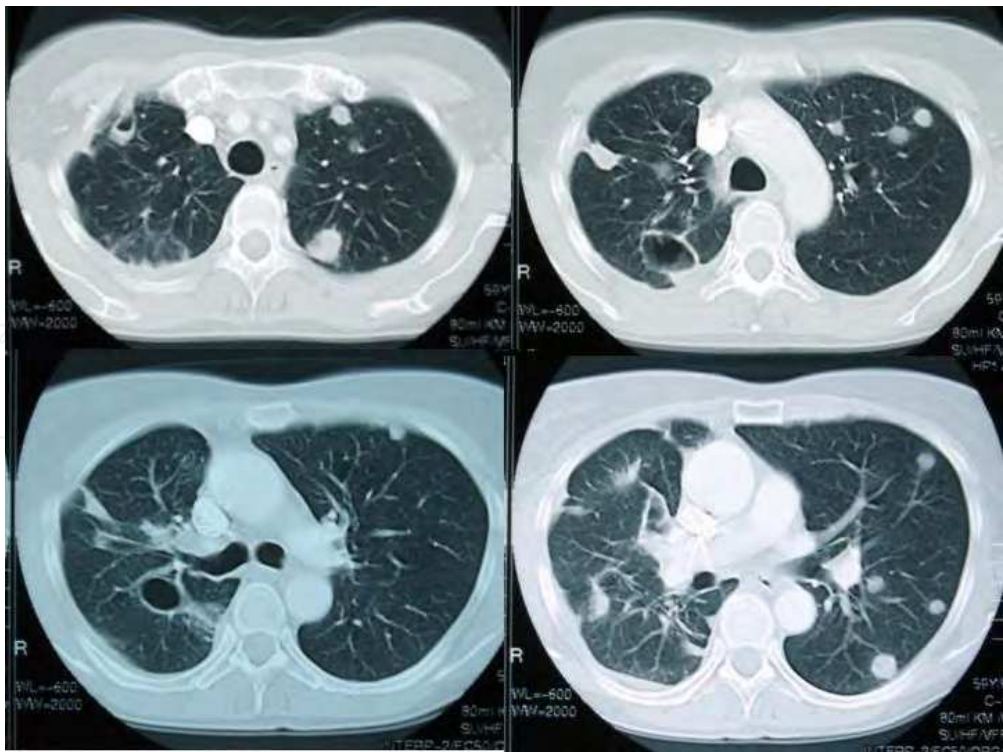


Fig. 2. Case Report 1: The Chest CT demonstrates the situation after the successful laser resection of pulmonary metastases on the right side and just before the procedure on left.

The new 1318 nm Nd:YAG laser system offers a unique opportunity to perform the procedure in a parenchyma-saving and lobe-sparing way. Therefore, the bilateral laser procedure was performed. The intraoperative situation can be seen on the series of photographs: the pulmonary artery is mobilized on a vessel loop; the upper vein lies next to the central, 30 mm great metastasis (Fig. 3). The laser resection of this metastasis was then performed. The next figure (Fig. 4) shows the situation immediately after the laser resection. The intraoperative situation – its close relation to segmental pulmonary vein – can be easily recognized. Exposed bronchial branches and segmental vessels at the segmental level were over-sewn and ligated with absorbable suture (4-0/ 3-0). The lung architecture and orientation was reconstructed following each nodular resection by reapproximating the visceral pleura with a running absorbable suture (4-0 Vicryl) (Fig. 5). This technique avoided a distortion of the lung tissue to allow consistent orientation and palpation of the initially noted lung nodules. At the end of the procedure, the resected lung was re-insuflated by a standard way in accordance with the routine thoracic surgical practice.

By performing the metastasectomy the above-described way, it was possible to save the patient's lobes and to operate on both lungs by a laser parenchyma sparing manner. The patient, now one year after the procedure, is in good condition with a full physical activity, living free of metastases.

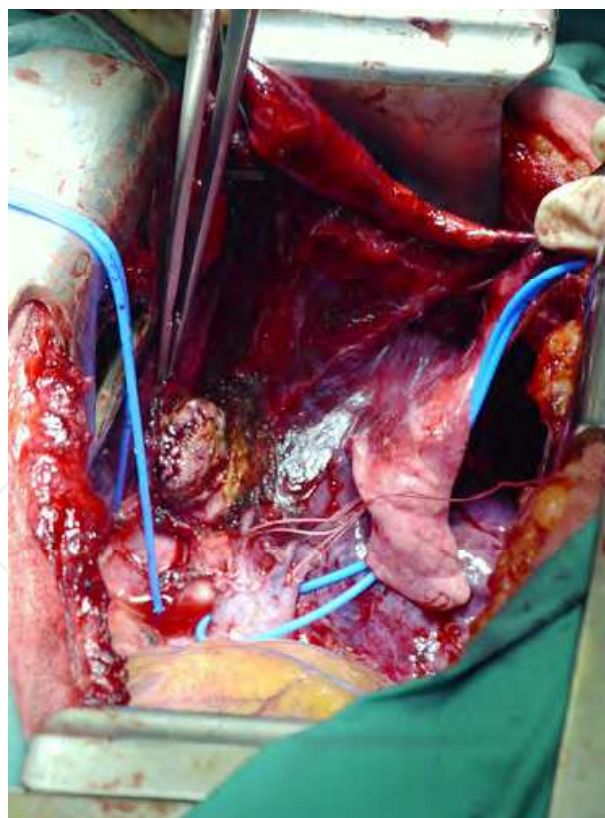

Fig. 3. Intraoperative view: Laser resection of 30 mm central metastasis localized in left upper lobe centrally to pulmonary artery. Intraoperative situation: pulmonary artery and the upper vein are mobilized on vessel loop (blue).

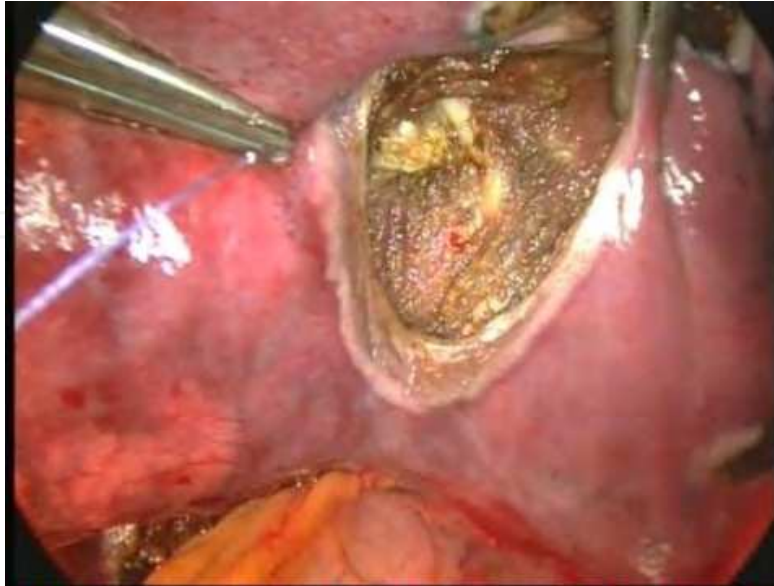

Fig. 4. The intraoperative situation – its close relation to segmental pulmonary vein - can be easily recognized. Exposed bronchial branches and segmental vessels at the segmental level were over-sewn and ligated with absorbable suture (4-0/ 3-0).

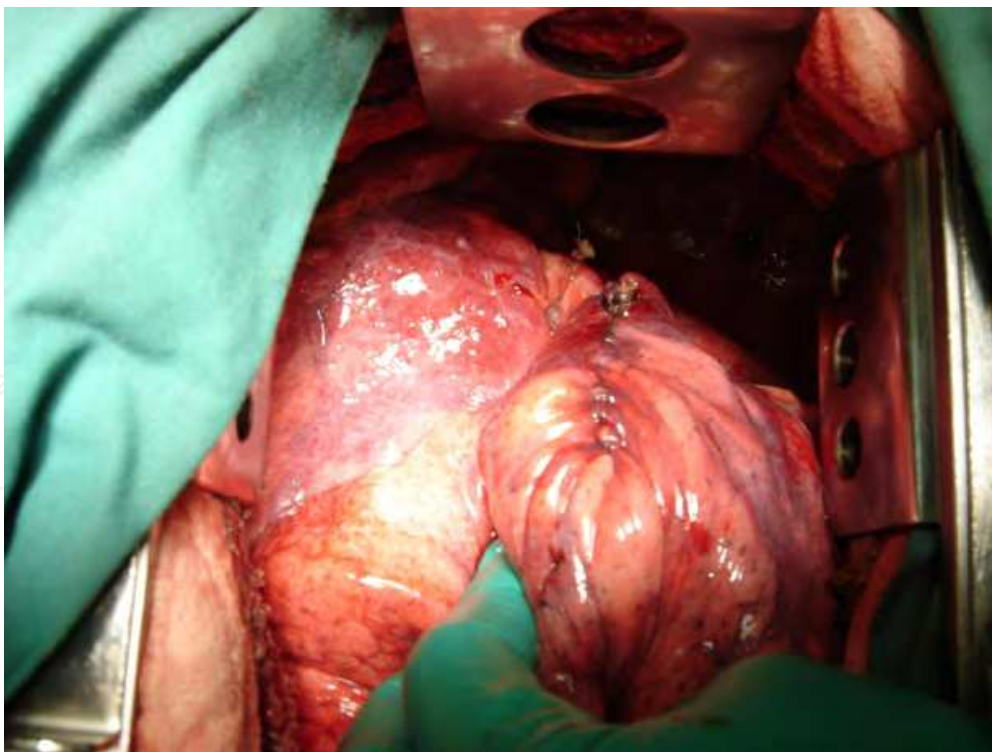


Fig. 5. Intraoperative view: Reconfiguration of the left upper lobe with continuous suture of the pleura visceralis.

2.4 Results

From January 1996 to May 2004, lung laser resections were performed in 328 patients. There were 164 males and 164 females and the main indications for laser lung resections included lung metastases of the following primaries: renal carcinoma in 112 cases, colorectal in 91 and breast cancer in 35 cases. In the remaining 90 cases laser resection was performed for metastases of lung cancer (n=12), malignant melanoma (n=1), sarcomas (n=15), head and neck carcinoma (n=12) and for metastases of other less frequent ones (n=27). These results were already reported and published elsewhere (Rolle et al., 2006).

This retrospective study analyzes the second largest indication group of colorectal carcinoma lung metastases (Pereszlenyi et al., 2006a, 2006b). 46 females and 45 males with median age of 64 yrs, ranged from 43 to 80 years were included. The number of complete removed metastases was 629, ranged 1-56; median 7 per patient. All laser resections were performed by the Nd:YAG laser system of 1318 nm wavelength with its lung parenchyma saving effect. The complete resection (R0) was achieved in 78 patients, incomplete (R1/2) in 13 patients.

There was no perioperative mortality. Follow-up was completed for all patients and ranged from 1-30 Mo with a median of 20 months. 1 Year-Survival (Y-S) for complete (R0) resection was 82%, 2 Y-S was 68%, 3 Y-S 42% and 5 Y-S was 22% (Fig. 6). For incomplete (R1/2) resection (n=13): 1 Year-Survival was 85%, 2 Y-S was 54%, 3 Y-S 46%, 4 Y-S 9% and 5 Y-S was 0 (Fig. 6).

Despite of that the 7 Metastases pro patient was removed and 19% of lymphatic-nodes involvement, the radical resection (R0) could be achieved. In 13 patients was the resection incomplete (R1/R2). For the R0 versus R1/2 see the Figure 6. The survival with and without lymphatic-node-involvement (N1-hilum, N2-mediastinum) after the radical resection (R0N0 versus R0N1/2) is demonstrated in Figure 7.

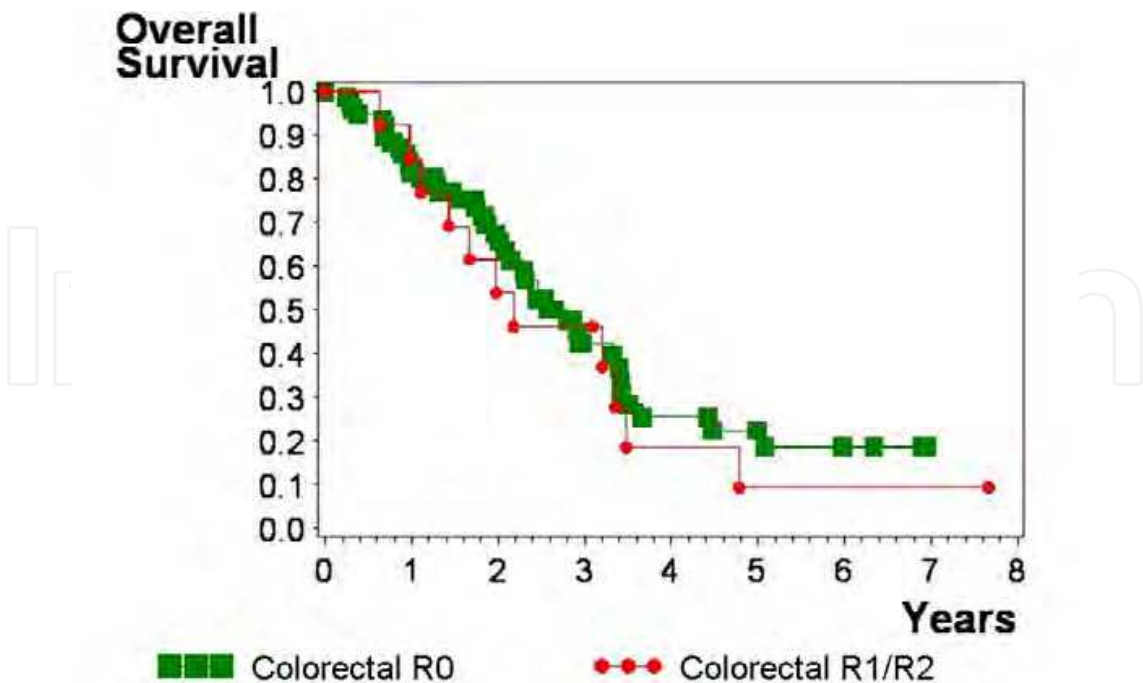


Fig. 6. Kaplan-Meier curve showing survival according to resection (Bullets = complete R0, squares = incomplete R1/R2 resections).

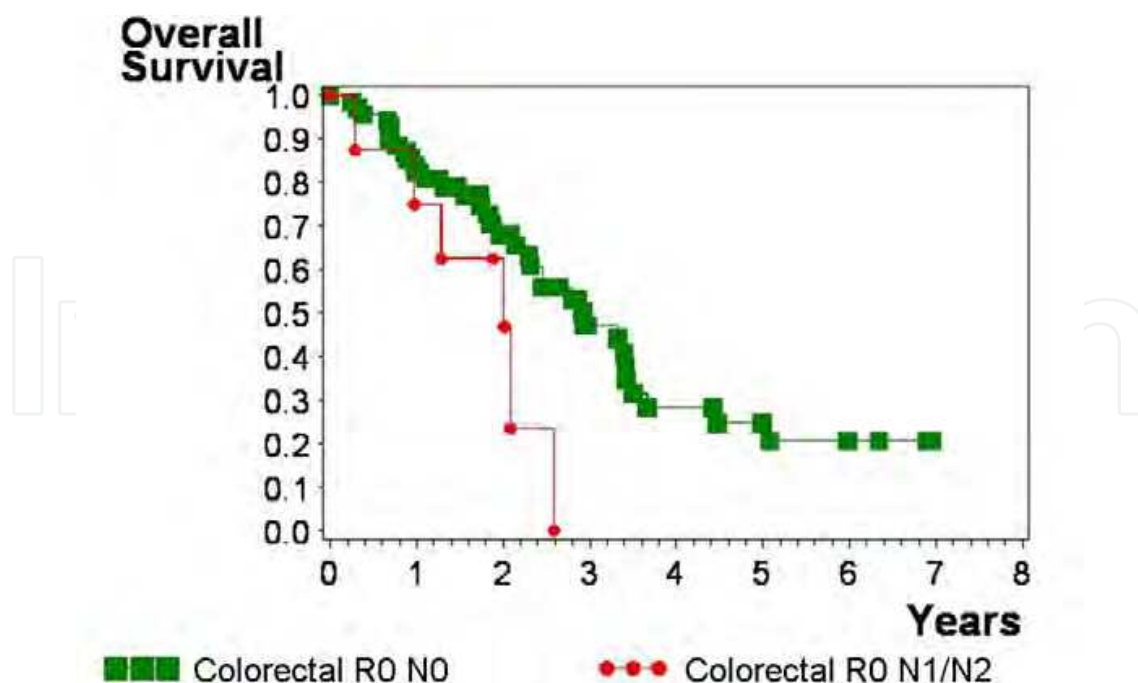


Fig. 7. Kaplan-Meier curve showing survival according to lymphnode-involvement (Bullets = complete without LN-involvement R0N0, squares = complete with LN1/N2-involvement R0 N1/N2).

### 3. Laser segmental lung resection

The technique of conventional lung segment resection, so called segmentectomy, is well known from the pioneer age of the thoracic surgery (pneumofistulotomy) when the apical sublobar lung resections were performed for lung tuberculosis. Nowadays, those resections are not so widely spread due to their “not enough radicalism” for lung cancer cases.

However, as it is already stated in the Introduction, these resections will gain more and more importance due to their lung parenchyma-sparing effect and the improving results on early postoperative morbidity and mortality (Keenan et al., 2004; Harada et al., 2005).

In this place, it should be emphasized that the segmental resection is also an anatomical lung resection as the lobectomy. It respects the anatomical structure of the lung with its bronchial and vascular composites together with its lymphatic flows.

A significant role in the technique of the segmental resection belongs to the laser system. Its cutting effect enables the thoracic surgeon to perform this kind of resection exactly within the anatomical borders of the pulmonary segment. Therefore it is feasible also for segments where the “classical” segment resections can only hardly be obtained, e.g. segment III, IX, X etc.

#### 3.1 Surgical technique

Laser segmentectomy is performed via an anterolateral muscle-sparing thoracotomy after fulfilling the standard indication criteria for a lung cancer resection (histologically confirmed lung tumor in its functional and oncologic operable stage). Preoperative evaluations are the same as for a routine thoracic intervention; including a history and physical examination, chest computed tomography (CT), pulmonary function tests, and a PET scan. If there are positive mediastinal lymphatic nodes proved by the test, a video-mediastinoscopy in order to clarify the N2/N3 status is added prior to the resection.

Next, a case report presents the technique of laser segmental lung resection. A 66-years-old male patient with histological confirmed Adenocarcinoma of the right upper lobe was evaluated for a lung resection. Because of the patient's significant comorbidity (ischemic heart disease, arterial hypertension, diabetes mellitus) and poor lung function (COPD, active smoker with history of 30 Pack/Years, FEV1 55%), the limited lung resection - Laser resection of the Segment 1 - was performed.

For the patient's preoperative images see Figure 8.

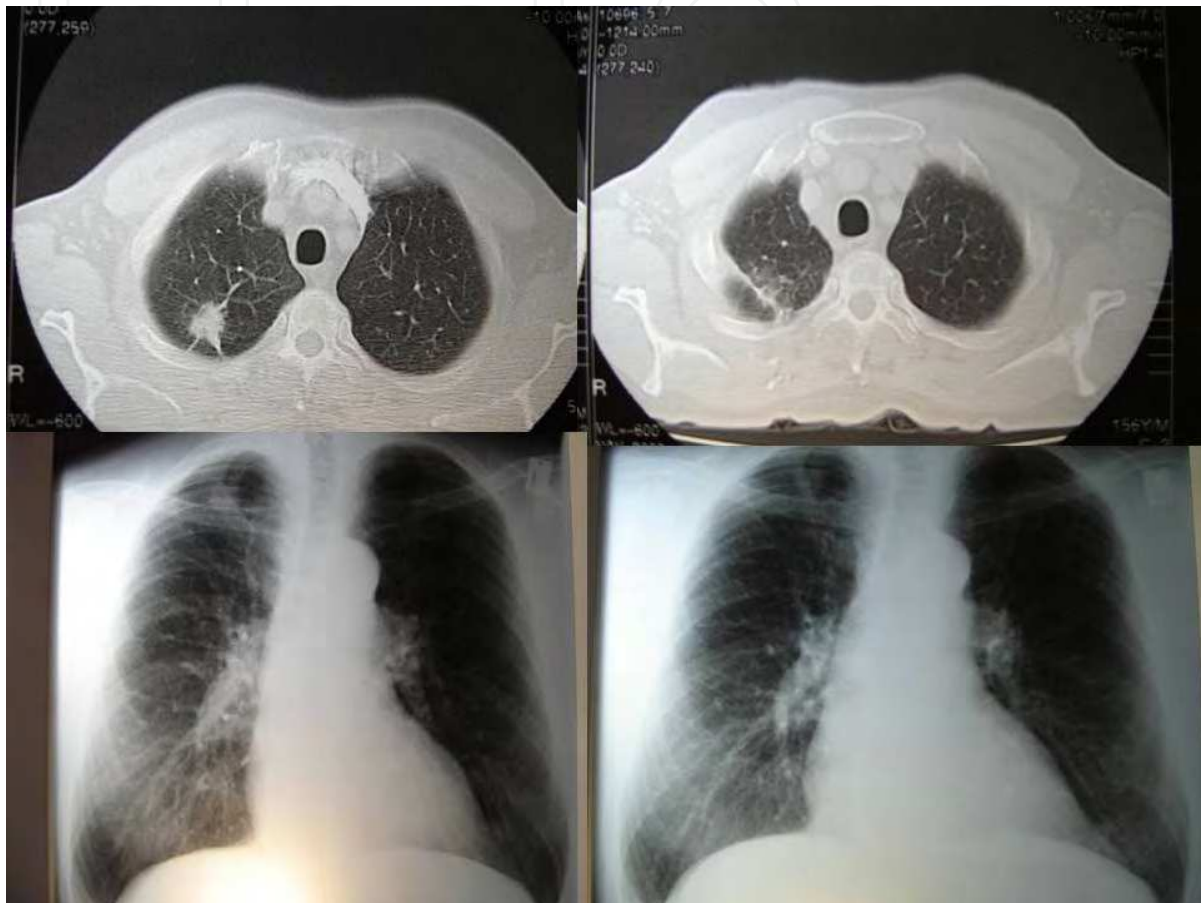


Fig. 8. Chest CT and X-ray pictures of Case 2. The perioperative images are on the left and the postoperative images are on the right side.

After the mobilization of the lung hilus, the segmental vessels and bronchus were mobilized on vessel loops. Fig.9. After this step, the lung parenchyma resection was performed by the laser system within the anatomical borders of the Segment 1. Fig.10. The visceralisation (reapproximating the visceral pleura with a running absorbable suture /4-0 Vicryl/) in order to restore the architecture of the upper lobe followed. As it was already described above, this technique avoided a distortion of the lung tissue to allow consistent orientation and palpation of the lung parenchyma. At the end of the procedure, the resected lung was re-insulated by a standard way in accordance with the routine thoracic surgical practice. Radical lymphadenectomy is routinely added to this procedure (Pereszlenyi et al., 2006).

The patient is now 3 years after the procedure, without any signs of tumor recurrence. The histological examination of the resected specimen has proved an Adenocarcinoma of the lung 3 cm of diameter, radically (R0) removed via the laser resection of the Segment 1. For postoperative CT scans see Figure 8.

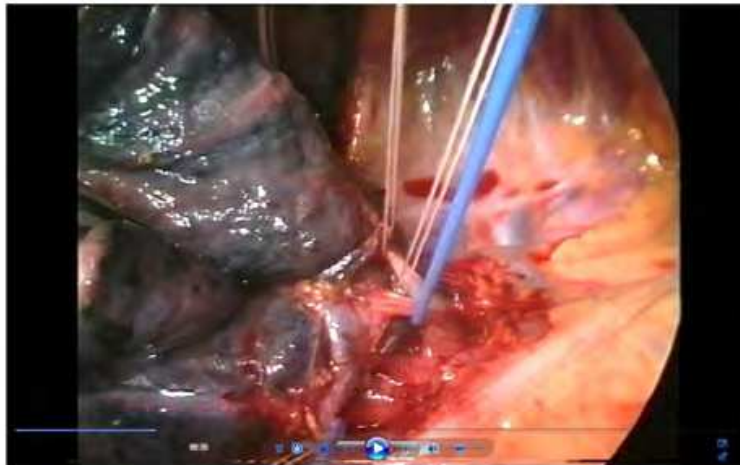

Fig. 9. Right lung hilus is mobilized; truncus anterior on the blue vessel loop with its segmental artery branches A1, A3.

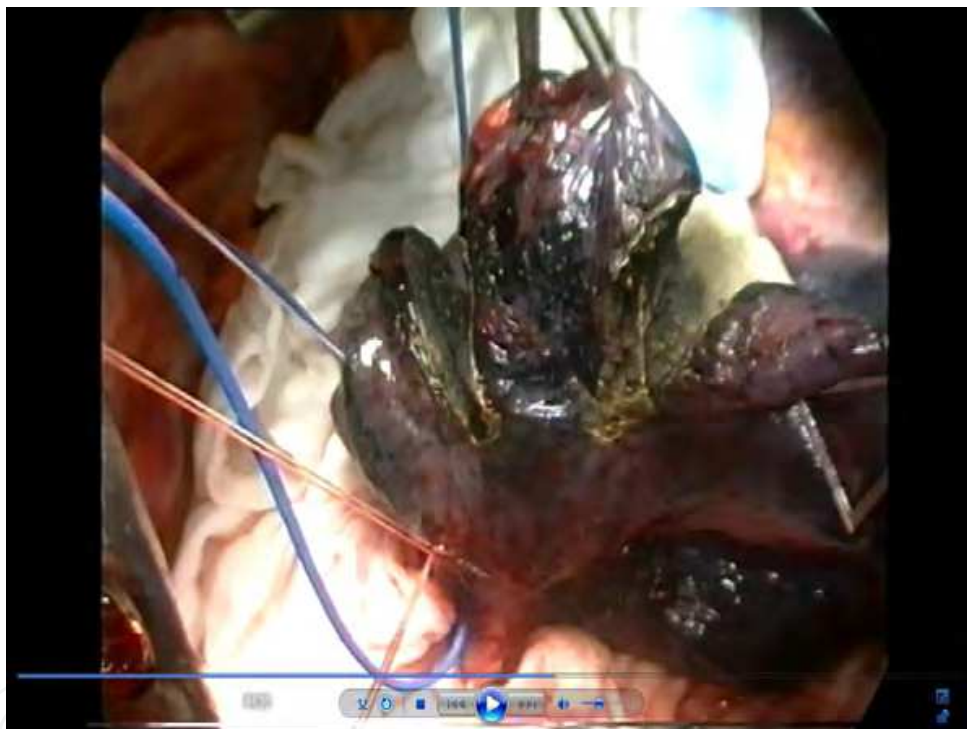

Fig. 10. Laser segmental resection within the anatomical borders of the Segment 1.

### 3.2 Results

From January 1996 to December 2001, laser segmental lung resections were performed in 53 patients (Pereszlenyi et al., 2006). The results after these resections were compared to standard lobectomies /n=154/ for non-small cell lung cancer (NSCLC). The data of this comparison are presented in the Table 2.

As it follows, the 1, 3, 5 Year-Survival (Y-S) is comparable in both groups, there is no statistical significance /p=0.696/ in terms of tumor recurrence rate (26.4% versus 29.2%). The postoperative mortality rate (11.3%) after laser lung segmental resection is explained by the significant comorbidity, limited lung function in elderly patients in whom this kind of lung parenchyma sparing resection was performed. Tab.2.

To conclude, we are convinced that radical surgical resection is still the therapy of choice in NSCLC treatment. However, laser segmental lung resection represents an optimal treatment eventuality especially for those high risk patients in whom the standard resection – lobectomy is not feasible or performable.

Our study demonstrates the possibility and justification of this treatment modality with comparable results after the standard ones (Harada et al., 2005).

	n	Mean Age/ yrs (Range)	Intraoperative mortality	Postoperative mortality	1,3,5 Years Survival	Tumor Recurrence Rate
Laser Segmental Resection	53	67.5 (49.5-82.7)	0	11.3%	95% 82% 65%	26.4%
Lobectomy	154	62.5 (28.3-77.6)	0	1.9%	92% 71% 58%	29.2%

Table 2. Laser segmental lung resection versus standard lobectomy for primary lung cancer (n=207). Selection criteria for laser segmental resection: high risk patients (elderly patient, poor performance status, FEV1<65%, significant comorbidity) and peripheral tumors of ≤ 4cm diameter.

4. Sleeve bronchoplastic lung resection

Last but not least, the sleeve lobectomy should be mentioned. Centrally localized lung tumors can be resected by a lobectomy extended into a resection of central part of the invaded bronchus. The shape of such resected bronchus has a form of a sleeve. That’s where the term “sleeve” lobectomy originates. There are numerous published studies showing the clear benefit for this type of lung resections. The most important advantage includes the avoidance of a major lung resection, e.g. pneumonectomy by performing a sleeve lobectomy. Its technique is well known, but in case of constructing so called “Neo-carina” followed by its re-implantation to the main stem bronchus can be very challenging also for experienced surgeons. Fig.11.

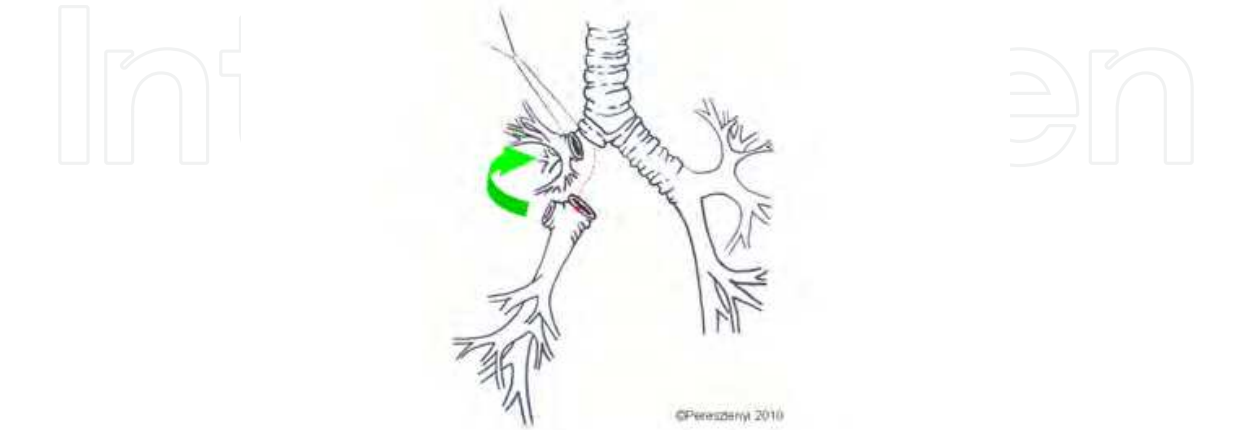


Fig. 11. Sleeve middle and lower (bi-)lobectomy: Re-implantation the upper lobe bronchus into main-stem bronchus right (or into distal trachea with construction of the “neo-carina”) after resection the tumor within the bilobectomy. Scheme.

In case of multiple lung lesions, the laser system plays a significant role. The centrally located endobronchial tumor is removed by a sleeve lobectomy, and any smaller peripheral lesions (satellites) are resected by laser. Fig.12. The technique of the laser resection is presented in detail in the first part of this chapter. Fig. 13.

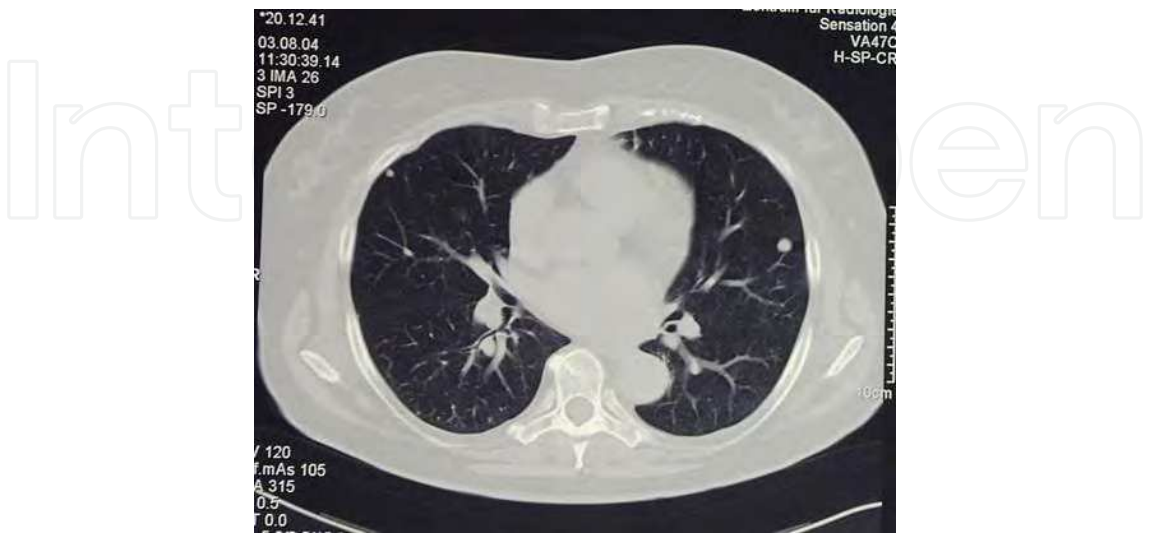


Fig. 12. Case Report 3: Chest CT shows the central lung tumor in the right lower lobe and two small satellites in the periphery of the lung.

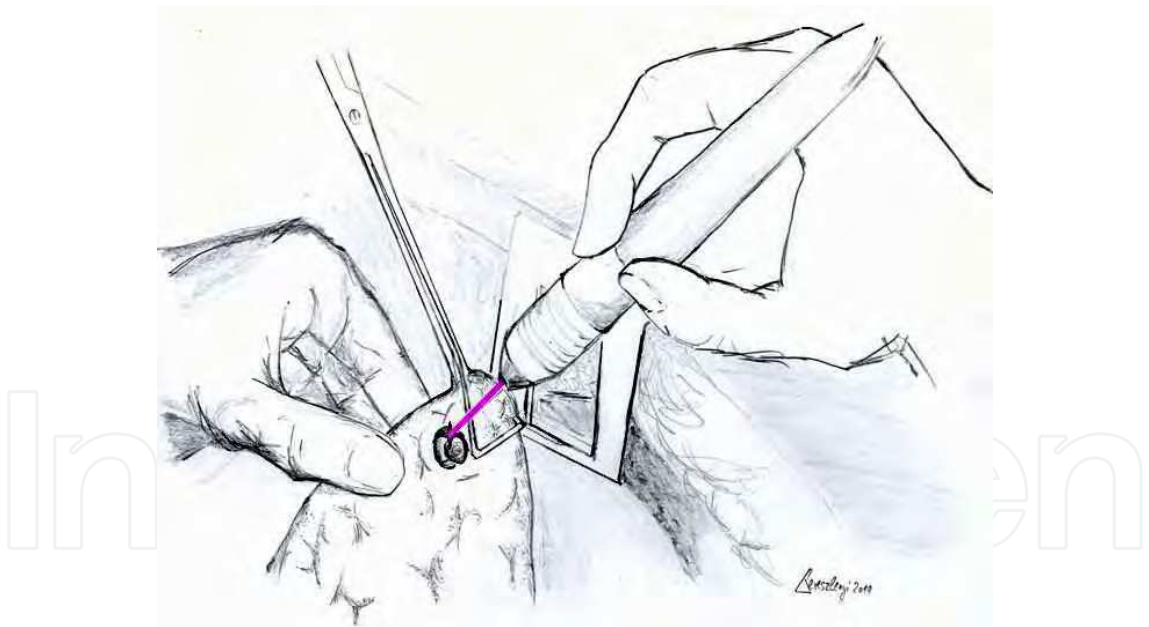


Fig. 13. Scheme of laser resection of small peripheral nodule located in the middle lobe after sleeve lower lobe resection for a large central located endobronchial tumor.

**4.1 Surgical technique, patients and methods**

Between January 2005 and January 2011, 58 patients (42 males, 16 females, mean age 61 yrs range 24 – 83) underwent sleeve lobectomy (SL) in our Institute. The indications for SL were: non-small cell lung carcinoma (NSCLC) in 47 /Fig.14/, and pulmonary metastases in 11 patients. Fig.15. As the metastatic pulmonary lesions were multiple, the Laser Resection (LR)

of these satellites was added to the SL procedure. The main indication for laser resection were metastases of renal-cell (n=4) and colorectal-carcinoma (n=3). Fig.15. The most detected histologic type of NSCLC was squamous-cell carcinoma (n=22), followed by adenocarcinoma (n=14). The laser resection (combined by SL) was performed after fulfilling the standard criteria for metastasectomy: primary tumors were radically removed and there were no evidence of any distant extrathoracic metastases. In four NSCLC patients the arterial sleeve was added to the left upper bronchial SL. Lymphadenectomy was routinely added to the both parenchyma-saving procedures. The Tumor Stage is shown in the Figure 16 according to the newest, revised TNM Classification from 2009 (Goldstraw et al., 2007).

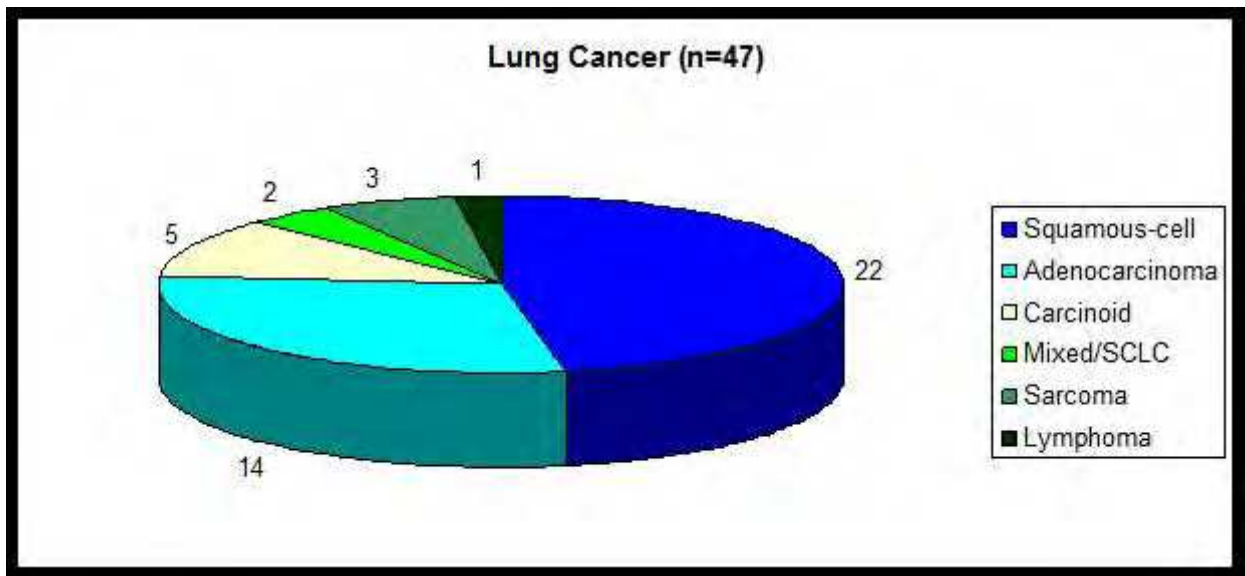


Fig. 14. Tumor histology distribution (NSCLC; n=47).

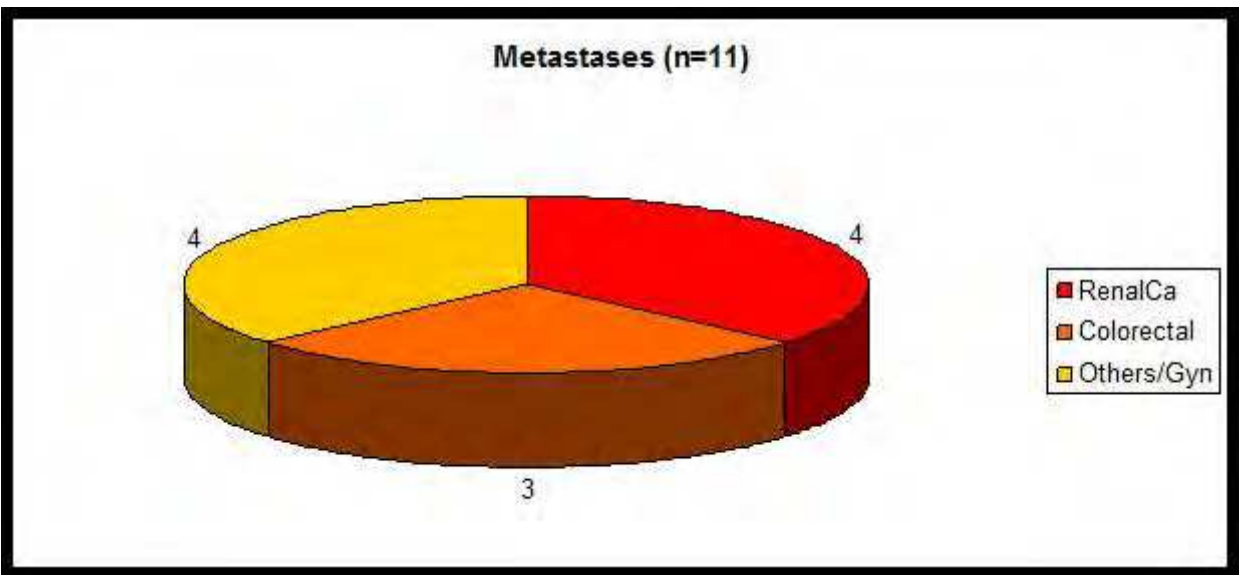


Fig. 15. Tumor histology distribution (Lung Metastases; n=11).

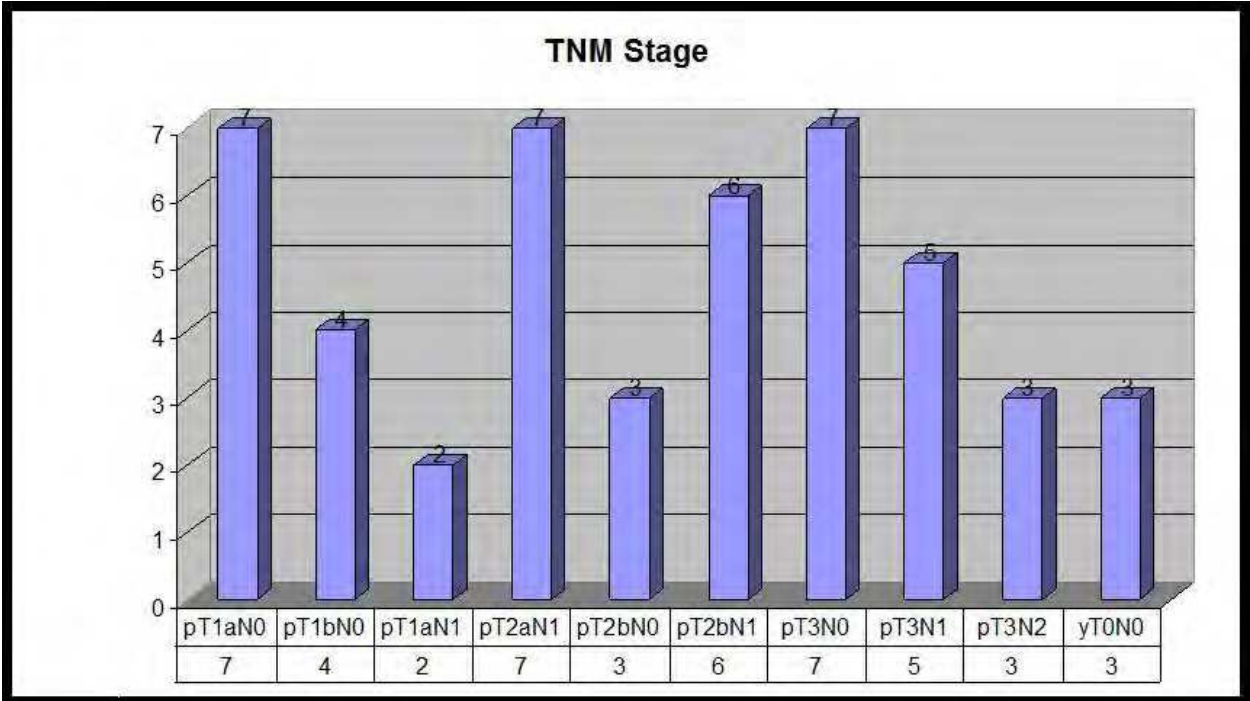


Fig. 16. Tumor Stage according to TNM Classification 2009 (n=47). yT0N0 - As the result of the successful neoadjuvant treatment, the tumor is not detectable in the resected lung specimen.

The location of the tumors and types of sleeve resections are shown in Table 3. Almost 40% of the patients underwent right sleeve upper lobe resection.

Side and Type of Procedure	Number of Patients (%)
Right Lung	
Upper Lobe	23 (39)
Middle Lobe	1 (2)
Middle and Lower Lobe	1 (2)
Lower Lobe	14 (24)
Left Lung	
Upper Lobe	12 (21)
Lower Lobe	7 (12)

Table 3. The location of tumors and types of sleeve resections (n=58).

Following the double-lumen tube intubation and the standard anterolateral, muscle-sparing thoracotomy, we proceed with the resection. A bronchial anastomosis is performed by

interrupted monofilament absorbable suture of PDS 3-0 or 4-0. The vascular anastomosis was performed by running suture of the non-absorbable material of Prolene 5-0 (or 4-0) in four NSCLC patients after the left upper sleeve lobectomy was finished. Mediastinal (hilar) lymphadenectomy is routinely performed as well as an intraoperative frozen section analysis of the resected bronchus (and vessel). After the reconstruction of the bronchus, a routine fiber bronchoscopy is always performed by the first surgeon. In our series, we didn't cover the bronchial anastomosis by any autologous flap or any other materials.

4.2 Results

A negative bronchial (vascular) margin was achieved in all. No 30-days postoperative mortality occurred. Follow-up (completed for all patients with median of 12 Mo) showed no anastomotic complications, no local recurrence on the bronchial (arterial) anastomosis. Survival was analyzed according to Kaplan-Meier method with the estimated 1, 2, 4 years overall survival. Fig. 17.

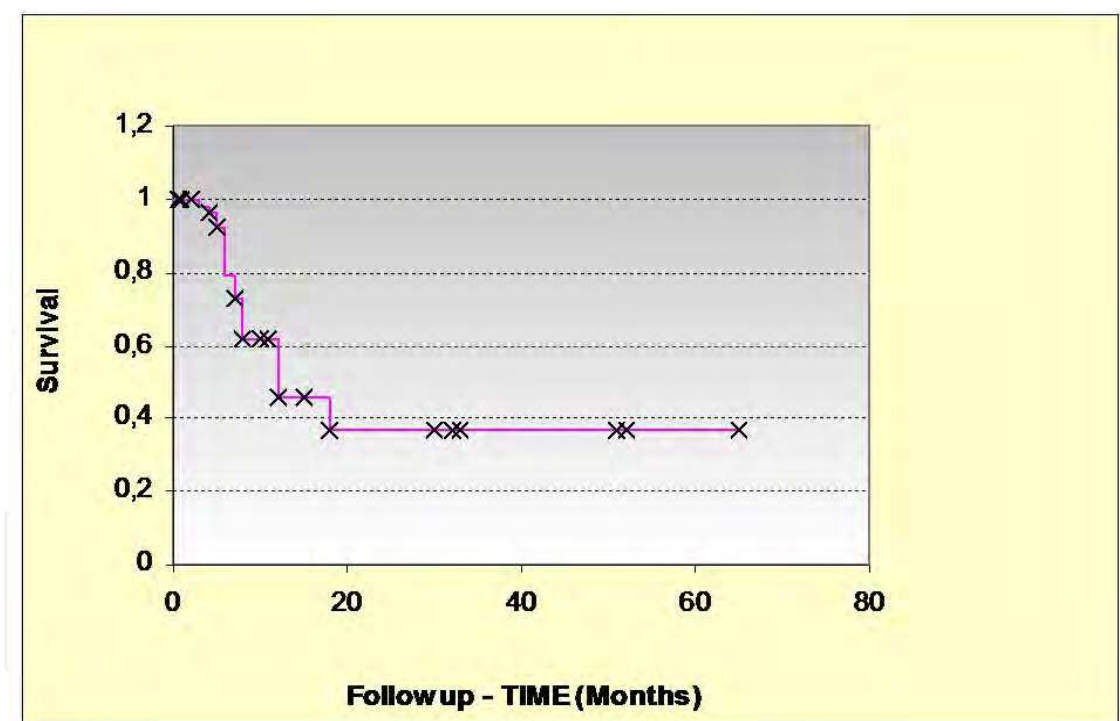


Fig. 17. Kaplan-Meier curve showing Survival at 20, 40, 60 Months.

In accordance with the reported results from the literature we can also conclude, the bronchial and vascular sleeve lobectomy can be performed safely, and is a good alternative solution to avoid pneumonectomy (Konstantinou et al., 2009; Ludwig et al., 2005). As shown in our study, selected patients with central lung metastases can be also included for this procedure after fulfilling the standard criteria for pulmonary metastasectomy. The central role for these kinds of procedures belongs to the laser lung-parenchyma-saving

resection. In our study all laser resections were performed by a 1318-nm Nd:YAG laser system of 40 W power output.

Laser resection may expand the scope of surgical treatment for pulmonary metastases, allowing a more complete resection. The indications for laser resection may expand to include patients who are not considered ideal candidates for lung metastasectomy because of poor residual lung function or multifocal pulmonary disease. The 1318-nm Nd:YAG laser for the resection of pulmonary metastases demonstrates a significant influence on the conservation of tissue during metastasectomy and appears to minimize complications.

## 5. References

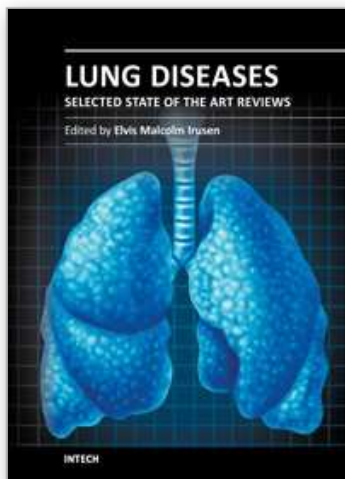
- Allen E, Turk JL, Murley R. The case book of John Hunter FRS. London: Royal Society of Medicine Services; 1993.
- Barney JD, Churchill ET. Adenocarcinoma of the kidney with metastasis to the lung cured by nephrectomy and lobectomy. *J Urol* 1939;42:269-76.
- Bayly IG, Kartha VB, Stevens WH. The absorption spectra of liquid phase H<sub>2</sub>O, HDO, and D<sub>2</sub>O from 0.7 micron to 10 micron. *Infrared Physics* 1963;3:211-23.
- Bramson M. Infrared Radiation. A handbook for applications. Plenum Press, New York, 1968.
- Branscheid D, Krysa S, Wollkopf G, Bulzebruck H, Probst G, Horn M, Schirren J, Vogt-Moykopf I. Does ND-YAG laser extend the indications for resection of pulmonary metastases? *Eur J Cardiothorac Surg* 1992;6:590-7.
- Dinstl K, Fischer PL. Der Laser. Grundlagen und klinische Anwendung. Springer, Berlin, Heidelberg, New York, 1981.
- Divis J. Ein Beitrag zur operativen Behandlung der Lungengeschwülste. *Acta Chir Scand* 1927;62:329-41.
- Goldstraw P, Crowley J, Chansky K, et al. The IASLC lung cancer staging project: proposals for the revision of the TNM stage groupings in the forthcoming (seventh) edition of the TNM classification of malignant tumours. *J Thorac Oncol* 2007;2:706 -714.
- Harada H, Okada M, Sakamoto T et al. Functional advantage after radical segmentectomy versus lobectomy for lung cancer. *Ann Thorac Surg* 2005;80:2041-2045.
- Häussinger K, Held E, Huber R: Endobronchial laser therapy, differential therapeutic use, and clinical value. *Klin Wochenschr* 1984;62:74-80.
- Keenan RJ, Landreneau RJ, Maley RH Jr et al. Segmental resection spares pulmonary function in patients with stage I lung cancer. *Ann Thorac Surg* 2004;78:228-233.
- Kodama K, Doi O, Higashiyama M, Tatsuta M, Iwanaga T. Surgical management of lung metastases. Usefulness of resection with the neodymium:yttrium-aluminium-garnet laser with median sternotomy. *J Thorac Cardiovasc Surg* 1991;101:901-8.
- Kodama K, Doi O, Higashiyama M, Yokouchi H. Usefulness of Nd:YAG laser for the excision of multiple lung metastases and segmentectomy for primary lung cancer. *Kyobu Geka* 1992;45:51-5.
- Konstantinou M, Potaris K, Sakellaridis T, Chamalakakis G. Sleeve lobectomy for patients with non small-cell lung cancer: a simplified approach. *Eur J Cardiothorac Surg* 2009;36:1045-1051.

- LoCicero J, Hartz RS, Frederiksen JW, Michaelis LL. Laser assisted parenchyma-sparing pulmonary resection. *J Thorac Cardiovasc Surg* 1989;97:732-6.
- LoCicero J, Hartz RS, Frederiksen JW, Michaelis LL. New applications of the laser in pulmonary surgery. Hemostasis and sealing of air leaks. *Ann Thoracic Surg* 1985;40:546-50.
- Ludwig C, Stoelben E, Olschewski M, Hasse J. Comparison of morbidity. 30-day mortality and long-term survival after pneumonectomy and sleeve lobectomy for non-small cell carcinoma. *Ann Thorac Surg* 2005;79:968-73.
- Mineo TC, Ambrogi V, Pompeo E, Nofroni I. The value of the Nd:YAG laser for the surgery of lung metastases in a randomized trial. *Chest* 1998;113:1402-7.
- Moghissi K. Experience in non-contact Nd:YAG laser in pulmonary surgery. *Eur J Cardiothorac Surg* 1988;2:87-94.
- Pereszlenyi A, Bis B, Baier B, Schilling A, Rudek B, Rolle A. Metastasized colorectal carcinoma - is there a place for a lung laser metastasectomy? *An Oncol* 2006;17(Suppl 6): vi 84.
- Pereszlenyi A, Rolle A, Huscher S, Bis B, Baier B, Rudek B: Laser segmental lung resection for stage I non-small cell lung cancer (VIDEO). 11th International Thoracic Surgery Congress - 23rd Annual Meeting - Austrian Society of Surgical Oncology (ACO-ASSO), St. Wolfgang, Austria, October 5-7, 2006.
- Pereszlenyi A, Rolle A, Huscher S, Koch R, Rudek B: Laser segmental lung resection versus lobectomy for stage I non-small cell lung cancer - a prospective single institution study. *Eur. Surg.* 2006, Vol.38, Supplement Nr.210:55.
- Pereszlenyi A, Schilling A, Rudek B, Baier B, Rolle A. Ergebnisse nach Laserresektion metastasierender Lungenmetastasen von kolorektalem Karzinom. 146. Jahrestagung der West- und Norddeutschen Gesellschaft für Chirurgie. Hamburg, 31.11.-03.12.2006.
- Rolle A, Eulerich E. Extensive multiple and lobe-sparing pulmonary resections with the Nd:YAG laser and a new wavelength of 1318 nm. *Acta Chirurgica Hungarica* 1999;38(1):115-7.
- Rolle A, Pereszlenyi A, Koch R, Richard M, Baier B. Is surgery for multiple lung metastases reasonable? A total of 328 consecutive patients with multiple-laser metastasectomies with a new 1318-nm Nd:YAG laser. *J Thorac Cardiovasc Surg.* 2006;131:1236-41.
- Rolle A, Thetter O, Häussinger K, Hallfeldt KKJ, Schmölder A. Einsatz des Neodym YAG Lasers in der Thoraxchirurgie. *Herz Gefäss Thorax Chir* 1989;3:85-91.
- Rolle A, Unsöld E, Ruprecht L, Permanetter W, Frank F. Morphologic aspects of Nd:YAG laser application (wavelengths 1064 nm and 1318 nm) on lung tissue. *Laser Med Surg* 1988;4:10-14.
- Stokes LF, Auth DC, Tanaka D, Gray JL, Gulasik C. Biomedical utility of 1320 nm Nd:YAG laser radiation. *IEEE Trans Biomed Eng* 1981;28:297-9.
- Thomford NR, Woolner LD, Clagett OT. The surgical treatment of metastatic tumors in the lungs. *J Thorac Cardiovasc Surg.* 1965;49:357-63.

Van Schil PE, Hendriks JM, Van Putte BP, Stockman BA, Lauwers PR, Ten Broecke PW, Grootenboers MJ, Schramel FM: Isolated lung perfusion and related techniques for the treatment of pulmonary metastases. *Eur J Cardiothorac Surg* 2008;33: 486-495.

IntechOpen

IntechOpen



## **Lung Diseases - Selected State of the Art Reviews**

Edited by Dr. Elvisgran Malcolm Irusen

ISBN 978-953-51-0180-2

Hard cover, 690 pages

**Publisher** InTech

**Published online** 02, March, 2012

**Published in print edition** March, 2012

The developments in molecular medicine are transforming respiratory medicine. Leading clinicians and scientists in the world have brought their knowledge and experience in their contributions to this book. Clinicians and researchers will learn about the most recent advances in a variety of lung diseases that will better enable them to understand respiratory disorders. This treatise presents state of the art essays on airways disease, neoplastic diseases, and pediatric respiratory conditions. Additionally, aspects of immune regulation, respiratory infections, acute lung injury/ARDS, pulmonary edema, functional evaluation in respiratory disorders, and a variety of other conditions are also discussed. The book will be invaluable to clinicians who keep up with the current concepts, improve their diagnostic skills, and understand potential new therapeutic applications in lung diseases, while scientists can contemplate a plethora of new research avenues for exploration.

### **How to reference**

In order to correctly reference this scholarly work, feel free to copy and paste the following:

Arpad Pereszlenyi (2012). Lung Parenchyma Sparing Resection for Pulmonary Malignancies, Lung Diseases - Selected State of the Art Reviews, Dr. Elvisgran Malcolm Irusen (Ed.), ISBN: 978-953-51-0180-2, InTech, Available from: <http://www.intechopen.com/books/lung-diseases-selected-state-of-the-art-reviews/lung-parenchyma-sparing-resection-for-pulmonary-malignancies>

**INTECH**  
open science | open minds

### **InTech Europe**

University Campus STeP Ri  
Slavka Krautzeka 83/A  
51000 Rijeka, Croatia  
Phone: +385 (51) 770 447  
Fax: +385 (51) 686 166  
[www.intechopen.com](http://www.intechopen.com)

### **InTech China**

Unit 405, Office Block, Hotel Equatorial Shanghai  
No.65, Yan An Road (West), Shanghai, 200040, China  
中国上海市延安西路65号上海国际贵都大饭店办公楼405单元  
Phone: +86-21-62489820  
Fax: +86-21-62489821

© 2012 The Author(s). Licensee IntechOpen. This is an open access article distributed under the terms of the [Creative Commons Attribution 3.0 License](https://creativecommons.org/licenses/by/3.0/), which permits unrestricted use, distribution, and reproduction in any medium, provided the original work is properly cited.

IntechOpen

IntechOpen