

# We are IntechOpen, the world's leading publisher of Open Access books Built by scientists, for scientists

6,900

Open access books available

185,000

International authors and editors

200M

Downloads

Our authors are among the

154

Countries delivered to

TOP 1%

most cited scientists

12.2%

Contributors from top 500 universities



WEB OF SCIENCE™

Selection of our books indexed in the Book Citation Index  
in Web of Science™ Core Collection (BKCI)

Interested in publishing with us?  
Contact [book.department@intechopen.com](mailto:book.department@intechopen.com)

Numbers displayed above are based on latest data collected.  
For more information visit [www.intechopen.com](http://www.intechopen.com)



## Sternal Wound Complications Following Cardiac Surgery

Zane B. Atkins<sup>1</sup> and Walter G. Wolfe<sup>2</sup>

<sup>1</sup>*Department of Surgery Durham Veterans  
Affairs Medical Center Durham, NC*

<sup>2</sup>*Department of Surgery Duke University  
Medical Center Durham, NC  
USA*

### 1. Introduction

Median sternotomy is a commonly performed incision with distinct advantages for exposure of mediastinal and pulmonary hilar structures [1]. However, a well-defined incidence of wound complications is associated with sternotomy, which are costly and potentially lethal in cases of deep sternal wound infection (DSWI) or mediastinitis [2-13]. Not only is DSWI associated with significant perioperative mortality, but historically even successfully treated DSWI is associated with reduced mid- and long-term survival compared with matched cardiac surgical patients without this dreaded postoperative complication [7-12].

In the past 10 years, we have accumulated extensive experience with managing DSWI as a referral center for these difficult problems. We and others have formalized a protocol for managing mediastinal infection utilizing negative pressure wound therapy which allows sternal salvage and improved outcomes in the majority of cases of DSWI [14-16]. This report describes our protocol for managing mediastinitis and presents our results for the past 18 years.

### 2. Background

Median sternotomy was originally introduced by Milton in 1897 and was performed infrequently for various conditions of the mediastinum until cardiac surgery as a field blossomed in the 1950s [17]. Shumacker first suggested median sternotomy as the procedure of choice for approaches to the heart and great vessels [18] since it avoided the significant pain and other complications, primarily pulmonary- or pleural-based, of the bilateral anterior thoracotomy ("clamshell") incision, which was most frequently used up to that point. However, not until Julian and colleagues demonstrated discrete advantages of the median sternotomy incision for cardiac surgery, particularly improved surgical efficiency, excellent exposure the heart, great vessels, and pulmonary hila, and reduced pulmonary trauma, was a convincing argument for median sternotomy as the incision of choice for cardiac surgical procedures put forth [19 Table 1]. The utility of this incision, the ease and speed of performance, and the common nature of surgically-treated cardiovascular and

STRUCTURE	STERNOTOMY	RIGHT THORACOTOMY	LEFT THORACOTOMY
RIGHT ATRIUM	+++	++	0
RIGHT VENTRICLE	+++	+	+
LEFT ATRIUM	+++	+	+
LEFT VENTRICLE	++	0	+++
SVC	+++	++	0
IVC	+++	++	0
ASC AORTA/root	+++	+	+
RIGHT SCA	++	++	0
INNOMINATE	+++	++	0
LEFT SCA	+	0	+++
DESC AORTA	0	0	+++
Main PA	+++	0	++
RIGHT PA	++	+++	0
LEFT PA	++	0	+++
PROX TRACHEA	++	+	+
ESOPHAGUS	0	+++	++
HEMIDIAPHRAGM	++	+	+
MAIN STEM BRONCHI	0	+++	++

Table 1. Comparison of exposure of various intrathoracic anatomic structures through median sternotomy, right thoracotomy, or left thoracotomy. (+++ denotes excellent, reliable exposure; 0 denotes no reliable exposure)

thoracic diseases in multiple populations approached through this incision are factors which combine to make median sternotomy the most commonly performed osteotomy worldwide [20]. Recently, several alternatives to median sternotomy have been promoted, including thoracoscopic and robotic approaches to cardiac and thoracic procedures [21, 22]. These approaches are possible as a result of high fidelity instrumentation and video platforms but are limited by steep learning curves and expense. Therefore, for most hospital systems performing cardiac surgical procedures, median sternotomy remains the mainstay incision.

3. Definition and classification

There is still no universally accepted method for treatment of DSWI or other sternal wound complication. One possible explanation for this is that until relatively recently, thorough classification schemes providing specific criteria for assignment as deep sternal infection, mediastinitis, superficial infection, or sterile sternal dehiscence were lacking. However, it is important to distinguish between these individual entities since each demands a different management strategy. Furthermore, results of reported series which include a variety of wound complications will differ from those that report a homogenous population. For example, sternal wound infections that are limited to the superficial soft tissues obviously demand less aggressive intervention for treatment and will generally respond more readily to treatment than deep sternal infection with higher likelihood for success. Therefore, when

comparing different treatment modalities for sternal wound infection, it is important to be clear about the extent of infection, since heterogeneity could skew reported results. Two prominent classification schemes have been proposed and are in use. Mediastinal dehiscence or the more chronic form, sternal nonunion, is defined as sternal wound disruption without any evidence for infection either clinically or pathologically [23, 24]. These entities will not be discussed in any detail. In contrast, mediastinitis, as characterized by the U.S. Centers for Disease Control and Prevention (CDC), is an infection of the mediastinum diagnosed by isolation of pathogenic organisms from the mediastinal fluid or tissue especially when there is obvious evidence of infection at the time of sternal exploration [25]. Alternatively, a combination of clinical features including chest pain, sternal drainage with bony instability, fevers, radiographic findings such as widened mediastinum, and bacterial isolation may also warrant a diagnosis of mediastinitis. Obviously, from the surgical perspective, these definitions are somewhat lacking since either superficial infections, confined to the soft tissues, or deep infections, involving the bone and/or retrosternal space could produce bacteremia and clinical signs of severe infection [23].

Fortunately, more descriptive classification schemes have been introduced and provide more specific insight into the pathologic involvement of the sternal tissues and the clinical consequences and course [23, 26, 27]. For example, the classification scheme introduced by El Oakley and Wright is based on the time at which the patient presents with mediastinitis relative to the initial surgical procedure [23]. Schulman et al have advocated a similar classification system [27]. In addition, the El Oakley description also accounts for relevant risk factors underlying the clinical scenario and whether or not previous attempts to treat the sternal wound infection have been made and failed [Table 2]. Therefore, five distinct categories of infection are described, each with important treatment implications. For example, the subtypes I and II appear to respond well to primary sternal closure with mediastinal irrigation, while subtypes III-V appear to require more aggressive sternal debridement and repair techniques [23].

Classification	Description of Infection
Type 1	Mediastinitis within 2 weeks of operation without risk factors
Type 2	Mediastinitis between 2 and 6 weeks of operation without risk factors
Type 3a	Type 1 with one or more risk factors
Type 3b	Type 2 with one or more risk factors
Type 4a	Type 1, 2, or 3 after one failed therapy
Type 4b	Type 1, 2, or 3 after more than one failed therapy
Type 5	Mediastinitis presenting 6 weeks or more after operation

Table 2. Classification scheme of mediastinitis introduced by El Oakley and Wright based on the time at which the patient presents with mediastinitis relative to the initial surgical procedure (modified from El Oakley and Wright [23]).

The classification by Jones et al differs from that of El Oakley and Wright in that it is more descriptive anatomically and physiologically [26, TABLE 3]. Three different “types” of sternal infection are described, encompassing both superficial and deep infections, and based on the degree of underlying tissue involvement with infection. We have preferred the use of this classification system as it is simpler to use since it based strictly on features observed or encountered at the time of initial sternal exploration. In addition, Type 3b is physiologically meaningful since it denotes the patient who is systemically ill from the sternal wound process. In our own institutional experience of 222 adult cardiac surgical patients treated for postoperative DSWI, approximately 50% of patients exhibited septicemia (Jones 3b) upon initial presentation [14].

Class	Depth of Involvement	Description
1a	Superficial	Skin/subcutaneous tissue dehiscence
1b	Superficial	Exposed deep fascia, sutures intact
2a	Deep	Exposed bone, stable wired sternotomy
2b	Deep	Exposed bone, unstable wired sternotomy
3a	Deep	Exposed necrotic or fractured bone, unstable, heart exposed
3b	Deep	Types 2 or 3 with septicemia

Table 3. Mediastinal wound classification system modified from Jones et al [26]. Although anatomic involvement by infection is distinguished, the presence of septicemia is the most important feature clinically.

4. Risk factors and pathophysiology

Multiple different etiologies for development of DSWI have been invoked over time. For example, most infections were traditionally thought to arise as a result of breaks in proper surgical technique, prompting strict guidelines for sterile surgical technique. In addition, secondary involvement the mediastinum from remote sites such as leg incisions or the pulmonary tree has also been suggested as a mechanism for DSWI. The “endogenous pathway,” seeding of the mediastinum from other host sources, does appear to be important in the development of *S. aureus* mediastinitis. To illustrate, Jakob et al showed that nasal carriage of *S. aureus* was an independent predictor of sternal infection postoperatively [28], while others have demonstrated that application of mupirocin to the nares of *S. aureus* colonized individuals can help reduce postoperative infection [29]. More recently, other factors have been recognized as important contributors to cardiac surgical site infections. For instance, the appropriate timing of perioperative antibiotics and strict perioperative glucose control are both associated with reduced surgical wound infectious complications [30, 31]. Several different patient-related factors have been repeatedly implicated in the development of DSWI, most consistently obesity and diabetes mellitus [5, 6, 32, TABLE 4]. Eklund et al and others have observed that increasing severity of obesity elevates the risk for surgical site infection in a step-wise fashion [6, 13, 33]. Furthermore, when obesity is described in terms of percentage body fat, the relationship between obesity and surgical site infection is nearly linear and appears more accurate than use of body mass index as a descriptor of obesity [34]. Potential explanations for relationship between obesity and DSWI include technical problems

Study	# Patients	Identified Risk Factors
Milano CA, et al. Circulation 1995 [9]	6,459	Obesity, NYHA class, redo surgery, CPB duration
Toumpoulis IK, et al. Chest 2005 [55]	3,760	Diabetes, preoperative hemodynamic instability, renal failure, bilateral IMA, sepsis and/or endocarditis
Immer FF, et al. Ann Thorac Surg 2005 [94]	5,690	Obesity, diabetes mellitus, COPD, bilateral IMA
Fowler G, et al. Circulation 2005 [13]	300,000	Obesity (BMI of 30-40 kg/m <sup>2</sup> ), diabetes, previous MI, urgent operative status, hypertension
Prabhakar G, et al. Ann Thorac Surg 2002 [32]	559,004	Obesity
Sjorgren J, et al. Ann Thorac Surg 2005 [90]	4,826	Diabetes, obesity, reduced EF, renal failure, multi-vessel CAD
Olsen MA, et al. J Thorac Cardiovasc Surg 2002 [10]	1,980	Obesity (BMI>30 kg/m <sup>2</sup> ), diabetes, > 4 units RBC transfusion, IABP, current smoking
Cayci C,et al. Ann Plast Surg 2008 [52]	7,978	Obesity (BMI>30 kg/m <sup>2</sup> ), diabetes, urgent operation, recent smoking; h/o CVA, total HLOS, sepsis/endocarditis postop
Risnes I, et al. Ann Thorac Surg 2010 [12]	18,352	COPD, obesity (BMI > 30 kg/m <sup>2</sup> ), blood transfusion, advanced age, male sex, diabetes

Table 4. Compiled analyses for underlying risk factors associated with sternal wound infection. Obesity and diabetes mellitus are consistently shown to be independent predictors of poststernotomy mediastinitis.

during surgery owing to the patient’s size, increased bleeding, increased deadspace in the wound, and ineffective or inadequate dosing of perioperative antibiotics [6, 9]. Although multiple mechanisms for sternal wound complications are proposed, it is widely accepted that reduced sternal perfusion, often by virtue of internal mammary artery (IMA) harvesting for use as a vascular conduit in coronary artery revascularization, is one of the most important causes of sternal nonhealing and infection [1-6, 8, 26], especially when both IMAs are harvested for bypass graft surgery [5]. Therefore, more cases of DSWI appear to occur after coronary artery bypass grafting or after combined procedures that include coronary artery surgery [7, 35]. Other viable explanations for DSWI etiology include poor bone stock from osteoporosis, malnutrition, and other factors; poorly performed sternotomy leading to sternal fractures and/or costosternal disassociation; and other patient related factors including peripheral vascular disease and lung disease [8, 36]. Several other factors have been implicated in the development of DSWI but may not be manifest in the context of a retrospective review or randomized trial because the numbers are too low. For example, it is generally accepted that postoperative steroids or chronic immunosuppression increases risk for DSWI, but this has been difficult to demonstrate in even large database reviews [13, 37]. Finally, Risnes et al have demonstrated in a review of over 18,000 consecutive patients undergoing coronary artery surgery in Norway, the major preventable risk factor associated with the development of DSWI was the amount of blood product transfusion perioperatively [12].

Several risk analyses are available to estimate the individual patient's propensity for developing DSWI. For example, using Society of Thoracic Surgery National Cardiac Database information, Fowler et al created a model to estimate the risk for systemic infection after coronary artery bypass surgery using patient characteristics available preoperatively [13]. The Fowler model also provides for inclusion of important intraoperative details known to influence postoperative infection including the need for intra-aortic balloon counterpulsation and prolonged cardiopulmonary bypass times [13]. Although the model devised by Fowler et al was based on various cases of major infection after coronary artery surgery, including DSWI, the authors did validate the model as predictive of infection in a test population from the STS Database, and the model was also recently validated in a different cohort of patients from the UK as being predictive of DSWI [38]. The EuroSCORE system also has been shown to predict infection and associated mortality with acceptable discrimination [39].

## 5. Incidence

Despite advancements in most aspects of perioperative care, rates of sternal wound complications, including mediastinitis, following adult cardiac surgery have varied little over the past 30 years [2-6], although incremental reduction in single center rates of DSWI have been noted and attributed to adjunctive measures such as strict perioperative glucose control [40]. As noted previously, rates of DSWI vary with regard to the specific definition used to describe the pathology encountered and the patient population studied. In general, reported rates of DSWI are relatively low, ranging from 0.25% to 3.6 % [2-9, 38, 39, 41, 42]. However, the incidence of superficial sternal infection exceeds that of deep sternal infection by as many as three times [10, 41, 43], and Francel has stated that as many as 70% of patients with poststernotomy infection will have superficial tissue involvement [44].

## 6. Diagnosis

Depending on the virulent nature of the sternal wound infection, patients typically present within 30 days of cardiac surgery. The most common symptoms include sternal wound drainage, sternal instability, fever, and malaise. In many cases, a high index of suspicion is required to establish the diagnosis, especially when classic signs and symptoms are absent. In addition, it is often difficult to distinguish on physical examination the difference between deep sternal wound infection (infection present beneath the sternum) and superficial sternal infection. Therefore, early wound opening and inspection with appropriate sampling of tissue for bacteriologic assessment is strongly encouraged when sufficient clinical suspicion exists.

One of the most reliable signs of DSWI is sternal instability, which frequently implies a deeper problem than can be appreciated at the superficial level [44]. While sternal instability can be tested on physical examination, we have often noted that the patient themselves will typically report sternal clicking with inspiration, cough, or various other physical maneuvers, so this information should be thoughtfully considered if DSWI diagnosis is being entertained.

The use of various radiographic examinations is often encouraged when evaluating for DSWI, and, in fact, is included as part of the CDC guidelines for defining mediastinitis [25]. Formerly, PA and lateral chest radiograph was the investigative procedure of choice, where details such

as a “sternal stripe” indicated present of air between the two sternal halves. The lateral displacement of one or more sternal wires, secondary to tearing of the wire through one side of the sternum, has been a frequently noted finding in the case of poststernotomy infection [37]. More recently, chest computed tomography has been suggested as the procedure of choice for assessing sternal wound infection when a diagnosis cannot be established by clinical examination alone [45, 46]. Mediastinal fluid collections, free gas bubbles, soft tissue swelling, pleural effusions, sternal dehiscence, and subcutaneous fluid collections have been the predominant CT findings in cases of DSWI [47], but these features appear to be more specific and sensitive for DSWI presenting more than 3 weeks after surgery [48].

## 7. Morbidity and mortality

Mediastinal infection negatively impacts early, mid-term, and long-term survival after adult heart surgery [2, 7-12]. While it is intuitive that clinically serious DSWI reduces 30-day and/or in-hospital survival relative to similar patients not suffering this complications, the effect of DSWI on long-term survival is especially insulting since many patients referred for heart surgery expect to gain a survival advantage compared with other treatment options for their underlying heart disease [49].

Prior to the development of modern protocols for DSWI management, which include thorough sternal debridement and use of vascularized flaps to repair the mediastinal defect resulting from debridement, early mortality from DSWI exceeded 50% [50]. In the “modern era,” reported rates of in-hospital or 30-day DSWI mortality for range from 7% to over 30% [11,14, 35, 42, 51, 52]. In our own recent experience, early mortality for DSWI is approximately 16% [14]. Therefore, despite many advancements in intensive care medicine, DSWI continues to be a deadly complication. Death in the early period is typically the result of sepsis or other infectious complications including multiorgan failure [12]. Morisaki et al. recently demonstrated methicillin-resistant *S. aureus* infection to be an independent risk factor for in-hospital mortality in their cohort of poststernotomy DSWI patients [53].

Patients surviving infectious complications and the acute insult of DSWI exhibit reduced mid-term survival compared with controls. For example, one-year mortality for DSWI following CABG is significantly increased compared with similar patients who did not develop DSWI [2, 8, 10]. Milano et al and Braxton et al both demonstrated a doubling of mid-term mortality among patients with DSWI after CABG compared with controls [9, 54]. Karra et al examined predictors of one-year mortality after treatment for DSWI and found that delay in closing the mediastinal defect; age over 65 years; need for ICU care prior to sternal debridement; and methicillin-resistant *S. aureus* infections were each independently associated with mortality [7].

Long-term survival has consistently been demonstrated to suffer in patients with a history of poststernotomy DSWI [5, 8, 9, 12, 35, 52, 54-56, Figure 1]. For example, Filsoufi et al reviewed nearly 5,800 adult heart surgery patients at a single institution over 8 years and found DSWI to be associated with significantly reduced 5-year survival compared with patients who did not develop DSWI [35]. Similarly, Risnes et al reviewed their experience of over 18,000 cardiac surgical patients with a mean follow-up of over 10 years. Long-term survival for patients whose course was complicated by DSWI was <50% compared with >70% for patients without DSWI, and DSWI was independently associated with reduced long-term survival after cardiac surgery [HR 1.59; 95% CI 1.16 - 2.70,  $p = 0.003$ ] [12]. Similar data have been also been reported by Toumpoulis et al. [55].

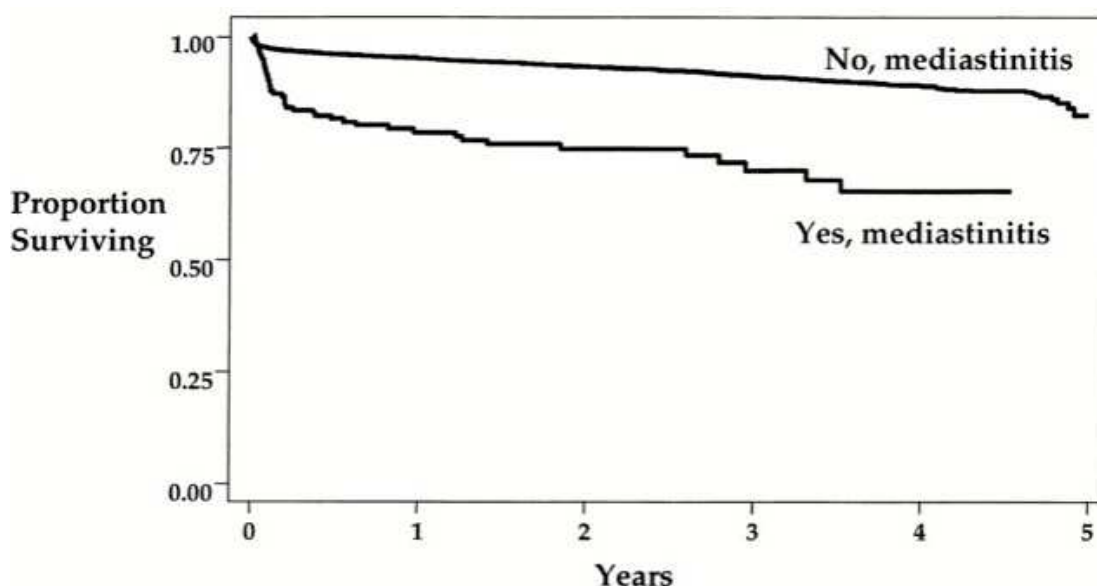


Fig. 1. From Braxton et al with permission [8], patients suffering mediastinal infection after coronary artery bypass grafting have worse overall long-term survival compared with similar patients not experiencing the complication.

It is unclear as to the specific reasons for worse long-term survival after DSWI is successfully treated, but cardiac-related deaths or progression of cardiovascular disease appears to be a common cause of death for those with DSWI [8, 12]. In addition, Chu et al recently reported that patients with peripheral vascular disease had worse outcomes long-term after coronary artery surgery [57]. We recently evaluated long-term survival in a cohort of 222 adult cardiac surgical patients treated at Duke University Hospital for poststernotomy mediastinitis. Using multivariable regression analysis and at a mean follow-up of 5.5 years, the following variables were noted to be independently associated with survival: heart failure [Hazard ratio (HR) 1.58,  $p = 0.029$ ]; sepsis [HR 2.38,  $p < 0.001$ ]; peripheral vascular disease [HR 2.06,  $p = 0.001$ ], age  $> 65$  years [HR 1.61,  $p = 0.037$ ]; and take back for bleeding [HR 2.96;  $p = 0.007$ ] (unpublished data).

Not only does DSWI lead to increased mortality among post-surgical patients, it is also closely associated with other types of postoperative complications. For example, in a recent review of morbidity following coronary surgery from the Virginia Cardiac Surgery Quality Initiative, DSWI was the not only the most expensive complication, but it was also associated with a longer length of hospital stay, by more than two full weeks, than any other single postoperative complication, including perioperative stroke and renal failure [4]. Other reports have corroborated the impact of DSWI on overall hospital length of stay [2, 6, 52]. Speir et al also demonstrated that DSWI was the most likely form of postoperative morbidity to be associated with other complications such as prolonged ventilation, bleeding, renal failure, and atrial fibrillation [4]. DSWI has also been associated with increased rates of stroke, need for inotropic or mechanical cardiac support, and perioperative myocardial infarction, renal failure, and prolonged mechanical ventilation [12, 51].

## 8. Microbiology

Numerous bacterial pathogens may contribute to DSWI, but the most commonly isolated organisms are *Staphylococcus*, either coagulase-negative *Staphylococcus* (CNS) or *S. aureus*

[58]. In our own recently described experience, methicillin-sensitive and methicillin-resistant *S. aureus* each accounted for 35% of wound isolates, while CNS was present in 12%, and gram negative organisms were found in 18% [14]. It is noteworthy that our protocols for preoperative preparation of the cardiac surgical patient do not routinely incorporate mupirocin treatment. Additionally, many patients included in our cohort of patients treated for DSWI underwent primary cardiac surgery at referring facilities. Therefore, specific details in these patients predisposing to a certain pathogen were often lacking. Risk factors for the development of methicillin-resistant *S. aureus* poststernotomy mediastinitis include previous hospitalization and takeback for bleeding after the original cardiac surgical procedure [59]. Gardlund et al have attributed the development of *S. aureus* infection to the development of bacteremia [60], which is corroborated by our own data in which 50% of patients treated for DSWI had evidence of bacteremia or septicemia (Jones classification 3b) at the time of clinical presentation with DSWI [14]. Finally, it has been demonstrated that methicillin-resistant strains of *S. aureus* are more virulent and deadly than methicillin-sensitive strains, and, in fact, methicillin resistance was the only independent predictor of early mortality in one analysis [61].

In contrast, *S. epidermidis* often presents with a rather indolent course, often not manifesting clinically until 3 weeks or more postoperatively [62]. CNS is frequently isolated in cases of sternal instability or nonunion, which may itself arise from obesity or acute or chronic pulmonary disease [60]. CNS has recently been noted to of increasing incidence and has been reported to be present in roughly 50% of sternal infections in some series [6, 11, 60].

Gram negative organisms contribute less commonly to the pathogenesis of DSWI. Gram-negative infections of the mediastinum classically arise in the setting of other postoperative infectious complications such pneumonia, urinary tract infections, intra-abdominal infections, or other nosocomial infections [58, 60]. Mekontso-Dessap et al reviewed their experience with DSWI after cardiac surgery and found that Enterococcus species were the most common isolates in early cases of DSWI (<14 days), which likely arise from translocation of these bacteria from other sources in the host [63]. In contrast, *Staphylococcus* species, often CNS, were the most common isolates in cases presenting more remotely from the original surgery [63].

## 9. Cost of DSWI

One of the most impactful consequences of DSWI is the costs incurred in its management, in part due to the multiple associated conditions that frequently complicate the clinical picture of these sick patients [4, 12]. The average hospital costs for patients treated for DSWI is approximately 2.5 to 3 times that of similarly matched patients who enjoy an uncomplicated postoperative course [23, 64, 65]. As noted, increased costs are primarily attributed to associated comorbid conditions that arise during the treatment of mediastinitis, increased length of hospital stays, including frequent need for ICU services, and the need for multiple surgical procedures when using traditional approaches to DSWI [4, 23]. For example, Hollenbeak et al found that patients with DSWI remained hospitalized an average of 3 weeks longer than noninfected patients after coronary artery surgery [2]. Interestingly, in the same study it was noted that DSWI patients who ultimately expired incurred nearly \$61,000 US dollars more in costs than other DSWI patients who ultimately survived, presumably secondary to the multiple comorbidities associated with clinically aggressive mediastinitis [2]. Using more recently acquired information, Speir et al found that mediastinitis was the single

most costly complication in Virginia after coronary artery surgery, raising the cost of care by over \$62,000 US dollars, or more than 240% increase, on average, [4].

Therefore, it is apparent that treatment of these critically ill patients is extremely expensive to the hospital system, even if the complication is uncommonly encountered. As a result, and based on increased scrutiny of various hospital-associated conditions, the US Center for Medicare and Medicaid Services no longer reimburses for hospital costs incurred in treatment of DSWI following coronary artery bypass surgery [66]. Interestingly, however, it appears that use of negative pressure therapy in the treatment of DSWI contains associated costs. For example, Mokhtari et al reported the use of VAC therapy to be cost effective and efficacious in eradicating mediastinal infection [65]. In our own experience, patients treated with negative pressure therapy for DSWI had costs that were \$150,000 US dollars less than the average Medicare charges for treatment required for DSWI (\$152,00 vs. \$ 300,000) [67].

## 10. Treatment of DSWI

Upon establishing the diagnosis of sternal wound infection, the immediate goal of treatment is complete eradication of infection followed by stabilization of the sternum and chest wall. Multiple strategies for managing mediastinitis have been proposed and range from open mediastinal packing to debridement with closure over drains, to placement of vascularized tissue flaps. In addition, negative pressure therapy (NPT) has been used to aide in the treatment of mediastinal infection, as first reported in 1999 [68]. Several initial series described the use of NPT for treating mediastinitis and outlined potential benefits of this approach to controlling mediastinal infection [15, 16, 45, 69, 70]. However, a consensus as to best treatment for mediastinal infection has yet to be established. For example, Schimmer et al recently surveyed 79 cardiac surgery programs in Germany to query DSWI management strategies [71]. They found that approximately 1/3 of the centers preferentially used NPT for controlling mediastinal contamination, while another 1/3 use closed chest irrigation, and another 1/3 combine management approaches [71]. Other groups continue to advocate more aggressive surgical therapy in addressing infected sternal wounds [7, 72].

Initially, the primary treatment for DSWI was open packing followed by secondary closure [73]. This method was labor intensive, cumbersome, and was characterized by significant rates of recurrent infection and other complications [58]. Shortly thereafter, Schumaker and Mandelbaum proposed early closure over drains [74], which allowed continual irrigation of the infected mediastinum [73, 74]. Although this approach represented an improvement relative to open packing procedure, the latter procedure was still associated with failure rates of at least 25% [73].

Omental flap repair of the infected mediastinum was originally reported in 1976 by Lee [75] and has been shown to have distinct advantages over continuous antibiotic irrigation through drains [76] and over muscle flaps for sternal wound defect repair [9, 14]. This is thought to occur by obliterating dead space, a mechanism that can also be credited to muscle flap repair of the open mediastinum [26]. However, the omentum may have angiogenic and immunologic properties that stimulate more complete sternal defect healing [58]. Other advantages of using the greater omentum to flap the sternal defect include superior malleability and excellent blood flow. As originally described, traditional omental flap repair of the mediastinum involves a laparotomy to mobilize and place the graft through the anterior portion of the diaphragm [Figure 2]. More recently, harvesting the

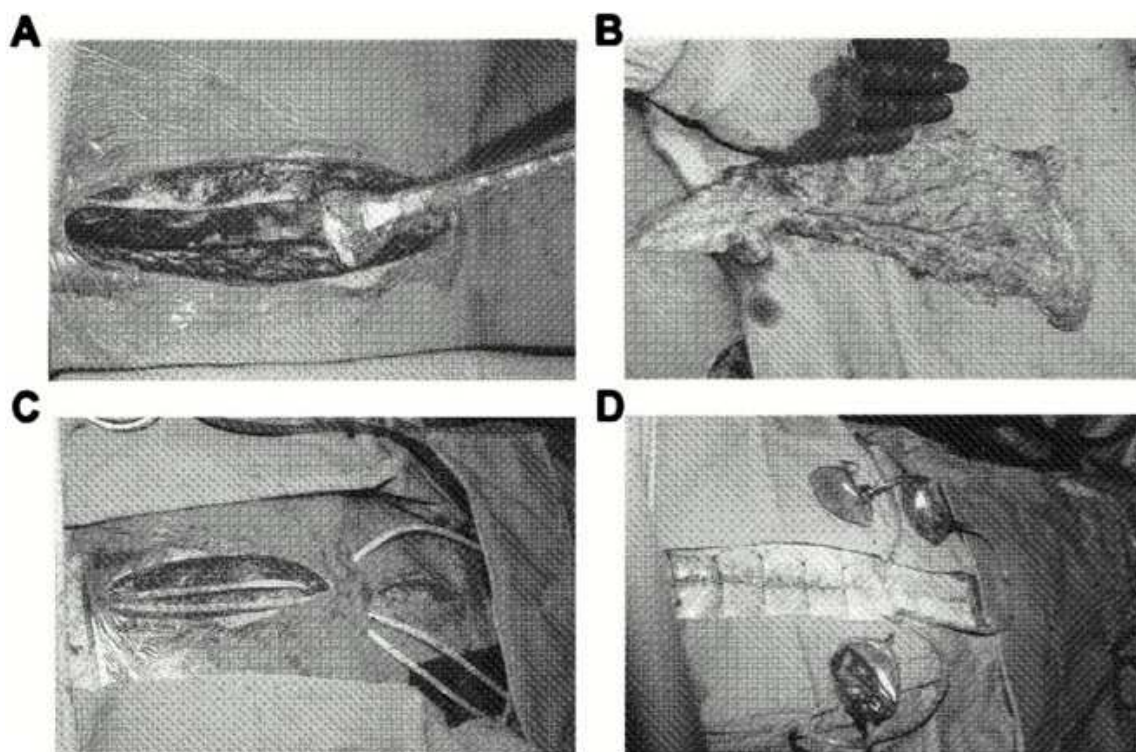


Fig. 2. Preparation of the omental flap graft for transfer to the mediastinum from Milano et al with permission [80]. After preparation of the mediastinum [A], a laparotomy is performed and the greater omental graft is prepared by mobilizing it from the transverse colon [B]. Once the graft is tunneled through an anterior diaphragm incision, it is secured in the mediastinum to fill the defect. Care is taken to avoid twisting or kinking the omental graft as it is delivered from the abdomen into the mediastinum [C]. The mediastinum is then closed over drains with retention sutures. The drains are placed to bulb suction [D].

omental pedicle using a laparoscopic approach may have advantages over open abdominal procedures and has been utilized successfully [77].

Jurkiewicz et al first reported on the successful use of muscle flaps in DSWI in 1980 [78], while the Emory groups' experience with muscle flap repair of the infected mediastinum refined approaches and clarified advantages of these techniques [26]. As with omental flap repair, discrete advantages of complete mediastinal repair with vascularized muscle flaps were demonstrated as compared with closed chest irrigation [26, 79]. Milano et al compared omental and pectoralis muscle flap repairs for the infected mediastinum and found that procedural details, early complications, and hospital length of stay were all improved with omental flap repair [80]. Omental flap repair also trended towards improved survival and reduced chronic pain when compared with pectoralis flap procedures [80]. In fact, significant long-term complications can be associated with muscle flap repair of the mediastinum including paresthesias, sternal instability, truncal weakness, and prolonged pain syndromes [9, 26, 81, 82]. Reporting on the long term results of muscle flap coverage of the mediastinum, Ringelman noted persistent pain in over 50% of patients, numbness and paresthesias in 44%, sternal instability in over 40%, and shoulder weakness in 1/3 of patients [82]. It is worth noting, however, that unfavorable outcomes with open packing and/or mediastinal irrigation prompted recommendations for aggressive mediastinal debridement including radical sternectomy

[78, 83]. While effective in removing devitalized and infected tissue, the resulting sternal defect required large-volume vascularized tissue such as muscle flaps or large omental flaps to obliterate deadspace. As a result, many of the negative long-term consequences often experienced and attributed to muscle flap repair may actually have originated with radical sternal debridement. After the introduction of NPT management of mediastinal sepsis/infection, radical sternal debridement has been de-emphasized [14, 16, 83, 84]. Stated differently, the use of NPT to treat the infected mediastinum helps to avoid radical sternal debridement and likely avoids chronic syndromes previously seen and perhaps erroneously attributed to treatment methods.

Obdeijn et al introduced the use of negative pressure therapy (NPT) for treatment of the infected mediastinum after median sternotomy [68]. The introduction of vacuum-assisted closure (VAC®) technology [Kinetic Concepts Inc. USA San Antonio, TX], based on the application of negative or subatmospheric pressure to the wound, has improved management of DSWI, as demonstrated by several groups including our own, and is now considered a cornerstone in the management of these complex clinical scenarios [14, 15, 70, 73]. Negative pressure therapy appears to induce effective proliferation of the effectors of wound healing [85] removes wound exudates, improves regional blood flow [86], and reduces accumulation of inflammatory mediators such that earlier and more complete wound healing results [70]. Laboratory studies also show that NPT induces early wound healing through microdeformations within the wound, stimulating cell division, proliferation, and angiogenesis [73, 87]. One distinct advantage of the mechanisms of NPT is more thorough eradication of infection, stimulation of vigorous wound granulation, and the subsequent promotion of safe and effective sternal closure either primarily or with rigid osteosynthesis [11, 14, 88]. Wound treatment with NPT appears to be significantly lower rates of recurrent wound complications such as reinfection, seromas, or hematomas [14, 89, 90]. However, there is a recognized tendency for recurrent infection when MRSA is the inciting organism or with prolonged mechanical ventilation [91].

Clinically, NPT has been associated with significantly lower mortality rates in the acute management of mediastinitis [11, 89]. For instance, Petzina et al recently compared 118 patients with poststernotomy DSWI and demonstrated that patients treated with NPT had better survival and less sternal re-infection compared with patients in whom NPT was not used [89]. In addition, as may have been expected, shorter hospital stays were noted within the NPT group. Baillot et al reported similar results by, while documenting a reduction in acute DSWI mortality from 14.1% to less than 5% when NPT was incorporated into treatment regimens [11]. Finally, De Feo et al evaluated 157 patients with poststernotomy DSWI at a single institution over 15 years. Patients in whom NPT was incorporated in the treatment regimen had reduced early mortality rates and, reduced reinfection rates, and slightly reduced overall hospital stays [92].

As noted previously, long term mortality among patients with DSWI has been historically poor compared with similar patients not suffering the complication, but recent evidence suggests this may be changing. The first evidence for this phenomenon was reported by Sjogren et al, who compared 46 patients with poststernotomy mediastinitis managed with NPT with a matched cohort of cardiac surgical patients not experiencing postoperative mediastinitis [93]. Actuarial and adjusted 5-year survival was not different between groups, demonstrating for the first time that long-term results of heart surgery were not negatively impacted by DSWI [Figure 3].

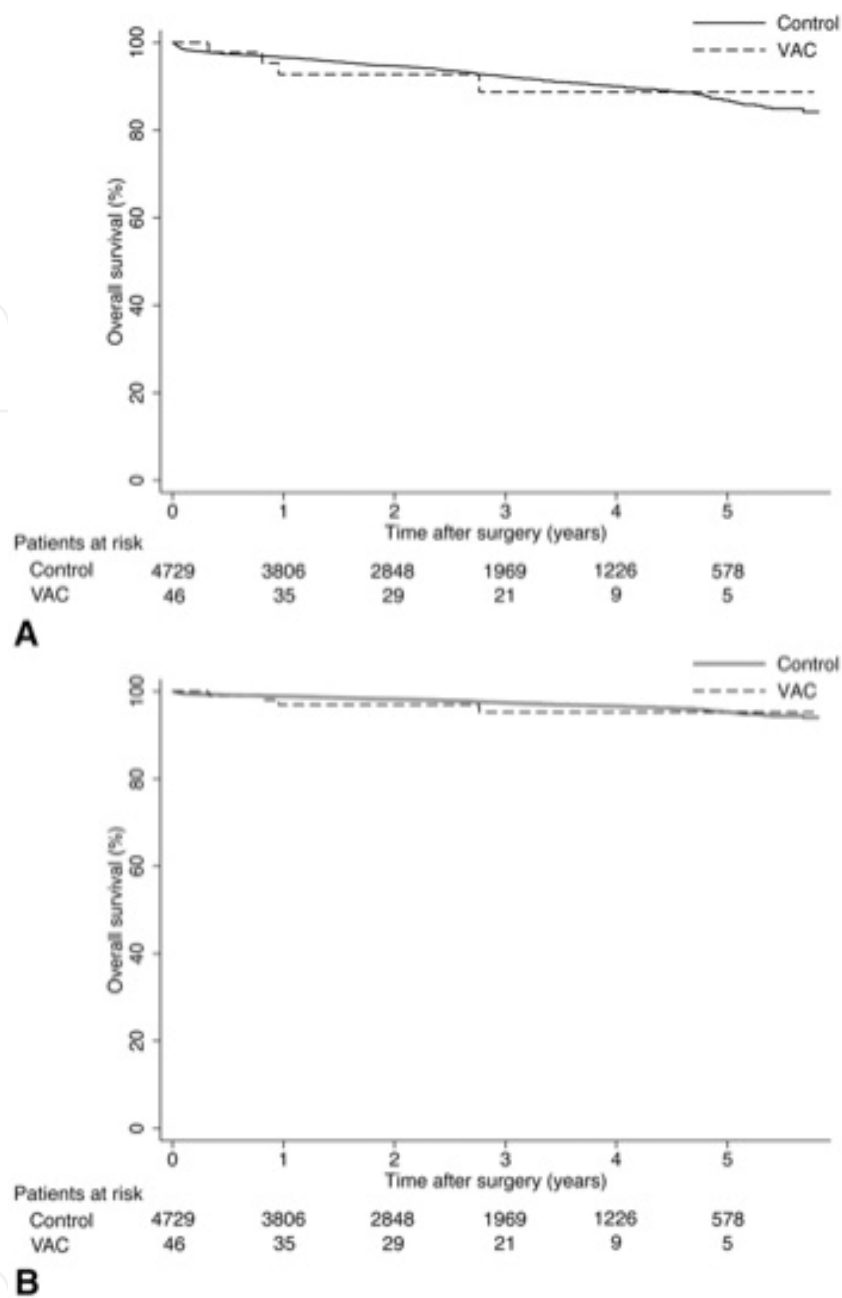


Fig. 3. Actuarial (panel A) and adjusted (panel B) survival curves for patients with poststernotomy mediastinitis treated with vacuum-assisted closure (VAC) as compared to control subjects who did not experience mediastinitis after heart surgery. No difference in long-term survival was demonstrated between the groups. From Sjogren et al [93], with permission.

Another study from the UK demonstrated that midterm survival for patients with postoperative mediastinitis was similar to patients not suffering the complication [51]. Similar results have been reported by Cayci et al from Columbia University, who found that DSWI was associated with increased early mortality but long-term survival was not different from controls. Furthermore, DSWI was not an independent predictor of mortality in their single-center experience [52]. It is unclear as to why this may be the case, but it is notable that NPT was used in over 80% of patients with mediastinitis as a

means for clearing infection, and nearly 50% of patients in their cohort were managed with vac therapy alone or vac + secondary sternal closure. In our own series, we found that use of NPT for controlling mediastinal infection was an independent predictor of survival on multivariable analysis [unpublished data], and that patients managed with NPT had significantly improved long term survival compared with patients not treated with NPT [Figure 4].

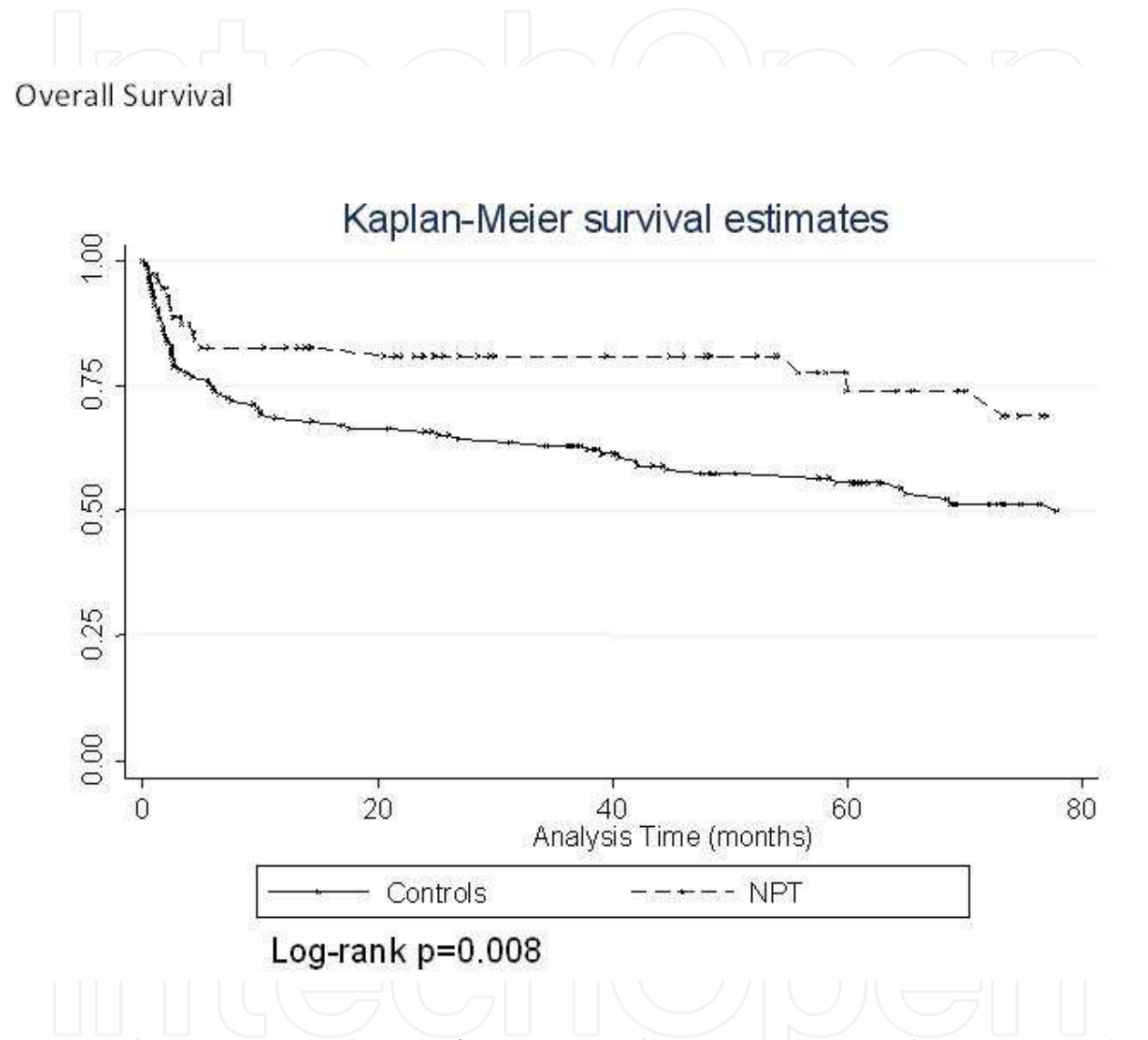


Fig. 4. Kaplan Meier survival curves for patients with poststernotomy mediastinitis treated with negative pressure therapy (NPT) or by traditional means for controlling mediastinal infection (controls). Patients treated with NPT had significantly improved long-term survival by log rank analysis.

11. Suggested treatment algorithms for DSWI

While accumulating extensive experience with DSWI management as a referral center for these difficult problems. We and others have formalized protocols for managing mediastinal infection utilizing NPT which allows sternal salvage and improved outcomes in the majority of cases of DSWI [14-16, Figure 5].

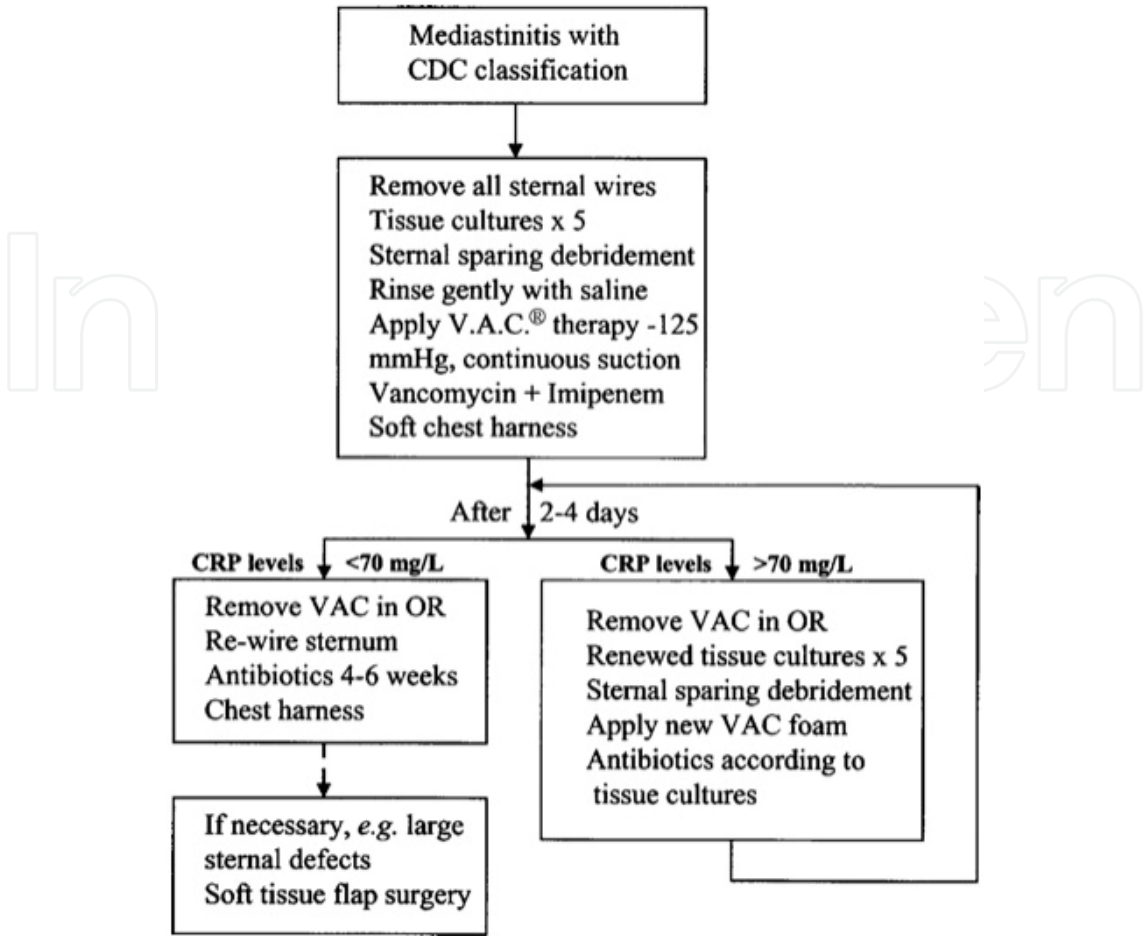


Fig. 5. Suggested algorithm for management of mediastinal infection after cardiac surgery via median sternotomy, with permission from Sjogren et al [15]. Emphasis is placed on gentle sternal debridement, negative pressure therapy to the mediastinum, and closure based on monitored serum C-reactive protein levels.

As noted previously, successful treatment of DSWI begins with recognition of signs and symptoms of sternal infection, which may occasionally be subtle. Sternal wound exploration to ensure a prompt and accurate diagnosis is warranted when signs of mediastinitis are present. This approach also helps to distinguish between superficial and deep sternal infections. At the time of initial sternal exploration, tissues and fluid should be obtained for bacteriologic analysis. Targeted antibiotic therapy for 4-6 weeks duration is prescribed and is determined by the culture results [14, 15]. If the infectious process extends beneath the facial layer, all sternal hardware should be removed. The sternum itself is then gently debrided of grossly devitalized tissue, but wide excision of the sternum is not necessary and may be injurious and counterproductive. Limited sternal debridement is now preferred and good results have been seen with this approach [14, 16, 83, 93, 94]. Negative pressure therapy is then instituted on the opened incision after limited sternal debridement. The polyurethane foam is subsequently changed in the operating room or at the bedside every 2-3 days. During this time, assessment as to the state of the sternum is made to determine if mediastinal flap repair is required or if secondary sternal closure is possible. Our general approach for determining when the sternum can reliably be reapproximated is based on the state of the sternum after several days of NPT. Wound characteristics precluding secondary

sternal reapproximation include multiple transverse sternal fractures, poor bone stock, costosternal separation, or the requirement for such extensive sternal debridement that reapproximation of the sternal halves is not feasible. Gustafsson et al have advocated use of serum C-reactive protein levels to guide wound closure timing [95, Figure 6]. C-reactive protein levels less than 70 mg/L corresponded with successful sternal reapproximation [95]. Successes have also been reported with sternal plating as a treatment for the fractured sternum [11, 96], but our approach has been conservative in this regard since any residual infectious process could contaminate the implanted hardware [91].

Numerous clinical advantages for DSWI management protocols incorporating NPT have been observed, many centered upon the sternal stabilization achieved when vacuum-assisted closure is engaged [70]. The sternal stability afforded by NPT improves pain compared with open packing or other approaches for addressing the infected mediastinum [88]. In addition, the stabilized sternum yields several pulmonary benefits, the first of which is the ability to successfully separate from mechanical ventilation. This promotes earlier and more effective patient mobilization and prevents the patient from being confined to bed, where other complications common to DSWI therapy are often incurred [70]. Negative pressure therapy also improves ventilation and overall pulmonary function and leads to more effective chest physiotherapy [70, 97]. Importantly, no deleterious hemodynamic effects of NPT have been documented although this has been speculated [70].

## 12. Complications of treating mediastinitis

It has been estimated that approximately 15% of patients develop recurrent infection [98]. In the experience of Bapat et al, this has included recurrent infection with the same organism associated with the original sternal infection [99], and we speculate that if the polyurethane foam required for NPT is not adequately inserted with each dressing change, small, isolated spaces may arise within the wound that can become superinfected. We recently reported rates of recurrent wound complications associated with various mediastinal flap coverages. For example, muscle flap repair of the treated mediastinum, consisting predominantly of pectoralis muscle flaps, was associated with increased rates of recurrent wound complications such as hematoma, seromas, and recurrent infection [14]. Conversely, use of NPT prior to definitive repair of the sternal wound defect was associated with increased rates of successful secondary sternal closure without the need for any flap transfer, and with shortened length of hospital stay after definitive repair. Excellent results have been reported elsewhere when NPT is incorporated into management protocols for DSWI [65].

Petzina et al recently reported a 7.2% rate of “major complications” associated with NPT for DSWI in a cohort of 69 patients. Most complications were bleeding-related [100]. On the other hand, cardiac function and hemodynamics appear to be stable during NPT to the open mediastinal wound [101, 102].

When NPT is used, caution should be exercised with regard to the length of therapy. In our own experience, prolonged use of NPT leads to a “frozen” mediastinum, making subsequent closure by vascularized flaps or other technique difficult to perform and places the cardiac structures at risk for injury during subsequent sternal repair. Others have noted the similar difficulties [99]. In such cases, continued application of NPT to closure by secondary intent may be the best therapeutic option rather than to place the mediastinal structures at risk for injury during attempted flap repair.

### 13. Can mediastinitis be prevented?

Loop has stated: “prevention and better treatment of sternal wound complications must be a major goal in assuring the highest quality of cardiovascular care...[5]. Although most efforts towards DSWI have focused on the treatment of DSWI, several methods to reduce rates of mediastinitis have been proposed and validated recently. As a result, efforts to prevent mediastinal infection may already be working. For instance, investigators from Boston recently reported on their experience with DSWI between 1992 and 2006, separating analysis into early and late time periods. They noted that DSWI had decreased from 1.57% to 0.88% over the last 5 years of their analysis and attributed the positive findings to adoption of strict glucose control algorithms [40]. Tight glycemic control appears to be effective in significantly reducing rates of DSWI. [30, 103]. In addition, Lazar et al demonstrated improved coronary surgery outcomes with a strategy for strict glucose control (125 – 200 mg/dL) using glucose-insulin-potassium solution, including reduced ischemic events and improved rates of wound infection in a cohort of diabetic patients undergoing CABG [31].

Antimicrobial therapy has also positively impacted rates of DSWI. Most notably, appropriate timing and selection of preoperative antibiotics has been associated with reduced rates of surgical site infection [6, 104]. Furthermore, use of nasal mupirocin in patients undergoing cardiac surgery via median sternotomy eradicates 95 – 100% of *S. aureus* for up to one year postoperatively [105], and sternal wound infections are also reduced by nearly 2/3 in some series with the use of mupirocin in patients colonized with *S. aureus* [106, 107].

Technical details of the median sternotomy incision and closure almost certainly impact the likelihood for DSWI postoperatively. Baskett et al have argued that assiduously following technical details and proper surgical and aseptic techniques can also dramatically reduce rates of poststernotomy infection [42]. They emphasize the importance of accurate reapproximation of the sternal halves and caution against the use of bone wax to gain sternal hemostasis [42]. Since sternal instability is often evoked as one mechanism contributing to the development of sternal infection, evaluation of the most effective sternal closure methods has been undertaken. For example, Schimmer et al compared standard closure techniques by transsternal or peristernal wiring with techniques using additional lateral wire reinforcement in the method described by Robicsek in a cohort of 815 high-risk patients [108]. There were no differences observed in the rates of sternal dehiscence or superficial or deep sternal wound infections, but they did show that more sternal wires placed for closure was associated with significantly reduced rates of DSWI [108]. Others have emphasized that rigid sternal closure techniques are preferred, particularly in those considered at high risk for sternal wound complications such as dehiscence and infection. These techniques are widely used in most surgical practices that incorporate osteotomy incisions. In fact, cardiac surgery is now the only discipline not routinely repairing osteotomies with rigid plating techniques [109]. Lee et al recently reported their experience with titanium plate fixation of the sternum in 750 patients at high risk for sternal wound complications, noting 97.6% freedom from sternal infection or dehiscence [110]. Levin et al have also introduced another form of rigid sternal closure as an alternative to wire circlage and highlighted advantages to this approach [111]. Although rigid sternal closure techniques have not been compared prospectively with wire circlage, cadaveric studies have shown rigid plate fixation techniques to be superior to wire circlage by providing increased stiffness to the wound closure and less lateral displacement of the sternal halves [112].

Other suggested techniques for reducing the incidence of DSWI include ensuring true midline sternotomy as this is thought to preserve periosteal blood flow and limits transverse sternal fractures which contribute to sternal nonunion and instability [42, 44]. Since sternal ischemia is thought to play an important role in most cases of DSWI, limiting the length of internal mammary artery harvested for use as a coronary artery bypass conduit or avoiding its use altogether in prohibitively high risk patients may help to reduce DSWI [44]. Harvesting the internal mammary artery as a skeletonized conduit is also preferable to harvesting the graft as a pedicle since this preserves more peristernal blood flow [113]. Finally, sternal foreign bodies that may impede bony union, especially bone wax, should be avoided [42, 44]. In contrast, vancomycin paste or gentamicin-soaked absorbable sponges applied to the sternum upon closure have been shown to reduce rates of sternal bacterial contamination [114, 115]. However a more recent randomized controlled trial evaluating the impact of gentamicin-soaked collagen sponge on poststernotomy wound infection did not show an advantage of this approach over controls [116].

Based on the aforementioned successes with NPT in the treatment of documented DSWI we and others have recently evaluated the application of NPT to clean, closed incisions as a method to prevent complications in high-risk wounds [117, 118]. We initially applied this form of “well wound therapy” in a cohort of 57 adult cardiac surgery patients known to be at increased risk for DSWI based on a validated risk stratification model [13]. No cases of superficial or deep sternal wound infections were noted although the group had an estimated 6% risk for DSWI [118]. This form of NPT was noted to be easy to apply, well-tolerated by the patients, and was also judged to be cost-effective when utilized in patients with increased demonstrated risk for DSWI [117]. Since the time of the original report, we have used this novel wound treatment system in over 200 high risk patients and continue to observe reduced rates of sternal wound complications (unpublished data). However, residual problems have been encountered with gross technical errors including off-center sternal incisions, sternal fractures, and costo-sternal separation.

The mechanisms underlying such positive clinical findings are not well understood, but based on well described mechanisms of vacuum-assisted therapy in open incisions, it is hypothesized that applying NPT to the closed incision also favorably affects wound perfusion. Therefore, we assessed peristernal perfusion after median sternotomy and under various degrees of reduced native sternal perfusion as a result of mammary artery harvesting using laser Doppler flowmetry, demonstrating that after median sternotomy and IMA harvesting, peristernal perfusion is significantly reduced and recovers little in the first 4 postoperative days [119]. However, NPT applied to the closed incision increases peristernal perfusion compared with controls regardless of the status of the ipsilateral IMA, providing a rare piece of physiologic evidence for the efficacy of NPT and supports use of NPT as a form of “well wound therapy,” particularly in patients at high-risk for sternotomy complications [119]. These findings are clinically important and relevant, implying that NPT can augment peristernal soft tissue perfusion made relatively ischemic by IMA harvesting. Although this study does not address bony perfusion, *per se*, Fokin et al proposed that substrate diffusion through peristernal tissues may be an important mechanism to maintain perfusion in sternal wounds rendered ischemic by mammary artery harvesting until collateral blood supply to the sternum is well-established [120, 121]. If so, NPT may indeed augment sternal and/or periosteal perfusion via improved peristernal “diffusion” through improved soft tissue perfusion.

## 14. Conclusions

Deep sternal wound infections remain dreaded and deadly complications associated with cardiac surgery. However, incremental improvements have been made recently with regard to lowering rates of observed infections due to a variety of measures. In addition, it appears that management of DSWI with negative pressure therapy alleviates the impact of this condition on short- and long-term survival. Further investigation is needed to determine the potential impact of negative pressure therapy on closed incisions as a novel method to prevent sternal wound complications.

## 15. References

- [1] Durrleman N, Massard G. Sternotomy. Multimedia Manual Cardio Thorac doi:10.1510/mmcts.2006.001875.
- [2] Hollenbeak CS, Murphy DM, Koenig S, Woodward RS, Dunagan WC, Fraser VJ. The clinical and economic impact of deep chest surgical site infections following coronary artery bypass graft surgery. *Chest* 2000; 118: 397-402.
- [3] Taylor GJ, Mikell FL, Moses HW, et al. Determinants of hospital charges for coronary artery bypass surgery: the economic consequences of postoperative complications. *Am J Cardiol* 1990; 65: 309-13.
- [4] Speir AM, Kasirajan V, Barnett SD, Fonner E, Jr. Additive costs of postoperative complications for isolated coronary artery bypass grafting patients in Virginia. *Ann Thorac Surg* 2009; 88: 40-6.
- [5] Loop FD, Lytle BW, Cosgrove DM, et al. Maxwell Chamberlain memorial paper. Sternal wound complications after isolated coronary artery bypass grafting: early and late mortality, morbidity, and cost of care. *Ann Thorac Surg* 1990; 49: 179-87.
- [6] Eklund AM, Lyytikainen O, Klemets P, et al. Mediastinitis after more than 10,000 cardiac surgical procedures. *Ann Thorac Surg* 2006; 82: 1784-9.
- [7] Karra R, McDermott L, Connelly S, Smith P, Sexton DJ, Kaye KS. Risk factors for 1-year mortality after postoperative mediastinitis. *J Thorac Cardiovasc Surg* 2006; 132: 537-43.
- [8] Braxton JH, Marrin CAS, McGrath PD, Ross CS, Morton JR, Norotsky M, Charlesworth DC, Lahey SJ, Clough RA, O'Connor GT. Mediastinitis and long-term survival after coronary artery bypass graft surgery. *Ann Thorac Surg* 2000; 70: 2004-7.
- [9] Milano CA, Kesler K, Archibald N, Sexton DJ, Jones RH. Mediastinitis after coronary artery bypass graft surgery. Risk factors and long-term survival. *Circulation* 1995; 92: 2245-51.
- [10] Olsen MA, Lock-Buckley P, Hopkins D, Polish LB, Sundt TM, Fraser VJ. The risk factors for deep and superficial chest surgical-site infections after coronary artery bypass graft surgery are different. *J Thorac Cardiovasc Surg* 2002; 124: 136-45.
- [11] Baillet R, Cloutier D, Montalin L, et al. Impact of deep sternal wound infection management with vacuum-assisted closure therapy followed by sternal osteosynthesis: a 15-year review of 23,499 sternotomies. *Eur J Cardiothorac Surg* 2010; 37: 880-7.
- [12] Risnes I, Abdelnoor M, Almdahl SM, Svennevig JL. Mediastinitis after coronary artery bypass grafting risk factors and long-term survival. *Ann Thorac Surg* 2010; 89: 1502-10.

- [13] Fowler VG Jr, O'Brien SM, Muhlbaier LH, Corey GR, Ferguson TB, Peterson ED. Clinical predictors of major infections after cardiac surgery. *Circulation* 2005; 112 [Suppl 1]: I-358-65.
- [14] Atkins BZ, Onaitis MO, Hutcheson KA, Kaye K, Petersen RP, Wolfe WG. Does method of sternal repair influence long-term outcome of postoperative mediastinitis? *Am J Surg* 2011. In Press.
- [15] Sjogren J, Malmso M, Gustafsson R, Ingemansson R. Poststernotomy mediastinitis: a review of conventional surgical treatments, vacuum-assisted closure therapy and presentation of the Lund University Hospital mediastinitis algorithm. *Eur J Cardiothorac Surg* 2006; 30: 898-905.
- [16] Domkowski PW, Smith ML, Gonyon DL Jr, et al. Evaluation of vacuum-assisted closure in the treatment of post-sternotomy mediastinitis. *J Thorac Cardiovasc Surg* 2003; 126: 386-90.
- [17] Milton H. Mediastinal surgery. *Lancet* 1897; 1: 872-5.
- [18] Shumacker HB, Jr, Lurie PR. Pulmonary valvulotomy: description of a new approach about diagnostic characteristics of pulmonic valvular stenosis. *J Thorac Surg* 1953; 25: 173-86.
- [19] Julian OC, Lopez-Belio M, Dye WS, Javid H, Grove WJ. The median sternal incision in intracardiac surgery with extracorporeal circulation: a general evaluation of its use in heart surgery. *Surgery* 1957; 42: 753-61.
- [20] Raman J, Straus D, Song DH. Rigid plate fixation of the sternum. *Ann Thorac Surg* 2007; 84: 1056-8.
- [21] McGinn JT Jr, Usman S, Lapierre H, Pothula VR, Mesana TG, Ruel M. Minimally invasive coronary artery bypass grafting: dual-center experience in 450 consecutive patients. *Circulation* 2009; 120: S78-84.
- [22] de Canniere D, Wimmer-Greinecker G, Cichon R, et al. Feasibility, safety, and efficacy of totally endoscopic coronary artery bypass grafting: multicenter European experience. *J Thorac Cardiovasc Surg* 2007; 134: 710-6.
- [23] El Oakley RM, Wright JE. Postoperative mediastinitis: classification and management. *Ann Thorac Surg* 1996; 61: 1030-6.
- [24] Olbrecht VA, Barreiro CJ, Bonde PN, et al. Clinical outcomes of noninfectious sternal dehiscence after median sternotomy. *Ann Thorac Surg* 2006; 82: 902-7.
- [25] Horan TC, Andrus M, Dudeck MA. CDC/NHSN surveillance definition of health care-associated infection and criteria for specific types of infections in the acute care setting. *Am J Infect Control* 2008; 36: 309-32.
- [26] Jones G, Jurkiewicz MJ, Bostwick, et al. Management of the infected median sternotomy wound with muscle flaps. *Ann Surg* 1997; 225: 766-78.
- [27] Schulman NH, Subramanian V. Sternal wound reconstruction: 252 consecutive cases. The Lenox Hill experience. *Plast Reconstr Surg* 2004; 114: 44-8.
- [28] Jakob HJ, Borneff-Lipp M, Bach A, et al. The endogenous pathway is a major route for deep sternal wound infection. *Eur J Cardiothorac Surg* 2000; 17: 154-60.
- [29] Kluytmans JA, Mouton JW, VandenBergh MF, et al. Reduction of surgical-site infections in cardiothoracic surgery by elimination of nasal carriage of *Staphylococcus aureus*. *Infect Control Hosp Epidemiol* 1996; 17: 780-5.

- [30] Furnary AP, Gao G, Grunkemeier GL, et al. Continuous insulin infusion reduces mortality in patients with diabetes undergoing coronary artery bypass grafting. *J Thorac Cardiovasc Surg* 2003; 125: 1007-21.
- [31] Lazar HL, Chipkin SR, Fitzgerald CA, Bao Y, Cabral H, Apstein CS. Tight glycemic control in diabetic coronary artery bypass graft patients improves perioperative outcomes and decreases recurrent ischemic events. *Circulation* 2004; 109: 1497-502.
- [32] Prabhakar G, Haan CK, Peterson ED, Coombs LP, Cruzzavala JL, Murray CF. The risks of moderate and extreme obesity for coronary artery bypass grafting outcomes: a study from the Society of Thoracic Surgeons' database. *Ann Thorac Surg* 2002; 74: 1125-31.
- [33] Eagle KA, Guyton RA, Davidoff R, et al. ACC/AHA 2004 guideline update for coronary artery bypass graft surgery: a report of the American College of Cardiology/American Heart Association Task Force on Practice Guidelines (Committee to Update the 1999 Guidelines for Coronary Artery Bypass Graft Surgery.) American College of Cardiology Web Site. Available at <http://www.acc.org/clinical/guidelines/cabg/cabg.pdf>
- [34] Waisbren E, Rosen H, Bader AM, Lipsitz SR, Rogers SO, Eriksson E. Percent body fat and prediction of surgical site infection. *J Am Coll Surg* 2010; 210: 381-9.
- [35] Filsoufi, F, Castillo JG, Rahmanian PB, et al. Epidemiology of deep sternal wound infection in cardiac surgery. *J Cardiothorac Vasc Anesth* 2009; 23: 488-94.
- [36] Pevni D, Uretzky G, Mohr A, et al. Routine use of bilateral skeletonized internal thoracic artery grafting: long-term results. *Circulation* 2008; 118: 705-12.
- [37] Graeber GM, McClelland WT. Current concepts in the management and reconstruction of the dehiscence median sternotomy. *Semin Thorac Cardiovasc Surg* 2004; 16: 92-107.
- [38] Ariyaratnam P, Bland M, Loubani M. Risk factors and mortality associated with deep sternal wound infections following coronary bypass surgery with or without concomitant procedures in a UK population: a basis for a new risk mode? *Interact Cardiovasc Thorac Surg* 2010; 11: 543-6.
- [39] Paul M, Raz A, Leibovici L, Madar H, Holinger R, Rubinovitch B. Sternal wound infection after coronary artery bypass graft surgery: validation of existing risk scores. *J Thorac Cardiovasc Surg* 2007; 133: 397-403.
- [40] Matros E, Aranki SF, Bayer LR, et al. Reduction in incidence of deep sternal wound infections: random or real? *J Thorac Cardiovasc Surg* 2010; 139: 680-5.
- [41] Ridderstolpe L, Gill H, Granfeldt H, Ahlfeldt H, Rutberg H. Superficial and deep sternal wound complications: incidence, risk factors, and mortality. *Eur J CTS* 2001; 20: 1168-75.
- [42] Baskett RJF, MacDougall CE, Ross DB. Is mediastinitis a preventable complication? A 10-year review. *Ann Thorac Surg* 1999; 67: 462-5.
- [43] Blanchard A, Hurni M, Ruchat P, Stumpe F, Fischer A, Sadeghi H. Incidence of deep and superficial sternal infection after open heart surgery. A ten years retrospective study from 1981 to 1991. *Eur J Cardiothorac Surg* 1995; 9: 153-7.
- [44] Francel TJ. A rational approach to sternal wound complications. *Semin Thorac Cardiovasc Surg* 2004; 16: 81-91.

- [45] Cowan KN, Teague L, Sue SC, Mahoney JL. Vacuum-assisted wound closure of deep sternal infections in high-risk patients after cardiac surgery. *Ann Thorac Surg* 2005; 80: 2205-12.
- [46] Goodman LR, Kay HR, Teplick SK, Mundth ED. Complications of median sternotomy: computed tomographic evaluation. *Am J Roentgenol* 1983; 141: 225-30.
- [47] Yamashiro et al; and Misawa Y, Fuse K, Hasegawa T. Infectious mediastinitis after cardiac operations: computed tomographic findings. *Ann Thorac Surg* 1998; 65: 622-4.
- [48] Yamashiro T, Kamiya H, Murayama S, et al. Infectious mediastinitis after cardiovascular surgery: role of computed tomography. *Radiat Med* 2008; 26: 343-7.
- [49] Hoffman SN, TenBrook JA Jr., Wolf MP, Pauker SG, Salem DN, Wong JB. A meta-analysis of randomized controlled trials comparing coronary artery bypass graft with percutaneous transluminal coronary angioplasty: one-to eight-year outcomes. *J Am Coll Cardiol* 2003; 41: 1293-304.
- [50] Sarr MG, Gott VL, Townsend TR. Mediastinal infection after cardiac surgery. *Ann Thorac Surg* 1984; 38: 415-23.
- [51] Sachithanandan A, Nanjaiah P, Nightingale P, et al. Deep sternal wound infection requiring revision surgery: impact on mid-term survival following cardiac surgery. *Eur J Cardiothorac Surg* 2008; 33: 673-8.
- [52] Cayci C, Russo M, Cheema FH, et al. Risk analysis of deep sternal wound infections and their impact on long-term survival: a propensity analysis. *Ann Plast Surg* 2008; 61: 294-301.
- [53] Morisaki A, Hosono M, Sasaki Y, et al. Evaluation of risk factors for hospital mortality and current treatment for poststernotomy mediastinitis. *Gen Thorac Cardiovasc Surg* 2011; 59: 261-7.
- [54] Braxton JH, Marrin CAS, McGrath, et al. 10-year follow-up of patients with and without mediastinitis. *Semin Thorac Cardiovasc Surg* 2004; 16: 70-6.
- [55] Toumpoulis IK, Anagnostopoulos CE, Deroose JJ Jr, Swistel DG. The impact of deep sternal wound infection on long-term survival after coronary artery bypass grafting. *Chest* 2005; 127: 464-71.
- [56] Stahle E, Tammelin A, Bergstrom R, Hanbreus A, Nystrom SO, Hansson HE. Sternal wound complications-incidence, microbiology, and risk factors. *Eur J Cardiothorac Surg* 1997; 11: 1146-53.
- [57] Chu D, Bakaeen FG, Wang XL, et al. The impact of peripheral vascular disease on long-term survival after coronary artery bypass graft surgery. *Ann Thorac Surg* 2008; 86: 1175-80.
- [58] Tang GHL, Maganti M, Weisel RD, Borger MA. Prevention and management of deep sternal wound infection. *Semin Thorac Cardiovasc Surg* 2004; 16: 62-9.
- [59] Lin CH, Hsu RB, Chang SC, Lin FY, Chu SH. Poststernotomy mediastinitis due to methicillin-resistant *Staphylococcus aureus* endemic in a hospital. *Clin Infect Dis* 2003; 37: 679-84.
- [60] Gardlund B, Bitkover C, Vaage J. Postoperative mediastinitis in cardiac surgery-microbiology and pathogenesis. *Eur J Cardiothorac Surg* 2002; 21: 825-30.
- [61] Mekontso-Dessap A, Kirsch M, Brun-Buisson C, Loisanche D. Poststernotomy mediastinitis due to *Staphylococcus aureus*: comparison of methicillin-resistant and methicillin-susceptible cases. *Clin Infect Dis* 2001; 32: 877-83.

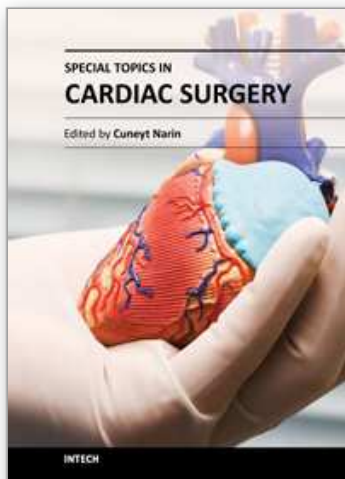
- [62] Tegnell A, Aren C, Ohman L. Coagulase-negative staphylococci and sternal infections after cardiac operation. *Ann Thorac Surg* 2000; 69: 1104-9.
- [63] Mekontso Dessap A, Vivier E, Girou E, Brun-Buisson C, Kirsch M. Effect of time to onset on clinical features and prognosis of post-sternotomy mediastinitis. *Clin Microbiol Infect* 2011; 17: 292-9.
- [64] Graf K, Ott E, Vonberg RP, Kuehn C, Haverich A, Chaberny IF. Economic aspects of deep sternal wound infections. *Eur J Cardiothorac Surg* 2010; 37: 893-6.
- [65] Mokhtari A, Sjogren J, Nilsson J, Gustafsson R, Malmjsjo M, Ingemansson R. The cost of vacuum-assisted closure therapy in treatment of deep sternal wound infection. *Scand Cardiovasc J* 2008; 42: 85-9.
- [66] Center for Medicare and Medicaid Services;  
<http://www.cms.hhs.gov/HospitalAcqCond/>
- [67] O'Reilly KB. Medicare's no-pay events: coping with the complications.  
<http://www.ama-assn.org/amednews/2008/07/14/prsa0714.htm>
- [68] Obdeijn MC, de Lange MY, Lichtendahl DH, et al. Vacuum-assisted closure in the treatment of poststernotomy mediastinitis. *Ann Thorac Surg* 1999; 68: 2358-60.
- [69] Luckraz H, Murphy F, Bryant S, Charman SC, Ritchie AJ. Vacuum-assisted closure as a treatment modality for infections after cardiac surgery. *J Thorac Cardiovasc Surg* 2003; 125: 301-5.
- [70] Malmjsjo M, Ingemansson R, Sjogren J. Mechanisms governing the effects of vacuum-assisted closure in cardiac surgery. *Plast Reconstr Stur* 2007; 120: 1266-75.
- [71] Schimmer C, Sommer SP, Bensch M, Elert O, Leyh R. Management of poststernotomy mediastinitis: experience and results of different therapy modalities. *Thorac Cardiovasc Surg* 2008; 56: 200-4.
- [72] Cabbabe EB, Cabbabe SW. Immediate versus delayed one-stage sternal debridement and pectoralis muscle flap reconstruction of deep sternal wound infections. *Plast Reconstr Surg* 2009; 123: 1490-4.
- [73] Orgill DP, Austen WG Jr, Butler CE, et al. Guidelines for treatment of complex chest wounds with negative pressure wound therapy. *WOUNDS* 2004; Suppl B: 1-23.
- [74] Schumaker HB, Mandelbaum I. Continuous antibiotic irrigation in the treatment of infection. *Arch Surg* 1963; 86: 384-7.
- [75] Lee AB, Schimert G, Shaktin S, et al. Total excision of the sternum and thoracic pedicle transposition of the greater omentum; useful stratagems in managing severe mediastinal infection following open heart surgery. *Surgery* 1976; 80: 433-6.
- [76] Kutsal A, Ibrisim E, Catav Z, et al. Mediastinitis after open heart surgery. Analysis of risk factors and management. *J Cardiovasc Surg (Torino)* 1991; 32: 38-41.
- [77] van Wingerden JJ, Coret ME, van Nieuwenhoven CA, Totte ER. The laparoscopically harvested omental flap for deep sternal wound infection. *Eur J Cardiothorac Surg* 2010; 37: 87-92.
- [78] Jurkiewicz MJ, Bostwick J, hester TR, et al. Infected median sternotomy wound. Successful treatment by muscle flaps. *Ann Surg* 1980; 191: 738-44.
- [79] Nahai F, Rand RP, Hester TR, et al. Primary treatment of the infected sternotomy wound with muscle flaps: a review of 211 consecutive cases. *Plast Reconstr Surg* 1989; 84: 434-41.

- [80] Milano CA, Georgiade G, Muhlbaier LH, Smith PK, Wolfe WG. Comparison of omental and pectoralis flaps for poststernotomy mediastinitis. *Ann Thorac Surg* 1999; 67: 377-81.
- [81] Yuen JC, Zhou AT, Serafin DT, et al. Long-term sequelae following median sternotomy wound infection and flap reconstruction. *Ann Plast Surg* 1995; 35: 585-9.
- [82] Ringelman PR, Vander KC, Cameron D, Bumgartner WA, Manson PN. Long-term results of flap reconstruction in median sternotomy wound infection. *Plast Reconstr Surg* 1994; 93: 1208-14.
- [83] Gottlieb LJ, Piolet RW, Karp RB, Krieger LM, Smith DJ Jr, Deeb GM. Rigid internal fixation of the sternum in postoperative mediastinitis. *Arch Surg* 1994; 129: 489-93.
- [84] Douville EC, Asaph JW, Dworkin RJ, et al. Sternal preservation: a better way to treat most sternal wound complications after cardiac surgery. *Ann Thorac Surg* 2004; 78: 1659-64.
- [85] Chen SZ, Li J, Li XY, et al. Effects of vacuum-assisted closure on wound microcirculation: an experimental study. *Asian J Surg* 2005; 28: 211-7.
- [86] Wackenfors A, Gustafsson R, Sjogren J, et al. Blood flow responses in the peristernal thoracic wall during vacuum-assisted closure therapy. *Ann Thorac Surg* 2005; 79: 1724-30.
- [87] Saxena V, Hwang C-W, Huang S, Eichbaum Q, Ingber D, Orgill DP. Vacuum-assisted closure: microdeformations of wounds and cell proliferation. *Plast Reconstr Surg* 2004; 114: 1086-96.
- [88] Gustafsson RI, Sjogren J, Ingemansson R. Deep sternal wound infection: a sternal-sparing technique with vacuum-assisted closure therapy. *Ann Thorac Surg* 2003; 76: 2048-53.
- [89] Petzina R, Hoffmann J, Navasardyan A, et al. Negative pressure wound therapy for post-sternotomy mediastinitis reduces mortality rate and sternal re-infection rate compared to conventional treatment. *Eur J Cardiothorac Surg* 2010; 38: 110-3.
- [90] Sjogren J, Gustafsson R, Nilsson J, Malmsjo M, Ingemansson R. Clinical outcome after poststernotomy mediastinitis: vacuum-assisted closure versus conventional treatment. *Ann Thorac Surg* 2005; 79: 2049-55.
- [91] Gaudreau G, Costache V, Houde C, et al. Recurrent sternal infection following treatment with negative pressure wound therapy and titanium transverse plate fixation. *Eur J Cardiothorac Surg* 2010; 37: 888-92.
- [92] De Feo M, Della Corte A, Vicchio M, Pirozzi F, Nappi G, Cotrufo M. Is post-sternotomy mediastinitis still devastating after the advent of negative-pressure wound therapy? *Tex Heart Inst J* 2011; 38: 375-80.
- [93] Sjogren J, Nilsson J, Gustafsson R, Malmsjo M, Ingemansson R. The impact of vacuum-assisted closure on long-term survival after post-sternotomy mediastinitis. *Ann Thorac Surg* 2005; 80: 1270-75.
- [94] Immer FF, Durrer Muhlemann KS, Erni D, Gahl B, Carrel TP. Deep sternal wound infection after cardiac surgery: modality of treatment and outcome. *Ann Thorac Surg* 2005; 80: 957-61.
- [95] Gustafsson R, Johnsson P, Algotsson L, Blomquist S, Ingemansson R. Vacuum-assisted closure therapy guided by C-reactive protein level in patients with deep sternal wound infection. *J Thorac Cardiovasc Surg* 2002; 123: 895-900.

- [96] Voss B, Bauernschmitt R, Will A, et al. Sternal reconstruction with titanium plates in complicated sternal dehiscence. *Eur J Cardiothorac Surg* 2008; 34: 139-45.
- [97] Ramnarine IR, McLean A, Pollock JC. Vacuum-assisted closure in the paediatric patient with post-cardiotomy mediastinitis. *Eur J Cardiothorac Surg* 2002; 22: 1029-31.
- [98] Kaye AE, Kaye AJ, Pahk B, McKenna ML, Low DW. Sternal wound reconstruction: management in different cardiac populations. *Ann Plast Surg* 2010; 64: 658-66.
- [99] Bapat V, El-Muttardi N, Yound C, Venn G, Roxburgh J. Experience with vacuum-assisted closure of sternal wound infections following cardiac surgery and evaluation of chronic complications associated with its use. *J Card Surg* 2008; 23: 227-33.
- [100] Petzina R, Malmsjo M, Stamm C, Hetzer R. Major complications during negative pressure wound therapy in poststernotomy mediastinitis after cardiac surgery. *J Thorac Cardiovasc Surg* 2010; 140: 1133-6.
- [101] Malmsjo M, Lindstedt S, Ingemansson R. Effects on heart pumping function when using foam and gauze for negative pressure wound therapy of sternotomy wounds. *J Cardiothorac Surg* 2011; 6: 5.
- [102] Torbrand C, Ugander M, Engblom H, et al. Changes in cardiac pumping efficiency and intra-thoracic organ volume during negative pressure wound therapy of sternotomy wounds, assessment using magnetic resonance imaging. *Int Wound J* 2010; 7: 305-11.
- [103] Kramer R, Groom R, Weldner D, et al. Glycemic control and reduction of deep sternal wound infection rates. *Arch Surg* 2008; 143: 451-6.
- [104] Bratzler DW, Houck PM for the Surgical Infection Prevention Guidelines Writers Workgroup. Antimicrobial prophylaxis for surgery: an advisory statement from the National Surgical Infection Prevention Project. *Clin Infect Dis* 2004; 38: 1706-15.
- [105] Perl TM, Golub JE. New approaches to reduce *Staphylococcus aureus* nosocomial infection rate: treating aureus nasal carriage. *Ann Pharmacother* 1998; 32: S7-16.
- [106] Cimochoowski G, Harostock M, Brown R, et al. Intranasal mupirocin reduces sternal wound infection after open heart surgery in diabetics and nondiabetics. *Ann Thorac Surg* 2001; 71: 1572-9.
- [107] Carrier M, Marchand R, Auger P, et al. Methicillin-resistant *Staphylococcus aureus* infection in a cardiac surgical unit. *J Thorac Cardiovasc Surg* 2002; 123: 40-4.
- [108] Schimmer C, Reents W, Berneder S, et al. Prevention of sternal dehiscence and infection in high-risk patients: a prospective randomized multicenter trial. *Ann Thorac Surg* 2008; 86: 1897-904.
- [109] Song DH, Lohman RF, Renucci JD, Jeevanandam V, Raman J. Primary sternal plating in high-risk patients prevents mediastinitis. *Eur J Cardiothorac Surg* 2004; 26: 367-72.
- [110] Lee JC, Raman J, Song DH. Primary sternal closure with titanium plate fixation: plastic surgery effecting a paradigm shift. *Plast Reconstr Surg* 2010; 125: 1720-4.
- [111] Levin LS, Miller AS, Gajjar AH, et al. An innovative approach for sternal closure. *Ann Thorac Surg* 2010; 89: 1995-9.
- [112] Ozaki W, Buchman SR, Iannettoni MD, Frankenburg EP. Biomechanical study of sternal closure using rigid fixation techniques in human cadavers. *Ann Thorac Surg* 1998; 65: 1660-5.

- [113] Kamiya H, Akhyari P, Martens A, Karck M, Haverich A, Lichtenberg A. Sternal microcirculation after skeletonized versus pedicled harvesting of the internal thoracic artery: a randomized study. *J Thorac Cardiovasc Surg* 2008; 135: 32-7.
- [114] Friberg O, Svedjeholm R, Soderquist B, Granfeldt H, Vikersfors T, Kallman J. Local gentamicin reduces sternal wound infections after cardiac surgery: a randomized controlled trial. *Ann Thorac Surg* 2005; 79: 153-62.
- [115] Vander Salm T, Okike O, Pasque M, et al. Reduction of sternal infection by application of topical vancomycin. *J Thorac Cardiovasc Surg* 1989; 98: 618-22.
- [116] Bennett-Guerrero E, Ferguson TB Jr, Lin M, et al. Effect of an implantable gentamicin-collagen sponge on sternal wound infections following cardiac surgery. *JAMA* 2010; 304: 755-62.
- [117] Stannard JP, Atkins BZ, O'Malley D, et al. Use of negative pressure therapy on closed surgical incisions: a case series. *Ostomy Wound Manage* 2009; 55: 58-66.
- [118] Atkins BZ, Wooten MK, Kistler J, Hurley K, Hughes GC, Wolfe WG. Does negative pressure wound therapy have a role in preventing poststernotomy wound complications? *Surg Innov* 2009; 16: 140-6.
- [119] Atkins BZ, Tetterton JK, Petersen RP, Hurley K, Wolfe WG. Laser Doppler flowmetry assessment of peristernal perfusion after cardiac surgery: beneficial effect of negative pressure therapy. *Int Wound J* 2011; 8: 56-62.
- [120] Fokin AA, Robicsek F, Masters TN, Fokin A Jr, Reames MK, Anderson JE, Jr. Sternal nourishment in various conditions of vascularization. *Ann Thorac Surg* 2005; 79: 1352-7.
- [121] Medalion B, Katz MG, Lorberboym M, Bder O, Schachner A, Cohen AJ. Decreased sternal vascularity after internal thoracic artery harvesting resolves with time: an assessment with single photon emission computed tomography. *J Thorac Cardiovasc Surg* 2002; 123: 508-11.

IntechOpen



## **Special Topics in Cardiac Surgery**

Edited by Prof. Cuneyt Narin

ISBN 978-953-51-0148-2

Hard cover, 308 pages

**Publisher** InTech

**Published online** 29, February, 2012

**Published in print edition** February, 2012

This book considers mainly the current perioperative care, as well as progresses in new cardiac surgery technologies. Perioperative strategies and new technologies in the field of cardiac surgery will continue to contribute to improvements in postoperative outcomes and enable the cardiac surgical society to optimize surgical procedures. This book should prove to be a useful reference for trainees, senior surgeons and nurses in cardiac surgery, as well as anesthesiologists, perfusionists, and all the related health care workers who are involved in taking care of patients with heart disease which require surgical therapy. I hope these internationally cumulative and diligent efforts will provide patients undergoing cardiac surgery with meticulous perioperative care methods.

### **How to reference**

In order to correctly reference this scholarly work, feel free to copy and paste the following:

Zane B. Atkins and Walter G. Wolfe (2012). Sternal Wound Complications Following Cardiac Surgery, Special Topics in Cardiac Surgery, Prof. Cuneyt Narin (Ed.), ISBN: 978-953-51-0148-2, InTech, Available from: <http://www.intechopen.com/books/special-topics-in-cardiac-surgery/sternal-wound-complications-following-cardiac-surgery>

**INTECH**  
open science | open minds

### **InTech Europe**

University Campus STeP Ri  
Slavka Krautzeka 83/A  
51000 Rijeka, Croatia  
Phone: +385 (51) 770 447  
Fax: +385 (51) 686 166  
[www.intechopen.com](http://www.intechopen.com)

### **InTech China**

Unit 405, Office Block, Hotel Equatorial Shanghai  
No.65, Yan An Road (West), Shanghai, 200040, China  
中国上海市延安西路65号上海国际贵都大饭店办公楼405单元  
Phone: +86-21-62489820  
Fax: +86-21-62489821

© 2012 The Author(s). Licensee IntechOpen. This is an open access article distributed under the terms of the [Creative Commons Attribution 3.0 License](https://creativecommons.org/licenses/by/3.0/), which permits unrestricted use, distribution, and reproduction in any medium, provided the original work is properly cited.

IntechOpen

IntechOpen