

# We are IntechOpen, the world's leading publisher of Open Access books Built by scientists, for scientists

6,900

Open access books available

186,000

International authors and editors

200M

Downloads

Our authors are among the

154

Countries delivered to

TOP 1%

most cited scientists

12.2%

Contributors from top 500 universities



WEB OF SCIENCE™

Selection of our books indexed in the Book Citation Index  
in Web of Science™ Core Collection (BKCI)

Interested in publishing with us?  
Contact [book.department@intechopen.com](mailto:book.department@intechopen.com)

Numbers displayed above are based on latest data collected.  
For more information visit [www.intechopen.com](http://www.intechopen.com)



# Chronic Obstructive Pulmonary Disease: Emphysema Revisited

Nhue L. Do and Beek Y. Chin\*  
*Beth Israel Deaconess Medical Center  
Harvard School of Medicine  
Center for Life Sciences  
Boston, MA  
USA*

## 1. Introduction

The chronic obstructive pulmonary disease (COPD) encompasses two phenotypically related diseases, chronic bronchitis and emphysema [1-2]. Although the hallmark of COPD is inflammation and inability to maintain efficient gas exchange, emphysema is often characterized by atypical over-distension of the alveoli and permanent destruction of the surrounding supporting structures leading to irreversible damage to gaseous exchange. Statistically, it is rapidly approaching a leading cause of mortality in the United States [3], with a morbidity of 4.9 million [4] and mortality rate at 4.2 per 100,000 [5]. Even with a higher prevalence of COPD related incidences in chronic bronchitis, mortality from emphysema (12,790) had exceeded that of chronic bronchitis (667) in pulmonary-related deaths [5] making early diagnosis and treatment of emphysema an alarming and continued cause for concern.

## 2. Pathogenesis of emphysema

The pathogenesis of emphysema is embodied by enlargement of alveolar space, progressive destruction of connective tissue and loss of elasticity leading to eventual collapse of the small airways and destruction of pulmonary-alveolar units, all of which combine to limit gas exchange and airflow out of the lungs. These physical manifestations are usually initiated by chronic inflammation and induction of persistent oxidative stress mediated primarily by the neutrophil, a key innate immune cell residing in the conducting airways [6]. The persistent thought for the past four decades was that the tenuous balance between proteases and anti-proteases determined the severity of airway damage and alveolar enlargement, with the main protease-inhibitor, alpha1 anti-trypsin (AAT1) [6] severely lacking to combat the secretagogue elastase, from the chronically activated resident neutrophils [7-8]. Activated neutrophils also promote the secretion of mucus and inhibit the clearance ability of mucocilliary cilia thus adding to the severity of disease.

---

\* Corresponding Author

The role of another innate cell, the alveolar macrophage which resides in the alveolar region [9-10] has been demonstrated to be markedly influenced by the pro-inflammatory milieu and also promote the secretion of elastase [11] primarily matrix-metalloproteases (MMP), and key cytokines/chemokines responsible for sustaining inflammation and inhibition of the healing or resolution process [11]. Of all the MMP implicated, MMP-9 was demonstrated to be markedly elevated in patients with emphysema [12-13]. Even though MMP-9 is capable of breaking down extra cellular matrices and cause destruction of the septal and alveolar walls, recent evidence has questioned its role [14-15] suggesting that some of the MMP may not be directly associated with the progression of disease as inhibiting the expression does not affect the severity in smoke-induced emphysema in rodents.

A majority of recent documented emphysema cases is primarily attributed to inhalation of damaging stimuli such as cigarette smoke (CS) [16]. The emergent contribution of oxidants is integral to the development of emphysema. CS either in the form of chronic smoking or in the laboratory to induce experimental-emphysema in rodents, consists of both reactive oxygen and reactive nitrogen species, both of which are robust inducers of inflammation [17]. Additionally, other components of CS such as particulate matter, in itself a potent activator of macrophages [18-19], is able to induce the generation of macrophage-derived oxidants, thus adding to the persistence of a pro-inflammatory milieu. These CS- and macrophage-derived oxidants can contribute to the inactivation of AAT1, promote the activation of MMP and impair the pulmonary-alveolar units (PAU) *in situ*, therefore exaggerating the already compromised situation [20]. Another index of emphysema which has recently emerged is the increased pulmonary capillary endothelial cell turnover as a direct result of the destruction of the PAU [21], resulting in the elaboration of endothelial microparticle (EMP). Using stringent criteria to determine the source of PAU, the authors confirmed that emphysematous patients have increased circulating plasma levels of pulmonary capillary endothelium-derived EMP as a result of increased endothelial turnover. They also added that the detection of EMP in the plasma superseded any spirometry evidence of emphysema, thus adding an early novel albeit invasive biomarker of emphysema.

There are three major causative factors for the development of emphysema; environmental, social and genetic predisposition. Coal miners and those working with silica often inhale airborne toxicants that contribute to initial oxidative stress [22]. It is the inability to remove these toxicants that lead to progressive inflammation and destruction of respiratory tissue. In addition to the anti-protease role of AAT1, recent evidence documenting the role of AAT1 as an anti-inflammatory protein [reviewed in 23] only highlights the importance of those who inherited this deficiency. The influence of smoking or 'inhalation of toxicants by choice' remains a controversial and somewhat contentious causative factor of emphysema. However, the combination of AAT1 deficiency and chronic smoking or coal miners who are heavy smokers almost always result in the progressive development of emphysema.

### 3. Presentation of COPD: Emphysema

Chronic obstructive pulmonary disease (COPD) has significant impact on not only patients inflicted with the disease but also on the healthcare system under which they are taken care of.

Patients with severe COPD have significant physical impairment with reduction in quality of life and can result in death. The healthcare system requires that patients have multiple office visits and frequent hospitalizations on top of chronic lifelong therapy that includes medications and long-term oxygen treatments. Early diagnosis of COPD can help early management of symptoms and make lifestyle changes such as the cessation of smoking, as ultimately these practices are the only options to slowing the progression of disease. However, this disease is still underdiagnosed with only 15% of smokers diagnosed with COPD [24].

Patients with emphysema can have varying degrees of symptoms ranging from few to chronic respiratory complaints with acute exacerbations. Some symptoms include dyspnea, cough, wheezing, and acute chest illnesses. Any patient with a chronic cough, dyspnea or a history of any exposure to risk factors such as CS, occupational dusts, chemicals and smoke from home or heating fuels should have the diagnosis of emphysema suspected for their symptoms [25]. Some patients may unknowingly restrict their own activities since emphysema is slowly progressive and persistent. Physical examination findings are usually only present in patients with severe disease which includes, over distention of the lungs in the stable state with the chest held near full inspiratory position at the end of normal expiration, and a low diaphragmatic position resulting in retraction of the lower intercostal spaces (Hoover's sign) [26]. Additionally, there is decreased intensity of breath and heart sounds accompanied by a prolonged expiratory phase [27]. Wheezes on auscultation on slow or forced breathing with a prolongation of forced expiratory time may be evidence of airflow obstruction. Some of the frequently classically described characteristics include purse-lip breathing, accessory respiratory muscle usage of the neck and shoulder girdle muscles. Other findings may be unusual positions to relieve dyspnea such as leaning forward with arms outstretched (tripod position) [28], digital clubbing, dependent edema in the absence of right heart failure, neck vein distention and an enlarged liver due to right heart failure.

Patients with suspected emphysema may present at various stages of the disease process. Chest radiography is usual the initial study performed or ordered but will not be diagnostic except in severe cases, however, is still important to exclude other lung diseases. Signs of hyperinflation on the chest radiograph include; rapidly tapering vascular shadows with increased radiolucency of the lung, a flat diaphragm and a long narrow heart shadow on posterior-anterior films and flat diaphragmatic contour and increased retrosternal airspace on a lateral radiograph (*Figure 1a-b*). Bullae may also be identified on a chest radiograph. Computed tomography (CT) is better able to characterize the involvement pattern as either centriacinar or panacinar. Centriacinar usually involves the upper lobes in the center of secondary pulmonary lobules, in contrast to panacinar with involves the lung bases and the entire secondary pulmonary nodule with generalized paucity of the vascular structures. CT has become the mainstay in evaluating patients for lung volume reduction surgery [29-30].

Pulmonary function tests (PFTs) have become the cornerstone of the diagnostic evaluation of patients because these patients may be symptomatic but have no physical exam findings [31]. PFTs can determine the severity of the airflow obstruction and can also be used to follow the disease progression, with spirometry being the essential confirmatory test that not only stages COPD but also distinguishes the phenotype of COPD [32]. The forced expiratory volume in one second (FEV1) and forced vital capacity (FVC) is needed to

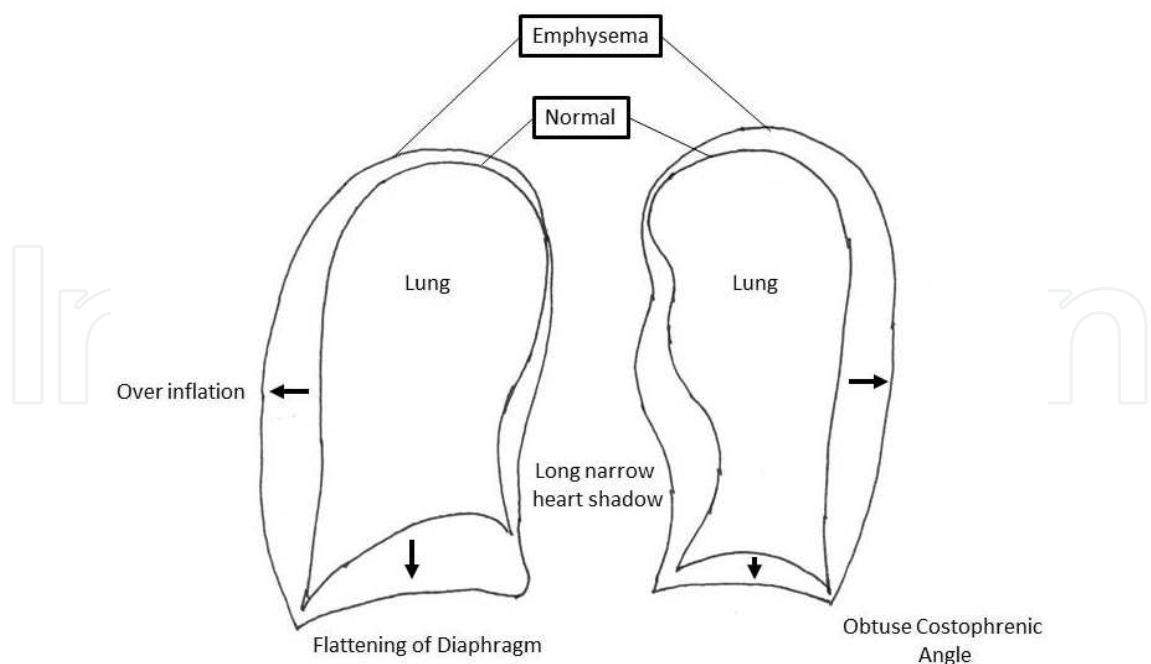


Fig. 1a. Schematic of typical anteroposterior

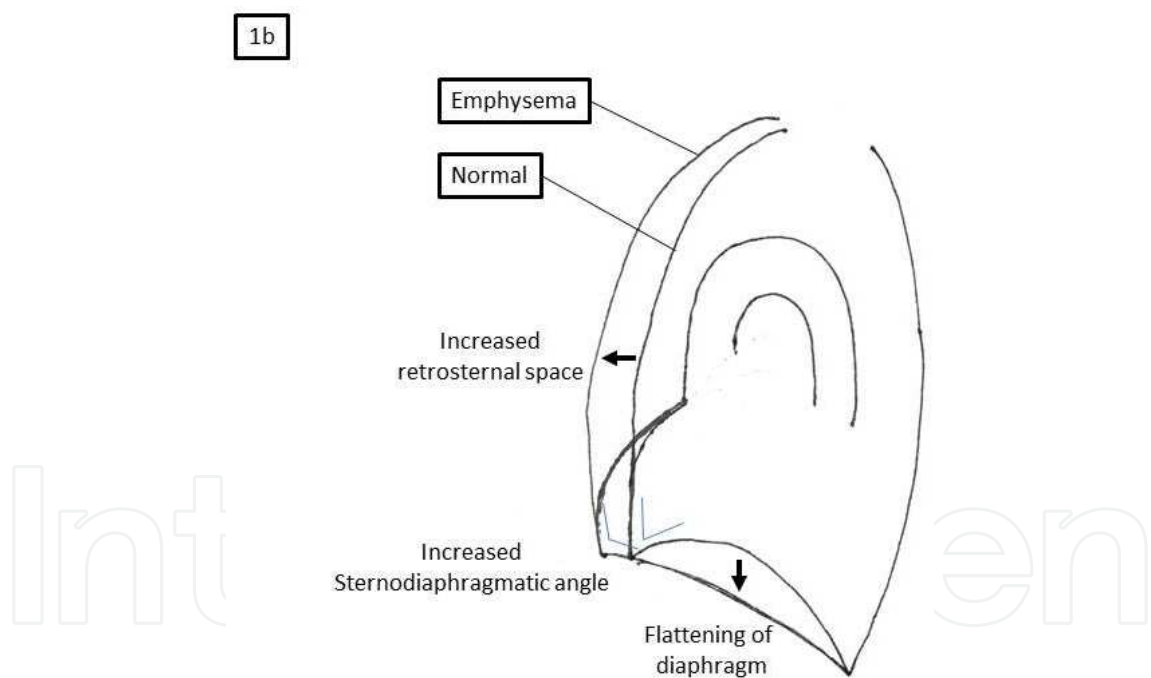


Fig. 1b. Lateral chest radiograph findings of emphysema.

establish the presence of obstruction, with a ratio of less than 0.70 being significant for obstruction [33]. The inspiratory capacity is usually decreased with tachypnea due to dynamic hyperinflation and increased total lung capacity, functional residual capacity and residual volume. The measurement of carbon monoxide diffusing capacity can help to establish the presence of emphysema but is not used in the routine diagnosis of COPD. Arterial blood gases (ABG) is used to correlate symptoms with blood oxygenation levels but is not needed in mild to moderate airflow obstruction. ABG is optional in moderately severe

airflow obstruction however, for severe disease, ABG then becomes the major monitoring tool once hypoxemia with hypercapnia develops.

## 4. Treatment of emphysema

The treatment of pulmonary emphysema has not only puzzled surgeons but has also attracted their interest throughout history. Many operations have been proposed however, it was not until further understanding of the physiological impairment of the disease was understood that appropriate surgical treatment evolved. Surgical treatment for patients on maximal medical therapy but remain symptomatic carries both morbidity and mortality; however, the operations also carry with them the hope of relief from dyspnea. Three typical operations performed for emphysema are bullectomy, volume reduction, and lung transplantation.

### 4.1 Bullectomy

Bullae are defined as emphysematous spaces larger than 1 cm in diameter in the inflated lung, usually demarcated from surrounding lung tissue and pathologically consists of enlarged airspaces covered by visceral pleural. Bullae have been characterized into three different types with Type I and II associated with diffuse emphysema, with type III representing complete loss of parenchymal architecture throughout lung fields [34]. Bullae in emphysematous disease is believed to arise *via* a ball-valve mechanism where air is allowed to enter the airspace but not allowed to escape with progressive enlargement of the airspace over time [35-36]. The enlarged space-occupying lesion leads to compression of the surrounding emphysematous lung tissue with preferential filling of the bullae, when exposed to the same negative intrapleural pressure results in continued enlargement [37-39]. The indication for a bullectomy is to permit expansion of the previously collapsed surrounding lung tissue to regain function as well as restore physiologic respiratory function [40]. Compression of surrounding lung tissue by bullae impairs overall gas exchange due to low ventilation to perfusion ratios in the compressed lung region. Furthermore, bullae can result in increased intra-thoracic pressures eventually resulting in hemodynamic dysfunction from compression of the pulmonary arterial system, decrease in systemic venous return, and increased expiratory airway resistance [40]. Large bullae may also restrict the function of the diaphragm and the thoracic chest wall muscles. Bullectomy would remove the space-occupying lesion, reduce expiratory airway resistance, and reduce dead-space ventilation that may result in overall improvement in respiratory function.

The benefit of a bullectomy must be determined based on careful selection of individuals based on the size of the bullae, the degree of compression and whether underlying condition of compressed lung parenchyma exists [42-45]. The highest predictor for benefit from a bullectomy is that young individuals with large localized unilateral bullae that are nonventilated, nonperfused, with significant compression of surrounding lung tissue that has good perfusion and early emphysema [43]. Although posteroanterior and lateral radiographs can identify bullae, CT has become the mainstay imaging technique in delineating the anatomy of bullae [46]. The operative approach for bullectomy is variable and is dependent on the anatomic details of the bullae and specific techniques deployed by the surgeon in question. Single large bullae with a small pedicle may be excised using either a muscle-sparing thoracotomy or a video-assisted thorascopic surgery (VATS), and resected

with a stapler (Figure 2). In some instances, large bullae may have completely destroyed an entire lobe requiring lobectomy.

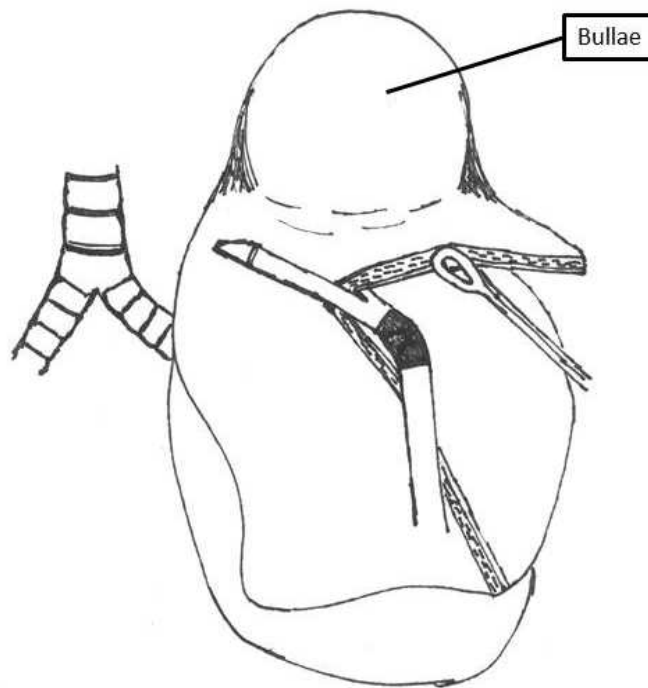


Fig. 2. VATS stapled bullectomy.

Mortality rates of bullectomy should range from 1 to 5%. The mortality rate of approximately 2.3% in well-selected patients was established more than 30 years ago by Fitzgerald *et al* with similar results in modern studies [42, 47]. Similar rates have been seen in patients undergoing VATS compared to thoracotomy approaches. Delayed expansion of the remaining lung tissue, parenchymal air leaks and pulmonary infections are some known post-operative complications, with air leaks being the most frequently occurring. Persistent air-leaks can be managed with the use of a Heimlich valve [48]. Results from bullectomies are difficult to analyze given that there are no prospective randomized clinical trials comparing medical therapy with surgery, as all previous studies were retrospective case series. The most recent series by Schipper *et al* looking at intermediate- to long-term results showed improvement in functional status up to 3 years after resection of giant bullae [47].

#### 4.2 Lung volume reduction (LVR)

Lung volume reduction (LVR) is similar to bullectomy, the difference being that LVR is an extension performed for diseases that affect the entire lung. LVR was pioneered by Otto Brantigan in the 1950s but was not adopted due to a high mortality rate of 18% [49]. Brantigan's initial hypothesis was that the diseased portions of the lung resulted in loss of elasticity and that removing the most diseased portions permitted and maintained patency of the remaining bronchioles to improve airflow [49]. It was not until several decades later that Delarue *et al* [50] and Dahan [51] *et al* re-introduced the concept in patients with end-stage emphysema. However, the role of LVR would not become popular until 1994 when Cooper [52] adapted Brantigan's initial concept. The underlying pathology of end-stage emphysema is characterized by distended airspaces that are inadequately ventilated but

with continued perfusion (ventilation-perfusion mismatch) nevertheless, resection of the diseased portions would result in improved ventilation to other functional regions. LVR also serves to re-establish normal chest wall dynamics and may result in improvement in hemodynamic function from the lowering of intra-thoracic pressure throughout the respiratory cycle.

Selection of candidates for LVR is dependent on the anatomic characteristics of the diseased portion of the lung with ideal candidates having heterogeneous upper-lobe involvement [53]. There is less dramatic improvement in candidates undergoing LVR with lower lobe involvement [54]. Patients being considered for LVR usually undergo scintigrams to identify potential targets for resection. The most important factor for success of LVR has been the meticulous selection of patients based on the National Emphysema Treatment Trial or NETT criteria [55]. Again CT has become the mainstay for characterization of possible resection margins. The mortality rate ranges from 0 to 7.5% with varying surgical approaches [52, 56-58]. Multiple approaches have been used including median sternotomy, bilateral thoracotomies or VATS (*Figure 3*). All have similar results with functional improvement disappearing over a period of 3 to 5 years, but LVR patients continue to have a clinical advantage over medical treatment for those 3-5 years with substantial gains in exercise tolerance, freedom with oxygen therapy, and overall improvement in quality of life. The most significant trial, NETT, reported the results which included 1218 patients randomized between LVRS and medical therapy between January 1998 and July 2002 [59]. This trial reported a 90-day surgical mortality of 7.9% without a significant difference in surgical approach. Patients with upper-lobe predominant emphysema had a greater survival benefit from surgery while those with lower-lobe predominant emphysema demonstrated survival benefits from medical therapy. Based on these promising results, LVR can be performed for patients who are not candidates for lung transplant.

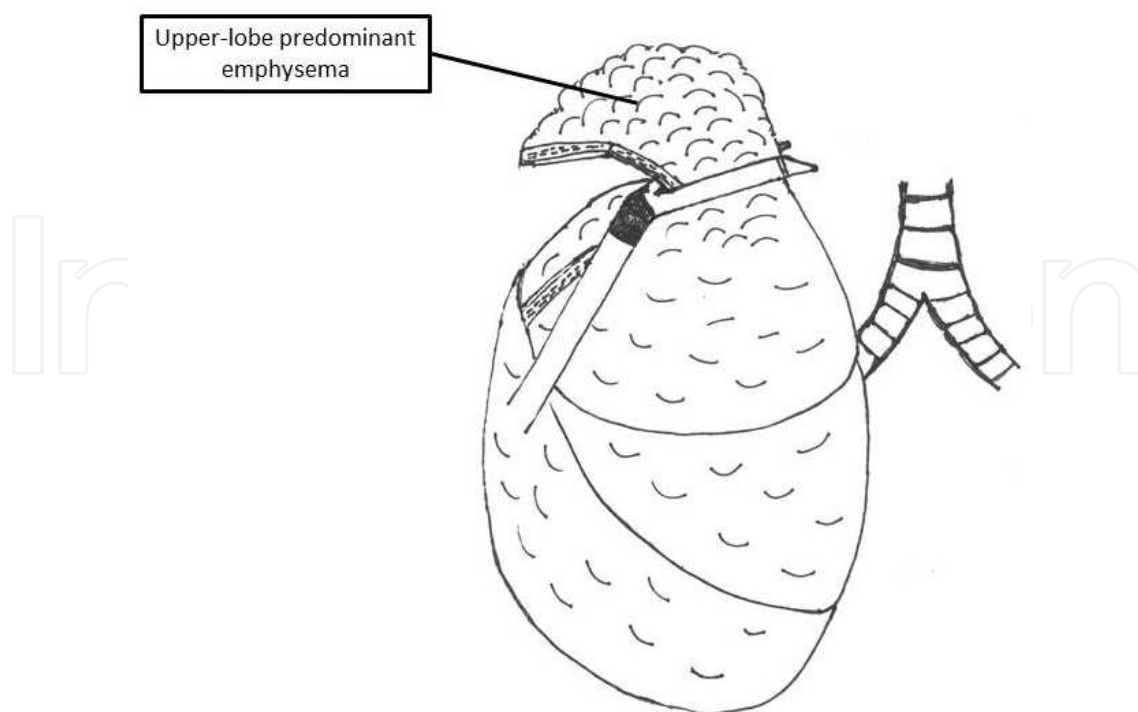


Fig. 3. VATS lung volume reduction surgery for upper-lobe predominant emphysema.

A new technique of lung volume reduction with less morbidity and mortality compared to surgical LVR is bronchoscopic lung volume reduction (LVR). Bronchoscopic LVR aims to achieve the same goals as LVRS: improve physiologic mechanics of the chest wall and diaphragm, restore ventilation-perfusion matching, and improve expiratory airflow. The method by which this is achieved is through the use of a bronchoscope to deploy one-way valves, administer sealants, or apply thermal ablation to exclude diseased portions of the lung [60-62]. It is important to note that these techniques have not been approved by the Food and Drug Administration (FDA) for the treatment of severe emphysema and are currently utilized on experimental basis only. The most developed and well-studied of the bronchoscopic techniques is the one-way valve. One-way valves allow air and mucus to escape from the excluded portion of lung yet concomitantly excluding that portion of the lung from normal physiological function. [61] Multiple valve designs have been tested, the largest on which was the Endobronchial Valve for Emphysema Palliation Trial (*Figure 4*) (VENT) [63-64] There was significant improvement in dyspnea, exercise capacity, and quality of life but not as significant as that which is seen in LVRS. [64]. Possible explanations for the minor improvement seen compare to LVRS have been attributed to collateral ventilation through incomplete lobar fissures. There were more complications of pneumonia, hemoptysis, and pneumothorax in the treatment group, all of which would be expected from an invasive procedure. [64]. The administration of sealants is far less developed and studied when compared to that of one-way valves, and includes the use of fibrin-thrombin mixtures to create a scaffold for collagen deposition by fibroblasts [65]. Preliminary studies show minor improvements in pulmonary function tests but no significant clinical benefits [66-67].

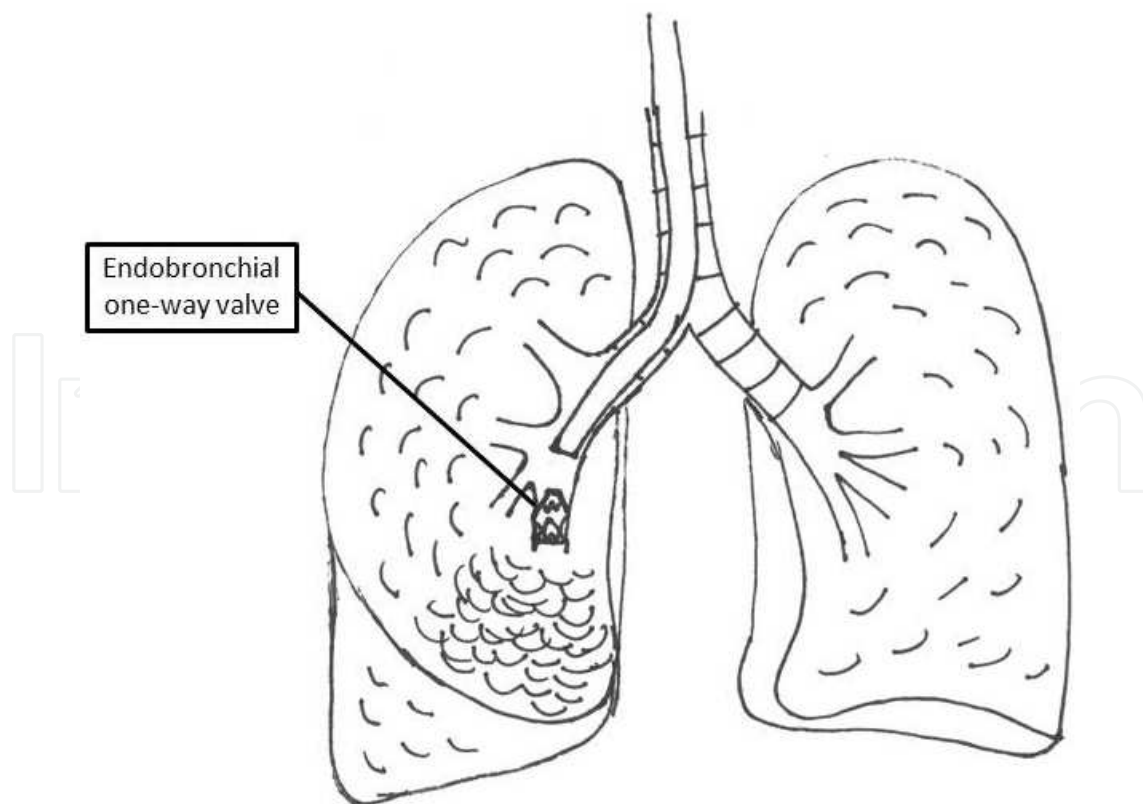


Fig. 4. Endobronchial lung volume reduction with one-valve for lower-lobe predominant emphysema.

Thermal ablation is the least developed and studied of the bronchoscopic LVR techniques. The use of heated vapor to induce an inflammatory response resulting in occlusion of a diseased portion of lung has only been tested in feasibility studies with further exploratory efforts required due to small sample sizes [68]. Although bronchoscopic LVR is an emerging technique, further analyses as well as long-term follow-up studies are needed.

### 4.3 Lung transplantation

Lung transplantation was originally thought to not be a feasible treatment for emphysema. It wasn't until after the seminal transplantation of single lungs demonstrating significant improvement in symptoms, that lung transplantation became a mainstay for the end-stage emphysema [69-71]. Currently, the most common indication for lung transplantation is idiopathic diffuse emphysema and AAT1 deficiency, two criteria that account for the majority of lung transplants [70]. Lung transplant patients are usually so critically ill that the risk of death from their lung disease enables the actual lung transplant operation to appear quite equitable. The advantages of a lung transplant result in complete replacement of the diseased lung with significant improvements in symptoms [72]. There are however, significant disadvantages to lung transplantation including higher mortality (5 to 15%), lifelong immunosuppression resulting in risks of serious infection and rejection with a cumulative survival rate of around 50% [73-74].

## 5. Summary

Emphysema can be a preventable and equally treatable pulmonary disease. With the advent of new diagnostic criteria such as the emergence of a key biomarker, circulating levels of EMP may lead to efficient diagnosis and preventative care. Patients with emphysema can present a varying array of symptoms and physical examination findings. While the majority of patients can be managed with medical therapy, those who continue to progress may require surgical intervention based on their diagnostic studies. The ideal surgical treatment of emphysema is dictated by a rigorous selection criteria for each of the possible interventions described and can dramatically improve the quality of life of individuals inflicted with this disease. New and innovative methods for treating crippling emphysemic patients who are not candidates for surgical treatments include bronchoscopic placement of one-way valves into diseased segments of lung tissue or airway bypass by means of inserting stents between bronchi and adjacent lung tissue [75-78], however, these emergent techniques necessitate further exploratory and long term studies.

## 6. References

- [1] Celli BR, MacNee W. Standards for the diagnosis and treatment of patients with COPD: a summary of the ATS/ERS position paper. *Eur Respir J* 2004;23:932-94.
- [2] World Health Organization. The GOLD global strategy for the management and prevention of COPD: Executive summary 2006 at <http://www.goldcopd.org>.
- [3] [http://www.cdc.gov/nchs/data/nvsr/nvsr58/nvsr58\\_19.pdf](http://www.cdc.gov/nchs/data/nvsr/nvsr58/nvsr58_19.pdf)
- [4] [http://www.cdc.gov/nchs/data/series/sr\\_10/sr10\\_249.pdf](http://www.cdc.gov/nchs/data/series/sr_10/sr10_249.pdf)
- [5] [http://www.cdc.gov/nchs/data/nvsr/nvsr58/nvsr58\\_19.pdf](http://www.cdc.gov/nchs/data/nvsr/nvsr58/nvsr58_19.pdf)

- [6] Laurell CB, Eriksson S: The electrophoretic  $\alpha$ -globulin pattern of serum in  $\alpha$ -antitrypsin deficiency. *Scand J Clin Invest* 1963, 15:132-140.
- [7] Senior RM, Griffin GL, Mecham RP: Chemotactic activity of elastin-derived peptides. *J Clin Invest* 1980, 66:859-862.
- [8] Janoff A, Sloan B, Weinbaum G, Damiano V, Sandhaus RA, Elias J, Kimbel P: Experimental emphysema induced with purified human neutrophil elastase: tissue localization of the instilled protease. *Am Rev Respir Dis* 1977, 115:461-478.
- [9] Tetley T. Matrix metalloproteinases: a role in emphysema? *Thorax* 52: 495–497, 1997.
- [10] Hautamaki RD, Kobayashi DK, Senior RM, Shapiro SD. Requirement for macrophage elastase for cigarette smoke-induced emphysema in mice. *Science*. 1997, 277(5334):2002-4.
- [11] Shapiro SD and Senior RM. Matrix metalloproteinases: matrix degradation and more. *Am J Respir Cell Mol Biol* 20: 1100–1102, 1999.
- [12] Finlay GA, O'Driscoll LR, Russell KJ, D'Arcy EM, Masterson JB, FitzGerald MX, O'Connor CM. Matrix metalloproteinase expression and production by alveolar macrophages in emphysema. *Am J Respir Crit Care Med*. 1997, 156(1):240-7.
- [13] Lim S, Roche N, Oliver BG, Mattos W, Barnes PJ, and Chung KF. Balance of matrix metalloproteinase-9 and tissue inhibitor of metalloproteinase-1 from alveolar macrophages in cigarette smokers. *Am J Respir Crit Care Med* 162: 1355–1360, 2000.
- [14] Atkinson JJ, Lutey BA, Suzuki Y, Toennies HM, Kelley DG, Kobayashi DK, Ijem WG, Deslee G, Moore CH, Jacobs ME, Conradi SH, Gierada DS, Pierce RA, Betsuyaku T, Senior RM. The role of matrix metalloproteinase-9 in cigarette smoke-induced emphysema. *Am J Respir Crit Care Med*. 2011, 183(7):876-84.
- [15] Macnee Voekel, Norbert F. Voelkel, William MacNee. *Chronic Obstructive Lung Disease*. Eds. Macnee Voekel, William MacNee. PMPH-USA, 2008, 69-71.
- [16] Global Initiative for Chronic Obstructive Pulmonary Disease. Caverley P, Augusti A, Anzueto, et al, eds. *Global Strategy for the Diagnosis, Management, and Prevention of Chronic Obstructive Pulmonary Disease*. Medical Communications Resources; 2008.
- [17] MacNee W. Pathogenesis of chronic obstructive pulmonary disease. *Proc Am Thorac Soc*. 2005, 2:258–66.
- [18] Mehta H, Nazzal K, Sadikot RT. Cigarette smoking and innate immunity. *Inflamm Res*. 2008, 57(11):497-503.
- [19] Domagala-Kulawik J. Effects of cigarette smoke on the lung and systemic immunity. *J Physiol Pharmacol*. 2008, 59 Suppl 6:19-34.
- [20] Owen CA. Proteinases and oxidants as targets in the treatment of chronic obstructive pulmonary disease. 2005, *Proc Am Thorac Soc* 2:373–85.
- [21] Gordon C, Gudi K, Krause A, Sackrowitz R, Harvey BG, Strulovici-Barel Y, Mezey JG, Crystal RG. Circulating endothelial microparticles as a measure of early lung destruction in cigarette smokers. *Am J Respir Crit Care Med*. 2011, 184(2):224-32.
- [22] Kuempel ED, Wheeler MW, Smith RJ, Vallyathan V, Green FH. Contributions of dust exposure and cigarette smoking to emphysema severity in coal miners in the United States. *Am J Respir Crit Care Med*. 2009, 180(3):257-64.

- [23] Janciauskiene SM, Bals R, Koczulla R, Vogelmeier C, Köhnlein T, Welte T. The discovery of  $\alpha$ 1-antitrypsin and its role in health and disease. *Respir Med.* 2011, 105(8):1129-39.
- [24] Rennard SI, Vestbo J. COPD: the dangerous underestimate of 15%. *Lancet.* Apr 15 2006, 367(9518):1216-1219.
- [25] Global Initiative for Chronic Obstructive Lung Disease strategy for the diagnosis, management and prevention of chronic obstructive pulmonary disease: an Asia-Pacific perspective. *Respirology.* 2005, 10(1):9-17.
- [26] Lemyze M, Bart F. Hoover sign. *Cmaj.* 2011, 183(2):E133.
- [27] Garcia-Pachon E, Padilla-Navas I. Frequency of Hoover's sign in stable patients with chronic obstructive pulmonary disease. *Int J Clin Pract.* 2006, 60(5):514-517.
- [28] Bhatt SP, Guleria R, Luqman-Arafath TK, et al. Effect of tripod position on objective parameters of respiratory function in stable chronic obstructive pulmonary disease. *Indian J Chest Dis Allied Sci.* 2009, 51(2):83-85.
- [29] Klein JS, Gamsu G, Webb WR, Golden JA, Muller NL. High-resolution CT diagnosis of emphysema in symptomatic patients with normal chest radiographs and isolated low diffusing capacity. *Radiology.* 1992, 182(3):817-821.
- [30] Park KJ, Bergin CJ, Clausen JL. Quantitation of emphysema with three-dimensional CT densitometry: comparison with two-dimensional analysis, visual emphysema scores, and pulmonary function test results. *Radiology.* 1999, 211(2):541-547.
- [31] Qaseem A, Wilt TJ, Weinberger SE, et al. Diagnosis and management of stable chronic obstructive pulmonary disease: a clinical practice guideline update from the American College of Physicians, American College of Chest Physicians, American Thoracic Society, and European Respiratory Society. *Ann Intern Med.* 2011, 155(3):179-191.
- [32] Weatherall M, Marsh S, Shirtcliffe P, Williams M, Travers J, Beasley R. Quality of life measured by the St George's Respiratory Questionnaire and spirometry. *Eur Respir J.* 2009, 33(5):1025-1030.
- [33] Miller MR, Hankinson J, Brusasco V, et al. Standardisation of spirometry. *Eur Respir J.* 2005, 26(2):319-338.
- [34] Reid L. The pathology of emphysema. London,: Lloyd-Luke; 1967.
- [35] F BE, Harden A, Greene DG, Cournand A, Richards DW, Jr. Pulmonary insufficiency. IV. A study of 16 cases of large pulmonary air cysts or bullae. *Medicine (Baltimore).* 1950, 29(3):169-194.
- [36] Cooke FN, Blades B. Cystic disease of the lungs. *J Thorac Surg.* 1952, 23(6):546-569.
- [37] Klingman RR, Angelillo VA, DeMeester TR. Cystic and bullous lung disease. *Ann Thorac Surg.* 1991, 52(3):576-580.
- [38] Morgan MD, Denison DM, Strickland B. Value of computed tomography for selecting patients with bullous lung disease for surgery. *Thorax.* 1986, 41(11):855-862.
- [39] Morgan MD, Edwards CW, Morris J, Matthews HR. Origin and behaviour of emphysematous bullae. *Thorax.* 1989, 44(7):533-538.
- [40] De Giacomo T, Rendina EA, Venuta F, et al. Bullectomy is comparable to lung volume reduction in patients with end-stage emphysema. *Eur J Cardiothorac Surg.* 2002, 22(3):357-362.
- [41] Ting EY, Klopstock R, Lyons HA. Mechanical properties of pulmonary cysts and bullae. *Am Rev Respir Dis.* 1963, 87:538-544.

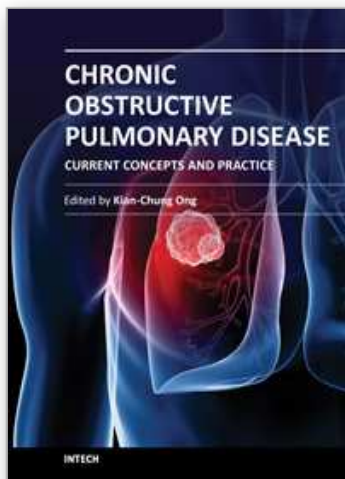
- [42] FitzGerald MX, Keelan PJ, Cugell DW, Gaensler EA. Long-term results of surgery for bullous emphysema. *J Thorac Cardiovasc Surg.* 1974, 68(4):566-587.
- [43] Mineo TC, Ambrogi V, Pompeo E, Mineo D. New simple classification for operated bullous emphysema. *J Thorac Cardiovasc Surg.* 2007, 134(6):1491-1497.
- [44] Nakahara K, Nakaoka K, Ohno K, et al. Functional indications for bullectomy of giant bulla. *Ann Thorac Surg.* 1983, 35(5):480-487.
- [45] Pride NB, Barter CE, Hugh-Jones P. The ventilation of bullae and the effect of their removal on thoracic gas volumes and tests of over-all pulmonary function. *Am Rev Respir Dis.* 1973,107(1):83-98.
- [46] Carr DH, Pride NB. Computed tomography in pre-operative assessment of bullous emphysema. *Clin Radiol.* 1984,35(1):43-45.
- [47] Schipper PH, Meyers BF, Battafarano RJ, Guthrie TJ, Patterson GA, Cooper JD. Outcomes after resection of giant emphysematous bullae. *Ann Thorac Surg.* 2004, 78(3):976-982; discussion 976-982.
- [48] McKenna RJ, Jr., Fischel RJ, Brenner M, Gelb AF. Use of the Heimlich valve to shorten hospital stay after lung reduction surgery for emphysema. *Ann Thorac Surg.* 1996, 61(4):1115-1117.
- [49] Brantigan OC, Mueller E, Kress MB. A surgical approach to pulmonary emphysema. *Am Rev Respir Dis.* 1959, 80(1, Part 2):194-206.
- [50] Delarue NC, Woolf CR, Sanders DE, et al. Surgical treatment for pulmonary emphysema. *Can J Surg.* May 1977, 20(3):222-231.
- [51] Dahan M, Salerin F, Berjaud J, Renella Coll J, Gaillard J. [Value of hemodynamics in the surgical indications of emphysema]. *Ann Chir.* 1989, 43(8):669-672.
- [52] Cooper JD, Patterson GA, Sundaresan RS, et al. Results of 150 consecutive bilateral lung volume reduction procedures in patients with severe emphysema. *J Thorac Cardiovasc Surg.* 1996, 112(5):1319-1329.
- [53] Sciurba FC. Preoperative predictors of outcome following lung volume reduction surgery. *Thorax.* 2002, 57 Suppl 2:II47-II52.
- [54] Ciccone AM, Meyers BF, Guthrie TJ, et al. Long-term outcome of bilateral lung volume reduction in 250 consecutive patients with emphysema. *J Thorac Cardiovasc Surg.* 2003, 125(3):513-525.
- [55] Rationale and design of the National Emphysema Treatment Trial (NETT): A prospective randomized trial of lung volume reduction surgery. *J Thorac Cardiovasc Surg.* 1999, 118(3):518-528.
- [56] Date H, Goto K, Souda R, et al. Bilateral lung volume reduction surgery via median sternotomy for severe pulmonary emphysema. *Ann Thorac Surg.* Apr 1998;65(4):939-942.
- [57] McKenna RJ, Jr., Brenner M, Fischel RJ, Gelb AF. Should lung volume reduction for emphysema be unilateral or bilateral? *J Thorac Cardiovasc Surg.* 1996, 112(5):1331-1338; discussion 1338-1339.
- [58] Miller JL, Jr., Lee RB, Mansour KA. Lung volume reduction surgery: lessons learned. *Ann Thorac Surg.* 1996, 61(5):1464-1468.
- [59] Fishman A, Martinez F, Naunheim K, et al. A randomized trial comparing lung-volume-reduction surgery with medical therapy for severe emphysema. *N Engl J Med.* 2003, 348(21):2059-2073.

- [60] Herth FJ, Eberhardt R, Ingenito EP, Gompelmann D. Assessment of a novel lung sealant for performing endoscopic volume reduction therapy in patients with advanced emphysema. *Expert Rev Med Devices*. 2011, 8(3):307-312.
- [61] Herth FJ, Gompelmann D, Ernst A, Eberhardt R. Endoscopic lung volume reduction. *Respiration*. 2010, 79(1):5-13.
- [62] Ingenito EP, Wood DE, Utz JP. Bronchoscopic lung volume reduction in severe emphysema. *Proc Am Thorac Soc*. 2008, 5(4):454-460.
- [63] Sciurba FC, Ernst A, Herth FJ, et al. A randomized study of endobronchial valves for advanced emphysema. *N Engl J Med*. 2010, 363(13):1233-1244.
- [64] Strange C, Herth FJ, Kovitz KL, et al. Design of the Endobronchial Valve for Emphysema Palliation Trial (VENT): a non-surgical method of lung volume reduction. *BMC Pulm Med*. 2007, 7:10.
- [65] Ernst A, Anantham D. Endoscopic management of emphysema. *Clin Chest Med*. 2010, 31(1):117-126.
- [66] Berger RL, Decamp MM, Criner GJ, Celli BR. Lung volume reduction therapies for advanced emphysema: an update. *Chest*. 2010, 138(2):407-417.
- [67] Reilly J, Washko G, Pinto-Plata V, et al. Biological lung volume reduction: a new bronchoscopic therapy for advanced emphysema. *Chest*. 2007, 131(4):1108-1113.
- [68] Snell GI, Hopkins P, Westall G, Holsworth L, Carle A, Williams TJ. A feasibility and safety study of bronchoscopic thermal vapor ablation: a novel emphysema therapy. *Ann Thorac Surg*. 2009, 88(6):1993-1998.
- [69] Mal H, Andreassian B, Pamela F, et al. Unilateral lung transplantation in end-stage pulmonary emphysema. *Am Rev Respir Dis*. 1989, 140(3):797-802.
- [70] Pasque MK, Cooper JD, Kaiser LR, Haydock DA, Triantafillou A, Trulock EP. Improved technique for bilateral lung transplantation: rationale and initial clinical experience. *Ann Thorac Surg*. 1990, 49(5):785-791.
- [71] Patterson GA, Cooper JD, Goldman B, et al. Technique of successful clinical double-lung transplantation. *Ann Thorac Surg*. 1988, 45(6):626-633.
- [72] Gaisert HA, Trulock EP, Cooper JD, Sundaresan RS, Patterson GA. Comparison of early functional results after volume reduction or lung transplantation for chronic obstructive pulmonary disease. *J Thorac Cardiovasc Surg*. 1996, 111(2):296-306.
- [73] Mendeloff EN, Meyers BF, Sundt TM, et al. Lung transplantation for pulmonary vascular disease. *Ann Thorac Surg*. 2002, 73(1):209-217.
- [74] Meyers BF, de la Morena M, Sweet SC, et al. Primary graft dysfunction and other selected complications of lung transplantation: A single-center experience of 983 patients. *J Thorac Cardiovasc Surg*. 2005, 129(6):1421-1429.
- [75] Bhattacharyya P, Sarkar D, Nag S, Ghosh S, Roychoudhury S. Transbronchial decompression of emphysematous bullae: a new therapeutic approach. *Eur Respir J*. 2007, 29(5):1003-1006.
- [76] Bhattacharyya P, Bardhan S, Nag S, Mukherjee S, Verma A. Transthoracic decompression of emphysematous bulla: a novel experience. *Indian J Chest Dis Allied Sci*. 2011, 53(1):51-53.
- [77] Wood DE, McKenna RJ, Jr., Yusef RD, et al. A multicenter trial of an intrabronchial valve for treatment of severe emphysema. *J Thorac Cardiovasc Surg*. 2007, 133(1):65-73.

- [78] Reilly J, Washko G, Pinto-Plata V, et al. Biological lung volume reduction: a new bronchoscopic therapy for advanced emphysema. *Chest*. 2007, 131(4):1108-1113.

IntechOpen

IntechOpen



## **Chronic Obstructive Pulmonary Disease - Current Concepts and Practice**

Edited by Dr. Kian-Chung Ong

ISBN 978-953-51-0163-5

Hard cover, 474 pages

**Publisher** InTech

**Published online** 02, March, 2012

**Published in print edition** March, 2012

A decade or so ago, many clinicians were described as having an unnecessarily 'nihilistic' view of COPD. This has certainly changed over the years... This open access book on COPD provides a platform for scientists and clinicians from around the world to present their knowledge of the disease and up-to-date scientific findings, and avails the reader to a multitude of topics: from recent discoveries in the basic sciences to state-of-the-art interventions on COPD. Management of patients with COPD challenges the whole gamut of Respiratory Medicine - necessarily pushing frontiers in pulmonary function (and exercise) testing, radiologic imaging, pharmaceuticals, chest physiotherapy, intensive care with respiratory therapy, bronchology and thoracic surgery. In addition, multi-disciplinary inputs from other specialty fields such as cardiology, neuro-psychiatry, geriatric medicine and palliative care are often necessary for the comprehensive management of COPD. The recent progress and a multi-disciplinary approach in dealing with COPD certainly bode well for the future. Nonetheless, the final goal and ultimate outcome is in improving the health status and survival of patients with COPD.

### **How to reference**

In order to correctly reference this scholarly work, feel free to copy and paste the following:

Nhue L. Do and Beek Y. Chin (2012). Chronic Obstructive Pulmonary Disease: Emphysema Revisited, Chronic Obstructive Pulmonary Disease - Current Concepts and Practice, Dr. Kian-Chung Ong (Ed.), ISBN: 978-953-51-0163-5, InTech, Available from: <http://www.intechopen.com/books/chronic-obstructive-pulmonary-disease-current-concepts-and-practice/chronic-obstructive-pulmonary-disease-emphysema-revisited>

**INTECH**  
open science | open minds

#### **InTech Europe**

University Campus STeP Ri  
Slavka Krautzeka 83/A  
51000 Rijeka, Croatia  
Phone: +385 (51) 770 447  
Fax: +385 (51) 686 166  
[www.intechopen.com](http://www.intechopen.com)

#### **InTech China**

Unit 405, Office Block, Hotel Equatorial Shanghai  
No.65, Yan An Road (West), Shanghai, 200040, China  
中国上海市延安西路65号上海国际贵都大饭店办公楼405单元  
Phone: +86-21-62489820  
Fax: +86-21-62489821

© 2012 The Author(s). Licensee IntechOpen. This is an open access article distributed under the terms of the [Creative Commons Attribution 3.0 License](https://creativecommons.org/licenses/by/3.0/), which permits unrestricted use, distribution, and reproduction in any medium, provided the original work is properly cited.

IntechOpen

IntechOpen