

We are IntechOpen, the world's leading publisher of Open Access books Built by scientists, for scientists

6,900

Open access books available

186,000

International authors and editors

200M

Downloads

Our authors are among the

154

Countries delivered to

TOP 1%

most cited scientists

12.2%

Contributors from top 500 universities



WEB OF SCIENCE™

Selection of our books indexed in the Book Citation Index
in Web of Science™ Core Collection (BKCI)

Interested in publishing with us?
Contact book.department@intechopen.com

Numbers displayed above are based on latest data collected.
For more information visit www.intechopen.com



Novel Technologies for Mapping and Ablation of Complex Arrhythmias

Shahnaz Jamil-Copley, Louisa Malcolm-Lawes and Prapa Kanagaratnam
*Imperial College Healthcare NHS Trust, St Mary's Hospital, London,
 National Heart and Lung Institute, Imperial College London,
 UK*

1. Introduction

1.1 The burden of complex arrhythmias

Atrial fibrillation (AF) is the most common cardiac arrhythmia, affecting about 9% of the population over 70 years of age (Feinberg, Blackshear et al. 1995). It is characterised by an irregular pulse, leading to symptoms of shortness of breath, dizziness, palpitations, chest pain, lethargy and an increased risk of stroke (Kannel, Abbott et al. 1982). Current widely accepted indications for catheter ablation of AF are significant symptoms uncontrolled by anti-arrhythmic medications, however more recent European Guidelines have suggested catheter ablation may be used as a first line treatment for symptomatic paroxysmal AF in patients with no or minimal heart disease. Randomised trials from 2003 - 2010 have shown a range of success rates for catheter ablation of AF from 56 - 89% (freedom from AF off anti-arrhythmic drugs) compared to the use of AADs alone ranging from 4 - 43% (Camm, Kirchhof et al. ; Kannel, Abbott et al. 1982).

Atrial tachycardia (AT) is relatively rare, accounting for 5-15% of all supraventricular tachycardias (SVTs). It can be encountered in patients with a structurally normal heart or those with underlying structural or scar-related heart disease. In patients with structurally normal hearts, atrial tachycardia is associated with a low mortality rate. However spontaneous resolution of symptomatic episodes is uncommon. Prolonged episodes (typically months or years) of continuous atrial tachycardia can be problematic leading to irreversible changes of the atria, including negative remodeling with atrial enlargement and myopathy causing symptomatic congestive cardiac failure. In addition, prolonged episodes can make reversion and maintenance of normal sinus rhythm more difficult. In recent years, the significance of AT in the initiation and perpetuation of atrial fibrillation has become apparent. Paradoxically AT occurs in up to 50% of patients undergoing extensive ablation for persistent AF.

Sustained ventricular tachycardia (VT) is a significant cause of morbidity and sudden death especially in patients with underlying structural heart disease. Coronary heart disease is the most common cause of clinically documented VT occurring in 76-82% of the patients (CASCADE Study 1993; Kuch et al 2000; AVID Study 1997; CIDS Study 2000). Although implantable cardioverter defibrillators (ICD) prevent sudden cardiac death and antiarrhythmic drugs reduce the frequency of VT episodes, drug side-effects and repeated device therapies can have a major impact on quality of life (Moss et al 2004, Poole et al 2008, Schron et al 2002). Recurrent VT develops in 40-60% of patients receiving an ICD for ischaemic cardiomyopathy

after an episode of spontaneous sustained VT however the first ICD therapy appears to be the most important predictor of subsequent therapy in this population and is likely to occur within the first two years of implant (Koa-Wing M et al 2007). VT ablation has been shown to reduce therapies from ICDs, but in its current state, is technically challenging and time consuming with procedural times up to 8 hours (Cao et al 1996).

1.2 The challenges of complex arrhythmias

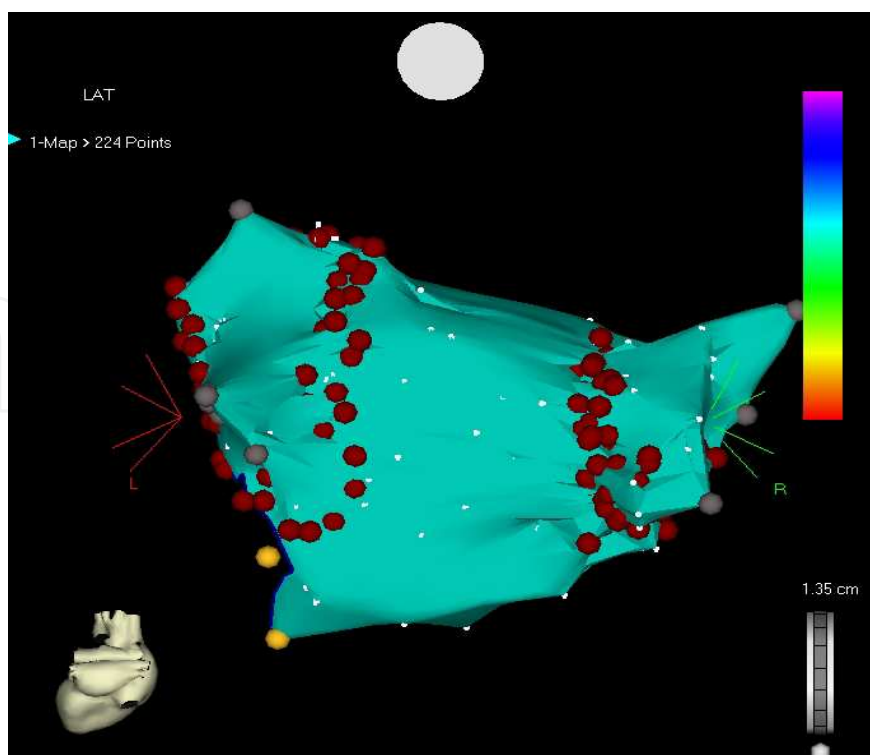
1.2.1 Atrial Fibrillation

Several models have been proposed to explain the continuous irregular atrial activation of clinical AF. It is widely accepted that the initiation of AF is from an atrial ectopic 'trigger' originating from the pulmonary veins (Haissaguerre, Jais et al. 1998). The 'trigger' can continue to act as 'a focal driver' maintaining AF or can establish a self-sustaining spiral wave (or rotor) in a localised region of the myocardium leading to fibrillatory activation in the remaining atria (Haissaguerre, Jais et al. 1998; Jalife, Berenfeld et al. 2002; Sahadevan, Ryu et al. 2004).

Pulmonary vein isolation to remove the 'trigger' has been shown to be effective in paroxysmal AF (Haissaguerre, Jais et al. 1998) (Pappone, Santinelli et al. 2004). However, triggers outside the pulmonary veins have also been identified in the superior vena cava and coronary sinus and these have been more challenging to identify and treat. Linear ablation has been performed in both paroxysmal and persistent AF along the principles of the Cox Maze surgical procedures, but these have not achieved the same success as the surgical approach (Cox, Boineau et al. 1995; Cox, Schuessler et al. 1996; Hsu, Jais et al. 2004). Linear ablation at the roof of the left atrium (Hocini, Jais et al. 2005) and the mitral isthmus between the left lower pulmonary vein and annulus has been shown to improve outcomes when there is proven conduction block of these lines (Jais, Hocini et al. 2004; Willems, Klemm et al. 2006). However, conduction block is difficult to achieve due to lack of catheter stability and failure to achieve transmuralit.

More recently, catheter-based substrate modification has targeted regions of highly fractionated electrograms that others suggest as drivers for persistent AF (Lellouche, Buch et al. 2007). Nadamanee et al achieved an 81% success rate for ablation after up to 4 procedures targeting only areas of complex fractionated atrial electrograms (CFAE) (Nadamanee, Schwab et al. 2008). However several other groups have failed to reproduce these success rates with CFAE ablation alone (Estner, Hessling et al. 2008). Speculation as to the mechanistic basis for CFAE has implicated regions of autonomic innervations termed the ganglionated plexi, as these were noted to be co-located with regions of CFAE in animal studies. Alternatively, they may originate from regions of atrial scarring or fibrosis, and are thought to represent a combination of wavefronts approaching the recording electrode from multiple directions. Integration of delayed-enhancement MRI imaging, particularly containing information relating to scar, may provide greater insight on the origin of CFAE. This is discussed in more detail later in this chapter.

Wide area circumferential ablation with pulmonary vein isolation, designed to encircle the PVs at a distance from the ostia, is a widely accepted technique for AF ablation and appears to achieve greater success rates than segmental PVI. (Marrouche, Martin et al. 2003; Pappone, Rosanio et al. 2003; Ouyang, Bansch et al. 2004) The most widely practiced approach is to use a 3D-navigation system to recreate a virtual left atrium and move around the chamber delivering lesions around the pulmonary veins and marking lesion points on the virtual anatomy.(Pappone, Oreto et al. 1999) The 3D geometry aids the operator in manipulating catheters around the complex anatomy of the left atrium which can vary significantly from patient to patient. This can prove particularly challenging with only 2D fluoroscopy for navigation.



Example of virtual left atrium and points marked (red balls) during wide area circumferential ablation

Despite these novel approaches, published success rates for single procedure AF ablation range remain around 50% to 88% (Lim, Matsuo et al. 2007; Matsuo, Lim et al. 2007; Natale, Raviele et al. 2007; O'Neill, Jais et al. 2007; Marchlinski 2008) which are still not comparable to the >95% success rates expected from ablations for other arrhythmias.

1.2.2 Atrial Tachycardia

Endocardial activation allows categorisation of ATs into focal and macro-reentrant. However in the era of persistent AF ablation the presence of “micro-reentry” circuits particularly within regions of previous complex fractionated atrial electrograms (CFAE) ablation scar must be acknowledged. It is therefore imperative to clarify the mechanism of the underlying AT during electrophysiological procedures to guide ablation therapy. Currently established techniques for guiding ablation in complex atrial tachycardias include activation and/or entrainment mapping. Routinely the tachycardia is displayed as an activation map on a recreated atrial geometry from endocardial location points collected using 3-D mapping technology. However, activation mapping is limited by a point-by-point acquisition process which is not always systematic, is often time-consuming and can miss small areas crucial to the circuit. Detailed mapping often requires >150-200 points with each circuit potentially involving multiple loops and figure-of-8 circuits. In order to identify the critical isthmus maintaining the tachycardia a trained operator is required to set an accurate “window of interest” and collect activation data, which requires significant processing to ensure all collected points have been correctly annotated to the chosen reference. In addition conventionally established entrainment manoeuvres are often used to confirm the diagnosis represented by activation mapping however these can have limitations if there is a variation in the tachycardia cycle length particularly in scarred atria with multiple regions of block and slow conduction.

The most commonly recognised mechanisms seen post-AF ablation are macro re-entrant roof-dependant and mitral isthmus dependant tachycardias however with increasing linear and CFAE ablation lesions, micro-reentrant circuits must also be appreciated. In these situations diagnostic yield from mapping and entrainment can test the most skilled electrophysiologist and although acute success rates have been reported ranging from 88-100%, recurrences are disappointing with rates ranging from 0-47% over a mean follow-up of 2 to 16 months (Gerstenfeld 2004; Chugh 2005; Deisenhofer 2006; Mesas 2004; Haïssaguerre 2005).

Several other circuits capable of sustaining re-entrant tachycardias are seen following cardiac surgery, particularly congenital heart disease.

These are typically a challenge to map and ablate due to the unpredictable location and extent of the underlying iatrogenic scar exposing the limitations of the aforementioned diagnostic techniques.

1.2.3 Ventricular Tachycardia

The biggest challenge in VT ablation remains scar-related VT including ischaemic and dilated cardiomyopathy. The substrate for post-infarct VT is produced by channels of slow conduction within the scar border (the diastolic pathway), created by anatomical and functional lines of block. Identification and ablation of these diastolic pathways is required for successful VT ablation (Koa-Wing, Ho SY et al 2007; Stevenson, Khan et al 1993). Conventional techniques to identify the diastolic pathway consist of performing activation mapping followed by entrainment manoeuvres to locate areas within the scar that participate in the re-entrant circuit (Stevenson, Khan et al 1993; Huang & Wood 2006; Bogun, Good et al 2006), but non-inducibility, difficulty capturing scarred myocardium during entrainment, multiple different morphologies of VT, haemodynamic instability and circuit components deep to the sub-endocardium make this approach unreliable and prolonged with disappointingly high recurrence rates.

These limitations have led to a change in practice from targeting specific circuits to substrate modification of the scar by linear ablation in an attempt to transect potential diastolic pathways and render the VT non-inducible (Marchlinski, Callans et al 2000). Although acute ablation success rates at elimination of the “clinical” tachycardia have improved from 71-74% (Morady et al 1993, Gonska et al 1994, Kim et al 1994) in the mid-1990s to 90% in the 2000s (Sacher et al 2008) long-term outcomes remain unsatisfactory. This is despite the introduction of cardiac mapping systems, irrigated tip catheters and substrate based ablation strategies. Up to 31% of patients with an acutely successful ablation outcome of the “clinical” VT have arrhythmia recurrence. Ablation to non-inducibility of any VT has been reported with success rates approaching 65% but with recurrence rates of 29% during a median follow-up of 1 month (Sacher et al. 2008). The potential causes of recurrence or failure at the index procedure include inadequate mapping techniques of, often small, isthmi in a complex anatomic substrate and failure to achieve transmural lesions in those with circuits traversing the subendocardium and epicardium. Although epicardial circuits can be targeted percutaneously, this is not possible in up to 85% of patients with previous cardiac surgery (Sacher F, Roberts-Thomson K, et al. 2010).

2. Mapping

The development of intra-cardiac mapping was based on the use of individual contact catheters. Despite being able to record information from different sites using multipolar catheters, complex arrhythmias and complex substrates pose significant challenges using these techniques. 3-D electrophysiological mapping systems were developed to aid the

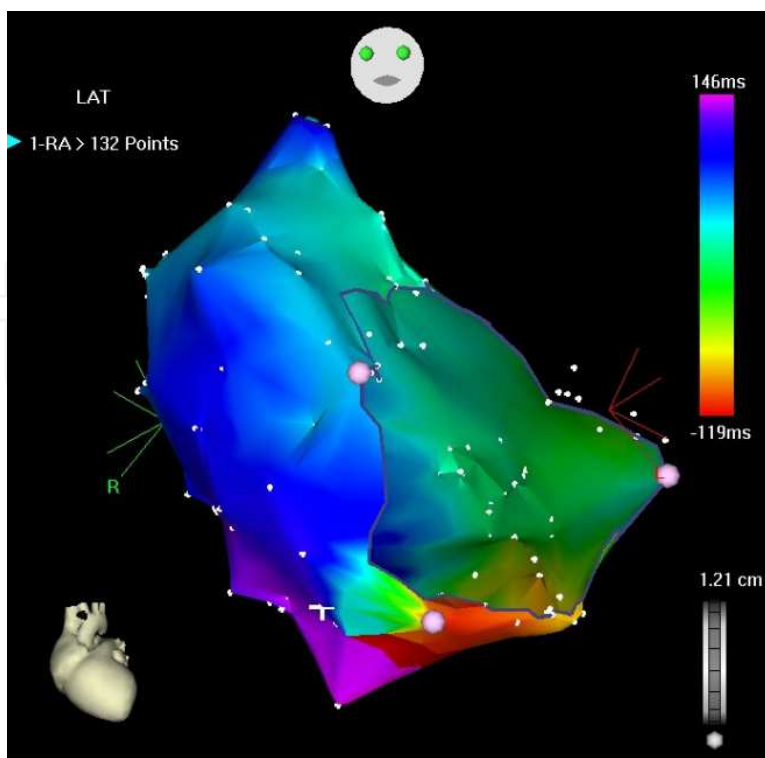
localisation of the source of focal tachycardias and the critical isthmi of re-entrant circuits (Stevenson, Delacretaz et al 1998; Marchlinski, Callans et al 1998; Earley, Showkathali et al 2006; Schilling, Peters et al 1999; Shah, Jais et al 1997) Conventionally, these systems display electrical data from mapping catheters as either local activation time (isochronal) or local voltage (isopotential) maps. These methods indicate the parameter being displayed using a colour-scale on a 3D representation of the cardiac chamber of interest.

The current versions of these mapping systems are not only significantly more accurate but they offer many more features to facilitate mapping of complex arrhythmias; voltage mapping, propagation maps, rapid mapping using multipolar catheters and mapping of fractionated electrograms and the input of anatomical data from pre-operative CT or MRI scans of the heart or rotational angiograms. The latest feature allowing 4-dimensional mapping, 'ripple-mapping', will also be discussed in this chapter.

The use of mapping systems has not been shown to reduce the duration of the procedure or the efficacy of the procedure (Sporton, Earley et al. 2004), however, it has been shown to significantly reduce the fluoroscopy time, thereby reducing the exposure of patients and lab staff to harmful radiation. (Scaglione, Biasco et al.)

2.1 Current mapping systems

Current electroanatomic mapping systems build a 3-dimensional geometry of a cardiac chamber by recording sequential positional co-ordinates from the catheter tip in contact with the myocardium and combining this information with concomitantly acquired electrogram data. Low voltage areas and scar can be easily identified to develop a picture of the underlying substrate for arrhythmogenesis. Electrogram timings with respect to a stable reference catheter, enables an activation map to be created, which is colour coded to differentiate between 'early' and 'late' signals.

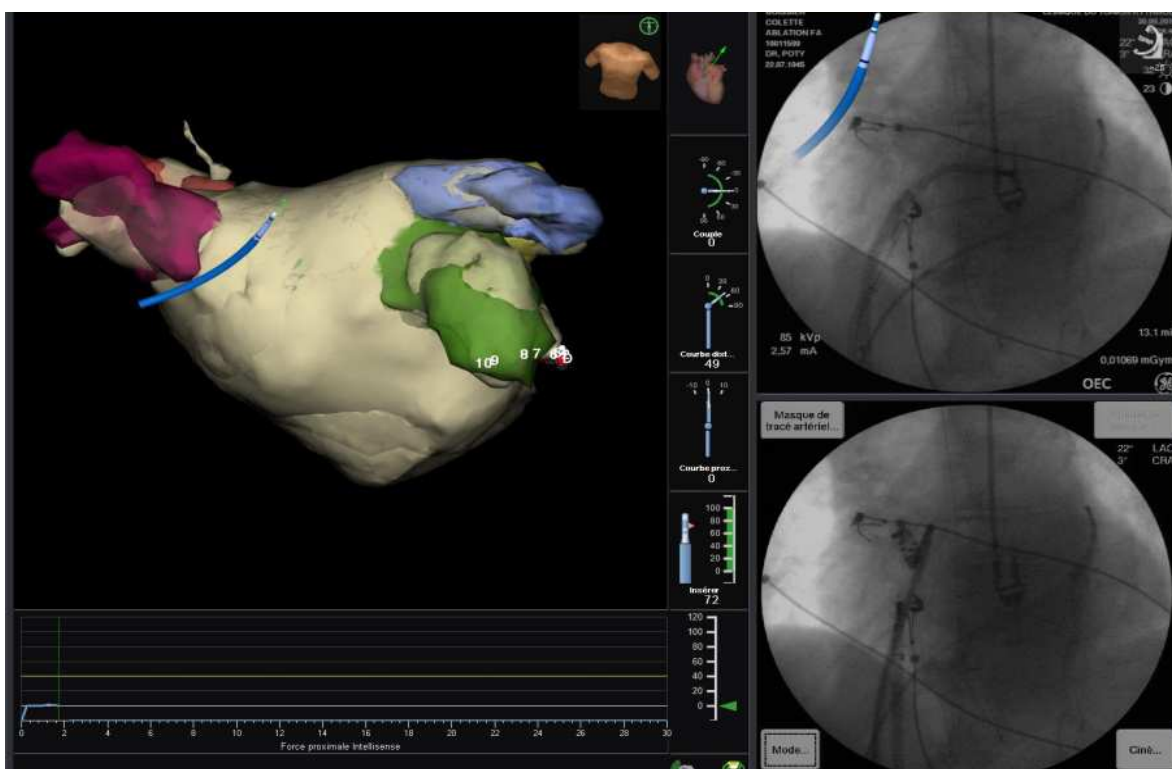


Colour coded activation map of a clockwise isthmus dependent right atrial flutter.

Alternatively, this can be displayed as a propagation map, which demonstrates activation of the excitatory wavefront as it advances across the chamber geometry. Maps can be rotated and viewed in multiple orientations at the same time so that the wavefront can be followed throughout the cardiac cycle. Electroanatomic mapping systems are primarily used for mapping stable tachycardias, however they can also facilitate substrate mapping during sinus rhythm, which is particularly useful when mapping VTs which cause significant haemodynamic compromise. Additionally, these systems facilitate encirclement of cardiac structures, the best example of which is the encirclement of pulmonary veins as part of the treatment for ablation of atrial fibrillation (AF). Areas targeted may lie between important scar boundaries (e.g. linear ablation lesions to transect the diastolic pathway in VT circuits) or between inert structures (e.g. linear ablation between the mitral valve annulus and the left inferior pulmonary vein in mitral isthmus-dependent atrial tachycardia).

2.2 Integration with robotic navigation

New Cohesion™ 3D visualisation module available with the Hansen Robotic Navigation system allows integration of the electroanatomic mapping system NavX or Velocity (St Jude Medical™). This facilitates navigation of the robotic catheter by producing an intuitive driving plane according to the orientation of the virtual geometry within the mapping system. This removes the requirement for the operator to re-orientate him or herself when using the virtual geometry of the left atrium to guide navigation. This has been tested in clinical studies and shown to reduce fluoroscopy times for robotic navigation and ablation of AF. (Steven, Servatius et al. 2009)



Example of Cohesion, Hansen Robotic navigation system fully integrated with NavX mapping system to provide intuitive driving in the orientation of the virtual LA geometry

2.3 Integration with MRI / CT imaging

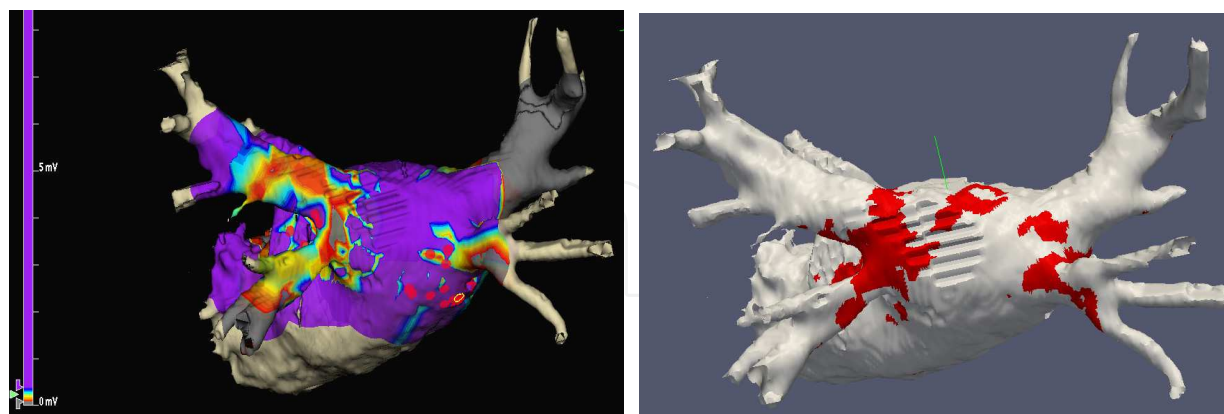
The CARTO™ and NavX™ systems can both integrate digital computed tomography (CT) or magnetic resonance imaging (MRI) images of the heart into a mapping study, allowing navigation of “virtual” catheters within a high resolution model of the patient’s anatomy.

CT / MRI studies can either be imported and segmented via the image processing platforms available in both mapping systems, or can be segmented offline by an experienced operator for direct import to the mapping system at the time of the procedure. Registration of the segmented chamber to the patient orientation is performed using fluoroscopy. Fixed anatomical landmarks close to the chamber of interest are acquired and subsequently registered with their corresponding sites on the CT/MRI image. The identified landmarks are then “merged” together to complete the registration process so that the catheter tip can be navigated within the detailed anatomical shell created on CT / MRI.

Electroanatomical mapping with CT/MRI image integration is particularly useful in patients with unusual or complex anatomy such as those with congenital heart disease and previous cardiac surgery. Detailed chamber anatomy is also helpful in pulmonary vein isolation procedures, by delineating the location, size and orientation of the pulmonary vein ostia. However, CT / MRI integration does not improve acute procedural efficacy or long term success rates.(Kistler, Rajappan et al. 2008)

2.4 Imaging of myocardial scar and integration with mapping systems

Delayed-enhanced Magnetic Resonance Imaging (DE-MRI) has been used for almost a decade to identify regions of ventricular scar. An increase in extracellular space within myocardial scar allows for an accumulation and prolonged wash-out time of the contrast agent, gadolinium.(Saraste, Nekolla et al. 2008). Information regarding ventricular or atrial scar can be obtained from voltage readings using intra-cardiac catheters. However, the integration of DE-MRI data may eliminate the need for acquisition of a detailed voltage map, and prevent inaccurate readings due to poor catheter contact.



Example of similarity between endocardially collected voltage map and regions of LA scar identified by DE-MRI

2.4.1 Ventricular scar in ischaemic VT

DE-MRI enables detection, characterization and accurate quantification of acute and chronic myocardial infarction (Simonetti et al; McNamara et al 2001). Quantification of infarct size on DE-MRI has been validated against true infarct size as verified by

histochemical staining in animal models (Kim RJ et al 1999). Heterogeneous tissue surrounding areas with dense LGE are hypothesized to be the imaging equivalent of slow conduction zones in patients with ischemic cardiomyopathy (Yan AT, Shayne AJ et al. 2006; Roes SD, Borleffs CJ et al 2009) although this is not a consistent finding. Until higher resolution images are possible we must accept the reality that the currently visualized “infarct core” and “heterogeneous tissue” is a mixture of true infarct core, true heterogeneous tissue, and artifacts, particularly those produced by volume averaging of infarct core with healthy tissue.

Utilising the technique described by Yan et al, Perez-David et al. demonstrated the connection between heterogeneous tissue on CMR and slow conduction zones identified by endocardial mapping. Furthermore, they confirmed that sites identified as critical VT isthmi by electrophysiological manoeuvres often reside in heterogeneous tissue identified by CMR.

2.4.2 Atrial scar in AF and AT

More recently, as scanners and scanning quality have improved, attention has turned to visualising atrial myocardium, in particular looking for regions of pre-existing fibrosis and iatrogenic scar following catheter ablation procedures.(Kim, Hillenbrand et al. 2000; Kim, Wu et al. 2000) Several recent studies have shown that high-spatial-resolution delayed enhancement MR (DE-MRI) imaging allows identification of scar induced by RF ablation in the left atrium(Peters, Wylie et al. 2007; McGann, Kholmovski et al. 2008; Badger, Adjei-Poku et al. 2009). Badger et al showed, however, that chronic atrial scar may not be formed and visible on MRI until up to 3 months following the ablation procedure. (Badger, Oakes et al. 2009) Integration of data from DE-MRI regarding location of scarred regions may benefit procedures such as repeat AF ablations and post-ablation atrial tachycardias. In particular, it may help identify the location of gaps within lines which are providing the substrate for ongoing AF / AT.

Methods for improved patient selection and non-invasive evaluation of the LA wall to assess the extent permanent tissue injury created by ablation, may be an important tool in improving ablation technique and increasing procedural success. Oakes et al demonstrated that the presence of left atrial fibrosis prior to ablation can also be detected using DE-MRI and that patients with higher levels of fibrosis had lower procedural success rates.(Oakes, Badger et al. 2009) On this basis they hypothesised that a further possible use of DE-MRI may be that of patient selection for atrial fibrillation ablation.

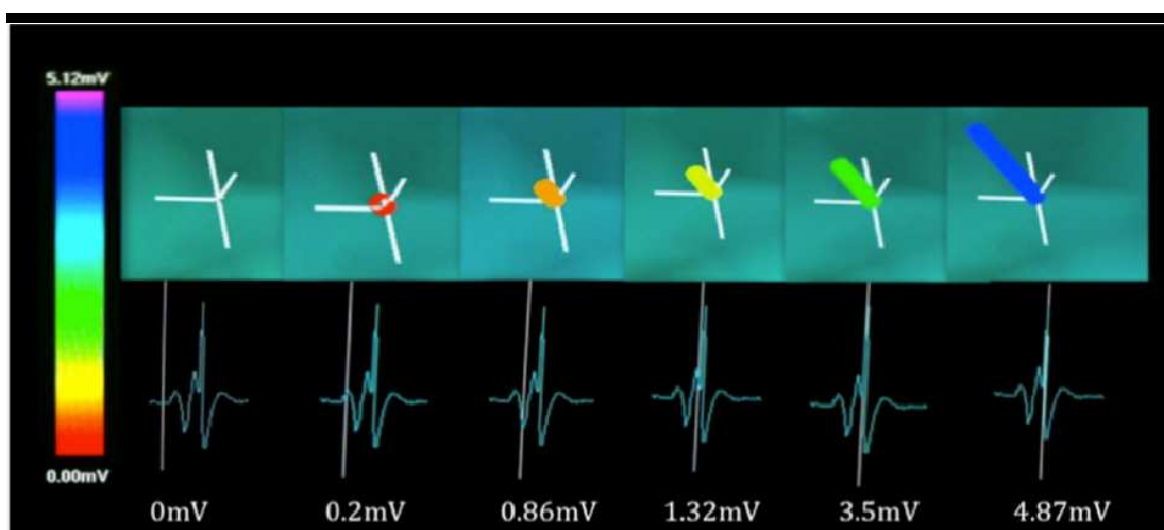
2.5 Novel mapping systems: CARTO Ripple

Despite the aforementioned advantages of current mapping systems there remain shortfalls and limitations to their use. The conversion of the raw electrical data to ‘clean’ activation maps requires operator expertise with the potential introduction of errors by incorrect assignment of local activation times or voltage thresholds. Furthermore interpolation of data within unmapped regions can lead to the display of false information. The introduction of integrated multielectrode mapping catheters should reduce this error by allowing creation of dense maps. This integration should also improve the rapidity with which maps are created with a likely increase in diagnostic yield (Patel et al 2008). Additionally, colour-spectrum isochronal maps are often converted to propagation maps that display moving activation wave fronts that are interpreted more intuitively but are mathematically extrapolated from the points collected and can give the operator a false sense of the

resolution of the map. Isopotential maps created by grouping far-field reconstructed electrograms (Ensite Array) that are above a pre-specified activation threshold voltage to create activation wave fronts are prone to errors due to the subjective variation introduced by voltage threshold adjustments. In addition the hardware is limited by far-field reconstruction of low voltage electrograms.

Intracardiac electrograms provide unique site-specific data about local electrical activation and in-vitro studies have demonstrated that underlying anatomical substrate can be deduced from the electrogram morphology (Spach MS, Miller WT et al 1979). Electrograms are categorised by largely binary descriptors; simple or complex, early or late, high or low amplitude. Potentially crucial information contained within electrograms is lost to interpretation with current 3D mapping systems. CARTO does not assign any characteristics to potentials (diastolic or late systolic) within ventricular scar and is unable to appropriately display valuable data contained within complex fractionated electrograms often representing regions of slow conduction which may play a pivotal role in scar related atrial arrhythmias. As the system can only assign a single value for the local activation time, isochronal and activation maps can be flawed if complex fractionated electrograms are annotated incorrectly.

ENSITE can collect simultaneous global activation data but is prone to far-field noise making low-amplitude fractionated signals difficult to differentiate from noise or repolarisation.



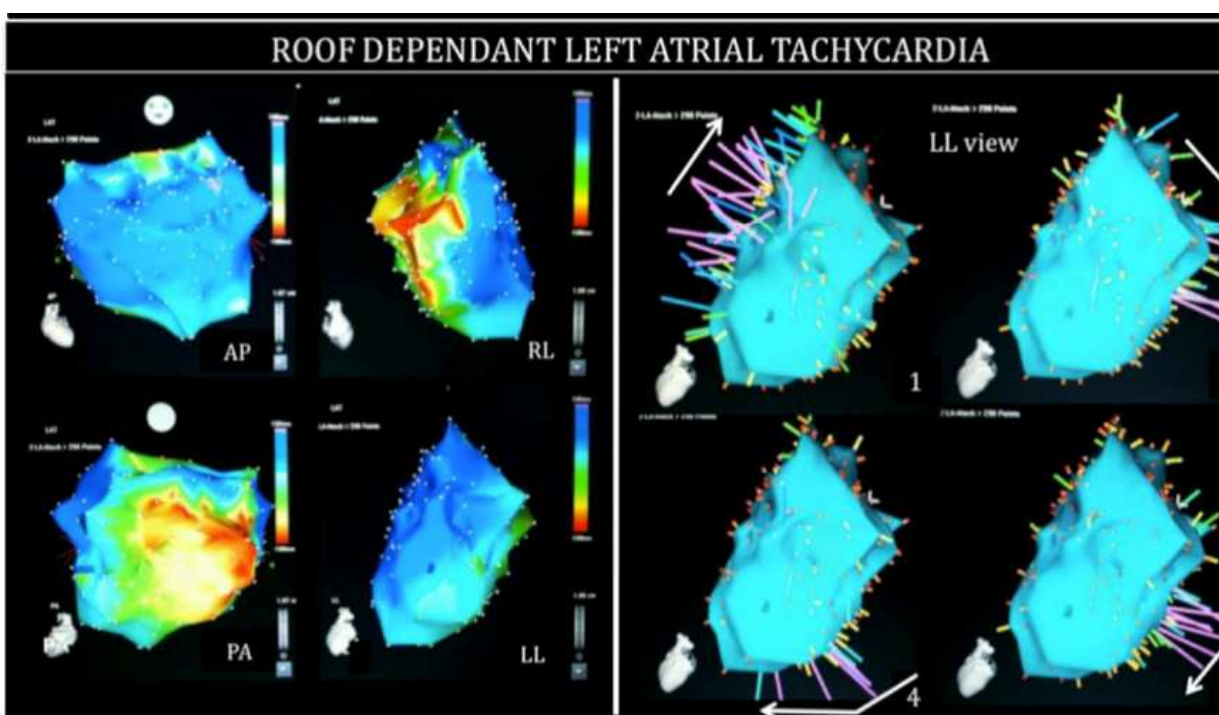
The top panel shows increasing Ripple bar height in correlation to the increasing magnitude of the electrogram voltage in the annotation window (shown in the lower window).

The bar height and colour are clearly visible. These can be correlated to the conventional reference colour bar from CARTO seen to the left of the panel with low voltage represented by red and high voltage represented by purple

The conventional 2D method for displaying electrograms is deflection from a baseline according to a voltage scale. The overall sequence of directions and rates of change and amplitudes of deflections define the electrogram "morphology". A new visualisation algorithm, Ripple Mapping, has allowed the reproduction of this 2D process on a 3D hull using a bar moving out from the cardiac surface conveying location, timing and electrogram morphology simultaneously (Linton, Koa-Wing, 2009). Multiple points collected in a small

area will display bars, which change according to the local voltage change and in a temporally accurate sequence producing a 'ripple' effect which conveys the direction of wave propagation without any operator annotation. The program avoids interpolation and as it does not use a single local activation time, all the components of the electrogram are preserved and displayed. Therefore a sequence of small potentials and complex electrograms can be temporally related to adjacent electrograms. This method has the benefit of using high quality contact electrograms capable of demonstrating low amplitude signals with accurate 3D localisation, enabling the assessment of electrogram morphology within scar.

During the proof-of-concept study this novel method of cardiac mapping showed low-amplitude continuous activity in four of five tachycardias at the site of successful ablation, consistent with a re-entrant mechanism. Cardiac Ripple Mapping has been integrated onto an off-line CARTO™ platform, which is currently undergoing validation and clinical evaluation.



Left panel: Displays a left atrial CARTO-XP local activation time (LAT) map of a patient with left atrial tachycardia following circumferential pulmonary vein isolation for paroxysmal atrial fibrillation. Analysis of the LAT map suggests the possibility of a focal tachycardia origination from the posterior wall near the right pulmonary veins.

Right panel: The same atrial tachycardia as seen on the corresponding unaltered Ripple map (left lateral view) shows a roof dependant atrial tachycardia which was confirmed by conventional entrainment manoeuvres.

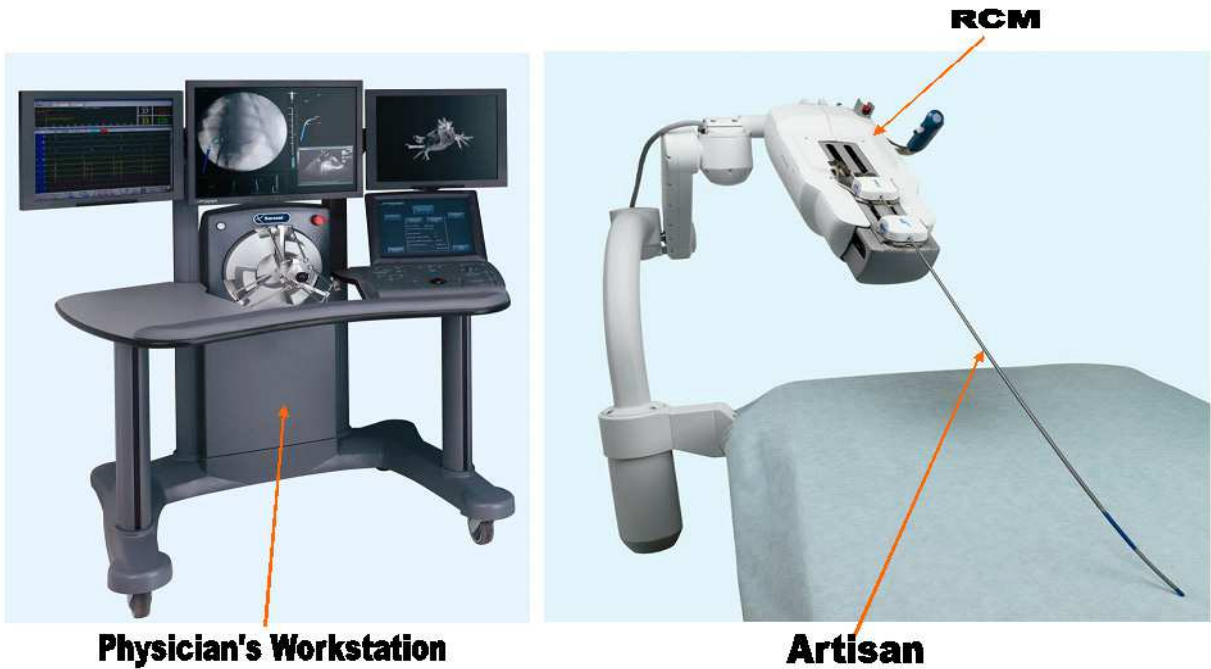
3. Ablation of complex arrhythmias

The achievement of transmuralty of ablation lesions for permanent VT abolition and pulmonary vein isolation is one of the ongoing challenges of ventricular tachycardia and atrial fibrillation ablation (Haissaguerre, Shah et al. 2000; Pappone, Santinelli et al.

2004);(Kosmidou, Inada et al. 2011 ; Willems, Steven et al. 2010). The Hansen™ robotic system was designed to improve catheter tip stability, lesion quality and clinical outcomes.

3.1 The Hansen robotic navigation system

The Hansen Sensei electromechanical robotic navigation system is capable of remotely steering a guide catheter to enable precise positioning and manipulation of any type of electrophysiological catheter within the heart for mapping and ablation. The Sensei system has been described in detail previously.(Saliba, Cummings et al. 2006; Kanagaratnam, Koa-Wing et al. 2008) In brief, the system comprises three linked components: the physician's workstation (Sensei™ robotic control system), remote catheter manipulator (RCM) and steerable guide catheter (Artisan™ Sheath). The steerable guide catheter comprises an outer (14F) and inner (10.5F) steerable sheath through which any 8.5F or less ablation catheter can be placed. The outer guide can be inserted, deinserted and can bend up to 90 degrees, whereas the inner guide is controlled by the 3D joystick and can be directed anywhere within the toroidal workspace. The Artisan sheath maintains the catheter position by the tensile strength of four pullwires so that the shape adopted by the sheath is uniquely suited to the point of interest to which the catheter is being positioned.(Kanagaratnam, Koa-Wing et al. 2008) This is in contrast to the manual approach, where the operator has to dynamically apply torque and flexion to prevent the catheter displacing from the point of interest. The Sensei™ robotic control system also incorporates a pressure sensor (Intellisense™), which calculates the contact force at the tip of the catheter using the differential resistance when continuously dithering the catheter in and out of the Artisan sheath. This tissue contact pressure enhances the validation of tissue contact and also provides for the ability to identify a pressure curve for optimal lesion production. (Kanagaratnam, Koa-Wing et al. 2008)



Hansen Robotic Artisan steerable sheath.

The Sensei system is currently compatible with all 8.5F or less mapping and irrigated ablation catheters. The physicians work station comprises 3 screens which can display any selected data including fluoroscopy, intracardiac echocardiography, electroanatomic mapping systems (Carto Biosense Webster, NavX St Jude Medical, Rotational Angiography imaging Philips ElectroNav etc.), and electrogram display systems (Bard Lab System Pro etc.) The free standing physician's work station and remote catheter manipulation system mounted on the patient table can be moved between laboratories and do not require any floor reinforcement such as that required for magnetic remote navigation systems.

The intended benefit of robotic catheter manipulation is that the catheter position is maintained once the physician has released the 3D joystick providing increased stability throughout the duration of RF delivery. In addition, the Intellisense system can confirm catheter contact during ablation.

3.1.1 Atrial and ventricular ablation

Several studies have been performed in animals to investigate whether the theoretical benefits of robotic ablation are translated into improved measurable parameters of lesion quality. In a study comparing robotic (Sensei) and manual ablation in 7 pig atria, robotic ablation reduced local electrogram amplitude to a greater degree than manual ablation ($49 \pm 2.6\%$ vs $29 \pm 4.5\%$ signal reduction after one minute $p=0.0002$) The incidence of $>50\%$ signal reduction was also greater for robotic (37%) than manual (21%) ($p=0.0001$). (Koa-Wing, Kojodjojo et al. 2009) Koa-Wing et al also noted that macroscopically the robotic lesions were more consistently transmural compared to the manual lesions, with no evidence of charring or perforation with either modality. In other in-vitro studies, 45W at 20-30g for 40secs, 83% of lesions were transmural, however 33% of lesions were associated with char formation. Using 30W and 20-30g pressure 0% were associated with char formation, however only 16% were associated with transmural lesion formation. (Di Biase, Natale et al. 2009),

Previous human studies comparing robotic and manual ablation have been non-randomised and have shown no significant difference in clinical outcomes. The primary aim of these studies was to prove safety and feasibility, however it is important to try to understand the potential reasons why these studies did not deliver the anticipated benefits of increased catheter precision and stability. (Willems, Steven et al 2010; Di Biase, Wang et al. 2009) The two studies both quoted using the same settings for both robotic and manual ablation (45W for 20secs and 20-25W for 60s) lesions. Interestingly, both reports comment on how robotic ablation required shorter radiofrequency duration. Therefore, in both series it appears that operators adjusted power according to anatomical location and local signal attenuation. Therefore, if the same target was being used for both manual and robotic arms, it is unsurprising that the clinical outcomes were similar.

The ability to titrate force and improve tissue contact are important attributes required during ablation in the ventricle which can be over a centimetre thick. Furthermore greater transmural of delivered lesions should negate the need to gain epicardial access in this patient population who have often previously undergone cardiac surgery, making percutaneous access less practical. The reduction in operator radiation exposure during these long procedures is of added value. There are no large scale trials of robotic VT ablation however acute feasibility is suggested by occasional single case reports (Duncan, Johns et al 2010; Koa-Wing, Linton et al. 2009) Larger scale studies should help clarify the role of this technology in ablation of complex arrhythmias.

4. Conclusion

With the rapidly progressing field of catheter ablation, advances in mapping and ablation technologies will lead to improved therapeutic outcomes in complex cardiac arrhythmias. Innovative methods of assessing, displaying and integrating the underlying substrate of complex scar with electrophysiological data will further streamline our current practice in these challenging cases.

5. References

- Anonymous (1997): A comparison of antiarrhythmic-drug therapy with implantable defibrillators in patients resuscitated from near fatal ventricular arrhythmias. The antiarrhythmics versus implantable defibrillators (AVID) Investigators. *N Engl J Med*, 337:1576- 1583.
- Badger, T. J., R. S. Oakes, et al. (2009). "Temporal left atrial lesion formation after ablation of atrial fibrillation." *Heart Rhythm* 6(2): 161-8.
- Badger, T. J., Y. A. Adjei-Poku, et al. (2009). "MRI in cardiac electrophysiology: the emerging role of delayed-enhancement MRI in atrial fibrillation ablation." *Future Cardiol* 5(1): 63-70.
- Bogun F., Good E., Reich S., Elmouchi D., Igit P., Lemola K., Tschopp D., Jongnarangsin K., Oral H., Chugh A., Pelosi F. & Morady F. (2006) Isolated potentials during sinus rhythm and pace-mapping within scars as guides for ablation of post-infarction ventricular tachycardia. *J Am Coll. Cardiol*, 47: 2013-2019.
- Calkins, H., J. Brugada, et al. (2007). "HRS/EHRA/ECAS expert Consensus Statement on catheter and surgical ablation of atrial fibrillation: recommendations for personnel, policy, procedures and follow-up. A report of the Heart Rhythm Society (HRS) Task Force on catheter and surgical ablation of atrial fibrillation." *Heart Rhythm* 4(6): 816-61.
- Camm, A. J., P. Kirchhof, et al. "Guidelines for the management of atrial fibrillation: the Task Force for the Management of Atrial Fibrillation of the European Society of Cardiology (ESC)." *Europace* 12(10): 1360-420.
- Cao, K. & Gonska, B. D. (1996). Catheter ablation of incessant ventricular tachycardia: acute and long-term results. *Eur Heart J*. 17:756-763.
- Cappato, R., H. Calkins, et al. (2005). "Worldwide survey on the methods, efficacy, and safety of catheter ablation for human atrial fibrillation." *Circulation* 111(9): 1100-5.
- Chugh A, Oral H, Lemola K, Hall B, Cheung P, Good E, Tamirisa K, Han J, Bogun F, Pelosi F, Morady F. Prevalence, mechanisms, and clinical significance of macroreentrant atrial tachycardia during and following left atrial ablation for atrial fibrillation. *Heart Rhythm*. 2005;2:464-471.
- Connolly SJ, Gent M, Roberts RS, Dorian P, Roy D, Sheldon RS, Mitchell LB, Green MS, Klein GJ, O'Brien B (2000): Canadian implantable defibrillator study (CIDS): A randomized trial of the implantable cardioverter defibrillator against amiodarone. *Circulation*, 101:1297-1302.
- Coumel, P. (1994). "Paroxysmal atrial fibrillation: a disorder of autonomic tone?" *Eur Heart J* 15 Suppl A: 9-16.

- Coumel, P. (1996). "Autonomic influences in atrial tachyarrhythmias." *J Cardiovasc Electrophysiol* 7(10): 999-1007.
- Cox, J. L., J. P. Boineau, et al. (1995). "Modification of the maze procedure for atrial flutter and atrial fibrillation. I. Rationale and surgical results." *J Thorac Cardiovasc Surg* 110(2): 473-84.
- Cox, J. L., R. B. Schuessler, et al. (1996). "An 8 1/2-year clinical experience with surgery for atrial fibrillation." *Ann Surg* 224(3): 267-73; discussion 273-5.
- Deisenhofer I, Estner H, Zrenner B, Schreieck J, Weyerbrock S, Hessling G, Scharf K, Karch MR, Schmitt C. Left atrial tachycardia after circumferential pulmonary vein ablation for atrial fibrillation: incidence, electrophysiological characteristics, and results of radiofrequency ablation. *Europace*. 2006;8:573-582.
- Deisenhofer, I., H. Estner, et al. (2009). "Does electrogram guided substrate ablation add to the success of pulmonary vein isolation in patients with paroxysmal atrial fibrillation? A prospective, randomized study." *J Cardiovasc Electrophysiol* 20(5): 514-21.
- Di Biase, L., A. Natale, et al. (2009). "Relationship between catheter forces, lesion characteristics, "popping," and char formation: experience with robotic navigation system." *J Cardiovasc Electrophysiol* 20(4): 436-40.
- Di Biase, L., Y. Wang, et al. (2009). "Ablation of atrial fibrillation utilizing robotic catheter navigation in comparison to manual navigation and ablation: single-center experience." *J Cardiovasc Electrophysiol* 20(12): 1328-35.
- Duncan, E., N. Johns, et al. (2010) "Robotic Catheter Navigation within the Left Ventricle." *Pacing Clin Electrophysiol*.
- Earley MJ, Showkathali R, Alzetani M, et al. (2006) Radiofrequency ablation of arrhythmias guided by non-fluoroscopic catheter location: a prospective randomized trial. *Eur heart J* 27:1223-1229.
- Estner, H. L., G. Hessling, et al. (2008). "Electrogram-guided substrate ablation with or without pulmonary vein isolation in patients with persistent atrial fibrillation." *Europace* 10(11): 1281-7.
- Feinberg, W. M., J. L. Blackshear, et al. (1995). "Prevalence, age distribution, and gender of patients with atrial fibrillation. Analysis and implications." *Arch Intern Med* 155(5): 469-73.
- Gerstenfeld EP, Callans DJ, Dixit S, Russo AM, Nayak H, Lin D, Pulliam W, Siddique S, Marchlinski FE. Mechanisms of organized left atrial tachycardias occurring after pulmonary vein isolation. *Circulation*. 2004; 110:1351-1357.
- Gerstenfeld, E. P., S. Dixit, et al. (2002). "Utility of exit block for identifying electrical isolation of the pulmonary veins." *J Cardiovasc Electrophysiol* 13(10): 971-9.
- Gonska D-B, Cao K, Schaumann A, Dorszewski A, von zur Muhlen F, Kreuzer H. (1994) Catheter ablation of ventricular tachycardia in 136 patients with coronary artery disease: results and long-term follow-up. *J Am Coll Cardiol*;24:1506-1514.
- Haines, D. E., D. D. Watson, et al. (1990). "Electrode radius predicts lesion radius during radiofrequency energy heating. Validation of a proposed thermodynamic model." *Circ Res* 67(1): 124-9.

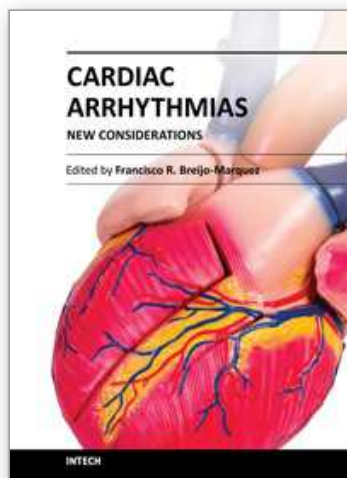
- Haïssaguerre M, Hocini M, Sanders P, Sacher F, Rotter M, Takahashi Y, Rostock T, Hsu LF, Bordachar P, Reuter S, Roudaut R, Clémenty J, Jaïs P. Catheter ablation of long-lasting persistent atrial fibrillation: clinical outcome and mechanisms of subsequent arrhythmias. *J Cardiovasc Electrophysiol*. 2005;16:1138-1147.
- Haïssaguerre, M., D. C. Shah, et al. (2000). "Electrophysiological breakthroughs from the left atrium to the pulmonary veins." *Circulation* 102(20): 2463-5.
- Haïssaguerre, M., P. Jaïs, et al. (1998). "Spontaneous initiation of atrial fibrillation by ectopic beats originating in the pulmonary veins." *N Engl J Med* 339(10): 659-66.
- Hocini, M., P. Jaïs, et al. (2005). "Techniques, evaluation, and consequences of linear block at the left atrial roof in paroxysmal atrial fibrillation: a prospective randomized study." *Circulation* 112(24): 3688-96.
- Hsu, L. F., P. Jaïs, et al. (2004). "Catheter ablation for atrial fibrillation in congestive heart failure." *N Engl J Med* 351(23): 2373-83.
- Huang SS, Wood MA. *Catheter Ablation of Cardiac Arrhythmias*. 1st Ed. 2006.
- Jaïs, P., M. Hocini, et al. (2004). "Technique and results of linear ablation at the mitral isthmus." *Circulation* 110(19): 2996-3002.
- Jalife, J., O. Berenfeld, et al. (2002). "Mother rotors and fibrillatory conduction: a mechanism of atrial fibrillation." *Cardiovasc Res* 54(2): 204-16.
- Kanagaratnam, P., M. Koa-Wing, et al. (2008). "Experience of robotic catheter ablation in humans using a novel remotely steerable catheter sheath." *J Interv Card Electrophysiol* 21(1): 19-26.
- Kannel, W. B., R. D. Abbott, et al. (1982). "Epidemiologic features of chronic atrial fibrillation: the Framingham study." *N Engl J Med* 306(17): 1018-22.
- Kim, R. J., E. Wu, et al. (2000). "The use of contrast-enhanced magnetic resonance imaging to identify reversible myocardial dysfunction." *N Engl J Med* 343(20): 1445-53.
- Kim, R. J., H. B. Hillenbrand, et al. (2000). "Evaluation of myocardial viability by MRI." *Herz* 25(4): 417-30.
- Kistler, P. M., K. Rajappan, et al. (2008). "The impact of image integration on catheter ablation of atrial fibrillation using electroanatomic mapping: a prospective randomized study." *Eur Heart J* 29(24): 3029-36.
- Koa-Wing, M., N. W. Linton, et al. (2009). "Robotic catheter ablation of ventricular tachycardia in a patient with congenital heart disease and Rastelli repair." *J Cardiovasc Electrophysiol* 20(10): 1163-6.
- Koa-Wing, M., P. Kojodjojo, et al. (2009). "Robotically assisted ablation produces more rapid and greater signal attenuation than manual ablation." *J Cardiovasc Electrophysiol* 20(12): 1398-404.
- Kosmidou, I., K. Inada, et al. (2011). "Role of repeat procedures for catheter ablation of postinfarction ventricular tachycardia." *Heart Rhythm* 8(10): 1516-22.
- Kuck KH, Cappato R, et al. (2000). Randomized comparison of antiarrhythmic drug therapy with implantable defibrillators in patients resuscitated from cardiac arrest: The cardiac arrest study Hamburg (CASH). *Circulation* 102:748-754.
- Lellouche, N., E. Buch, et al. (2007). "Functional characterization of atrial electrograms in sinus rhythm delineates sites of parasympathetic innervation in patients with paroxysmal atrial fibrillation." *J Am Coll Cardiol* 50(14): 1324-31.

- Lim, K. T., S. Matsuo, et al. (2007). "Catheter ablation of persistent and permanent atrial fibrillation: Bordeaux experience." *Expert Rev Cardiovasc Ther* 5(4): 655-62.
- Marchlinski FE, Callans DJ, Gottlieb CD, Zado E. (2000) Linear ablation lesions for control of unmappable ventricular tachycardia in patients with ischemic and nonischemic cardiomyopathy. *Circulation*. 101: 1288-1296
- Marchlinski, F. E. (2008). "Atrial fibrillation catheter ablation: learning by burning continues." *J Am Coll Cardiol* 51(10): 1011-3.
- Marrouche, N. F., D. O. Martin, et al. (2003). "Phased-array intracardiac echocardiography monitoring during pulmonary vein isolation in patients with atrial fibrillation: impact on outcome and complications." *Circulation* 107(21): 2710-6.
- Matsuo, S., K. T. Lim, et al. (2007). "Ablation of chronic atrial fibrillation." *Heart Rhythm* 4(11): 1461-3.
- McGann, C. J., E. G. Kholmovski, et al. (2008). "New magnetic resonance imaging-based method for defining the extent of left atrial wall injury after the ablation of atrial fibrillation." *J Am Coll Cardiol* 52(15): 1263-71.
- Mesas CE, Pappone C, Lang CC, Gugliotta F, Tomita T, Vicedomini G, Sala S, Paglino G, Gulletta S, Ferro A, Santinelli V. Left atrial tachycardia after circumferential pulmonary vein ablation for atrial fibrillation: electroanatomic characterization and treatment. *J Am Coll Cardiol*. 2004;44:1071-1079.
- Moss, A. J. et al. (2004). Long-term clinical course of patients after termination of ventricular tachyarrhythmia by an implanted defibrillator. *Circulation* 110: 3760-3765.
- Nademanee, K., M. C. Schwab, et al. (2008). "Clinical outcomes of catheter substrate ablation for high-risk patients with atrial fibrillation." *J Am Coll Cardiol* 51(8): 843-9.
- Natale, A., A. Raviele, et al. (2007). "Venice Chart international consensus document on atrial fibrillation ablation." *J Cardiovasc Electrophysiol* 18(5): 560-80.
- Oakes, R. S., T. J. Badger, et al. (2009). "Detection and quantification of left atrial structural remodeling with delayed-enhancement magnetic resonance imaging in patients with atrial fibrillation." *Circulation* 119(13): 1758-67.
- O'Neill, M. D., P. Jais, et al. (2007). "Catheter ablation for atrial fibrillation." *Circulation* 116(13): 1515-23.
- Ouyang, F., D. Bansch, et al. (2004). "Complete isolation of left atrium surrounding the pulmonary veins: new insights from the double-Lasso technique in paroxysmal atrial fibrillation." *Circulation* 110(15): 2090-6.
- Pappone, C., G. Oreto, et al. (1999). "Catheter ablation of paroxysmal atrial fibrillation using a 3D mapping system." *Circulation* 100(11): 1203-8.
- Pappone, C., S. Rosanio, et al. (2003). "Mortality, morbidity, and quality of life after circumferential pulmonary vein ablation for atrial fibrillation: outcomes from a controlled nonrandomized long-term study." *J Am Coll Cardiol* 42(2): 185-97.
- Pappone, C., V. Santinelli, et al. (2004). "Pulmonary vein denervation enhances long-term benefit after circumferential ablation for paroxysmal atrial fibrillation." *Circulation* 109(3): 327-34.
- Patel A, d'Avila A, Neuzil P, Kim S, Mela T, Singh J, Ruskin J, ReddyV. Atrial Tachycardia After Ablation of Persistent Atrial Fibrillation : Identification of the Critical Isthmus

- With a Combination of Multielectrode Activation Mapping and Targeted Entrainment Mapping. *Circ Arrhythm Electrophysiol* 2008;1;14-22.
- Perez-David E, Arenal Á, Rubio-Guivernau JL, et al. (2011) Noninvasive identification of ventricular tachycardia-related conducting channels using contrast-enhanced magnetic resonance imaging in patients with chronic myocardial infarction: comparison of signal intensity scar mapping and endocardial voltage mapping. *J Am Coll Cardiol*, 57:184 -94.
- Peters, D. C., J. V. Wylie, et al. (2007). "Detection of pulmonary vein and left atrial scar after catheter ablation with three-dimensional navigator-gated delayed enhancement MR imaging: initial experience." *Radiology* 243(3): 690-5.
- Poole, J. E. et al. (2008). Prognostic importance of defibrillator shocks in patients with heart failure. *N. Engl. J. Med* 359: 1009-1017
- Roes SD, Borleffs CJ, van der Geest RJ, et al. (2009) Infarct tissue heterogeneity assessed with contrast-enhanced MRI predicts spontaneous ventricular arrhythmia in patients with ischemic cardiomyopathy and implantable cardioverter-defibrillator. *Circ Cardiovasc Imaging*, 2:183-90.
- Sacher F, Roberts-Thomson K, Maury P et al. (2010) Epicardial ventricular tachycardia ablation. *J Am Coll Cardiol*, 55:2366-2372.
- Sacher F, Tedrow UB, et al. (2008). Ventricular tachycardia ablation: evolution of patients and procedures over 8 years. *Circ Arrhythmia Electrophysiol*. 1: 153-16
- Sahadevan, J., K. Ryu, et al. (2004). "Epicardial mapping of chronic atrial fibrillation in patients: preliminary observations." *Circulation* 110(21): 3293-9.
- Saliba, W., J. E. Cummings, et al. (2006). "Novel robotic catheter remote control system: feasibility and safety of transseptal puncture and endocardial catheter navigation." *J Cardiovasc Electrophysiol* 17(10): 1102-5.
- Sanders, P., P. Jais, et al. (2004). "Electrophysiologic and clinical consequences of linear catheter ablation to transect the anterior left atrium in patients with atrial fibrillation." *Heart Rhythm* 1(2): 176-84.
- Saraste, A., S. Nekolla, et al. (2008). "Contrast-enhanced magnetic resonance imaging in the assessment of myocardial infarction and viability." *J Nucl Cardiol* 15(1): 105-17.
- Scaglione, M., L. Biasco, et al. "Visualization of multiple catheters with electroanatomical mapping reduces X-ray exposure during atrial fibrillation ablation." *Europace* 13(7): 955-62.
- Schilling RJ, Peters N, Davies W. (1999) Mapping and ablation of ventricular tachycardia with the aid of a non-contact mapping system. *Heart*, 81:570-575.
- Schron, E. B. et al. (2002) Quality of life in the antiarrhythmics versus implantable defibrillators trial: impact of therapy and influence of adverse symptoms and defibrillator shocks. *Circulation* 105: 589-594.
- Shah DC, Jais P, Haissaguerre M, et al. (1997) Three-dimensional mapping of the common atrial flutter in the right atrium. *Circulation*, 96:3904-3912.
- Simonetti OP, Kim RJ, Fieno DS, et al. (2001) An improved MR imaging technique for the visualization of myocardial infarction. *Radiology*, 218:215-23.

- Spach MS, Miller WT, Miller-Jones E, Warren RB, Barr RC (1979): Extracellular potentials related to intracellular action potentials during impulse conduction in anisotropic canine cardiac muscle. *Circ Res.* 45:188-204
- Sporton, S. C., M. J. Earley, et al. (2004). "Electroanatomic versus fluoroscopic mapping for catheter ablation procedures: a prospective randomized study." *J Cardiovasc Electrophysiol* 15(3): 310-5.
- Steven, D., H. Servatius, et al. (2009). "Reduced Fluoroscopy During Atrial Fibrillation Ablation: Benefits of Robotic Guided Navigation." *J Cardiovasc Electrophysiol*.
- Stevenson W.G., Khan H., Sager P., Saxon L.A., Middlekauff H.R., Natterson P.D. & Wiener I. (1993) Identification of re-entry circuit sites during catheter mapping and radiofrequency ablation of ventricular tachycardia late after myocardial infarction. *Circulation*, 88: 1647-1670.
- Stevenson WG, Delacretaz E, Friedman PL, Ellison KE. (1998) Identification and ablation of macroreentrant ventricular tachycardia with the CARTO electroanatomic mapping system. *Pacing Clin Electrophysiol*, 21:1448-1456.
- Valles, E., R. Fan, et al. (2008). "Localization of atrial fibrillation triggers in patients undergoing pulmonary vein isolation: importance of the carina region." *J Am Coll Cardiol* 52(17): 1413-20.
- Willems, S., D. Steven, et al. (2010) "Persistence of Pulmonary Vein Isolation After Robotic Remote-Navigated Ablation for Atrial Fibrillation and its Relation to Clinical Outcome." *J Cardiovasc Electrophysiol*
- Willems, S., H. Klemm, et al. (2006). "Substrate modification combined with pulmonary vein isolation improves outcome of catheter ablation in patients with persistent atrial fibrillation: a prospective randomized comparison." *Eur Heart J* 27(23): 2871-8.
- Yokoyama, K., H. Nakagawa, et al. (2006). "Comparison of electrode cooling between internal and open irrigation in radiofrequency ablation lesion depth and incidence of thrombus and steam pop." *Circulation* 113(1): 11-9.

IntechOpen



Cardiac Arrhythmias - New Considerations

Edited by Prof. Francisco R. Breijo-Marquez

ISBN 978-953-51-0126-0

Hard cover, 534 pages

Publisher InTech

Published online 29, February, 2012

Published in print edition February, 2012

The most intimate mechanisms of cardiac arrhythmias are still quite unknown to scientists. Genetic studies on ionic alterations, the electrocardiographic features of cardiac rhythm and an arsenal of diagnostic tests have done more in the last five years than in all the history of cardiology. Similarly, therapy to prevent or cure such diseases is growing rapidly day by day. In this book the reader will be able to see with brighter light some of these intimate mechanisms of production, as well as cutting-edge therapies to date. Genetic studies, electrophysiological and electrocardiographic features, ion channel alterations, heart diseases still unknown, and even the relationship between the psychic sphere and the heart have been exposed in this book. It deserves to be read!

How to reference

In order to correctly reference this scholarly work, feel free to copy and paste the following:

Louisa Malcolm-Lawes, Shahnaz Jamil-Copley and Prapa Kanagaratnam (2012). Novel Technologies for Mapping and Ablation of Complex Arrhythmias, Cardiac Arrhythmias - New Considerations, Prof. Francisco R. Breijo-Marquez (Ed.), ISBN: 978-953-51-0126-0, InTech, Available from:
<http://www.intechopen.com/books/cardiac-arrhythmias-new-considerations/novel-techniques-for-mapping-and-ablation-of-complex-cardiac-arrhythmias>

INTECH
open science | open minds

InTech Europe

University Campus STeP Ri
Slavka Krautzeka 83/A
51000 Rijeka, Croatia
Phone: +385 (51) 770 447
Fax: +385 (51) 686 166
www.intechopen.com

InTech China

Unit 405, Office Block, Hotel Equatorial Shanghai
No.65, Yan An Road (West), Shanghai, 200040, China
中国上海市延安西路65号上海国际贵都大饭店办公楼405单元
Phone: +86-21-62489820
Fax: +86-21-62489821

© 2012 The Author(s). Licensee IntechOpen. This is an open access article distributed under the terms of the [Creative Commons Attribution 3.0 License](https://creativecommons.org/licenses/by/3.0/), which permits unrestricted use, distribution, and reproduction in any medium, provided the original work is properly cited.

IntechOpen

IntechOpen