

We are IntechOpen, the world's leading publisher of Open Access books Built by scientists, for scientists

6,900

Open access books available

186,000

International authors and editors

200M

Downloads

Our authors are among the

154

Countries delivered to

TOP 1%

most cited scientists

12.2%

Contributors from top 500 universities



WEB OF SCIENCE™

Selection of our books indexed in the Book Citation Index
in Web of Science™ Core Collection (BKCI)

Interested in publishing with us?
Contact book.department@intechopen.com

Numbers displayed above are based on latest data collected.
For more information visit www.intechopen.com



Femtosecond Laser-Assisted Astigmatism Correction

Duna Raoof-Daneshvar and Shahzad I. Mian
*University of Michigan, W.K. Kellogg Eye Center,
USA*

1. Introduction

Femtosecond lasers generate ultrashort pulses while utilizing minimal energy and inflicting trivial damage to surrounding tissues. The U.S. Food and Drug Administration (FDA) approved the IntraLase® femtosecond laser (Abbott Inc., Abbott Park, IL) for commercial use in 2000 for lamellar corneal surgery. Both the predictability and accuracy of femtosecond lasers have provided multiple applications of this unique laser in refractive surgery. In this chapter, we summarize the surgical techniques that have been developed for astigmatism correction utilizing the femtosecond laser. Novel methods that may be used to treat astigmatism include femtosecond laser-assisted keratotomy, limbal relaxing incisions, intracorneal ring segments, anterior lamellar keratoplasty, and excimer laser correction (laser in situ keratomileusis, or LASIK). (Table 1) The versatility and distinctive nature of the femtosecond laser have allowed its application in multiple avenues of corneal surgery and show promise in the treatment of astigmatism.

Surgical Techniques for Femtosecond Laser-Assisted Astigmatism Correction	
•	Astigmatic keratotomy
•	Limbal relaxing incisions
•	Intracorneal ring segments
•	Anterior lamellar keratoplasty
•	Excimer laser correction (LASIK)

Table 1. Surgical Techniques for Femtosecond Laser-Assisted Astigmatism Correction

2. Femtosecond laser history and principles

The earliest application of near-infrared (1053 nm) lasers in ophthalmology was with the focused neodymium-doped yttrium aluminum garnet (Nd:YAG) laser, which has a pulse duration in the nanosecond (10⁻⁹) range and produces photodisruption. Also known as photoionization, this process vaporizes small volumes of tissue with the formation of cavitation gas bubbles consisting of carbon dioxide and water, which ultimately dissipate

into the surrounding tissue (Juhasz et al., 1999). Since power is a function of energy per unit time, for a given energy, decreasing the time increases the power. By shortening the pulse duration of the near-infrared laser from the nanosecond to the femtosecond (10^{-15}) range, the zone of collateral tissue damage is significantly reduced. The femtosecond laser is similar to a Nd:YAG laser, but with an ultra-short pulse duration that is capable of producing smaller shock waves and cavitation bubbles (Stern, 1989). Thermal damage to neighboring tissue in the cornea has been measured to be in the order of $1\text{ }\mu\text{m}$ (Lubatschowski et al., 2000). Additionally, the near-infrared femtosecond laser can be focused anywhere within or behind the cornea and is also capable, to a certain extent, of passing through optically hazy media such as an edematous cornea.

The initial application of the femtosecond laser for corneal surgery was developed in the early 1990's in collaboration between the W.K. Kellogg Eye Center and the University of Michigan College of Engineering (Perry & Mourou, 1994). In 1997, The IntraLase® Corporation was founded which developed a femtosecond laser that scanned over the target tissue with a highly precise computer-operated optical delivery system (currently owned by Abbott Laboratories, Abbott Park, IL). This system was approved by the FDA in 2000 and the first commercial laser was introduced to the market in 2001 for creation of laser in situ keratomileusis (LASIK) flaps (Ratkay-Traub et al., 2001). The IntraLase® femtosecond laser system relies on a low-pressure (35 – 50 mm Hg) suction ring to align and stabilize the globe. A flat glass contact lens, which is attached to the laser delivery system, is then used to applanate the cornea within the suction ring. Laser pulses are delivered to make a lamellar corneal cut. The pattern then generates a circle at the edge of the lamellar plane that is successively moved anteriorly toward the applanation lens, making the flap edge. An internal shutter mechanism leaves a hinge of predetermined arc and location, but can be varied in advance by the surgeon (Sugar, 2007).

The femtosecond laser's unique technology has rapidly progressed since its inception. It was initially introduced as a 10-kHz laser, but the current widely-used IntraLase® system fires at a pulse rate of 60-kHz. In the new 150-kHz IntraLase® femtosecond system, with its high-precision computer control, the delivery system can create cuts of a wide variety of geometric depths, shapes, diameters, wound configurations, spot separation, and energy. There are multiple other commercially available femtosecond laser systems at the time of writing: Technolas Perfect Vision 520 FS (Technolas Perfect Vision, Munich, Germany), VisuMax Femtosecond System (Carl Zeiss Meditec, Jena, Germany), and Femto LDV (Ziemer Group, Port, Switzerland) (Table 2, Reggiani-Mello & Krueger, 2011).

3. Astigmatic keratotomy

In astigmatic keratotomy, incisions can be limbal, arcuate, or transverse and are traditionally performed free-hand or with a mechanical keratome (Poole and Ficker, 2006). Arcuate keratotomy has superior predictability and therefore remains the most popular procedure (Price et al, 2007). However, both free-hand and mechanized astigmatic keratotomy suffer from technical limitations including lack of precision and reproducibility of incision depth and length and presence of skip lesions. The instruments used for astigmatic keratotomy are front-cutting diamond blades and mechanized trephines, which can lead to corneal perforations, irregular astigmatism, undercorrections and worsening of the pre-existing astigmatism (Hoffart et al., 2009; Krachmer et al., 1980). Femtosecond laser technology offers the ability

Feature	Intralase IFS	Carl Zeiss Visumax	Technolas	Alcon Ultra Flap	Ziemer LDV
Pulse rate	150 KHz	500 KHz	80 KHz	200 KHz	>1 MHz
Pulse duration (fs)	>500	400	>500	350	200-300
Spot size (µm)	1-5	1	>1	5	<2
Pulse energy(nJ)	500-1300	<300	>500	300-1500	<100
Concept	Amplified	Amplified	Amplified	Amplified	Oscillator
Additional feature	Greatest number of treated eyes	Flex Smile	IntraCor	Low OBL formation	Portable, low energy
Suction	Manual	Computer-controlled low pressure	Manual	Manual	Computer-controlled within hand-piece
Laser-cornea coupling	Flat	Curved	Curved	Flat	Flat
Customizable features	High	Very high	High	High	Very limited

Table 2. Features of Current Femtosecond Laser Devices (Adapted from Reggiani-Mello and Krueger, 2011)

to control the desired shape, length, radius and depth of incisions in astigmatic keratotomy. Axial topographic maps are used to identify the steep meridians and a standardized nomogram is used to generate a surgical plan with paired incisions for each patient. Multiple studies have found femtosecond-assisted laser arcuate keratotomy to have enhanced predictability and a reduced rate of complications (Bahar et al., 2008; Hoffart et al., 2009).

3.1 Indications and surgical planning

This novel technique has been primarily described in treating high astigmatism following penetrating keratoplasty incisions (Buzzonetti et al., 2008; Harissi-Dagher & Azar, 2008; Kiraly et al., 2008; Kumar et al., 2010). Preoperative evaluation should include a comprehensive examination, manual keratometry, pachymetry, and corneal topography. Anterior segment optical coherence tomography (AS-OCT) may also be used to determine incision depth. Next, treatment parameters must be determined, which are comprised of incision depth, incision arc length, and optical zone diameter. Nomograms have been established to set these parameters, and vary with the amount of astigmatism and the age of the patient (Chu et al., 2005).

3.2 Surgical technique

In the United States, only the IntraLase® and Femto LDV® systems are enabled with software for astigmatic keratotomy at the time of writing (Wu, 2011). This procedure is performed under topical anesthesia. The limbus is initially marked with gentian violet to compensate for cyclotorsion. The patient is placed under the operating microscope and

prepared in a similar fashion for laser vision correction. An optical zone marker centered on the pupil is used to mark the zone diameter followed by an axis marker to indicate the planned locations of incisions. The corneal thickness at the optical zone along the planned incision sites is measured with the use of an ultrasound pachymeter. Alternatively, AS-OCT can be used in the preoperative surgical planning, applying the intended treatment diameter to the AS-OCT image and then the caliper tool to determine depth of suggested arcuate incision, at the planned location along the cornea.

After entering the treatment parameters, the suction ring is placed, followed by the applanation cone which is centered on the pupil. The treatment screen shows the locations of the incisions and the suction ring can be used to rotate the eye to ensure proper axis alignment. After the incisions are created and the suction ring and applanation cone are released, a Sinskey hook is immediately used to open the incisions. Postoperative care includes use of topical antibiotics and steroids for several weeks.

3.3 Outcomes

A growing number of studies have investigated femtosecond laser use in astigmatic keratotomy with promising results. The majority of these reports evaluated improvement in astigmatism following penetrating keratoplasty. In the United States, Harissi-Dagher and Azar were the first to report the outcome of femtosecond laser-assisted astigmatic keratotomy. In two patients, distance corrected visual acuity, DCVA, improved from 20/100 to 20/30 and from 20/200 to 20/60, and astigmatism was reduced by 3.6 D (from 8.5 to 4.9 D) and 2.7 D (from 7.0 to 4.3 D), respectively. The paired arcuate incisions were created just inside the graft-host junction within the corneal donor stroma. In this particular study, a depth of 400µm was the maximal allowed by the IntraLase® software which precluded deeper incisions (Harissi-Dagher & Azar, 2008). Concurrently in Germany, Kiraly et al. described the use of the femtosecond laser to perform arcuate incisions to correct high astigmatism in 10 post-keratoplasty patients. DCVA improved in 8 patients, the average corneal astigmatism was reduced by 3 diopters and the average refractive astigmatism by 4 D (Kiraly et al., 2008).

In an Italian study, Buzzonetti et al. used the IntraLase® system on 9 eyes in which paired 70° arc length incisions were performed at 80% of the corneal depth. Mean preoperative DCVA improved from 20/30 to 20/25, while the mean refractive astigmatism decreased by 6.00 D and the mean keratometric value decreased by 4.60 D (Buzzonetti et al., 2008). Kymionis et al. similarly reported a beneficial result in a patient with nonorthogonal post-keratoplasty astigmatism. Using the keratoplasty software on the IntraLase® 30-kHz system, two anterior arcuate incisions (60° arc length, from 180° to 240° and from 320° to 20°) were created at 75% depth of the thinnest measurement of the cornea. The patient's DCVA improved from 20/50 to 20/32 and manifest cylinder was reduced from 4.0 to 0.5 D. Improvement of topographic irregular astigmatism including surface regularity index and surface asymmetry index were noted as well (Kymoinnis et al., 2009). Using the 60-kHz IntraLase®, Kook et al. recently reported similar outcomes in 10 eyes. At 13 months, the mean uncorrected visual acuity and mean topometric astigmatism improved from (logMAR) 1.27 and 9.3 D, to (logMAR) 1.12 and 6.5 D, respectively (Kook et al., 2011).

In a large series of 37 post-keratoplasty eyes with greater than 5 D of regular astigmatism, Kumar et al. showed improvement of UCVA (logMAR 1.08 ± 0.34 to 0.80 ± 0.42), DCVA (logMAR 0.45 ± 0.27 to 0.37 ± 0.27), reduction of absolute cylindrical power (7.46 ± 2.70 to 4.77 ± 3.29), and reduction of the astigmatism vector ($2.52 \times 122^\circ \pm 5.4$ to $0.41 \times 126^\circ \pm 4.0$).

This study also showed that the refractive effect of astigmatic keratotomy stabilized at 3 months. For all cases, incision depth was 90% and incisions were placed at 0.5 mm within graft-host junction. Overcorrection was noted initially which led the authors to adjust the incision arc length: 40° to 60° for up to 6 D, 65° to 75° for 6 to 10 D, and 90° for >10 D of astigmatism (Kumar et al., 2010). Similarly, using the Technolas FS® laser system, which allows for deeper incision depth, Nubile et al. treated 12 post-keratoplasty eyes with incision depth of 90% and arc length of 40° to 80° within 1 mm of the graft-host junction. In addition to improved UCVA and DCVA, mean astigmatism was reduced from 7.16 ± 3.07 to 2.23 ± 1.55 D at one month (Nubile et al., 2009).

In a retrospective comparative case series, Bahar et al. compared the outcomes of IntraLase®-enabled astigmatic keratotomy and manual astigmatic keratotomy. Twenty eyes underwent manual astigmatic keratotomy using a diamond blade and 20 eyes underwent femtosecond laser assisted keratotomy. Both groups had improvement of UCVA and DCVA but only the femtosecond group achieved a statistically significant improvement. Compared with the manual technique, use of a femtosecond laser showed a trend towards greater improvement of visual acuity and defocus equivalent as well as greater reduction of absolute cylinder. Although manual keratotomy resulted in shift of astigmatism axis, the femtosecond laser brought the mean astigmatic vector closer to neutral (Bahar et al., 2008).

In the only known prospective randomized study at this time, Hoffart et al. compared the effectiveness of arcuate keratotomy with a femtosecond laser with incision depth set at 75% depth with mechanized astigmatic keratotomy using the Hanna® keratome (Moria, Doylestown, PA). Two groups of 20 eyes were randomly assigned to each method. Although no statistically significant differences were detected at six months, a wider spread of angle of error and an almost significant difference of mean absolute angle of error suggested a larger misalignment of treatment during mechanized astigmatic keratotomy (Hoffart et al., 2009).

Femtosecond laser assisted astigmatic keratotomy has also been shown to be effective in the management of astigmatism after descemet's stripping endothelial keratoplasty. In a case report, Levinger et al. showed absolute cylinder reduction from 5.75 to 2.75 D, improvement of UCVA from 20/300 to 20/60 and DCVA improvement from 20/100 to 20/40 (Levinger et al., 2009). In another case report, a patient with high astigmatism following Descemet's stripping automated endothelial keratoplasty (DSAEK) underwent femtosecond-assisted astigmatic keratotomy (Yoo et al., 2009). Six months after the procedure, the UCVA remained unchanged while the DCVA decreased from 20/40 to 20/50. The manifest refractive astigmatic error increased from $+5.25 \times 163$ to $+7.50 \times 80$ (surgically induced astigmatism was approximately 12.75 D with an overcorrection of about 7.50 D). This report showed that in post-DSAEK patients, adding the DSAEK donor corneal lenticule thickness in the preoperative peripheral corneal thickness measurements can result in full-thickness recipient corneal incisions and overcorrection.

Limited data exists demonstrating the use of femtosecond laser-assisted astigmatic keratotomy in reducing naturally occurring astigmatism. Abbey et al. reported a study in which this technique was performed on a patient with naturally occurring astigmatism of 5.25 D in both eyes. Treatment parameters were based on the modified Lindstrom nomogram for naturally occurring astigmatism and guided by the topographic cylinder axis. Significant improvement of UCVA (counting fingers to 20/50, 20/200 to 20/30) and reduction of manifest cylinder power (2.5 D, 3.0 D) were seen at one year (Abbey et al., 2009). Additional studies must be conducted to verify the efficacy of this technique in natural astigmatism, but the results presented thus far are promising.

3.4 Complications

Several complications have been noted in the published series specific to femtosecond laser-assisted astigmatic keratotomy (Table 3). In the study by Nubile et al., two intraoperative microperforations occurred in 1 of the 2 cuts. Both cases presented a slight intraoperative leak but required no specific action other than application of a bandage contact lens. They were self-sealing, and the anterior chambers were maintained with no postoperative sequelae. A mild, transient, inflammatory reaction adjacent to the keratotomies was observed in all patients and resolved within one week. There were no cases of immunologic rejection during the follow-up. The healing and clinical outcomes up to 6 months after surgery were uneventful in all cases (Nubile et al., 2009). In their study of 37 eyes, Kumar et al. reported that 8% of eyes experienced rejection, all of which resolved with topical steroids. Overcorrection occurred initially in 24% of eyes, which required resuturing of the astigmatic keratotomy incisions. After adjusting the treatment parameters in the subsequent eyes, overcorrection decreased to 11%. Two thirds of the eyes that experienced overcorrection were keratoconic, suggesting the ectatic eyes may be at increased risk for overcorrection (Kumar et al., 2010).

To date, there is one case report in the literature in which there was evidence of a large-thickness perforation immediately after femtosecond-assisted astigmatic keratotomy (Vaddavalli et al, 2011). The perforation was noted only after the incision was opened with a Sinskey hook with leakage of aqueous from the incision site. An air bubble was also noted in the anterior chamber before the incision was opened. Therefore, the surgeon must watch for air bubble in the anterior chamber which may indicate a full thickness perforation. In this report, the authors successfully treated the perforation with a bandage contact lens, topical steroids, and antibiotics. At 1 month, all incisions had healed well with no signs of infection. Careful peripheral pachymetric measurements can help avoid full-thickness incisions. Early recognition of full-thickness incision with air bubbles in the anterior chamber can help avoid separation of incision and leakage of aqueous. The adhesions in the femtosecond laser incisions help prevent leakage prior to mechanical separation.

Complications Associated with Femtosecond Laser-Assisted Astigmatic Keratotomy	
•	Microperforation
•	Full-thickness perforation
•	Inflammatory reaction
•	Graft rejection
•	Overcorrection
•	Undercorrection

Table 3. Complications Associated with Femtosecond Laser-Assisted Astigmatic Keratotomy

4. Limbal relaxing incisions

Limbal relaxing incisions have traditionally been used to correct low degree of astigmatism at the time of cataract surgery. They may be used to correct up to 3.5 D of astigmatism, flattening the steepest meridian of the cornea and eliminating a source of refractive error

(Nichamin, 2006). The results have been limited due to this technique's low predictability and reliability. For instance, an axis misalignment of just 5° results in a 17% reduction in effect (Nichamin, 2006). Inconsistencies in the results of manual limbal relaxing incisions are presumed to be related to imprecision in depth, axis, arc length, and optical zone. Theoretically, the improved accuracy afforded by the femtosecond laser could enhance the reliability of outcomes of laser limbal relaxing incisions. To date, no published studies have reported the use of femtosecond laser to create limbal relaxing incisions. The use of the femtosecond laser in cataract surgery will allow for more accurate placement and predictability of limbal relaxing incisions for astigmatism correction.

5. Intracorneal ring segments

Intracorneal ring segments (Intacs; Addition Technology, Des Plaines, IL or Keraring; Mediphacos, Belo Horizonte, Brazil) have been used for the correction of mild to moderate keratoconus and for correction of low myopia. Intacs are clear, thin, semicircular inserts made of polymethylmethacrylate (PMMA) that are implanted in the deep corneal stroma with the goal of modifying corneal curvature and subsequently generating refractive changes. They shorten the central arc length of the corneal surface which leads to flattening of the cornea. Traditionally, manual dissection is used to create the channels for the intracorneal ring segments. Femtosecond laser technology has been used to create channels for the intracorneal ring segments and has been shown to be comparable to manual dissection (Kouassi et al., 2011; Kubaloglu et al., 2010; Kubaloglu et al., 2011; Pinero et al., 2009; Rabinowitz et al. 2006). (Figure 1)

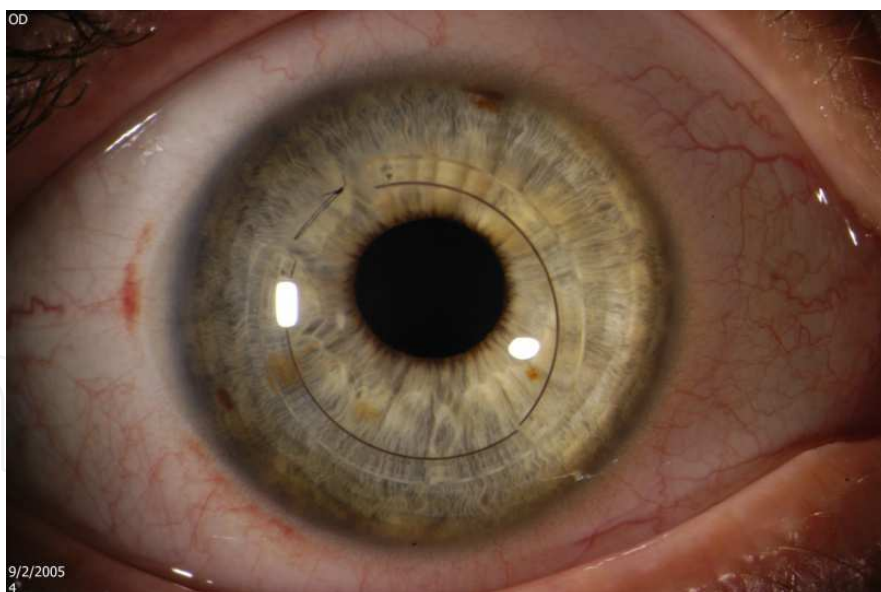


Fig. 1. Intracorneal ring segment implanted in a patient with keratoconus

5.1 Indications

Intracorneal ring segments are used in the management of astigmatism in multiple corneal ectatic disorders, such as keratoconus, and to reduce corneal steepening and refractive errors in pellucid marginal degeneration and post-LASIK ectasia. Intracorneal ring segments are an alternative option for visual rehabilitation for these patients and may delay or prevent the

need for corneal grafting. Additionally, they are useful for patients who exhibit contact lens intolerance and in whom spectacle correction does not provide optimal visual acuity.

5.2 Technique

This procedure is typically performed under topical anesthesia. First, the corneal thickness is measured by pachymetry at the area of implantation. The suction ring of the femtosecond laser system is then placed and centered. The glass lens is appanated to the cornea to fixate the eye and help maintain the precise distance from the laser head to the focal point. An entry cut with the femtosecond laser is created with the aim of allowing access for ring placement in the tunnel. The tunnel is then created at approximately 70–80% of the corneal thickness within 15 seconds. Subsequently, the ring segments are inserted in the created tunnels. To this date, there are no published studies comparing the visual and refractive outcomes for implanting intracorneal ring segments using these different locations (temporal versus relative to the astigmatism axis). Future studies must be done to clarify the role of the corneal incision in the outcomes obtained after intracorneal ring segment implantation.

5.3 Outcomes

In a retrospective case series, 118 eyes of 69 patients with keratoconus underwent Intacs implantation with the assistance of a femtosecond laser. In eyes with an inferior cone, a 0.45 mm Intacs insert was placed inferiorly to lift the cone and a 0.25 mm Intacs insert was placed superiorly to flatten the cornea and decrease baseline keratoconic asymmetric astigmatism. In eyes with central keratoconus, Intacs were inserted in the cornea according to the preoperative spherical equivalent in each eye. Intacs were inserted to 70% corneal depth and were successfully implanted in all eyes using a 15-kHz IntraLase femtosecond laser without intraoperative complications. At the end of the first postoperative year, 81.3% of eyes had improved UCVA and 73.7% had improved DCVA. The mean keratometry decreased from 51.6 D to 47.7 D, and the mean refractive spherical equivalent decreased from -7.6 D to -3.7 D (Ertan et al., 2006a). In a similar study, 9 eyes of 6 patients with pellucid marginal corneal degeneration had implantation of Intacs segments by a femtosecond laser technique. The UCVA improved from pre-operatively to 6 months after Intacs implantation: the mean difference was 3.5 ± 1.6 lines, which was statistically significant. The mean preoperative spherical refraction decreased from -3.86 ± 2.91 D to -2.77 ± 1.43 D and the mean cylindrical refraction from -2.41 ± 2.27 D to -0.94 ± 1.07 D (Ertan et al., 2006).

This group also has published a larger series with 306 keratoconic eyes (Ertan et al., 2008). All eyes underwent femtosecond laser assisted Intacs implantation with similar technique as discussed earlier. At a mean follow-up of 10.4 months, the DCVA improved in 71.6% of eyes and the UCVA improved in 75.7% of eyes. The mean keratometry significantly decreased from 50.7 D to 47.9 D and the mean manifest spherical refraction from -6.04 D to -3.09 D. The mean manifest cylindrical refraction reduced from -4.11 D to -3.82 D, although this was not statistically significant.

In another report, Cockunseven et al. showed similar promising results. Fifty eyes of 32 keratoconic patients had a statistically significant reduction in the spherical equivalent refractive error (mean of -5.62 ± 4.15 D to -2.49 ± 2.68 D) at 12 month follow-up. The UCVA before implantation was 20/40 or worse in 47 eyes, whereas at one year, 14 (28%) of 50 eyes had a UCVA of 20/40 or better. Thirty-nine eyes (68%) experienced a DCVA gain of one to four lines at one year (Coskunseven et al., 2008).

Studies have shown that creation of channels of intracorneal ring segments using femtosecond laser to be comparable to manual dissection. In a prospective randomized trial (Kubaloglu et al., 2010), 100 consecutive eyes with keratoconus were assigned to have tunnel creation with a mechanical device or a femtosecond laser. Kerarings with a 5.0 mm diameter and 160-degree arc length were implanted in all cases. At one year postoperatively, the UCVA improved by 2.4 lines in the mechanical group and 2.0 lines in the femtosecond group and the DCVA by 3.3 lines and 2.7 lines, respectively. There were no statistically significant differences between the 2 groups in visual or refractive results. Moreover, in a study by Rabinowitz et al. comparing the results of femtosecond laser (6-month results) and mechanical (12-month results) tunnel creation for Intacs implantation in 10 eyes, both groups showed significant reduction in average keratometry, spherical equivalent refraction, DCVA and UCVA. Statistical analysis, however, did not reveal any statistically significant differences between the two groups for any single parameter studied. Overall success, defined as contact lens or spectacles tolerance, was 85% in the laser group and 70% in the mechanical group (Rabinowitz et al. 2006). In another comparison by Kubaloglu et al., 96 eyes of 75 patients with keratoconus were retrospectively studied and their results showed that there was no statistically significant difference in any parameter between the group that underwent corneal tunnels with femtosecond laser (26 eyes) and those that underwent mechanical tunnel placement (70 eyes) (Kubaloglu et al., 2011). Additionally, in a retrospective study, Pinero et al. evaluated 146 eyes and demonstrated that intracorneal ring segments implantation using both mechanical and femtosecond laser-assisted procedures provide similar visual and refractive outcomes (Pinero, et al., 2009). Significant differences were found between the 2 groups for eyes implanted with Intacs for primary spherical aberration, coma, and other higher-order aberrations, favoring the femtosecond group ($P \leq 0.01$). Similarly, Kouassi et al. compared the two modalities using anterior segment optical coherence tomography in an observational prospective study. Their study demonstrated no statistical significant different in depth predictability (Kouassi, et al., 2011).

5.4 Complications

Intraoperative complications during intrastomal corneal ring segment implantation are rare. Reports have included segment decentration and inadequate tunnel depth. Ring segment extrusion, corneal neovascularization, mild deposits surrounding ring segments, and focal edema can also occur. In their study of 118 eyes undergoing Intacs placement with femtosecond laser, Ertan et al. found that 15.2% of eyes developed epithelial plugs at the incision site. During the first 6 months postoperatively, a few granulomatous particles were observed around the Intacs segments in 8.5% of eyes, which resolved with steroid drops (Ertan et al., 2006a). Segment extrusion occurred in 3 out of 306 eyes at 6 months postoperatively. Yellow particles around the segment, an epithelial plug at the incision site, and corneal haze around the segment were common observations during follow-up (Ertan et al., 2008).

In the largest survey to date, Coskunseven et al. conducted a retrospective chart review of 531 patients (850 eyes) who underwent Keraring (Mediphacos, Brazil) insertion. Intraoperatively, there were 22 (2.7%) cases of incomplete channel formation. Intraoperative complications included endothelial perforation (0.6%), and incorrect entry of the channel (0.2%). Postoperatively, there were 11 (1.3%) cases of segment migration, two (0.2%) cases of corneal melting and one (0.1%) case of mild infection. The overall complication rate was 5.7% (49 cases out of 850 eyes). To avoid the incidence of endothelial perforation, the authors suggested accurate pachymetry in a 5-mm optical zone at the implantation site. The

reference point is set as the point of thinnest pachymetry at the channel locations. Endothelial perforation can be prevented by stopping channel creation as soon as the complication is recognized before the incision (Coskunseven et al., 2011).

In an investigation to analyze the deviation of Intacs implanted in 59 eyes from the pupillary center, Ertan et al. found that the mean horizontal deviation was $788.33\mu\text{m} \pm 500.34$ with temporal displacement in all eyes. The mean vertical deviation was $370.83 \pm 313.17\mu\text{m}$ and there was an inferior displacement in 28.81% of eyes and superior displacement in 66.10% of eyes. This study showed that during applanation for Intacs by a femtosecond laser, the cornea and pupil are not in their natural position, which leads to decentration and misalignment of the segments. Therefore, the authors suggested marking the pupillary center on the natural corneal position before the applanation and making the arrangement according to this reference point to prevent decentration in channel creation with the femtosecond laser (Ertan et al., 2007).

6. Anterior lamellar keratoplasty

Lamellar keratoplasty may be necessary for correction of irregular astigmatism especially in the setting of keratoconus or post LASIK ectasia. Anterior lamellar keratoplasty is a partial-thickness corneal transplantation used in eyes with pathology limited to the anterior layers. Advantages of anterior lamellar keratoplasty include less invasive surgery as well as reduced risk of rejection. The major limitations with this procedure are the technical challenges of performing manual dissections and the resulting stromal interface irregularities between the donor and recipient interface. These complications may result in induced irregular astigmatism and loss of best-corrected visual acuity. Recent surgical advancements have led to renewed interest in anterior lamellar keratoplasty for appropriate corneal pathology. The femtosecond laser with its ability to perform precise, preprogrammed corneal dissections at a variety of depths and orientations has been a significant tool in the advancement of new lamellar keratoplasty techniques.

6.1 Indications

Astigmatism resulting from superficial corneal scars, after trauma, keratitis or corneal epithelial or anterior stromal dystrophies is the major indication for anterior lamellar keratoplasty.

6.2 Technique

The procedure may be performed under topical anesthesia. To create the donor graft, corneoscleral donor tissue is first mounted on an artificial anterior chamber. A donor graft is created using a 30-kHz IntraLase system with the following settings: donor lenticule thickness, 160 to 270 μm (thickness of the lenticule adjusted in relation to depth of the lesions according to the anterior segment OCT findings); donor lenticule diameter, 7.5 to 8.2 mm, spiral method; 1.9 to 2.9 microjoules spiral energy; 2.3 to 3.0 microjoules side cut energy; 360° side cut, 70° to 80° side cut angle; tangential spot separation, 11 to 12; and radial spot separation, 9 to 11 (Yoo et al., 2008). Depending on the donor tissue quality and edema, up to 20% additional thickness may be added to the donor lenticule to adjust for donor tissue swelling. The range of energy should be adjusted according to the severity of the corneal scar, with higher spiral energy and lower tangent and radial spot separation for denser scars.

A recipient corneal lenticule is next created using similar femtosecond laser settings except that the recipient corneal lenticule is set to be 0.1 mm smaller in diameter than the donor

graft diameter. The host corneal button is then removed and replaced with the donor lenticule on the recipient residual corneal stromal bed. The keratectomy incision should be dried with methylcellulose sponges. After approximately 5 minutes (to dehydrate the cornea and improve adhesion), the flap is checked for adhesion by depressing the peripheral host cornea and ensuring that the resulting indentation radiated into the lenticule (similar to checking for flap adhesion after LASIK with the striae test). A bandage contact lens is fitted over the cornea. Patients are then placed on a topical antibiotic and steroid for one week, and steroid drops should be slowly tapered over several months.

6.3 Outcomes

Yoo et al. first described this technique, performed at the Bascom Palmer Eye Institute in 12 eyes. In this study, AS-OCT was used in order to estimate the depth of scar tissue in the recipient cornea. The donor lenticule thickness was adjusted based on the depth of the lesion obtained from the AS-OCT measurements. At 12 months, the mean UCVA was improved in 7 (58.3%) compared with preoperative levels. The DCVA was unchanged or improved in all eyes when compared with the preoperative levels. Preoperatively, DCVA was 20/50 or worse in all eyes (range, HM-20/50), whereas at the last follow-up examination 10 (83%) of 12 eyes had DCVA of 20/50 or better (range, 20/80-20/25). The mean difference between preoperative and postoperative DCVAs was a gain of 3.8 lines (range, unchanged-8 lines). In all patients, both UCVA and DCVA stabilized between 1- and 6-month follow-up examinations. Therefore, the sutureless procedure resulted in the absence of irregular astigmatism and faster visual rehabilitation (Yoo et al., 2008).

To date, the longest term results of femtosecond assisted anterior lamellar keratoplasty in the literature were presented by Shousha and colleagues. Thirteen consecutive patients with anterior corneal pathologies were evaluated over a mean of 31 months post-operatively. The DCVA was significantly improved over preoperative values at the 12-, 18-, 24-, and 36-month visits. DCVA greater than 20/30 was achieved in 54% of patients at the 12-month visit when all 13 patients were available for follow-up, in 50% and 33% of patients at the 18- and 24-month visits, respectively, when 12 patients were available, and in 60% and 50% of patients at the 36- and 48-month visits when 5 and 2 patients were available, respectively. The BSCVA of the eye that completed the 60- and 70-month visits was 20/50. Patients achieved a mean gain of 5 lines of BSCVA at the 6-, 12-, 18-, and 24-month visits, 4 lines at the 36-month visit, 5 lines at the 48-month visit, and 6 lines at the 60- and 72-month visits. At a mean of five weeks postoperatively, 83.3% of patients achieved DCVA within 2 lines of that recorded at the 24-month visit. At the 12-month visit, mean spherical equivalent and refractive astigmatism were -0.4 diopters and 2.2 diopters, respectively, with no significant shift from preoperative values or values recorded in different follow-up visits (Shousha et al., 2011). Additional studies must be performed in order to determine treatment of astigmatism with anterior lamellar keratoplasty.

6.4 Complications

In the case series described above by Yoo et al., two eyes developed postoperative complications requiring additional surgery. In one eye, there was residual corneal scarring requiring phototherapeutic keratectomy (PTK; 40 µm deep) 10 months after femtosecond laser assisted anterior keratoplasty. The second procedure was performed due to anisometropia using hyperopic photorefractive keratectomy (PRK) over the graft (with

attempted correction +1.00+3.00×26) 4 months after femtosecond anterior lamellar keratoplasty. Haze formation was noted during the first three postoperative months and resolved in the following 9 months. Six patients developed dry eye signs and symptoms. All patients were treated with artificial tears and punctal occlusion. An improvement in dryness was found in these patients during the next 3 to 12 month follow-up. No graft rejection, infection, or epithelial ingrowth were noted in this series of patients (Yoo et al., 2008).

Similarly, in the study conducted by Shousha et al, residual corneal scar tissue was noted in 6 of the 11 eyes, despite the fact that PTK was performed intraoperatively on 3 of them. Despite the incomplete removal of scar tissue, those cases gained an average of 6.5 lines of BSCVA at the 6-month visit compared with preoperative BSCVA. Residual deposits were also noted in the 2 eyes. One eye developed an epithelial ingrowth in the interface 4 months postoperatively. Mild interface haze was noted in 3 eyes. One case had a thinned, steep cornea that was noted in the immediate postoperative period. Sequential manifest refraction and topography in the follow-up period showed progressive steepening of the cornea and an increase in refractive and topographic astigmatism, suggesting an ongoing ectatic process. At the last follow-up visit, the average keratometric reading was 50.7 D with 7 D of topographic cylinder. No rejection, failure, or infection was found in this case series, and all cases retained clarity of their grafts to the end of their follow-up period (Shousha et al., 2011).

7. Excimer laser correction

LASIK is a lamellar laser refractive surgery in which excimer laser ablation is done under a partial-thickness lamellar corneal flap. Astigmatism can be managed with excimer laser correction, where the excimer laser is used to reshape the surface of the cornea by removing anterior stromal tissue. A microkeratome was previously used to create a corneal flap with a shift over the last decade to femtosecond laser. The microkeratome used an oscillating blade to cut the flap after immobilization of the cornea with a suction ring. Microkeratomes from several companies cut the lamellar flaps with either superior or nasal hinges, and can cut to depths of 100–200 μm .

Several effective options for laser refractive surgery are available to treat varying degrees of astigmatism. The choices can broadly be divided into lamellar (LASIK) and surface (photorefractive keratectomy, laser epithelial keratomileusis [LASEK], and Epi-LASIK) ablation. Here, we describe the surgical technique for LASIK.

7.1 Indications and surgical planning

The preoperative assessment must include history of stable refraction, refraction, keratotomy, pachymetry, tear production, and complete eye examination.

7.2 Technique

First, the disposable applanation lens attached to the laser aperture is docked into the suction ring centered on the pupil. The suction ring is then locked into the applanation lens. The femtosecond laser is pre-programmed for each procedure with a planned flap diameter, flap thickness, hinge angle, raster energy, and side-cut energy. The flap is then created using a raster pattern, moving back and forth across the diameter of the flap. Initially, a pocket is created to allow the carbon dioxide and water gas bubbles to escape during photodisruption

in order to minimize the opaque bubble layer. The suction is released, and the appplanation lens and suction ring complex are lifted off the patient's eye.

Next, the patient is positioned at the excimer laser. After the eyelid skin is cleaned and draping is placed using a sterile technique, the flap edge is marked with a 2.0 mm diameter radial keratotomy optical zone marker dipped in gentian violet. A Sinsky hook is used to enter the lamellar interface adjacent to the hinge to allow a blunt spatula to be inserted in the lamellar plane and moved gently back and forth to break residual adhesions to lift the flap. The excimer laser is used to perform the stromal ablation. The flap is subsequently repositioned. Topical steroid and antibiotic are placed in the eye and tapered over the next few weeks.

7.3 Outcomes

LASIK has been successfully used to correct low to moderate astigmatism. In a report by the American Academy of Ophthalmology (Sugar et al., 2001), 160 articles were reviewed by a panel of experts with an objective to describe LASIK for myopia and astigmatism and examine the evidence to evaluate the procedure's efficacy and safety. LASIK was found to be effective and predictable in terms of obtaining very good to excellent uncorrected visual acuity for eyes treated with mild to moderate astigmatism (<2.0 diopters). Arbelaez et al. evaluated the postoperative clinical outcomes in eyes with astigmatism greater than 2.0 diopters that underwent LASIK using a femtosecond laser. At 6 months, 84% of the 50 eyes evaluated achieved 20/20 or better uncorrected distance visual acuity (UDVA) and 40% achieved 20/16 or better UDVA. Forty-four percent of eyes were within ± 0.25 diopters of the attempted astigmatic correction, and 78% were within ± 0.50 diopters (Arbelaez et al., 2009).

There is a wide collection of published studies that have compared the use of femtosecond laser and mechanical microkeratome in corneal flap creation. In one of the earliest comparative studies that investigated results obtained with the femtosecond laser versus those seen with a mechanical microkeratome (Hansatome Microkeratome; Bausch & Lomb, Rochester, New York and the Carriazzo-Barraquer Microkeratome; Moira, Anthony, France), Stonecipher and Kezirian found that there was better flap thickness predictability, fewer complications and less surgically induced astigmatism in the femtosecond laser eyes (Stonecipher and Kezirian, 2004). Tran et al. conducted a prospective, randomized clinical study, which compared induced aberrations following flap creation with the femtosecond laser and the Hansatome Microkeratome. Their results showed that the simple act of flap creation can change lower and higher-order aberrations and that there was a significant increase in higher-order aberrations seen in the microkeratome eyes but not in the femtosecond laser eyes (Tran et al., 2005). Additionally, in another prospective, contralateral eye study comparing the femtosecond laser and a blade microkeratome, the uncorrected visual acuity and manifest refractive outcomes were better in the femtosecond laser eyes (Durrie and Kezirian, 2005). Of note, the IntraLase Corporation supported the above three studies either directly or through providing financial compensation to the study's authors.

In a recent study that evaluated the thickness and side-cut angle of LASIK flaps using Fourier-domain optical coherence tomography (OCT), flap creation for bilateral LASIK was performed using an IntraLase, VisuMax, or Femto LDV femtosecond laser or a microkeratome. The study found that flap morphology differed according to the system used and the 3 femtosecond laser systems appeared to be superior to the microkeratome system (Ahn et al., 2011).

Alternatively, multiple reports have demonstrated no significant difference in visual acuity and corneal aberrations between LASIK with femtosecond laser compared with mechanical microkeratome (Calvo et al., 2010; Patel et al., 2007; Chan et al., 2008). In a randomized, controlled, paired-eye study, Patel et al. evaluated 21 patients (42 eyes) that received LASIK for myopia or myopic astigmatism to compare corneal high-order aberrations and visual acuity after LASIK with the flap created by a femtosecond laser to LASIK with the flap created by a mechanical microkeratome. Results showed no difference between the two groups in terms of high-contrast visual acuity, contrast sensitivity, and forward light scatter at 6 months after LASIK (Patel et al., 2007). In a similar prospective, randomized, paired-eye study, Calvo et al. showed the planar configuration of the femtosecond laser flap did not offer any advantage in corneal high-order aberrations or visual acuity through 3 years after LASIK (Calvo et al., 2010).

Most recently, a meta-analysis of seven prospective randomized controlled trials describes a total of 577 eyes with the goal of comparing femtosecond and microkeratome LASIK for myopia (Zhang et al., 2011). At 6 months or more of follow-up, no significant differences were found in the efficacy, accuracy, or safety of the two modalities. In eyes that had undergone femtosecond LASIK, however, the postoperative total aberrations and spherical aberrations were significantly lower. In a larger meta-analysis describing a total of 3,679 eyes, Chen et al. also found no significant differences between the two modalities in regards to visual acuity, final refractive error and astigmatism, or changes in higher order aberrations (Chen et al., 2012). Eyes in which femtosecond laser was utilized in flap creation, on the other hand, had significantly more predictable flap thickness than eyes in which the microkeratome was used. Although these two meta-analyses did not specifically investigate flap creation in astigmatism treatment, they both demonstrated that the use of femtosecond laser was not superior in regards to safety and efficacy when compared to the microkeratome, but it did have the potential advantage of increased predictability and reduced higher order aberrations.

7.4 Complications

In a study that aimed to describe complications associated with femtosecond laser-assisted flap creation in LASIK surgery, Haft et al. retrospectively evaluated 4772 eyes that underwent LASIK with the IntraLase femtosecond laser. All flaps were made with the 15- and 30-kHz IntraLase femtosecond laser. Forty-four (0.92%) eyes had direct or indirect complications due to flap creation. Thirty-two eyes had indirect complications (diffuse lamellar keratitis (DLK) and transient light sensitivity), 20 (0.42%) eyes developed DLK and 12 (0.25%) eyes had transient light sensitivity syndrome. Twelve (0.25%) eyes had direct femtosecond laser flap-related complications, 8 (0.17%) eyes had premature breakthrough of gas through the epithelium within the flap margins, 3 (0.06%) eyes had incomplete flaps due to suction loss, and 1 (0.02%) eye had irregular flap due to previous corneal scar. In summary, less than 1% of eyes had direct or indirect complications due to femtosecond laser flap creation, and LASIK complications specifically related to the IntraLase femtosecond laser did not cause loss of best spectacle-corrected visual acuity in any eyes (Haft et al., 2009).

In a prospective randomized contralateral eye study, Mian et al. investigated whether corneal sensation and dry-eye signs and symptoms after LASIK with a femtosecond laser are affected by varying hinge position, hinge angle, or flap thickness. Superior and temporal

hinge positions, 45-degree and 90-degree hinge angles, and 100 μm and 130 μm corneal flap thicknesses were compared. The study evaluated 190 consecutive eyes (95 patients). Corneal sensation was reduced at all postoperative visits, with improvement over 12 months. There was no difference in corneal sensation between the different hinge positions, angles, or flap thicknesses at any time point. This study also showed that dry-eye syndrome after LASIK with a femtosecond laser was mild and improved after 3 months (Mian et al., 2009).

8. Summary

Indications and techniques for femtosecond laser use for correction of astigmatism are evolving. The functionality of the femtosecond laser as a blade in the cornea has helped improve precision and safety of existing procedures to correct astigmatism. Future clinical trials will further establish the clinical efficacy and optimal technique for use of femtosecond lasers for correction of astigmatism. Although the cost of this technology currently has limited wide-scale use, adaptation of femtosecond lasers for cataract surgery may allow availability and reduction in expenses.


9. References

- Abbey, A., Ide, T., Kymionis, G. D., & Yoo, S. H. (2009). Femtosecond laser-assisted astigmatic keratotomy in naturally occurring high astigmatism. *British Journal of Ophthalmology*, 93(12), 1566.
- Ahn, H., Kim, J., Kim, C. K., Han, G. H., Seo, K. Y., Kim, E. K., et al. (2011). Comparison of laser in situ keratomileusis flaps created by 3 femtosecond lasers and a microkeratome. *Journal of Cataract and Refractive Surgery*, 37(2), 349.
- Arbelaez, M. C., Vidal, C., & Arba-Mosquera, S. (2009). Excimer laser correction of moderate to high astigmatism with a non-wavefront-guided aberration-free ablation profile: Six-month results. *Journal of Cataract and Refractive Surgery*, 35(10), 1789.
- Bahar, I., Levinger, E., Kaiserman, I., Sansanayudh, W., & Rootman, D. (2008). IntraLase-enabled astigmatic keratotomy for postkeratoplasty astigmatism. *American Journal of Ophthalmology*, 146(6), 897.
- Buzzonetti, L., Petrocelli, G., Laborante, A., Mazzilli, E., Gaspari, M., & Valente, P. (2009). Arcuate keratotomy for high postoperative keratoplasty astigmatism performed with the intralase femtosecond laser. *Journal of Refractive Surgery*, 25(8), 709-714.
- Calvo, R., McLaren, J. W., Hodge, D. O., Bourne, W. M., & Patel, S. V. (2010). Corneal aberrations and visual acuity after laser in situ keratomileusis: Femtosecond laser versus mechanical microkeratome. *American Journal of Ophthalmology*, 149(5), 785-793.
- Chan, A., Ou, J., & Manche, E. E. (2008). Comparison of the femtosecond laser and mechanical keratome for laser in situ keratomileusis. *Archives of Ophthalmology*, 126(11), 1484.
- Chen, S., Feng, Y., Stonjanovic, A., Jankov, MR., Wange, Q. (2012). IntraLase femtosecond laser vs mechanical microkeratome in LASIK for myopia: a systematic review and meta-analysis. *Journal of Refractive Surgery*. 28(1)15.
- Chu YR, Hardten DR & Lindquist TD. (2005). *Astigmatic Keratotomy*. Duane's Ophthalmology. Philadelphia: Lippincott Williams & Wilkins.
- Cosckunseven, E., Kymoinis, G., Tskilis, N., Atun, S., Arlan, E., Jankov, M., et al. (2008). One-year results of intrastromal corneal ring segment implantation (KeraRing)

- using femtosecond laser in patients with keratoconus. *American Journal of Ophthalmology*, 145(5), 775.
- Coskunseven, E., Kymionis, G. D., Tsiklis, N. S., Atun, S., Arslan, E., Siganos, C. S., et al. (2011). Complications of intrastromal corneal ring segment implantation using a femtosecond laser for channel creation: A survey of 850 eyes with keratoconus. *Acta Ophthalmologica*, 89(1), 54.
- Durrie, D. S., & Kezirian, G. M. (2005). Femtosecond laser versus mechanical keratome flaps in wavefront-guided laser in situ keratomileusis: Prospective contralateral eye study. *Journal of Cataract and Refractive Surgery*, 31(1), 120.
- Ertan, A., Kamburoglu, G., & Bahadir, M. (2006). Intacs insertion with the femtosecond laser for the management of keratoconus: One-year results. *Journal of Cataract and Refractive Surgery*, 32(12), 2039.
- Ertan, A., & Bahadir, M. (2006). Intrastromal ring segment insertion using a femtosecond laser to correct pellucid marginal corneal degeneration. *Journal of Cataract and Refractive Surgery*, 32(10), 1710-1716.
- Ertan, A., & Kamburoglu, G. (2007). Analysis of centration of intacs segments implanted with a femtosecond laser. *Journal of Cataract and Refractive Surgery*, 33(3), 484-487.
- Ertan, A., & Kamburoglu, G. (2008). Intacs implantation using a femtosecond laser for management of keratoconus: Comparison of 306 cases in different stages. *Journal of Cataract and Refractive Surgery*, 34(9), 1521-1526.
- Haft, P., Yoo, S., Kymionis, G., Ide, T., O'Brien, T., & Culbertson, W. (2009). Complications of LASIK flaps made by the IntraLase 15- and 30-kHz femtosecond lasers. *Journal of Refractive Surgery*, 25(11), 979-984.
- Harissi-Dagher, M., & Azar, D. T. (2008). Femtosecond laser astigmatic keratotomy for postkeratoplasty astigmatism. *Canadian Journal of Ophthalmology*. *Journal Canadien d'Ophtalmologie*, 43(3), 367-369.
- Hoffart L., Touzeau O., Borderie V., et al. (2007). Mechanized astigmatic arcuate keratotomy with the Hanna arcitome for astigmatism after keratoplasty. *J Cataract Refract Surg.*, 33:862-868.
- Hoffart, L., Proust, H., Matonti, F., Conrath, J., & Ridings, B. (2009). Correction of postkeratoplasty astigmatism by femtosecond laser compared with mechanized astigmatic keratotomy. *American Journal of Ophthalmology*, 147(5), 779.
- Juhasz, T., Loesel, F. H., Kurtz, R. M., Horvath, C., Bille, J. F., & Mourou, G. (1999). Corneal refractive surgery with femtosecond lasers. *IEEE Journal of Selected Topics in Quantum Electronics*, 5(4), 902.
- Karabatsas C.H., Cook S.D., Figueiredo F.C., et al. (1998). Surgical control of late postkeratoplasty astigmatism with or without the use of computerized video keratography: a prospective, randomized study. *Ophthalmology*, 105:1999-2006.
- Kezirian, G. M., & Stonecipher, K. G. (2004). Comparison of the IntraLase femtosecond laser and mechanical keratomes for laser in situ keratomileusis. *Journal of Cataract and Refractive Surgery*, 30(4), 804-811.
- Kiraly, L., Herrmann, C., Amm, M., & Duncker, G. (2008). Reduction of astigmatism by arcuate incisions using the femtosecond laser after corneal transplantation. 225(1), 70.
- Kook, D., Bhren, J., Klaproth, O. K., Bauch, A. S., Derhartunian, V., & Kohnen, T. (2011). [Astigmatic keratotomy with the femtosecond laser : Correction of high astigmatisms after keratoplasty.]. *Der Ophthalmologe*, 108(2), 143-150.

- Kouassi, F.X., Buestel, C., Raman, B., Melinte, D., Touboul, D., et al. Comparison of the depth predictability of intracorneal ring segment implantation by mechanical versus femtosecond laser-assisted techniques using optical coherence tomography (2011). *French Journal of Ophthalmology*. 0181-5512.
- Krachmer J.H., Fenzl R.E.(1980). Surgical correction of high postkeratoplasty astigmatism: relaxing incisions versus wedge resection. *Arch Ophthalmol.*, 98:1400-1402.
- Kubaloglu, A., Coskun, E., Sari, E. S., Gunes, A. S., Cinar, Y., Pinero, D. P., et al. (2011). Comparison of astigmatic keratotomy results in deep anterior lamellar keratoplasty and penetrating keratoplasty in keratoconus. *American Journal of Ophthalmology*, 151(4), 637-643.e1.
- Kubaloglu, A., Sari, E. S., Cinar, Y., Cingu, K., Koytak, A., Coskun, E., et al. (2010). Comparison of mechanical and femtosecond laser tunnel creation for intrastromal corneal ring segment implantation in keratoconus: Prospective randomized clinical trial. *Journal of Cataract and Refractive Surgery*, 36(9), 1556-1561.
- Kumar, N. L., Kaiserman, I., Shehadeh-Mashor, R., Sansanayudh, W., Ritenour, R., & Rootman, D. S. (2010). IntraLase-enabled astigmatic keratotomy for post-keratoplasty astigmatism: On-axis vector analysis. *Ophthalmology*, 117(6), 1228.
- Kymoinis, G., Yoo, S., Ide, T., & Culbertson, W. (2009). Femtosecond-assisted astigmatic keratotomy for post-keratoplasty irregular astigmatism. *Journal of Cataract and Refractive Surgery*, 35(1), 11.
- Levinger, E., Bahar, I., & Rootman, D. S. (2009). IntraLase-enabled astigmatic keratotomy for correction of astigmatism after descemet stripping automated endothelial keratoplasty: A case report. *Cornea*, 28(9), 1074.
- Lubatschowski, H., Maatz, G., Heisterkamp, A., Hetzel, U., Drommer, W., Welling, H., et al. (2000). Application of ultrashort laser pulses for intrastromal refractive surgery. *Graefe's Archive for Clinical and Experimental Ophthalmology*, 238(1), 33.
- Meltendorf, C., Burbach, G. J., Buhren, J., Bug, R., Ohrloff, C., & Deller, T. (2007). Corneal femtosecond laser keratotomy results in isolated stromal injury and favorable wound-healing response. *Investigative Ophthalmology Visual Science*, 48(5), 2068.
- Mian, S. I., Li, A. Y., Dutta, S., Musch, D. C., & Shtein, R. M. (2009). Dry eyes and corneal sensation after laser in situ keratomileusis with femtosecond laser flap creation:: Effect of hinge position, hinge angle, and flap thickness. *Journal of Cataract and Refractive Surgery*, 35(12), 2092.
- Nichamin, L. D. (2006). Nomogram for limbal relaxing incisions. *Journal of Cataract and Refractive Surgery*, 32(9), 1408.
- Nubile, M., Carpineto, P., Lanzini, M., Calienno, R., Agnifili, L., Ciancaglini, M., et al. (2009). Femtosecond laser arcuate keratotomy for the correction of high astigmatism after keratoplasty. *Ophthalmology*, 116(6), 1083.
- Patel, S. V., Maguire, L. J., McLaren, J. W., Hodge, D. O., & Bourne, W. M. (2007). Femtosecond laser versus mechanical microkeratome for LASIK: A randomized controlled study. *Ophthalmology*, 114(8), 1482.
- Perry, M. D., & Mourou, G. (1994). Terawatt to petawatt subpicosecond lasers. *Science*, 264(5161), 917.
- Pinero, D., Alio, J., El Kadry, B., Coskunseven, E., Morbelli, H., et al. (2009). Refractive and aberrometric outcomes of intracorneal ring segments for keratoconus: mechanical versus femtosecond-assisted procedures. *Ophthalmology*, 116(9), 1675. Poole T.R.

- & Ficker L.A. (2006). Astigmatic keratotomy for post-keratoplasty astigmatism. *J Cataract Refract Surg.*;32:1175–1179.
- Price F.W. Jr, Grene R.B., Marks R.G., et al. (1996). Arcuate transverse keratotomy for astigmatism followed by subsequent radial or transverse keratotomy: ARC-T Study Group. *Astigmatism Reduction Clinical Trial. J Refract Surg.*, 12:68–76.
- Rabinowitz, Y., Li, X., Ignacio, T., & Maguen, E. (2006). INTACS inserts using the femtosecond laser compared to the mechanical spreader in the treatment of keratoconus. *Journal of Refractive Surgery*, 22(8), 764–771.
- Ratkay-Traub, I., Juhasz, T., Horvath, C., Suarez, C., Kiss, K., Ferincz, I., et al. (2001). Ultra-short pulse (femtosecond) laser surgery: Initial use in LASIK flap creation. *Ophthalmology Clinics of North America*, 14(2), 347–55, viii.
- Reggiani-Mello, G., & Krueger, R. R. (2011). Comparison of commercially available femtosecond lasers in refractive surgery. *Expert Review of Ophthalmology*, 6(1), 55.
- Shousha, M. A., Yoo, S. H., Kymionis, G. D., Ide, T., Feuer, W., Karp, C. L., et al. (2011). Long-term results of femtosecond laser-assisted sutureless anterior lamellar keratoplasty. *Ophthalmology*, 118(2), 315–323.
- Stern, D. (1989). Corneal ablation by nanosecond, picosecond, and femtosecond lasers at 532 and 625 nm. *Archives of Ophthalmology*, 107(4), 587.
- Sugar, A., Rapuano, C. J., Culbertson, W. W., Huang, et al. (2002). Laser in situ keratomileusis for myopia and astigmatism: Safety and efficacy:: A report by the american academy of ophthalmology. *Ophthalmology*, 109(1), 175.
- Sugar, A. (2002). Ultrafast (femtosecond) laser refractive surgery. *Current Opinion in Ophthalmology*, 13(4), 246.
- Tran, D. B., Sarayba, M. A., Bor, Z., Garufis, C., Duh, Y., Soltes, C. R., et al. (2005). Randomized prospective clinical study comparing induced aberrations with IntraLase and hansatome flap creation in fellow eyes: Potential impact on wavefront-guided laser in situ keratomileusis. *Journal of Cataract and Refractive Surgery*, 31(1), 97.
- Vaddavalli, P., Hurmeric, V., & Yoo, S. (2011). Air bubble in anterior chamber as indicator of full-thickness incisions in femtosecond-assisted astigmatic keratotomy. *Journal of Cataract & Refractive Surgery*, 37(9) 1723.
- Wu, E. (2011). Femtosecond-assisted astigmatic keratotomy. *International Ophthalmology Clinics*, 51(2), 77.
- Yoo, S. H., Kymionis, G. D., Ide, T., & Diakonis, V. F. (2009). Overcorrection after femtosecond-assisted astigmatic keratotomy in a post-descemet-stripping automated endothelial keratoplasty patient. *Journal of Cataract and Refractive Surgery*, 35(10), 1833.
- Yoo, S. H., Kymionis, G. D., Koreishi, A., Ide, T., Goldman, D., Karp, C. L., et al. (2008). Femtosecond laser-assisted sutureless anterior lamellar keratoplasty. *Ophthalmology*, 115(8), 1303.
- Zhang, Z., Jun, H., Suo, Y., Patel, S., Montes-Mico, R., Manche, E., et al. (2011). Femtosecond Laser versus mechanical microkeratome laser in situ keraomileusis for myopia: Metanalysis of randomized constolled trials. *Journal of Cataract and Refractive Surgery*, 37(12), 2151.



Astigmatism - Optics, Physiology and Management

Edited by Dr. Michael Goggin

ISBN 978-953-51-0230-4

Hard cover, 308 pages

Publisher InTech

Published online 29, February, 2012

Published in print edition February, 2012

This book explores the development, optics and physiology of astigmatism and places this knowledge in the context of modern management of this aspect of refractive error. It is written by, and aimed at, the astigmatism practitioner to assist in understanding astigmatism and its amelioration by optical and surgical techniques. It also addresses the integration of astigmatism management into the surgical approach to cataract and corneal disease including corneal transplantation.

How to reference

In order to correctly reference this scholarly work, feel free to copy and paste the following:

Duna Raoof-Daneshvar and Shahzad I. Mian (2012). Femtosecond Laser-Assisted Astigmatism Correction, *Astigmatism - Optics, Physiology and Management*, Dr. Michael Goggin (Ed.), ISBN: 978-953-51-0230-4, InTech, Available from: <http://www.intechopen.com/books/astigmatism-optics-physiology-and-management/femtosecond-laser-assisted-astigmatism-correction>

INTECH
open science | open minds

InTech Europe

University Campus STeP Ri
Slavka Krautzeka 83/A
51000 Rijeka, Croatia
Phone: +385 (51) 770 447
Fax: +385 (51) 686 166
www.intechopen.com

InTech China

Unit 405, Office Block, Hotel Equatorial Shanghai
No.65, Yan An Road (West), Shanghai, 200040, China
中国上海市延安西路65号上海国际贵都大饭店办公楼405单元
Phone: +86-21-62489820
Fax: +86-21-62489821

© 2012 The Author(s). Licensee IntechOpen. This is an open access article distributed under the terms of the [Creative Commons Attribution 3.0 License](https://creativecommons.org/licenses/by/3.0/), which permits unrestricted use, distribution, and reproduction in any medium, provided the original work is properly cited.

IntechOpen

IntechOpen