

We are IntechOpen, the world's leading publisher of Open Access books Built by scientists, for scientists

6,900

Open access books available

186,000

International authors and editors

200M

Downloads

Our authors are among the

154

Countries delivered to

TOP 1%

most cited scientists

12.2%

Contributors from top 500 universities



WEB OF SCIENCE™

Selection of our books indexed in the Book Citation Index
in Web of Science™ Core Collection (BKCI)

Interested in publishing with us?
Contact book.department@intechopen.com

Numbers displayed above are based on latest data collected.
For more information visit www.intechopen.com



Cataract Surgery in Keratoconus with Irregular Astigmatism

Jean-Louis Bourges

*Université Sorbonne Paris Cité, Paris Descartes, Faculté de médecine
Assistance Publique-Hôpitaux de Paris, Hôtel-Dieu, Department of Ophthalmology
France*

1. Introduction

Keratoconus generates highly irregular corneal astigmatism. While age is well known to slow down the progression of keratoconic ectasia and tends to fix the subsequent irregular astigmatism, the natural onset of cataract contributes to further decrease vision in already disabled patients.

To offer these patients an optimal strategy for cataract treatment, different options on how to manage irregular astigmatism of a keratoconic patient with surgical cataract have been proposed and are reviewed.

The stage of keratoconus and the history of the patient are both critical to orient the strategy. However, combined parameters should be considered for patients with highly irregular astigmatism due to keratoconus, to anticipate refractive results close to those obtained on patients with normal corneas. Contact lens equipment, intracorneal segment rings, lamellar or penetrating keratoplasties and, more generally, therapeutics which are usually applied for keratoconus, can be opportunely combined with the whole range of solutions offered by modern cataract surgery. Different methods of keratometry and formulas for intraocular lens (IOL) calculation have been proposed to improve as much as possible the predictability of the final refractive status, which still remains far from the standards of classical cataract surgery. So far, multifocal IOLs are still not suitable when associated with irregular corneal astigmatism, but toric intraocular lenses (IOL) could be selectively considered as an option in these patients.

2. Spherical intraocular lens (IOL) power calculation

All formulas for intraocular lens calculation are mainly based on keratometric values. Precisely estimating the mean keratometry is therefore mandatory to define the closest IOL refractive power to the desired postoperative refraction. In keratoconus, however, standard deviations of differences between steepest and flattest keratometric reading vary greatly depending on the category of patients, from 1 up to more than 5 D for severe keratoconus, according to the Collaborative Longitudinal Evaluation of Keratoconus (CLEK) Study (Zadnik et al., 1998). Moreover, once a clear corneal incision has been performed during the procedure, keratometric readings from keratoconic corneas may turn unstable after cataract

surgery and evolve in an unforeseeable manner, even when patients have been operated on at a non-progressing preoperative state. The resulting change in corneal curvature should, though, be estimated prior to the surgery. Complex mathematical algorithms have been elaborated to predict lens power better in such difficult cases (Langenbacher et al., 2004), but they remain of restricted use in current clinical practice.

Finally, in most keratoconus, the corneal apex is decentered. For IOL power calculation, keratometric readings should therefore be taken in the central cornea, where the optical zone corresponds to the projection of the visual axis. How large the central optical zone should be is still to be clinically appreciated, as the balance observed between corneal curvatures of the two corresponding hemi-meridians depends on corneal apex decentration. Large optical zones create a significant hazard in IOL power calculation by overweighting high values taken from the apex of the ectasia, instead of averaging curvatures that are relevant for visual acuity in the optical axis.

Whatever method is eventually used to calculate the IOL power, the patient should be aware of the possible miscalculation induced by keratoconus on his/her intended postoperative refraction status.

2.1 Formulas for IOL power calculation

No 1 or 2 level of evidence-based medical data is available today to determine whether one particular calculation method will perform better than another for accuracy or reproducibility in IOL power estimation. Based on a retrospective analysis of a small cohort of nine patients (12 eyes) including various stages of keratoconus, Thebpatiphat *et al.* (Thebpatiphat et al., 2007) observed that the SRK-II formula provided the more predictable results than SRK or SRK-T. Still, it remains unclear whether one formula should be preferred to another. For instance, the SRK-T formula is reputed to achieve better results than SRK-II on myopic eyes (Brandser et al., 1997, Sanders et al., 1990), while keratoconus and myopia are frequently associated (Ernst et al., 2011).

Besides the dilemma of calculation formula and keratometry, it is critical to use clinically relevant data for axial length, which are challenging to evaluate in keratoconus. The decentered apex of keratoconic corneas creates unpredictable parallax errors in the visual axis estimation. For this reason, the axial length measurement should be perfectly aligned with the manifest visual axis, and optical measurements are often preferred to other manual or ultrasound (US) techniques to ensure patients' fixation easily, although US achieves better predictability in myopic eyes with normal corneas (Pierro et al., 1991).

2.2 Keratometry based on the manifest refraction

Careful manifest refraction contributes to refine highly irregular keratometric values. The Jackson cylinder method at best refines the manifest axis and the optimal power of the cylinder. Ideally, the difference between the two keratometric values should match with the value of the manifest cylinder. However, the mean value of objective astigmatism based on measured keratometry ($K_2 - K_1$) is usually reduced to more subjective values. It is not rare that the power for manifest cylinder is half measured values. Although favoring values that are clinically relevant, this method is somewhat empiric and lacks reproducibility. It should also be pointed out that accurate manifest refraction may not be possible in patients with cataract.

2.3 Topography-based keratometry

Elevation topographs take advantage of analyzing both anterior and posterior corneal curvatures to generate true net power maps (Kim et al., 2009). Irregular astigmatism, in keratoconus patients for instance, changes anterior curvature and posterior/anterior ratio. Standard IOL calculation formulas are not sufficiently accurate to predict IOL power. True net power maps provide significantly different values for estimating the corneal power within a specific corneal area by assuming paraxial imaging and combining two lenses separated by the central corneal thickness through Gaussian formulas (**Figure 1**). This feature is of particular interest in keratoconus, where the corneal thickness varies with a non-linear pattern from the center to the periphery of the cornea. The keratometric index is refined with elevation topographs (Ho et al., 2008). Moreover, where keratometers assume that keratometry derives from a constant corneal refractive power, elevation topographs measures the true power of the cornea (Eryildirim et al., 1994). They provide “optical” keratometeries closer to the manifest refraction than specular values. This objective method is more reproducible to prevent IOL power miscalculation, although it should be stressed that elevation topographs have their own limits in reproducibility and their data are not interchangeable for analysis (Bourges et al., 2009, Quisling et al., 2006).

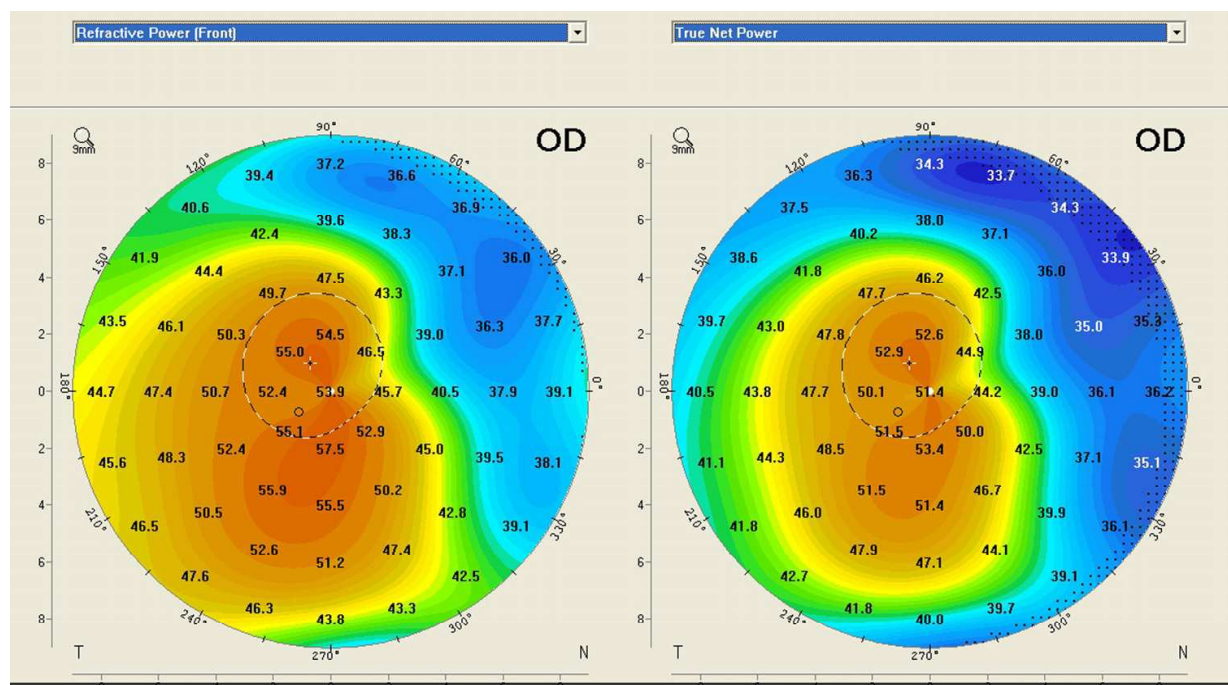


Fig. 1. Refractive power and true net power maps of patient CYS, 63-y-o female with keratoconus. Within a single acquisition, the elevation topograph (Pentacam, Oculus) provides both the anterior refractive power and the true net power of the cornea, which vary significantly for this keratoconic patient. Notice that with a simple topograph-based classification (Zadnik, 1998), the keratoconus could either be classified as severe (maximal K reading > 52 D), referring to refractive power map, or mild, based on a true net power map (45 D < maximal K reading ≤ 52 D).

More recently, Oculus released a new device associating Pentacam (Oculus) with the Galilei Dual Scheimpflug Analyzer (Ziemer Ophthalmics) to generate total corneal power maps

(TCP). It uses ray tracing technology, which propagates incoming parallel rays and uses Snell's law to refract these rays through the anterior and posterior corneal surfaces and determine corneal power. In eyes that have irregular astigmatism, in the near future, the use of TCP values might be superior to corneal power calculations based on Gaussian formula and contribute to further refine accuracy in IOL calculation. This remains to be validated in the clinical setting.

2.4 Equivalent K-Readings (EKR)

Equivalent K-Readings (EKR) are values provided by the Holladay Report and powered by the Pentacam (Oculus software). They are based on elevation topography maps. Equivalent K Readings correct keratometric values, focusing on the central cornea and balancing irregularities of the corneal curvature observed between steeper and flatter hemi-meridians. The accuracy of keratometric values thus obtained to calculate pseudophakic IOL on keratoconic cornea is still under investigation, but the preliminary results obtained on patients with irregular astigmatisms are encouraging. For example, **Figure 2** shows keratometric values obtained by various methods. The closest value from the manifest refraction is obtained with the topograph after EKR correction and is approximately half the value obtained using other means.

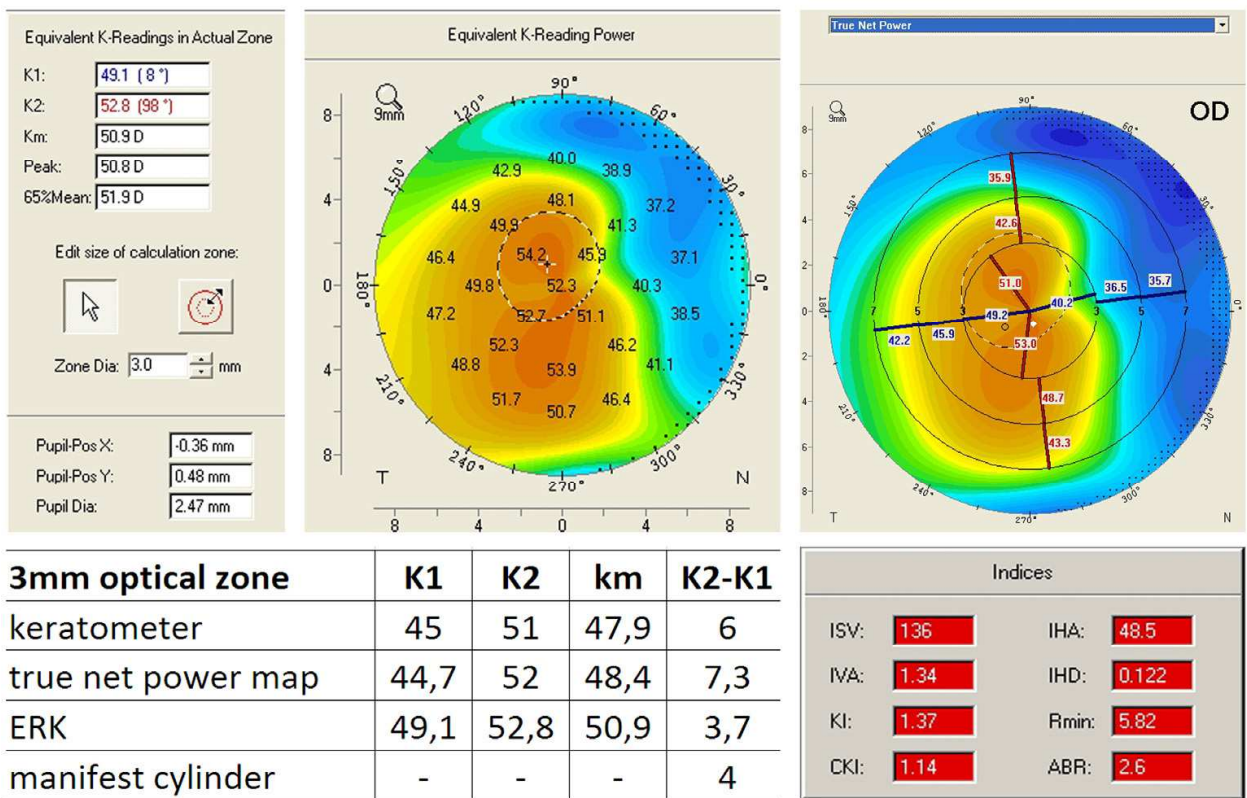


Fig. 2. Keratometric readings obtained by automatic keratometer, by topography true net power map, and by topographic map after EKR correction on a single patient with keratoconus. This case illustrates how close to the manifest values of the cylinder EKR values can be in keratoconus as compared to other keratometric readings.

3. Toric intraocular lens (IOL) implantation

Although the indication of toric intraocular lens (T IOL) implantation in keratoconus is still not fully admitted, and does not belong to laboratory recommendations because of the irregularity of astigmatism, it appears to be an emerging practice. The first T IOLs were inserted in phakic eyes for purely refractive purposes on stable keratoconus (Alfonso et al., 2011, Budo et al., 2005, Kamburoglu et al., 2007, Kamiya et al., 2008, Kamiya et al., 2011, Navas et al., 2009, Sauder et al., 2003, Sokel et al., 1973). Toric IOLs have been considered for pseudophakic implantation since 2003 (SauderJonas, 2003) and their worthiness is currently under investigation (Jaimes et al., 2011). If the surgeon’s choice is to place a toric IOL in a keratoconic eye, minimizing the corneal irregularity should be considered, as well as the eventuality of a possible keratoplasty. The latter generally rarely applies, as cataract occurs in the elderly and toric IOL should preferentially be proposed for stabilized keratoconus.

3.1 Reducing irregular astigmatism

Reducing the irregularity of astigmatism in keratoconus is a key factor to achieve good results in predictability and accuracy for IOL pseudophakic implantation in cataract surgery. Various methods have been proposed. The most popular are intracorneal segment rings (ICSR) placement and corneal collagen cross-linking (CXL) with or without PTK. At the margin, relaxing incisions and conductive keratoplasty have also been tested. Since Colin *et al.* proposed ICSR placement to reduce irregular astigmatism in keratoconus (Colin et al., 2000, Colin et al., 2001), the technique has become extremely popular among ophthalmic surgeons treating a wide range of ectatic corneal diseases (Dauwe et al., 2009, Ertan et al., 2007, Pinero et al., 2011). Despite that is unusual that irregular astigmatism of ectasia to be fully compensated by the procedure, it dramatically reduces differences in curvatures between opposite corneal hemi-meridians and usually makes toric IOL consecutive placement reasonably conceivable.

3.2 Case reports

Patient 1 was a 65-year-old women with combined keratoconus, high myopia, and a senile bilateral cataract. Her axial length was obtained by mode B echography and was measured at 31.40 mm OD and 31.10 mm OS. The IOL powers were calculated using various methods

| eye | corneal area (mm) | Equivalent K-readings | | SRK-II | | SRK-T | |
|-------|-------------------|-----------------------|-------------|---------------|------------------------|---------------|------------------------|
| | | keratometry | K value (D) | IOL power (D) | planned refraction (D) | IOL power (D) | planned refraction (D) |
| right | 3 | K1/K2 (D) | 43,1/44,6 | 3.5 | -3.07 | 3.5 | -2.88 |
| | | 65% Km (D) | 43.2 | 4 | -2.98 | 4.5 | -2.91 |
| left | 3 | K1/K2 (D) | 46,4/51 | 0 | -3.1 | -4.5 | -3.03 |
| | | 65% Km (D) | 52.3 | -3.5 | -2.92 | -11.5 | -3.1 |
| right | 4.5 | K1/K2 (D) | 43,4/45 | 3 | -2.88 | 3 | -2.9 |
| | | 65% Km (D) | 43.4 | 4 | -3.16 | 4.5 | -3.1 |
| left | 4.5 | K1/K2 (D) | 46,4/49,7 | 0.5 | -3.1 | -3.5 | -2.88 |
| | | 65% Km (D) | 52 | -3 | -3.15 | -11 | -3.05 |

Table 1. **IOL power calculation obtained with EKR for Patient 1.** The IOL power targeting a postoperative refraction of -3 D varied significantly for the patient, from 3 to 4.5 D and - 11.5 to 0.5 D respectively for OD and OS, depending on the keratometric value taken for calculation, on the IOL calculation formula and on the diameter of the central corneal area selected for EKR. K 1 and K2 = keratometric readings. Km = mean keratometry. 65%Km = median keratometry (most represented values).

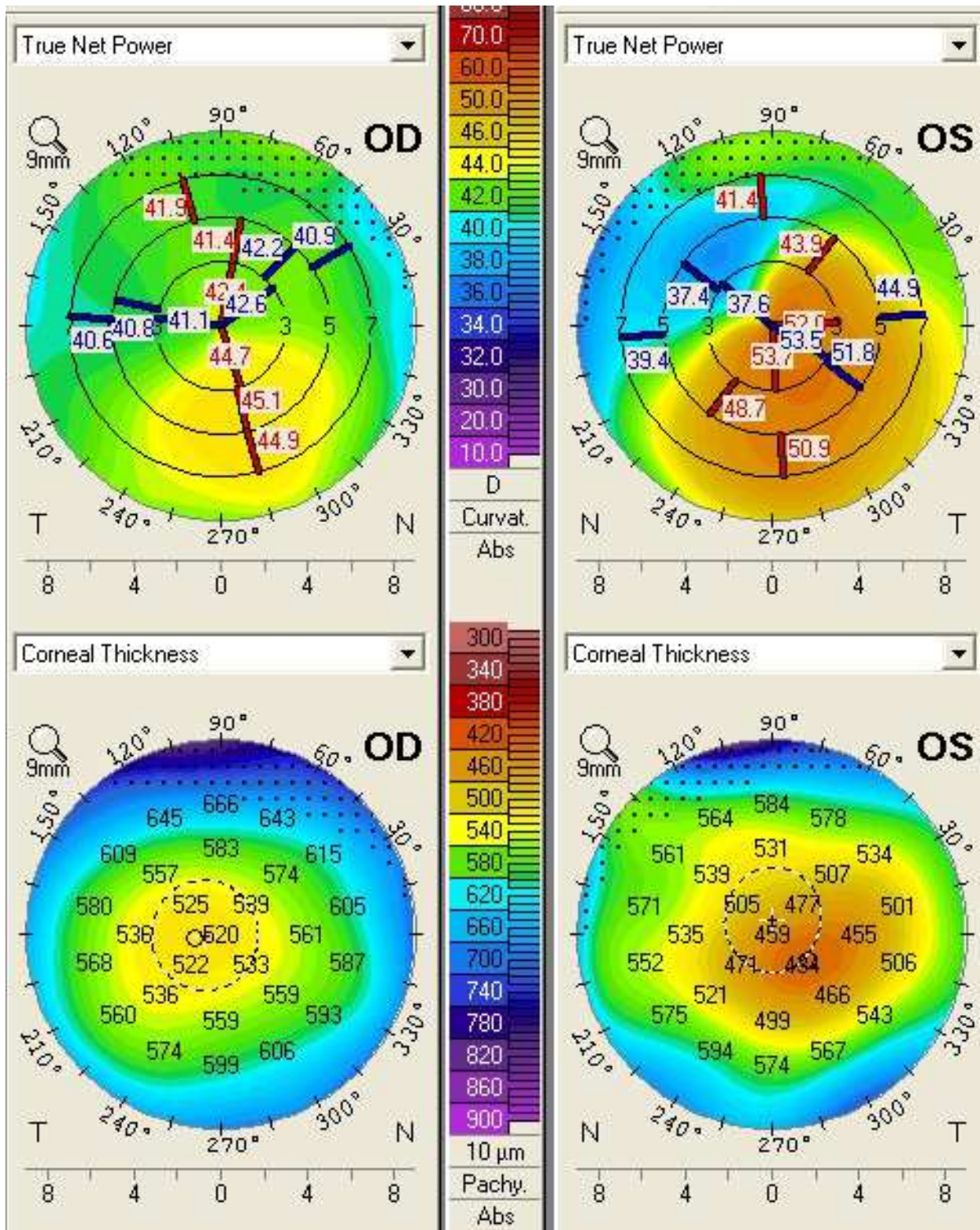


Fig. 3. Corneal topography (Pentacam Oculus) of Patient 1. Her keratoconus was considered moderate for OD (> 45 D) and severe for OS (> 52D). The topography shows fairly preserved corneal thickness.

and the post-operative refraction was estimated based on each of them. The resulting powers of IOL are shown in **table 1**. Her elevation topographies, the latter of which is displayed in **Fig. 3**, demonstrated that corneal curvature was not progressing over a 2 years period. She underwent bilateral cataract surgery. The left eye was first operated on based on an automated keratometry with the SRK-T formula. The IOL power calculation for the right eye was based on the 4.5 mm EKR using SRK-T. The 4.5 mm zone was chosen considering less than 3 D irregularities between two opposite meridians. Thus, a 3D IOL was placed in OD and a -9 D IOL placed in OS, planning a -2.50 D post-operative refraction for OD and emetropia for OS. She finally achieved a -2 D OD postoperative spherical equivalent and +1.25 D for OS. The manifest refraction was stable two months after surgery.

The poor predictability observed for the left postoperative refraction could be explained both by the uncertainty drawn by high myopia regarding axial length calculation and by miscalculations. At the time of the first operation, EKRs were not available and could not be used for IOL power estimation. However, the resulting manifest refraction clearly demonstrated that videotopographic true net powers would have better predicted refractive outcome in this case.

In the opposite eye, EKR performed nicely to predict the appropriate IOL power in the right eye despite uncertainties in axial length measurement linked to high myopia.

4. Additional considerations

4.1 Optical aberrations induced by keratoconus

No cataract surgery is able to reduce high order aberrations (HOA) induced by keratoconus significantly, so far. With appropriate light delivery settings, Light Adjustable Lenses (LAL) are attempt, at least in part, to address this issue on stable ectasia, since this post-insertion method for the correction of refractive errors has been used successfully to correct astigmatism after cataract surgery (Hengerer et al., 2011, Lichtinger et al., 2011, Sandstedt et al., 2006, Schwartz et al., 2001).

Topo-guided phototherapeutic keratectomy (PTK) has also been proposed after corneal collagen cross-linking to both stabilize the corneal ectasia and reduce the residual ametropia and other relevant HOA (Krueger et al., 2011, Kymionis et al., 2011).

4.2 Biomechanical outcome of the cornea after clear corneal incision

Although keratoconus is usually stable at the age of cataract surgery, any corneal wound or surgical event is at risk for progression of irregular astigmatism. Subsequently, surgeons should customize their postoperative follow-up toward such patients. As keratoconic corneas demonstrate deteriorated Young modulus, it is advised not to rely on self-sealing clear corneal incisions but rather to perform sutured incision, not only the safety issue, but because it opportunely offers an additional chance to improve refraction and regularize astigmatism.

5. Conclusion

Intraocular lens power calculation still demonstrates better accuracy in eyes with regular optical disorders compared to keratoconic corneas. However, modern videotopographies

and relevant formulas now significantly contribute to enhance the predictability of the manifest refraction after uneventful cataract surgery.

6. References


- Alfonso, J. F., Fernandez-Vega, L., Lisa, C. et al. (2011). Collagen copolymer toric posterior chamber phakic intraocular lens in eyes with keratoconus. *J Cataract Refract Surg*, Vol. 36, No. 6 (Jun), pp.906-16
- Bourges, J. L., Alfonsi, N., Laliberte, J. F. et al. (2009). Average 3-dimensional models for the comparison of Orbscan II and Pentacam pachymetry maps in normal corneas. *Ophthalmology*, Vol. 116, No. 11 (Nov), pp.2064-71
- Brandser, R., Haaskjold, E. and Drolsum, L. (1997). Accuracy of IOL calculation in cataract surgery. *Acta Ophthalmol Scand*, Vol. 75, No. 2 (Apr), pp.162-5
- Budo, C., Bartels, M. C. and van Rij, G. (2005). Implantation of Artisan toric phakic intraocular lenses for the correction of astigmatism and spherical errors in patients with keratoconus. *J Refract Surg*, Vol. 21, No. 3 (May-Jun), pp.218-22
- Colin, J., Cochener, B., Savary, G. et al. (2000). Correcting keratoconus with intracorneal rings. *J Cataract Refract Surg*, Vol. 26, No. 8 (Aug), pp.1117-22
- Colin, J., Cochener, B., Savary, G. et al. (2001). INTACS inserts for treating keratoconus: one-year results. *Ophthalmology*, Vol. 108, No. 8 (Aug), pp.1409-14
- Dauwe, C., Touboul, D., Roberts, C. J. et al. (2009). Biomechanical and morphological corneal response to placement of intrastromal corneal ring segments for keratoconus. *J Cataract Refract Surg*, Vol. 35, No. 10 (Oct), pp.1761-7
- Ernst, B. J.Hsu, H. Y. (2011). Keratoconus association with axial myopia: a prospective biometric study. *Eye Contact Lens*, Vol. 37, No. 1 (Jan), pp.2-5
- Ertan, A.Colin, J. (2007). Intracorneal rings for keratoconus and keratectasia. *J Cataract Refract Surg*, Vol. 33, No. 7 (Jul), pp.1303-14
- Eryildirim, A., Ozkan, T., Eryildirim, S. et al. (1994). Improving estimation of corneal refractive power by measuring the posterior curvature of the cornea. *J Cataract Refract Surg*, Vol. 20, No. 2 (Mar), pp.129-31
- Hengerer, F. H., Hutz, W. W., Dick, H. B. et al. (2011). Combined correction of sphere and astigmatism using the light-adjustable intraocular lens in eyes with axial myopia. *J Cataract Refract Surg*, Vol. 37, No. 2 (Feb), pp.317-23
- Ho, J. D., Tsai, C. Y., Tsai, R. J. et al. (2008). Validity of the keratometric index: evaluation by the Pentacam rotating Scheimpflug camera. *J Cataract Refract Surg*, Vol. 34, No. 1 (Jan), pp.137-45
- Kamburoglu, G., Ertan, A. and Bahadir, M. (2007). Implantation of Artisan toric phakic intraocular lens following Intacs in a patient with keratoconus. *J Cataract Refract Surg*, Vol. 33, No. 3 (Mar), pp.528-30
- Kamiya, K., Shimizu, K., Ando, W. et al. (2008). Phakic toric Implantable Collamer Lens implantation for the correction of high myopic astigmatism in eyes with keratoconus. *J Refract Surg*, Vol. 24, No. 8 (Oct), pp.840-2
- Kamiya, K., Shimizu, K., Kobashi, H. et al. Clinical outcomes of posterior chamber toric phakic intraocular lens implantation for the correction of high myopic astigmatism

- in eyes with keratoconus: 6-month follow-up, In: Graefes Arch Clin Exp Ophthalmol, Oct 16, Available from:
<http://www.springerlink.com/content/271mh27m11r84136/>
- Kim, S. W., Kim, E. K., Cho, B. J. et al. (2009). Use of the pentacam true net corneal power for intraocular lens calculation in eyes after refractive corneal surgery. *J Refract Surg*, Vol. 25, No. 3 (Mar), pp.285-9
- Krueger, R. R., Kanellopoulos, A. J. (2011). Stability of simultaneous topography-guided photorefractive keratectomy and riboflavin/UVA cross-linking for progressive keratoconus: case reports. *J Refract Surg*, Vol. 26, No. 10 (Oct), pp.S827-32
- Kymionis, G. D., Grentzelos, M. A., Karavitaki, A. E. et al. (2011). Transepithelial Phototherapeutic Keratectomy Using a 213-nm Solid-State Laser System Followed by Corneal Collagen Cross-Linking with Riboflavin and UVA Irradiation. *J Ophthalmol*, Vol. 2010, No. pp.146543
- Langenbucher, A., Haigis, W. and Seitz, B. (2004). Difficult lens power calculations. *Curr Opin Ophthalmol*, Vol. 15, No. 1 (Feb), pp.1-9
- Lichtinger, A., Sandstedt, C. A., Schwartz, D. M. et al. (2011). Correction of Astigmatism After Cataract Surgery Using the Light Adjustable Lens: A 1-Year Follow-Up Pilot Study. *J Refract Surg*, Vol. No. (Jan 17), pp.1-4
- Navas, A., Suarez, R. (2009). One-year follow-up of toric intraocular lens implantation in forme fruste keratoconus. *J Cataract Refract Surg*, Vol. 35, No. 11 (Nov), pp.2024-7
- Pierro, L., Modorati, G. and Brancato, R. (1991). Clinical variability in keratometry, ultrasound biometry measurements, and emmetropic intraocular lens power calculation. *J Cataract Refract Surg*, Vol. 17, No. 1 (Jan), pp.91-4
- Pinero, D. P., Alio, J. L. (2011). Intracorneal ring segments in ectatic corneal disease - a review. *Clin Experiment Ophthalmol*, Vol. 38, No. 2 (Mar), pp.154-67
- Quisling, S., Sjöberg, S., Zimmerman, B. et al. (2006). Comparison of Pentacam and Orbscan IIz on posterior curvature topography measurements in keratoconus eyes. *Ophthalmology*, Vol. 113, No. 9 (Sep), pp.1629-32
- Sanders, D. R., Retzlaff, J. A., Kraff, M. C. et al. (1990). Comparison of the SRK/T formula and other theoretical and regression formulas. *J Cataract Refract Surg*, Vol. 16, No. 3 (May), pp.341-6
- Sandstedt, C. A., Chang, S. H., Grubbs, R. H. et al. (2006). Light-adjustable lens: customizing correction for multifocality and higher-order aberrations. *Trans Am Ophthalmol Soc*, Vol. 104, No. pp.29-39
- Sauder, G., Jonas, J. B. (2003). Treatment of keratoconus by toric foldable intraocular lenses. *Eur J Ophthalmol*, Vol. 13, No. 6 (Jul), pp.577-9
- Schwartz, D. M., Jethmalani, J. M., Sandstedt, C. A. et al. (2001). Post implantation adjustable intraocular lenses. *Ophthalmol Clin North Am*, Vol. 14, No. 2 (Jun), pp.339-45, viii
- Sokol, E., Kim, Y. (1973). Toric peripheral curves for keratoconus rigid corneal lens fittings. *Br J Physiol Opt*, Vol. 28, No. 3 pp.182-8
- Thebpatiphat, N., Hammersmith, K. M., Rapuano, C. J. et al. (2007). Cataract surgery in keratoconus. *Eye Contact Lens*, Vol. 33, No. 5 (Sep), pp.244-6

Zadnik, K., Barr, J. T., Edrington, T. B. et al. (1998). Baseline findings in the Collaborative Longitudinal Evaluation of Keratoconus (CLEK) Study. Invest Ophthalmol Vis Sci, Vol. 39, No. 13 (Dec), pp.2537-46

IntechOpen

IntechOpen



Astigmatism - Optics, Physiology and Management

Edited by Dr. Michael Goggin

ISBN 978-953-51-0230-4

Hard cover, 308 pages

Publisher InTech

Published online 29, February, 2012

Published in print edition February, 2012

This book explores the development, optics and physiology of astigmatism and places this knowledge in the context of modern management of this aspect of refractive error. It is written by, and aimed at, the astigmatism practitioner to assist in understanding astigmatism and its amelioration by optical and surgical techniques. It also addresses the integration of astigmatism management into the surgical approach to cataract and corneal disease including corneal transplantation.

How to reference

In order to correctly reference this scholarly work, feel free to copy and paste the following:

Jean-Louis Bourges (2012). Cataract Surgery in Keratoconus with Irregular Astigmatism, *Astigmatism - Optics, Physiology and Management*, Dr. Michael Goggin (Ed.), ISBN: 978-953-51-0230-4, InTech, Available from: <http://www.intechopen.com/books/astigmatism-optics-physiology-and-management/cataract-surgery-on-irregular-astigmatism-of-keratoconus>

INTECH
open science | open minds

InTech Europe

University Campus STeP Ri
Slavka Krautzeka 83/A
51000 Rijeka, Croatia
Phone: +385 (51) 770 447
Fax: +385 (51) 686 166
www.intechopen.com

InTech China

Unit 405, Office Block, Hotel Equatorial Shanghai
No.65, Yan An Road (West), Shanghai, 200040, China
中国上海市延安西路65号上海国际贵都大饭店办公楼405单元
Phone: +86-21-62489820
Fax: +86-21-62489821

© 2012 The Author(s). Licensee IntechOpen. This is an open access article distributed under the terms of the [Creative Commons Attribution 3.0 License](https://creativecommons.org/licenses/by/3.0/), which permits unrestricted use, distribution, and reproduction in any medium, provided the original work is properly cited.

IntechOpen

IntechOpen