

# We are IntechOpen, the world's leading publisher of Open Access books Built by scientists, for scientists

6,900

Open access books available

186,000

International authors and editors

200M

Downloads

Our authors are among the

154

Countries delivered to

TOP 1%

most cited scientists

12.2%

Contributors from top 500 universities



WEB OF SCIENCE™

Selection of our books indexed in the Book Citation Index  
in Web of Science™ Core Collection (BKCI)

Interested in publishing with us?  
Contact [book.department@intechopen.com](mailto:book.department@intechopen.com)

Numbers displayed above are based on latest data collected.  
For more information visit [www.intechopen.com](http://www.intechopen.com)



## Neuropathies Associated with Cosmetic Surgeries

Alexander Cárdenas-Mejía, Xitlali Baron, Colin Coulter,  
Javier Lopez-Mendoza and Claudia Gutiérrez  
*Postgraduate Course in Plastic and Reconstructive Surgery,  
Universidad Nacional Autonoma de México,  
General Hospital "Dr. Manuel Gea González",  
México City  
Mexico*

### 1. Introduction

Plastic, aesthetic and reconstructive surgery encompasses a wide range of surgical procedures for various parts of the body such as the face, neck, breast, body contouring and surgery on the upper and lower limbs.

In the last two decades the number of aesthetic procedures across the world has increased significantly. Although aesthetic surgery is not new its current popularity has rapidly increased due to the improved outcomes of techniques using autologous tissue as well as minimally invasive techniques which cause less scarring following surgical procedures<sup>1</sup>.

However with this increase in the number of procedures, the number of postoperative complications has also risen although in the majority of cases these are minor<sup>1</sup>.

Major complications are rare and frequently related to factors unique to the patient (such as anatomical variants) rather than with the technical aspects of the surgical procedure<sup>1</sup>.

Nerve injury is a rare complication in patients who undergo aesthetic surgery; nonetheless, whatever the cause of the injury, it can lead to moderate disability in some patients.

Iatrogenic nerve lesions caused during aesthetic surgery can present in two ways. One is with a sensory change such as dysesthesia, anesthesia or chronic untreatable pain. The other is a change in motor function manifesting either as partial or complete loss of function or synkinesis. Both outcomes can lead to physical and emotional disability.

Plastic, aesthetic and reconstructive surgeons should have in mind all of the possible nerve injuries during the procedures. A thorough understanding of anatomy as well as changes with age is very important for the surgeons.

There are some nerve injuries which are unavoidable and form an inherent part of the surgical procedure with the full knowledge of the surgeon and the patient. These include procedures such as mammoplasty (augmentation, reduction or mastopexy) and dermolipectomies. In these procedures sectioning and injury to the nerve is unavoidable and sensory changes usually recover after a period of time.

## 2. Incidence

Across the international medical literature, it is clear that the incidence of nerve injuries differs according to the surgical area and the type of nerve.

Sensory nerves are at greater risk but injuries to them are not widely reported. However weakness of the temporal branch of the facial nerve has been reported in around 0.7% of patients<sup>4,6,29</sup>.

Forehead lifting; 50% of procedures result in some degree of decreased sensation to the forehead<sup>30</sup>. Body contouring procedures carry a high risk of injury to the sensory nerves. Breast reduction; Schlensz<sup>7</sup> reports sensory changes in up to 47.8% of patients. Breast augmentation; Ducic<sup>21</sup> reports the presence of chronic pain in 7% of patients. Abdominoplasty; Bufoni<sup>31</sup> reports sensory changes to the hypogastric area in up to 75% of patients. Calf augmentation; several papers report no nerve complications following surgery<sup>24,25,26</sup> but the nerves at risk are the medial sural nerve and the saphenous nerve which innervate the posterior part of the leg. Upper limb; Knoetgen<sup>9</sup> reports two cases (an incidence of 5%) of nerve-related complications during brachioplasties with injury to the medial antebrachial cutaneous nerve (MACN) in the arm.

The majority of the literature relating to iatrogenic nerve injuries caused by surgery concentrates on orthopaedic patients. However there are some documented reports of such injuries following aesthetic surgery procedures as well<sup>2</sup>.

These reports should be interpreted with caution. The majority of data comes from referral hospitals which see a high volume of patients. In these cases, the reported rates are very low probably owing to the vast experience of plastic surgeons that treat a high number of patients in these circumstances.

A detailed neurological examination is required to identify the deficits. Motor weakness may be obvious or the patient will bring it to the attention of the surgeon. On the other hand the sensory deficits at first may be mildly uncomfortable to the patient, but are usually well tolerated and may not be a major source of complaint for the patient.

Facial surgeries; Rhytidectomies carry the highest incidence of nerve injuries predominantly causing sensory changes. Damage to the great auricular nerve is reported in 1-7% of cases. Nerve injuries affecting the forehead typically show motor deficits in 0.5-3% of cases. These can result from damage to any of the branches of the facial nerve: marginal mandibular 3%, temporal 1.5%, cervical 1.75%, zygomatic and buccal 0.2%. The incidence increases if the procedure is performed endoscopically and when it is combined with ultrasound-assisted liposuction. The next most common procedures resulting in nerve injuries are blepharoplasties, rhinoplasties and genioplasties with some reported cases of isolated nerve injury<sup>3,4,5,6</sup>.

Breast surgeries; reduction mammoplasty utilizing the superior pedicle technique shows the highest incidence of sensory changes to the nipple-areola complex as high as 47.8%<sup>7</sup>.

Body contouring procedures; ultrasound-assisted liposuction causes the greatest incidence of sensory nerve lesions with reports of hyperesthesia in up to 79% of patients. This is followed by gluteal implantation which causes paresthesia in 4-20% of patients and paresis in 1.5% while only 1% of patients receiving gluteal lipoinjections suffer from paresthesia<sup>8</sup>.

The limbs; brachioplasties represent the highest rate of nerve injuries of up to 5% with injuries to the medial antebrachial cutaneous nerve. In the lower limbs the incidence is much lower with reports of damage to the medial sural cutaneous nerve and the medial saphenous nerve during the placement of calf implants<sup>9, 10, 11</sup>.

### 3. Mechanism of injury

The mechanism of injury varies between cases. It can be due to direct nerve traction caused by the use of retractors, direct mechanical injury, thermal or ultrasound injury, nerve laceration from instrument usage or damage by physical manipulation of the nerve.

Nerve entrapment or compression may also result due to sutures or the formation of scar tissue, haematomas or even poor positioning of the patient<sup>7</sup>. Other concomitant therapies such as radiation or chemotherapy can cause neuritis or neuropathy with or without compression. The position of the patient during the surgical procedure such as having the patient in the prone position can increase the risk of nerve injuries such as plexopathy<sup>2, 12</sup>.

### 4. Diagnosis

It should be emphasised that early diagnosis with appropriate treatment is necessary to ensure that optimum nerve function is restored. The deficits can get worse if patients have to wait longer for evaluation.

In the case of a late diagnosis nerve reconstruction is more difficult resulting in sub optimal nerve function. As Sunderland described, once atrophy of the motor end plate begins after 3 to 6 months, only partial reconstruction can be achieved<sup>2</sup>.

The diagnosis of nerve damage requires a complete neurological examination evaluating any sensory or motor impairment by validated scales i.e. British Medical Council Scale for Muscle Strength (BMRC) while sensory changes can be evaluated either by using the same scale or applying the Seddon classification.

Electrophysiological studies are an integral part of the evaluation to elucidate the site and possibly extent of the injury. The information gained ideally in the first 2-4 months will indicate which therapeutic options are most appropriate.

Measuring the quality of life using the standardised scale SF-36<sup>2</sup> can be worthwhile.

The above recommendations do not apply in the case of injuries to the facial nerve. The standardised scale recommended for use in these patients is the House-Brackmann scale. However some authors consider the Sunnybrook Facial Grading System to provide a better evaluation since it does not only group the patients into one of five possible categories (as the HB scale does) but also provides a more precise measurement scale assigning a score of between 0 and 100 to the patient. It also incorporates an evaluation of synkinesis by the fourth outpatient clinic. However for this group of patients the SF-36 scale is not useful. Frijters et al. (2008) reported no statistically significant relationship between injuries to branches of the facial nerve and SF-36 scores.<sup>13</sup>

Electrophysiological studies including nerve conduction studies of sensory and motor nerves and electromyography should be performed at the time of the diagnosis and during follow-up monitoring.

Somatosensory Evoked Potentials tests, electroneurography and electromyography are very helpful in diagnosing nerve injury<sup>14</sup>.

STANDARDIZED QUESTIONNAIRES	EVALUATION			TOTAL SCORE	WHO EVALUATES	SUBJECT OF EVALUATION
HOUSE BRACKMANN	NORMAL SYMMETRICAL FUNCTION IN ALL AREAS			1	INTERRATER	FACIAL PARALYSIS
	SLIGHT WEAKNESS NOTICEABLE ONLY ON CLOSE INSPECTION. COMPLETE EYE CLOSURE WITH MINIMAL EFFORT. SLIGHT ASYMMETRY OF SMILE WITH MAXIMAL EFFORT. SYNKINESIS BARELY NOTICEABLE, CONTRACTURE OR SPASM ABSENT.			2		
	OBVIOUS WEAKNESS, BUT NOT DISFIGURING. MAY NOT BE ABLE TO LIFT EYEBROW COMPLETE EYE CLOSURE AND STRONG BUT ASYMMETRICAL MOUTH MOVEMENT WITH MAXIMAL EFFORT. OBVIOUS, BUT NOT DISFIGURING SYNKINESIS, MASS MOVEMENT OR SPASM.			3		
	OBVIOUS DISFIGURING WEAKNESS. INABILITY TO LIFT BROW. INCOMPLETE EYE CLOSURE AND ASYMMETRY OF MOUTH WITH MAXIMAL EFFORT. SEVERE SYNKINESIS, MASS MOVEMENT, SPASM			4		
	MOTION BARELY PERCEPTIBLE. INCOMPLETE EYE CLOSURE, SLIGHT MOVEMENT CORNER MOUTH SYNKINESIS, CONTRACTURE, AND SPASM USUALLY ABSENT			5		
	NO MOVEMENT, LOSS OF TONE, NO SYNKINESIS, CONTRACTURE, OR SPASM			6		
SUNNYBROOK FACIAL GRADING SYSTEM	RESTING SYMMETRY	PALPEBRAL FISSURE	NORMAL NARROW WIDE	0 - 100 0: COMPLETE FACIAL PARALYSIS 100: NORMAL FACIAL FUNCTION	INTER AND INTRATER	FACIAL PARALYSIS
		NASOLABIAL FOLD	NORMAL ABSENT LESS OR MORE PRONOUNCED			
		CORNER OF THE MOUTH (TO THE NORMAL SIDE)	NORMAL DROOPED PULLED UP/OUT			
	SYMMETRY OF VOLUNTARY MOVEMENT	FOREHEAD WRINKLE	1 (NO MOVEMENT)			
		GENTLE EYE CLOSURE				
		OPEN MOUTH SMILE	5 (MOVEMENT COMPLETE)			
		SNARL				
	LIP PUCKER					
SYNKINESIS	DEGREE OF	0 (NO SYNKINESIS) 3 (SEVERE SYNKINESIS)				

SHORT FORM-36 HEALTH SURVEY	PHYSICAL FUNCTIONING	0 - 100 100: HIGHER LEVELS OF WELL FUNCTIONING OR WELL BEING	SELF REPORT QUESTIONNAIRE	LIFE QUALITY
	ROLE LIMITATIONS DUE TO PHYSICAL HEALTH PROBLEMS			
	BODILY PAIN			
	GENERAL HEALTH PERCEPTIONS			
	VITALITY			
	SOCIAL FUNCTIONING			
	ROLE LIMITATIONS DUE TO EMOTIONAL PROBLEMS			
	GENERAL MENTAL HEALTH			

Table 1. Scales to evaluate facial paralysis and sequelae

Electromyography has proven to be the most useful test in the study of these types of injuries. It evaluates and registers the electrical activity produced by skeletal muscles measuring the electrical potential generated by the muscle cells.

Electromyography is performed 14 to 21 days after the injury when Wallerian degeneration of the axons has occurred. However in the acute phase, it is not possible to distinguish the extent of the axonal degeneration until the 3<sup>rd</sup> to 14<sup>th</sup> day<sup>14</sup>. In acute injuries increased spontaneous activity including positive waves and fibrillation potentials are noted. When the motor end plates are reinnervated electromyography shows polyphasic action potentials<sup>15</sup>.

In circumstances where electrophysiological studies do not detect a loss of axonal continuity or Wallerian degeneration it is advisable to have a period of “watchful waiting” with regular nerve conduction studies to confirm that nerve transmission is not deteriorating<sup>15, 16</sup>. In any of the cases described above, patients presenting with a nerve injury should always be referred to a specialist in order to start the most appropriate treatment as early as possible.

5. Facial surgery

In facial surgery nerve injuries have been reported following procedures such as blepharoplasties, rhinoplasties, genioplasties and most commonly in rhytidectomies<sup>16</sup>. There have been some distressing reports of blindness following blepharoplasties. Data collected regarding rhinoplasties has reported cases of sensory loss of the nose-tip and injuries resulting from genioplasties have caused anesthesia or dysesthesia affecting the lips, chin and in some cases, paresthesia or paralysis of the lower lip.

However rhytidectomies are the commonest cause of facial nerve injuries. Patients can present with paresis with loss of function of the facial nerve- an event which can have a significant psychological impact for the patient<sup>14</sup>.

The majority of nerve injuries following rhytidectomies show sensory loss with the great auricular nerve being the most commonly affected. This is followed by injuries resulting in loss of motor function affecting in decreasing order the following divisions of the facial nerve: temporal, marginal mandibular, buccal and zygomatic.



There are some reports that rhytidectomies performed endoscopically on the upper third and upper half of the face can lead to complications such as transitory paresis of the temporal and zygomatic branches of the facial nerve showing recovery within six months after the procedure. When the procedure is carried out using ultrasound-assisted liposuction the incidence of motor nerve injuries is 7.6% (affecting the marginal mandibular branch)<sup>17</sup>.

Although an uncommon outcome from aesthetic surgery of the neck, injury to the spinal accessory nerve has been documented following cervicofacial lift and is most likely due to scar formation developing around the nerve.<sup>32</sup>

About 20% of injuries affecting the motor function of the facial nerve following rhytidectomies fail to show any spontaneous recovery of function.

The facial nerve and its branches travel along the anteromedial aspect of the parotid gland, running in a deep plane towards the superficial muscular and aponeurotic system (SMAS). The facial muscles are therefore innervated by the facial nerve from a deep position with the exception of the muscles elevating the corner of the mouth: buccinator and mentalis. With this in mind it is therefore necessary to perform a superficial dissection of the SMAS in order to avoid nerve-related complications<sup>2, 14, 16</sup>.

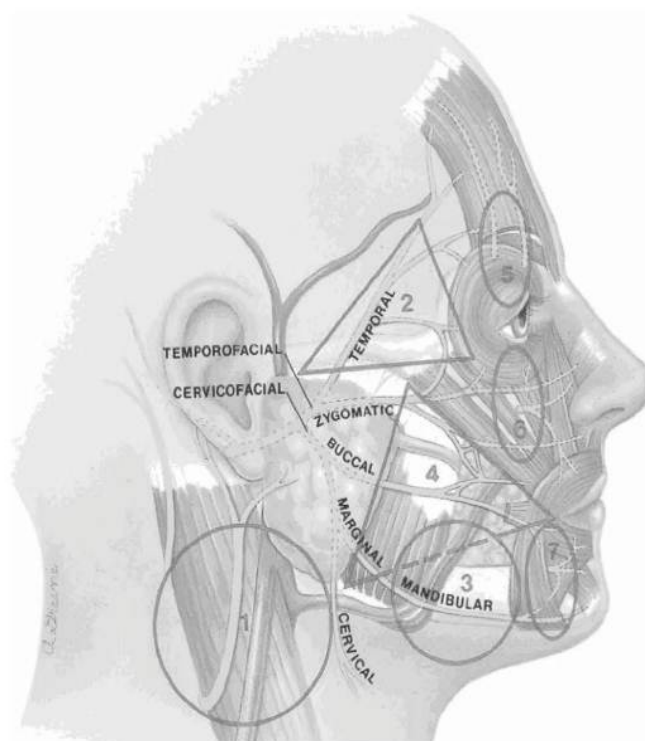


Fig. 1. Zeckel's nerve risk zones during face lift; major to minor risk; 1= great auricular nerve, 2= frontal branch of facial nerve, 3= marginal branch of facial nerve, 4= buccal branch of facial nerve, 5= supraorbital nerve, 6= infrorbital nerve, 7= mental nerve

Furthermore dissections of the posterior aspect of the sternocleidomastoid muscle ought to be undertaken with caution from beneath the mastoid process where the great auricular nerve runs more superficially thus increasing the risk of injury. Care must therefore be taken when using electrocautery while dissecting the superficial nerves.

Permanent damage to the nerve results in hypoesthesia or, in patients with a neuroma, painful dysesthesia in the lower two thirds of the ear and the skin of the neck and cheek.

The temporal branch of the facial nerve poses the greatest risk of motor damage followed by the marginal mandibular and buccal branches. In terms of anatomical regions, the temporo-frontal region, the angle of the mandible and the pre-parotid region are the riskiest areas in terms of nerve injury<sup>4, 8</sup>.

The temporal branch of the facial nerve is the thickest and is located anterior and caudal to the frontal branch of the superficial temporal artery in 91% of cases. Seckel locates the temporal branch in an area he describes as *Facial Zone 2*, where the nerve branch originates below the parotid gland at the level of the zygomatic arch before innervating the frontal muscle. Injury to the nerve results in paralysis of this muscle but orbicular function remains intact owing to the dual innervation it receives from the inferior zygomatic branches. This presents clinically as paralysis on the affected side of the forehead with ptosis of the eyebrow and a loss of symmetry during animation on that side<sup>4, 18</sup>.

In the middle third of the face the branches of the facial nerve can be damaged when carrying out deep dissection in front of the anterior border of the parotid gland. In the inferior third of the face the marginal branch can be damaged when carrying out deep dissection from beneath the inferior border of the mandible.

In subperiosteal rhytidectomies and other procedures where the tissue is elevated above the zygomatic arch, the superficial layer of the deep temporal fascia can be damaged when penetrating the superficial temporal fat pad.

Injury to the nerve results in asymmetry of the lower lip especially when opening the mouth and when smiling. If the triangular muscle of the lips is denervated, the corner of the mouth cannot be moved and the lower lip cannot be lowered making it impossible to show the inferior teeth on the affected side. At rest, the zygomatic muscles, which are normally innervated, are not opposed because the triangular muscle of the lips has no tone and the commissure of the mouth is held in such a way that the lower lip lies above the teeth when at rest.

One way of damaging the marginal mandibular nerve is by electrocautery while trying to control bleeding from the facial vein or less frequently from the facial artery. Both are found medially and deep to the marginal mandibular branch. The electric current can be passed to the nerve causing damage.

## 6. Breast surgery

The surgical procedures performed on the breast which can cause nerve injuries and chronic neurogenic pain include breast reconstruction, breast reduction, mastopexy and breast lifting<sup>21</sup>.

The symptoms can be due to neuromas-in-continuity with the intercostal nerve branches caused either by direct compression or by scar formation resulting from nerve traction or dissection.

Ducic describes the different zones of the breast which are susceptible to nerve injury as the superior, inferior, medial, lateral, central or the nipple-areola complex (NAC)<sup>21</sup>.

In surgery of the mammary gland, preserving the innervation of the nipple-areola complex has become a fundamental matter of importance. Nerve injuries affecting the NAC are most commonly expected during breast reduction surgery<sup>7</sup>.



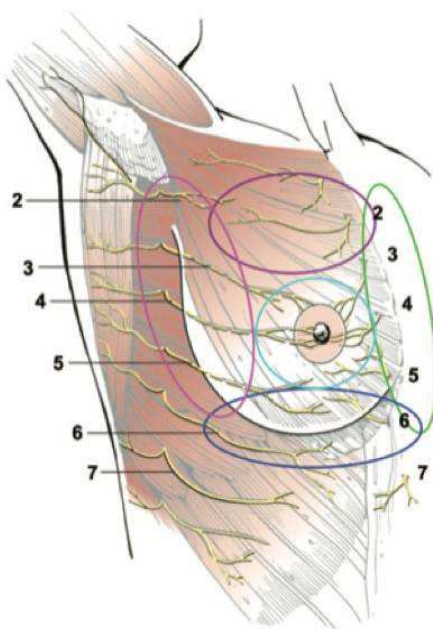


Fig. 2. Ducic's danger zones for nerve injuries, resulting in chronic postoperative breast pain

The mammary gland is innervated by the medial branches of the first to sixth intercostal nerves and the lateral branches of the second to seventh intercostal nerves<sup>21</sup>.

Innervation of the NAC is supplied by the anterior and lateral branches of the third, fourth and fifth intercostal nerves. The nipple is innervated by the anterior and lateral branches of the fourth intercostal nerve with additional innervations supplied by the lateral branches of the third to fifth nerves and the anterior branches of the second to fifth<sup>7, 22</sup>.

The anterior branches run superficially through the subcutaneous tissue emerging superficially in the medial border of the areola. These branches can be damaged when the areola size is reduced. The lateral branches pass deeply through the pectoral fascia ending in the superficial posterior border of the complex in 93% of cases. These branches are damaged when the tissue is resected occurring most frequently during the breast reduction technique using the superior pedicle (Lejour, Lassus)<sup>7, 22</sup>.

In breast augmentation, transareolar access can damage the third and fourth intercostal branches, inframammary incisions can injure the fifth and sixth intercostal nerves, transaxillary access may injure the second intercostal nerve and incisions made in the infraumbilical region (not currently used) can damage the tenth. In breast reconstruction the third to seventh intercostal nerves may be damaged, including the lateral, inferior and medial zones. During mastopexy the third and fourth intercostal nerves are damaged with the central zone of the breast being predominantly affected. The most common nerve injury presenting in cases of breast reduction is caused by a simultaneous injury affecting the central, inferior and lateral zones. In light of this, the majority of authors (Giorgiade, McKissock and Wuringuer) agree that techniques using the inferior pedicle are the only ones where innervation of the NAC is preserved<sup>7, 21</sup>.

Some authors do not recognize the importance of nerve injuries to the NAC, making reference to reports of reinnervation with free-nipple-grafts through the dermal plexus using the supraclavicular and third intercostal nerve<sup>22</sup>.

7. Body contouring

The neuropathies reported in body contouring procedures can be due to direct nerve injury, compression or traction.

The position of the patient, appropriate cushioning and knowledge of the anatomy are crucial to avoid nerve injury<sup>16</sup>.

Temporary paresthesia is frequently reported around the site of surgery owing to direct laceration of the cutaneous nerves. Tight clothing can also elicit this effect where temporary inflammation causes paresthesia fading after 48 hours or once the external compression has been removed<sup>16</sup>.

Direct nerve injuries which have been reported include those to the lateral femoral cutaneous nerve, the iliohypogastric nerve and the ilioinguinal nerve during abdominoplasty procedures.

The lateral femoral cutaneous nerve is the longest branch of the lumbar plexus emerging from the dorsal branch of the second, third and fourth lumbar nerves<sup>23</sup>.

The lateral femoral cutaneous nerve can be located 2cm medial to the anterior superior iliac spine. It passes through psoas major emerging from its lateral inferior border advancing through the inguinal ligament towards the thigh<sup>16, 23</sup>.

In the thigh, the anterior division of the femoral nerve gives off cutaneous branches which supply sensation to the anterior surface of the thigh and muscular branches to the pectineus and sartorius muscle<sup>23</sup>.

The posterior division of the femoral nerve originates from the saphenous nerve which supplies sensation to the anterior and medial part of the leg. Its muscular branches innervate the quadriceps femoris. A weak patellar tendon reflex is the clearest objective sign of femoral neuropathy. This causes instability of the knee joint by weakness of the quadriceps. Abdominoplasty is the most frequent cause of damage to this nerve, especially when retractors are used. Transverse incisions of the abdomen and a thin body habitus are also additional risk factors<sup>23</sup>.

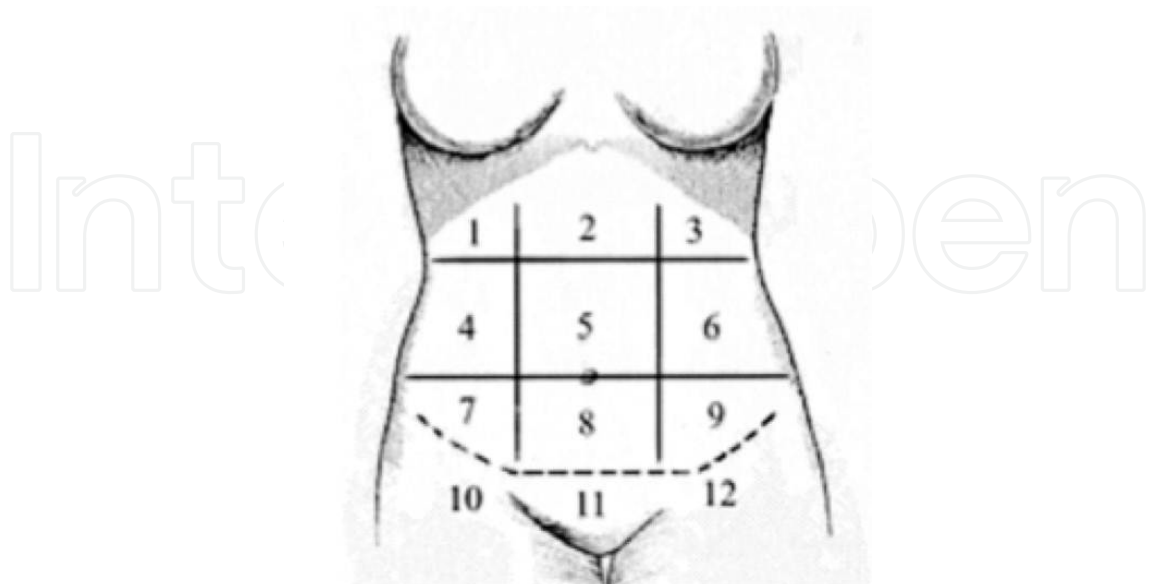


Fig. 3. Bufoni’s zones to evaluate sensibility of the abdomen after abdominoplasty. Zone 4 is the area that takes longer time for recovery and sometimes will never recover.

Gluteal lipoinjections are another one of the aesthetic surgical procedures where complications of this type are described. These include damage to the sciatic nerve which can occur in three different ways: direct injury by the cannula, extrinsic compression by injected adipose tissue or intrinsic compression by accidental injection of fat into the nerve sheath. The majority of minor injuries present as transient paresthesia or hyperesthesia and self-limiting muscle weakness but serious injuries such as axonotmesis of the nerve can also present in this way.<sup>1</sup>

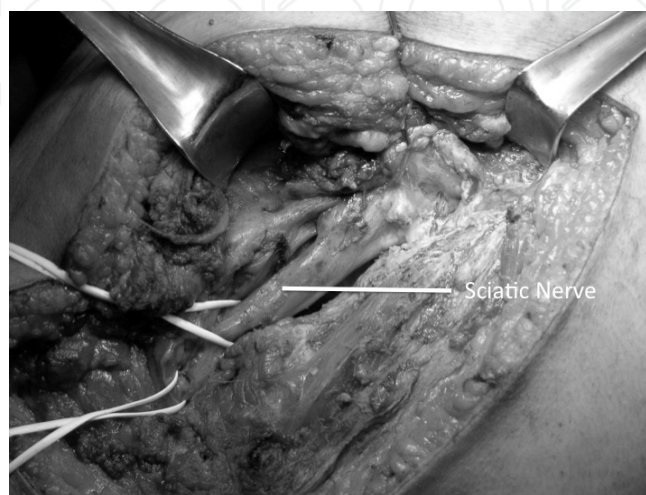


Fig. 4. Sciatic nerve lipoinjected during a gluteal lipoinjection. We reported good recovery after neurolysis.

In procedures on the gluteal region, Meieta reports a rate of 20% of transient paresthesia in the intramuscular region following gluteal implantation which returns to normal after three weeks of treatment with gabapentin<sup>8</sup>.

Bruner et al. report transient sciatic paresthesia in 4% of patients for two to three weeks in 261 patients and a transient loss of sciatic motor function in two patients (1.5%) with restoration of motor function in one to two weeks and an improvement in the paresthesia in one to two months.

Mendieta describes a frequency of transient paresthesia in less than 1% of gluteal lipoinjections and Restrepo & Ahmed also report this outcome without quantifying the amount<sup>8</sup>.

With this in mind it is important to have as thorough an understanding of the gluteal region as it is for the rest of the body's anatomy.

## 8. Aesthetic surgery on the limbs

The medial antebrachial cutaneous nerve can be damaged during brachioplasty. An incidence of 6% has been reported with the presence of paresthesia that resolves over the course of 13 months up to the most severe injury being complex regional pain syndrome type II<sup>9</sup>.

The medial antebrachial cutaneous nerve and the medial brachial nerve originate from the medial cord in 78% of cases and from the inferior trunk in 22%. It emerges from the axilla travelling medially to the brachial artery. It runs adjacent to the basilic vein or posterior to it. Although not all authors agree that the nerve runs continuously alongside the basilic vein its location in relation to the cubital nerve is medial and posterior<sup>9,16</sup>.

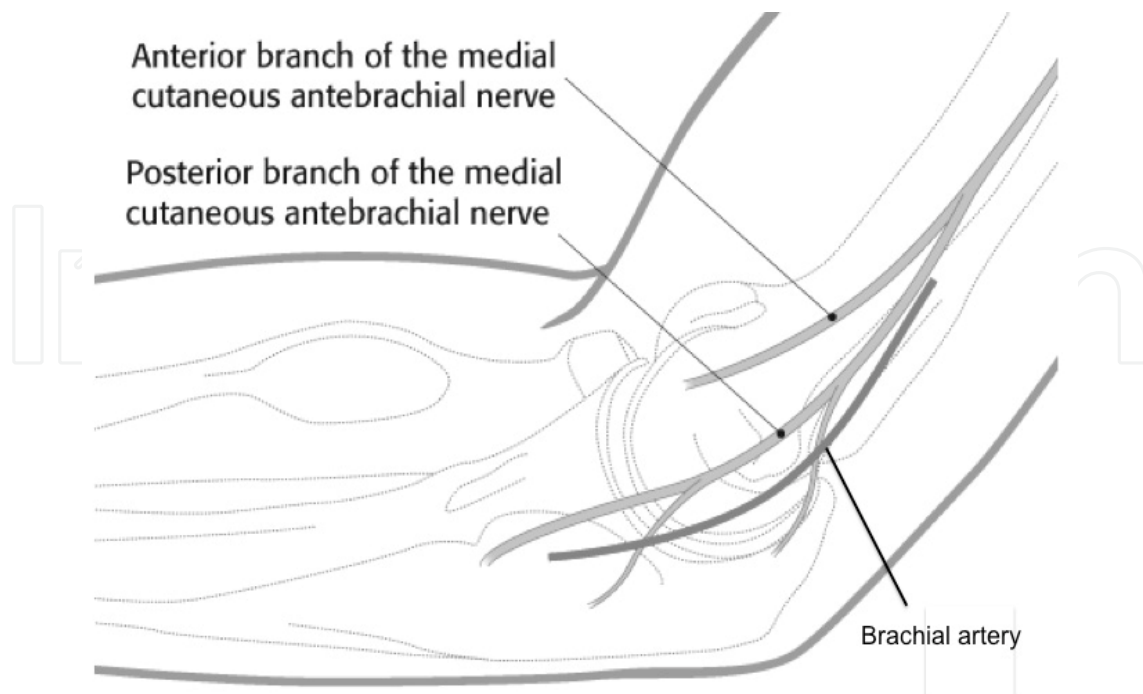


Fig. 5. Medial cutaneous branch and his terminal branches, anatomy landmarks.

The medial antebrachial cutaneous nerve and the medial brachial nerve are two constant structures which run below the deep fascia on the edge of the intermuscular septum in the arm, perforating the fascia as it moves superficially to approximately 14cm to the medial condyle (from 8 to 21cm) dividing itself into two branches, anterior and posterior. The posterior branch innervates the region peripheral to the medial epicondyle while the anterior branch moves towards the proximal end of the forearm to innervate it. From the site where it becomes superficial, the nerve perforates the deep fascia, this is what causes the risk of damage during brachioplasty. This risk is greatest when the surgical site is located in the intermuscular septum, a location preferred by many authors, since it is where scarring can easily be hidden.

To avoid injury during brachioplasty it is advisable to leave a margin of 1cm of adipose tissue around the deep fascia during the surgical procedure<sup>9</sup>.

In the lower limb, damage to the medial sural cutaneous nerve and the medial saphenous nerve can occur during calf implantation. This can be avoided by preserving the fascial connection across the medial aspect of the leg<sup>24, 25, 26</sup>.

## 9. Medical treatment

Early identification of nerve injury is important to initiate therapeutic intervention<sup>16</sup>.

Once the injury has been diagnosed and the extent of it has been determined, one can offer conservative management for those who present with first or second degree paralysis; the re-myelination and regeneration of the nerve should lead to a complete recovery. In these cases physical therapy will also help with the restoration of function<sup>27</sup>.

## 10. Drugs

There are drugs which are indicated for use in the conservative management of the patient's injury, as adjuvant therapy to the surgical procedure whose primary or secondary function is to help with nerve regeneration<sup>28</sup>.

Although there are not enough studies, the use of steroids in nerve injuries is safe and probably effective when administering a dose of 1 mg/kg/day for 7-10 days or with steroid injections if there are no contraindications to their use<sup>28</sup>.

Other drugs used in the regeneration of nerve fibres include Etioxine, Zofenopril, Nimodipine and Tacrolimus.

Other drugs can be used but their function is to control neuropathic pain and include Gabapentin, B Complex and Pregabalin.

## 11. Surgical treatment

The estimated extent of axonal loss is the best indicator of expected recovery. The injuries which show less than 50% of sensory/motor loss will show recovery, in some cases over the course of a year. However if after four months of treatment the patient still does not show signs of nerve repair and the EMG does not show signs of nerve regeneration one ought to consider surgical intervention<sup>2</sup>.

In the case of nerve injuries with axonotmesis demonstrated by electrical conduction studies, one ought to carry out end-to-end (primary) neurorrhaphy as soon as possible.

When it is possible, this procedure offers better results compared with injuries that are repaired using interposition nerve grafts or by nerve transfers. Nerve transfers can sometimes cause synkinesis in the face<sup>13</sup>.

Nerve repair can be epineurial and perineurial or one can use surgical adhesives for the apposition of nerves without needing to perform neurorrhaphy<sup>14</sup>.

One ought to follow the basic principles of nerve suturing which are to alleviate the tension and to avoid excessive scarring and fibrosis at the site of anastomosis<sup>14</sup>.

Other alternatives are nerve conduits which are currently used for the interposition of nerve grafts and cross-face neurotizations. In some cases though it may not be possible to sacrifice a healthy nerve<sup>14</sup>.

And finally, in other procedures one may also consider the use of muscle replacement and aesthetic treatments.

Nowadays the use of stem cell injections and growth factors is being added to all surgical techniques<sup>14</sup>.

## 12. Prevention

In each surgical procedure it is recommended that the neuronal structure be preserved as well as taking caution when using different surgical positions to avoid nerve injuries especially when the patient is in the prone position since this has been known to cause vascular events and nerve injuries such as plexopathy<sup>12</sup>.

Nerve injuries during surgery are not always avoidable and sometimes lead to permanent motor and/or sensory loss.

During the surgical procedure one ought to use blunt instruments for the dissection, avoid the use of manoeuvring or blocking and also avoid excessive use of electrocautery.



Being conscious of the possible appearance of nerve injuries one can take appropriate measures to avoid them and early detection of the injury will help the recovery of the patient.


### 13. References

- [1] Cárdenas A, Rodriguez J, Leon D, Taylor J, Gutierrez C. Bilateral Sciatic Nerve Axonotmesis After Gluteal Lipoaugmentation. *Ann Plast Surg*. 63: 4, 2009.
- [2] Kořmuřcuř F, Zwolak P, Benditte-Klepetko H, Deutinger M. Management Strategies for Peripheral Iatrogenic Nerve Lesions. *Annals of Plastic Surgery*. Volume 54, Number 2, 2005.
- [3] Grotting J, Beckenstein M. Cervicofacial Rejuvenation using ultrasound- assisted lipectomy. Vol 107. No. 3. 2001
- [4] Zani R, Fadul R, Dias Da Rocha M, Santos R, Chaves m, Masako L. Facial nerve in rhytidoplasty: anatomic study of its trajectory in the overlying skin and the most common sites of injury. *Annals of Plastic Surg* Volume 51, number 3. 2003.
- [5] Cordier B, De la Torre J, Al Hakeem M, Rosenberg L. Rejuvenation of the midface by elevating the malar fat pad: review of technique, cases and complications. *Plast. Reconstr. Surg*. 110: 1526, 2002.
- [6] Chang S, Pusic A, Rohrich R. A systematic review of comparison of efficacy and complication rates among face lift techniques. *Plast. Reconstr. Surg*. 127: 423, 2011.
- [7] Schlenz I, Rigeñ S, Schemper M, Kuzbari R. Alteration of Nipple and Areola Sensitivity by Reduction Mammoplasty: A Prospective Comparison of Five Techniques. *Plast Reconstr. Surg*. 115: 743, 2005
- [8] Bruner T, Roberts T, Nguyen K. Complications of buttocks augmentation: Diagnosis, management and prevention. *Clin in Plastic Surg*. 33 (2006) 449. *Clin Plastic Surg* 33 (2006) 449-466
- [9] Knoetgen J, Moran S. Long-term outcomes and complications associated with brachioplasty: a retrospective review and cadaveric study. *Plast. Reconstr. Surg*. 117: 7. 2219. 2006.
- [10] Niechajev I. Calf Augmentation and Restoration. *Sweden Plast. Reconstr. Surg*. 116: 295, 2005
- [11] Aiache A. Calf Implantation. *Plast. Reconstr. Surg*. 83 : 1989.
- [12] Shermak M, Shoo B, Deune G. Prone positioning precautions in plastic surgery. *Plast. Reconstr. Surg*. 117: 5. 1584. 2006.
- [13] Frijters E, Hofer S, Mureau M. Long-term subjective and objective outcome after repair of traumatic facial nerve injuries. *Ann Plast Surg* 2008; 61: 181-187.
- [14] Greywoode J, Hao H, Artz G, Heffelfinger R. Management of traumatic facial nerve injuries. *Facial Plastic Surgery* Vo. 26.No. 6.2010
- [15] Hadlock T, Kowaleski J, Lo D, Mackinnon S, Heaton J. Rodent facial nerve recovery after selected lesions and repair techniques. *Plast. Reconstr. Surg*. 125: 99, 2010.
- [16] Michaels J, Coon D, Rubin P. Complications in postbariatric body contouring: postoperative management and treatment. *Plast. Reconstr. Surg*. 127: 1693, 2011
- [17] Grotting J, Beckenstein M. Cervicofacial Rejuvenation using ultrasound- assisted lipectomy. Vol 107. No. 3. 2001
- [18] Rodriguez-Bruno K, Papel D. Rhytidectomy: principles and practice emphasizing safety. *Facial Plastic Surgery* Vo. 27.No. 1. 2011



- [19] Rovak J, Tung T, Mackinnon S. The surgical management of facial nerve injury. *Seminars in plastic surgery* . Vol. 18 No. 1. 2004.
- [20] Saylam C, Ucerler H, Orhan M, Uckan A, Cuneyt O. Localization of the mandibular branch of the facial nerve. *The Journal of Craniof Surg.* Vol 18, Number 1. 2007.
- [21] Ducic I, Seibith L, Iorio M. Chronic postoperative breast pain: danger zones for nerve injuries. *Plast. Reconstr. Surg.* 127: 41, 2011
- [22] Greuse M, Hamdi M, DeMey A. Breast sensitivity after vertical mamaplasty. *Plast Reconstr Surg.* Vol. 107, No. 4. 2001
- [23] Pechter E, Smith P. Transient Femoral Neuropathy after abdominoplasty. *Ann Plast Surg* 2008;61: 492-493
- [24] Gustein R. Augmentation of the Lower Leg: A New Combined Calf-Tibial Implant. *Plast. Reconstr. Surg.* 117: 817, 2006.
- [25] Niechajev I. Calf Augmentation and Restoration. *Sweden Plast. Reconstr. Surg.* 116: 295, 2005.
- [26] Aiache A. Calf Implantation. *Plast. Reconstr. Surg.* 83 : 1989.
- [27] Novak C. Rehabilitation strategies for facial nerve injuries. *Seminars in plastic surgery.* Vol. 18 No. 1. 2004.
- [28] Lindsay R, Heaton J, Edwards C, Smitson C, Hadlock T. Nimodipine and Acceleration of Functional Recovery of the Facial Nerve After Crush Injury. *Arch Facial Plast Surg.* 2010;12(1):49-52
- [29] Matarasso A, Elkwood A, Rankin M, Elkowitz M. National Plastic Surgery Survey: Face Lift Techniques and complications. *Plast Reconstr Surg* 2000;106:1185-1195
- [30] Behmand R, Guyuron B. Endoscopic Forehead Rejuvenation, long term results. *Plast Reconstr Surg* 2006; 117(4):1137-1143
- [31] Bufoni FA, Xerfan N, Masako FL, Sensibility of the abdomen after abdominoplasty. *Plastic Reconstr Surg.* 2004;114:577-582
- [32] Seror P. Accesory nerve lesion after cervicofacial lift: clinical and electrodiagnosis evaluations of two cases. *Muscle Nerve* 2009;39(3):400-405

IntechOpen



## **Peripheral Neuropathy - Advances in Diagnostic and Therapeutic Approaches**

Edited by Dr. Ghazala Hayat

ISBN 978-953-51-0066-9

Hard cover, 206 pages

**Publisher** InTech

**Published online** 29, February, 2012

**Published in print edition** February, 2012

Over the last two decades we have seen extensive progress within the practice of neurology. We have refined our understanding of the etiology and pathogenesis for both peripheral and central nervous system diseases, and developed new therapeutic approaches towards these diseases. Peripheral neuropathy is a common disorder seen by many specialists and can pose a diagnostic dilemma. Many etiologies, including drugs that are used to treat other diseases, can cause peripheral neuropathy. However, the most common cause is Diabetes Mellitus, a disease all physicians encounter. Disability due to peripheral neuropathy can be severe, as the patients suffer from symptoms daily. This book addresses the advances in the diagnosis and therapies of peripheral neuropathy over the last decade. The basics of different peripheral neuropathies is briefly discussed, however, the book focuses on topics that address new approaches to peripheral neuropathies.

### **How to reference**

In order to correctly reference this scholarly work, feel free to copy and paste the following:

Alexander Cárdenas-Mejía, Xitlali Baron, Colin Coulter, Javier Lopez-Mendoza and Claudia Gutiérrez (2012). Neuropathies Associated with Cosmetic Surgeries, *Peripheral Neuropathy - Advances in Diagnostic and Therapeutic Approaches*, Dr. Ghazala Hayat (Ed.), ISBN: 978-953-51-0066-9, InTech, Available from: <http://www.intechopen.com/books/peripheral-neuropathy-advances-in-diagnostic-and-therapeutic-approaches/neuropathies-associated-with-cosmetic-surgeries>

**INTECH**  
open science | open minds

### **InTech Europe**

University Campus STeP Ri  
Slavka Krautzeka 83/A  
51000 Rijeka, Croatia  
Phone: +385 (51) 770 447  
Fax: +385 (51) 686 166  
[www.intechopen.com](http://www.intechopen.com)

### **InTech China**

Unit 405, Office Block, Hotel Equatorial Shanghai  
No.65, Yan An Road (West), Shanghai, 200040, China  
中国上海市延安西路65号上海国际贵都大饭店办公楼405单元  
Phone: +86-21-62489820  
Fax: +86-21-62489821

© 2012 The Author(s). Licensee IntechOpen. This is an open access article distributed under the terms of the [Creative Commons Attribution 3.0 License](https://creativecommons.org/licenses/by/3.0/), which permits unrestricted use, distribution, and reproduction in any medium, provided the original work is properly cited.

IntechOpen

IntechOpen