

We are IntechOpen, the world's leading publisher of Open Access books Built by scientists, for scientists

6,900

Open access books available

186,000

International authors and editors

200M

Downloads

Our authors are among the

154

Countries delivered to

TOP 1%

most cited scientists

12.2%

Contributors from top 500 universities



WEB OF SCIENCE™

Selection of our books indexed in the Book Citation Index
in Web of Science™ Core Collection (BKCI)

Interested in publishing with us?
Contact book.department@intechopen.com

Numbers displayed above are based on latest data collected.
For more information visit www.intechopen.com



How Dentistry Can Help Fight Osteoporosis

Plauto Christopher Aranha Watanabe,
Marlivia Gonçalves de Carvalho Watanabe and Rodrigo Tioosi
*¹São Paulo University, Ribeirão Preto Dental School
Brazil*

1. Introduction

The late 20th century has brought to many patients a promising horizon: the lust of aging. Implicit in this "present" in longevity, however, is the known adverse changes in body tissues. The consequences of aging often involve the risk of osteoporosis, leading to an impaired quality of life of the elderly patients. Morphological and functional oral sequelae of aging are well documented in dental literature, but not those resulting from osteoporosis. Many authors have cited the possible correlation between age, systemic osteoporosis, periodontal disease, tooth loss, and changes in quantity and quality of bone of the maxilla and mandible. The restoration of occlusion for partially and totally edentulous patients often requires adequate bone therapy. Consequently, the frequent use of implant-supported prostheses for elderly patients who are routinely or potentially osteoporotic demand a better understanding of the relationship between osteoporosis, the stomatognathic system and muscle insertions. The jaw is constantly subjected to masticatory forces, movements during speech, breathing, and swallowing and is therefore an adequate structure for studying bone quality.

Panoramic radiography produces an image that displays both maxilla and mandible, the teeth, their supporting structures, and other important structures such as the nasal cavity, maxillary sinuses, temporomandibular joint, styloid process, and often to the bone hyoid. Although dentists routinely focus interest on the teeth and alveolar ridges when examining some panoramic radiograph, they should also be able to consider major changes in other structures that appear in the image (WHITE et al, 2004; FARMAN et al, 1993; WATANABE et al, 2004).

"The Selection of Patients for X-Ray Examination", US Food And Drug Administration Center for Devices and Radiological Health (FDA/CDRH), or "GUIDELINES FOR PRESCRIBING DENTAL RADIOGRAPHS", GPR, was first published in 1987 using the American population (USA), considering the total exposure to ionizing radiation arising from any source. In 2004, the GPR has been updated and published once more after hard work of a board of experts from the "American Dental Association and Food Drugs Administration" (ADA, 2004). The actual GPR expanded the use of panoramic radiography, proposing this technique as the first alternative for supplementary examination for dental diagnosis, recognizing the great technological advancement and improvement of the equipment for panoramic radiographs.

While the panoramic radiograph should not be prescribed primarily for the detection of the systemic conditions affecting the maxillomandibular region, we must recognize that in the

routine of health professionals, dentists, is used for initial assessment of dento-alveolar conditions, and it would be important that these dentists recognize certain conditions in these radiographic images that indicate the presence of systemic diseases. It should be understood that "systemic disease" means conditions that are spread inside the body, rather than localized primarily or only in tissues of the oral cavity. Below we will mention and describe some conditions on the images on panoramic radiographs that suggest significant disease extent, enough to affect quality of life and longevity of patients. A major disease that afflicts mainly men and women in old age is osteoporosis.

"Osteo" is Latin for bone. "Pores" means "full of pores or holes." Thus, osteoporosis means "bones that are full of holes." The bone mass reflects the balance between formation by osteoblasts and resorption by osteoclasts. Around the third decade of life the peak bone mass is reached, and then begins a slow process more continuous bone loss progresses with age. Osteoporosis is a multifactorial metabolic bone disease characterized by low bone mineral density (BMD), the deterioration of the microarchitecture of cancellous or trabecular bone, and changes in the physical properties of bone, leading to increased bone fragility with a consequent increase in fracture risk mainly of bones like the femur, forearm and spine (Fig.1). In the case of the oral cavity, the biggest consequence of this damage is the resorption of the alveolar ridge and possibly teeth loss as well as providing poor quality bone for the installation of oral implants. Nevertheless, it may also lead to mandibular fracture.




Fig. 1. Schematically drawing of the normal bone trabecular tissue, showing a trabecular net of thick and linked. Already to the right we see sharpening trabecular tissue and a net with bigger medullar spaces.

Osteoporosis is the process of quantitative loss of bone density per unit volume, with maintenance and reduction of the qualitative properties of mineralized bone. This change is responsible for the imbalance of the mechanics of the skeleton, increased number of fractures, notably in the spine, femoral neck and distal segment of the radio. The most common structural changes are the reduction of trabecular bone in size and number, and the thinning of the cortical region, with greater involvement of trabecular structure. This can also be seen in the maxillomandibular region, most obviously in the jaw, with decreased cortical thinning and inferior mandibular body.

Osteoporosis in postmenopausal women in the United States constitutes a public health problem because it affects 25 million women, with an annual average of 1.3 million fractures

and estimated cost of seven to ten billion dollars. In Brazil, although the fragility of our statistics do not allow further information, we can say that the problem worsens each year, mostly by increasing the relative population of menopausal women and increased life expectancy of this group. So, osteoporosis is a public health problem, affecting millions of people worldwide. Like any other disease, osteoporosis affects the self-esteem of the patient and leads to complications in the family routine, generating costs for the public health system in the patient treatment. These concepts resonate across the world, and especially in Brazil, a developing country with explicit socio-economic-cultural deficit.

Asymptomatic progression of osteoporosis, in conjunction with the possibility of catastrophic disability, this disorder is the biggest public health priority in many countries. Osteoporosis can progress asymptotically until a bone fracture or a dental loss. One in two women and one in eight men over age 50 will develop osteoporosis. If the disease occurs, 15% and 20% of women will need special care for long periods due to loss of the ability to manage basic activities at home. Half of the persons who suffered a hip fracture lose their ability to live independently, and around 20% of this persons will die within a year as a result of the fracture (COSMAN & LINDSAY, 2004), (Fig.2).

Osteoporosis is not only a woman's disease. Not as many men have it as women do – maybe because most men have more bone density. As they age, men lose bone density slowly than women. However, men also need to be aware of the risks of osteoporosis and men have more fractured femurs than women.

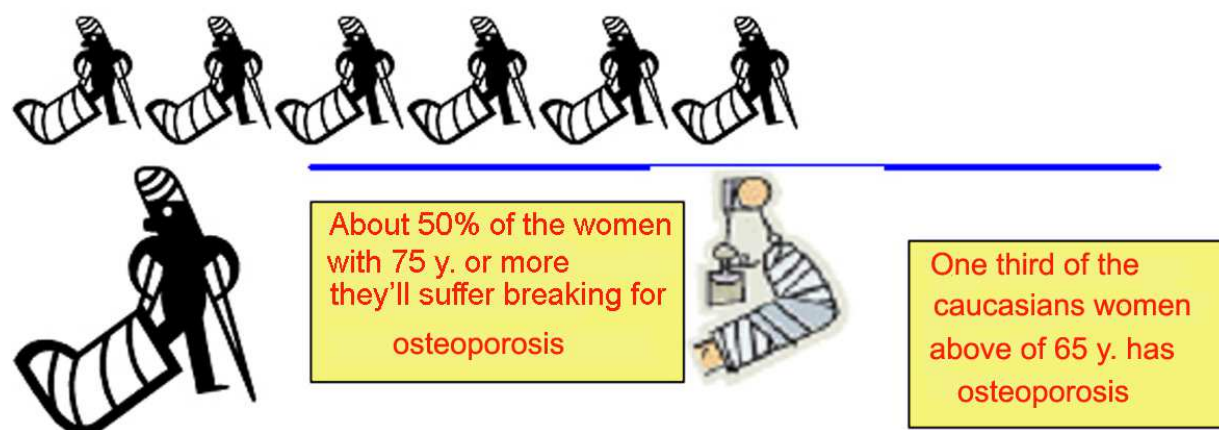


Fig. 2. Some data alarming epidemiologists on osteoporosis in the world.

In Brazil, the prevalence of osteoporosis is poorly understood (SS-HSPE, 1995); however, in 2001 the osteoporosis clinic at UNIFESP measured the use of public resources and the annual cost for patients with postmenopausal osteoporosis. The average annual cost for the patient was approximately \$442.00 per patient. However, some authors⁹ assessed the direct cost during hospitalization for an osteoporotic hip fracture in the private health system, such as health insurance coverage, and the authors concluded that the cost was approximately \$ 6.900/patient (KOWALSKI et al, 2001). The study, "Osteoporosis - 2000 of Brazil", developed by 300 medical experts, estimated that less than one-third of Brazilians who have osteoporosis diagnosis of disease, and that only 20% of those are receiving treatment (ARAUJO et al, 2006; MARQUES NETO & LEDERMAN, 1995).

2. Singular characteristics in geographical location

2.1 Emergent country

Food and / or nutrition are some of the main factors that affect bone quality as a whole, and significantly influence the osteoporosis disease in the world.

As to the geographical aspect, we should mention that Brazil, for example is between the equator and temperate zone just below the Tropic of Capricorn, which clearly favors the protection against the deleterious effects of osteoporosis, because fortunately, as a tropical country, received the largest part of the year the sunlight that is essential to activate vitamin D. Vitamin D (or calciferol) is a vitamin that promotes the absorption of calcium (after exposure to sunlight), essential for normal development of bones and teeth; it also acts as newly discovered immune system, heart, brain and in insulin secretion by the pancreas. This has primary function in the absorption of calcium in the body.

Among the environmental factors involved in osteoporosis, nutrition, particularly with respect to consumption of protein, dairy products and vegetables, has been named as a participant in the formation of bone mass (ANDERSSON 1999; RIZZOLI & BONJOUR, 1999; ROUSSEAU, 1997). The calcium and vitamin D during childhood seem to play an important role in the health of bones (WARDLAW, 1993). Retrospective studies in adults suggest that calcium intake in the first phase of development are associated with the risk of developing osteoporosis and fractures during adulthood (STALLINGS, 1997; VON MULHEN et al, 1999). However, we must consider the sensitivity of this nutrient absorption varies depending on the genetic constitution of the individual (MAY et al, 1994).

This privileged geographic location facilitates the cultivation of a variety of foods (from temperate and tropical climates). Fishing, and therefore the habit of eating fish is extremely encouraged by the fact that our country has an extensive Atlantic coast, more than 8000 km, and thus favors the fishery, which is quite diversified. Including food fish in the daily diet can greatly contribute to bone quality, mainly due to calcium that food provides. Fish is a major source of calcium along with other foods such as milk, yogurt, vegetables, nuts and cereals (Table 1).

This geographical location, yet is related to the sociological aspect, therefore, should remember the mixture among Indians, Portuguese and African blacks and among immigrants who came to Brazil from the nineteenth century, attracted by the opening of the immigration movement. Italian families, German, Portuguese, Spanish, Polish, Japanese and Arabs introduced their eating habits in the regions where they settled. These people, mainly Asians and Caucasians, are the main osteoporosis risk groups, owing much to the genetic characteristics. Even with respect to indigenous peoples, one of the most accepted theories of his presence in the Americas, is the migration of peoples from Asia across the Bering Strait (Bering Strait is a strait between Cape Dezhnev, the easternmost point of mainland Asian and Cape Prince of Wales, the westernmost of the American continent). During the last glacial era, with the recession of ocean water, the area of the Straits has become a natural bridge between Asia and the Americas, now called the Bering Land Bridge, where they could have reached America the people who first colonized). So you can see how confusing it is analyzing the DXA scans, which has standard tables to compare the bone mass values determined by tests of X-ray absorption, mainly due to the intense miscegenation of the population in Brazil (Fig. 3).

But we can go further in this confused analysis in our country, commenting on the various geographic regions of Brazil and food characteristics.






		
<p>The native indians of the Region North had as basic food the “mandioca”. The fish also represent an important parcel of the feeding, being the most consumed “tambaqui”, “traíra”, “piranha”, fished, sardine of river, “tucunaré”, “pacu” and “pirarucu” (called “cod the Amazônia”). All rich ones in sodium, potassium and calcium.</p>	<p>Beyond the influences aboriginal, Portuguese and black, the Northeast region received contributions from dutches, Frenchmen and English that had invaded the territory had dominated and it during a time. The result is a rich and varied culinary, that came to characterize the food of the region. With exception of the blacks, all the other peoples are group of risk osteoporosis.</p>	<p>The region Center-West, possesss innumerable families of colonists of the states of the South. These colonists had wide experience in cattle agriculture and modern. Of this form, its culinary was conditional to the resources of the environment, especially of fishes and the hunting, as: “pacu”, “piranha”, “golden”, “painted”, “anta”, “cotia”, “paca”, “capivara”, deer and alligator. Thus, this feeding is positive in relation osteoporosis.</p>
		
	<p>In the region Southeastern they are the states richest of the country. Its food received diverse influences, that follow the history of the settling: of the indians; Jesuits; tamers (bandeirantes); Italian immigrants, of the Spaniard and Arabs in <i>Rio de Janeiro</i>, and of the Germans and Italians. Here also influences we see it sociological of these European, caucasianos peoples, groups of osteoporosis risk. The South region was the one that received greater influence from immigrants. This because the tempering climate of the region was more similar to the European climate, facilitating the adaptation of the Italians, Germans, Poles and ucranianos, that if had established preferential in agricultural activities.</p>	

Table 1. Brazilian geographic regions and the main alimentary characteristics. Demographic census. Brazil, 2000.

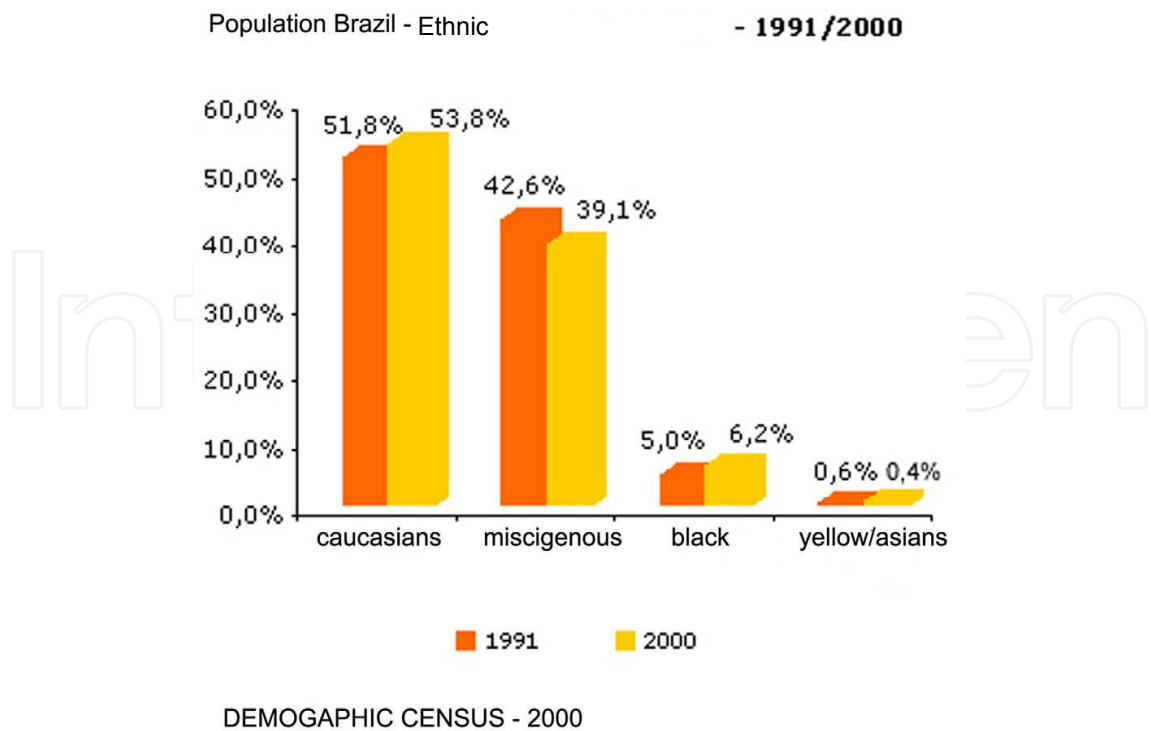


Fig. 3. Composition of the Brazilian population for race, 1991/2000 (IBGE-Brazilian Institute of the Geography and Statistic)

Caffeine, for example, is a food consumed by millions of Brazilians and their effect has been studied on bone quality. In 2002, Heaney conducted a literature review and concluded that "there is no evidence that caffeine has the harmful effect on bone status or calcium deposition in individuals who eat the recommended amount of calcium per day, or more than 3 cups of coffee. In our studies we have observed that there is a significant increase in the circulating calcium in rats that ingested caffeine daily, causing obvious radiolucency of the mandibular bone, the tibia and femur.

There are at least 31 recent cross-sectional studies, case control and cohort studies (observational studies are where individuals are selected or classified) according to exposure status, being followed to evaluate the incidence of disease, combining caffeine intake and bone health involving many thousands of patients (PINTO NETO, 2002). Aspects of bone health measured include BMD, its changes, the rate of fracture and osteoporosis. These observational studies could demonstrate only associations and not relationships of cause and effect.

Although the reviewed evidence is contradictory, the weight of evidence does not support the idea that beverages containing caffeine adversely affect bone health. The reason for the contradictory results is unclear. Taking as an example study, the inverse association observed before adjustment for obscure aspects between intake of caffeinated beverages and bone mass, disappeared after adjusting for other risk factors (JOHANSSON et al, 1992). It would also be possible that the intake of caffeinated beverages is acting as a marker for a true causal factor. It is known that there is an inverse relationship between milk intake and consumption of beverages containing cafeína (BAUER et al, 1993). It is possible, therefore, that a low intake of milk instead of a high intake of caffeinated beverages is the true cause of ill health óssea (HALLSTON et al, 2006). In 2009, some authors (WAUGH et al, 2009) published a systematic review of checking the risk factors for low bone mass in healthy

women aged 40-60 years. They found that there was good evidence that low body weight and Postmenopausal (PM) status are risk factors for low bone mineral density, and also found that there is good evidence that ingestion of alcohol and caffeine, and reproductive history were not factors risk. The results of a recent study (VONDRACEK et al, 2009), however, contradict these results. Changes in the lifestyle and healthy habits to favor the bones, such as calcium and vitamin D nutrition, regular exercise, limiting consumption of caffeine and alcohol, and the fact that tobacco smoking is not essential to the management of risk of osteoporosis. (Figure 4)

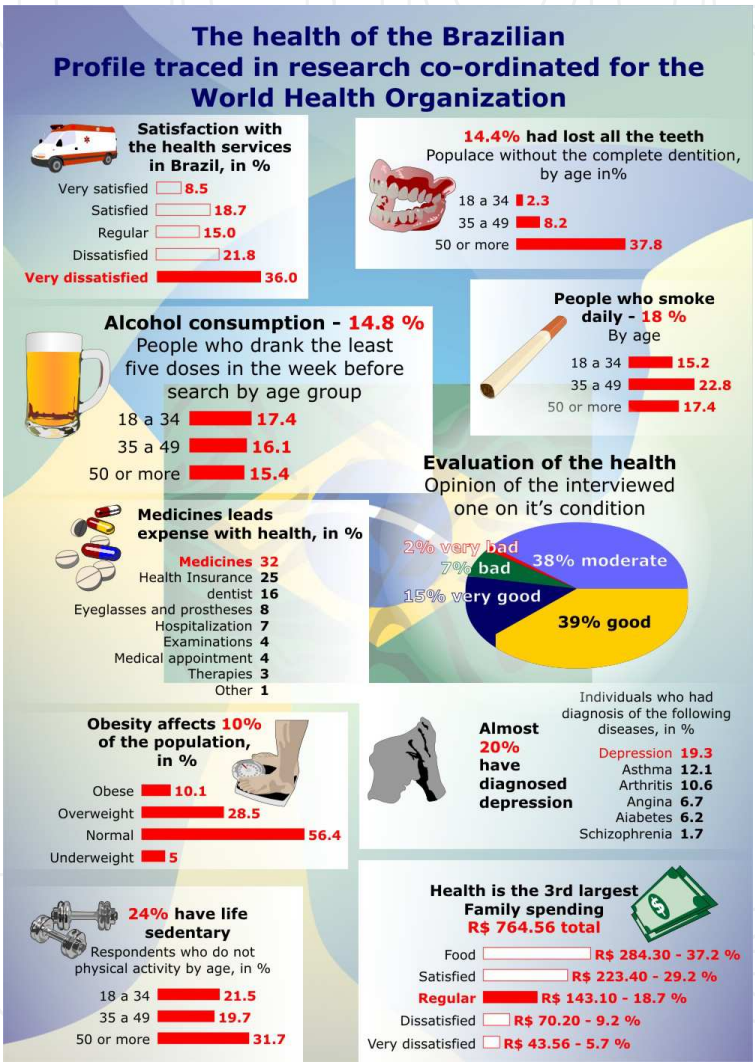


Fig. 4. Relative illustration to the health of the Brazilian (FIOCRUZ/WHO, 2008.)

Radiographic factors of osteoporosis in the skeleton include generalized osteopenia which is always more prominent in the column, cortical thinning, and accentuation of primary trabeculation and loss of the secondary trabeculation. Osteoporosis can be linked to pain, especially in the lower back. It can also result in pathological fracture, loss of stature, and severe kyphosis.

Radiological factors of osteoporosis in the mandible include relative radiolucency of the jaws and jaw and defining the reduced cortical, and erosions (Fig. 5 and 6). At the early stages of the disease is possible to find a sharp contrast from the oblique line of mandible,

mainly due to loss of trabecular bone mass, which leaves the body more mandibular radiolucent, accentuating the contrast effect in relation to the oblique line. The precision with which the panoramic radiographs can be used to assess the likelihood of a person having osteoporosis is still debated, with evidence being divided, polarized rather than for or against.

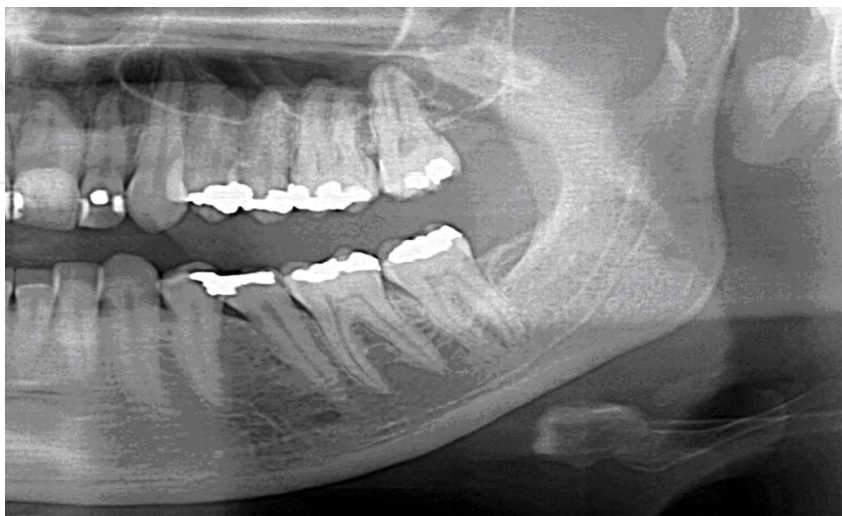


Fig. 5. Interest Region . Normal Mandibular inferior cortex – Cropped panoramics images

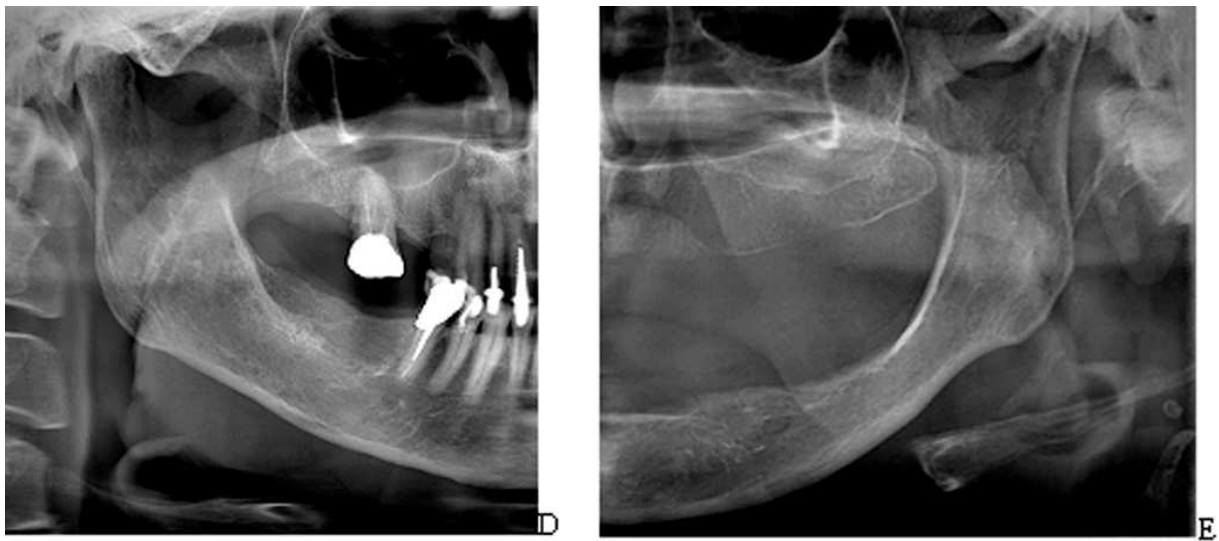


Fig. 6. Osteoporosis – Cropped panoramics images shows a relative radiolucency of both jaws with reduced definition and mandibular inferior cortex moderately eroded, evidence of lacunar resorption (right-D) or cortex severely eroded (left-E),

3. Population in developing countries will be the most affected

Currently, according to WHO, the majority of hip fractures due to osteoporosis happens in the countries of Europe and North America. This projection is based on the fact that the demographic changes that must occur within the next 50 years will significantly increase the number of elderly in Asia, Africa and South America. According to the Brazilian

Institute of Geography and Statistics (IBGE), the group 30 to 59 rose from 25% of the population (in 1940) to 32.9% (1998), and is expected to reach 40.2% in 2020. The elderly above 60 years, amounted to 12.4 million people in 1998 and may be 25 million over the next 21 years. We must emphasize that life expectancy measured in the last IBGE Sense is 73 years on average.

In Europe, every 30 seconds someone suffers a fracture due to osteoporosis. It is estimated that in 2050, Latin America and Asia, the incidence of hip fractures due to bone disease should be for one in two cases. In Asia, according to medical records, is considered more dramatic the expected increase in cases of hip fractures in the coming decades. Other studies show that in the Middle East will triple the number of hip fractures caused by disease in the next 20 years. Cosman & Lindsay, 2004.

4. Bone loss: Clinical implication

The major consequence of bone loss (PO) in our aging society is fracture. In the oral cavity could be considered tooth loss, affecting 26 million people in Brazil, according to the IBGE. Oral health of Brazilian social inequality is indicative of the country. According to the Brazilian part of the World Health Survey, released by Fiocruz (Oswaldo Cruz Foundation) and held last year at the WHO (World Health Organization), 14.4% of Americans have lost all their teeth (SZWARC W A L D & V I A C A V A, 2005).

Taking into account that the IBGE estimates 179 million in the current population in Brazil, that means about 26 million no longer have any natural teeth. The comparison between the social classes shows that, among the poorest, this percentage reaches 17.5%, and among the richest, is 5.9%. Fiocruz made the separation between classes by the number of consumer goods (televisions, refrigerators, etc.). The worst situation was found among women over 50 in poor families: 55.9%. That is, postmenopausal women are main group at risk for osteoporosis. The researchers compared risk factors for health. The data show that 10.1% of the population can be considered obese, according to the WHO standards, and that 28.5% of Americans are overweight. The percentage of underweight people is 5%. These people probably have very brittle bones, and thus risk of systemic osteoporosis. The rate of those who said they had drunk at least five servings of alcoholic beverages in the previous week is about 14.8%, a percentage that is higher in the younger age group (18-34 years), which reaches 17.4%. Daily smokers represent 18.1%, and the habit is lower among those between 18 and 34 -15.2%. It is a fact that excessive alcohol and smoking affects bone mass and quality of oral health. The poll found that 24% of the population is sedentary. This is a major factor influencing the quality of the bone skeleton.

4.1 Measurements based on radiographs

Many physicians believe that an X-ray may also be appropriate after experiencing a loss in height or a change in posture, or some alteration in the skeleton. This is an old concept that still exists. One should remember that this is a concept of more than 50 years, when radiology still worked with slow films, with technology of grains in emulsions, ecrans that emitted blue light, 16 times more radiation and chemical processing. Nowadays, radiology works with little radiation, X-ray equipments are more accurate, conventional films have the technology of tabular grains, ecrans that emit green light (more sensitive), and still digital

images, with ample possibility in computers that increase the diagnostic capacity. This has led professionals to change their thoughts in relation to the older concept.

4.2 X-ray absorptiometry: Dental radiography

X-ray absorptiometry is a technique widely utilized for measuring bone mineral density (BMD). The low correlation among densitometric results obtained for distinct bone sites valuation imposes the development of a technique for accurate mineral density assessment on maxillary and mandibular bones specifically, adequate for dentistry procedures. For maxillary and mandibular bone mineral density measurements by single energy x-ray computed absorptiometry, periapical intraoral radiographs can be taken using an aluminum densitometric scale. Watanabe et al, 2008 measured the density values on 55 adult patients that were arranged in four population groups, with distinction among maxillary and mandibular bone and patient gender. The measurements were statistically evaluated, resulting in the determination of the population reference data based on the average density and respective standard deviation for each group. Assuming one standard deviation as the confidence interval, the lower threshold for normality corresponds to bone mineral density of 2.00 mm for women maxillary bone, 3.28 mm for women mandibular bone, 3.88 mm for men maxillary bone and 5.45 mm for men mandibular bone. These thresholds were implemented on Cromox[®] DOMM 3.2.2 system, for normal and osteopenia distinct diagnosis, associated to low effective radiation dose on a technique with more comprehensive use in the population (WATANABE et al, 2008). (Figure 7 and 8)




Fig. 7. Prototypes III and IV of the densitometry scale (coins are used as a size reference).

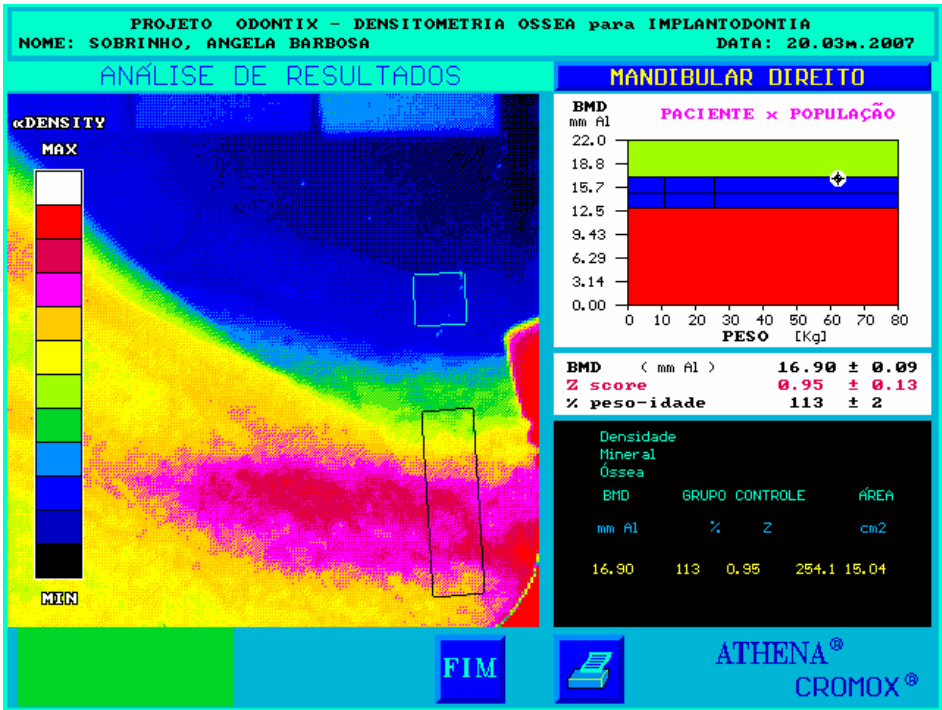


Fig. 8. Densitometric exam of the mandible in the Software Cromox

5. Radiographic signs of osteoporosis in dental radiography

5.1 Panoramic and oral radiography

Dentists are in a potentially valuable position for patient screening for signs of osteoporosis; significant portion of the population visits their dentist annually and dental radiographs are prescribed for many. In the last four decades, numerous researchers have reported that osteoporosis can be diagnosed through oral radiographs; panoramic radiography is widely used for routine dental examinations and it would be very useful to determine if radiographic changes in the mandible could show skeletal osteopenia and have an important role in detection of osteoporosis. Thickness of the inferior border of the mandible below the mental foramen has often been measured as the panoramic mandibular index (PMI) either directly or as a ratio of the thickness to the distance of the mental foramen from the inferior border. (Fig. 5)

The use of panoramic radiography is common in a dental setting and is also advocated by the International Guide to Prescription Radiographs⁴. Digital radiographs are an increasingly popular option in the clinic. Such images are composed of pixels with a specific numerical value for each one. Two important methods of evaluating the pixels in these images are Fractal dimension (FD) and Pixel Intensity (PI) analyses. FD is expressed numerically and consists in describing complex shapes and structural patterns in the bone. PI is a grayscale measure, ranging from zero (black) to 256 (white) in a 8-bit digital image (VON MULHEN et al, 1999). Because the panoramic radiograph is an exam more common and affordable than DXA, its application in the early detection of low bone mass would bring significant benefits for the treatment of osteoporosis (VON WOWERN, 1986).

The cardinal radiographic signs of osteoporosis in the skeleton include osteopenia generalized thinning and the accentuation of corticosteroids in the bones, and the accentuation of the trabecular bone. The factors include spontaneous fracture, and

traumatic, especially the spine, wrist, hip or spine, invagination at the base of the skull and bones of grainy skull (VON WOWERN, 1986). The main radiographic signs of osteoporosis in the maxilla and mandible (Figure 2) include a generalized radiolucency on both the maxilla and mandible, as evidenced by defining the cortical or accentuation of the maxillary sinus, nasal cavity, oblique line, and others. Where you can see some cervical vertebrae in panoramic radiography, the appearance of the "frame" of the bones can also be observed. A morphometric analysis of bone in cross section (VON WOWERN, 1986) showed that the structure of the jaw bones and jaw in dentate elderly, is characterized by cortical porous, relatively thin, with demineralization of the bone endosteum, as in other skeletal bones, and these changes age-related cortical tend to be more common in women than in men. The bones of the jaw and jaw variations between individuals and regional structures and density of trabecular bone may mask the decrease in bone mass that is related with gender and age, as seen in other trabecular bones of the skeleton. The methods for evaluating these age-related changes in the maxilla and mandible were listed by Bras et al, 1982.

6. Panoramic radiography

The integrity of the bone microarchitecture is an important element of the bone quality and contributes for the mechanical abilities of the bone (FARMAN *et al.*, 1993; TAGUCHI, 2004; BOUXSEIN, 2003; SEEMAN, 2003; WOWERN, 2001).

RESEARCHERS	THECNICS	Regions	Measures
Bras <i>et al.</i> (1982)	Panoramic Radiography	-----	Cortical width
Benson <i>et al.</i> (1991)	Panoramic Radiography	-----	Ratio: width of the cortical one with in the distance of the inferior edge of mental forame for the inferior edge of the jaw
Klemetti <i>et al.</i> (1994)	Panoramic Radiography	-----	Basal Cortical, classification: C ₁ ; C ₂ ; C ₃ , endosteals edge.
Kribbs <i>et al.</i> (1992)	Intramural film with Aluminun penetrometer	Gonio, mental forame, and mandibular molar region.	Bony density by microdensitometer.
Wowern (1993)	Dual-Foton absorciometria (DPA), mandible.	Basal of the mandibular molar region	Bone Mineral Content (BMC), g/cm ² .
Corten (1995) Horner <i>et al.</i> (1998)	X-rays Dual Emission (DXA)	Edentulus Mandible	BMC em g/cm ³ , both sides .
Bassi <i>et al.</i> (1999) Klemetti <i>et al.</i> (1995) Lindth <i>et al.</i> (1996) Taguchi <i>et al.</i> (1996)	CTQC Dual or Single Energy.	Mandible	Bone Mineral Density – cortical and trabecular bony, separately horizontal in mg/cm ³

Table 2. Original methods for evaluation of the changes of the bone of the jaw *in vivo*

6.1 Radio-morphometric indices (Table 2)

- Mental Index (MI) (LEDGERTON et al, 1997, 1999): the cortical thickness in the mental region can be measured using a modified technique from the primarily described by Ledgerton *et al.* Initially, the mental foramen is identified and then a line is drawn perpendicularly from the top edge of the mental foramen to the bottom edge of the mandibular body, where another line was drawn to serve as reference to obtain the mandibular cortical bone thickness at a sharp angle (normal greater than or equal to 3.0 mm) (Fig. 6-7);
- Panoramic mandibular index (PMI) (BENSON et al, 1991; ANDRADE et al, 2009), (Fig. 6-7)

The measurements can be made in the panoramic radiographs in the mental foramen area, with the aid of the RADIOIMP software (RADIO MEMORY LTDA, version 2.0). When opening the image of the panoramic radiograph, the program requests the calibration of the same, where the following information should be inserted:

1. Type of equipment used: e.g. SuperVeraviewscope.
2. Image Resolution: 300 dpi.
3. Equipment Magnification: 30%

After the simultaneous alteration of the brightness and contrast tool of the images for better visualization of the mental foramen area, the measurements can be initiated, according to the technique proposed by Benson et al, 1991 based in the technique of the Wical & Swoope (1974). The first step is the identification and the tracing of the mental foramen unilaterally; then, a parallel line will be drawn down the long axis of the mandibular body and tangent to the inferior border of each side. Later, the mandibular cortex will be measured, through a line drawn perpendicularly from the first and afterwards the height of the mental foramen will be also measured, given by the distance of the inferior border of the foramen to the base of the mandible. All the measured lines presented a 90° degree format. For better identification of the measured area, the zoom tool will be also used to facilitate the the measurements, as the presented values were around 0,3 cm (Figure 9 and 10).

The thickness of the mandibular cortex is divided by the distance between the mental foremen and the inferior mandibular cortex to obtain the PMI (BENSON et al, 1991).

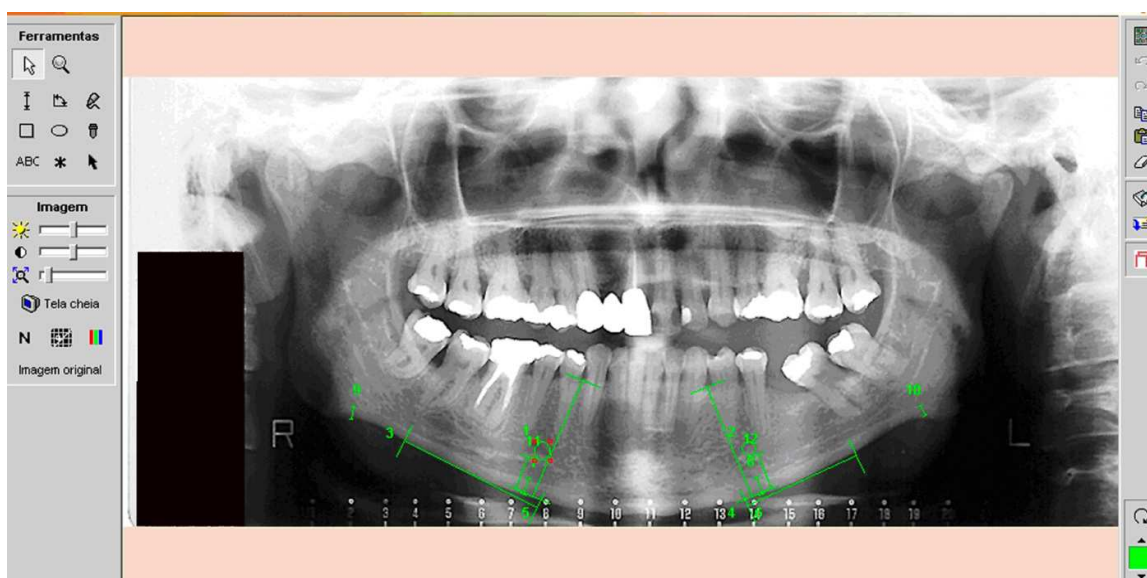

Fig. 9. Measurement of the Mental and Antigoniac indices. Radioimp-RADIO MEMORY LTDA, version 2.0

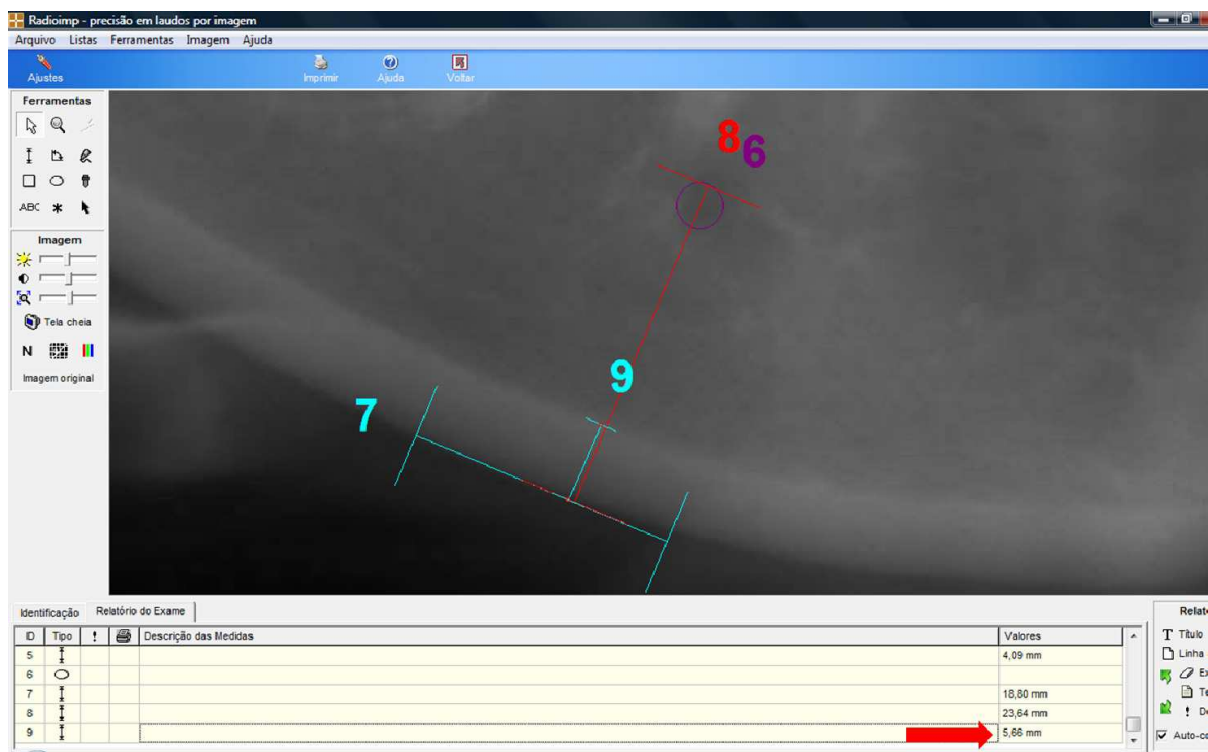


Fig. 10. Mental index in detail.

Klemetti Classification

The mandibular cortical shape is classified into one of three groups according to the method of Klemetti et al, which considers qualitatively the endosteal margin of mandibular cortical (KLEMETTI et al, 1994): C1 – the endosteal cortical margin is even and sharp on both sides, normal cortex (Figure 11); C2 – the endosteal margin has semi-lunar defects (lacunar resorption) or endosteal cortical residues on one or both sides (Figure 11), mild to moderate cortex erosion; C3 – the cortical layer forms heavy endosteal cortical residues and is clearly porous, severely eroded cortex (Figure 11).

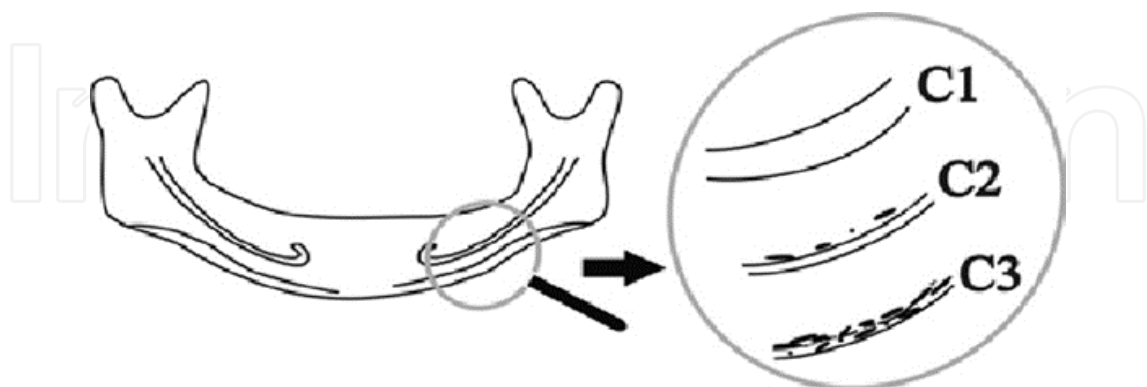


Fig. 11. Klemetti classification

- Antegoniac Index (AI) (DUTRA et al, 2005; MAHL et al, 2008) – mandibular cortical thickness measured on a line perpendicular to the mandibular cortex at the time that it crosses the tangent to the anterior edge of the industry (normal value greater than or equal to 3.2 mm);

- Goniac Index (IG) (DUTRA et al, 2005) – mandibular cortical thickness measured on the bisector of the angle between the tangent lines to the posterior border of the ramus and the mandibular base (normal greater than or equal to 1.0 mm). (Figure 12)

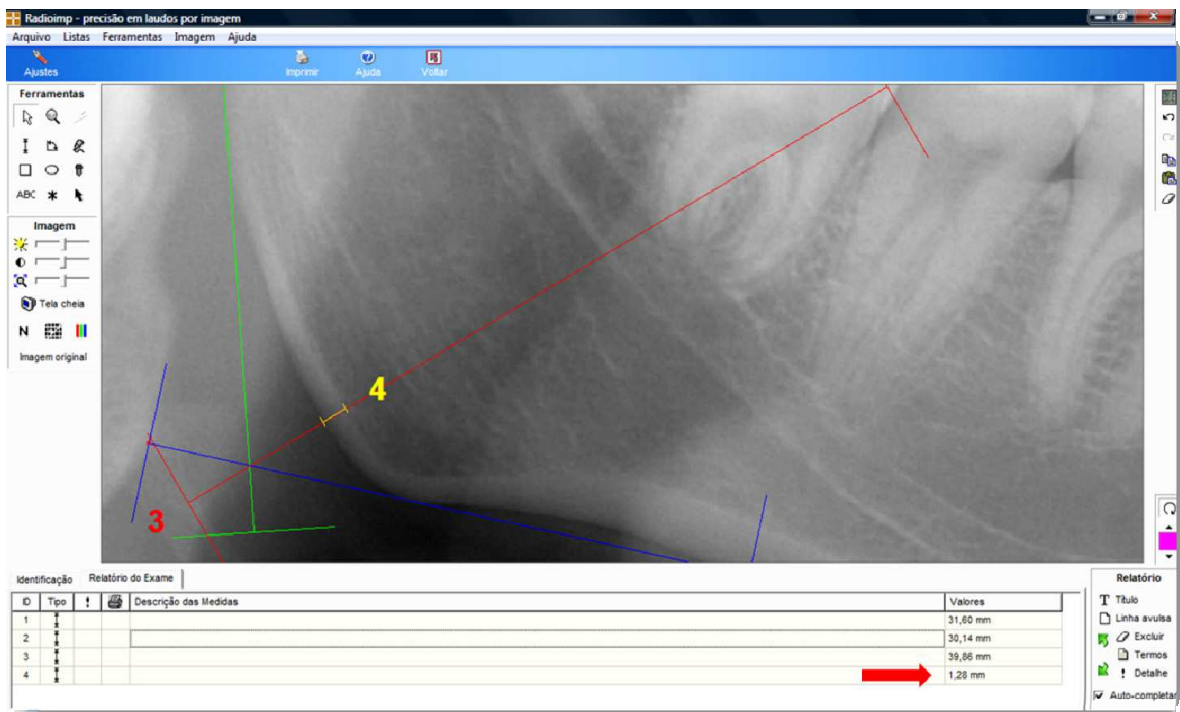

Fig. 12. Method of the measured Goniac Index (IG)

In the study of indices proposed in radio-morphometric mandible (TAGUCHI et al, 1995) it was found that the indices evaluated were reproducible; PMI and MI showed the highest sensitivity for detecting osteopenia / osteoporosis, but the specificity of the panoramic mandibular index was low, all the indices evaluated were able to identify low bone mass, however, only PMI and MI could differentiate patients with osteopenia / osteoporosis.

7. Evidence to support panoramic radiography for the diagnosis of osteoporosis

If persons at risk of osteoporosis can be screened using panoramic radiographs, screening of persons without subjective symptoms that are difficult to diagnose or persons without concern for osteoporosis, and instruction for only persons potentially having osteoporosis to undergo closer examination such as DXA or referral to a facility equipped with that apparatus allow early detection and early treatment of patients suffering from osteoporosis, and also reduce costs of the examination. Furthermore, the method used for this screening must be simple and usable even without having any special skills or requiring complicated operations.

The relationship between osteoporosis and oral signals was investigated to evaluate the possibility of using this as an indicator of osteoporosis. Some authors Taguchi et al 1995 studied 64 postmenopausal women aged between 50 and 70 years. Signals consisted of osteoporotic fracture of the thoracic spine seen on lateral radiographs of the lung. Oral signs were the number of teeth present, cortical thickness, alveolar bone resorption, and

morphological classification of the cortex in the panoramic radiograph. The number of teeth (N) was significantly correlated with the probability of fracture in the thoracic spine and was used to derive equation and the probability for the presence of fractures of the thoracic spine: probability value = $1 / (1 + z)$, where $Z_{age} = 18.68 + 0.29 - 0.27 N$. The probability value greater than 0.5 suggests the possibility of fractures in the thoracic vertebrae. It can be concluded that this equation combined with the findings in the panoramic radiograph could serve as a simple and useful tool for the dentist to evaluate the possibility of latent osteoporosis.

Panoramic radiographs are routinely used in most radiographic indications for the various types of dental patients. Such use as the primary complementary diagnostic exam is endorsed by N°. 453 Law of the Health Ministry - ANVISA - Brazil, a recommendation supported by the principle of radioprotection known as ALARA (As Low As Reasonably Achievable), i.e. we should always use the least amount of radiation possible, for better diagnostic information and for the well-being of the patient (SVS-MS, 1998).

In 1991 an index of bone mass radiomorphometric cortical (BENSON et al, 1991) the panoramic mandibular index (PMI). The MPI was obtained as the result of the ratio between the thickness of the mandibular inferior cortex (ECM) and the distance between the bottom of the mental foramen and the lower limit of the mandibular inferior cortex (DMC). Being that the higher the value of IPM, the lower jaw bone resorption. The differences in the index in a population of 353 adults, evenly divided by gender, age (30 to 90), and racial groups (blacks, Hispanics and whites) were evaluated with respect to the side, race, gender, and age, and combinations of these variables. Blacks were found in average IPM higher than in Hispanics or whites, who were demographically similar. Age-related changes comparing younger and older groups within each sex and racial group showed a significant decrease in average IPM with increasing age in black and Hispanic women. The average PMI in whites increases with advancing age.

The precision of the panoramic mandibular index in detecting patients with osteopenia and osteoporosis was studied and the authors concluded that the action taken in panoramic radiographs (IPM) of the patients studied was able to identify low bone mass and is able to differentiate patients with osteopenia and osteoporosis. Thus, IPM can be used by dentists to make an early approach that osteoporosis is a systemic condition that affects almost half the female population and brings many risks and damage their health (KNEZOVIC-ZLATARIC & CELEBIC, 2005).

Other authors (NAKAMOTO et al, 2003) assessed whether untrained dental practice would be able to determine whether panoramic radiographs women have low bone mineral density (OD). The researchers studied the concordance of the observer and the diagnostic efficiency in detecting low DOM in women. This was done when the appearance (normal or eroded) of the mandibular inferior cortex on dental panoramic radiographs of 100 postmenopausal women who had carried out assessments DOM lumbar spine and femoral neck. The intra-and inter-observer was assessed with kappa statistics. The diagnostic efficiency (sensitivity, specificity, and predictive values) was analyzed by comparing the two groups classified by the mandibular inferior cortex (women with normal cortex and women with eroded mandibular inferior cortex) with those classified by DOM (DOM women with normal and women with osteopenia or osteoporosis). The average sensitivity and specificity were 77% and 40%, respectively, when the DOM of the lumbar spine was used as the default, and 75% and 39%, respectively, when the DOM of the femoral neck

comprised the standard. Nineteen of the 21 untrained general dental practice showed a moderate to almost perfect intra-observer agreement. We conclude that dental panoramic radiographs could be used in clinical dental practice to identify postmenopausal women who have low DOM undetected.






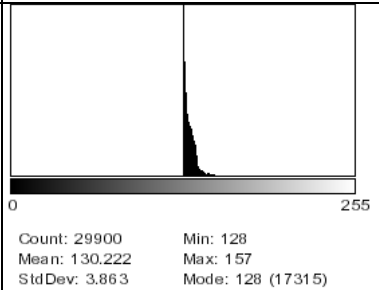




The frequency of osteoporosis was evaluated according to bone sites using a cross-sectional clinical study. The authors evaluated 610 densitometric examinations in relation to frequency of osteoporosis / osteopenia and agreement of the diagnosis according to the bone site. Despite the high correlation of BMD between the different bone sites, the frequency of osteoporosis varied with the site assessed. This study demonstrated that there is discordance in the BMD results according to the study area, affecting the occurrence of osteoporosis. Clinical trial for fracture risk assessment, the use of two different bone sites is the most appropriate procedure. For routine clinical dental surgeon, which includes the panoramic radiography in the care protocol and the jaws could be used for that purpose, and to request carpal radiography, which can add information of bone quality, especially in view of the proportions of trabecular and cortical bone of the phalanges of the hand and also in the cortical distal radio (ZANETTE et al, 2003).

In 2005, Klein conducted a study conducted with the objective to modify the skeletonization algorithm to quantify and create other radiographic images in panoramic radiographs. According to the study of observations and the evaluations that were made, it can be concluded that: 1) the part of the experiment related to the use of radiographic images by means of skeletonization on panoramic radiographs was effective because it increased the radius of the visual perception of the architecture in the trabecular bone and observed the trabeculae, the marrow spaces, such as micro-damage, or micro fractures, 2) despite the agreement between the examiners who have not reached recorded levels above 80%, a high significance in the overall proportion of black points and end points with the odds of a diagnosis concerning the existence or not of bone fragility. 3) results confirmed that the greater bone fragility actually revealed to be a loss of lamellae of trabecular bone architecture and its fairly large marrow spaces.

When studying osteoporosis, there is consensus that inexpensive methods of screening for osteoporosis are needed. The results of this study (WHITE et al, 2005) suggest that dentists have sufficient information to routinely identify people with low BMD using the images of panoramic radiography in dental practice. Radiographs with low doses of radiation, comparable to 4 bitewing radiographs, and the patients identified as having risk of osteoporosis should be referred to a primary health care for further evaluation.

The literature on oral radiographic signs of osteoporosis was revised in 2002, including alveolar bone resorption, and decreased inferior cortical mandibular (ICM). The authors concluded that the panoramic radiograph is an important tool that displays enough information to diagnose osteoporosis (WATANABE et al, 2002). Also in 2002, HORNER et al made a study evaluating the relative utility of clinical indices and radiographic diagnosis in patients with low skeletal bone mass between 135 on healthy pre-menopausal women, aged 45-55 years who sought dental treatment. The DOM was measured in the spine and hip using DXA and classified according to the WHO criteria for Caucasian women. In each patient the (ICM) was measured on panoramic radiographs. The body mass index (BMI) is a simple calculation of the estimated risk of osteoporosis (SCORE). All indexes, (ICM), BMI and SCORE showed significant correlation with skeletal bone density. Thus, the authors concluded that the thinning of the ICM <3mm in peri-menopausal healthy women is associated with low skeletal bone mass.

Three indicators of bone quality on panoramic radiographs were studied to determine the correlation with low DOM using DXA in a Brazilian population (Watanabe, 2003). Examination of the trabecular bone and ICM in the panoramic radiograph showed early signs of osteoporosis. There was significant correlation of these factors with the parameters measured as the percentage of trabeculae, fractal dimension and trabecular connectivity (Figures. 13 and 14).

 Fig. 7.1	Image interest area (original), 230 X 130 pixels	 Fig. 7.2	Image copy of the Figure 7.1, with "Gaussian blur" of 33 radius (pixels)
 Fig. 7.3	Result of subtraction Figures 7.1 and 7.2 images process	 Count: 29900 Min: 0 Mean: 2.109 Max: 20 StdDev: 3.189 Mode: 0 (16349)	Fig. 7.4 Histogram 7.3 image
 Fig. 7.5	Result of addition of the constant, 128 to 7.3 image	 Count: 29900 Min: 128 Mean: 130.222 Max: 157 StdDev: 3.863 Mode: 128 (17315)	Fig. 7.6 Histogram 7.5 image
 Fig. 7.7	Result of binary transformation (threshold) of the 7.5 image, with 128 brightness value	 Count: 29900 Min: 0 Mean: 234.302 Max: 255 StdDev: 69.641 Mode: 255 (27473)	Fig. 7.8 Histogram 7.7 image
 Fig. 7.9	Result of the erode process of the image Figure 7.7	 Count: 29900 Min: 0 Mean: 234.302 Max: 255 StdDev: 69.641 Mode: 255 (27473)	Fig. 7.10 Histogram of the image Figure 7.9

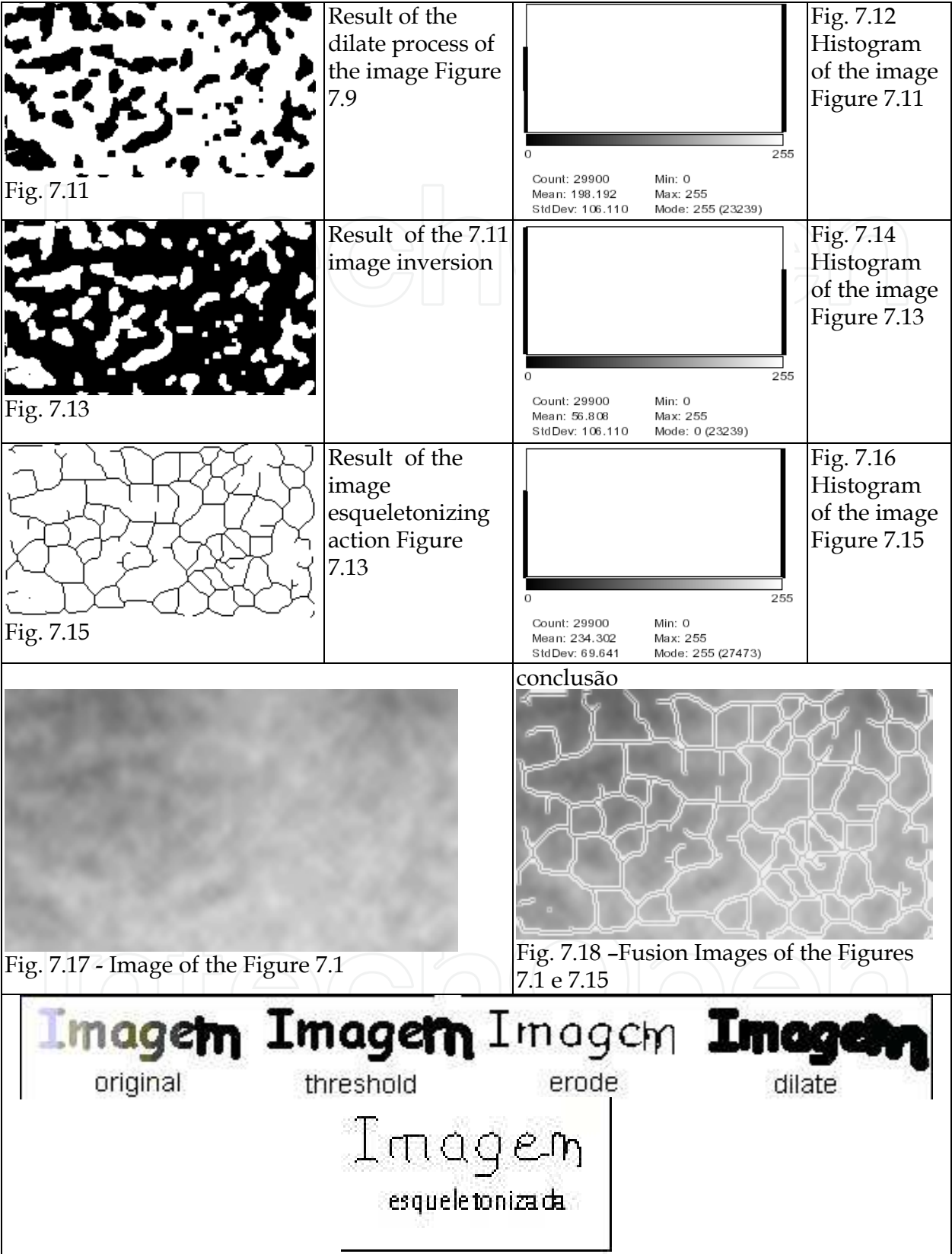


Fig. 13. Representation of the process of esqueletonized of region of mandibular interest, panoramic x-ray, for study of the percentage of trabeculae, fractal dimension and bony connectivity.

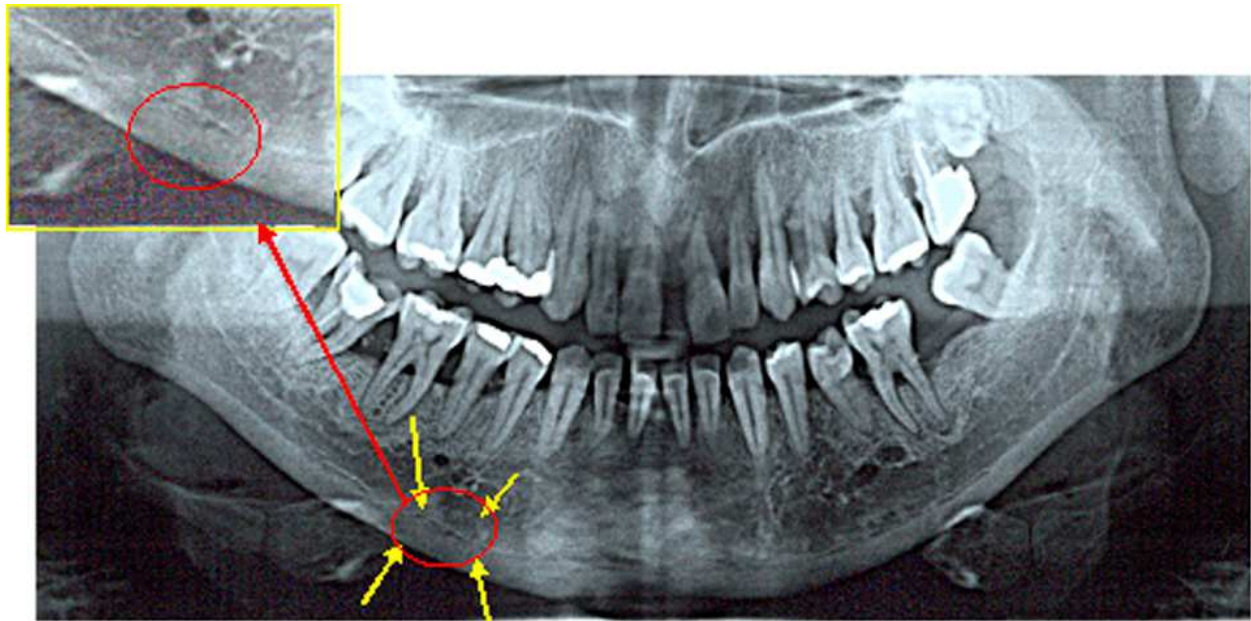


Fig. 14. Detail of the erosion in the mandibular inferior cortical

The diagnostic performance of measurements on panoramic radiographs (PR) and a self-assessment tool for osteoporosis (OST) that identifies women with spinal osteoporosis (WHO) on 159 pre-menopausal (PrM) and 157 post-menopausal (PsM) women with a history of hysterectomy, ovariectomy, or use estrogen were compared. The morphology of the ICM and its thickness were evaluated in the panoramic radiographs. The authors concluded that clinicians can refer women with suspected osteoporosis (PsM) in the column to undergo DXA based on tests conducted on panoramic radiographs with similar performance in the OST (TAGUCHI et al, 2004). The correlation of Klemetti rating for the PR using digital panoramic radiographs of Brazilian women was also studied in 2004 by TAGUCHI et al. Significant correlation was found with DXA of the forearm DOM, indicating that the panoramic radiograph is valuable in the identification of patients at risk for osteoporosis.

DOM and radio-morphometric linear parameters in elderly patients with different types of dentures were studied (DUTRA et al, 2005). Three parameters were measured: Mandibular inferior cortex thickness (CMT), the Antegoniac Index (IA) and Goniac Index (GA). The DOM was measured in the jaw with the use of a copper penetrometer. The results showed that there was a statistically significant difference between patients with all teeth and those with denture for all the measured radio-morphometric indices ($p < 0.001$). Also in 2005, LEE et al suggested that dentists had sufficient radiographic and clinical information to identify patients with osteoporosis. The author concluded that the changes found in the trabecular structures on panoramic radiographs supplemented with clinical information is an indicative of risk for hip fracture in elderly women.

It can be concluded that the dentist may suspect systemic risk of osteoporosis when the patient presents the following radiographic signs found in panoramic and periapical radiographs (WATANABE et al, 2004):

- Klemetti Class II or III, radiolucent spaces in the mandibular inferior cortical (Fig. 10);
- CIM thickness less than 3.0 mm;
- Disorganization of the basal mandibular trabecular bone with low numbers and low connectivity;

- sharp contrast between the branch / mandibular body and strengthening of structures, such as the oblique line (Figure 15).

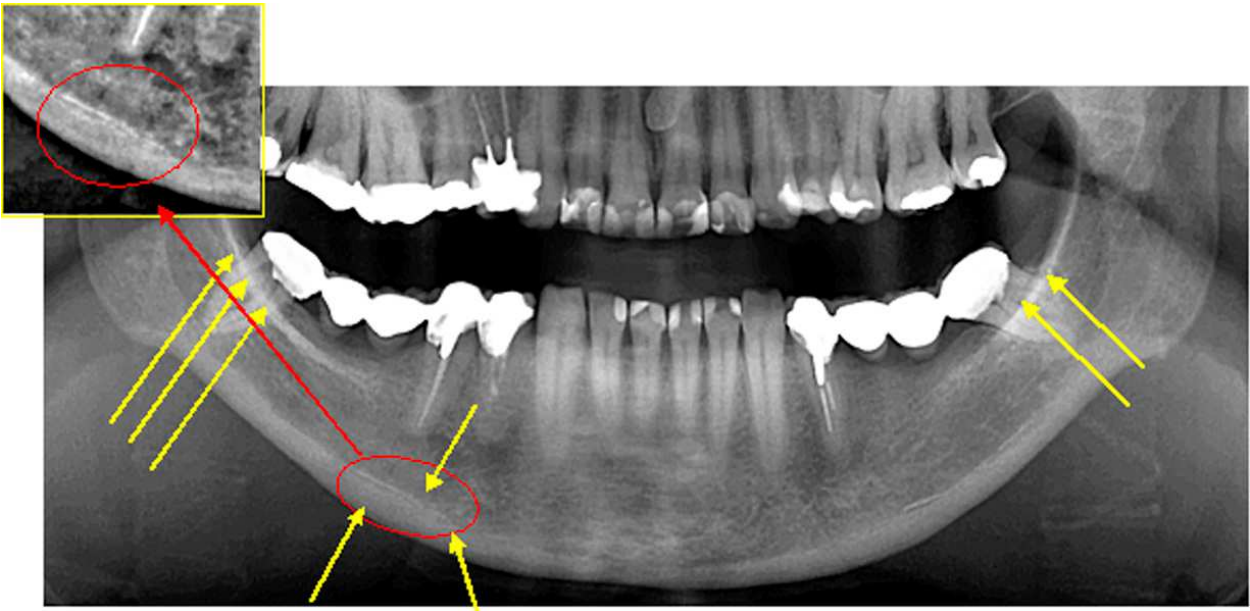


Fig. 15. Detail of the pseudoperoarthritis in the mandibular inferior cortical and accented oblique line in the mandible.

It is possible to correlate Bone Mineral Index (BMI)with mandibular bone quality (MBQ). The authors studied the correlation between body mass index and mandibular bone quality in Brazilians of both sexes. According to the methodology employed in this study, not all patients with poor MBQ had low BMI, but the majority who had low BMI, had bad MBQ (DUTRA et al, 2005).

$IMC = \frac{Weight(kg)}{Height^2(m^2)}$	Underweight	Normal	Overweight	Obese
	<22	22,0 - 24,9	25,0 - 29,9	≥ 30,0

Lee et al (2005) conducted a study in the visual cortical lower mandible on panoramic radiographs to identify postmenopausal women with low BMD. The authors concluded that the visual analysis of the mandibular inferior cortex on panoramic radiographs may be useful in identifying women with low DOM PM (LEE et al, 2005).

Dutra et al studied the radiomorphometric indices and their relationships with gender, age and dental status, using the antgoniac index (AI) and chin index (MI) in patients with and without teeth. It was concluded that there is a renovation in the mandibular inferior cortex (MIC) with age and that would be influenced by gender and dental status. The difficulty in measuring the AI in a reproducible way, and their interaction with dental status and low correlation with MI in younger patients would discourage its use for the purpose of identifying patients at risk of osteoporosis ((DUTRA et al, 2005).

An image analysis software that can accurately measure the thickness of the mandibular inferior cortex (MIC) in PR has been developed as an indicator of low BMD. The authors found that the action taken by the software had significant correlation with the BMD and could contribute to the identification of osteopenia. The study was supported by the European Commission FP5 "Quality of Life and Management of Living Resources"(Report

of the 10th European Congress of Dentomaxillofacial Radiology, 2006). Another study investigated the OSTEODENT trabecular pattern in intraoral radiographs, and concluded that this factor would serve for the diagnosis of osteoporosis. Other authors stated that ICM is effective in the diagnosis of osteoporosis because it had high specificity and thus could be used in primary health care. Analyzing the densitometric measurements in intraoral radiographs to detect osteoporosis was the proposal of some authors who concluded that bone density in the region of premolars, expressed in millimeters of aluminum would be favorable for showing the presence of systemic osteoporosis.

In 2007, Ishii et al evaluated the diagnostic efficiency in identifying postmenopausal women with osteoporosis by analyzing femoral bone loss in the jaw. It is known that cortical thickness measurements in lower jaw is useful to that purpose. The results suggest that the assessment of alveolar bone resorption was not as effective in detecting postmenopausal women with osteoporosis compared to femoral cortical thickness measures lower jaw.

The detection of cortical erosions in lower mandible on panoramic radiographs and tools based on questionnaires were studied in 2008, and it was found similar diagnostic efficacy in identifying postmenopausal osteoporotic women. Furthermore the authors evaluated the diagnostic performance to identify osteoporosis and biochemical markers of bone turnover for high risk of fracture. The analysis of urine and blood plasma were measured for bone mineral density (OD) of the spine and hip by DXA. The results suggest that panoramic radiography was superior to questionnaire-based tool to identify women with high risk of fractures (TAGUCHI et al, 2008).

In 2009, Elsubeihi & Heersche studied the effects of ovariectomy on the toothed jaws and mandible of rats were investigated and compared to changes in relation to the tibia and femur using DXA scans (dual X-ray Absorptiometry) and histomorphometric measurements. The results showed that the loss of bone in the jaws without teeth in ovariectomized animals was similar to what occurred in the tibia and femur, while the lack of significant effects of ovariectomy on bone mass in toothed mandibles suggests that the functional load on the force bite prevents bone loss in the jaws with teeth. Evaluating the quality of mandibular bone in edentulous persons, persons with less than 21 teeth and those over 21 teeth, it was found significant differences in the bone quality, measured by the mandibular inferior cortical thickness, indicating that the person with more than 21 teeth in the oral cavity has a better quality of mandibular bone.

It was also studied in 2010, by Watanabe et al, the correlation of the elongated styloid process with low BMD diagnosed by DXA. The authors could verify the existence of a strong correlation between women with osteopenia and osteoporosis, and women with fracture risk presented calcification of the stylohyoid ligament (Figure 16). In another article of the same year, Watanabe et al, 2009 studied the morphological pattern trabecular digitally comparing the same regions of interest in different radiographs, periapical and panoramic (Figure 17). The authors could verify that when the analysis of skeletonized images of certain regions was performed, significant differences between the measurements were found and such comparison should therefore be careful. Khojastehpour et al. analyzed the usefulness of the Panoramic Mandibular Index (PMI) on panoramic radiographs for the diagnosis of osteoporosis in women and concluded that dental panoramic radiographs could be used in the clinical practice to assist identifying individuals with low bone mass through PMI (KHOJASTEHPOUR et al, 2009).

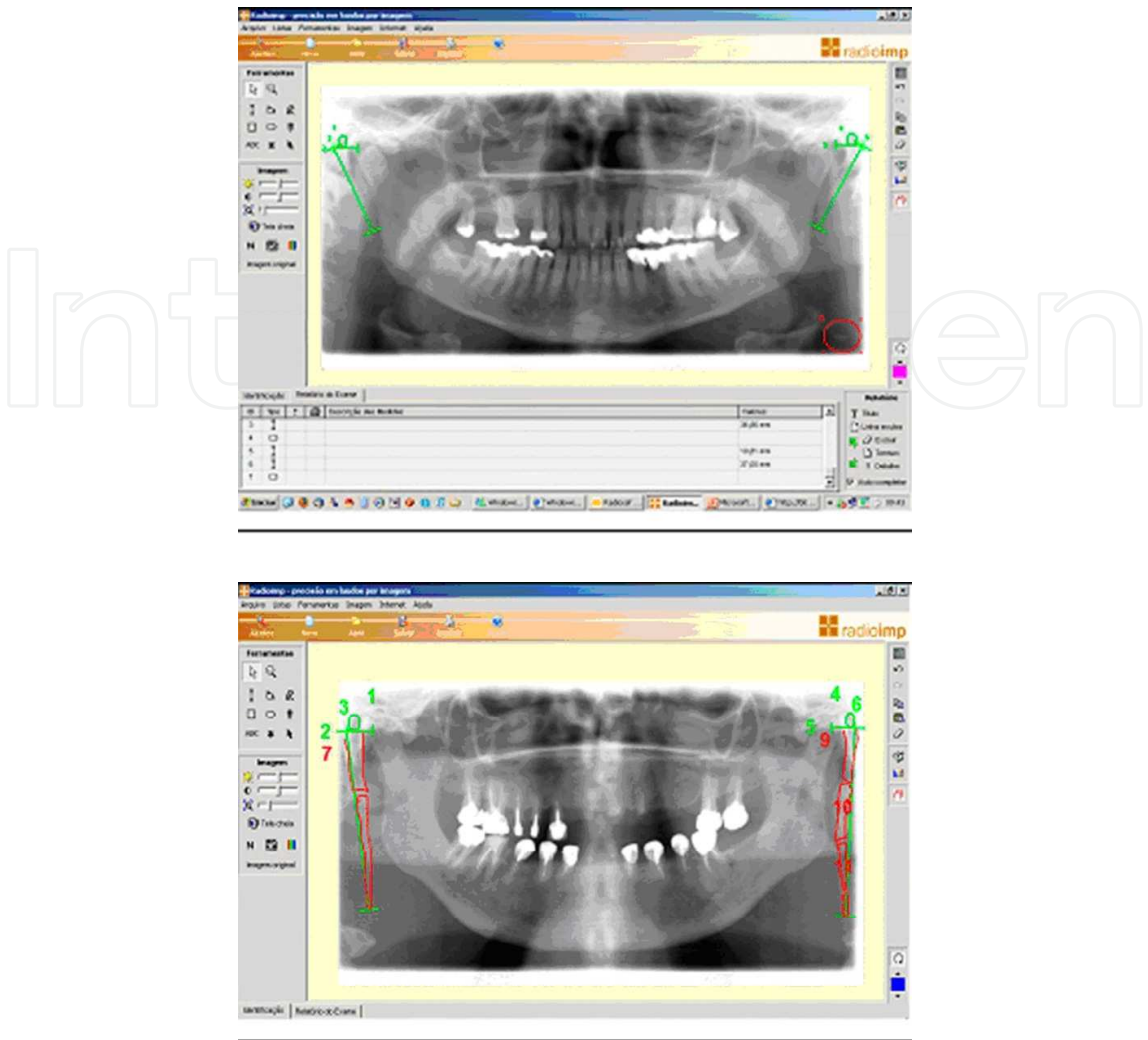


Fig. 16. Measure of the Elongated styloid process in the panoramic radiographic

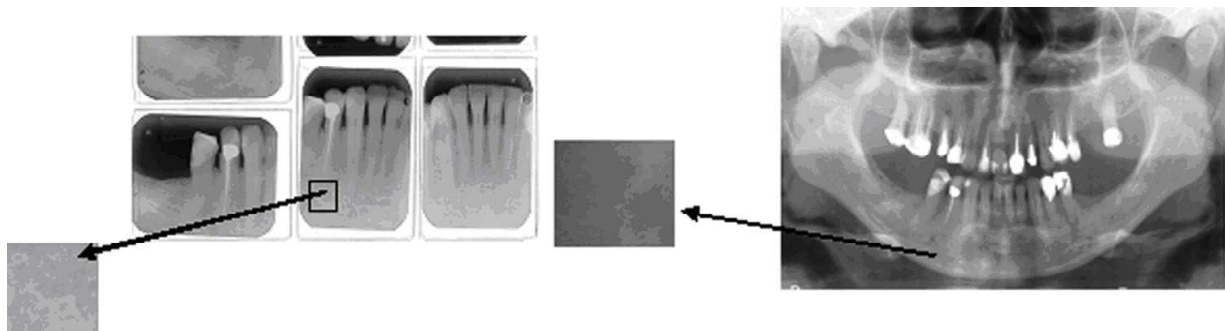


Fig. 17. The same interest region to prepare the image to skeletonized

8. Periodontal disease and osteoporosis

Some studies have suggested that osteoporosis and periodontitis are associated (PERSSON et al, 2002): (1) the prevalence of self-reported history of osteoporosis in an older population, ethnically diverse, (2) the concordance between panoramic mandibular index (PMI) and self-reported osteoporosis, and (3) the probability of having a self-

reported history of osteoporosis and a diagnosis of periodontitis. Panoramic radiographs and medical histories were obtained from 1084 Chinese women aged 60-75 years (mean \pm 68.5 years). Patients were classified as having or not periodontitis or within three grades of severity. The PMI was found positive in 39% of patients, in contrast to self-reported osteoporosis (8%). The intra-class correlation between the PMI and self-reported osteoporosis was 0.20 ($p < 0.01$). The probability of an association between osteoporosis and IPM was of 3%. Patients with osteoporosis and self-reported a positive PMI had worse periodontal conditions ($p < 0.01$).

The prevalence dominance PMI positive was high and consistent with the epidemiological studies however, only partly consistent with a self-reported history of osteoporosis, with a higher prevalence of positive PMI. The loss of horizontal alveolar bone was associated with osteoporosis and self-reported positive results of PMI. Contradictory findings were found by authors (LUNDSTROM et al, 2001) who examined periodontal conditions in a cohort of women aged 70 years compared with an osteoporotic flu control with a normal BMD (210 women, 70 years). Hip radiographs were measured with DXA. The examination included a PR and intraoral radiographs. In conclusion, the study found no statistical significance in the periodontal conditions or marginal bone level between the two groups, although the results should be interpreted with extreme caution as the study sample was small.

We studied the correlation between periodontal disease and osteoporosis, comparing age, parameters of the panoramic radiographic and clinical periodontal disease. The panoramic radiographic parameters evaluated were: mandibular cortical thickness (MCT), patients were not treated, adults who had no other systemic disease and should have more than 20 teeth. They were evaluated by panoramic radiography with respect to alveolar bone loss (ABL). The mandibular bone mass was assessed by measuring the mandibular inferior cortical thickness (MICT). The POA was significantly higher CIMT and significantly lower for patients PMs (> 6 years after menopause). The number of teeth was significantly lower in the group PM (> 11 years after menopause). The age and ABL had positive correlation in men and women. Women in which MICT was lower than the average ($- 2$ SD) should be diagnosed as osteoporosis. The results showed that periodontal disease has correlation with osteoporosis, and thus the MICT could be useful in detecting signs of osteoporosis in women with periodontal disease (OTOGOTO & OTA, 2003).

Some authors (JAGELAVICIENE & KUBILIUS, 2006) evaluated the relationship between systemic osteoporosis and periodontal disease. Radiology provides information in determining the type and degree of alveolar resorption, periodontal condition, and the number of teeth. These parameters provide valuable information when the corresponding data correlation study was searched.

8.1 Osteonecrosis of the jaw after oral bisphosphonate for osteoporosis

Although all the benefits of the therapy with bisphosphonate, mainly for the treatment of osteoporosis, this drug is commonly associated with osteonecrosis of the jaw (ONJ). The use of bisphosphonate was first reported in 2003 (MARX, 2003), and other case series reported similar findings, usually in patients undergoing parenteral treatment for malignancies. Osteonecrosis of the jaw associated with the use of oral bisphosphonate for the treatment of osteoporosis is much less frequently reported (PAZIANAS et al, 2007; YARON et al, 2007). The American Society for Bone and Mineral Research defines bisphosphonate-associated ONJ or BRONJ as “an area of exposed bone in the maxillofacial region that has not healed

within 8 weeks after the identification by a healthcare provider in a patient who is receiving or has been exposed to a bisphosphonate and has not had radiation therapy in the craniofacial region" (KHOSLA et al, 2007) . The American Association of Oral and Maxillofacial Surgeons (AAOMS) (WOO et al) has revised its 2006 landmark position paper on Bisphosphonate-Related Osteonecrosis of the Jaw to reflect the most current research on this condition. BRONJ appears as a non-healing exposed bone in the maxillofacial region and may affect patients undergoing intravenous cancer-related bisphosphonate therapy or more rarely, patients treated with oral or IV bisphosphonates for osteoporosis. Despite its low prevalence, the potential risk of BRONJ occurring after the use of oral bisphosphonate for osteoporosis should never be neglected.

Also, the European Society on Clinical and Economic Aspects of Osteoporosis and Osteoarthritis (ESCEO) has developed some standards for the prevention, recognition and management of BRONJ (PHAL et al, 2007). In osteoporosis patients, no specific interventions prior to starting bisphosphonate therapy are required except to encourage regular dental care.

The radiographic aspects associated with osteochemonecrosis of the jaws related with the oral use of bisphosphonate (BP) should be identified. The most important radiographic features are: Osteosclerosis limited to the alveolar process, widening of the lamina dura, expansion of the periodontal ligament space, bony sequestra, jaw expansion, radiolucency, and periosteal new bone formation. Osteosclerosis is frequent. It is usually found in the presence of periodontal disease, probably because it is attributed to the fact that BP accumulates preferentially in sites of high bone turnover or remodeling (KHAN et al, 2008).

Radiographic changes are not evident until there is extensive bone involvement. Therefore, panoramic radiographs may not reveal significant changes in the early stages of osteonecrosis as numerous different pathologies. When there is extensive bone involvement, regions of mottled bone similar to diffuse osteomyelitis or postirradiation osteoradionecrosis are noted (KUNCHUR & GOSS, 2008). After prolonged exposure to intravenous bisphosphonates, osteosclerosis of the bone, especially osteosclerotic lamina, may be noted radiographically Edwards et al, 2008 (Figures 18-19). The patient in these images received the diagnosis from breast cancer IIIa - AP, and began chemotherapy in July 2003, and gone through bilateral mastectomy. In 2007 it had been diagnosed metastasis in the liver and in the column when the x-ray of the column was made and the monthly use of zometa. The first requested x-ray to the Radiologic Service was in 2008 for the Dental Service of the hospital for diagnostic purpose. It was observed the absence of 7 teeth and horizontal resorption of the alveolar Crests and sclerosis of the horny lamina of teeth 16; 15; 14; 13; 25; 27; 36; 35; 45 and 48. These alterations are indicative of possible bone exposition, suggesting the presence of a sub-clinic degree of osteonecrosis, "the zero" in accordance with AAOMS. In April of 2009, new panoramic x-ray was made and served as base for dentists to consider the interruption of the administration of zometa. After the evaluation of the patient, physicians had substituted zometa by 70mg of alendronate sodium, in an attempt to prevent the occurrence of osteonecrosis in the maxillaries. The jaws are mainly affected because of the teeth, that are embedded in bone. This active bone has fast turnover, principally the horny lamina (alveolar bone also). Most of the times, dentists need to proceed with invasive dental procedures that injures the bone. Hence, the osteonecrosis is viable.

8.2 Incidence

- 0.8% -1.6% (industry-sponsored)
 - AAOMS
- 8% -12% (independent)

0.01% -0.04% (oral)

0.8% -12% (i.v.)

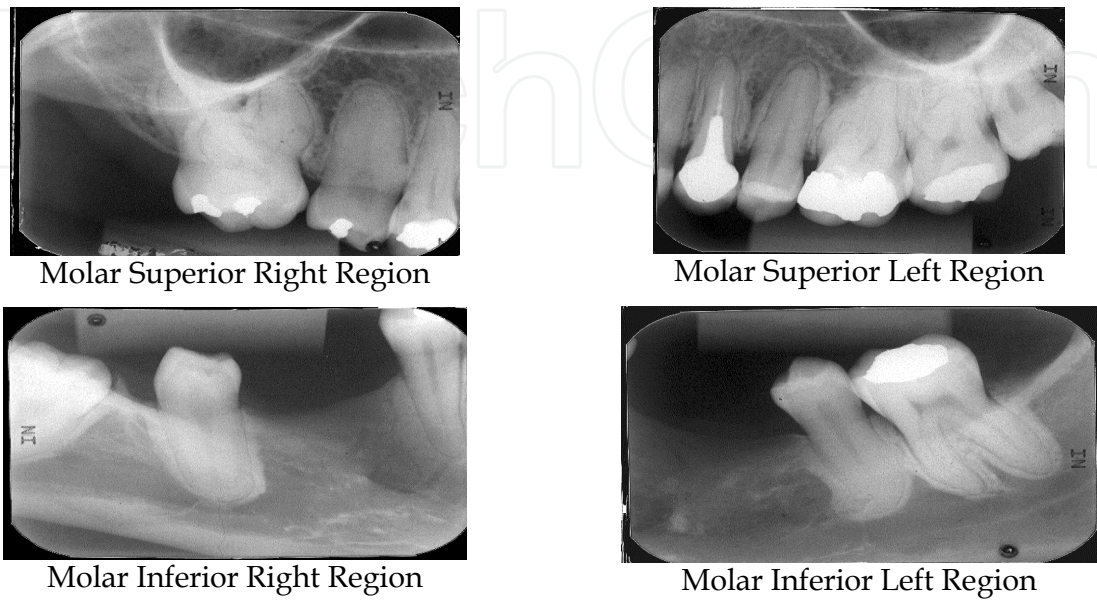


Fig. 18. Periapical radiographs showed widening of the lamina dura in all regions in the mouth

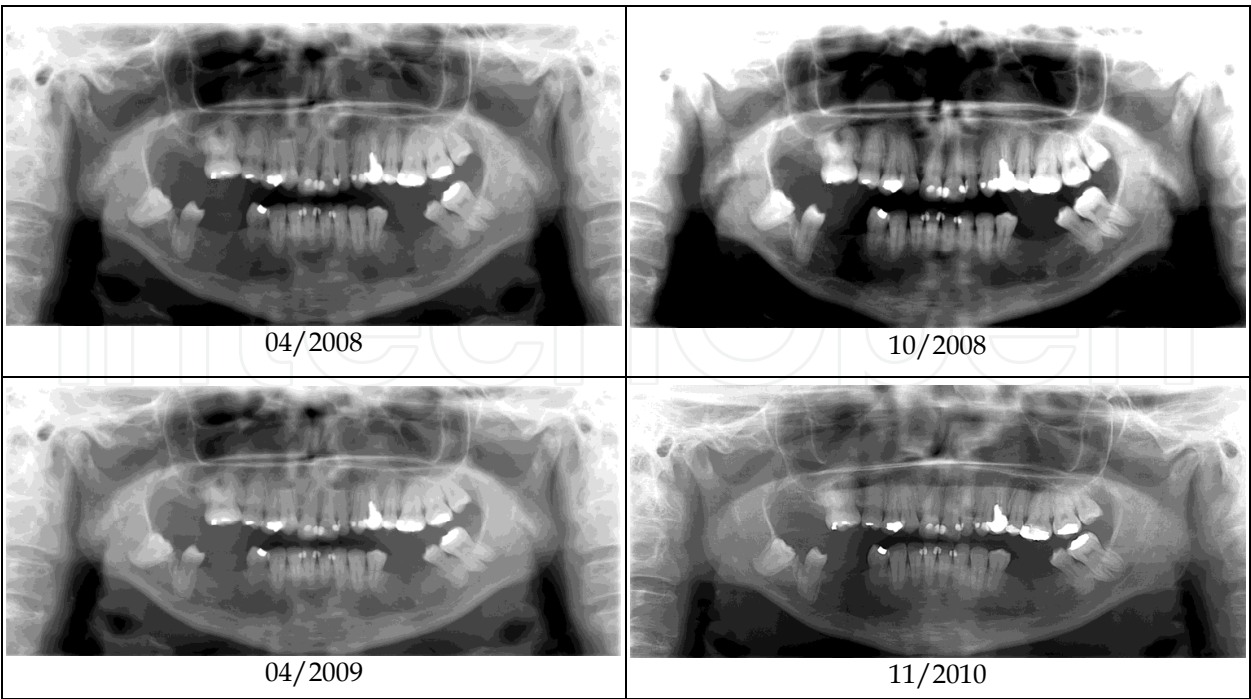


Fig. 19. Panoramic radiographs showed widening of the lamina dura in all regions in the mouth in four different periods.

9. Conclusions

Dentist are healthcare professionals and currently graduate with a different vision for prevention. Modern dentistry has been made responsible for important technical and socio-economic status. New technologies and treatments developed brought great advances in improving the health of the population. Visits to the dentist are much more frequent, and it is routinely visited by patients who have never had cavities. Elucidation of the population with respect to dental care has turned dentists in a professional for oral diagnosis, monitoring, prevention and oral aesthetics, rather than a curative professional.

This expanded the role of dentistry, including the Family Health Program (FHP) in Brazil that is the most significant advancement of the profession, which leads us to think about how these professionals can contribute to the improvement of health as a whole, enabling the dentist to act more widely.

The dentist is who examines the mouth of the population. The teeth are only a portion of the mouth. There are a huge range of other elements that require constant care and observation. Thus, the saying "dentistry beyond the teeth" reinforces, and aims to modernize dentistry career on several fronts, giving a broader professional training and creating conditions so that they can increasingly contribute in improving the health of the population. This modernization involves different aspects ranging from a reformulation, modification of certain areas of research within the faculties, until a fight over a new aspect of insertion of the dental professional in the job market.

We feel that there is sufficient evidence that the radiographic images that the dentist routinely uses, particularly the panoramic radiograph can provide important signals related to poor bone quality, and thus we suspect that the involvement of other bone sites such as spine, hip and forearm, and sites that increase the risk of osteoporotic fracture. We therefore endorse the patients with poor bone quality diagnosed by the oral physician to search for other skeletal sites for poor bone quality. Early detection can lead to appropriate treatment and relief of adversities. This is an area where the dentist can greatly contribute in reducing the morbidity and even the mortality, thus enhancing its performance as a health professional, understanding the patient as a whole.

As osteoporosis is a global epidemic with enormous social costs, with high morbidity and mortality; the Global Forum 2005 indicated osteoporosis as a neglected disease. These are the diseases that, despite having a high incidence in the developing countries, do not receive investments in Research & Development in proportion to their epidemiological importance. Neglected diseases can be defined as a group of diseases associated with poverty. The precarious living conditions and health inequities are major factors responsible for the incidence of neglected diseases. So it is important that the Dentist be prepared for the possibility of evaluating and interpreting the morfometric indices on panoramic radiographs, which could allow the interaction with other health professionals in assessing and preventing the risk for osteoporosis.

10. References

American Dental Association, U.S. Food & Drug Administration. (2004). The Selection of Patients For Dental Radiograph examinations. GUIDELINES FOR PRESCRIBING DENTAL RADIOGRAPHS.

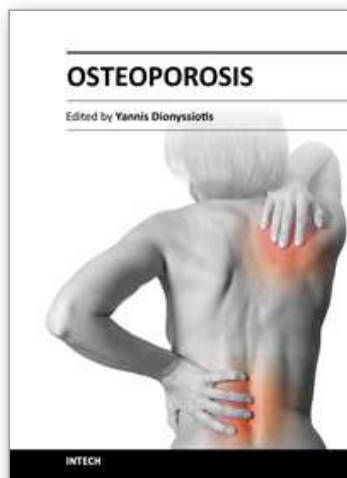
- Anderson, J. J. (1999). Plant-based diets and bone health: nutritional implications. *Am J Clin Nutr*, Vol. Vol.70, pp.539-542.
- Andrade, K.M., Mazzetto, M.O., & Watanabe, P.C.A. (2009). A precisão do Índice Panorâmico Mandibular na detecção de pacientes com osteopenia e osteoporose. *Anais da 31ª JORP, FORP/USP*.
- Araújo, D.V., Oliveira, J.H.A., & Bracco, O.L. (2006). Custo da fratura osteoporótica de fêmur no sistema suplementar de saúde brasileiro. *Arq Bras Endocrinol Metab.*, Vol. 49, No. 6, pp. 897-901.
- Bauer, D.C. et al. (1993). *Annals of Internal Medicine*, Vol.118, pp.657-665.
- Benson, B.W., Prihoda, T.J., & Glass, B.J. (1991). Variations in adult cortical bone mass as measured by a panoramic mandibular index. *Oral Surg Oral Med Oral Pathol.*, Vol.71, pp.617-21.
- Bras, J., van Ooij, C.P., Abraham-Inpijn, K., Kusen, G.J., & Wilink, J.M. (1982). Interpretation of the mandibular angular cortex: a diagnostic tool in metabolic bone loss. Part I. Normal state and postmenopausal osteoporosis. *Oral Surg.*, Vol.53, pp.541-545.
- Cosman, R., & Lindsay, R. (2004). Therapeutic potential of parathyroid hormone. (2004). *Curr Osteoporos Rep.*, Vol.2, pp.5-11.
- Watanabe, P.C.A, Dias, F. C. , Issa, J. P. M., Monteiro, S. A. C., Paula, F. J. A., & Tiossi, R. (2010). Elongated styloid process and atheroma in panoramic radiography and its relationship with systemic osteoporosis and osteopenia. *Osteoporosis International*, May; Vol.21, N°(5), pp.831-6 p. 177-181.
- Dutra, V., Yang, J., Devlin, H., & Susin, C. (2005). Radiomorphometric índices and their relation to gender, age, and dental status. *Oral Surg Oral Med Oral Pathol Oral Radiol Endod*, Vol. 99, N°(4), pp.479-84 Apr.
- Edwards, B.J., Hellstein, J.W., Jacobsen, P.L., Kaltman, S., Mariotti, A., & Migliorati, C.A., (2008). American Dental Association Council on Scientific Affairs Expert Panel on Bisphosphonate-Associated Osteonecrosis of the Jaw. Updated recommendations for managing the care of patients receiving oral bisphosphonate therapy. *J Am Dent Assoc*, Vol .139, N°(12), pp.1674-1677.
- Elsubeihi, E.S., & Heersche, J.N. (2009). Comparison of the effect of ovariectomy on bone mass in dentate and edentulous mandibles of adult rats. *Eur J Prosthodont Restor Dent* (England), Mar, Vol.17, N°(1), pp.9-21.
- FIOCRUZ/WHO. A Saúde do Brasileiro. 2008 FUNDAÇÃO INSTITUTO BRASILEIRO DE GEOGRAFIA E ESTATÍSTICA - IBGE. Anuário Estatístico do Brasil, 1995. Rio de Janeiro, 1996.
- Farman, A.G., Nortjé, C.J., & Wood, R.E. (1993). *Oral and maxillofacial diagnostic imaging*. St Louis: Mosby-Year Book.
- Global Forum. (2005). Poverty, equity e health research: *A Report on Forum 9*, Mumbai. Geneva, p.63,.
- Hallstrom, H. et al, (2006). *Osteoporosis International*, Online Edition, May.
- Heaney, R.P. (2002). Food and Chemical Toxicology, Vol.40, pp. 1263-1270.
- Homer, K., Devlin, H., & Harvey, L. (2002). Detecting patients with low skeletal bone mass. *J Dent.*, Vol.30, pp.171-175.
- Ishii, K., Taguchi, A., Nakamoto, T., Ohtsuka, M., Sutthiprapaporn, P., Tsuda, M., Kodama, I., Kudo, Y., Sumida, H., Suei, Y., & Tanimoto, K. (2007). Diagnostic efficacy of

- alveolar bone loss of the mandible for identifying postmenopausal women with femoral osteoporosis. *Dentomaxillofac Radiol* (England), Jan, Vol.36, N°(1), p28-33, N°(4), pp.479-84.
- Jagelavičienė, E., & Kubilius, R. (2006). The relationship between general osteoporosis of the organism and periodontal diseases. *Medicina* (Kaunas), Vol.42, N°(8), pp. 613-618.
- Johansson, C. et al. (1992). *Age and Ageing*, Vol.21, pp.20-26.
- Khan, A.A., Sándor, G.K., & Dore, E. (2008). Canadian consensus practice guidelines for bisphosphonate associated osteonecrosis of the jaw. *J Rheumatol*,35:1391-7. Erratum in: *J Rheumatol*, Vol.35, pp.2084.
- Khojastehpour, L., Shahidi, S.H., Barghan, S., & Aflaki, E.L. (2009). Efficacy of Panoramic Mandibular Index in Diagnosing Osteoporosis in Women. *J. Dent.*, Vol. 6, N° (1200), pp.11-15.
- Khosla, S., Burr, D., & Cauley, J. (2007). Bisphosphonate-associated osteonecrosis of the jaw: report of a task force of the American Society for Bone and Mineral Research. *J Bone Miner Res*, Vol.22, pp.1479-91.
- Klein, C.G. (2005). *Evaluation of the bone architecture to trabecular by means of digital image processing in panoramic x-rays*. Master thesis. Paraná Federal Technological university
- Klemetti, E., Kolmakov, S., & Kroger, H. (1994). Pantomography in assessment of the osteoporosis risk group. *Scand J Dent Res.*, Vol.102, pp.68-72.
- Knezović-Zlatarić, D., & Čelebić, A. (2005). Comparison of mandibular bone density and radiomorphometric indices in wearers of complete or removable partial dentures. *Oral Radiol.*, Vol.21, N°(2), pp51 - 55 .
- Kowalski, S.C., Sjenzeld, V.L., & Ferraz, M.B. (2001). Utilização de recursos em osteoporose. *Ver Ass Méd Brasil.*, Vol.47, N°(4), pp. 352-7.
- Kunchur, R., & Goss, A.N. (2008). The oral health status of patients on oral bisphosphonates for osteoporosis. *Aust Dent J*, Vol.53, pp354-7.
- Ledgerton, D., Horner, K., & Devlin, H. (1997). Panoramic mandibular index as a radiomorphometric tool an assessment of precision. *Dentomaxillofac Radiol.*, Vol.26, pp.95-100.
- Ledgerton, D., Horner, K., & Devlin, H. (1999). Radiomorphometric indices of the mandible in a British female population. *Dentomaxillofac Radiol.*, Vol.28, pp.173-81.
- Lee, K., Taguchi, A., Ishii, K., Suei, Y., Fujita, M., Nakamoto, T., Ohtsuka, M., Sanada, M., Tsuda, M., Ohama, K., Tanimoto, K., & White, S.C. (2005). Visual assessment of the mandibular cortex on panoramic radiographs to identify postmenopausal women with low bone mineral densities. *Oral Surg Oral Med Oral Pathol Oral Radiol Endod* Aug, Vol.100, N°(2), pp.:226-31 .
- Lundstrom, A., Jendlo, J., Stenstrom, B., Toss, G., & Raval, N. (2001). Periodontal conditions in 70-year-old women with osteoporosis. *Swed Dent J.*, Vol.25, pp.89-96.
- Mahl, C.R.W., Licks, R., & Fontanella, V.R.C. (2008). Comparison of morphometric indices obtained from dental panoramic radiography for identifying individuals with osteoporosis/osteopenia *Radiol Bras.* Mai/Jun, Vol.41, N°(3), pp.183-187.
- Marques Neto, J.F., & Lederman, R. (1995). *Osteoporose: Brasil ano 2000*. 1st ed. São Paulo: Limay.
- Marx, R.E.. (2003). Pamidronate (Aredia) and zoledronate (Zometa) induced avascular necrosis of the jaws: a growing epidemic. *J Oral Maxillofac Surg*, Vol.61, pp.115-7.

- May, H., Murphy, S., & Khaw, K. T. (1994). Cigarette smoking and bone mineral density in older men. *Q J M*, Vol.87, pp.625-630.
- Nakamoto, T., Taguchi, A., Ohtsuka, M., Suei, Y., Fujiya, M., & Tanimoto, K. (2003). Dental panoramic radiograph as a tool to detect postmenopausal women with low bone mineral density: untrained general dental practitioners diagnostic performance. *Osteoporos Int.*, Vol.14, pp.659-664.
- American Dental Association Council on Scientific Affairs. (2008). Osteonecrosis of the Jaw. Updated recommendations for managing the care of patients receiving oral bisphosphonate therapy: an advisory statement from the. *J Am Dent Assoc*, Vol.139, pp.1674-7.
- Otogoto, J, & Ota, N. (2003). Correlation between periodontal disease and osteoporosis using panoramic radiographic parameters for diagnosed osteoporosis in dental clinic. *Clin Calcium*. May, Vol.13, N°(5), pp.582-6.
- Pazianas, M., Miller, P., Blumentals, W.A., Bernal, M., & Kothawala, P. (2007). A review of the literature on osteonecrosis of the jaw in patients with osteoporosis treated with oral bisphosphonates: prevalence, risk factors, and clinical characteristics. *Clin Ther*, Vol.29, pp.1548-58.
- Persson, R.E., Hollender, L.G., Powell, L.V., MacEntee, M.I., Wyatt, C.C., & Kiyak, H.A., et al. (2002). Assessment of periodontal conditions and systemic disease in older subjects. I. Focus on osteoporosis. *J Clin Pedodontol.*, Vol.29, N°(9), pp.796-802.
- Phal, P.M., Myall, R.W., Assael, L.A., & Weissman, J.L. (2007). Imaging findings of bisphosphonate-associated osteonecrosis of the jaws. *AJNR Am J Neuroradiol*. Vol.28, N°(6), pp.1139-1145.
- Pinto Neto A.M., et al. (2002). Consenso Brasileiro em Densitometria. *Rev. Bras. Reumatol.*, Vol.42, N°(6), pp.343-354, nov/dez.
- Report of the 10th European Congress of Dentomaxillofacial Radiology, may-june, 2006.
- Rizzoli, R., & Bonjour, J. P. (1999). *Malnutrition and osteoporosis*. *Z. Gerontol Geriatr*, Vol.32, pp.31-37.
- Rousseau, M. E. (). *Dietary prevention of osteoporosis*. Lippincotts Prim Care Pract, 1997, 1:307-319.
- Secretaria da Saúde. Hospital do Servidor Público Estadual. (1995). Osteoporosis: *Basic diagnosis and therapeutic elements for a National Consensus Proposal*. São Paulo (São Paulo). *Med J.*, Vol.113, Suppl, pp.1-64.
- Secretaria de Vigilância Sanitária, Ministério da Saúde Brasil. Portaria 453 - (1998). *"Diretrizes de proteção radiológica e radiodiagnóstico médico e odontológico"* Brasília (Brasil).
- Stallings, V. A. (1997). Calcium and bone health in children: a review. *Am J Ther*, Vol.4, pp.259-273.
- Szwarcwald, C.L., & Viacava, F. (2005). *Pesquisa Mundial de Saúde (PMS)*. Cad. Saúde Pública, Rio de Janeiro, Vol.21 Sup:S4-S5.
- Taguchi A., Suei Y., Sanada M., Ohtsuka M., Nakamoto T., & Sumida H.. (2004). Validation of Dental Panoramic Radiography Measures for Identifying postmenopausal Women with Spinal Osteoporosis *AJR.*, Vol.183, pp1755-1760.
- Taguchi, A., Ohtsuka, M., Nakamoto, T., Suei, Y., Kudo, Y., Tanimoto, K., & Bollen, A.M.. (2008). Detection of post-menopausal women with low bone mineral density and

- elevated biochemical markers of bone turnover by panoramic radiographs. *Dentomaxillofac Radiol* (England), Dec, Vol.37, N°(8), p433-7.
- Taguchi, A., Tanimoto, K., Suei, Y., Otani, K. & Wada, T. (1995). Oral signs as indicators of possible osteoporosis in elderly women. *Oral Surgery, Oral Medicine, Oral Pathology, Oral Radiology and Endodontics*, Vol.80, pp.612-616.
- Von Muhlen, D., Visby, L., Barret-Connor, E., & Bettencourt, R. (1999). Evaluation of the simple calculated osteoporosis risk estimation (SCORE) in older caucasian women: the Rancho Bernardo Study. *Osteoporos Int*, Vol.10, pp.79-84.
- Vondracek, S.F., Hansen, L.B., McDermott, M.T. (2009). Osteoporosis risk in premenopausal women. *Pharmacotherapy*, Vol.29, N°(3). pp305-17.
- Wardlaw, G M. (1993). Putting osteoporosis in perspective. *J Am Diet Assoc*, Vol.93, pp1000-1006.
- Watanabe, P.C.A., Arita, E.S., Monteiro, S.A.C., Oliveira, T.M., & Taguchi A. (2004). The relationship among three indicators of bone quality in the osteoporosis research on panoramic radiographic. *Osteoporos Int.*, Vol.15(Suppl 1), S.67, pp255MO.
- Watanabe, P.C.A., Bóscolo, F.N., Nishioka, R.S., Shitomi, C.I.H., & Menezes, W.M.M. (2008). Avaliação da densidade mineral óssea na maxila e mandíbula utilizando-se radiografias periapicais. *Rev. ABRO*, Vol. 09, N° 1 JANEIRO/JULHO.
- Watanabe P.C.A., Faria, L.M.L., Issa J.P.M., & MONTEIRO, S.A.C. (2009). Morphodigital evaluation of the trabecular bone pattern in the mandible using digitized panoramic an periapical radiographs. *Minerva Stomatologica*, Vol. 58, p. 73-80.
- Watanabe P.C.A., Monteiro S.A.C., Lacerda, S.A., Taguchi A., & Arita, E.S. (2004). Interrelation of two quality indicators for osteoporosis research in panoramic X-Rays of Brazilian Women. *Rev Int Estomatol. Curitiba*, Vol.1, N°(3), pp.200-206.
- Watanabe, P. C. A. , Silva, A. B. M. , Pardini, L. .C., & Arita E.S. (2002). Osteoporose: um foco de estudo na odontologia. RPG. *Revista de Pós-Graduação (USP)*, São Paulo, Vol. 9, N°4, p. 379-382,.
- Watanabe, P.C.A. (2003). - “Relação de Três Indicadores de Qualidade Óssea na Pesquisa da Osteoporose em Radiografias Panorâmicas” - Tese de apresentada para a obtenção do Título de Livre-docente da USP, Ribeirão Preto,.
- Waugh, E.J. et al, (2009). Risk factors for low bone mass in healthy 40-60 year old women: a systematic review of the literature. *Osteoporosis International*, Vol.20, N°1, pp. 1-21.
- White, S.C., Taguchi A., Kao D., Wu, S., Susan K., & Yoon D. (2004). *Clinical and panoramic predictors of femur bone mineral density*. International Osteoporosis Foundation, National osteoporosis Foundation.
- White, S.C., Taguchi, A., Kao, D., Wu, S., Service, S.K., & Yoon, D. (2005). Clinical and panoramic predictors of femur bone mineral density. *Osteoporos Int.*, Londres, Vol.16, N°(3), pp.339-46.
- Wical, K.E., & Swoope, C.C. (1974). Studies of residual ridge resorption. Part I. Use of panoramic radiographs for evaluation and classification of mandibular resorption. *J. Prosthet. Dent.*, St.Louis, Vol.32, N°(1), p.7-12.
- Woo S.B., Hellstein J.W., & Kalmer J.R. (2006). Narrative review: bisphosphonates and osteonecrosis of the jaws. *Ann Intern Med*, Vol. 144. Pp.753-61.

- von Wowern N. (). Bone mass of mandibles. In vitro and in vivo analyses (Thesis). Danish Med Bull. Vol.33. pp23–44.
- Yarom N., Yahalom R., Shoshani Y., Hamed W., Regev E., & Elad S. (2007). Osteonecrosis of the jaw induced by orally administrated bisphosphonates: incidence, clinical features, predisposing factors and treatment outcome. *Osteoporos Int*, Vol.18. pp1363-70.
- Zanette E., Stringari F.F., Machado F., Marroni B.J., Ng D.P.K., & Canani L.H. (2003). Avaliação do Diagnóstico Densitométrico de Osteoporose/Osteopenia Conforme o Sítio Ósseo. *Arq Bras Endocrinol Metab*, Vol.47. N°(1). pp30-36.



Osteoporosis

Edited by PhD. Yannis Dionyssiotis

ISBN 978-953-51-0026-3

Hard cover, 864 pages

Publisher InTech

Published online 24, February, 2012

Published in print edition February, 2012

Osteoporosis is a public health issue worldwide. During the last few years, progress has been made concerning the knowledge of the pathophysiological mechanism of the disease. Sophisticated technologies have added important information in bone mineral density measurements and, additionally, geometrical and mechanical properties of bone. New bone indices have been developed from biochemical and hormonal measurements in order to investigate bone metabolism. Although it is clear that drugs are an essential element of the therapy, beyond medication there are other interventions in the management of the disease. Prevention of osteoporosis starts in young ages and continues during aging in order to prevent fractures associated with impaired quality of life, physical decline, mortality, and high cost for the health system. A number of different specialties are holding the scientific knowledge in osteoporosis. For this reason, we have collected papers from scientific departments all over the world for this book. The book includes up-to-date information about basics of bones, epidemiological data, diagnosis and assessment of osteoporosis, secondary osteoporosis, pediatric issues, prevention and treatment strategies, and research papers from osteoporotic fields.

How to reference

In order to correctly reference this scholarly work, feel free to copy and paste the following:

Plauto Christopher Aranha Watanabe, Marlivia Gonçalves de Carvalho Watanabe and Rodrigo Tiossi (2012). How Dentistry Can Help Fight Osteoporosis, Osteoporosis, PhD. Yannis Dionyssiotis (Ed.), ISBN: 978-953-51-0026-3, InTech, Available from: <http://www.intechopen.com/books/osteoporosis/how-dentistry-can-help-fight-osteoporosis>

INTECH
open science | open minds

InTech Europe

University Campus STeP Ri
Slavka Krautzeka 83/A
51000 Rijeka, Croatia
Phone: +385 (51) 770 447
Fax: +385 (51) 686 166
www.intechopen.com

InTech China

Unit 405, Office Block, Hotel Equatorial Shanghai
No.65, Yan An Road (West), Shanghai, 200040, China
中国上海市延安西路65号上海国际贵都大饭店办公楼405单元
Phone: +86-21-62489820
Fax: +86-21-62489821

© 2012 The Author(s). Licensee IntechOpen. This is an open access article distributed under the terms of the [Creative Commons Attribution 3.0 License](https://creativecommons.org/licenses/by/3.0/), which permits unrestricted use, distribution, and reproduction in any medium, provided the original work is properly cited.

IntechOpen

IntechOpen