

We are IntechOpen, the world's leading publisher of Open Access books Built by scientists, for scientists

6,900

Open access books available

186,000

International authors and editors

200M

Downloads

Our authors are among the

154

Countries delivered to

TOP 1%

most cited scientists

12.2%

Contributors from top 500 universities



WEB OF SCIENCE™

Selection of our books indexed in the Book Citation Index
in Web of Science™ Core Collection (BKCI)

Interested in publishing with us?
Contact book.department@intechopen.com

Numbers displayed above are based on latest data collected.
For more information visit www.intechopen.com



Minimally Invasive Treatment of Vertebral Body Fractures

Pasquale De Negri and Tiziana Tirri

*Department of Surgical Oncology and Pain Medicine,
IRCCS Centro di Riferimento Oncologico della Basilicata, Rionero in Vulture,
Italy*

1. Introduction

Gestures rather harmless at first sight like weight-lifting, a sudden movement, sometimes only remaking the bed in the morning could cause, in susceptible individuals, the failure and collapse of the vertebral body. Painful fractures, which cause changes in appearance and posture, persistent back pain, limited mobility and a general decay in the affected individuals, most often even unaware of the cause of their evil (Eastell et al., 1991). One of the most frequent causes of fractures of the vertebral body is osteoporosis (Dempster, 2011; Haczynski, 2001), relentless and "silent" disease spread rapidly, due to an aging world population. Vertebral fractures can also be the result of a traumatic event, of hematologic malignancies (multiple myeloma, leukemia), solid tumor metastases to the spine (Bouvard et al., 2011) or long-term steroid therapy (treatment of rheumatoid arthritis, post-transplant patients) (Naganathan et al., 2000). Despite the persistent pain and a more accentuated thoracic and lumbar deformities, those affected often find it hard to realize it, confusing the symptoms with a simple back pain. A compression fracture of the vertebral body not properly treated, increases by 5 times the risk of further fractures, with all that entails in terms of quality of life of the patient and health and social costs (Oleksik et al., 2000). Usually, in case of spinal pain from vertebral fracture, the patient underwent conservative treatment, covering the prescription of a rigid bust, prolonged immobilization and anti-inflammatory medication and painkillers (Prather et al., 2007). A similar solution, however, may not always be sufficient to solve the problem, because the pain can persist for several months and, above all, the patient does not recover the correct posture with increased comorbidity (Cauley et al., 2000). Currently there are minimally invasive methods, such as balloon kyphoplasty, vertebroplasty, and other percutaneous techniques for stabilization, inherently safe for characteristics and dynamics of action, allowing an immediate relief of the pain, and ensuring a good recovery of the statics of the spine (Frank, 2003).

2. Spine anatomy

The spine consists of 33 vertebrae, including 7 cervical, 12 thoracic, 5 lumbar, 5 sacral segments often fused together, and finally 4 coccygeal segments (Gray, 1973). These segments are spaced by the intervertebral discs and structurally connected by ligaments and muscles. Observed in the lateral projection, a normal spine shows lordosis at the cervical

and lumbar regions and a mild kyphosis at the thoracic and sacral regions. These variations in the curvature are important because they are responsible for the orientation of the single vertebra and important components such as the vertebral pedicles, which are the main access route of percutaneous stabilization techniques which will be discussed later (Ortiz & Deramond, 2001). The size of the vertebrae gradually increase from cervical to lumbar tract with variability dependent on the size of the individual. Theoretically there is an increase in volume ranging from 7.2 ml of the cervical area to 22.4 ml of the lumbar spine. In the thoracic area vertebrae are connected bilaterally with the ribs by ligaments that go from the head of the rib to the vertebral body and then from the rib to the vertebral transverse process. The pedicles of the lower thoracic are relatively large and oriented in an anterior-posterior direction. Heading toward the upper tract, we observe a progressive reduction in the size of the pedicles whose orientation becomes more oblique. In the lumbar tract, we observe larger vertebrae and the orientation of the pedicles is different as we go from L1 to L5. The pedicles of the lumbar spine than have a straight anterior-posterior direction similar to that of the lower thoracic. The pedicles tend therefore to be more oblique in the lower lumbar vertebrae reaching their maximum inclination at L5 (fig. n. 1).

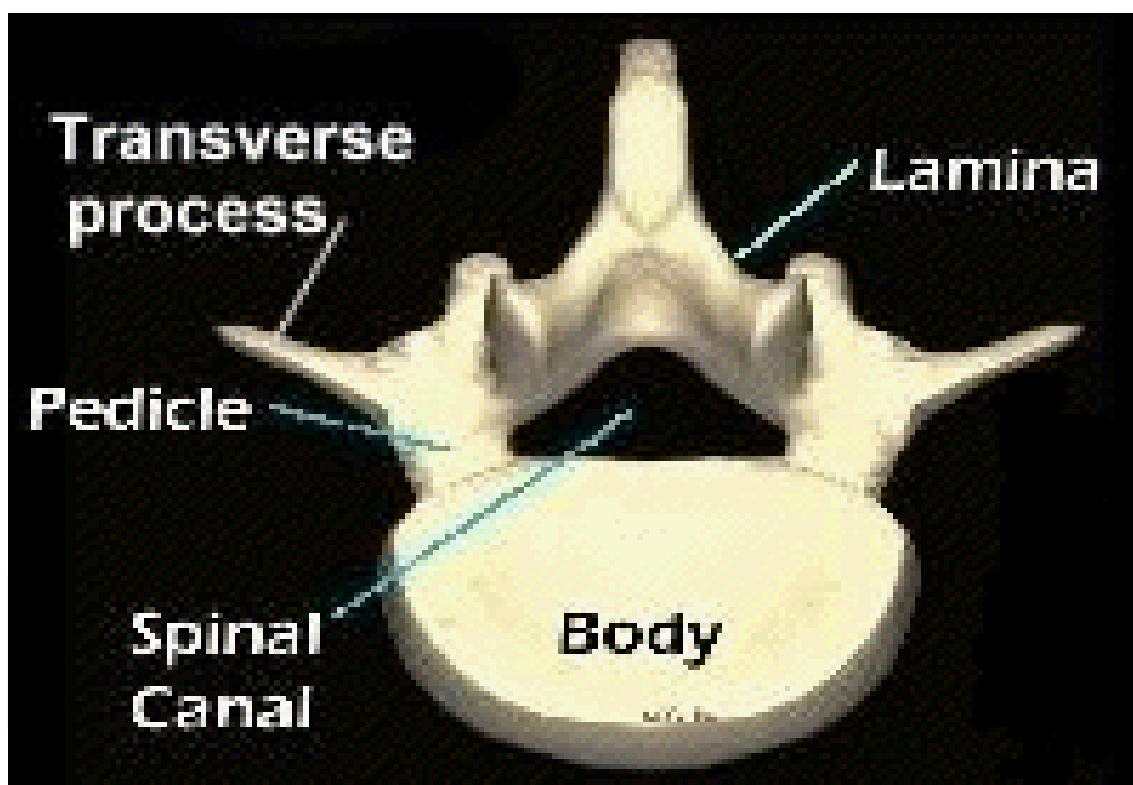


Fig. 1. Vertebral anatomy

The sacrum is then connected to the pelvis through the sacroiliac joints. The sacrum forms the keystone of the pelvis thus counteracting slipping down determined by the higher load. This situation is then responsible for sacral insufficiency fractures secondary to osteoporosis and trauma (De Smet et al., 1985). The blood supply for vertebral bodies derives from arterial branches leaving the aorta, running along the lateral margins of the vertebrae and then sending collaterals to the vertebral bodies, the epidural space and nerve roots. These branches are connected above and below the vertebrae in the paraspinal regions. The

vertebral venous system, instead, consists of three interconnected systems venous valve diameter (interosseous, epidural and paravertebral). These systems are in close communication with the intertrabecular and intraosseous space. The most important venous system, responsible for the drainage of blood from the vertebral venous system, is the basivertebral that connects with the epidural venous system which surrounds the nerve roots and dural sac. The lateral drainage of the vertebral veins communicate with the paravertebral veins forming a system that runs on both sides of the vertebrae vertically and horizontally and interconnects with epidural anterior and posterior venous system. The central veins are major tributaries of the vena cava and azygos carrying the effluent venous blood to the lungs (Groen et al., 2004).

3. Features of vertebral fractures

The vertebral body is made by an extremely thin cortical shell filled with a porous cancellous centrum, the latter carrying about 90% of the load (Duan et al., 2001). During a vertebral compression fracture, the cortex buckles and cracks while the cancellous part collapses and become compacted, reducing the height and volume of vertebra. A vertebral compression fracture (VCF) is defined as a fracture (fig. n. 2) in which there is a partial collapse of the vertebral body with a reduction of at least 20% of the height of the vertebra (Eastell et al., 1991). Vertebral compression fractures may be related to primary osteoporosis, to drugs (prolonged use of steroids as observed in patients with COPD, rheumatoid arthritis, patients with lymphoma or myeloma, transplant patients, androgen deprivation therapy in patients with prostate cancer) or to primary or secondary neoplastic disease. It has been found an incidence of approximately 700,000 spinal fractures annually in the U.S., which represents a large problem for the health care system (US Department of Health and Human Services, 2004), while in Europe every 30 seconds a patient reports a fracture as a result of osteoporosis (EPOS Group, 2002; O'Neill et al., 2009). In Italy each year we observe at least 30 - 40.000 vertebral fractures osteoporosis-related (Johnell et al., 2006). The disability has been associated with an increase in fee costs for home care and treatment of concurrent medical problems; pain treatment can be difficult: often the pain is not adequately controlled with oral medication alone. It has been calculated that 40% of women of average age (8 out 20) and 15% of middle-aged men (3 out 20) will present one or more osteoporotic fractures during their lifetime (Silverman, 1992). Vertebral compression fractures and the fractures of sacrum have inherent characteristics that are influenced by the biomechanics of each spinal element. VCFs are clearly caused by a number of different force vectors. The intrinsic alignment of the column, the presence or absence of kyphosis or lordosis, has a direct influence on the type of fracture. VCFs in the lumbar and cervical areas are typically determined by a bending mechanism. Since the 3/4 of body weight are distributed in 2/3 of the anterior part of spine, it is common to observe the compression of the anterior part of the vertebral body without involvement of the posterior vertebral wall and the connected elements (Denis, 1983). Vertebral fractures can occur with many simple variants: there may be compression of the posterior wall with or without protrusion of fragments into the spinal canal, whose presence always results in compressive spinal cord or nerve disease; some fractures may lead to the creation of air-filled cavities or liquid in the vertebral body; vertebral compression can be extreme with a loss of vertebral body height more than 70%, ("vertebra plana"). Less frequently, VCFs are caused by trauma, the so-

called burst fractures, characterized by multiple interruptions along the perimeter of the body; less common are those in which there is a separation of the front and the back of the vertebral body (Magerl et al., 1994). It is important to note that the percentage loss of vertebral body height is not related to the amount of pain experienced by the patient nor the duration of pain. The upper endplate is most frequently affected by fractures than the lower one. Most fractures related to osteoporosis are located in the midthoracic (T7-T8), thoracolumbar (T11-T12), and lumbar regions. At the sacrum, rather than vertebral compression fractures, we observe fracture lines that give rise to the so-called sacral insufficiency (Schindler et al., 2007). Fractures can affect one or both wings of the sacrum with or without involvement of the central part. VCFs are associated with significant morbidity with difficulty to perform common activities of daily living and increased mortality directly related to the number of fractures and deformities secondary to changes in the kyphotic spine. These deformities cause respiratory and gastrointestinal disorders. VCFs reduce lung function: a thoracic VCF causes a loss of 9% of forced vital capacity, and lung function (FVC, FEV 1) decreased significantly in patients with thoracic and lumbar fractures (Sclaich et al., 1998). In addition, once an osteoporotic vertebral fracture occurred, the risk of subsequent fracture is increased by 5 to 10 times. In patients with VCF the risk of mortality increases of 23-34%; it has been also observed that in case of hip or vertebral fracture, there is an increased risk of mortality, respectively, from 7 to 9 times (Lindsay et al., 2001).

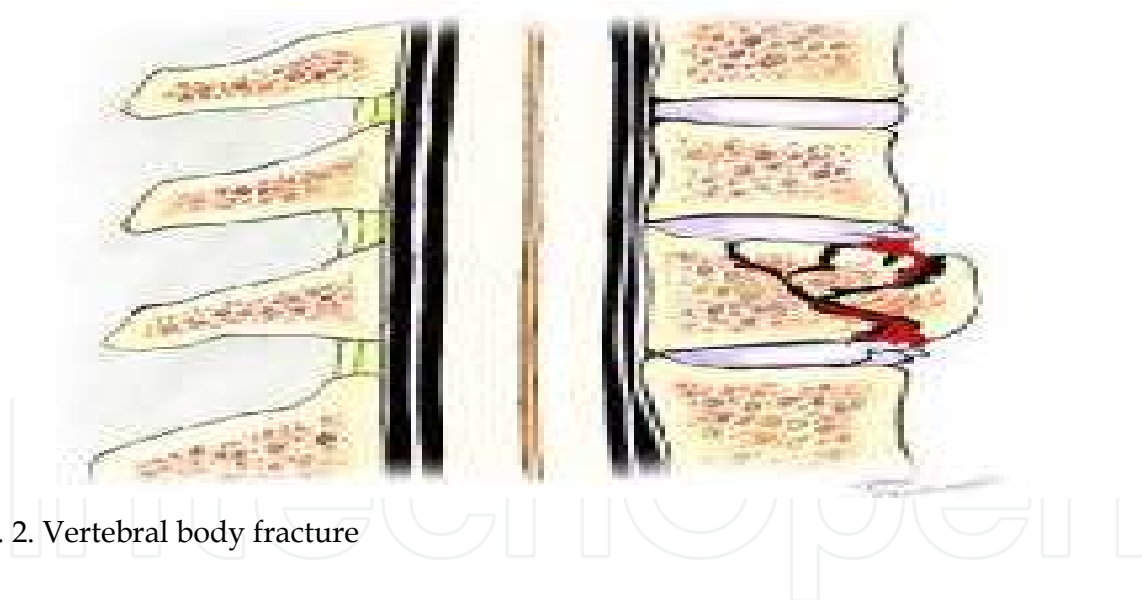


Fig. 2. Vertebral body fracture

4. Evaluation and selection of the patient

Due to the complex etiology of back pain, sometimes the diagnosis of vertebral fracture is delayed despite the persistence of severe back pain and the initial defects of posture not attributable to other causes (Nolla et al., 2001). It has been observed that in most cases the fracture has been recognized during a routine examination. The pain ranges from mild to intense, it can become chronic, but it can also disappear after a few weeks, that is, once the fracture has consolidated. The persistence of pain is higher in people in whom the bone repair is slower. In the acute phase there may be a sudden back pain after a slight injury or no history of trauma; painful is elicited with local palpation over the posterior elements of

the involved vertebral body, with no radicular pain. In the chronic phase we observe a deformity of the spine, due to loss of height of the vertebral body and the gradual emergence of a protuberant abdomen. The residual back pain in patients with healed vertebral fracture is typically of muscular origin and derives from the now permanent spinal deformity caused by the fracture. In patients with vertebral fracture, in fact, the center of gravity moves forward, creating a wide anterior flexor movement, while muscles of the back and ligaments must offset the increase in flexion. In the presence of contributory causes of back pain (i.e. arthritis and stenosis), treatment of vertebral fracture is not able to offer complete relief from pain.

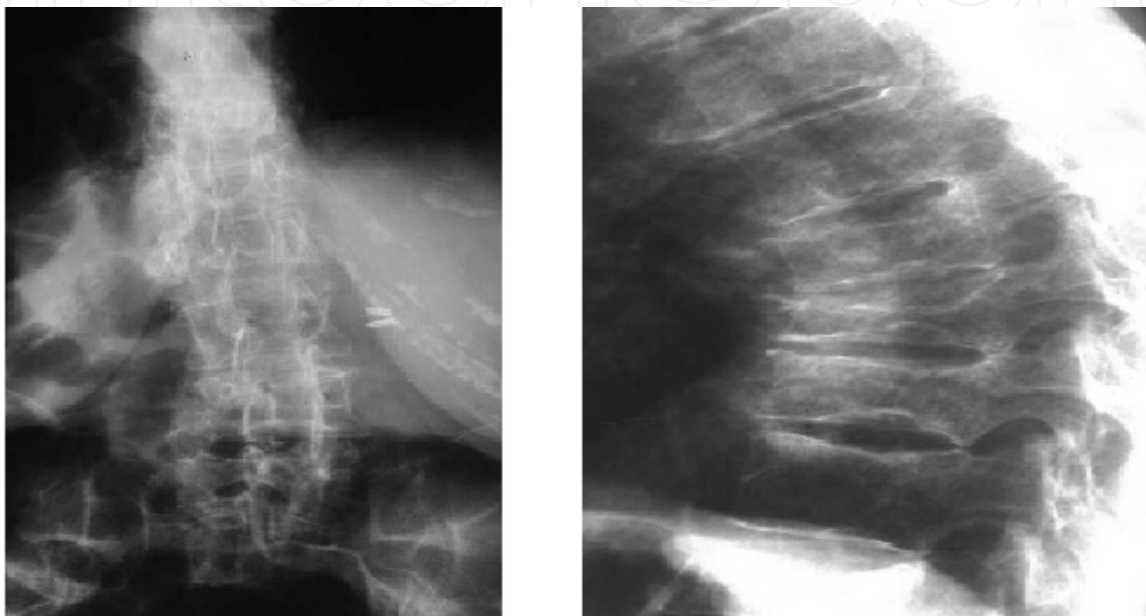


Fig. 3. AP and LL images of dorsal column with a VCF

In order to correctly diagnose a vertebral fracture, we need a thorough neurological examination to rule out concomitant causes and an accurate X-ray imaging (fig. n. 3). The X-ray imaging includes: preferably a plain radiograph in lateral position as very often the vertebral fracture can be difficult to diagnose if the examination is performed in the anteroposterior position as the direction of the beams is not parallel to the endplates; MRI sequences with T1, T2 and STIR weighted sequences; a CT scan of the affected vertebra; in alternative a bone scan. When the patient with suspected vertebral fracture undergoes an MRI examination, the aim is to look for the edematous reactive component. The finding of bone marrow edema during an MRI is very useful in predicting which patients will benefit most from treatment. Fractures of recent onset, thus with the presence of edema, are those that best respond to the treatment. On sagittal T1-weighted sequences, edema associated with compression appears dark, compared with the high (bright) signal normally seen in the marrow fat. Heavily T2-weighted sequences are the most sensitive, with fluid representing marrow edema; standard T2-weighted fast spin-echo sequences without fat saturation pulse are often insensitive to marrow edema because of the relatively high signal intensity from fatty marrow.

Finally MRI with short tau inversion recovery (STIR) sequences can eliminate all the fatty component to show only the reactive fluid component. In the event that it is impossible to perform an MRI, the patient may undergo a bone scan that identifies osteoblast activity;

unfortunately osteoblast activity has been active for about two years after the fracture and the level of the vertebra with fracture is difficult to identify. CT scan however is mandatory to assess the integrity of the posterior wall of the vertebral body and to assess eventual posterior displacement of bone fragments and eventually to assess the adjacent vertebrae (Wehrli et al., 1995).

5. Techniques of pain relief in vertebral compression fractures

Purpose of the augmentation / stabilization techniques, in case of vertebral fracture, is to obtain adequate pain relief, to ensure the healing of vertebral body so to allow the rapid resumption of activities related to daily life, possibly to restore the height of the vertebral body and thus to counteract spinal kyphosis and the consequences related to it. The spinal augmentation / stabilization techniques are indicated in patients in whom conservative treatment represents another cause of morbidity due to bed rest, immobility and intolerable side effects related to analgesics prescribed, or when an “open” surgical procedure is not advisable on the basis of the patient's clinical condition. The techniques that we will describe are: vertebroplasty (Mathis et al., 2001), balloon kyphoplasty (Taylor et al., 2007) and vertebral stabilization by percutaneous pedicular screws (Foley et al., 2001). Biplane fluoroscopy allows the procedures to be performed more rapidly, but they can also be accomplished safely with a single-plane C-arm; CT has been described as an aid to fluoroscopy, but it adds considerable complexity and cost to the procedure without corresponding benefit to the routine treatment of a VCF (Gangi et al., 1994).

5.1 Vertebroplasty

Vertebroplasty (VP) was performed as an open procedure to improve the grip of pedicle screws in spinal surgery or during filling of the continuous solutions in the vertebral body after resections for cancer. Percutaneous VP was performed for the first time by Galibert and Deramond (Galibert et al., 1987) for the treatment of severe neck pain secondary to a hemangioma that affected the entire body of C2; after an intervention of laminectomy and resection of the neoplastic component invading the epidural space, they decided to strengthen the structure of the vertebra by the injection of polymethylmethacrylate (PMMA) by anterolateral percutaneous approach. The amount of PMMA injected was 3 ml, with a complete pain relief. The technique was then introduced in the U.S., where it was used primarily to treat pain from osteoporotic vertebral fracture (Deramond et al., 1998). After other experiences, the same authors established key points for the execution of this technique (Mathis et al., 2001). They decided to use large-bore needle (10-13 gauge) for the thoracic and lumbar levels and a smaller needle (13-15 gauge) for the cervical level; the PMMA was made opaque by the addition of contrast to make it visible when injected and to evaluate the distribution during the injection. After a small skin incision, the disposable bone needle is advanced, under fluoroscopic guidance, using an unilateral or bilateral transpedicular/extrapedicular approach (at lumbar and thoracic spine level respectively) through the centre of the pedicle (fig. n. 4), and then into the vertebral body with the expectation that the central portion of the vertebra can be filled. Fluoroscopy, with frequent switching between the frontal and lateral projections, ensures that the needle is correctly positioned. The tip of the needle should be placed within the anterior one-third of the vertebral body, close to the midline; biopsy, if indicated, can be performed before final

needle placement. Once the needle has been inserted into vertebral body, the cement (polymethylmetacrylate-PMMA) is prepared and mixed until it becomes like toothpaste and then injected through the needle (between 3 - 6 ml) under continuous lateral fluoroscopic control in order to observe and prevent any cement leakage. The cement diffuses into space and tends to solidify in 1 hour, stabilizing the vertebral body. After procedure, in fact, the patient must remain lying down for several hours, to prevent movement of cement that is not yet consolidated. The approach to the cervical vertebrae is anterior; needle introduction should preferably be done on the right side (opposite the esophagus) and avoiding carotid artery, internal jugular vein, vertebral artery and esophagus.

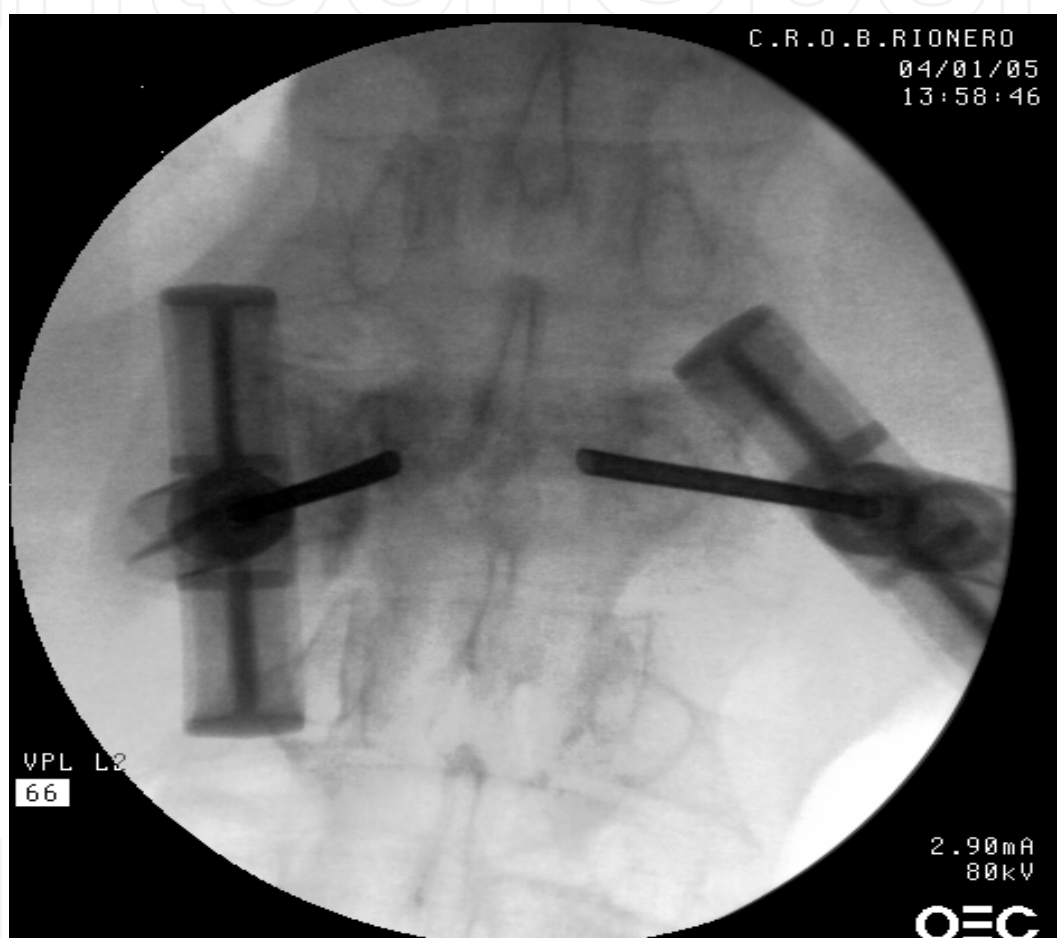

Fig. 4. AP X-ray image of vertebroplasty

Vertebroplasty is a treatment used to get relief from pain, but has little or no effect on the recovery of the height of the vertebral body fractured. The mechanisms, by which we obtain adequate analgesia, are two: the first mechanism is based on the ability of PMMA to combine the individual bone fragments in a single block, avoiding the painful micro shiftings of individual fragments between them. The second mechanism may be related to the exothermic process that accompanies the polymerization of PMMA and that would result in a "thermal neurolysis" of the nerve within the vertebral body. In addition, the PMMA results in a significant strengthening of osteoporotic bone, reducing the risk of subsequent fractures. The incidence of complications ranges from 1 to 3% in osteoporotic vertebrae.

The majority of complications could be divided into:

- minor:
 - bleeding of the site of needle insertion,
 - rib fracture ,
 - transient fever
 - transient worsening of pain symptoms secondary to the heat produced by the polymerization of the cement,
 - cement leaks into the disk or in paravertebral soft tissues
 - new fractures in adjacent vertebrae (Lindsay et al., 2001)
- moderate
 - irritation of the nerve trunks,
 - cement leak in epidural space
 - needle displacement
 - infection
- severe
 - cement leaks into paravertebral veins, leading to pulmonary embolism, cardiac perforation, cerebral embolism and even death. (less than 1% when treating osteoporotic compression fractures, increasing to 2-5% when treating osteolytic metastatic disease) (Scroop et al., 2002).

The possible extrusion of cement in the spinal canal (which occurs with an incidence of 3%) is a feared complication, requiring immediate surgical decompression in an attempt to limit the damage from spinal cord compression (Mathis, 2003). Cement can also leak into the disk space. We do not know actually if a cement leak into the disk may be responsible for fracture of an adjacent vertebra as adjacent-level fractures after VP are known to occur also without leak.

After vertebroplasty, it has been reported a marked improvement in pain symptoms in 90% of cases, but residual pain may persist in the early days, in the area of needle insertion or for muscle distraction. The complete disappearance of pain, accompanied by the discontinuation of analgesic drugs has been observed after 3 to 6 weeks. Despite the disappearance of pain, the patient must pay attention to physical activity as the possibility of subsequent vertebral fracture is always present.

5.2 Kyphoplasty

Kyphoplasty (KP) has been introduced as an alternative approach in US (Garfin et al., 2001). It can be performed in thoracic vertebrae from T5 to T12 and on all lumbar vertebrae. It is similar to vertebroplasty and has been referred to as “balloon-assisted vertebroplasty” (BKP). Kyphoplasty is a technological advancement of vertebroplasty (fig. n. 5); beside the relief of pain secondary to the VCF, it is possible to obtain a partial recovery of the height of the vertebral body (Lieberman et al., 2001). To restore vertebral anatomy after a fracture, the vertebral endplates must be reduced to their correct anatomic position. This action requires the volume of vertebral body to be increased (creation of a void) and requires sufficient separating force to move the endplates (reduction). The reduction of the fractured vertebra reduces the kyphosis of the spine; this effect determines an esthetic improvement (posture) and could reduce the risk of fracture of the adjacent vertebra as a result of abnormal load bearing. Kyphoplasty entails the inflation of a percutaneously delivered balloon in the

vertebral body; the balloon restores the vertebral body height in addition to creating the cavity. Into the cavity created by the balloon, a preparation of PMMA thicker than that used in vertebroplasty is then injected under relatively low pressure; because this PMMA is more viscous than that used for vertebroplasty and it is injected under lower pressure than in vertebroplasty, the risk of intravascular extrusion is thought to be lower. The risk of cement extravasation is reduced due to containment produced by the newly created vertebral cavity. The entity of the vertebral body reduction varies from case to case, depending by the maximum volume of the balloon inflated and the pressure required to. Although associated with a finite level of cement leakage, serious adverse events appear to be rare. Osteoporotic vertebral compression fractures appear to be associated with a higher level of cement leakage following BKP than non-osteoporotic vertebral compression fractures (Taylor et al., 2007).

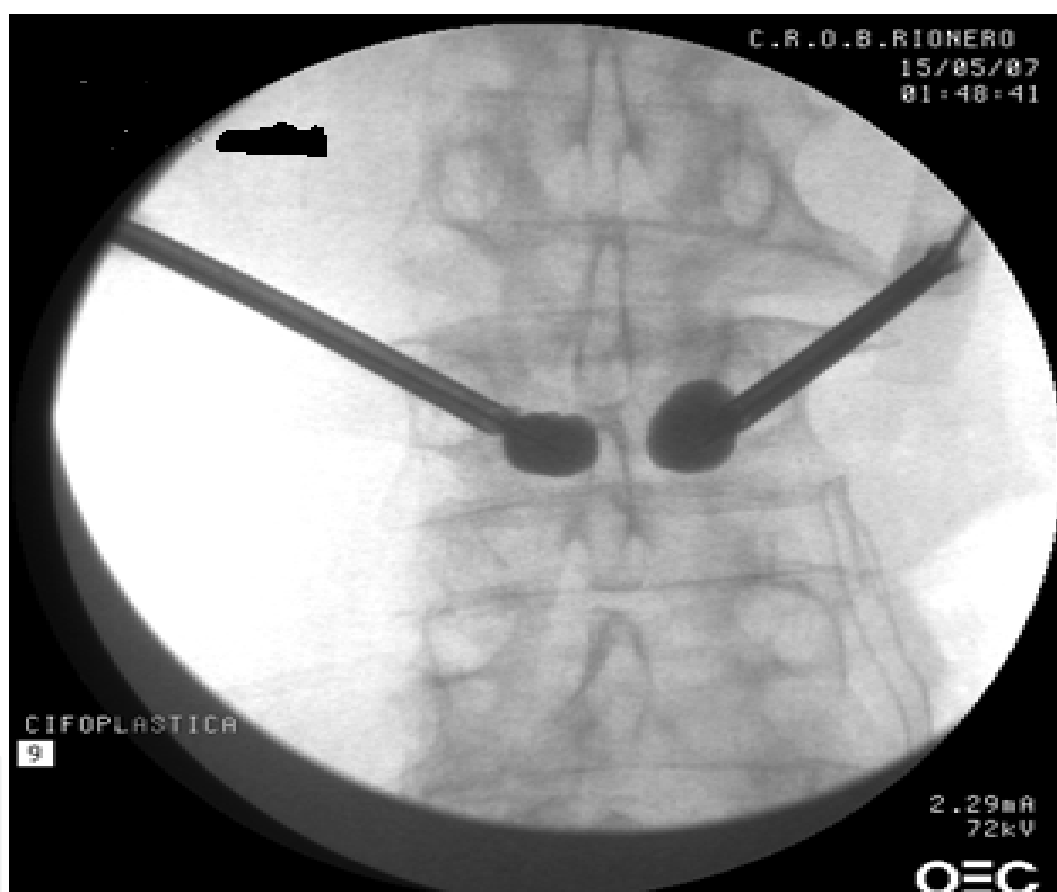

Fig. 5. AP X-ray image of kyphoplasty

In 2009 it has been conducted a study in which 300 patients have been randomly assigned to receive kyphoplasty treatment or non-surgical care. The primary outcome has been the difference in change from baseline to 1 month in the short-form (SF)-36 physical component summary (PCS) score between the kyphoplasty and control groups. Quality of life and other efficacy measurements and safety have been assessed up to 12 months. Serious adverse events (such as myocardial infarction and pulmonary embolism) did not occur perioperatively and were not related to procedure. Authors concluded that balloon kyphoplasty was an effective and safe procedure for patients with acute vertebral fractures and could be used as an early treatment option (Wardlaw et al, 2009).

5.3 Cement selection

The introduction of an external component in the human body brings up the general problem of biocompatibility. Several types of cement are actually available: the recent development of polymethyl methacrylate cement (**PMMA**s) and the market introduction of new cements like **composite cements** and **calcium phosphate cements**, allow physicians to choose the best material for the treatment of different lesions causing vertebral pain.

5.3.1 Polymethyl methacrylate (PMMA)

The most commonly used cement is poly-methyl methacrylate (PMMA) and its function is to immobilize the fracture and increase the strength of the vertebra. PMMA cements fall into two general categories: rapid set or slow set types. Most inexperienced operators initially feel more comfortable by using the slow-set varieties, because these materials allow more working time of the cement at room temperature; however, the rapid-set materials offer definite advantages that quickly surface. A new acrylic osseous cement, with 10% hydroxyapatite well-known for its osteo-conductive properties, possesses better biocompatibility than traditional cements. The hydroxyapatite particles on the surface of the cement improve the response from the osteoblasts, consequently reducing inflammatory reactions. The high viscosity properties of Confidence Spinal Cement System ©(DePuy Spine, Inc 2011) allows for interdigitation, preserving the trabecular structure of bone; this cement shows immediate post-mixing high viscosity, so reducing the potential leakage within vertebral body. *N*-methyl-pyrrolidone (NMP) has been added to a PMMA bone cement (Boger et al., 2009) making the PMMA cement more compliant for the use in cancellous bone augmentation in osteoporotic patients due to modification of its mechanical properties similar to those of cancellous bone, a lower polymerization temperature, and an extended handling time.

5.3.2 Composite cements

They have been used since the late 1970's in orthopedic applications, like pedicle screws augmentation. Those cements offset the disadvantages of PMMA like the exothermic reaction, the release of unreacted monomer in the circulatory system and the modification of the initial composition of the PMMA (changes in the monomer-to-polymer-ratio and addition of contrast materials). Moreover they appear to be more biocompatible, easy-to-handle with sufficient radiopacity and with good biomechanical properties. One of these composite cements is Cortoss® (Sun et al., 2008) developed by Orthovita-Malvern, USA, a glass-ceramic reinforced cement based on the Bowen molecule diluted with triethylene glycol dimethacrylate (TEGDMA) (Smit et al., 2008). The optimal temperature of Cortoss® to be used is as close as possible to 20°C. Higher temperature will reduce the setting time; to obtain a good fluoroscopic visualisation, there is no need to modify Cortoss, as it contains over 65% of radiopaque fillers.

5.3.3 Calcium phosphate cements (CPCs)

Calcium phosphate cements (CPCs) are made of different calcium phosphate (CaP) powders and an aqueous solution belonging to the category of the low-temperature cements. CaPs are very similar to the mineral part of bone. They are less injectable if compared with other PMMA cements, which are hydrophobic and tend to stay compact within the vertebral bodies. In order to prevent this problem, we could create a cavity in the vertebral body with an expandable balloon and filling the new cavity with CPC or removal of bone

marrow from the vertebrae using a suction device and injection of the CPC. CPCs are justified in the treatment of recent burst fractures of thoracolumbar vertebral bodies in young patients (Bohner et al., 2005).

5.4 Pedicle screw-assisted spinal stabilization

The use of pedicle screw-assisted spinal stabilization (Foley et al., 2001; Fuentes et al., 2010) has become popular worldwide; pedicle screw fixation is a safe and effective treatment for many spinal disorders, including vertebral fractures not suitable to be treated by vertebroplasty/kyphoplasty. Standard “open” techniques for pedicle screw placement have been associated with a wide median incision of the back and the disconnection of large muscle areas, to allow adequate visualization of the spine and bone, for easy access, with extensive blood loss, lengthy period of hospitalization and costs. Recently it has been introduced into the market a minimally invasive posterior fixation of the lumbar spine in which percutaneous screws and rods are used, minimizing paraspinous tissue trauma without sacrificing the quality of spinal fixation (fig. n. 6).

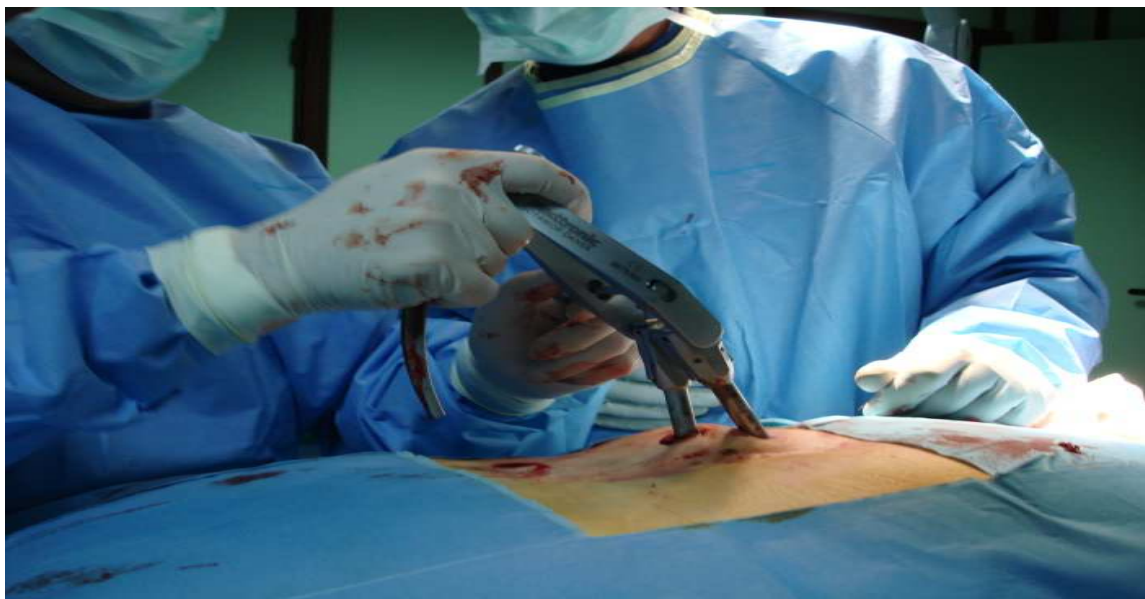

Fig. 6. Live insertion of percutaneous screw assisted spinal stabilization device

In fact the minimally invasive techniques with the aid of new fluoroscopy generation allows to place percutaneous spinal instrumentation accurately, through small skin incisions and with minimal radiation exposure. The vertebral pedicles represent a very strong connecting structure in the spine, so the placement of a screw inside the pedicle allows for a significant strengthening of the vertebra. The length of screws varies according to different dimensions of the pedicles. The most common screws are made of titanium and are equipped with a head (poliassial screws) that can rotate so as to adapt to different conditions and anatomical locations. Once placed, the rods can be percutaneously inserted into the screws, contributing to the stabilization of the spine (fig. n. 7). The benefit of percutaneous intervention is evident because the surgical incisions are less painful, blunt dissection and the muscle dilation do not alter the normal anatomy, blood loss is minimal, the scars are esthetically irrelevant and hospital stay is significantly reduced. Although there are still not many prospective randomized studies comparing conservative treatment versus mini-invasive methods of

vertebral stabilization (Kallmes et al., 2009; Buchbinder et al., 2006; Clazen et al., 2010; Clark et al., 2011), pain relief is often achieved in 80% of cases with the latter within a few hours, stopping the progression of the deformity of the spine, even in long-term studies.

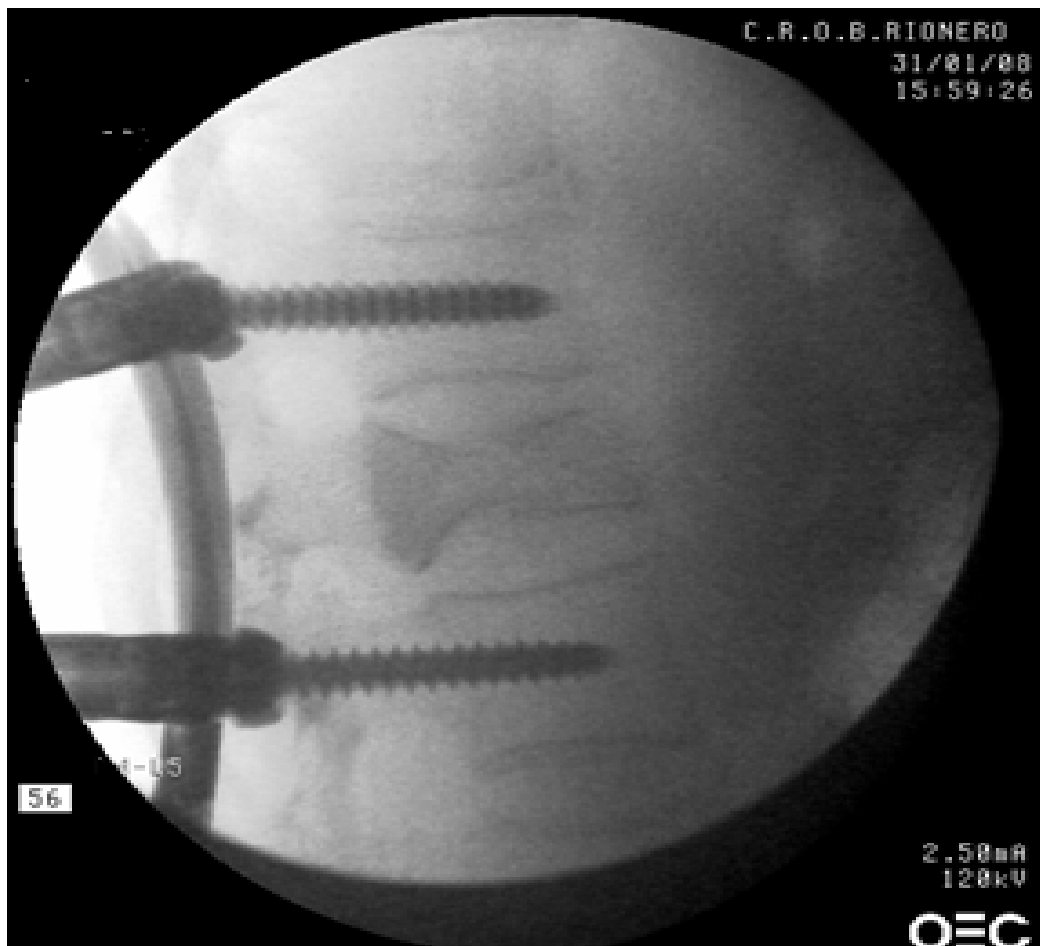


Fig. 7. LL X-ray image of percutaneous screw assisted spinal stabilization device

The immediate analgesic effect is due to cement injection into the fracture, while the long-term effect is guaranteed by stabilization or correction of spinal deformity, which guarantees not only the restoration of proper biomechanics but also the reduction in fracture risk of other vertebrae. The improvement of quality of life is significant, allowing more motor activity of the patient, which in turn leads to better preservation of bone mass and thus fracture risk containment, not only of the spine.

6. Controversies

Buchbinder et al. in 2009 performed a multicenter, randomized, double-blind, placebo-controlled trial in which participants with painful osteoporotic vertebral fractures not older than one year and unhealed, were randomly assigned to undergo vertebroplasty or a sham procedure. Outcomes were assessed at 1 week and at 1, 3, and 6 months; the primary outcome was pain evaluation at 3 months. They found no beneficial effect of vertebroplasty as compared with a sham procedure in patients at 1 week or at 1, 3, or 6 months after treatment.

Kallmes et al. in 2009 in a multicenter trial, randomly assigned 131 patients with painful osteoporotic vertebral compression fractures to undergo either vertebroplasty or a simulated procedure without cement; patients were allowed to cross over to the other study group after 1 month. For those receiving the sham procedure, 42% opted to receive VP at three months, compared with 12% for the other arm. The two groups did not differ significantly on Roland-Morris Disability Questionnaire (RDQ) or average pain intensity at 1 month, but there was a trend toward a higher rate of clinically meaningful improvement in pain in the vertebroplasty group. The authors found that improvements in pain and pain-related disability associated with vertebral fractures in patients treated with vertebroplasty were similar to the improvements of control group. Anyway the higher rate of cross-over could reflect dissatisfaction with the sham procedure compared with PV, or possibly flaws in the blinding of the sham procedure such that patients were able to "guess" which intervention underwent. Clark et al. and Baerlocher et al. in 2009 criticized the previous study underlying that a more appropriate selection criterion would have included patients with uncontrolled pain for less than 6 weeks as the number of patients with pain for less than 6 weeks was too small for a subgroup analysis. Moreover the study of Buchbinder had a target enrollment of 200 patients, but only 78 were enrolled over 4 years, substantially limiting statistical power. More criticism evidenced that in the study, described as multicenter trial, two of the four hospitals withdrew early from the study, after enrolling five patients each; 68% of the procedures were performed in one hospital by one radiologist; respectively 64% and 70% of eligible patients declined to participate in trials reported by Buchbinder and Kallmes raising further concerns regarding patient selection. Both trials did not examine the role of VP in non osteoporotic vertebral fractures or in the inpatient setting (Weinstein, 2009). Recently a multicenter study, the so called VERTOS II, randomized over 200 patients with a vertebral compression fracture and pain of less than 6 weeks duration to conservative treatment or VP; participants and physicians as well as outcome assessors were not blinded. Sham procedure was not performed. Authors found a statistically significant reduction in pain in the VP arm after one month and one year (Clazen et al., 2010). Rousing et al. reported a 12-month follow-up from an open-label, randomized study including 50 patients with a vertebral fracture less than 8 weeks comparing VP with conservative management. They observed an immediate and significant pain relief following VP. One month after hospital discharge, patients undergone VP, had a statistically significantly reduction in pain compared with the ones in conservative therapy arm. However, no difference in pain scores have been observed between groups after 3 and 12 months. They suggested that the role of VP may therefore be considered as a short-term method of pain control in those who fail conservative treatment or for those whom conservative treatment and the accompanying immobilization carry serious risks (Rousing et al., 2010).

7. Conclusions

Long-term effectiveness and complication data from VP or KP are currently lacking. Performing a true blinded randomized-controlled trial between conservative therapy and invasive techniques is impossible. It is the authors' opinion that for patients who are failing conservative treatment or are at increased risk from prolonged bed rest, (i.e. older patients or patients with COPD), augmentation techniques could offer a good pain relief in comparison to conservative treatment, even if no durable long-term benefit has been yet demonstrated. On the other side patients with pain of greater than three months duration

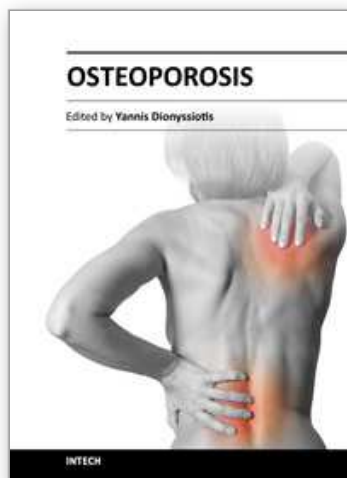
are less likely to benefit from these techniques. Patients need to be carefully screened by history, examination, and imaging prior to the procedure, so to identify the subgroup of patients who may really get benefit from these vertebral augmentation procedures. VP and KP remain an important intervention for the treatment of those patients hospitalized due to severe pain following osteoporotic-induced vertebral fracture.

8. References

- Boger A, Wheeler K, Montali A & Gruskin E. NMP-Modified PMMA Bone Cement with Adapted Mechanical and Hardening Properties for the Use in Cancellous Bone Augmentation. *Journal of Biomedical Materials Research Part B: Applied Biomaterials*. 2009; Vol. 90B, Issue 2: 760–766
- Bohner M., Gbureck U. & Barralet J. Technological issues for the development of more efficient calcium phosphate bone cements: A critical assessment. *Biomaterials* 2005; Nov 26 (33): 6423–9.
- Bouvard B, Hoppé E, Soulié P, Georgin-Mege M, Jadaud E, Abadie-Lacourtoisie S, Petit Le Manac'h A, Laffitte A, Levasseur R, Audran M, Chappard D, Legrand E. High prevalence of vertebral fractures in women with breast cancer starting aromatase inhibitor therapy. *Ann Oncol* 2011; first published online September 7, 2011
- Buchbinder R, Osborne RH & Kallmes D. Vertebroplasty appears no better than placebo for painful osteoporotic spinal fractures, and has potential to cause harm (editorial). *Med J Aust* 2006; Nov 2, 191(9): 476–7
- Buchbinder R, Osborne RH., Ebeling PR., Wark JD., Mitchell P, Wriedt C, Graves S, Staples M P. & Murph B. A Randomized Trial of Vertebroplasty for Painful Osteoporotic Vertebral Fractures. *N Engl J Med* 2009; August 6, 361: 557–568
- Cauley JA, Thompson DE, Ensrud KC, Scott JC, Black D. Risk of mortality following clinical fractures. *Osteoporos Int* 2000; Vol. 11, Issue 7 : 556–561.
- Clark WA, Burnes JP & Lyon SM. Vertebroplasty for acute osteoporotic fractures – position statement from the Interventional Radiology Society of Australasia. *Journal of Medical Imaging and Radiation Oncology* 2011; Vol 55, Issue 1 : 1–3
- Dempster DW. Osteoporosis and the burden of osteoporosis-related fractures. *Am J Manag Care* 2011 May; 17(6 Suppl): S164–9.
- Denis F. Spinal instability as defined by the three column spine concept in acute spinal trauma. *Clinical Orthopedics and Related Research* 1984; Oct 189: pp 65–76
- Deramond H, Depriester C, Galibert P & Le Gars D. Percutaneous vertebroplasty with polymethylmethacrylate: technique, indications, and results. *Radiol Clin North Am* 1998; May 36, 3: 533–546
- De Smet AA, Neff JR. Pubic and sacral insufficiency fractures: Clinical course and radiologic findings. *AJR Am J Roentgenol*. 1985; 145: 601–606.
- Duan Y, Seeman E & Turner CH. The biomechanical basis of vertebral body fragility in men and women. *J Bone Miner Res* 2001; Dec, 16, 12: 2276–2283
- Eastell R, Cedel SL, Wahner HW, Riggs BL, Melton III LJ. Classification of vertebral fractures. *Journal of Bone and Mineral Research*. 1991, March, Volume 6, Issue 3: pp 207–215
- European Prospective Osteoporosis Study (EPOS) Group. Incidence of vertebral fracture in Europe: results from the European Prospective Osteoporosis Study (EPOS). *J Bone Miner Res* 2002; Apr 17, 4: 716–724

- Foley KT, Gupta SK, Justis JR & Sherman MC. Percutaneous pedicle screw fixation of the lumbar spine. *Neurosurg Focus* 2001;10 (4):Article 10
- Frank PM. Minimally Invasive Treatments of Osteoporotic Vertebral Compression Fractures. *Spine* 2003, Vol.28, Issue 15S, pp S45-S53
- Fuentes S, Blondel B, Metellus P, Gaudart J, Adetchessi T & Dufour H. Percutaneous kyphoplasty and pedicle screw fixation for the management of thoraco-lumbar burst fractures. *Eur Spine J*. 2010;Aug 19, 8:1281-7
- Galibert P, Deramond H, Rosat P & Le Gars D. Preliminary note on the treatment of vertebral angioma by percutaneous acrylic vertebroplasty [in French]. *Neurochirurgie* 1987;33, 2 :166-168
- Gangi A, Kastler BA & Dietemann JL. Percutaneous vertebroplasty guided by a combination CT and fluoroscopy. *AJNR Am J Neuroradiol* 1994;Jan 15, 1:83-86
- Garfin SR, Yuan HA & Reiley MA. New technologies in spine: kyphoplasty and vertebroplasty for the treatment of painful osteoporotic compression fractures. *Spine (Phila Pa 1976)*. 2001;Jul 15, 26, 14:1511-5
- Gray H. Osteology. In: Goss CM, ed. *Anatomy of the Human Body*. 29th ed. Philadelphia, Pa: Lea & Febiger;1973: 100-4.
- Groen RJM, du Toit DF, Phillips FM, Hoogland PVJM, Kuizenga K, Coppes MH, Muller CJF, Grobbelaar M & Mattysen J. Anatomical and Pathological Considerations in Percutaneous Vertebroplasty and Kyphoplasty: A Reappraisal of the Vertebral Venous System. *Spine* 2004, Vol 29, Issue 13: 1465-1471
- Haczynski J & Jakimiuk A. Vertebral fractures: a hidden problem of osteoporosis. *Med Sci Monit* . 2001; 7(5):1108-17 (ISSN: 1234-1010)
- Johnell O. & Kanis J. A. An estimate of the worldwide prevalence and disability associated with osteoporotic fractures . *Osteoporosis International* 2006, Vol 17, Issue 12: pp. 1726-1733
- Kallmes DF, Comstock BA, Heagerty PJ, Turner JA, Wilson DJ, Diamond TH, Edwards R, Gray LA, Stout L, Owen S, Hollingworth W, Ghdoke B, Annesley-Williams DJ, Ralston SH, & Jarvik JG. A Randomized Trial of Vertebroplasty for Osteoporotic Spinal Fractures. *N Engl J Med* 2009;Aug 6, 361, 6:569-579
- Klazen C, Lohle P, de Vries J, Jansen FH, Tielbeek AT, Blonk MC, Venmans A, van Rooij W J J, Schoemaker MC, Juttman JR, Lo TH, Verhaar H J J, van der Graaf Y, van Everdingen K J, Muller A F, Elgersma O E H, Halkema D R, Fransen H, Janssens X, Buskens E & Mali W P Th M. Vertebroplasty versus conservative treatment in acute osteoporotic vertebral compression fractures (VERTOS II): an open-label randomised trial. *The Lancet*, 2010;Sep 25, vol. 376: pp. 1085-1092
- Lieberman IH, Dudeney S, Reinhardt MK et al. Initial outcome and efficacy of kyphoplasty in the treatment of painful osteoporotic vertebral compression fractures. *Spine* 2001;July 15,26, 4:1631-1638
- Lindsay R, Silverman SL, Cooper C, Hanley DA, Barton I, & Broy SB. Risk of a new vertebral fracture in the year following a fracture .*JAMA* 2001;Jan 17, 285, 3:320-323
- Magerl F, Aebi M, Gertztein SB, Harms J & Nazarian S. A comprehensive classification of thoracic and lumbar injuries.*Eur J Spine* 1994;3, 4:184-201
- Mathis JM, Barr JD, Belkoff SM , Barr MS, Jensen ME & Deramond H. Percutaneous Vertebroplasty: A Developing Standard of Care for Vertebral Compression Fractures . *AJNR Am J Neuroradiol* 2001;Feb 22, 2:373-381

- Mathis JM. Percutaneous vertebroplasty: complication avoidance and technique optimization. *AJNR Am J Neuroradiol* 2003; Sep 24, 8:1697-1706
- Naganathan V, Jones G, Nash P, Nicholson G, Eisman J & Sambrook PN. Vertebral Fracture Risk With Long-term Corticosteroid Therapy. *Arch Intern Med.* 2000; Vol 160:2917-2922
- Nolla JM, Gomez-Vaquesro C, Romera M, Roig-Vilaseca D. Osteoporotic vertebral fracture in clinical practice: 669 patients diagnosed over a 10 year period. *J. Rheumatol.* 2001; Oct 28, 10:2289-2293
- O'Neill T. W., Felsenberg D., Varlow J., Cooper C., Kanis J. A. & Silman A. J. The prevalence of vertebral deformity in European men and women: The european vertebral osteoporosis study. *Journal of Bone and Mineral Research.* 1996, July Vol 11, Issue 7: pp 1010-1018
- Oleksik A, Lips P, Dawson A, Minshall ME, Shen W, Cooper C & Kanis J. Health-related quality of life (HRQOL) in postmenopausal women with low BMD with or without prevalent vertebral fractures. *J Bone Miner Res* 2000; 15:1384-1392.
- Ortiz OO, Deramond H. Spine anatomy. In : *Percutaneous Vertebroplasty*. JM Mathis, H Deramond, and SM Belkoff (eds). New York Springer, 2001:7-24
- Prather H, Watson JO & Gilula LA. Nonoperative management of osteoporotic vertebral compression fractures. *Injury* . 2007; 38 Suppl 3:S40-8 (ISSN: 0020-1383)
- Rousing R, Hansen KL, Andersen MO, Jespersen SM, Thomsen K & Lauritsen JM. Twelve-months follow-up in forty-nine patients with acute/semiacute osteoporotic vertebral fractures treated conservatively or with percutaneous vertebroplasty: a clinical randomized study. *Spine*, 2010; vol. 35, no. 5, pp. 478-482.
- Schindler OS, Watura R & Cobby M. Sacral insufficiency fractures. *Journal of Orthopaedic Surgery* 2007; Vol. 15, no. 3:339-46
- Sclaich C, Minne HW, Bruckner T, Wagner G et al. Reduced pulmonary function in patients with spinal osteoporotic fractures. *Osteoporosis Int* 1998; 8, 3:261-267
- Scroop R, Eskridge J & Britz GW. Paradoxical cerebral arterial embolization of cement during intraoperative vertebroplasty: case report. *AJNR Am J Neuroradiol* 2002; May 23, 5:868-870
- Smit RS, van der Velde D & Hegeman JH. Augmented pin fixation with Cortoss® for an unstable AOA3 type distal radius fracture in a patient with a manifest osteoporosis. *Arch Orthop Trauma Surg* 2008; Sep 128, 9: 989-993
- Sun K, Mendel E, Rhines L, Burton A & Liebschner M. Disperse cement filling in vertebroplasty may reduce risk of secondary tissue damage. *Eur Cell Mater* 2006; 11: 12 (abstr).
- Taylor RS, Fritzell P & Taylor RJ. Ballon kyphoplasty in the management of vertebral compression fractures: an updated systematic review and meta-analysis. *Eur Spine J* 2007; 16:1085-1100
- Trials of Vertebroplasty for Vertebral Fractures. *N Engl J Med* 2009; Dec 24, 361, 26:2097-2100
- US Department of Health and Human Services. Bone Health and Osteoporosis: a report of the surgeon general. Rockville, MD: US Department of Health and Human Services, 2004
- Wehrli FW, Ford JC & Haddad JG. Osteoporosis: clinical assessment with quantitative MR imaging in diagnosis. *Radiology* 1995; Sep 196, 3:631-641
- Weinstein JN. Balancing Science and Informed Choice in Decisions about Vertebroplasty. *N Engl J Med* 2009; Dec 24, 361, 26:619-621



Osteoporosis

Edited by PhD. Yannis Dionyssiotis

ISBN 978-953-51-0026-3

Hard cover, 864 pages

Publisher InTech

Published online 24, February, 2012

Published in print edition February, 2012

Osteoporosis is a public health issue worldwide. During the last few years, progress has been made concerning the knowledge of the pathophysiological mechanism of the disease. Sophisticated technologies have added important information in bone mineral density measurements and, additionally, geometrical and mechanical properties of bone. New bone indices have been developed from biochemical and hormonal measurements in order to investigate bone metabolism. Although it is clear that drugs are an essential element of the therapy, beyond medication there are other interventions in the management of the disease. Prevention of osteoporosis starts in young ages and continues during aging in order to prevent fractures associated with impaired quality of life, physical decline, mortality, and high cost for the health system. A number of different specialties are holding the scientific knowledge in osteoporosis. For this reason, we have collected papers from scientific departments all over the world for this book. The book includes up-to-date information about basics of bones, epidemiological data, diagnosis and assessment of osteoporosis, secondary osteoporosis, pediatric issues, prevention and treatment strategies, and research papers from osteoporotic fields.

How to reference

In order to correctly reference this scholarly work, feel free to copy and paste the following:

Pasquale De Negri and Tiziana Tirri (2012). Minimally Invasive Treatment of Vertebral Body Fractures, Osteoporosis, PhD. Yannis Dionyssiotis (Ed.), ISBN: 978-953-51-0026-3, InTech, Available from: <http://www.intechopen.com/books/osteoporosis/minimally-invasive-treatment-of-vertebral-body-fractures>

INTech
open science | open minds

InTech Europe

University Campus STeP Ri
Slavka Krautzeka 83/A
51000 Rijeka, Croatia
Phone: +385 (51) 770 447
Fax: +385 (51) 686 166
www.intechopen.com

InTech China

Unit 405, Office Block, Hotel Equatorial Shanghai
No.65, Yan An Road (West), Shanghai, 200040, China
中国上海市延安西路65号上海国际贵都大饭店办公楼405单元
Phone: +86-21-62489820
Fax: +86-21-62489821

© 2012 The Author(s). Licensee IntechOpen. This is an open access article distributed under the terms of the [Creative Commons Attribution 3.0 License](https://creativecommons.org/licenses/by/3.0/), which permits unrestricted use, distribution, and reproduction in any medium, provided the original work is properly cited.

IntechOpen

IntechOpen