

We are IntechOpen, the world's leading publisher of Open Access books Built by scientists, for scientists

6,900

Open access books available

185,000

International authors and editors

200M

Downloads

Our authors are among the

154

Countries delivered to

TOP 1%

most cited scientists

12.2%

Contributors from top 500 universities



WEB OF SCIENCE™

Selection of our books indexed in the Book Citation Index
in Web of Science™ Core Collection (BKCI)

Interested in publishing with us?
Contact book.department@intechopen.com

Numbers displayed above are based on latest data collected.
For more information visit www.intechopen.com



Osteonecrosis of the Jaw Involving Bisphosphonate Treatment for Osteoporosis

Maria Panaś, Małgorzata Zaleska and Tomasz Kaczmarzyk
*Department of Oral Surgery,
 Medical College of the Jagiellonian University Kraków,
 Poland*

1. Introduction

Bisphosphonates (BPs) play a key role in the treatment of both primary and secondary osteoporosis on account of their effect on the calcium metabolism in the human body. The administering of BPs reduces the frequency of fractures of the spine, the neck of the femur and the wrist. They also promote bone mass growth in the whole skeleton. In addition, they improve the quality of life of treated patients significantly (Almazrooa & Woo, 2009; Watts & Diab, 2010).

However, during the course of treatment with bisphosphonates it is of importance to bear in mind the possible development of a specific complication, namely osteonecrosis of the jaw. It should be noted that no bisphosphonate-related necrosis is observed in other bones.

Since 2003 when the first cases of osteonecrosis of the jaw following BP administration were described (Marx, 2003), more references to BPs Bisphosphonate-Related Osteonecrosis of the Jaw, i.e. BRONJ, have appeared in the literature, encompassing new and more numerous groups of patients (Durie et al., 2005; Kos et al., 2010; Otto et al., 2011; Ruggiero et al., 2004). BRONJ was initially observed in patients receiving BPs for malignant tumours, bone metastases (most frequently from breast, prostate or lung cancer), and in cases of multiple myeloma (Wang et al., 2007). BPs such as pamidronate and zoledronate were applied intravenously and doses of the medication exceeded many times over the dose used in osteoporosis. Recently, BRONJ has likewise been confirmed in patients with osteoporosis who had received oral alendronate, and in earlier years - etidronate (Magremanne, 2008; Palaska et al., 2009; Watts & Diab, 2010).

BRONJ manifests itself as a necrotically changed, exposed bone with a depleted mucous membrane and often accompanying by inflammation (Peters et al., 1993). It frequently follows a tooth extraction. It occurs more commonly in the mandible than in the maxilla (Kos et al., 2010; Ruggiero et al., 2004).

Osteonecrosis of the jaw can also be triggered by other factors than the administering of BPs (Almazrooa & Woo, 2009). It occurs after: radiation therapy of the facial area, trauma (osteotomy of the jaw bone or during intubation), viral infection (Herpes zoster or HIV), fungal infection with *Aspergillus*, circulatory insufficiency, local application of chemical agents in dental treatment, inhaling cocaine, and osteomyelitis. Also described is the idiopathic exposure of the lingual surface of the mandibular base in its posterior section in the area of the protruding mylohyoid ridge covered with thin mucous membrane and

poorly vascularised as a physiological result of trauma of the mucosa membrane in generally healthy individuals. BRONJ most frequently appears in this region. Osteonecrosis is also encountered in cases of long-term steroid use, but usually it affects the femur (Almazrooa & Woo, 2009).

Diagnosis of BRONJ can be made in case of bone exposure lasting longer than eight weeks, with no previous history of radiation therapy of the facial region (Almazrooa & Woo, 2009; Ruggiero et al., 2006).

2. Clinical and radiologic profile

Necrosis of the jaw bone in patients treated with BPs can remain asymptomatic for many months or even years.

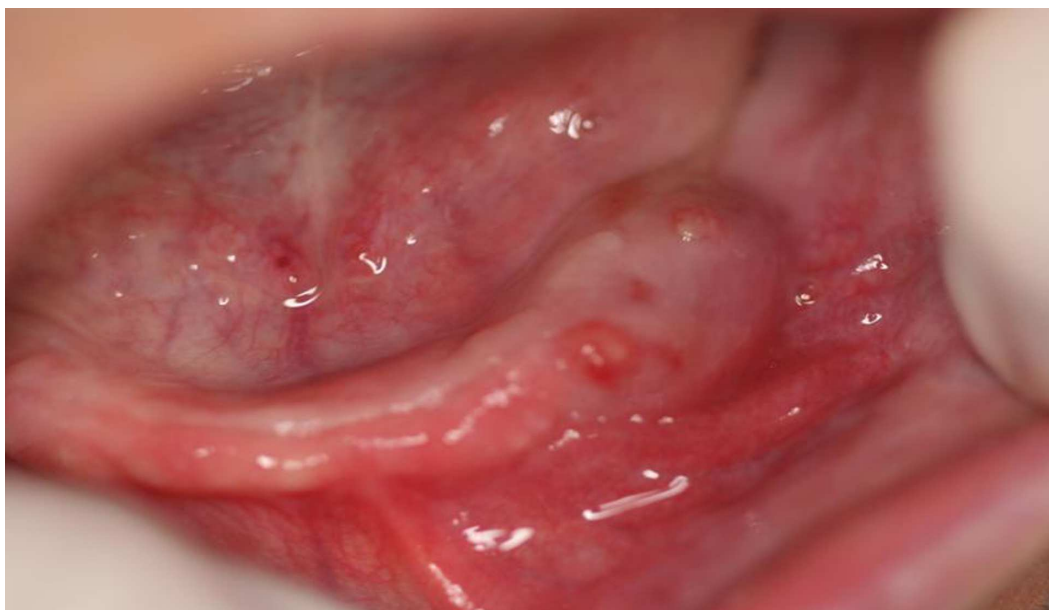

Fig. 1. Redness of the oral mucosa and purulent fistulas of the lower gingiva

The bone becomes exposed, and is sometimes accompanied by pain. The first symptoms before the emergence of a clinically developed image of necrosis include pain, tooth mobility, swelling and redness of the mucosa membrane, and ulceration (Figure 1). These symptoms can appear independently, but much more commonly they do occur after surgery on the alveolar ridge, mostly after tooth extraction. Since the post-extraction socket does not heal, subsequently pain sensation occurs, followed by inflammation of the surrounding tissue and bone necrosis. This leads to pathological fractures of the mandible, the appearance of skin (Figure 2) and gingival (Figure 1) fistulas or secondary inflammation of the maxillary sinus and oro-antral fistulas in the area of necrosis. Numbness of the skin of the lips and face may also be observed. In the initial period the exposed bone is smooth before later becoming rough and coarse. The sharp border of the bone can cause subsequent ulceration of the surrounding tissue exposed to the injury. The most frequent site of traumatic ulceration is the posterior-lateral part of the tongue adjacent to the sequestrum on the lingual surface of the mandibular body (Migliorati et al., 2005; Ruggiero et al., 2006). Initially radiological images show no significant changes (Figure 3). There may be a widening of the periodontal space around existing teeth, and later rarefaction of the bone as

in the case of bone inflammation, as well as loss of bone structure. Later, bone sequestra may develop, leading to pathological fractures (Figure 4) (Almazrooa & Woo, 2009; Ruggiero et al., 2006).

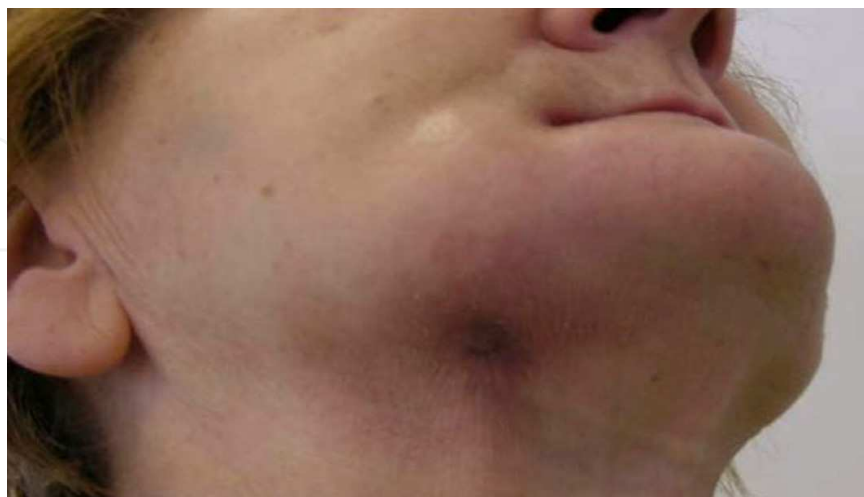

Fig. 2. Skin fistula in course of BRONJ

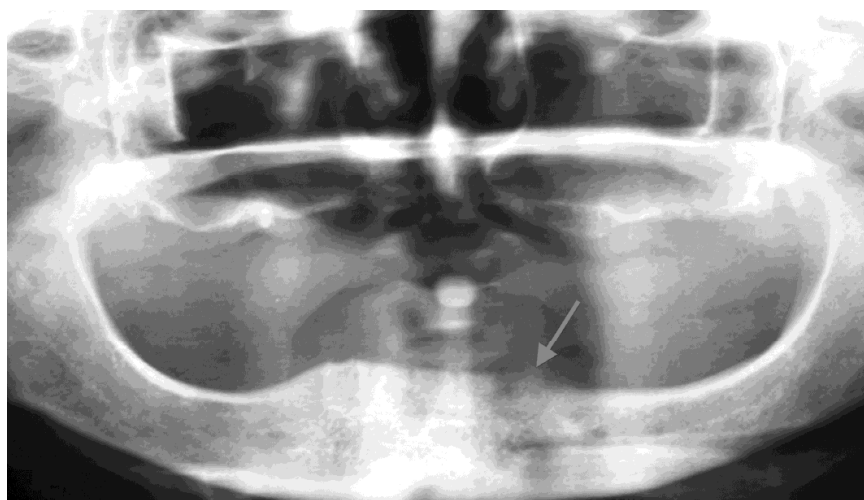


Fig. 3. Unobtrusive marginal osteolysis during the initial phase of BRONJ (arrow)

Histopathological examination demonstrates typical images of chronic inflammation of the bone with fibrous granulation tissue with abundant, chronic partially purulent inflammatory infiltration and necrotically changed osseous trabeculae (Figures 5, 6 & 7) (Migliorati et al., 2005; Ruggiero et al., 2006; Panás et al., 2010).

Ruggiero et al. (2006) suggested a division of BRONJ into three degrees depending on the progress in the pathology:

Degree 1: Exposure of bone without swelling or redness of the surrounding soft tissue (Figure 1). No change in the radiological image. The exposure of the bone may be preceded by pain.

Degree 2: Exposure of bone with inflammatory swelling of the soft tissue or with a secondary infection, the presence of pain and teeth mobility. Radiological images show necrotic changes in the bone that may resemble rarefaction of bone around the apices of the teeth (Figure 10), widening of the periodontal space.

Degree 3: Exposure of bone with accompanying pain, inflammatory swelling of the surrounding soft tissue or secondary infection that is difficult to control with antibiotic treatments. Appearance of gingival and skin fistulas in the region of bone sequestra or pathological fractures of the mandible, hypoesthesia of the lower lip, as well as secondary inflammation of the maxillary sinus, and oro-nasal fistula in the necrosis of the jaw. Radiograms show bone rarefaction, sequestra, and sometimes pathological fractures (Figure 4).

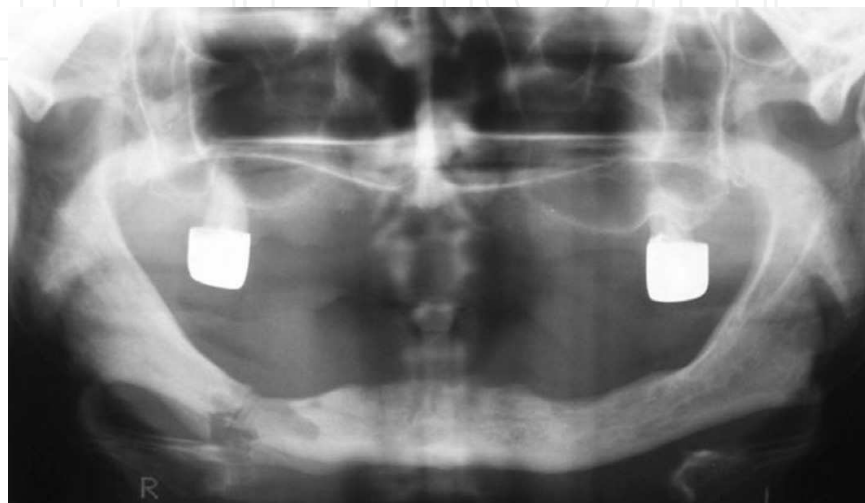


Fig. 4. Pathological fracture in course of BRONJ of the right mandible body

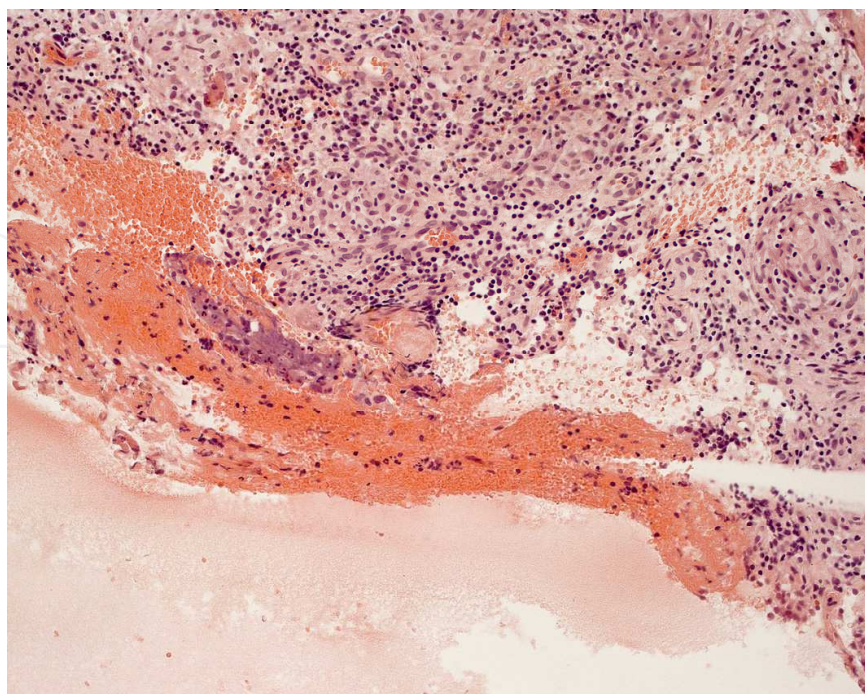


Fig. 5. Histopathological examination of BRONJ (H&E, x60)

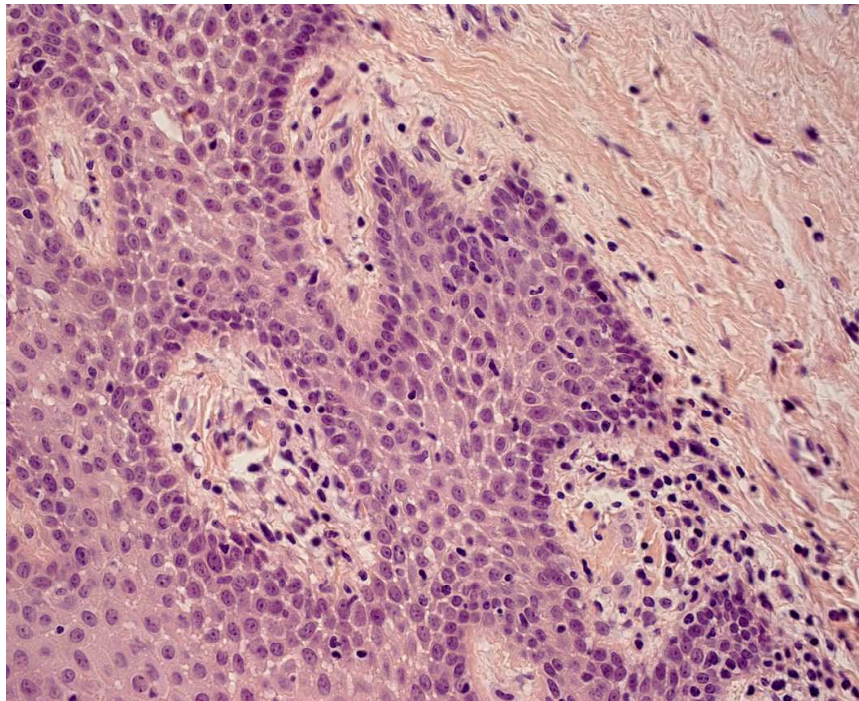


Fig. 6. Histopathological examination of BRONJ (H&E, x120)

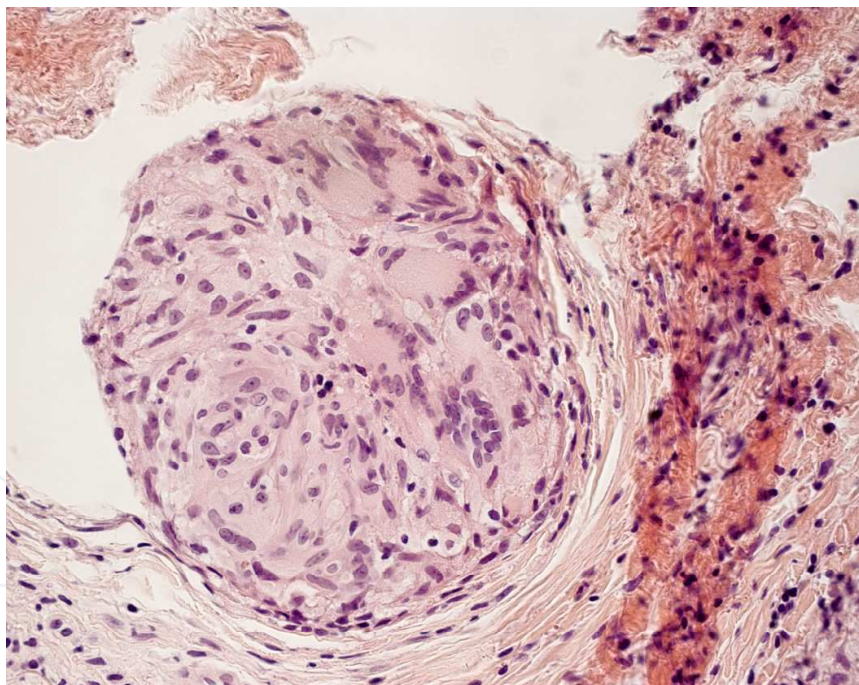


Fig. 7. Histopathological examination of BRONJ (H&E, x140)

3. Pathogenesis

The pathogenesis of BRONJ is connected with the fact that BPs have a significant influence on the physiological process of bone tissue remodelling by hampering the effect of osteoclasts function, leading to their apoptosis and the inhibition of the differentiation of osteoclast precursor cells. BPs also inhibit angiogenesis by reducing the level of VEGF

(vascular endothelial growth factor) in the blood (Almazrooa et al., 2009; Marx, 2003; Ruggiero et al., 2004). Certain bisphosphonates (i.e. pamidronate) significantly reduce blood flow through the diploe, as shown by experimental research, and this may be the reason for the occurrence of ischaemic osteonecrosis (Choi et al., 2007). BPs tend to be deposited in the jaw bones because of their high metabolic rate. The greater metabolic rate is caused by the constant pressure on the bone, especially during chewing. Micro-cracking of the maxillary bone resulting from the physiological force of chewing requires repair, and the need for bone repair and remodelling increases in the case of surgical procedures, i.e. after tooth extraction, which in patients receiving BPs is hampered by the inhibition of key elements in this process (Migliorati et al., 2005). Reduced blood supply in the mandibular body in its posterior section on the lingual side explains the frequent appearance of BRONJ in this area. Risk factors for the development of BRONJ (Table 1) include radiotherapy of the facial region, chemotherapy, the use of corticosteroids, diabetes and coagulopathies (Palaska et al., 2009; Ruggiero et al., 2006). The duration, type and method of BP treatment are also significant factors that determine the appearance of osteonecrosis. The longer the bisphosphonate is administered the greater the risk of BRONJ appearing. When administered intravenously, necrosis occurs 4.4 times more frequently compared to oral route of administration, and among intravenous medications it is most common with zoledronic acid (Almazrooa & Woo, 2009) . The average time for BRONJ to appear is 2 years for BPs administered intravenously among patients with neoplastic diseases, as compared with 4.6 years for oral therapy in cases of osteoporosis, with the minimum time being 3 years (Palaska et al., 2009). Tobacco smoking and excessive alcohol intake also favour the development of BRONJ.

General risk factors	Local risk factors
Concomitant therapies: corticosteroids, other immunosuppressants (eg methotrexate, thalidomide), chemotherapeutic agents (eg hormone antagonists)	Mandibular molar extractions (two thirds of BRONJ cases have been reported in the mandible)
Systemic conditions affecting bone turnover: immunocompromised patients, rheumatoid arthritis, poorly controlled diabetes	All dentoalveolar surgery
Smoking	Periodontitis/poor oral hygiene (the bacterial biofilm present in periodontal disease is responsible for gingival inflammation and alveolar bone resorption; this pathology, together with the interactions between bacteria themselves and BPs can increase the possibility of BRONJ)
Sociodemographic characteristics: extreme of age (over 6th decade), gender (females)	Trauma related to dentures
	Thin mucosal coverage, lingual to lower molars and bony tori

Table 1. Risk factors for developing BRONJ according to Malden et al. (2009)

A particularly high risk factors for BRONJ development are the extraction of a tooth or any other surgery on the alveolar ridge as well as injury to the mucosa membrane by a denture plate and the occurrence of ulceration (Marx, 2007; Ruggiero et al., 2006). The bacterial environment of the oral cavity favours secondary superinfection with subsequent

inflammation. Aerobic bacteria strains predominate in bacteriological tests, including Streptococci sensitive to penicillin and clindamycin, but Actinomyces species and Eikenella corrodens are also quite often cultured (Block Veras et al., 2008; Panaš et al., 2010). In addition, bacterial products increase bone resorption and decrease rate of bone remodelling, when there is an increased need for remodelling of the bone after surgery performed on the alveolar ridge.

4. Treatment

Treatment of patients with BRONJ is difficult and challenging. The recommended therapy for first degree BRONJ cases is frequent rinsing of the oral cavity with an antiseptic solution, e.g. chlorhexidine, together with regular clinical check-ups of the oral cavity.

In case of a second degree BRONJ one shall undergo antibacterial therapy involving a targeted antibiotic, together with analgesics and rinsing of the oral cavity.

During the third degree BRONJ the surgical removal of necrotic bone is necessary. Targeted antibiotic therapy administered orally or intravenously is also advisable (Rizzoli et al., 2008), as is intensive rinsing of the oral cavity. In addition to the removal of bone sequestra, it is also often necessary to perform a partial resection of the mandible or maxilla (Kunchur et al., 2009; Ruggiero et al., 2006; Williamson, 2009). Moreover, some authors propose the application of hyperbaric oxygen therapy (Migliorati et al., 2005).

Discontinuation of BPs therapy remains an issue of contention on account of their long half-life time, i.e. approximately 10 years, after they become concentrated within the body skeleton (Dello Russo, 2007). Any decision to withdraw BPs due to the development of BRONJ should be made by consensus with the attending physician and dentist.

Due to the long half life times of BPs in the bone, osteonecrosis recurs despite the introduction of the appropriate treatment (Watts & Diab, 2010).

5. Prevention

Because of the difficulties in treating BRONJ and the specificity of this chronic disease, prevention is of vital importance.

Before BPs treatment is implemented, all patients should be referred for dental examination (Shane et al., 2006). It is important to achieve oral cavity assanation, so that no surgical procedures on the alveolar ridge will be necessary during the course of BPs treatment, which significantly increases the risk of the development of BRONJ. It will be necessary to extract those teeth that are not suitable for conservative or endodontic treatment, carry out conservative therapy on other teeth and also perform periodontal treatment. Teeth for which the prognosis for restoration is poor should be extracted. Other essential hygienic procedures and elective dento-alveolar surgery should be performed during this period. The introduction of bisphosphonates should take place 4 - 6 weeks after the dento-alveolar surgery, after suitable healing of the bone wound (Kunchur et al, 2009; Malden et al., 2009; Ruggiero et al., 2006).

Prophylactic procedures in the oral cavity, consisting in the maintenance of good oral hygiene, control of caries, and conservative therapy, must continue for the entire period of BPs treatment. Patients using removable partial or complete dentures must be examined to identify any possible pressure of the denture base on the mucosa membrane of the oral cavity as well as the emergence of decubitus ulcers, especially in the lingual region of the lower prosthesis.

Patients must be taught the necessity of regular dentist check-ups and maintaining perfect oral hygiene as well as the importance of refraining from smoking and alcohol drinking. Patients

should also be made aware of early manifestations of developing osteonecrosis, which should be reported immediately to a dentist; any pain sensations in the oral cavity, oedema or bone exposure, should be reported to the attending physician (Haumschild & Haumschild, 2010).

During the course of BPs treatment surgical procedures involving teeth extractions should be avoided. If a tooth is not suitable for restoration crown of the tooth should be removed, but its roots should be left in place after endodontic treatment. However, significantly mobile teeth with periodontal abscess should be extracted. The timing and conditions of this procedure should be determined by the dental surgeon in consultation with the attending physician. Certain authors suggest that to minimise the risk of BRONJ, BPs treatment should be interrupted ("drug holidays") prior to the planned surgical procedure and, if the need arises, BPs should be replaced with a different medication used for osteoporosis. Recently it has been postulated that the CTX test (the C-terminal Cross-Linking Telopeptide test) should be carried out beforehand. This test can identify a risk group of patients treated with BPs as a measure of the total rate of bone remodelling. A safe CTX value prior to the procedure is 150 pg/ml. The surgery should be carried out with an antibiotic prophylaxis, the most recommended being penicillin derivatives or metronidazole (Bahlous et al., 2009; Kunchur et al., 2009; Malden et al., 2009; Marx et al., 2007).

Placement of dental implants in patients receiving intravenous BPs should be avoided (Ruggiero et al., 2006). However, some authors claim that oral route of BPs administration does not conflict with dental implant placement (Dello Russo et al., 2007). Nevertheless, in these cases, prophylactic antibiotic administration is obligatory and informed consent about an increased risk of implant failure should be provided.

In view of the possible development of BRONJ with prolonged BPs treatment for osteoporosis, the option of BP withdrawal after 5 years should be considered, a fact which shall be decided by the attending physician. Prolonged BPs therapy of more than 5 years should be carefully considered for patients with a high risk of spinal fracture, e.g. those with very low BMD (bone mineral density) (Watts & Diab, 2010).

Some authors claim that bone healing in patients who have been taking oral BPs for less than 3 years is expected to be uncomplicated (Marx et al., 2007). In this period, the accumulation of an oral BP in bone is slowed by its minimal gastrointestinal absorption (Dello Russo et al., 2007). Therefore, a serum CTX is not required prior to oral surgical procedures. However, if the patient relates a history of greater than 3 years of oral BP use or fewer than 3 years but with concomitant corticosteroid or chemotherapy use, a CTX test is highly recommended (Marx et al., 2007).

6. Conclusion

BRONJ complications during BPs treatment appear far more commonly among cancer patients who have received high doses of BPs intravenously. However, until now 200 cases of BRONJ have been observed in patients with osteoporosis (Rondon, 2009). Owing to an ageing population and the growing number of patients with osteoporosis, for whom BPs play a key role in their treatment, more attention should be paid to this problem as well as to learning the risk factors for the development of BRONJ. An important factor affecting the outcome of osteoporosis treatment is co-operation between the attending physician and the dentist.

One example of the development of BRONJ following BP administration is the case of a 70-year old female patient with osteoporosis who was treated with oral bisphosphonate (alendronate group) for 8 years. She reported periodic pain and bleeding in the posterior part of the lower gingiva under the denture base, where a small fistula was identified

together with redness of the mucosa membrane. A pantomographic X-ray revealed rarefaction of the bone of the mandibular body on the left side with a diameter of 3 centimetres (Figure 8). *Actinomyces naeslundii* were cultured in the bacteriological test. With a targeted antibiotic prophylaxis (clindamycin) curettage was performed on inflamed granulation tissue with minor bone sequestra from the area of the bone rarefaction. Histopathological tests showed fibrous-granulation tissue with extensive partially purulent inflammatory infiltration and necrotically changed osseous trabeculae with adjacent colonies of *Actinomyces*. Two months before, BP was withdrawn and a preparation of calcium and vitamin D3 was prescribed instead. The pain resumed 8 months after the surgery and an X-ray showed an increase in rarefaction of the bone structure (Figure 9). An antibiotic was used once again and the bone was curetted. Nine months later pain and a purulent fistula appeared in the region of the endodontically treated upper premolar tooth 25, together with a focus of the rarefaction of the bone structure on the X-ray (Figure 10), which was subsequently curetted. Histopathological test: osteomyelitis. The patient is currently in the course of another seven month follow-up without complications. CT does not show any new osteolytic lesions in the jaws (Figure 11).

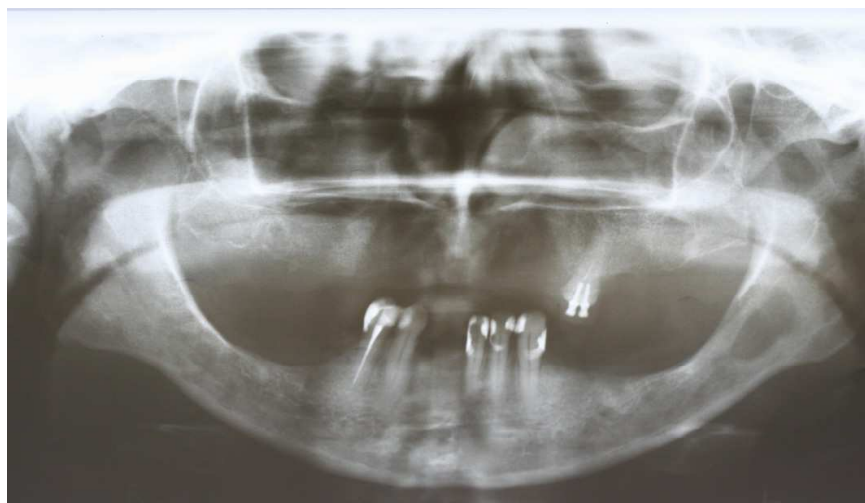

Fig. 8. Focal osteolysis of the left mandible body

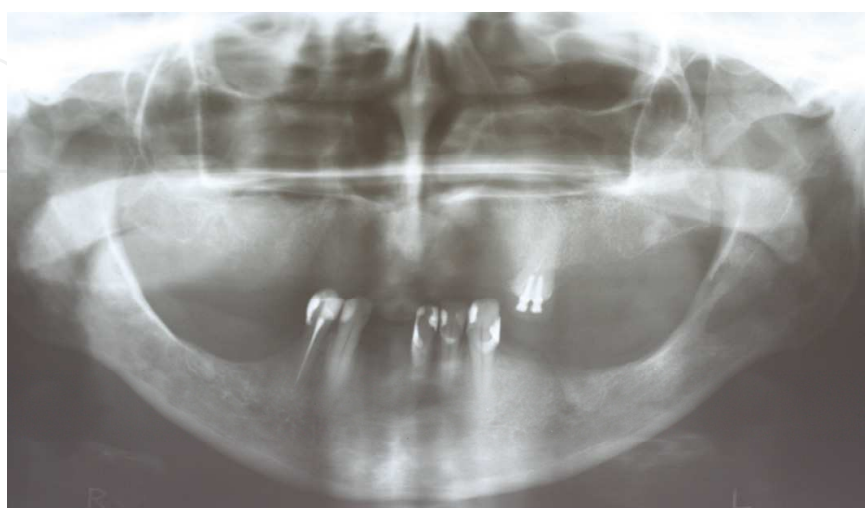


Fig. 9. Follow-up X-ray examination reveals progression of the bone resorption

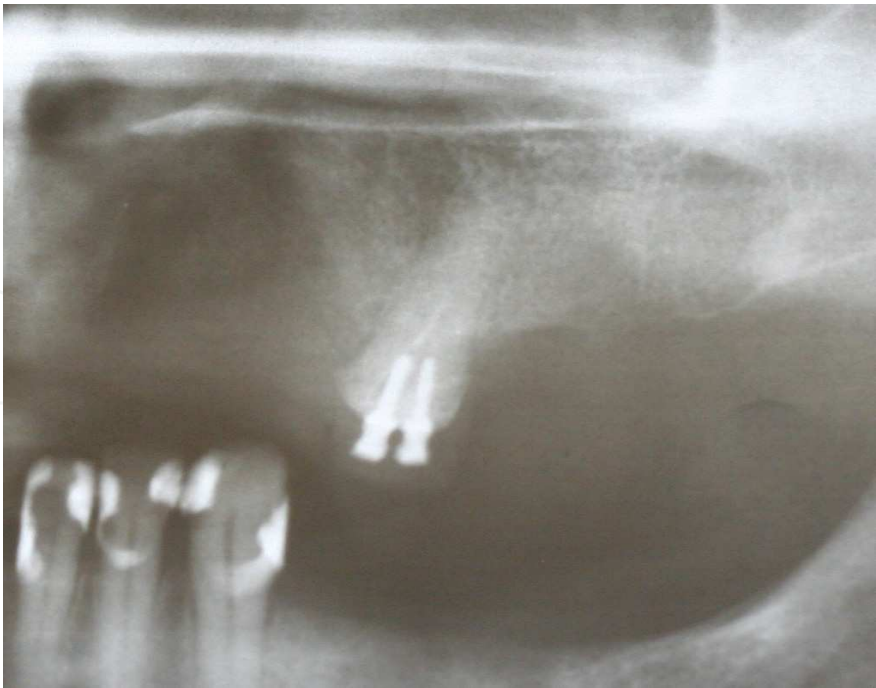


Fig. 10. Osteolytic lesion in the periapical area of the tooth 25

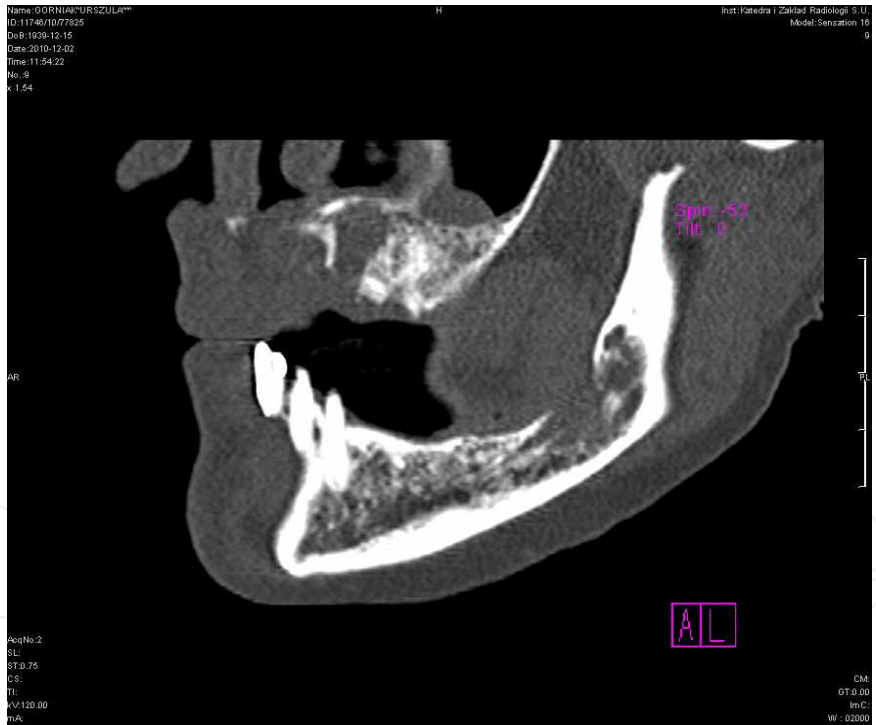


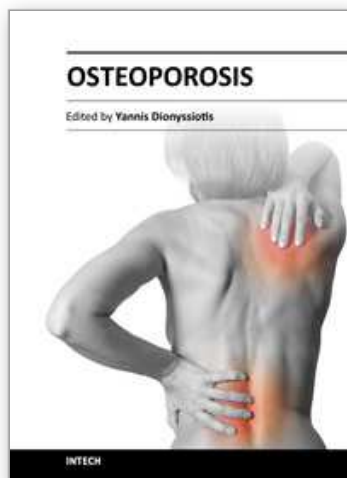
Fig. 11. Follow-up CT-scan confirming the existence of osteolytic lesions in the left mandible body and in the left maxilla. However, it does not reveal any new lesion

7. References

Almazrooa, S.A., & Woo, S.B. (2009). Bisphosphonate and non bisphosphonate – associated osteonecrosis of the jaw. A review. *J Am Dent Assoc*, Vol. 140, No. 7, pp. 864-875

- Bahlous, A., Bonzid, K., Sahli, H., Sallami, S., & Abdelmoula, J. (2009). Effects of risedronate on bone turnover makers in osteoporotic postmenopausal women: comparison of two protocols of treatment. *Tunis Med*, Vol. 87, No. 6, pp. 380-381
- Block Veras, R., Kriwalsky, M.S., Wilhelms, D., & Schubert, J. (2008). Osteochemonecrosis: bacterial spectra and antibiotics. *Proceedings of J Craniomaxillofac Surg*, Bologna, September 2008
- Choi, J.Y., Kim, H.J., Lee, Y.C., Cho, B.O., Seong, H.S., Cho, M., & Kim S.G. (2007). Inhibition of bone healing by pamidronate in calvarial bony defects. *Oral Surg Oral Med Oral Pathol Oral Radiol Endod*, Vol. 103, No. 3, pp. 321-328
- Dello Russo, N.M., Jeffcoat, M.K., Marx, R.E., & Fugazzotto, P. (2007). Osteonecrosis in the jaws of patients who are using oral bisphosphonates to treat osteoporosis. *Int J Oral Maxillofac Implants*, Vol. 22, No. 1, pp. 146-153
- Durie, B.G., Katz, M., & Crowley, J. (2005). Osteonecrosis of the jaw and bisphosphonates. *N Eng J Med*, Vol. 353, No. 1, pp. 99-102
- Haumschild, M.S., & Haumschild R.J. (2010). Postmenopausal females and the link between oral bisphosphonates and osteonecrosis of the jaw: a clinical review. *J Am Acad Nurse Pract*, Vol. 22, No. 10, pp. 534-539
- Khan, A.A., & Canadian Association of Oral and Maxillofacial Surgeons. (2008). Canadian consensus practice guideline for bisphosphonate associated osteonecrosis of the jaw. *J Rheumatol*, Vol. 35, No. 7, pp. 1391-1397
- Kos, M., Kuebler, J.F., Luczak, K., & Engelke, W. (2010). Bisphosphonate - related osteonecrosis of the jaws: a review of 34 cases and evaluation of risk. *J Craniomaxillofac Surg*, Vol. 38, No. 4, pp. 255-259
- Kunchur, R., & Goss, A.N. (2008). The oral health status of patients on oral bisphosphonates for osteoporosis. *Aust Dent J*, Vol. 53, No. 4, pp. 354-357
- Kunchur, R., Need, A., Hughes, T., & Goss A. (2009). Clinical investigation of C-terminal cross-linking telopeptide test in prevention and management of bisphosphonate-associated osteonecrosis of the jaws. *J Oral Maxillofac Surg*, Vol. 67, No. 6, pp. 1167-1173
- Magremanne, M. (2008). Osteoporosis, bisphosphonates and jaws osteochemonecrosis. *Rev Med Brux*, Vol. 29, No. 4, pp. 262-269
- Malden, N., Beltes, C., & Lopes, V. (2009). Dental extractions and bisphosphonates: the assessment, consent and management, a proposed algorithm. *Br Dent J*, Vol. 206, No. 2, pp. 93-98
- Marx, R.E. (2003). Pamidronate (Aredia) and zoledronate (Zometa) induced avascular necrosis of the jaws: a growing epidemic. *J Oral Maxillofac Surg*, Vol. 61, No. 9, pp. 1115-1117
- Marx, R.E., Cillo, J.E. Jr., & Ulloa J.J. (2007). Oral bisphosphonate - induced osteonecrosis: risk factors, prediction of risk using serum CTX testing, prevention and treatment. *J Oral Maxillofac Surg*, Vol. 65, No. 12, pp. 2397-2410
- Migliorati, C.A., Schubert, M.M., Peterson, D.E. & Seneda, L.M. (2005). Bisphosphonate - associated osteonecrosis of mandibular and maxillary bone. *Cancer*, Vol. 104, No. 1, pp. 83-93
- Otto, S., Abu-Id, M.H., Fedele, S., Warnke, P.H., Becker, S.T., & Kolk, A. (2011) Osteoporosis and bisphosphonates - related osteonecrosis of the jaw: not just a sporadic

- coincidence – a multi-centre study. *J Craniomaxillofac Surg*, Vol. 39, No. 4, pp. 272-277.
- Palaska, P.K., Cartsos, V., & Zavras, A.I. (2009). Bisphosphonates and time to osteonecrosis development. *Oncologist*, Vol. 14, No. 11, pp. 1154-1166
- Panaś, M., Zaleska, M., & Pełka, P. (2010). Bisphosphonate-related osteonecrosis of the jaws. *Reumatologia*, Vol. 48, No. 3, pp. 198-203
- Peters, E., Lovas, G.L., & Wysocki, G.P. (1993). Lingual mandibular sequestration and ulceration. *Oral Surg Oral Med Oral Pathol Oral Radiol Endod*, Vol. 75, No. 6, pp. 739-743
- Rizzoli, R., Burlet, N., Cahall, D., Delmas, P.D., Eriksen, E.F., Felsenberg, D., Grbic, J., Jontell, M., Landesberg, R., Laslop, A., Wollenhaupt, M., Papapoulos, S., Sezer, O., Sprafka, M., & Reginster, J.Y. (2008). Osteonecrosis of the jaw and bisphosphonate treatment of osteoporosis. *Bone*, Vol. 42, No.5, pp. 841-847
- Rondon, N. (2009). Osteonecrosis of the jaw (ONJ), In: *yourdentistryguide.com*, Available from: <<http://www.yourdentistryguide.com/osteonecrosis>>
- Ruggiero, S.L., Mebrotra, B., Rosenberg, T.J., & Engroff, S.J. (2004). Osteonecrosis of the jaws associated with the use of bisphosphonates: a review of 63 cases. *J Oral Maxillofac Surg*, Vol. 62, No. 5, pp. 527-534
- Ruggiero, S.L., Fantasia, J., & Carlson E. (2006). Bisphosphonate – related osteonecrosis of the jaw: background and guidelines for diagnosis, staging and management. *Oral Surg Oral Med Oral Pathol Oral Radiol Endod*, Vol. 102, No. 4, pp. 433-441
- Shane, E., Goldring, S., Christakos, S., Drezner, M., Eisman, J., Silverman, S., & Pendrys, D. (2006). Osteonecrosis of the jaw: more research needed. *J Bone Miner Res*, Vol. 21, No. 10, pp. 1503-1505
- Wang, E.P., Kaban, L.B., Strewler, G.J., Raje, N. & Troulis M.J. (2007). Incidence of osteonecrosis of the jaw in patients with multiple myeloma and breast or prostate cancer on intravenous bisphosphonate therapy. *J Oral Maxillofac Surg*, Vol. 65, No. 7, pp. 1328-1331
- Watts, N.B., & Diab, D.L. (2010). Long – term use of bisphosphonates in osteoporosis. *J Clin Endocrinol Metab*, Vol. 95, No. 4, pp. 1555-1556
- Williamson, R.A. (2009). Surgical management of bisphosphonates and time to osteonecrosis development. *Oncologist*, Vol. 14, No. 11, pp. 1154-1166
- Wao, S.B., Hellstein, J.W., & Kalmar J.R. (2006). Systematic review: bisphosphonates and osteonecrosis of the jaws. *Ann Intern Med*, Vol. 144, No.10, pp. 753-761



Osteoporosis

Edited by PhD. Yannis Dionyssiotis

ISBN 978-953-51-0026-3

Hard cover, 864 pages

Publisher InTech

Published online 24, February, 2012

Published in print edition February, 2012

Osteoporosis is a public health issue worldwide. During the last few years, progress has been made concerning the knowledge of the pathophysiological mechanism of the disease. Sophisticated technologies have added important information in bone mineral density measurements and, additionally, geometrical and mechanical properties of bone. New bone indices have been developed from biochemical and hormonal measurements in order to investigate bone metabolism. Although it is clear that drugs are an essential element of the therapy, beyond medication there are other interventions in the management of the disease. Prevention of osteoporosis starts in young ages and continues during aging in order to prevent fractures associated with impaired quality of life, physical decline, mortality, and high cost for the health system. A number of different specialties are holding the scientific knowledge in osteoporosis. For this reason, we have collected papers from scientific departments all over the world for this book. The book includes up-to-date information about basics of bones, epidemiological data, diagnosis and assessment of osteoporosis, secondary osteoporosis, pediatric issues, prevention and treatment strategies, and research papers from osteoporotic fields.

How to reference

In order to correctly reference this scholarly work, feel free to copy and paste the following:

Maria Panaś, Małgorzata Zaleska and Tomasz Kaczmarzyk (2012). Osteonecrosis of the Jaw Involving Bisphosphonate Treatment for Osteoporosis, *Osteoporosis*, PhD. Yannis Dionyssiotis (Ed.), ISBN: 978-953-51-0026-3, InTech, Available from: <http://www.intechopen.com/books/osteoporosis/osteonecrosis-of-the-jaw-involving-bisphosphonate-treatment-for-osteoporosis>

INTech
open science | open minds

InTech Europe

University Campus STeP Ri
Slavka Krautzeka 83/A
51000 Rijeka, Croatia
Phone: +385 (51) 770 447
Fax: +385 (51) 686 166
www.intechopen.com

InTech China

Unit 405, Office Block, Hotel Equatorial Shanghai
No.65, Yan An Road (West), Shanghai, 200040, China
中国上海市延安西路65号上海国际贵都大饭店办公楼405单元
Phone: +86-21-62489820
Fax: +86-21-62489821

© 2012 The Author(s). Licensee IntechOpen. This is an open access article distributed under the terms of the [Creative Commons Attribution 3.0 License](https://creativecommons.org/licenses/by/3.0/), which permits unrestricted use, distribution, and reproduction in any medium, provided the original work is properly cited.

IntechOpen

IntechOpen