

# We are IntechOpen, the world's leading publisher of Open Access books Built by scientists, for scientists

6,900

Open access books available

186,000

International authors and editors

200M

Downloads

Our authors are among the

154

Countries delivered to

TOP 1%

most cited scientists

12.2%

Contributors from top 500 universities



WEB OF SCIENCE™

Selection of our books indexed in the Book Citation Index  
in Web of Science™ Core Collection (BKCI)

Interested in publishing with us?  
Contact [book.department@intechopen.com](mailto:book.department@intechopen.com)

Numbers displayed above are based on latest data collected.  
For more information visit [www.intechopen.com](http://www.intechopen.com)



# Pediatric Dentistry – A Guide for General Practitioner

Mandeep S. Viridi

*PDM Dental College and Research Institute, Bahadurgarh, Haryana  
India*

## 1. Introduction

Children a resource of the world are the promise of what our future is going to be. A healthy child is a better promise of a better world than an unhealthy child. Oral health is a very important aspect to ensure a healthy future therefore oral health for children is a worthy concern regardless of child's nationality, ethnicity or geographic location. Dentistry for children has come a long way from its humble beginning in 1924 with the publishing of first comprehensive text book on dentistry for children followed by formation of The American Academy of Pedodontics in the late forties, which was also recognized by council of dental education a part of the ADA to certify candidates to practice specialized dentistry for children. Mid eighties saw the present name American Academy of Pediatric Dentistry being adopted followed by defining pediatric dentistry which in the present day is defined as an age-defined specialty that provides both primary and comprehensive preventive and therapeutic oral health care for infants and children through adolescence, including those with special health care needs<sup>1</sup>.

Pediatric Dentistry as the definition implies is a body of knowledge that is dependent upon curriculum of other dental subjects along with the latest development happening in various specialties of dentistry. To be able to give primary, comprehensive and preventive oral health care to children of all ages the pediatric dentist relies on preventive dentistry, pulpal therapy, instrumentation and restoration of teeth, dental material, oral surgery, preventive and interceptive orthodontics, and principals of prosthetics. Besides the dental knowledge, a working knowledge is also required of pediatric medicine, general and oral pathology along with growth and development. For the development of appropriate preventive strategy it is imperative that the pediatric dentist have knowledge of nutrition and systemic as well as topical effects of fluoride. To be able to deal effectively with children behavior management and a thorough knowledge of psychological development is imperative because child needs to be treated differently than the adult.

### 1.1 Prenatal stage

The prenatal period is a gestation of approximately nine months, beginning with the period of ovum that lasts for about two weeks and is marked by blast cyst getting attached to the wall of the uterus. This is followed by the period of embryo lasting for about next six weeks and is characterized by development of the organ systems. Following which the period of

fetus lasting right up to the delivery of the child is the time when maturation of the newly formed organs takes place.

The role of pediatric dentist starts at pre natal stage in guiding the expecting parents to maintain oral health as the mouth is an obvious portal of entry to the body, and oral health reflects and influences general health and well being. Maternal oral health has significant implications for birth outcomes and infant oral health. Maternal periodontal disease, that is, a chronic infection of the gingiva and supporting tooth structures, has been associated with preterm birth, development of preeclampsia, and delivery of a small-for-gestational age infant. Prematurely born children have higher prevalence of enamel defects. In very low birth-weight children, the prevalence of enamel defects could be even higher. Both systemic and local factors contribute to the etiology of dental defects.

Low birth-weight children are often intubated at birth, and left-sided defects on maxillary anterior teeth occurred twice as frequently as right-sided defects, probably the result of trauma from left sided laryngoscopy.

Maternal oral flora is transmitted to the newborn infant, and increased cariogenic flora in the mother predisposes the infant to the development of caries. It is intriguing to consider preconception, pregnancy, or intrapartum treatment of oral health conditions as a mechanism to improve women's oral and general health, pregnancy outcomes, and their children's dental health. However, given the relationship between oral health and general health, oral health care should be a goal in its own right for all individuals. Regardless of the potential for improved oral health to improve pregnancy outcomes, public policies that support comprehensive dental services for vulnerable women of childbearing age should be expanded so that their own oral and general health is safeguarded and their children's risk of caries is reduced. Oral health promotion should include education of women and their health care providers' ways to prevent oral disease from occurring, and referral for dental services when disease is present <sup>2</sup>.

## **2. Role of pediatric dentist at birth**

Infant oral health, along with perinatal oral health, is one of the foundations upon which preventive education and dental care must be built to enhance the opportunity for a lifetime free from preventable oral disease. Caries is perhaps the most prevalent infectious disease in children. Almost half children have caries by the time they reach kindergarten. Early childhood caries (ECC) can be a particularly virulent form of caries, beginning soon after tooth eruption, developing on smooth surfaces, progressing rapidly, and having a lasting detrimental impact on the dentition. This disease affects the general population but is more likely to occur in infants who consume a diet high in sugar, and whose mothers have a low education level. Caries in primary teeth can affect children's growth, result in significant pain and potentially life-threatening infection, and diminish overall quality of life.

Caries is a disease that is, by and large, preventable. Early risk assessment allows for identification of parent-infant groups who are at risk for ECC and would benefit from early preventive intervention. The ultimate goal of early assessment is the timely delivery of educational information to populations at high risk for developing caries in order to prevent the need for later surgical intervention.

An oral health risk assessment for infants by 6 months of age allows for the institution of appropriate preventive strategies as the primary dentition begins to erupt. Caries risk assessment can be used to determine the patient's relative risk for caries. Even the most judiciously designed and implemented caries risk assessment tool, however, can fail to identify all infants at risk for developing ECC. In these cases, the mother may not be the colonization source of the child's oral flora, the dietary intake of simple carbohydrates may be extremely high, or other uncontrollable factors may combine to place the patient at risk for developing caries. Therefore, screening for risk of caries in the parent and patient coupled with oral health counseling, although a feasible and equitable approach to ECC control is not a substitute for the early establishment of the dental home. Whenever possible, the ideal approach to infant oral health care, including ECC prevention and management, is the early establishment of a dental home.

### 3. Anticipatory guidance

General anticipatory guidance given by AAPD for the mother (or other intimate caregiver) includes the following:

- Oral hygiene: Tooth-brushing and flossing by the mother on a daily basis are important to help dislodge food and reduce bacterial plaque levels.
- Diet: Important components of dietary education for the parents include the cariogenicity of certain foods and beverages, role of frequency of consumption of these substances, and the demineralization/remineralization process.
- Fluoride: Using a fluoridated toothpaste approved by the relevant Dental Association and rinsing every night with an alcohol-free, over-the-counter mouth rinse containing 0.05% sodium fluoride have been suggested to help reduce plaque levels and help enamel remineralization.
- Caries removal: Routine professional dental care for the mothers can help keep their oral health in optimal condition. Removal of active caries with subsequent restoration is important to suppress maternal MS reservoirs and has the potential to minimize the transfer of MS to the infant, thereby decreasing the infant's risk of developing ECC.
- Delay of colonization: Education of the parents, especially mothers, on avoiding saliva-sharing behaviors (eg. sharing spoons and other utensils, sharing cups, cleaning a dropped pacifier or toy with their mouth) can help prevent early colonization of MS in their infants.
- Xylitol chewing gums: Evidence demonstrates that mothers' use of xylitol chewing gum can prevent dental caries in their children by prohibiting the transmission of MS.

General anticipatory guidance for the young patient (0 to 3 years of age) includes the following:

- Oral hygiene: Oral hygiene measures should be implemented no later than the time of the eruption of the first primary tooth. Cleansing the infant's teeth as soon as they erupt with either a washcloth or soft toothbrush will help reduce bacterial colonization. Children's teeth should be brushed twice daily with fluoridated toothpaste and a soft, age-appropriate sized toothbrush. A "smear" of toothpaste is recommended for children less than 2 years of age, while a "pea-size" amount of paste is recommended

for children 2-5 years of age. Flossing should be initiated when adjacent tooth surfaces cannot be cleansed with a toothbrush.

- **Diet:** High-risk dietary practices appear to be established early, probably by 12 months of age, and are maintained throughout early childhood. Frequent night time bottle feeding, ad libitum breast-feeding, and extended and repeated use of a sippy or no-spill cup are associated with, but not consistently implicated in ECC. Likewise, frequent consumption of snacks or drinks containing fermentable carbohydrates (e.g., juice, milk, formula, soda) also can increase the child's caries risk.
- **Fluoride:** Optimal exposure to fluoride is important to all dentate infants and children. The use of fluoride for the prevention and control of caries is documented to be both safe and effective. Twice-daily brushing with fluoridated toothpaste is recommended for all children as a preventive procedure. Professionally-applied fluoride, as well as at home fluoride treatments, should be considered for children at high caries risk based upon caries risk assessment. Systemically-administered fluoride should be considered for all children drinking fluoride deficient water (<0.6 ppm). Caution is indicated in the use of all fluoride-containing products. Fluorosis has been associated with cumulative fluoride intake during enamel development, with the severity dependent on the dose, duration, and timing of intake. Decisions concerning the administration of additional fluoride are based on the unique needs of each patient.
- **Injury prevention:** Practitioners should provide age appropriate injury prevention counseling for orofacial trauma. Initially, discussions would include play objects, pacifiers, car seats, and electric cords.
- **Non-nutritive habits:** Non-nutritive oral habits (e.g., digit or pacifier sucking, bruxism, abnormal tongue thrust) may apply forces to teeth and dentoalveolar structures. It is important to discuss the need for early sucking and the need to wean infants from these habits before malocclusion or skeletal dysplasia's occur.

#### 4. Birth to the eruption of first teeth

Besides the anticipatory guidelines some time conditions are present which require immediate attention these could include developmental anomalies such as

- **Partial ankyglosia (tongue tie)**

Tongue-tie is a condition in which the lingual frenulum is either too short or anteriorly placed limiting the mobility of the tongue.

Early in fetal development, the tongue is attached to the floor of the mouth. With cell death and atrophy, the only attachment is the frenulum. Tongue-tie results when the frenulum is short and this may limit the movement of the tongue. When there is an attempt to stick the tongue out, there may be a V shaped notch at the tip. The incidence is 0.5/1000 Physical exam will easily demonstrate the short or anteriorly placed lingual frenulum.

Years ago it was routine to clip the frenulum at the time of delivery. Midwives had a long sharp nail to cut the frenulum and obstetricians would inspect the mouth and cut the frenulum immediately after the delivery. Tongue-tie is associated with speech abnormalities especially lisping and inability to pronounce certain sounds.

Tongue-tie actually represents partial ankyloglossia and fusion represents complete ankyloglossia. Case reports indicate that squeals of ankyloglossia may include speech



defects, difficulty in breastfeeding, or dental problems. However, controlled trials on ankyloglossia have not been appropriately studied, and therefore indications for therapy remain controversial. The tip of the tongue normally grows until 4 years of age, and initial restrictions of movement may improve as the child gets older. Therefore, frenulectomy should not be performed before 4 years of age <sup>4</sup>.

#### MANAGEMENT

1. Physician education
2. Parental education and reassurance
3. Monitor for appropriate weight gain if exclusively breastfeeding
4. Complete fusion requires surgery

- **Paramedian lip pits (congenital lip pits)**

PITS OF THE LOWER lip (fistulas of lower lip, paramedian sinuses of lower lip, humps of lower lip, labial cysts, etc.) is a very rare congenital malformation, first described by Demarquay in 1845. This minimally deforming anomaly is remarkable chiefly for its association with facial clefts. The fact that clefts that occur in families with the lip pits anomaly have a stronger familial tendency than clefts in families without lip pits has attracted the attention of people dealing with cleft patients.

- **Bifid uvula**

A bifid or bifurcated uvula is a split or cleft uvula. Newborns with cleft palate also have a split uvula. The bifid uvula results from the incomplete fusion of the medial nasal and maxillary processes. Bifid uvulas have less muscle in them than a normal uvula, which may cause recurring problems with middle ear infections. While swallowing, the soft palate is pushed backwards, preventing food and drink from entering the nasal cavity. If the soft palate cannot touch the back of the throat while swallowing, food and drink can enter the nasal cavity. Splitting of the uvula occurs infrequently but is the most common form of mouth and nose area cleavage among newborns. Bifid uvula occurs in about 2% of the general population, although some populations may have a high incidence, such as Native Americans who have a 10% rate. Bifid uvula is a common symptom of the rare genetic syndrome Loeys-Dietz syndrome, which is associated with an increased risk of aortic aneurysm.

- **Hyperplastic labial frenum**

- **White Sponge Nevus**

White sponge nevus (WSN), also known as Cannon's disease, hereditary leukokeratosis of mucosa and White sponge nevus of Cannon, is an autosomal dominant skin condition. Although congenital in most cases, it can first occur in childhood or adolescence. It presents in the mouth, most frequently as a thick bilateral white plaque with a spongy texture, usually on the buccal mucosa, but sometimes on the labial mucosa, alveolar ridge or floor of the mouth. The gingival margin and dorsum of the tongue are almost never affected. Although this condition is perfectly benign, it is often mistaken for leukoplakia. There is no treatment, but because there are no serious clinical complications, the prognosis is excellent.

## 5. Normal teething and conditions associated with eruption of teeth

Teething is the process by which an infant's teeth erupt, or break through, the gums. Teething is also referred to as "cutting" of the teeth. Teething is medically termed odontiasis.

The onset of teething symptoms typically precedes the eruption of a tooth by several days. While a baby's first tooth can present between 4 and 10 months of age, the first tooth usually erupts at approximately 6 months of age. Some dentists have noted a family pattern of "early," "average," or "late" teethers.

A relatively rare condition, "natal" teeth, describes the presence of a tooth on the day of birth<sup>7</sup>. The incidence of such an event is one per 2,000-3,000 live births. Usually, this single and often somewhat malformed tooth is a unique event in an otherwise normal child. Rarely, the presence of a natal tooth is just one of several unusual physical findings which make up a syndrome. If the possibility of a syndrome exists, consultation with a pediatric dentist and/or geneticist can be helpful. The natal tooth is often loose and is commonly removed prior to the newborn's hospital discharge to lessen the risk of aspiration into the lungs.

Teething is generally associated with gum and jaw discomfort as the infant's tooth prepares to erupt through the gum surface. As the tooth moves beneath the surface of the gum tissue, the area may appear slightly red or swollen. Sometimes a fluid-filled area similar to a "blood blister" or eruption hematoma may be seen over the erupting tooth. Some teeth may be more sensitive than others when they erupt. The larger molars may cause more discomfort due to their larger surface area that can't "slice" through the gum tissue as an erupting incisor is capable of doing. With the exception of the eruption of the third molars (wisdom teeth), eruption of permanent teeth rarely cause the discomfort associated with eruption of "baby" (primary or deciduous) teeth.

Teething may cause the following symptoms:

- increased drooling, restless or decreased sleeping due to gum discomfort, refusal of food due to soreness of the gum region, fussiness that comes and goes, bringing hands to the mouth, mild rash around the mouth due to skin irritation secondary to excessive drooling, and rubbing the cheek or ear region as a consequence of referred pain during the eruption of the molars.

Importantly, teething is not associated with the following symptoms: fever (especially over 101 F), diarrhea, runny nose and cough, prolonged fussiness, or rashes over the body.

Sometime minimal intervention may be required during teething in the form of certain over-the-counter medicines can be placed directly on the gums to help relieve pain. They contain medications that temporarily numb the gum tissue. They may help for brief periods of time but have a taste and sensation that many children do not like. It is important not to let the medicine numb the throat because that may interfere with the normal gag reflex and may make it possible for food to enter the lungs. Medicines that are taken by mouth to help reduce the pain.

Acetaminophen (Tylenol) or ibuprofen (Advil or Motrin) can also help with pain. Ibuprofen should not be administered to infants younger than 6 months of age. Medications should be used only for the few times when other home-care methods do not help. Caution should be taken not to overmedicate for teething. The medicine may mask significant symptoms that could be important to know about.

Infant gums often feel better when gentle pressure is placed on the gums. For this reason, gently rubbing of the gums with a clean finger or having the child bite down on a clean washcloth. If the pain seems to be causing feeding problems, sometimes a different shaped

nipple or use of a cup may reduce discomfort and improve feeding. Cold objects may help reduce inflammation as well, never put anything in a child's mouth that might enable the child to choke.

## 6. The primary dentition years

The first primary tooth emerges at around six months of age and by three years root development is complete. This is the preschool years and children are called preschoolers and they are increasing their cognitive abilities but still in the preconceptual stage and should be considered unsophisticated in thinking. This sophistication only develops during the period of intuitive thought where the child learns the skills of writing and classification after four years of age and can follow dental instructions given to him.

Another difference observed three years onwards is the development of self control where in these children can distract themselves for example when receiving anesthesia and can be taught to monitor their behavior and they may feel guilty if they are not following the expected norms. In clinical management terms the child is not emotionally mature but surely emotionally complex and will respond to praise and will hurt and respond to aggression and hostility.

### 6.1 Managing the developing occlusion

Guidance of eruption and development of the primary, mixed, and permanent dentitions is an integral component of comprehensive oral health care for all pediatric dental patients. Such guidance should contribute to the development of a permanent dentition that is in a stable, functional, and esthetically acceptable occlusion. Early diagnosis and successful treatment of developing malocclusions can have both short-term and long term benefits while achieving the goals of occlusal harmony and function and dentofacial esthetics.

Many factors can affect the management of the developing dental arches and minimize the overall success of any treatment. The variables associated with the treatment of the developing dentition that will affect the degree to which treatment is successful include, but are not limited to: chronological/mental/emotional age of the patient and the patient's ability to understand and cooperate in the treatment; intensity, frequency, and duration of an oral habit; parental support for the treatment; compliance with clinician's instructions; craniofacial configuration; craniofacial growth; concomitant systemic disease or condition; accuracy of diagnosis; appropriateness of treatment.

Anomalies of primary teeth and eruption may not be evident/diagnosable prior to eruption, due to the child's not presenting for dental examination or to a radiographic examination not being possible in a young child. Evaluation, however, should be accomplished when feasible. The objectives of evaluation include identification of: all anomalies of tooth number and size (as previously noted); anterior and posterior crossbites; presence of habits along with their dental and skeletal sequelae.

Oral Habits and posterior crossbites should be diagnosed and addressed as early as feasible<sup>8</sup>. Parents should be informed about findings of adverse growth and developing malocclusions. Interventions/treatment can be recommended if diagnosis can be made,



treatment is appropriate and possible, and parents are supportive and desire to have treatment done.

Oral habits may apply forces to the teeth and dentoalveolar structures. The relationship between oral habits and unfavorable dental and facial development is associational rather than cause and effect. Habits of sufficient frequency, duration, and intensity may be associated with dentoalveolar or skeletal deformations such as increased overjet, reduced overbite, posterior crossbite, or long facial height. As preliminary evidence indicates that some changes resulting from sucking habits persist past the cessation of the habit, it has been suggested that early dental visits provide parents with anticipatory guidance to help their children stop sucking habits by age 36 months or younger.

## **6.2 Managing developing malocclusion in primary dentition**

Anterior and posterior cross bites are malocclusions which involve one or more teeth in which the maxillary teeth occlude lingually with the antagonistic mandibular teeth. Dental crossbites result from the tipping or rotation of a tooth or teeth. The condition is localized and does not involve the basal bone. Skeletal cross bites involve disharmony of the craniofacial skeleton.

A simple anterior cross bite can be aligned as soon as the condition is noted, if there is sufficient space; otherwise, space needs to be created first. Such appliances as acrylic incline planes, acrylic retainers with lingual springs, or fixed appliances all have been effective. If space is needed, an expansion appliance also is required. Early correction of unilateral posterior crossbites has been shown to improve functional conditions significantly and largely eliminate morphological and positional asymmetries of the mandible.

Class II malocclusion (distocclusion) may be unilateral or bilateral and involves a distal relationship of the mandible to the maxilla or the mandibular teeth to maxillary teeth. This relationship may result from dental (malposition of the teeth in the arches), skeletal (mandibular retrusion and/or maxillary protrusion), or a combination of dental and skeletal factors. Early Class II treatment improves self-esteem and decreases negative social experiences. Incisor injury that is more severe than simple enamel fractures has been associated positively with increased overjet and prognathic position of the maxilla. Early treatment for Class II malocclusions can be initiated, depending upon patient cooperation and management this will result in an improved overbite, overjet, and intercuspation of posterior teeth and an esthetic appearance and profile compatible with the patient's skeletal morphology.

Class III malocclusion may be unilateral or bilateral and involves a mesial relationship of the mandible to the maxilla or mandibular teeth to maxillary teeth. This relationship may result from dental factors (malposition of the teeth in the arches), skeletal factors (asymmetry, mandibular prognathism, and/or maxillary retrognathism), or a combination of these factors. Treatment of Class III malocclusions is indicated to provide psychosocial benefits for the child patient by reducing or eliminating facial disfigurement and to reduce the severity of malocclusion by promoting compensating growth. Early Class III treatment in a growing patient will result in improved overbite, overjet, and intercuspation of posterior teeth and an esthetic appearance and profile compatible with the patient's skeletal morphology.

### 6.3 Local anesthesia for children

Local anesthetic administration is an important consideration in the behavior guidance of a pediatric patient<sup>9</sup>. Age-appropriate “nonthreatening” terminology, distraction, topical anesthetics, proper injection technique, can help the patient have a positive experience during administration of local anesthesia. In pediatric dentistry, the dental professional should be aware of proper dosage (based on weight) to minimize the chance of toxicity and the prolonged duration of anesthesia, which can lead to accidental lip or tongue trauma. Knowledge of the gross and neuroanatomy of the head and neck allows for proper placement of the anesthetic solution and helps minimize complications (eg, hematoma, trismus, intravascular injection). Familiarity with the patient’s medical history is essential to decrease the risk of aggravating a medical condition while rendering dental care. Appropriate medical consultation should be obtained when needed.

The application of topical anesthetic may help minimize discomfort caused during administration of local anesthesia. Topical anesthetic is effective on surface tissues (2-3 mm in depth) to reduce painful needle penetration of the oral mucosa. A variety of topical anesthetic agents are available in gel, liquid, ointment, patch, and aerosol forms.

Injectable anesthetic available for dental usage include lidocaine, mepivacaine, articaine, prilocaine, and bupivacaine. Absolute contraindications for local anesthetics include a documented local anesthetic allergy. Local anesthetics without vasoconstrictors should be used with caution due to rapid systemic absorption which may result in overdose. Epinephrine decreases bleeding in the area of injection. Epinephrine concentrations of 1:50,000 may be indicated for infiltration in small doses into a surgical site to achieve hemostasis but are not indicated in children to control pain.

### 6.4 Dental diseases in primary dentition years

#### 6.4.1 Dental caries

Dental caries, also known as tooth decay or a cavity, is a disease where bacterial processes damage hard tooth structure (enamel, dentin, and cementum). These tissues progressively break down, producing dental caries (cavities, holes in the teeth). Two groups of bacteria are responsible for initiating caries: *Streptococcus mutans* and *Lactobacillus*. If left untreated, the disease can lead to pain, tooth loss, infection, and, in severe cases, even death. Today, caries remains one of the most common diseases throughout the world. Cariology is the study of dental caries. One particular condition that is seen in this age group is the Early Childhood Caries (ECC). The disease of early childhood caries (ECC) is the presence of 1 or more decayed (noncavitated or cavitated lesions), missing (due to caries), or filled tooth surfaces in any primary tooth in a child 71 months of age or younger. In children younger than 3 years of age, any sign of smooth-surface caries is indicative of severe early childhood caries (S-ECC). From ages 3 through 5, 1 or more cavitated, missing (due to caries), or filled smooth surfaces in primary maxillary anterior teeth or a decayed, missing, or filled score of  $\geq 4$  (age 3),  $\geq 5$  (age 4), or  $\geq 6$  (age 5) surfaces constitutes S-ECC<sup>10</sup>.

The recommended method of preventing such a condition include

Reducing the mother’s/primary caregiver’s/sibling(s) MS levels (ideally during the prenatal period) to decrease transmission of cariogenic bacteria. Minimizing saliva-sharing activities (eg, sharing utensils) between an infant or toddler and his family/cohorts. Implementing oral hygiene measures no later than the time of eruption

of the first primary tooth. If an infant falls asleep while feeding, the teeth should be cleaned before placing the child in bed. Tooth brushing of all dentate children should be performed twice daily with a fluoridated toothpaste and a soft, age-appropriate sized toothbrush. Parents should use a 'smear' of toothpaste to brush the teeth of a childless than 2 years of age. For the 2-5 year old, parents should dispense a 'pea-size' amount of toothpaste and perform or assist with their child's tooth brushing. Flossing should be initiated when adjacent tooth surfaces can not be cleansed by a toothbrush. Establishing a dental home within 6 months of eruption of the first tooth and no later than 12 months of age to conduct a caries risk assessment and provide parental education including anticipatory guidance for prevention of oral diseases. Avoiding caries-promoting feeding behaviors. In particular: Infants should not be put to sleep with a bottle containing fermentable carbohydrates. Ad libitum breast-feeding should be avoided after the first primary tooth begins to erupt and other dietary carbohydrates are introduced. Parents should be encouraged to have infants drink from a cup as they approach their first birthday. Infants should be weaned from the bottle at 12 to 14 months of age. Repetitive consumption of any liquid containing fermentable carbohydrates from a bottle or no-spill training cup should be avoided. Between-meal snacks and prolonged exposures to foods and juice or other beverages containing fermentable carbohydrates should be avoided.

#### **6.4.2 Behaviour management in dental clinic**

Safe and effective treatment of dental diseases often requires modifying the child's behavior. Behavior guidance is a continuum of interaction involving the dentist and dental team, the patient, and the parent directed toward communication and education. Its goal is to ease fear and anxiety while promoting an understanding of the need for good oral health and the process by which that is achieved. For treating children a variety of behavior guidance approaches are used it is important to, assess accurately the child's developmental level, dental attitudes, and temperament and to predict the child's reaction to treatment. The child who presents with oral/dental pathology and noncompliance makes the management more challenging. The pediatric dental staff can play an important role in behavior guidance. Communication may be accomplished by a number of means but, in the dental setting, it is affected primarily through dialogue, tone of voice, facial expression, and body language. One should communicate with the child patient briefly at the beginning of a dental appointment to establish rapport and trust. However, once a procedure begins, the dentist's ability to control and shape behavior becomes paramount, and information sharing becomes secondary<sup>11</sup>.

Various behavior management techniques such as Tell-show-do is used by many pediatric professionals. The technique involves verbal explanations of procedures in phrases appropriate to the developmental level of the patient (tell); demonstrations for the patient of the visual, auditory, olfactory, and tactile aspects of the procedure in a carefully defined, nonthreatening setting (show); and then, without deviating from the explanation and demonstration, completion of the procedure (do). The tell-show-do technique is used with communication skills (verbal and nonverbal) and positive reinforcement. Voice control is a controlled alteration of voice volume, tone, or pace to influence and direct the patient's behavior. Parents unfamiliar with this technique may benefit from an

explanation prior to its use to prevent misunderstanding. Distraction is another technique involving diverting the patient's attention from what may be perceived as an unpleasant procedure. Giving the patient a short break during a stressful procedure can be an effective use of distraction prior to considering more advanced behavior guidance techniques.

Some children may require a more advanced behavior management techniques using pharmacological agents such as conscious sedation, deep sedation or general anesthesia. Nitrous oxide/oxygen inhalation is a safe and effective technique of giving conscious sedation to reduce anxiety and enhance effective communication. Its onset of action is rapid, the effects easily are titrated and reversible, and recovery is rapid and complete. Additionally, nitrous oxide/oxygen inhalation mediates a variable degree of analgesia, amnesia, and gag reflex reduction.

Some children and developmentally disabled patients require general anesthesia to receive comprehensive dental care in a safe and humane fashion. Many pediatric dentists (and others who treat children) have sought to provide for the administration of general anesthesia by properly-trained individuals in their offices or other facilities (eg, outpatient care clinics) outside of the traditional hospital setting. The Elective Use of Minimal, Moderate, and Deep Sedation and General Anesthesia in Pediatric Dental Patients practiced.

#### **6.4.3 Preventing dental caries**

Pit and fissure sealants has been described as a material placed into the pits and fissures of caries-susceptible teeth that micromechanically bonds to the tooth preventing access by cariogenic bacteria to their source of nutrients<sup>12</sup>.

##### **Fluoride application**

###### *Systemically-administered fluoride supplements*

Fluoride supplements should be considered for all children drinking fluoride-deficient (<0.6 ppm) water. After determining the fluoride level of the water supply or supplies (either through contacting public health officials or water analysis), evaluating other dietary sources of fluoride, and assessing the child's caries risk, the daily fluoride supplement dosage can be determined using the Dietary Fluoride Supplementation Schedule.

###### *Professionally-applied topical fluoride treatment*

Professional topical fluoride treatments should be based on caries-risk assessment. A pumice prophylaxis is not an essential prerequisite to this treatment. Appropriate precautionary measures should be taken to prevent swallowing of any professionally-applied topical fluoride. Children at moderate caries risk should receive a professional fluoride treatment at least every 6 months; those with high caries risk should receive greater frequency of professional fluoride applications (ie, every 3-6 months). Ideally, this would occur as part of a comprehensive preventive program in a dental home.

###### *Fluoride-containing products for home use*

Therapeutic use of fluoride for children should focus on regimens that maximize topical contact, preferably in lower-dose, higher-frequency approaches. Fluoridated toothpaste should be used twice daily as a primary preventive procedure. Twice daily use has benefits greater than once daily brushing.

Additional at-home topical fluoride regimens utilizing increased concentrations of fluoride should be considered for children at high risk for caries. These may include over-the-counter or prescription strength formulations. Fluoride mouth rinses or brush-on gels may be incorporated into a caries-prevention program for a school-aged child at high risk.

#### **6.4.4 Management of dental caries**

Restorative treatment is based upon the results of an appropriate clinical examination and is ideally part of a comprehensive treatment plan. The treatment plan should take into consideration: developmental status of the dentition; caries-risk assessment, patient's oral hygiene, anticipated parental compliance and likelihood of timely recall, patient's ability to cooperate for treatment. The restorative treatment plan must be prepared in conjunction with an individually-tailored preventive program. Caries risk is greater for children who are poor, rural, or minority or who have limited access to care. Factors for high caries risk include decayed/missing/filled surfaces greater than the child's age, numerous white spot lesions, high levels of mutans streptococci, low socioeconomic status, high caries rate in siblings/parents, diet high in sugar, and/or presence of dental appliances. Studies have reported that maxillary primary anterior caries has a direct relationship with caries in primary molars, and caries in the primary dentition is highly predictive of caries occurring in the permanent dentition.

#### **6.5 Pulp therapy for primary teeth**

The primary objective of pulp therapy is to maintain the integrity and health of the teeth and their supporting tissues. It is a treatment objective to maintain the vitality of the pulp of a tooth affected by caries, traumatic injury, or other causes.

Vital pulp therapy for primary teeth diagnosed with a normal pulp or reversible pulpitis includes placement of a protective liner which is a thinly-applied liquid placed on the pulpal surface of a deep cavity preparation, covering exposed dentin tubules, to act as a protective barrier between the restorative material or cement and the pulp. Placement of a thin protective liner such as calcium hydroxide, dentin bonding agent, or glass ionomer cement is at the discretion of the clinician. This placement in the deep area of the preparation is utilized to preserve the tooth's vitality, promote pulp tissue healing and tertiary dentin formation, and minimize bacterial microleakage. Adverse post-treatment clinical signs or symptoms such as sensitivity, pain, or swelling should not occur.

Indirect pulp treatment is a procedure performed in a tooth with a deep carious lesion approximating the pulp but without signs or symptoms of pulp degeneration. The caries surrounding the pulp is left in place to avoid pulp exposure and is covered with a biocompatible material. A radiopaque liner such as a dentin bonding agent, resin modified glass ionomer, calcium hydroxide, zinc oxide/eugenol, or glass ionomer cement is placed over the remaining carious dentin to stimulate healing and repair. Indirect pulp capping has been shown to have a higher success rate than pulpotomy in long term studies. It also allows for a normal exfoliation time. Therefore, indirect pulp treatment is preferable to a pulpotomy when the pulp is normal or has a diagnosis of reversible pulpitis.

Direct pulp cap can be done. When a pinpoint mechanical exposure of the pulp is encountered during cavity preparation or following a traumatic injury, a biocompatible



radiopaque base such as mineral trioxide aggregate (MTA) or calcium hydroxide may be placed in contact with the exposed pulp tissue. The tooth is restored with a material that seals the tooth from microleakage.

A pulpotomy is performed in a primary tooth with extensive caries but without evidence of radicular pathology when caries removal results in a carious or mechanical pulp exposure. The coronal pulp is amputated, and the remaining vital radicular pulp tissue surface is treated with a long-term clinically successful medicament such as Buckley's Solution of formocresol or ferric sulfate. Electrosurgery also has demonstrated success. Glutaraldehyde and calcium hydroxide have been used but with less long-term success. MTA is a more recent material used for pulpotomies with a high rate of success.

Nonvital pulp treatment for primary teeth diagnosed with irreversible pulpitis or necrotic pulp include Pulpectomy. Pulpectomy is a root canal procedure for pulp tissue that is irreversibly infected or necrotic due to caries or trauma. The root canals are debrided and shaped with hand or rotary files. Followed by obturation by resorbable material such as nonreinforced zinc/oxide-eugenol, iodoform-based paste (KRI), or a combination paste of iodoform and calcium hydroxide. The tooth then is restored with a restoration that seals the tooth from microleakage.

#### **6.5.1 Expected outcome of pulp therapy**

No post-treatment signs or symptoms such as sensitivity, pain, or swelling should be evident. There should be no radiographic evidence of pathologic external or internal root resorption or other pathologic changes. There should be no harm to the succedaneous tooth. A smooth transition from primary to permanent dentition should be afforded<sup>13</sup>.

#### **6.5.2 Acute dental trauma to primary teeth and management**

The greatest incidence of trauma to the primary teeth occurs at 2 to 3 years of age, when motor coordination is developing. Dental injuries can have improved outcomes if the public is made aware of first-aid measures and the need to seek immediate treatment. Because optimal treatment results follow immediate assessment and care, dentists have an ethical obligation to ensure that reasonable arrangements for emergency dental care are available. The history, circumstances of the injury, pattern of trauma, and behavior of the child and/or caregiver are important in distinguishing nonabusive injuries from abuse.

After a primary tooth has been injured, the treatment strategy is dictated by the concern for the safety of the permanent dentition. If determined that the displaced primary tooth has encroached upon the developing permanent tooth germ, removal is indicated. In the primary dentition, the maxillary anterior region is at low risk for space loss unless the avulsion occurs prior to canine eruption or the dentition is crowded. Fixed or removable appliances, while not always necessary, can be fabricated to satisfy parental concerns for esthetics or to return a loss of oral or phonetic function.

When an injury to a primary tooth occurs, informing parents about possible pulpal complications, appearance of a vestibular sinus tract, or color change of the crown associated with a sinus tract can help assure timely intervention, minimizing complications for the developing succedaneous teeth. Also, it is important to caution parents that the primary tooth's displacement may result in any of several permanent tooth complications, including enamel hypoplasia, hypo calcification, crown/root dilacerations, or disruptions

in eruption patterns or sequence. The risk of trauma-induced developmental disturbances in the permanent successors is greater in children whose enamel calcification is incomplete.

### **6.5.3 Managing premature loss of primary tooth**

The premature loss of primary teeth due to caries, trauma, ectopic eruption, or other causes may lead to undesirable tooth movements of primary and/or permanent teeth including loss of arch length. Arch length deficiency can produce or increase the severity of malocclusions with crowding, rotations, ectopic eruption, crossbite, excessive overjet, excessive overbite, and unfavorable molar relationships. It is recommended that space maintainers be used to reduce the prevalence and severity of malocclusion following premature loss of primary teeth. Space maintenance may be a consideration in the primary dentition after early loss of a maxillary incisor when the child has an active digit habit. An intense habit may reduce the space for the erupting permanent incisor.

## **7. The transition from primary dentition to permanent dentition**

This period is characterized by having distinctive need due to: a potentially high caries rate; increased risk for traumatic injury and periodontal disease; a tendency for poor nutritional habits; an increased esthetic desire and awareness; complexity of combined orthodontic and restorative care (eg, congenitally missing teeth); dental phobia; potential use of tobacco, alcohol, and other drugs; (8) pregnancy; (9) eating disorders; and (10) unique social and psychological needs.

The management of these patients can be multifaceted and complex. An accurate, comprehensive, and up-to-date medical history is necessary for correct diagnosis and effective treatment planning. Familiarity with the patient's medical history is essential to decreasing the risk of aggravating a medical condition while rendering dental care. If the parent is unable to provide adequate details regarding a patient's medical history, consultation with the medical health care provider may be indicated. The practitioner also may need to obtain additional information confidentially from an adolescent patient.

### **7.1 Management of dental caries during mixed dentition period**

Immature permanent tooth enamel, a total increase in susceptible tooth surfaces, and environmental factors such as diet, independence to seek care or avoid it, a low priority for oral hygiene, and additional social factors also may contribute to the upward slope of caries during this period. It is important to emphasize the positive effects that fluoridation, routine professional care, patient education, and personal hygiene can have in counteracting the changing pattern of caries this population.

Fluoridation has proven to be the most economical and effective caries prevention measure. Both systemic benefit of fluoride incorporation into developing enamel and, topical benefits can be obtained through optimally-fluoridated water, professionally-applied and prescribed compounds, and fluoridated dentifrices.

Oral Hygiene with a fluoridated dentifrice and flossing can provide benefit through the topical effect of the fluoride and plaque removal from tooth surfaces. This time of heightened

caries activity and periodontal disease due to an increased intake of cariogenic substances and inattention to oral hygiene procedures warrant a good oral hygiene through daily plaque removal, including flossing, with the frequency and pattern based on the individual's disease pattern and oral hygiene needs

Diet management including diet analysis and modification can be very helpful to reduce the effect of carbohydrates, foods rich in sucrose and beverages with acidic Ph. A diet analysis should result in overall nutrient and energy needs calculation, psychosocial aspects of adolescent nutrition; dietary carbohydrate intake and frequency; intake and frequency of acid-containing beverages and wellness considerations.

Sealant placement is an effective caries-preventive technique that should be considered on an individual basis. Sealants have been recommended for any tooth, primary or permanent, that is judged to be at risk for pit and fissure caries. Caries risk may increase due to changes in patient habits, oral microflora, or physical condition, and unsealed teeth subsequently might benefit from sealant applications. Children at risk for caries should have sealants placed. An individual's caries risk may change over time; periodic reassessment for sealant need is indicated throughout this phase.

## **8. Restorative dentistry**

In cases where remineralization of noncavitated, demineralized tooth surfaces is not successful, as demonstrated by progression of carious lesions, dental restorations are necessary. Preservation of tooth structure, esthetics, and each individual patient's needs must be considered when selecting a restorative material. Molars with extensive caries or malformed, hypoplastic enamel—for which traditional amalgam or composite resin restorations are not feasible—may require full coverage restorations. Each restoration must be evaluated on an individual basis. Preservation of noncarious tooth structure is desirable.

### **8.1 Periodontal disease**

Gingivitis characterized by the presence of gingival inflammation without detectable loss of bone or clinical attachment is common in children. Normal and abnormal fluctuation in hormone levels, including changes in gonadotrophic hormone levels during the onset of puberty, can modify the gingival inflammatory response to dental plaque. Similarly, alterations in insulin levels in patients with diabetes can affect gingival health. In both situations, there is an increased inflammatory response to plaque. However, the gingival condition usually responds to thorough removal of bacterial deposits and improved daily oral hygiene.

Periodontitis aggressive periodontitis is more common in children and adolescents. Aggressive periodontitis can be localized or generalized. Localized aggressive periodontitis (LAGP) patients have interproximal attachment loss on at least two permanent first molars and incisors, with attachment loss on no more than two teeth other than first molars and incisors. Generalized aggressive periodontitis (GAgP) patients exhibit generalized interproximal attachment loss including at least three teeth that are not first molars and incisors. Successful treatment of aggressive periodontitis depends on early diagnosis, directing therapy against the infecting microorganisms and providing an environment for

healing that is free of infection. a combination of surgical or non-surgical root debridement in conjunction with antimicrobial (antibiotic) therapy.

**Necrotizing periodontal diseases** The two most significant findings used in the diagnosis of NPD are the presence of interproximal necrosis and ulceration and the rapid onset of gingival pain. Patients with NPD can often be febrile. Necrotizing ulcerative gingivitis/periodontitis sites harbor high levels of spirochetes and *P. intermedia*, and invasion of the tissues by spirochetes has been shown to occur. Factors that predispose children to NPD include viral infections (including HIV), malnutrition, emotional stress, lack of sleep, and a variety of systemic diseases. Treatment involves mechanical debridement, oral hygiene instruction, and careful follow-up. Debridement with ultrasonics has been shown to be particularly effective and results in a rapid decrease in symptoms. If the patient is febrile, antibiotics may be an important adjunct to therapy. Metronidazole and penicillin have been suggested as drugs of choice.

## 8.2 Occlusal considerations

Malocclusion can be a significant treatment need in the transition period as both environmental and genetic factors come into play. Although the genetic basis of much malocclusion makes it unpreventable, numerous methods exist to treat the occlusal disharmonies, temporomandibular joint dysfunction, periodontal disease, and disfigurement which may be associated with malocclusion. Temporomandibular disorders require special attention to avoid long-term problems. Congenitally missing teeth present complex problem and often require combined orthodontic and restorative care for satisfactory resolution.

**Positional Malocclusion** problems that present significant esthetic, functional, physiologic, or emotional dysfunction are potential difficulties in mixed dentition. These can include single or multiple tooth malpositions, tooth/jaw size discrepancies, and craniofacial disfigurements. Treatment of malocclusion should be based on professional diagnosis, available treatment options, patient motivation and readiness, and other factors to maximize progress. If need be an orthodontist should be included for treatment.

Congenitally missing permanent teeth can have a major impact on the developing dentition. When treating patients with congenitally missing teeth, many factors must be taken into consideration including, but not limited to, esthetics, patient age, and growth potential, as well as periodontal and oral surgical needs. Evaluation of congenitally missing permanent teeth should include both immediate and long-term management.

Abnormal or ectopic eruption patterns of the permanent teeth can contribute to root resorption, bone loss, gingival defects, space loss, and esthetic concerns. Early diagnosis and treatment of ectopically erupting teeth can result in a healthier and more esthetic dentition. Prevention and treatment may include extraction of deciduous teeth, surgical intervention, and/or endodontic, orthodontic, periodontal, and/or restorative care.

## 8.3 Traumatic injuries

The most common injuries to permanent teeth occur secondary to falls, followed by traffic accidents, violence, and sports. All sporting activities have an associated risk of orofacial injuries due to falls, collisions, and contact with hard surfaces. It has been demonstrated that dental and facial injuries can be reduced significantly by introducing mandatory

protective equipment such as face guards and mouthguards. Additionally, participation in leisure activities such as skateboarding, rollerskating, and bicycling also benefit from appropriate protective equipment.

To efficiently determine the extent of injury and correctly diagnose injuries to the teeth, periodontium, and associated structures, a systematic approach to the traumatized child is essential. Assessment includes a thorough medical and dental history, clinical and radiographic examination, and additional tests such as palpation, percussion, sensitivity, and mobility evaluation. Intraoral radiography is useful for the evaluation of dentoalveolar trauma. If the area of concern extends beyond the dentoalveolar complex, extra oral imaging may be indicated. Treatment planning takes into consideration the patient's health status and developmental status, as well as extent of injuries. Advanced behavior guidance techniques or an appropriate referral may be necessary to ensure that proper diagnosis and care are given.

Management of traumatized tooth can vary from simple restoration or re attachment of a broken fragment in a tooth that does not involve pulp to advanced pulpal and periodontal management where these are involved. The objective of such management should be to maintain pulp vitality and restore normal esthetics and function.

Avulsion is the complete displacement of tooth out of socket. The periodontal ligament is severed and fracture of the alveolus may occur. The avulsed tooth should be replanted as soon as possible and then stabilized in its anatomically correct location to optimize healing of the periodontal ligament and neurovascular supply while maintaining esthetic and functional integrity. The tooth has the best prognosis if replanted immediately. If the tooth cannot be replanted within 5 minutes, it should be stored in a medium that will help maintain vitality of the periodontal ligament fibers. The best (ie, physiologic) transportation media for avulsed teeth include (in order of preference) Viaspan™, Hank's Balanced Salt Solution (tissue culture medium), and cold milk. Next best would be a non-physiologic medium such as saliva (buccal vestibule), physiologic saline, or water.

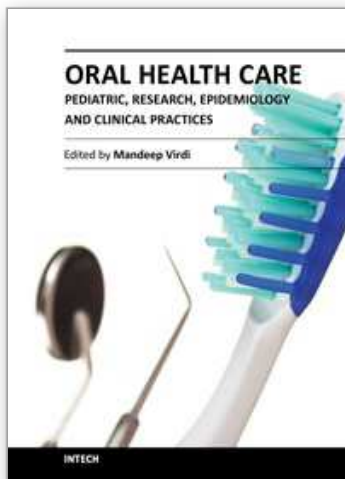
## 9. References

- [1] American Dental Association Commission on Dental Accreditation. Accreditation standards for advanced specialty education programs in pediatric dentistry. Chicago, Ill; 2000
- [2] Kim A. Boggess and Burton L. Edelstein. Oral Health in Women During Preconception and Pregnancy: Implications for Birth Outcomes and Infant Oral Health. *Matern Child Health J.* 2006 September; 10(Suppl 1): 169-174.
- [3] Increased prevalence of developmental dental defects in low birth-weight, prematurely born children: a controlled study. W. Kim Seow, BDS, MDSc, FRACDS Carolyn Humphrys, BDS, David I. Tudehope, MBBS, FRACP. *The American Academy of Pediatric Dentistry* Volume 9 Number 3
- [4] Levy, Paul Tongue-tie, Management of Short SubLingual Frenulum. *Pediatrics in Review* September 1995
- [5] Shu, M.D., Jennifer (April 12, 2010). "Will a bifid uvula cause any problems?". CNN. Retrieved 2010-08-07
- [6] Terrinoni A, Rugg EL, Lane EB, et al (Mar 2001). "A novel mutation in the keratin 13 gene causing oral white sponge nevus". *J. Dent. Res.* 80 (3): 919-923.



- [7] Natal and neonatal teeth: a review. Adekoya-Sofowora CA. Niger Postgrad Med J. 2008 Mar;15(1):38-41
- [8] Guideline on Management of the Developing Dentition and Occlusion in Pediatric Dentistry. Originating Committee Clinical Affairs Committee - Developing Dentition Subcommittee Review Council Council on Clinical Affairs Adopted 1990 Revised 1991, 1998, 2001, 2005, 2009
- [9] Malamed SF. Basic injection technique in local anesthesia. In: Handbook of Local Anesthesia. 5th ed. St. Louis, Mo: Mosby; 2004:159-69.
- [10] Definition of Early Childhood Caries (ECC) Originating council on clinical affairs Review Adopted 2003 AAPD Revised 2007, 2008
- [11] American Academy of Pediatric Dentistry. Policy on interim therapeutic restorations. Pediatric Dent 2009;31 (special issue):38-9.
- [12] Simonsen RJ. Chapter 2: Pit and fissure sealants. In: Clinical Applications of the Acid Etch Technique. 1st ed. Chicago, IL: Quintessence Publishing Co, Inc; 1978:19-42
- [13] Guideline on Pulp Therapy for Primary and Immature Permanent Teeth, AAPD REFERENCE MANUAL V 33 /NO 611/12

IntechOpen



## **Oral Health Care - Pediatric, Research, Epidemiology and Clinical Practices**

Edited by Prof. Mandeep Virdi

ISBN 978-953-51-0133-8

Hard cover, 302 pages

**Publisher** InTech

**Published online** 29, February, 2012

**Published in print edition** February, 2012

Oral health care in pediatric dentistry deals with complete oral health, including preventive aspects for children right from their conception to adolescence, encompassing all the spheres of dentistry including various specialties. It also includes planning a preventive program at individual and community levels. The current research interests in oral health care include studies regarding the role of stem cells, tissue culture, and other ground-breaking technologies available to the scientific community in addition to traditional fields such as anatomy, physiology, and pharmaceuticals etc of the oral cavity. Public health and epidemiology in oral health care is about the monitoring of the general oral health of a community, general afflictions they are suffering from, and an overall approach for care and correction of the same. The oral health care-giver undertakes evaluation of conditions affecting individuals for infections, developmental anomalies, habits, etc. and provides corrective action in clinical conditions. The present work is a compendium of articles by internationally renowned and reputed specialists about the current developments in various fields of oral health care.

### **How to reference**

In order to correctly reference this scholarly work, feel free to copy and paste the following:

Mandeep S. Virdi (2012). Pediatric Dentistry – A Guide for General Practitioner, Oral Health Care - Pediatric, Research, Epidemiology and Clinical Practices, Prof. Mandeep Virdi (Ed.), ISBN: 978-953-51-0133-8, InTech, Available from: <http://www.intechopen.com/books/oral-health-care-pediatric-research-epidemiology-and-clinical-practices/current-developments-in-pediatric-dentistry>

**INTech**  
open science | open minds

### **InTech Europe**

University Campus STeP Ri  
Slavka Krautzeka 83/A  
51000 Rijeka, Croatia  
Phone: +385 (51) 770 447  
Fax: +385 (51) 686 166  
[www.intechopen.com](http://www.intechopen.com)

### **InTech China**

Unit 405, Office Block, Hotel Equatorial Shanghai  
No.65, Yan An Road (West), Shanghai, 200040, China  
中国上海市延安西路65号上海国际贵都大饭店办公楼405单元  
Phone: +86-21-62489820  
Fax: +86-21-62489821

© 2012 The Author(s). Licensee IntechOpen. This is an open access article distributed under the terms of the [Creative Commons Attribution 3.0 License](https://creativecommons.org/licenses/by/3.0/), which permits unrestricted use, distribution, and reproduction in any medium, provided the original work is properly cited.

IntechOpen

IntechOpen