7

Subchondral Bone in Osteoarthritis

David M. Findlay
Discipline of Orthopaedics and Trauma, University of Adelaide, Adelaide, Australia

1. Introduction

Osteoarthritis (OA) is characterised by progressive degenerative damage to articular cartilage, but ultimately the disease affects the whole joint, with important implications for the affected limb and the entire body (Martel-Pelletier and Pelletier, 2010; Edmonds, 2009). There has been an ongoing debate regarding the origins of OA, and specifically whether it initiates in the bone or the cartilage. The debate is somewhat artificial because it assumes that the answer must be one or the other of these possibilities. More likely, OA has multiple etiologies, which converge to produce the recognized manifestations of joint pain and stiffness and degeneration of articular cartilage. Genetic and environmental risk factors for OA, such as increased weight, female sex, joint dysplasias and malalignment, and injury, clearly contribute to the establishment and progression of this condition (Felson, 1988). However, it is most important to consider all possibilities for the underlying cause(s) for OA because our current level of understanding has failed to produce treatments for this condition that offer much more than palliation, with many sufferers proceeding to joint replacement in end stage disease.

There are well described changes that are observed in both articular cartilage and subchondral bone in OA (Martel-Pelletier and Pelletier, 2010; Edmonds, 2009; Goldring and Goldring, 2010; Kwan et al., 2010). Changes in the bone include sclerotic changes, typified by increased subchondral plate thickness and osteophyte formation, and the development of bone marrow lesions that can be visualized by MR imaging, and which seem to precede, temporally and spatially, bone cysts in the subchondral compartment (Tanamas et al., 2010). The subchondral bone does much more than provide a substrate on which the articular cartilage sits. While it does give support to the cartilage, it also offers complementarity of shape to the opposite side of the articulation, with important consequences for the joint when this congruency is lost. In addition, the predominantly trabecular structure of the subchondral bone gives compliance and shock absorption to the joint (Madry et al., 2010). It was thought that the sclerotic changes in the subchondral bone in OA made it stiffer and less compliant, resulting in increased loading of the cartilage (Radin et al., 1982) but later work showed that the bone in OA may actually be less mineralised and therefore less stiff (Day et al., 2001). The price paid for the shock absorption role of subchondral bone is the production of damage within the bone matrix by repeated loading. This bone matrix damage is repaired by bone turnover and remodeling, which are highly developed functionalities of bone cells: osteocytes to detect the damage, osteoclasts to remove the damage and osteoblasts to replace sites of damage with healthy new bone (Eriksen, 2010). A

characteristic of OA is that the process of subchondral remodeling is increased (Tat et al., 2010), as visualized, for example, with bone scintigraphy (Dieppe et al., 1993). The subchondral compartment also carries essential infrastructure for the joint: it has a rich nervous supply, consistent with it being a major source of pain in joint pathology such as OA, and abundant vasculature, suggesting a significant negative impact on joint health if blood supply to this site is reduced.

2. Bone structure as a cause of OA

2.1 Bone micro-architecture in OA

Changes in the microstructure of bone in OA, particularly the subchondral plate and the trabecular bone, have been well described (Madry et al., 2010; Fazzalari and Parkinson, 1998, Shen et al, 2009, Blain et al., 2008). In human OA subjects, changes consistently include thicker trabeculae and a higher trabecular BV/TV than for normal or osteoporotic subchondral bone. In severe OA, a reduced hardness of trabecular bone from the femoral head, compared with normal subjects, was found (Dall'Ara et al., 2011). All these changes have been measured in bone taken at late stage disease, at which time they may relate to the skeleton broadly because they have been found in bone from the inter-trochanteric region of the proximal femur, which is separated by several centimeters from the affected joint (Kumarasinge et al., 2010), and in bone from the iliac crest. Nevertheless, it is not known when in human disease these changes appear and whether they are in some way causative of the disease process or simply describe it. Animal models for the most part show that changes in the subchondral bone parallel cartilage degradation (for example, Moodie et al., 2011). A recent comprehensive study by Stok et al. used longitudinal high resolution imaging to compare over time the joints of two mouse strains, one which spontaneously develops OA of the knee, and one which does not (Stok et al., 2009). The susceptible mice developed more trabecular bone, in a region specific manner, and particularly in the tibial compartment, in parallel with arthritic changes in the articular cartilage. Even in this very comprehensive study, the authors were unable to assign initiation of disease to either bone or cartilage.

2.2 Bone shape changes leading to OA

It is clear that shape deformities in bone can lead to OA in some joints, most obviously and commonly the hip and knee. There are a large number of ways in which bone shape can become sub-optimal for joint articulation and load bearing. These can be either congenital, developmental, or due to disease or fracture. Examples include malalignment of the knee (Hunter et al., 2009a) and the dysplastic hip, whether this occurs as a result of perinatal dislocation or congenitally incorrect morphology of the acetabulum or femoral head. Untreated hip dysplasia can manifest as joint laxity or impingement and decreased joint range of motion, and can result in degenerative changes, often accompanied with pain, and in OA at an early age (Mechlenburg, 2008). Genetics are likely to play a major role in OA that has bone deformity as its underlying cause. Waarsing et al. (2011a) have reported in abstract on the changes in femoral shape that occur across the lifetime of rats. The implications of their data are that deformity can develop over time, driven by genes or environment of interaction between these. Indeed, in recently published work from the same group, a range of shape 'modes' are described for the proximal femur, several of

which predispose to OA, but only in carriers of susceptibility alleles of genes that associate with OA (Waarsing et al., 2011b). In human subjects, it was shown that the shape of the proximal femur, in particular the relative size of the femoral head and neck, was associated with the risk of OA (Lynch et al., 2009). Diseases such as Paget's disease of bone, or deficiency of factors essential for skeletal development and health, such as in vitamin D-dependent Rickets, can also cause bone deformities and malalignment of bones that alter the biomechanics of joints and lead to OA (Ralston, 2008). Finally, fractures that involve articular cartilage can destroy the congruency of the joint, leading to the development of OA. This is typically seen in pelvic fractures that involve the acetabulum and in tibial plateau fractures when good reduction of the fracture has not been achieved (Honkonen, 1995). All of these shape changes alter the biomechanics of joints, which is then transduced in ways that are still poorly understood into cellular and biochemical changes that lead to inflammation and eventually cartilage loss.

3. Differential gene expression in OA bone

In addition to structural changes in bone in OA, gene expression in bone from OA individuals is quite different from that in age and sex-matched controls or osteoporotic individuals. Taking RNA from trabecular bone at the intertrochanteric region of the femur, a site distal from the articular surface of the femur, Kuliwaba et al. (2000) showed that IL-6 and IL-11 mRNA were significantly less abundant in an OA group than in an age-matched control group. Osteocalcin mRNA expression was significantly greater in OA and increased significantly with age in the OA group but not in controls. Hopwood et al. (2005, 2007) performed gene microarray analysis on bone from the same region of the femur and identified a large number of differentially expressed genes in OA compared with control or osteoporotic bone. In some cases, variance of gene expression was greater in the OA bone than control or osteoporotic bone and for other genes the variance was less. For some genes, there was a clear gender-related difference. A substantial number of the top-ranking differentially expressed genes are known to play roles in osteoblasts, osteocytes and osteoclasts. Many of these genes are targets of either the WNT or the TGF-beta/BMP signalling pathways and a subset is involved in osteoclast function. The authors suggested that altered expression of these sets of genes may in part explain the altered bone remodelling observed in OA. Increased insulin-like growth factor types I and II and TGF-beta protein was reported in OA cortical bone from the iliac crest, consistent with an increased anabolic stimulus in OA bone (Dequeker et al., 1993). Also consistent with this are the observations of Truong et al. (2006), of differential expression in OA of genes encoding bone anabolic factors in trabecular bone from the proximal femur. Those data revealed elevated mRNA for alkaline phosphatase, osteocalcin, osteopontin, COL1A1, and COL1A2 in OA bone compared to control, which the authors suggested reflect possible increases in osteoblastic biosynthetic activity and/or bone turnover at the intertrochanteric region of the femur in OA. Interestingly, in the controls but not in the OA samples, positive associations were observed between a number of the molecular and histomorphometric parameters, suggesting, firstly, that the measured expression of genes in bone relates to remodeling mechanisms and, secondly, that these bone regulatory processes may be altered in OA. These data were supported by more recent work, again showing strong associations between the expression of genes, such as CTNNB1 and TWIST1 and structural and remodeling indices in control bone but not in OA and the converse with genes such as

MMP25 (Kumarasinghe et al., 2010). Gene expression has also been explored in osteoblasts taken from OA subchondral bone. Interestingly, these cells appear to retain in culture differences, compared with control cells, in the expression of important regulatory genes, with a very recent example showing increased TGF-beta in OA cells inducing increased DKK-2 (Chan et al., 2011). Silencing of either TGF-beta or DKK2 in these cells was reported to normalize the OA phenotype, including the decreased mineralization, in untreated OA osteoblasts. Strong associations were found between the ratio of RANKL/OPG mRNA and the indices of bone turnover, ES/BS and OS/BS, but only in trabecular bone from control individuals and not in OA bone (Fazzalari et al., 2001), again suggesting that bone turnover may be regulated differently in this disease. Truong et al. (2006) further speculated that the finding of differential gene expression, as well as architectural changes and differences between OA and controls at a skeletal site distal to the active site of joint degeneration, supports the concept of generalised involvement of bone in the pathogenesis of OA. The above data invite the speculation that altered expression of the genes that direct bone turnover leads to differences in bone, subchondrally or generally, which increases the risk of OA or initiates or progresses the disease. However, the limitation of the work to date is that it has all been performed in bone from end-stage disease. What is urgently required in order to better understand OA, and the role of bone in it, is longitudinal data describing gene expression and its relationship to bone turnover, across the OA disease process. It should be acknowledged that a great deal of effort has been made to identify genetic risk factors for OA through gene association studies (Spector and McGregor, 2004). Genes implicated in these association studies include VDR, AGC1, IGF-1, ER alpha, TGF-beta, cartilage matrix protein, cartilage link protein, and collagen II, IX, and XI. While some of these genes might appear to relate more to cartilage than bone, genes such as VDR, IGF-1 and TGF-beta could well be involved in the regulation of bone growth and remodeling. In discussion, these authors describe OA as a complex disease, in which genes may operate differently at different body sites and on different disease features within body sites. In addition, it is not known at what stage of development OA-related genes might influence the skeleton.

4. Vascular pathology

There is now a great deal of evidence to support the concept that vascular pathology might be directly involved in skeletal pathology (reviewed in Findlay, 2007). In particular, venous stasis, hypertension, and altered coagulability have all been reported in both animal models of OA, and in the human disease (Arnoldi et al., 1994). Since bone is highly vascular, particularly at the ends of long bones, and cartilage is avascular, vascular pathology can directly affect bone (and other tissues in the joint) but cannot directly affect articular cartilage. Some of the evidence for changes in vascularity and/or blood flow in the subchondral bone having a causal role in OA is presented below.

4.1 Impaired venous blood flow and increased intraosseous pressure in OA

Impaired venous blood flow (venous stasis) and consequent decreased outflow of blood from the articular ends of long bones, resulting in increased intraosseous pressure, has long been proposed as one causal factor in osteoarthritis. Long bones have multiple feeding and draining vessels, but the ability of the system to drain the blood is compromised once the larger draining vessels, for example the femoral vein, are blocked. Patients with severe

degenerative osteoarthritis of the hip are reported to have impaired venous drainage from the juxtachondral cancellous bone across the cortex (Lucht et al., 1981). Brookes and Helal (1968) further investigated the concept that defective venous drainage is generally present in OA. Their work was based on the assumptions that there is a disturbance of osteogenesis in OA and that vascular factors are involved in normal bone turnover. They used phlebography to examine the subchondral vasculature in a large group of knee osteoarthritic patients compared with individuals with no OA symptoms. They found that the subchondral medullary sinusoids were distended only in the patients with primary OA and the contrast agent was cleared more slowly from affected knees, suggesting a more sluggish cancellous circulation. The patients with sinusoidal engorgement all had a history of diffuse aching pain in the affected bone and, for those patients treated by osteotomy, relief of pain was concomittent with resolution of the vascular engorgement. Anecdotally, the affected bone was softer than normal, as judged by ease of insertion of a needle, suggesting decreased mineral in the bone. The patient data are interesting but, since they relate to established OA, they give little clue to cause and effect. However, in the same publication, the authors described an experiment in rats, in which they ligated the draining veins from the knee and produced venous engorgement in the hind limb bones. An increased amount of trabecular bone was noted in the tibial and femoral epiphyses of these animals and both the subchondral bone plate and the calcified zone of the articular cartilage were also thickened. These very interesting observations led Brookes and Helal (1968) to propose that osteoarthritis can be promoted by venous congestion resulting in impeded microcirculation. Arnoldi wrote extensively on the role of vascular pathology in osteoarthritis and suggested a continuum of vascular changes and joint disease from OA to osteonecrosis (Arnoldi, 1994). He concluded that intact arterial inflow combined with increased resistance to venous outflow is responsible for the intraosseous venous hypertension frequently observed in established osteoarthritis, as well as in nontraumatic ischemic necrosis of bone. He further showed that increasing the intraarticular pressure in rabbits increased intraosseous pressure. This is because the drainage veins from the ends of the long bones in general lie within the joint capsule. For example, the drainage veins from the femoral neck emerge at the edge of the cartilage and are initially within the joint capsule. Thus, even small increases in articular pressure are sufficient to collapse these thin walled vessels and decrease the flow of blood. These findings suggest that increased intra-articular pressure, produced by obesity or intra-articular inflammation, could be one of the mechanisms for producing intraosseous hypertension in OA, either as a primary event in the disease or as an exacerbating factor. Kiaer et al. (1990) showed increased intraosseous pressure and hypoxia in the femoral head of hips with early osteoarthritis and in ischemic necrosis of bone. They concluded that necrosis of bone trabeculae and marrow are early manifestations of both osteoarthritis and ischemic necrosis of bone. Lee et al. (2009) used modern imaging techniques to explore the relationship between fluid dynamics in subchondral bone and OA progression. Using dynamic contrast-enhanced (DCE) MRI, they described the temporal and spatial perfusion patterns in subchondral bone in relation to the development of bone and cartilage lesions, in the Dunkin-Hartley guinea pig model of OA. They obtained evidence for decreased perfusion of the subchondral bone and fluid stasis in that model, likely due to outflow obstruction, and that these changes temporally precede, and spatially localise at, the same site as eventual bone and cartilage lesions. These data

support, in a spontaneous animal model that mirrors many of the changes seen in human disease, a role for vascular changes in the subchondral bone as drivers for OA disease.

4.2 Consequences of decreased bone blood perfusion in the subchondral bone

Arnoldi (1994) discussed the concept that decreased bone blood perfusion, and the consequent decreased interstitial fluid flow in the subchondral bone, lead to ischaemia and bone death. This idea related primarily to vascular necrosis of bone, but there is some evidence that episodes of ischaemia in the subchondral bone compartment might occur also in OA. Thus, there are two potential outcomes of venous stasis in subchondral bone. The first is that poor perfusion in the subchondral bone may also result in a decrease in nourishment to the overlying cartilage, as proposed by Imhof et al. (1997). More recently, Pan et al. (2009) were one of several groups to show that small molecules can penetrate into the calcified cartilage from the subchondral bone. In elegant experiments, they used fluorescence and photobleaching methods to demonstrate that fluorescein can diffuse between subchondral bone and articular cartilage, and that these compartments form a functional unit with biochemical as well as mechanical interactions. Secondly, the mechanical strength of the subchondral bone may be adversely affected by episodes of ischaemia. What is commonly observed in both established OA and in early OA, in individuals with painful joints (Mandalia et al., 2005), are areas of subchondral bone that appear bright with magnetic resonance (MR) imaging, which are often termed bone marrow lesions (BML) (reviewed in Bassiouni, 2010 and Daheshia and Yao, 2011). Longitudinal studies have shown that the presence of BML is a potent risk factor for structural deterioration in knee OA (Felson et al., 2003; Hunter et al., 2006; Garnero et al, 2005; Zhai et al., 2006; Carrino et al., 2006; Dore et al., 2010) and future joint replacement (Tanamas et al., 2010). Enlargement of these bone marrow lesions has been strongly associated with increased cartilage loss (Mandalia et al., 2005). Conversely, a reduction in the extent of bone marrow abnormalities on MRI is associated with a decrease in cartilage degradation (Hunter et al., 2006). It has recently been shown that subchondral cysts, which are characteristic of established and severe OA, arise at the same sites as BML (Crema et al, 2010). A number of studies point to possible causal factors for BML, including mechanical loading (Bennell et al., 2010), dietary fatty acid intake (Wang et al., 2009) and total serum cholesterol and triglycerides (Davies-Tuck et al., 2009), disturbances in the latter having well established vascular implications. BML have been described as containing bone that is sclerotic, but which has reduced mineral density, perhaps rendering the area mechanically compromised (Hunter et al., 2009). Consistent with this, is the finding that BMLs are strongly associated with subchondral bone attrition (Roemer et al., 2010). Thus, episodes of venous stasis in OA may lead to loss of osteocyte viability in the corresponding regions of subchondral bone. It has been shown that loss of osteocyte viability causes increased bone turnover in order to repair damaged and necrotic bone tissue, due to activation of osteoclastic resorption (Noble et al., 2003; Cardoso et al., 2009). There may be a stage in this process, during which bone attrition leads to compromised structural support for the overlying articular cartilage.

There is good histological and biochemical evidence of increased bone remodelling in subchondral bone containing BML (Plenk et al., 1997). In addition, increased subchondral bone remodeling, detected by bone scans, has been well described in established OA, where it has been reported to predict joint space narrowing (Berger et al., 2003; MacFarlane et al., 1993). Whether the increased bone turnover is cause or effect cannot be determined in

human OA, however several animal models of OA are interesting in this regard. Muraoka et al. (2007) reported that in Hartley guinea pigs, the subchondral cancellous bone was fragile before the onset of cartilage degeneration. In the rat anterior cruciate ligament transection model of OA, increased subchondral bone resorption is associated with early development of cartilage lesions, which precedes significant cartilage thinning and subchondral bone sclerosis (Hayami et al., 2006). Significantly, treatment with the anti-resorptive bisphosphonate, alendronate, in that model suppressed both subchondral bone resorption and the later development of OA symptoms in the knee joint (Hayami et al., 2004), suggesting that subchondral bone remodeling plays an important role in the pathogenesis of OA. Similarly, calcitonin reduced the levels of circulating bone turnover markers and the severity of OA lesions in the dog model of ACLT (Manicourt et al., 1999). Thus, it is likely that events in the subchondral bone have a direct effect on the overlying cartilage. Amin et al. (2009) reported on very interesting experiments in which chondrocyte survival was assessed in bovine cartilage explants in the presence or absence of subchondral bone in the explant culture. Although the authors noted several limitations of their experiments and cautioned against over-interpretation, they made several observations. They found that excision of subchondral bone from articular cartilage resulted in an increase in chondrocyte death at seven days, mainly in the superficial zone. However, the presence of the excised subchondral bone in the culture medium abrogated this increase in chondrocyte death, most likely due to soluble mediator(s) released from the subchondral bone. Amin et al. (2009a) also reported in abstract on an experiment, using the same model, but comparing normal and OA human osteochondral explants. In that experiment, chondrocyte death increased in cartilage after excision of the subchondral bone but inclusion of healthy excised bone in culture protected the cartilage. In contrast, chondrocytes were not protected by the inclusion of sclerotic OA subchondral bone. Neither the cells nor the molecules responsible for chondrocyte survival or death were identified in these experiments, and this information is required. Nevertheless, it is known that active osteoclasts produce cytokine products that are catabolic for chondrocytes, such as IL-1 beta (O'Keefe et al., 1997), and osteocytes have been shown capable of assuming a catabolic phenotype (Atkins et al., 2009). Therefore, active remodeling in the juxta-articular bone could promote a catabolic phenotype in chondrocytes in the overlying articular cartilage.

4.3 Prevalence of hypertension in OA

Patients with end-stage hip OA exhibit a high prevalence of vascular-related comorbidities (Kiefer et al., 2003) and a causal link between the progression of OA and atheromatous vascular disease and hypertension has recently been proposed (Huang et al., 1995). Uncontrolled hypertension is a strong risk factor, not only for cardiovascular disease, but also numerous end-organ morbidities. There is evidence that the consequences of hypertension are due to endothelial cell damage or dysfunction (Tektonidou et al., 2004; Korompilias et al., 2007; Zhang et al., 2007). Because both coagulation and fibrinolysis are regulated by vascular endothelial cells, hypertension is associated with increased risk of thrombotic disorders. The potential importance of altered coagulability is discussed below. There appears to be a higher incidence of hypertension in individuals with OA, although it is difficult to dissect a direct contribution of one to the other. It has been reported that generalized osteoarthrosis is significantly more common in older males with high than with low diastolic blood pressure (Lawrence et al., 1975). In the cohort described in that

publication, the relationship between hypertension and osteoarthrosis was independent of obesity. Osteoarthrosis of the knee in females was reported as more frequent in hypertensive individuals, again independent of obesity. However, many of those patients were overweight or obese, as commonly observed in OA cohorts. Weinberger et al. (1989) reported that 75% of a cohort of patients with OA had symptoms associated with hypertension and heart disease, which is probably higher than an age-matched population. These data do not provide a strong link between hypertension and the initiation or progression of OA and it would be of interest to explore this relationship more in similar populations treated or untreated for their hypertension. In attempting to elucidate whether hypertension is a causal factor in OA, it is important to determine whether it is truly involved in the disease or is simply a component of the disease cluster of the 'metabolic syndrome', which includes increased BMI and obesity, hypertension, and a compilation of factors characterized by insulin resistance and the identification of 3 of the 5 criteria of abdominal obesity, elevated triglycerides, decreased high-density lipoprotein level, elevated blood pressure, and elevated fasting plasma glucose (Steinbaum, 2004).

4.4 Coagulation abnormalities in OA

Coagulation abnormalities have been described in patients with hip osteonecrosis (ON), resulting in investigation in OA as well. Intravascular coagulation, activated by a variety of underlying diseases, has been postulated as the common link leading to ischaemic insult, intraosseous thrombosis and bone necrosis. Patients with hip ON were investigated for the presence of a spectrum of thrombophilic disorders to assess whether their presence is associated with an increased risk of ON (Korompilias et al., 2004). More than 80% of these patients had a thrombotic abnormality and the authors speculated that ON may result from repetitive thrombotic or embolic phenomena that occur in the vulnerable vasculature of the femoral head. In a rabbit model of steroid-associated femoral ON, micro-angiography of the subchondral bone showed clear evidence of thrombus-blocked and leaking blood vessels (Zhang et al., 2007). Understanding of the relationship between hypercoagulable states and ON may allow pharmacologic intervention to prevent this process. The work of Cheras and Ghosh showed that changes in coagulability of the blood might also predispose to OA (Cheras et al., 1997; Ghosh and Cheras, 2001). Cheras *et al*. (1993) observed intraosseous intravascular lipid and thrombosis, particularly in the venous microvasculature, in femoral heads from patients with degenerative osteoarthritis, but not in non-osteoarthritic femoral heads. A study of femoral heads from OA patients showed frequent widespread loss of osteocyte viability, and led to the suggestion that episodic osteocyte death and elevated bone remodeling, as discussed above, could be a cause rather than a result of at least some forms of OA (Cheras et al., 1993). Intriguingly, Ghosh and Cheras (1997) found significant differences in serum fibrinogenic and fibrinolytic parameters, and lipid profiles, between an osteoarthritis group and a control group. Their data are consistent with hypercoagulability and hypofibrinolysis in OA. They described increased pro-coagulant factors in individuals with a comparatively recent diagnosis of OA and proposed that the findings of coagulation and lipid abnormalities support a possible relationship between the etiology of osteoarthritis and ischemic necrosis of bone. Interestingly, the coagulability changes were associated with evidence of increased bone turnover, possibly due to increased bone repair in OA. A potential consequence of ischemia in the subchondral bone is the loss of interstitial fluid flow that leads to cell death of osteocytes (Bakker et al., 2004). If an increased propensity for

intravascular coagulation has a role in OA, treatments that normalize clotting would be expected to reduce the symptoms of OA. Although this possibility has not been well researched, Ghosh and Cheras (1997) described a study, which utilized large breed dogs with or without radiologically confirmed hip OA. The dogs were given subcutaneous Calcium Pentosan Polysulphate (CaPPS) for 4 weeks. Prior to treatment, platelet aggregability was increased in the OA group, which, like the human OA group described above, also displayed hypofibrinolysis. Interestingly, CaPPS treatment normalized these parameters and the dogs showed clinical improvement with respect to their OA symptoms. Qualitatively similar results were seen in a 24-week study in human OA subjects treated with CaPPS, although interpretation of this study was complicated by a strong placebo response. In a more recent study, sodium pentosan polysulphate was given to patients with OA of grade Kellgren-Lawrence 1 to 3 (Kumagia et al., 2010). At a dose of drug that increased INR significantly, OA symptoms improved rapidly and for the period of the study. Despite such studies, the role of this class of compound in human OA is controversial, with the possible reasons for different findings being that they are perhaps not, in fact, efficacious, or that they have been given to inappropriate cohorts, with advanced OA, or that there is variability of drug quality and potency, or the already mentioned placebo response that is common in OA. However, the basic science continues to be supportive of a therapeutic role for these compounds in OA. A recent study in a mouse model of collagenase-induced OA showed that glucosamine hydrochloride treatment inhibited destructive changes in cartilage and bone erosion and prevented osteophyte formation (Ivanovska and Dimitrova, 2011). These observations occurred in parallel with decreased expression of the bone anabolic molecule, BMP-2, in the subchondral bone and increased expression of the anti-anabolic Wnt inhibitor, DKK-1. In attempting to account for these effects, there is a large literature describing the anti-inflammatory effects of the glucosamine class of compounds, in particular with anti-inflammatory and anti-atherosclerotic effects on vascular endothelial cells (Ju et al., 2008; Largo et al., 2009). The concept that protection of vascular endothelial cells can have a beneficial effect in subchondral bone and joints is supported by the study mentioned above using a rabbit model of steroid-associated femoral ON (Zhang et al., 2007). Micro-angiography of the subchondral bone showed clear evidence of thrombus-blocked and leaking blood vessels in this disorder, which was prevented in this model by coadministration of flavinoid vascular protective agents. It has not been determined whether hypercoagulability and hypofibrinolysis precede or cause OA, or whether they are a consequence of the disease. However, familial studies by Glueck et al. (1994), in patients with ischemic necrosis of bone, indicated that genetically linked hypofibrinolysis associated with raised PAI-1 may be a major cause of osteonecrosis. Similar familial studies in osteoarthritis are indicated, in addition to prospective studies of individuals with hypercoagulability or hypofibrinolysis.

5. Summary

OA is clearly a disease that intimately involves bone, in ways that include altered gene expression in bone, altered bone structure, altered blood flow and altered biomechanics. The extent of involvement of various joint components is likely to be different in different joints and in different disease causations. In some joints, notably hips and knees, there are bone shapes, either congenital or acquired, that predispose to OA. To that extent, OA can be said

to initiate in the bone. Longitudinal studies are required to investigate the causes of bone shape abnormalities and whether there might be an opportunity to intervene to maintain, particularly in hip joints, their optimal shape. What role the bone plays in the initiation and progression of 'idiopathic' or 'general' OA is still not clear, although changes can be observed in subchondral bone from its earliest manifestations. There is also evidence that agents that are known to act on bone and not directly on cartilage, such as bisphosphonate anti-resorptives, can inhibit the course of OA, at least experimentally. The data reviewed here suggest the value of investigating other agents that address bone turnover, and promote the health of the subchondral vasculature, in OA. These approaches could accompany other current management, such as weight loss, exercise programs and intra-articular lubricants, starting as early in the disease as possible. In evaluation of approaches that target the bone in OA, endpoints will benefit from new imaging modalities that are much more informative of all the compartments of the joint, cartilage, synovium, tendon and muscle, and bone.

6. Acknowledgements

Funding from the National Health and Medical Research Council of Australia is gratefully acknowledged, as is the support of the Department of Orthopaedics and Trauma at the Royal Adelaide Hospital, Adelaide, SA, Australia and the University of Adelaide.

7. Abbreviations

OA: osteoarthritis, MRI: magnetic resonance imaging, BML: bone marrow lesions, ON: osteonecrosis, BMI: body mass index, ES/BS: eroded surface/bone surface, OS/BS: osteoid surface/bone surface, RANKL: receptor activator of nuclear factor kappa B ligand, OPG: osteoprotegerin

8. References

Amin AK, Huntley JS, Simpson AH, Hall AC. Chondrocyte survival in articular cartilage: the influence of subchondral bone in a bovine model. J Bone Joint Surg Br. 2009 91:691-9.

Amin AK, Huntley JS, Simpson AH, Hamish, A, Hall AC. Bone-Cartilage Interactions: The Survival of Human Articular Chondrocytes is Influenced by Subchondral bone. Transactions 2009a ORS meeting, http://www.ors.org/web/Transactions/55/0973.PDF

Arnoldi CC. Vascular aspects of degenerative joint disorders. A synthesis. Acta Orthop Scand Suppl. 1994 261:1-82.

Atkins GJ, Welldon KJ, Holding CA, Haynes DR, Howie DW, Findlay DM. The induction of a catabolic phenotype in human primary osteoblasts and osteocytes by polyethylene particles. Biomaterials. 2009 30:3672-81.

Bakker A, Klein-Nulend J, Burger E. Shear stress inhibits while disuse promotes osteocyte apoptosis. Biochem Biophys Res Commun 2004 320:1163-8.

Bassiouni HM.Bone marrow lesions in the knee: the clinical conundrum. Int J Rheum Dis. 2010 13:196-202.

Bennell KL, Creaby MW, Wrigley TV, Bowles KA, Hinman RS, Cicuttini F, Hunter DJ. Bone marrow lesions are related to dynamic knee loading in medial knee osteoarthritis. Ann Rheum Dis. 2010 69:1151-4.

Berger CE, Kroner AH, Minai-Pour MB, Ogris E, Engel A. Biochemical markers of bone metabolism in bone marrow edema syndrome of the hip. Bone 2003 33:346-51.

Blain H, Chavassieux P, Portero-Muzy N, Bonnel F, Canovas F, Chammas M, Maury P, Delmas PD. Cortical and trabecular bone distribution in the femoral neck in osteoporosis and osteoarthritis. Bone. 2008 43:862-8.

Brookes M, Helal B. Primary osteoarthritis, venous engorgement and osteogenesis. J Bone Joint Surg Br. 1968 50:493-504.

Cardoso L, Herman BC, Verborgt O, Laudier D, Majeska RJ, Schaffler MB. Osteocyte apoptosis controls activation of intracortical resorption in response to bone fatigue. J Bone Miner Res. 2009 24:597-605.

Carrino JA, Blum J, Parellada JA, Schweitzer ME, Morrison WB. MRI of bone marrow edema-like signal in the pathogenesis of subchondral cysts. Osteoarthritis Cartilage 2006 14:1081-5.

Chan TF, Couchourel D, Abed E, Delalandre A, Duval N, Lajeunesse D. Elevated Dickkopf-2 levels contribute to the abnormal phenotype of human osteoarthritic osteoblasts. J Bone Miner Res. 2011 26:1399-410.

Cheras PA, Freemont AJ, Sikorski JM. Intraosseous thrombosis in ischemic necrosis of bone and osteoarthritis. Osteoarthritis Cartilage 1993 1:219-32.

Cheras PA, Whitaker AN, Blackwell EA, Sinton TJ, Chapman MD, Peacock KA. Hypercoagulability and hypofibrinolysis in primary osteoarthritis. Clin Orthop 1997 334:57-67.

Crema MD, Roemer FW, Zhu Y, Marra MD, Niu J, Zhang Y, Lynch JA, Javaid MK, Lewis CE, El-Khoury GY, Felson DT, Guermazi A. Subchondral cystlike lesions develop longitudinally in areas of bone marrow edema-like lesions in patients with or at risk for knee osteoarthritis: detection with MR imaging- the MOST study. Radiology. 2010 256:855-62.

Daheshia M, Yao JQ. The bone marrow lesion in osteoarthritis. Rheumatol Int. 2011 31:143-8.

Dall'Ara E, Ohman C, Baleani M, Viceconti M. Reduced tissue hardness of trabecular bone is associated with severe osteoarthritis. J Biomech. 2011 44:1593-8.

Davies-Tuck ML, Hanna F, Davis SR, Bell RJ, Davison SL, Wluka AE, Adams J, Cicuttini FM. Total cholesterol and triglycerides are associated with the development of new bone marrow lesions in asymptomatic middle-aged women - a prospective cohort study. Arthritis Res Ther. 2009 11:R181.

Day JS, Ding M, van der Linden JC, Hvid I, Sumner DR, Weinans H. A decreased subchondral trabecular bone tissue elastic modulus is associated with pre-arthritic cartilage damage. J Orthop Res. 2001 19:914-8.

Dequeker J, Mohan S, Finkelman RD, Aerssens J, Baylink DJ. Generalized osteoarthritis associated with increased insulin-like growth factor types I and II and transforming growth factor beta in cortical bone from the iliac crest. Possible mechanism of increased bone density and protection against osteoporosis. Arthritis Rheum. 1993 36:1702-8.

Dieppe P, Cushnaghan J, Young P, Kirwan J. Prediction of the progression of joint space narrowing in osteoarthritis of the knee by bone scintigraphy. Ann Rheum Dis. 1993 52:557-63.

Dore D, Martens A, Quinn S, Ding C, Winzenberg T, Zhai G, Pelletier JP, Martel-Pelletier J, Abram F, Cicuttini F, Jones G. Bone marrow lesions predict site-specific cartilage defect development and volume loss: a prospective study in older adults. Arthritis Res Ther. 2010 12:R222.

Edmonds S. Therapeutic targets for osteoarthritis. Maturitas. 2009 63:191-4.

Eriksen EF. Cellular mechanisms of bone remodeling. Rev Endocr Metab Disord. 2010 11:219-27.

Fazzalari NL, Parkinson IH. Femoral trabecular bone of osteoarthritic and normal subjects in an age and sex matched group. Osteoarthritis Cartilage. 1998 6:377-82.

Fazzalari NL, Kuliwaba JS, Atkins GJ, Forwood MR, Findlay DM. The ratio of messenger RNA levels of receptor activator of nuclear factor kappaB ligand to osteoprotegerin correlates with bone remodeling indices in normal human cancellous bone but not in osteoarthritis. J Bone Miner Res. 2001 16:1015-27.

Felson DT. Epidemiology of hip and knee osteoarthritis. Epidemiol Rev. 1988 10:1-28

Felson DT, McLaughlin S, Goggins J, LaValley MP, Gale ME, Totterman S, Li W, Hill C, Gale D. Bone marrow edema and its relation to progression of knee osteoarthritis. Ann Intern Med. 2003; 139:330-6.

Findlay DM. Vascular pathology and osteoarthritis. Rheumatology (Oxford). 2007 46:1763-8.

Garnero P, Peterfy C, Zaim S, Schoenharting M. Bone marrow abnormalities on magnetic resonance imaging are associated with type II collagen degradation in knee osteoarthritis: a three-month longitudinal study. Arthritis Rheum 2005 52:2822-9.

Ghosh P, Cheras PA. Vascular mechanisms in osteoarthritis. Best Pract Res Clin Rheumatol 2001 15:693-709.

Glueck CJ, Glueck HI, Welch M, Freiberg R, Tracy T, Hamer T, Stroop D. Familial idiopathic osteonecrosis mediated by familial hypofibrinolysis with high levels of plasminogen activator inhibitor. Thromb Haemost 1994 71:195-8.

Goldring MB, Goldring SR. Articular cartilage and subchondral bone in the pathogenesis of osteoarthritis. Ann N Y Acad Sci. 2010 1192:230-7

Hayami T, Pickarski M, Wesolowski GA, McLane J, Bone A, Destefano J, Rodan GA, Duong L. The role of subchondral bone remodeling in osteoarthritis: reduction of cartilage degeneration and prevention of osteophyte formation by alendronate in the rat anterior cruciate ligament transection model. Arthritis Rheum 2004 50:1193-206.

Hayami T, Pickarski M, Zhuo Y, Wesolowski GA, Rodan GA, Duong le T. Characterization of articular cartilage and subchondral bone changes in the rat anterior cruciate ligament transection and meniscectomized models of osteoarthritis. Bone 2006 38:234-43.

Hopwood B, Gronthos S, Kuliwaba JS, Robey PG, Findlay DM, Fazzalari NL. Identification of differentially expressed genes between osteoarthritic and normal trabecular bone from the intertrochanteric region of the proximal femur using cDNA microarray analysis. Bone. 2005 36:635-44.

Hopwood B, Tsykin A, Findlay DM, Fazzalari NL. Microarray gene expression profiling of osteoarthritic bone suggests altered bone remodelling, WNT and transforming

growth factor-beta/bone morphogenic protein signalling. Arthritis Res Ther. 2007 9:R100.

Huang PL, Huang Z, Mashimo H, Bloch KD, Moskowitz MA, Bevan JA, Fishman MC. Hypertension in mice lacking the gene for endothelial nitric oxide synthase. Nature 1995 377:239-42.

Hunter DJ, Zhang Y, Niu J, Goggins J, Amin S, LaValley MP, Guermazi A, Genant H, Gale D, Felson DT. Increase in bone marrow lesions associated with cartilage loss: a longitudinal magnetic resonance imaging study of knee osteoarthritis. Arthritis Rheum 2006 54:1529-35.

Hunter DJ, Gerstenfeld L, Bishop G, Davis AD, Mason ZD, Einhorn TA, Maciewicz RA, Newham P, Foster M, Jackson S, Morgan EF. Bone marrow lesions from osteoarthritis knees are characterized by sclerotic bone that is less well mineralized. Arthritis Res Ther. 2009 11:R11.

Hunter DJ, Sharma L, Skaife T. Alignment and osteoarthritis of the knee. J Bone Joint Surg Am. 2009a 91 Suppl 1:85-9.

Imhof H, Breitenseher M, Kainberger F, Trattnig S. Degenerative joint disease: cartilage or vascular disease? Skeletal Radiol 1997 26:398-403.

Ivanovska N, Dimitrova P. Bone resorption and remodeling in murine collagenase-induced osteoarthritis after administration of glucosamine. Arthritis Res Ther. 2011 13:R44.

Ju Y, Hua J, Sakamoto K, Ogawa H, Nagaoka I. Modulation of TNF-alpha-induced endothelial cell activation by glucosamine, a naturally occurring amino monosaccharide. Int J Mol Med. 2008 22:809-15.

Kiaer T, Pedersen NW, Kristensen KD, Starklint H. Intra-osseous pressure and oxygen tension in avascular necrosis and osteoarthritis of the hip. J Bone Joint Surg Br. 1990 72:1023-30.

Kiefer FN, Neysari S, Humar R, Li W, Munk VC, Battegay EJ. Hypertension and angiogenesis. Curr Pharm Des 2003 9:1733-44.

Korompilias AV, Ortel TL, Urbaniak JR. Coagulation abnormalities in patients with hip osteonecrosis. Orthop Clin North Am 2004 35:265-71.

Kuliwaba JS, Findlay DM, Atkins GJ, Forwood MR, Fazzalari NL. Enhanced expression of osteocalcin mRNA in human osteoarthritic trabecular bone of the proximal femur is associated with decreased expression of interleukin-6 and interleukin-11 mRNA. J Bone Miner Res. 2000 15:332-41.

Kumagai K, Shirabe S, Miyata N, Murata M, Yamauchi A, Kataoka Y, Niwa M. Sodium pentosan polysulfate resulted in cartilage improvement in knee osteoarthritis--an open clinical trial. BMC Clin Pharmacol. 2010 10:7.

Kumarasinghe DD, Perilli E, Tsangari H, Truong L, Kuliwaba JS, Hopwood B, Atkins GJ, Fazzalari NL. Critical molecular regulators, histomorphometric indices and their correlations in the trabecular bone in primary hip osteoarthritis. Osteoarthritis Cartilage. 2010 18:1337-44.

Kwan Tat S, Lajeunesse D, Pelletier JP, Martel-Pelletier J. Targeting subchondral bone for treating osteoarthritis: what is the evidence? Best Pract Res Clin Rheumatol. 2010 24:51-70.

Largo R, Martínez-Calatrava MJ, Sánchez-Pernaute O, Marcos ME, Moreno-Rubio J, Aparicio C, Egido J, Herrero-Beaumont G. Effect of a high dose of glucosamine on

systemic and tissue inflammation in an experimental model of atherosclerosis aggravated by chronic arthritis. Am J Physiol Heart Circ Physiol. 2009 297:H268-76.

Lawrence JS Hypertension in relation to musculoskeletal disorders. Ann Rheum Dis 1975 34:451-56.

Lee JH, Dyke JP, Ballon D, Ciombor DM, Rosenwasser MP, Aaron RK. Subchondral fluid dynamics in a model of osteoarthritis: use of dynamic contrast-enhanced magnetic resonance imaging. Osteoarthritis Cartilage. 2009 17:1350-5.

Lucht U, Djurhuus JC, Sørensen S, Bünger C, Sneppen O The relationship between increasing intraarticular pressures and intraosseous pressures in the juxtaarticular bones. An experimental investigation in dogs. Acta Orthop Scand. 1981 52:491-5.

Lynch JA, Parimi N, Chaganti RK, Nevitt MC, Lane NE; Study of Osteoporotic Fractures Research Group. The association of proximal femoral shape and incident radiographic hip OA in elderly women. Osteoarthritis Cartilage. 2009 17:1313-8.

Macfarlane DG, Buckland-Wright JC, Lynch J, Fogelman I. A study of the early and late 99technetium scintigraphic images and their relationship to symptoms in osteoarthritis of the hands. Br J Rheumatol 1993 32:977-81.

Madry H, van Dijk CN, Mueller-Gerbl M. The basic science of the subchondral bone. Knee Surg Sports Traumatol Arthrosc. 2010 18:419-33.

Mandalia V, Fogg AJ, Chari R, Murray J, Beale A, Henson JH. Bone bruising of the knee.Clin Radiol 2005; 60:627-36.

Manicourt DH, Altman RD, Williams JM, Devogelaer JP, Druetz-Van Egeren A, Lenz ME, Pietryla D, Thonar EJ. Treatment with calcitonin suppresses the responses of bone, cartilage, and synovium in the early stages of canine experimental osteoarthritis and significantly reduces the severity of the cartilage lesions. Arthritis Rheum 1999 42:1159-67.

Martel-Pelletier J, Pelletier JP. Is osteoarthritis a disease involving only cartilage or other articular tissues? Eklem Hastalik Cerrahisi. 2010 21:2-14.

Mechlenburg I. Evaluation of Bernese periacetabular osteotomy: prospective studies examining projected load-bearing area, bone density, cartilage thickness and migration. Acta Orthop Suppl. 2008 79:4-43.

Moodie JP, Stok KS, Müller R, Vincent TL, Shefelbine SJ. Multimodal imaging demonstrates concomitant changes in bone and cartilage after destabilisation of the medial meniscus and increased joint laxity. Osteoarthritis Cartilage. 2011 19:163-70.

Muraoka T, Hagino H, Okano T, Enokida M, Teshima R. Role of subchondral bone in osteoarthritis development: a comparative study of two strains of guinea pigs with and without spontaneously occurring osteoarthritis. Arthritis Rheum. 2007 56:3366-74.

Noble BS, Peet N, Stevens HY, Brabbs A, Mosley JR, Reilly GC, Reeve J, Skerry TM, Lanyon LE. Mechanical loading: biphasic osteocyte survival and targeting of osteoclasts for bone destruction in rat cortical bone. Am J Physiol Cell Physiol. 2003 284:C934-43.

O'Keefe RJ, Teot LA, Singh D, Puzas JE, Rosier RN, Hicks DG. Osteoclasts constitutively express regulators of bone resorption: an immunohistochemical and in situ hybridization study. Lab Invest. 1997 76:457-65.

Pan J, Zhou X, Li W, Novotny JE, Doty SB, Wang L. In situ measurement of transport between subchondral bone and articular cartilage. J Orthop Res. 2009 27:1347-52.

Plenk H Jr, Hofmann S, Eschberger J, Gstettner M, Kramer J, Schneider W, Engel A. Histomorphology and bone morphometry of the bone marrow edema syndrome of the hip.Clin Orthop Relat Res 1997 334:73-84.

Radin EL, Swann DA, Paul IL, McGrath PJ. Factors influencing articular cartilage wear in vitro. Arthritis Rheum. 1982 25:974-80.

Ralston SH. Pathogenesis of Paget's disease of bone. Bone. 2008 43:819-25.

Roemer FW, Neogi T, Nevitt MC, Felson DT, Zhu Y, Zhang Y, Lynch JA, Javaid MK, Crema MD, Torner J, Lewis CE, Guermazi A. Subchondral bone marrow lesions are highly associated with, and predict subchondral bone attrition longitudinally: the MOST study. Osteoarthritis Cartilage. 2010 18:47-53.

Shen Y, Zhang ZM, Jiang SD, Jiang LS, Dai LY. Postmenopausal women with osteoarthritis and osteoporosis show different ultrastructural characteristics of trabecular bone of the femoral head. BMC Musculoskelet Disord. 2009 10:35.

Spector TD, MacGregor AJ. Risk factors for osteoarthritis: genetics. Osteoarthritis Cartilage. 2004 12 Suppl A:S39-44.

Steinbaum SR. The metabolic syndrome: an emerging health epidemic in women. Prog Cardiovasc Dis 2004 46:321-36.

Stok KS, Pelled G, Zilberman Y, Kallai I, Goldhahn J, Gazit D, Müller R. Revealing the interplay of bone and cartilage in osteoarthritis through multimodal imaging of murine joints. Bone. 2009 45:414-22.

Tanamas SK, Wluka AE, Pelletier JP, Martel-Pelletier J, Abram F, Wang Y, Cicuttini FM. The association between subchondral bone cysts and tibial cartilage volume and risk of joint replacement in people with knee osteoarthritis: a longitudinal study. Arthritis Res Ther. 2010 12:R58.

Tektonidou MG, Anapliotou M, Vlachoyiannopoulos P, Moutsopoulos HM. Presence of systemic autoimmune disorders in patients with autoimmune thyroid diseases. Ann Rheum Dis 2004 63:1159-61.

Truong LH, Kuliwaba JS, Tsangari H, Fazzalari NL. Differential gene expression of bone anabolic factors and trabecular bone architectural changes in the proximal femoral shaft of primary hip osteoarthritis patients. Arthritis Res Ther. 2006 8:R188.

Waarsing JH, Botter SM, Gabriëls S, Van der Pluijm I, Weinans H. The Life-Course of Femoral Shape in Mice. Transactions 2011a ORS meeting, http://www.ors.org/web/Transactions/57/0369.PDF

Waarsing JH, Kloppenburg M, Slagboom PE, Kroon HM, Houwing-Duistermaat JJ, Weinans H, Meulenbelt I. Osteoarthritis susceptibility genes influence the association between hip morphology and osteoarthritis. Arthritis Rheum. 2011b 63:1349-54.

Wang Y, Davies-Tuck ML, Wluka AE, Forbes A, English DR, Giles GG, O'Sullivan R, Cicuttini FM. Dietary fatty acid intake affects the risk of developing bone marrow lesions in healthy middle-aged adults without clinical knee osteoarthritis: a prospective cohort study. Arthritis Res Ther. 2009 11:R63.

Weinberger M, Tierney WM, Booher P. Common problems experienced by adults with osteoarthritis. Arthritis Care Res 1989; 2:94-100.

Zhai G, Blizzard L, Srikanth V, Ding C, Cooley H, Cicuttini F, Jones G. Correlates of knee pain in older adults: Tasmanian Older Adult Cohort Study. Arthritis Rheum 2006 55:264-71.

Zhang G, Qin L, Sheng H, Yeung KW, Yeung HY, Cheung WH, Griffith J, Chan CW, Lee KM, Leung KS. Epimedium-derived phytoestrogen exert beneficial effect on preventing steroid-associated osteonecrosis in rabbits with inhibition of both thrombosis and lipid-deposition. Bone. 2007 40:685-92.

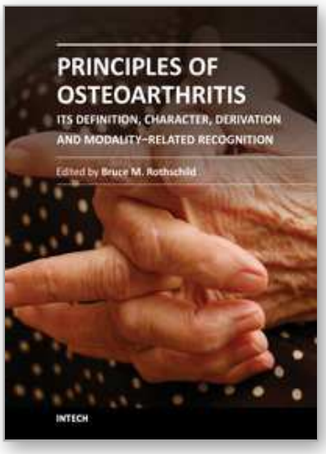

Principles of Osteoarthritis- Its Definition, Character, Derivation and Modality-Related Recognition
Edited by Dr. Bruce M. Rothschild

ISBN 978-953-51-0063-8
Hard cover, 590 pages
Publisher InTech
Published online 22, February, 2012
Published in print edition February, 2012

This volume addresses the nature of the most common form of arthritis in humans. If osteoarthritis is inevitable (only premature death prevents all of us from being afflicted), it seems essential to facilitate its recognition, prevention, options, and indications for treatment. Progress in understanding this disease has occurred with recognition that it is not simply a degenerative joint disease. Causative factors, such as joint malalignment, ligamentous abnormalities, overuse, and biomechanical and metabolic factors have been recognized as amenable to intervention; genetic factors, less so; with metabolic diseases, intermediate. Its diagnosis is based on recognition of overgrowth of bone at joint margins. This contrasts with overgrowth of bone at vertebral margins, which is not a symptomatic phenomenon and has been renamed spondylosis deformans. Osteoarthritis describes an abnormality of joints, but the severity does not necessarily produce pain. The patient and his/her symptoms need to be treated, not the x-ray.

How to reference
In order to correctly reference this scholarly work, feel free to copy and paste the following:

David M. Findlay (2012). Subchondral Bone in Osteoarthritis, Principles of Osteoarthritis- Its Definition, Character, Derivation and Modality-Related Recognition, Dr. Bruce M. Rothschild (Ed.), ISBN: 978-953-51-0063-8, InTech, Available from: http://www.intechopen.com/books/principles-of-osteoarthritis-its-definition-character-derivation-and-modality-related-recognition/subchondral-bone-in-osteoarthritis

INTECH
open science | open minds

InTech Europe
University Campus STeP Ri
Slavka Krautzeka 83/A
51000 Rijeka, Croatia
Phone: +385 (51) 770 447
Fax: +385 (51) 686 166
www.intechopen.com

InTech China
Unit 405, Office Block, Hotel Equatorial Shanghai
No.65, Yan An Road (West), Shanghai, 200040, China
中国上海市延安西路65号上海国际贵都大饭店办公楼405单元
Phone: +86-21-62489820
Fax: +86-21-62489821