

# We are IntechOpen, the world's leading publisher of Open Access books Built by scientists, for scientists

6,900

Open access books available

185,000

International authors and editors

200M

Downloads

Our authors are among the

154

Countries delivered to

TOP 1%

most cited scientists

12.2%

Contributors from top 500 universities



WEB OF SCIENCE™

Selection of our books indexed in the Book Citation Index  
in Web of Science™ Core Collection (BKCI)

Interested in publishing with us?  
Contact [book.department@intechopen.com](mailto:book.department@intechopen.com)

Numbers displayed above are based on latest data collected.  
For more information visit [www.intechopen.com](http://www.intechopen.com)



# Extracorporeal Membrane Oxygenation in the Transition of Emergent Thoracic Surgery

Shao-Jung Hsu and Kuang-Yao Yang

*Department of Chest Medicine, Taipei Veterans General Hospital,  
School of Medicine, National Yang-Ming University,  
Taiwan, Republic of China*

## 1. Introduction

Extracorporeal membrane oxygenation (ECMO) has been used more extensively since it became known as a potential bridge therapy, in patients with severe respiratory failure even under optimum conventional mechanical ventilator support, for further definite therapy. In the area of thoracic surgery, ECMO may have already become a useful life-saving tool but studies on this treatment method remain scarce. Currently available reports and case series reveal that patients with massive hemoptysis or critical tracheal stenosis may benefit from temporary ECMO therapy during the transition of emergent thoracic surgery.

## 2. ECMO

ECMO, also called extracorporeal life support, is a type of cardiopulmonary bypass. In May 1953, Gibbon (Gibbon, 1954) used artificial oxygenation and perfusion support for the first successful open heart surgery. Then it was first also effectively used in an adult patient with acute post-traumatic respiratory failure in 1972 (Hill et al., 1972). The following preliminary studies in 1970s suggested that ECMO could support oxygenation in patients with profound respiratory failure. Recently, the CESAR trial demonstrated that ECMO-based management can improve survival in patients with severe acute respiratory failure (Peek et al., 2009). As technological continues to advance, increasing indications and reports suggest that ECMO has a role to play in the transition of emergent thoracic surgery (Hsu et al., 2011).

There are two types of ECMO: venous-arterial (VA) and venous-venous (VV) ECMO. VV ECMO supports isolated oxygenation failure, whereas VA ECMO provides hemodynamic and respiratory support. Although VA ECMO applies cardiopulmonary bypass, it has more complications due to the alteration of hemodynamic system. As a result, VV ECMO is typically used for respiratory failure while VA ECMO is used for cardiac failure.

### 2.1 Initiation of ECMO

ECMO is composed of a pump, an oxygenator and a heat exchanger. Once cannulation established, a large volume of blood is extracted from vessels by the mechanical pump. It

passes through the oxygenator and heat exchanger. The oxygenated blood is then finally re-infused into the vessels. A complete circuit can be established in 40 minutes by an experience team. In VV ECMO, blood is drawn distally into the right atrium and returned into right atrium in an attempt to minimize recirculation. To achieve this, a drainage cannula is inserted in the right common femoral vein and the other infusion cannula is inserted in the right internal jugular vein. The tip of each cannula should be placed near the junction of the vena cava and the right atrium (fig. 1A). Alternatively, a double lumen cannula can be placed in one major vein (fig. 1B).

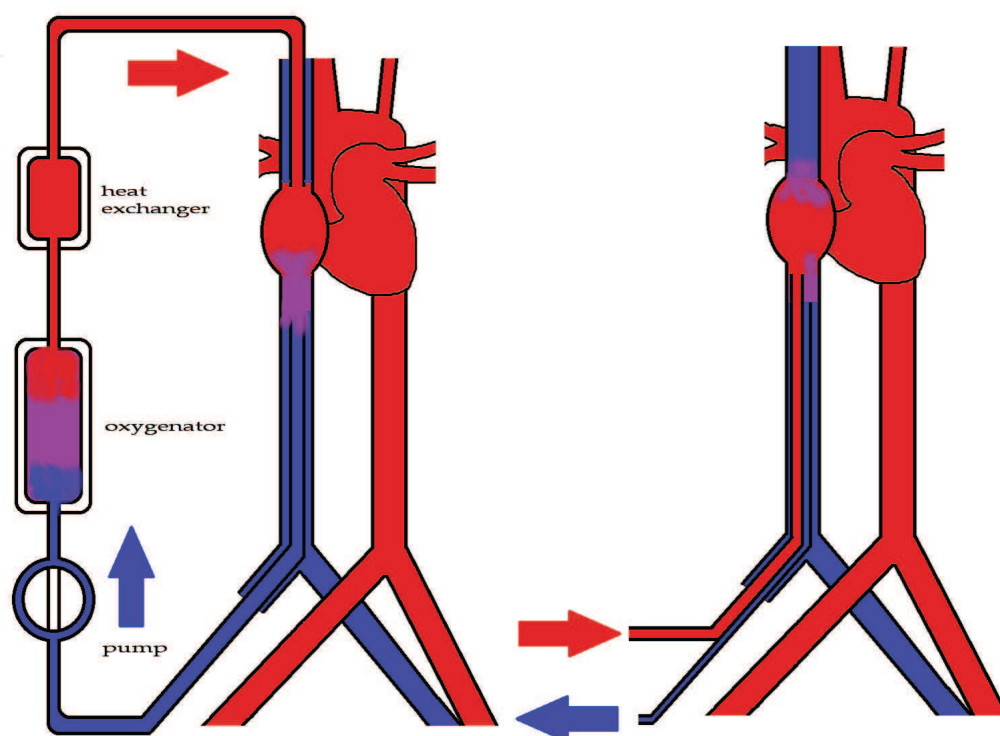


Fig. 1. A: Cannulation of VV ECMO through the femoral vein and jugular vein.  
B: Alternative cannulation with a double lumen cannula through one major vein.

In VA ECMO, blood is drawn from the common femoral vein and returned into the femoral artery (fig. 2A). Venous blood is oxygenated and pumped back into arterial circulation. As a result, both the heart and lungs are bypassed. The main concern in femoral artery cannulation is hypoxia of the ipsilateral leg. On the other hand, if native heart function was present, the oxygenated blood may not reach the proximal aorta and this would result in hypoxia of the heart and upper body. Alternatively, carotid artery cannulation could be performed (fig. 2B). But the risk of watershed cerebral infarction increases when utilizing this method. Because ECMO draw a large volume of blood from vessels, the circuit should be primed with fluid. In most cases, the circuit is re-circulated with normal saline, heparin and crystalloid first. A typical regimen is normal saline 2000ml with heparin 2000units/liter. Once ECMO activated, packed red blood cells are transfused to compensate for the diluting effects of the priming fluid. There is no consensus about the total amount of units that should be transfused. This depends on the volume of the circuit, the perfusion status of patients and the underlying disease. Typically, the goal is to make the hematocrit more than 30% and the mean arterial pressure more than 65mmHg.

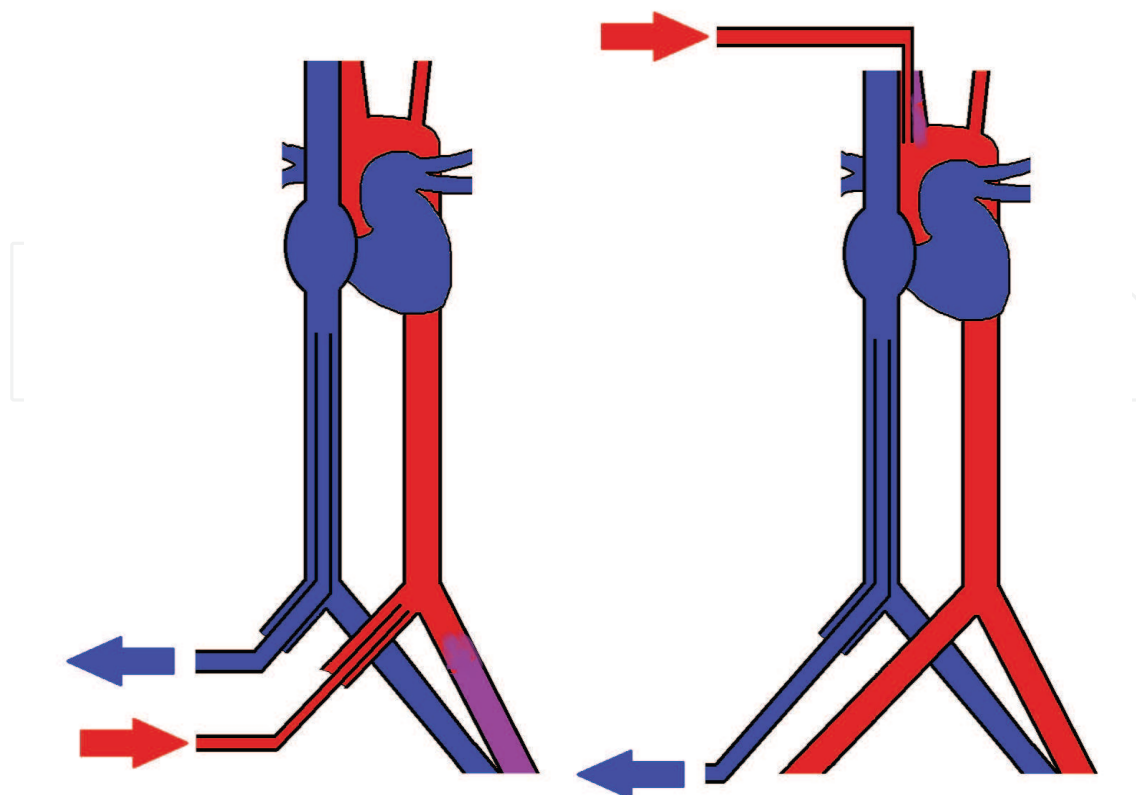


Fig. 2. A: Cannulation of VA ECMO through the femoral vein and artery. B: Cannulation through the femoral vein and carotid artery. Each path has its own unique risks with regards to complications.

## 2.2 Maintenance of ECMO

During the extracorporeal circulation, thrombosis may occur in the circuit and induce an embolism because of blood surface interaction. As a result, anticoagulation with a continuous infusion of unfractionated heparin is mandatory. The anticoagulant is monitored by activated clotting time (ACT). In general, ACT should be titrated to 210 to 230 seconds. The target should be decreased if the patients have a tendency towards bleeding. Platelets are continuously consumed because of the exposure to the foreign surface and the sheer force. As a result, platelet counts should also be monitored frequently. Sedation is definitely needed during ECMO. Adequate sedation can decrease the anxiety and suffering of patients and put the cardiopulmonary system at rest. The common agents for sedation in ICU are a continuous infusion of midazolam or propofol. Muscle relaxants could be added as well if the patients cannot tolerate use of mechanical ventilators well. Regardless, ECMO should only be utilized when patients are adequately sedated.

## 2.3 Complications

ECMO alters hemodynamic stability and induces a large amount of blood run in a device out of body. As a result, complications including localized tissues ischemia and hemostatic instability may occur. The VA ECMO also changes the direction of blood flow which may cause more complications than VV ECMO.

### 2.3.1 Complications in VV and VA ECMO

Bleeding tendency is usually increased and profound bleeding may even become life-threatening. The occurrence rate of bleeding ranges from 7-34%. The contributing factors are due to the mandatory continuous infusion of unfractionated heparin, platelet consumption and sometimes the underline diseases such as massive hemoptysis and sepsis-related DIC. Effective management depends upon the sites and the causes of bleeding. For example, if the bleeding source is mucosa or gastrointestinal tract, medical management including correcting thrombocytopenia and transfusing with fresh frozen plasma may be necessary. If the bleeding persists or develops into profound bleeding, unfractionated heparin infusion must be withheld temporarily. After the bleeding stops, heparin should be added once again but the target ACT could be adjusted. On the other hand, bleeding from the surgical or device-insertion wounds, including ECMO cannulation site, often requires surgical intervention. This ranges from bedside electrocautery to surgical exploration to achieve bleeding stoppage.

Thrombosis occurs at a rate of 8-17% and heparinization may help to reduce the incidence rate, but could also increase the potential for bleeding events. The balance between homeostasis and thrombosis require frequent clinical and laboratory monitoring. The pressure gradient across the oxygenator is a useful tool to be monitored, and a sudden change in the gradient may suggest a thrombus formation.

Bleeding from a cannulated site is not uncommon. Vascular perforation and arterial dissection may occur during the placement of the cannula. Thus, the utilization of an experienced surgeon is quite important to avoid such complications.

### 2.3.2 Complications only in VA ECMO

In VA ECMO, oxygenated blood is infused into carotid artery or femoral artery, which forms a countercurrent to native blood flow from the left ventricle. As a result, the increased afterload may worsen the cardiac output of the left ventricle. This results in left ventricle distension, acute pulmonary hypertension and then even pulmonary hemorrhage.

If the infusion cannula is placed in the femoral artery, not only the direction of blood flow of left ventricle, but also the blood flow of aorta is changed. Blood stasis in the aorta is induced if we are not able to maintain left ventricle output. Consequently, aorta thrombosis may develop.

In this type of situation, blood flow from ECMO supplies lower extremities and visceral organs, where as the brain, heart and upper extremities are supplied by the heart itself. It is obvious that the oxygen saturation from the blood vessels supplied by ECMO is much higher than that by heart. Under this type of condition, cerebral and cardiac hypoxia may occur without being recognized if saturation is only monitored by blood sampling from the lower extremities. As a result, monitoring blood saturation during VA ECMO only by digital oxymetry or single arterial line should be avoided.

### 2.4 Pumpless extracorporeal lung-assisted (pECLA) device

Pumpless extracorporeal lung-assisted device, a novel type of ECMO, had been developed in recent 10 years. In 1967, Rashkind and colleagues first proposed the concept of pECLA (Rashkind et al. 1967). In recent years, the commercialized devices are available and become more and more popular in intensive care unit (Walles, 2007).

During setting up, the blood was drawn from the common femoral artery and sent back to the femoral vein. The pressure gradient driving blood flow in the device was supplied by heart pumping. As a result, pECLA does not need a centrifugal or roller pump. In this way, it could be set more easily with lower cost and lower dose of heparin than conventional ECMO. However, the device was built to remove carbon dioxide in patient with acute respiratory distress syndrome under lung protective ventilation strategy. Since the blood was drawn from the artery, the oxygenated ability of pECLA was not superior to conventional ECMO. In the management of massive hemoptysis or critical tracheal stenosis, the main problem encountered was hypoxemic respiratory failure, but not hypercapnia. As a result, the application of pECLA in these patients may need more strictly selection.

In summary, ECMO is a powerful therapeutic tool since it can replace the function of the heart and lungs. However, it has several potential complications and their risks increase as the duration of ECMO is prolonged. As a result, it can only serve as a salvage tool in life-threatening conditions and as a bridge to the definite therapy. There are two types of ECMO, the VA type and the VV type. Although VA type can supply perfusion pressure, it obviously has more complications than the VV type. In the field of emergent thoracic surgery, which we will introduce in the following sections, the cardiac function is usually preservative. As a result, VV type ECMO is the first choice in emergent thoracic surgery.

In thoracic surgery, there are 2 conditions, massive hemoptysis and major airway obstruction, where oxygenation is difficult to maintain. Under these conditions, if oxygenation could not be maintained by optimized mechanical ventilation or if the risk of life-threatening hypoxemia is very high, ECMO should be considered.

### **3. Massive hemoptysis**

Massive hemoptysis is an important and potentially fatal event. It has been variably defined as an expectoration of blood amount ranging from 100-1000 ml in 24 hours (Dweik & Stoller, 1999). Since 200 ml of blood could fulfill the anatomical dead space of a major airway and 400 ml of blood might impede the oxygen exchange of alveolar space, massive hemoptysis can be defined as the expectorated blood volume that induces a life-threatening condition by virtue of airway obstruction or severe blood loss (Garzon et al., 1982).

#### **3.1 Conventional management of massive hemoptysis**

In the management of massive hemoptysis, protection of the non-bleeding lung and maintenance of adequate oxygen saturation are the major priorities. Then, the second step is to identify the source of the bleeding. The final step is the definite and specific treatment to prevent recurrent bleeding. Among the 3 steps, lung protection and maintenance of oxygenation are the most critical and could determine the outcome of patients. There are five methods for lung protection if the patient has continuous bleeding: decubitus position, selective intubation, double lumen intubation, Fogarty catheter placement and bronchoscope balloon tamponade (Lordan et al., 2003).

At first, an attempt should be made to identify the bleeding side of the lung. After that, the patient should be laid with the bleeding side down to isolate the bleeding lung and ventilate



the normal lung. Single lung intubation could be performed if the amount of blood is too great (Gourin & Garzon, 1975). For right side bleeding, the bronchoscope could be placed in the left main bronchus and the endotracheal tube could be inserted in the left lung under the guidance of bronchoscope. For left side bleeding, the endotracheal tube could be placed in the right main bronchus simply by “pushing deeper”; however, this procedure has the risk of occluding the right upper lobe bronchus.

Double lumen endotracheal tube is an alternative method for lung isolation. However, it has four major disadvantages and is not routinely performed in ICU. First, it is difficult for a physician to decide whether double lumen tube should be inserted if the patient only has mild hemoptysis at presentation. Second, it is difficult for an operator to insert a double lumen catheter if the patient was under a hypoxemic status with large amount of blood in the trachea and pharynx. Third, an experienced operator is mandated to avoid the serious result of mal positioning, especially during the transference of patients from ICU to an angiography room. The last disadvantage is that there are still not enough trials to definitively demonstrate whether the double lumen catheter procedure is effective.

Fogarty catheter and bronchoscope balloon tamponade can be applied for lung isolation. A Fogarty catheter (14Fr/100cm length) can be placed over the bleeding bronchus under the guidance of bronchoscope. After inflated, the blood could be restricted in the bleeding side. Bronchoscope balloon tamponade may be more selective in restricting the blood. A 4-7 Fr balloon catheter is passed through the working channel of the bronchoscope and inflated to isolate the lung. However, both interventions need the guidance of bronchoscope. If the patient has massive bleeding, the large amount of blood in the trachea will impede the placement of a balloon catheter.

### **3.2 ECMO in massive hemoptysis**

Several methods for lung isolation have been developed. Their aim is basically the same: to ventilate the good lung and to maintain adequate oxygenation. As a result, if a physician is able to establish a route for oxygenation without depending on inadequate ventilation support, the definite therapy could be applied more safely, even if we fail to protect the good lung. ECMO has such characteristics and might be useful in certain circumstances.

If the patient had “abrupt desaturation”, ECMO can be implemented in 40 minutes by an experienced team. VV ECMO is the first choice, since most patients with massive hemoptysis are threatened by desaturation, rather than hypotension and shock. ECMO can be used as a bridge therapy for the definite treatment, such as angiography embolization and surgery.

Comprehensive review for ECMO use in life-threatening hemoptysis is lacking, and there are still no studies in the related literature on this topic. Since no original study has been published, the experience in application of ECMO in certain patients is largely based on case reports and case series. As early as in 1974, Hanson and colleague reported the first case with pulmonary hemorrhage rescued by ECMO (Hanson et al., 1974). However, not until the 1990s was there was a study or report about the use of ECMO in certain situations. There may be two reasons for this lack of reporting. The first, there is still the argument about the benefit of ECMO in an adult population at that era. And the second, heparinization during

Author, year (list in reference)	Underlie disease	Duration (days)	ACT (seconds)	Note
Hernandez et al., 2002	Wegener’s granuloma	9	150	Pediatric
Kolovos et al., 2002	Autoimmune disease or sepsis	4.9	160-180	Pediatric, Case No. 8
Ahmed et al., 2004	ANCA vasculitis	12	Full anticoagulation since day 3	
Fujita et al., 2005	Fulminant hepatitis s/p liver transplant	4	N/ A	
Agarwal et al., 2005	Microscopic polyangitis	7	160-180	
Arokianathana et al., 2005	Leptospirosis	7	N/ A	
Sun et al., 2006	Idiopathic Pulmonary Hemosiderosis	5	170-200	
Zhong et al., 2008	Microscopic polyangitis	12	120-200	

Table 1. The application of ECMO in the 8 reported cases of diffuse alveolar hemorrhage.

ECMO may precipitate further lung hemorrhage. In 2002, Kolovos and colleague reported the largest series and again raised the profile of reconsidering the role of ECMO in severe hemoptysis and pulmonary hemorrhage (Kolovos et al., 2002). They reported 8 children, aged 2 months to 18 years, with pulmonary hemorrhage due to sepsis or autoimmune disease received ECMO as the final therapeutic method because of severe respiratory failure. The eight children exhibited varying degrees of coagulopathy but still received heparinization. The ACT was controlled between 160 to 180 seconds. There was no profound hemorrhage after they received ECMO and all of them were weaned from ECMO successfully after pulmonary hemorrhage was controlled. After that report, although bleeding tendency was still thought to be a relative contraindication for ECMO, it seems that some patients with severe pulmonary hemorrhage could be rescued by ECMO use.

As mentioned above, studies and reports in the related literature in this field are still scarce. To the best of our knowledge, there are only 13 reports about the application of ECMO in massive hemoptysis; 8 of them had diffused alveolar hemorrhage (DAH) (Table 1). In DAH, the use of ECMO has a stronger indication because there is no effective lung protective strategy. The patients in these reports were on ECMO support for 4 to 12 days. Heparin was used at a lower dosage to keep ACT around 120 to 200 seconds, instead of 210 to 230 seconds. Alternatively, delaying the application of heparin seems to be a safe method. All of the patients in these case reports were successfully weaned from ECMO after the underlying causes of severe hemoptysis were under control.

There are 5 reports about the use of ECMO in localized lung hemorrhage (Table 2). In 2 of them, the patients encountered abrupt desaturation during the procedure (bronchial artery embolization and operation), and lung protective therapy was difficult under that condition. Yuan et al. reported a patient with massive hemoptysis due to trauma and a double lumen endotracheal tube was intubated at the ER. However, the patient's clinical condition deteriorated and ECMO was used as a rescue method. In our experience, we have reported a case with bronchiectasis and massive hemoptysis (Hsu et al. 2011). The patient presented



with acute respiratory failure due to a rapid progression of severe hemoptysis. A total of 4000 ml of packed red blood cells was transfused within 24 h to keep the hemoglobin level at around 10 mg/dl. The ventilator setting was in the volume control mode, at a positive end-expiratory pressure of 15 cm H<sub>2</sub>O, and a FiO<sub>2</sub> of 100%; however, these setting only could maintain the arterial blood gas at a PaO<sub>2</sub> of 62 mmHg. ECMO was applied due to high risk of transferring the patient from the intensive care unit to the angiography room and in-procedure mortality. After bronchial artery embolization successfully, ECMO was weaned 1 day later. No heparinization was performed because of the short term application of ECMO. The patient received left lower lobe lobectomy 2 weeks later due to intermittent small amount of hemoptysis. After the surgery, hemoptysis did not recur. He was discharged in ambulatory condition without any oxygen therapy.

Author, year (list in reference)	Underlie disease	Duration (days)	ACT (seconds)	Note
Fukui et al., 2006	Pulmonary hypertension	12	40-50 since day 3	
Bianchini et al., 2007	Swan-Ganz related trauma	2.5	N/A	During operation
Bedard et al., 2008	Aorto-pulmonary fistula	N/A	N/A	During bronchial arterial embolization
Yuan et al., 2008	Double lumen related trauma	10	60-80	
Hsu et al., 2011	Bronchiectasis	1	No heparin	

Table 2. The application of ECMO in the 4 reported cases of localized lung hemorrhage.

The use of ECMO in massive hemoptysis may be beneficial for certain populations. However, there are still a number of debates about the use of ECMO, since available data is not sufficient in this field. First, setting up ECMO is an invasive procedure, and physicians may not maximize the “conventional therapy” before initiating ECMO. Second, heparinization is usually necessary in ECMO, but it may produce a more severe hemorrhage. Third, ECMO itself may bring about some complications, such as platelet consumption, bleeding and/or thromboembolism.

In summary, maintenance of oxygenation is the most important object in the management of massive hemoptysis. ECMO should be used if all other methods fail or cannot be performed to maintain adequate oxygenation. However, there is still some uncertainty that needs to be addressed, such as the selection criteria of patients and the method of heparinization. Based on currently available evidence, the use of ECMO as a bridge tool for life-threatening hemoptysis can allow a patient to undergo definite therapy more safely.

4. Critical tracheal stenosis

Critical tracheal stenosis can be caused by either malignant or benign lesion. The symptoms may develop abruptly or slowly. In a chronic disease, such as malignancy, chronic inflammatory disease or collagen vascular disease, patients present with progressive dyspnea and stridor. While in acute conditions, such as blunt or penetrating neck trauma, patients may suffer from life-threatening asphyxia. The nature and severity of symptoms depends on the location and the magnitude of the lesion.

#### 4.1 Conventional management of critical tracheal stenosis

Most patients with tracheal stenosis present with chronic symptoms. However, a 50% reduction in the cross-sectional area of the trachea usually results in dyspnea on exertion, whereas a 75% reduction in the cross-sectional area produces dyspnea and stridor at rest. This means that when these symptoms develop, the airway has been severely compromised with impending life-threatening obstruction (Wood, 2002). The patient may be compensated for airway obstruction, but even a small amount of secretion can be lethal. As a result, the strategies of management are different according to the time point of diagnosis.

If the tracheal stenosis is diagnosed early, physicians have enough time to make a complete study. The treatment options include surgical resection, reconstruction, therapeutic bronchoscopy with ablation and airway-stent placement. Before the management takes place, a secure airway could be performed utilizing an efficient method. The fiberoptic bronchoscope (FOB) provides a safe and effective way for airway control (Ovassapian, 2001). With FOB, the lesion could be evaluated vividly and the residual lumen of airway could be estimated. After that, the largest endotracheal tube (ETT) that can pass the lumen should be chosen, since the airway pressure is inversely proportional to the inner diameter of the ETT. To avoid trauma to the airway or the trachea lesion, the ideal size of FOB is 1mm smaller than the internal diameter of ETT. The ideal-sized FOB should be used if available. After determining the size of ETT and FOB, intubation could be performed by experienced anaesthesiologist.

If critical airway stenosis has developed, management will then become more difficult. The position of stenosis is important in this circumstance. For upper airway stenosis, FOB - assisted intubation or emergent tracheotomy can stabilize the airway. For severe mid-level tracheal stenosis, intubation above the stenotic portion can be performed first. After positive pressure ventilation, the residual lumen will be mildly dilated. Then a smaller tracheal tube is placed under the assistance of FOB through trachea or directly placed into main bronchus by the surgeon during surgery.

However, sometimes endotracheal intubation may be impossible, and even dangerous, possibly leading to complete airway obstruction. For most patients, emergent tracheotomy is ineffective because it cannot bypass the obstructive lesion. FOB may precipitate cough, bleeding or further mucosal edema and worsen the obstruction. There are only few choices for patients with this type of life-threatening major airway obstruction. One way is place the patient in a quiet room with very mild sedation and cool humidified oxygen. Nebulized epinephrine and dexamethasone help decrease the contraction and edema of the airway. It may temporary attenuate the symptoms and facilitate subsequent procedure, and FOB - assisted intubation.

#### 4.2 ECMO in critical tracheal stenosis

In patients with critical tracheal stenosis, the key to saving their lives is to maintain safe and efficient gas exchange. However, conventional anesthetic technique has a high risk of causing airway total occlusion, and the risk is inversely proportional to the residual lumen of the airway. As a result, if intubation is performed under a "back up" system, that can maintain adequate oxygenation even under total airway occlusion, it becomes safer for patients and less challenging to anaesthesiologists. Thus, ECMO serves as an ideal tool in this situation.

In paediatric surgery, an increasing number of reports and small-scale patient studies have pointed out that ECMO, either elective or emergent, serves as a good-bridge tool for trachea reconstruction. In neonates with congenital trachea anomalies, ECMO reduces the risk of surgery to allow more precise and unrushed airway reconstruction (Huang et al., 2007)(Kunisaki et al., 2008). Elective ECMO uses in postoperative period also contribute to improve patients’ outcome (Connonlly & McGuirt, 2001).

However, in the field of adults with critical trachea stenosis, we remain in the “case report era.” In 1999, Onozawa and colleagues first reported a case with critical airway obstruction due to thyroid cancer. The diameter of residual lumen of trachea was only 5mm. VA ECMO was applied before induction and the surgery was performed smoothly. After the partial resection of the thyroid tumor and the insertion of tracheostomy, ECMO was decannulated successfully. Following that, there are total 7 case reports with 9 adult patients involving the application of ECMO during critical tracheal stenosis surgery (table 3). These physicians attempted to intubate the patients reported but failed in two of them. One of them even experienced hypoxia cardiac arrest. Emergent ECMO was activated and this saved the patient’s life. Among them, the variable etiologies ranged from benign to malignant origin. The residual lumens of trachea are between 1mm to 5mm. The locations of trachea lesion distribute from 1.5cm above carina to upper level of trachea. VA ECMO was first used and more recently VV ECMO has been applied in cases of critical tracheal stenosis. Both types of ECMO can supply adequate oxygenation for performing the definite therapy.

Author, year (list in reference)	Underlie disease	Diameter & position of residual lumen	Ecmo type	Note
Onozawa et al., 1999	thyroid tumor	5mm	VA ECMO	
Kurokawa et al., 2000	tracheolysis	3mm	VV ECMO	
Chen et al., 2004	neurofibroma	more than 5.5mm, 5cm above carina	N/A	ETT, ECMO stand by only
Zhou et al., 2007	Post intubation trachea stenosis	2-3mm, 1.5cm above carina	VA ECMO	ETT but failure, emergent ECMO
	Leiomyoma	1mm, 6cm below vocal cords	VA ECMO	
Jeon et al., 2009	Thyroid tumor	N/ A (3x4 cm)	VV ECMO	
Smith et al., 2009	Papilloma	N/ A ( 2.5x2.8 cm), 2.5cm above carina	VV ECMO	
	Papilloma	N/ A, extend 2 cm below vocal cords to just above carina	VV ECMO	Bronchoscope ETT related hypoxic cardiac arrest
Shao et al., 2009	Bilateral nodular goiter	5mm,	VA ECMO	

Table 3. The application of ECMO in critical airway stenosis during surgery

In summary, although there is still no original study published in this field, the related case reports have provided useful information. If the residual lumen of trachea is less than 5mm or the ETT cannot pass the lesion, a “stand by” ECMO should be considered before anaesthesia induction. VV ECMO is preferred since it can maintain adequate oxygenation with fewer complications.

And finally, it is worth noting that the criteria for patient selection still needs further investigation to demonstrate the benefits of ECMO as a bridge therapy in critical trachea stenosis. The cost-effectiveness of this method is also worthy of further investigation. Before a definitive conclusion can be made, ECMO should be kept in mind as one option for clinical physicians when handling a patient with critical tracheal stenosis.

## 5. Conclusion

During the transition of emergent thoracic surgery, the most important objective is to maintain vital signs, ensuring that they are stable. However, in cases of massive hemoptysis and critical airway stenosis, it remains difficult for physicians to achieve adequate oxygenation since these conditions share the same challenge: difficult airway maintenance. In this field, ECMO serves as the rationale option if conventional therapy cannot achieve adequate oxygenation. Due to the lack of an original study, the role of ECMO in the transition of emergent thoracic surgery still deserves further investigation regarding its utilization and cost-effectiveness. Based on the current evidence available, ECMO could make the transition of emergent thoracic surgery safer.

## 6. References

- Ahmed, SH. et al. (2004). Use of extracorporeal membrane oxygenation in a patient with diffuse alveolar hemorrhage. *CHEST*, No.126, Vol.1, (July 2004), pp. 305–309, ISSN 0012-3692.
- Arokianathana, D. et al. (2005). Leptospirosis: a case report of a patient with pulmonary haemorrhage successfully managed with extra corporeal membrane oxygenation. *The Journal of Infection*, Vol.50, No.2, (February 2005), pp. 158-162, ISSN 0163-4453.
- Agarwal, HS. et al. (2005). Extra corporeal membrane oxygenation and plasmapheresis for pulmonary hemorrhage in microscopic polyangiitis. *Pediatric Nephrology*, Vol. 20, No.4, (April 2005), pp. 526-528, ISSN 0931-041X.
- Bedard, E. et al. (2008). Life-threatening hemoptysis following the Fontan procedure. *The Canadian Journal of Cardiology*, Vol.24, No.2, (February 2008), pp. 145-147, ISSN 0828-282X.
- Bianchini, R. et al. (2007). Extracorporeal membrane oxygenation for Swan-Ganz induced intraoperative hemorrhage. *Ann Annals of Thorac Surgery*, Vol.83, No.6, (Jun 2007), pp. 2213– 2214, ISSN 0003-4975.
- Chen, PT. et al. (2004). Anesthetic management of a patient undergoing segmental resection of trachea with an endotracheal neurofibroma and nearly total occlusion of trachea. *Acta Anaesthesiology Taiwanica*, Vol.42, No.4, (December 2004), pp. 233-236, ISSN 1875-4597.

- Connolly, KM. & McGuirt, WF Jr. (2001). Elective extracorporeal membrane oxygenation: an improved perioperative technique in the treatment of tracheal obstruction. *The Annals of Otolaryngology, Rhinology and Laryngology*, Vol.110, No.3, (March 2001), pp. 205-209, ISSN 0003-4894.
- Dweik, RA. & Stoller, JK. (1999). Role of bronchoscopy in massive hemoptysis. *Clinics in Chest Medicine*, Vol.20, No.1, (March 1999), pp. 89-105, ISSN 0272-5231
- Fujita, S. et al. (2005). Expanded efficacy and indication of extracorporeal membrane oxygenation for preoperative pulmonary bleeding on pediatric cadaveric orthotopic liver transplantation. *Transplantation*, Vol.79, No.11, (June 2005), pp. 1637, ISSN 0041-1337.
- Fukui, S. et al. (2006). Recovery from hemorrhagic pulmonary damage by combined use of a left ventricular assist system and right ventricular assist system and extracorporeal membrane oxygenation. *The Journal of Heart and Lung Transplantation*, Vol.25, No.2, (February 2006), pp. 248-250, ISSN 1053-2498.
- Garzon AA.; Cerruti MM. & Golding ME. (1982). Exsanguinating hemoptysis. *The journal of Thoracic and Cardiovascular Surgery*, Vol.84, No.6, (December 1982), pp. 829-833, ISSN 0022-5223.
- Gibbon, JH. Jr. (1954). Application of a mechanical heart and lung apparatus to cardiac surgery. *Minnesota Medicine*, Vol.37, No.3, (March 1954), pp. 171-178, ISSN 0026-556X.
- Gourin, A. & Garzon, AA. (1975). Control of hemorrhage in emergency pulmonary resection for massive hemoptysis. *Chest*, Vol.68, No.1, (July 1975), pp. 120-121, ISSN 0012-3692.
- Hanson, EL. et al. (1974). Venoarterial bypass with a membrane oxygenator: Successful respiratory support in a woman following pulmonary hemorrhage secondary to renal failure. *Surgery*, Vol.75, No.4 (April 1974), pp. 557-565, ISSN 0039-6060.
- Hernandez, ME. et al. (2002). Acute onset of Wegener's granulomatosis and diffuse alveolar hemorrhage treated successfully by extracorporeal membrane oxygenation. *Pediatric Critical Care Medicine*, Vol.3, No.1, (January 2002), pp. 63-66, ISSN 1529-7535.
- Hill, JD. et al. (1972). Prolonged extracorporeal oxygenation for acute post-traumatic respiratory failure (shock-lung syndrome). Use of the Bramson membrane lung. *The New England Journal of Medicine*, Vol.286, No.12, (March 1972), pp. 629-634, ISSN 0028-4793.
- Hsu, SJ. et al. (2011). Life-threatening hemoptysis due to left inferior phrenic artery to pulmonary artery fistula rescued by extracorporeal membrane oxygenation therapy. *Interactive Cardiovascular and Thoracic Surgery*, Vol.12, No.2, (February 2011), pp. 337-338, ISSN 1569-9293.
- Huang, SC. et al. (2007). Perioperative extracorporeal membrane oxygenation support for critical pediatric airway surgery. *European Journals of Pediatrics*, Vol.166, No.11, (November 2007), pp. 1129-1133, ISSN 0340-6199.
- Jeon, HK. et al. (2009). Extracorporeal oxygenation support for curative surgery in a patient with papillary thyroid carcinoma invading the trachea. *The Journal of Laryngology and Otolaryngology*, Vol.123, No.7, (July 2009), pp. 807-810, ISSN 0022-2151.




- Kolovos, NS. et al. (2002). Extracorporeal life support for pulmonary hemorrhage in children: A case series. *Critical Care Medicine*, Vol.30, No.3, (March 2002), pp. 577-580, ISSN 0090-3493.
- Kunisaki, SM. et al. (2008). Extracorporeal membrane oxygenation as a bridge to definitive tracheal reconstruction in neonates. *Journal of Pediatric Surgery*, Vol.43, No. 5, (May 2008), pp. 800-804, ISSN 0022-3468.
- Kurokawa, S. et al. (2000). Anesthetic management using extracorporeal circulation of a patient with severe tracheal stenosis by thyroid cancer. *The Japanese journal of anesthesiology*, Vol.49, No.11, (November 2000), pp. 1242-1246, ISSN 0021-4892.
- Lordan, JL.; Gascoigne, A. & Corris, PA. (2003). The pulmonary physician in critical care \* Illustrative case 7: Assessment and management of massive haemoptysis. *Thorax*, Vol. 58, No.9, (September 2003), pp. 814-819, ISSN 0040-6376.
- Onozawa, H. et al. (1999). Anesthetic management using extracorporeal circulation of a patient with severe tracheal stenosis by thyroid cancer. *The Japanese journal of anesthesiology*, Vol.48, No.6, (June 1999), pp. 658-661, ISSN 0021-4892
- Ovassapian, A. (2001). The flexible bronchoscope. A tool for anesthesiologists. *Clinics in Chest Medicine*, Vol.22, No.2, (June 2001), pp. 281-299, ISSN 0272-5231.
- Peek, GJ. et al. (2009). Efficacy and economic assessment of conventional ventilatory support versus extracorporeal membrane oxygenation for severe adult respiratory failure (CESAR): a multicentre randomised controlled trial. *Lancet*, Vol.374, No.9698, (October 2009), pp. 1351-1363, ISSN 0140-6736.
- Rashkind, WJ. et al. (1967). Hemodynamic effects of arteriovenous oxygenation with a small-volume artificial extracorporeal lung. *The Journal of Pediatrics*, Vol.70, No.2, (March 1967), pp. 425-429, ISSN 0022-3476
- Shao, Y. et al. (2009). Extracorporeal membrane oxygenation-assisted resection of goiter causing severe extrinsic airway compression. *The Annals of Thoracic Surgery*, Vol.88, No.2, (August 2009), pp. 659-661, ISSN 0003-4975.
- Smith, IJ. et al. (2009). Use of extracorporeal membrane oxygenation during resection of tracheal papillomatosis. *Anesthesiology*, Vol.110, No.2, (February 2009), pp.427-429, ISSN 0003-3022.
- Sun, LC. et al. (2006). Extracorporeal membrane oxygenation to rescue profound pulmonary hemorrhage due to idiopathic pulmonary hemosiderosis in a child. *Pediatric Pulmonology*, Vol.41, No.9, (September 2006), pp.900-903, ISSN 8755-6863.
- Walles, T. (2007). Clinical experience with the iLA Membrane Ventilator pumpless extracorporeal lung-assist device. *Expert Review of Medical Device*, Vol.4, No.3, (May 2007), pp. 297-305, ISSN 1743-4440
- Wood, DE. (2002). Management of malignant tracheobronchial obstruction. *The Surgical Clinics of North America*, Vol.82, No.3, (June 2002), pp. 621-642, ISSN 0039-6109.
- Yuan, KC. et al. (2008). Treatment of endobronchial hemorrhage after blunt chest trauma with extracorporeal membrane oxygenation. *The Journal of Trauma*, Vol.65, No.5, (November 2008), pp. 1151-1154, ISSN 0022-5282.
- Zhong, H. et al. (2008). Extracorporeal membrane oxygenation for pulmonary hemorrhage in microscopic polyangiitis. *Chinese Medical Journal*, Vol.121, No.24, (December 2008), pp. 2622-2623, ISSN 0366-6999.

Zhou, YF. Et al. (2007). Anesthetic management of emergent critical tracheal stenosis. *Journal of Zhejiang University. Science. B.*, Vol.8, No.7, (July 2007), pp. 522-525, ISSN 1673-1581.

IntechOpen

IntechOpen



### **Topics in Thoracic Surgery**

Edited by Prof. Paulo Cardoso

ISBN 978-953-51-0010-2

Hard cover, 486 pages

**Publisher** InTech

**Published online** 15, February, 2012

**Published in print edition** February, 2012

Thoracic Surgery congregates topics and articles from many renowned authors around the world covering several different topics. Unlike the usual textbooks, Thoracic Surgery is a conglomerate of different topics from Pre-operative Assessment, to Pulmonary Resection for Lung Cancer, chest wall procedures, lung cancer topics featuring aspects of VATS major pulmonary resections along with traditional topics such as Pancoast tumors and recurrence patterns of stage I lung disease, hyperhidrosis, bronchiectasis, lung transplantation and much more. This Open Access format is a novel method of sharing thoracic surgical information provided by authors worldwide and it is made accessible to everyone in an expedite way and with an excellent publishing quality.

### **How to reference**

In order to correctly reference this scholarly work, feel free to copy and paste the following:

Shao-Jung Hsu and Kuang-Yao Yang (2012). Extracorporeal Membrane Oxygenation in the Transition of Emergent Thoracic Surgery, Topics in Thoracic Surgery, Prof. Paulo Cardoso (Ed.), ISBN: 978-953-51-0010-2, InTech, Available from: <http://www.intechopen.com/books/topics-in-thoracic-surgery/extracorporeal-membrane-oxygenation-in-the-transition-of-emergent-thoracic-surgery>

**INTECH**  
open science | open minds

### **InTech Europe**

University Campus STeP Ri  
Slavka Krautzeka 83/A  
51000 Rijeka, Croatia  
Phone: +385 (51) 770 447  
Fax: +385 (51) 686 166  
[www.intechopen.com](http://www.intechopen.com)

### **InTech China**

Unit 405, Office Block, Hotel Equatorial Shanghai  
No.65, Yan An Road (West), Shanghai, 200040, China  
中国上海市延安西路65号上海国际贵都大饭店办公楼405单元  
Phone: +86-21-62489820  
Fax: +86-21-62489821

© 2012 The Author(s). Licensee IntechOpen. This is an open access article distributed under the terms of the [Creative Commons Attribution 3.0 License](https://creativecommons.org/licenses/by/3.0/), which permits unrestricted use, distribution, and reproduction in any medium, provided the original work is properly cited.

IntechOpen

IntechOpen