

# We are IntechOpen, the world's leading publisher of Open Access books Built by scientists, for scientists

6,900

Open access books available

185,000

International authors and editors

200M

Downloads

Our authors are among the

154

Countries delivered to

TOP 1%

most cited scientists

12.2%

Contributors from top 500 universities



WEB OF SCIENCE™

Selection of our books indexed in the Book Citation Index  
in Web of Science™ Core Collection (BKCI)

Interested in publishing with us?  
Contact [book.department@intechopen.com](mailto:book.department@intechopen.com)

Numbers displayed above are based on latest data collected.  
For more information visit [www.intechopen.com](http://www.intechopen.com)



## Neuroimaging Findings in Dementia with Lewy Body: A Review

Francesca Baglio, Maria Giulia Preti and Elisabetta Farina  
Fondazione Don Carlo Gnocchi ONLUS Milano  
Politecnico di Milano  
Italy

### 1. Introduction

#### 1.1 Dementia with Lewy bodies: An overview

Dementia with Lewy bodies (DLB) is a progressive neurodegenerative disorder characterized by the core clinical features of fluctuating consciousness, visual hallucinations and parkinsonism.

The term DLB and the clinical criteria were first introduced and proposed by Mc Keith and colleagues in 1996 during the First International Workshop of the Consortium on Dementia with Lewy Bodies (McKeith et al., 1996) and were revised in 2005 to improve the sensitivity for diagnosis (McKeith et al., 2005). Interestingly, in these revised criteria, imaging with Single Photon Emission Computed Tomography (SPECT) or Positron Emission Tomography (PET) played an important role for the first time in the clinical diagnostic criteria of a dementia and was included as a suggestive feature supporting the diagnosis.

After Alzheimer's disease (AD), DLB is now considered the second most common type of degenerative dementia in elderly people (Aarsland et al., 2008; McKeith et al., 2004) observed in 15 to 25% of autopsy series (Heidebrink, 2002; McKeith et al., 1996; Perry et al., 1990). These percentages are consistent with the few available epidemiological population-based studies (de Silva et al., 2003; Herrera et al., 2002; Rahkonen et al., 2003; Stevens et al., 2002; Yamada et al., 2001; Yamada et al., 2002), which have reported the prevalence of DLB ranging from 0 to 30.5% of all dementia cases in individuals older than 65 years and from 0 to 5% in the general population (Zaccai et al., 2005). However, DLB is a regularly misdiagnosed clinical condition, with autopsy reports indicating a higher frequency than that detected in clinical settings (Farina et al., 2009; Mollenhauer et al., 2010).

The pathological background of DLB has been a matter of controversy and is a complex issue (see Fig. 1). The core neuropathological finding is the presence of  $\alpha$ -synuclein aggregates which form neuronal inclusions called Lewy bodies (LBs). According to the consensus pathological guidelines, based on a semiquantitative scoring of  $\alpha$ -synuclein pathology (LBs density and distribution) in specific brain regions, DLB is distinguished into three different phenotypes (brainstem, transitional/limbic, and diffuse neocortical). Moreover, DLB pathological features are often associated to various degrees of AD pathology (i.e. limbic and neocortical spread of LB lesions with or without concomitant AD amyloid plaque pathology).

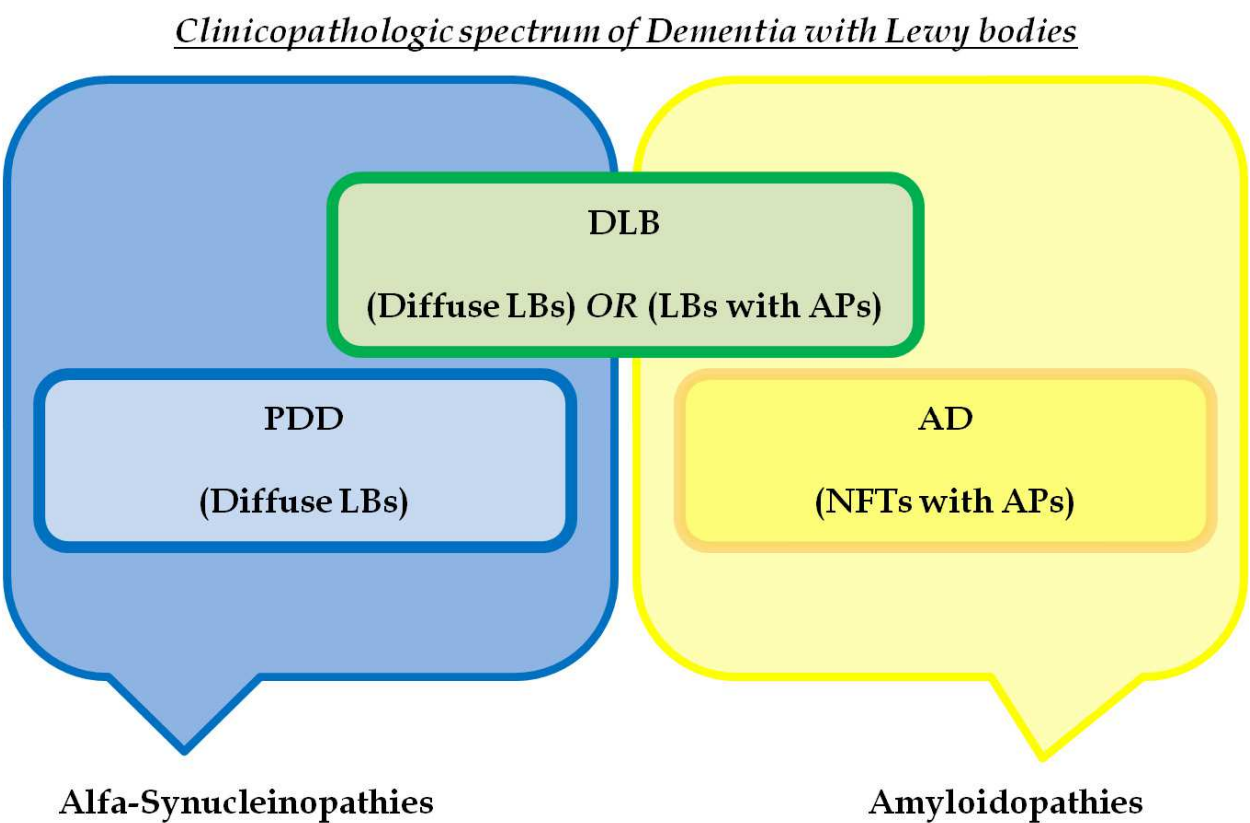


Fig. 1. Clinicopathological interaction between dementia with Lewy bodies (DLB), Parkinson's disease dementia (PDD) and Alzheimer's disease (AD). LBs: Lewy Bodies; NFTs: neurofibrillary tangles; APs: amyloid plaques.

As previously described, the clinical criteria for the diagnosis of DLB were established in 1996 (McKeith et al., 1996) and revised in 2005 (McKetih et al., 2005) to include additional suggestive clinical features (REM sleep behaviour disorder and severe neuroleptic sensitivity) as well as specific neuroradiological findings (Dopamine SPECT or PET imaging). The central feature for the diagnosis, that must be present for either probable or possible DLB, is a condition of dementia. This dementia is defined as a progressive cognitive decline of sufficient magnitude to interfere with normal social or occupational function and with prominent deficits on tests of attention, executive function, and visuospatial ability. The cognitive deficits are not necessarily associated with memory impairment at list at the early stages of the diseases. Then, “probable” DLB is characterized by the presence of this central characteristic with any two of the three core features (fluctuating cognition, recurrent visual hallucinations, or parkinsonism) or one core feature and one suggestive feature, whereas “possible” DLB is diagnosed in the absence of any core features but in the presence of one or more suggestive features. Finally, clinical criteria also includes supportive features (commonly present but not proven to have diagnostic specificity) and findings that do not support DLB (see Table 1 for a detailed description of clinical criteria).

DLB shares many common clinical (motor, cognitive, attentional, and psychiatric symptoms), neuropsychological (prominent deficits on tests of attention, executive function, and visuospatial ability) and pathological features (LBs  $\alpha$ -synuclein aggregates) with Parkinson Disease Dementia (PDD). In the last years, in fact, DLB and PDD have been both included in the same nosological chapter of synucleinopathies, that is Lewy Body Dementias

<b>THE CLINICAL DIAGNOSTIC CRITERIA FOR DEMENTIA WITH LEWY BODIES</b> from the Third International report of the DLB consortium (McKeith et al, 2005)		
<b>CENTRAL FEATURE</b> <input type="checkbox"/> Dementia with impairment in everyday functioning. <input type="checkbox"/> Prominent or persistent memory impairment may not necessarily occur in the early stages but is usually evident with progression. <input type="checkbox"/> Deficits on tests of attention, executive function, and visuospatial ability may be especially prominent.	<b>CORE FEATURES</b> <input type="checkbox"/> Fluctuating cognition with pronounced variations in attention and alertness <input type="checkbox"/> Recurrent visual hallucinations <input type="checkbox"/> Parkinsonism	<b>SUGGESTIVE features</b> <input type="checkbox"/> REM sleep behavior disorder <input type="checkbox"/> Severe neuroleptic sensitivity <input type="checkbox"/> Reduced dopaminergic activity in basal ganglia (SPECT or PET imaging)
<i>For a diagnosis of "Probable" DLB:</i> Central feature AND two core features - OR -Central feature AND one or more core features with one or more suggestive features <i>For a diagnosis of "Possible" DLB:</i> Central feature AND one core feature - OR - Central feature AND one or more suggestive features -- <i>Timing cut-off</i> <i>"one -year rule" between the onset of dementia and parkinsonism to distinguish DLB and PDD</i>		
<b>SUPPORTIVE FEATURES</b> <i>these are often present but do not have diagnostic specificity</i> <input type="checkbox"/> Repeated falls and syncope <input type="checkbox"/> Transient, unexplained loss of consciousness <input type="checkbox"/> Severe autonomic dysfunction, e.g., orthostatic hypotension, urinary incontinence <input type="checkbox"/> Hallucinations in other modalities <input type="checkbox"/> Systematized delusions <input type="checkbox"/> Depression <input type="checkbox"/> Relative preservation of medial temporal lobe structures on CT/MRI scan <input type="checkbox"/> Generalized low uptake on SPECT/PET perfusion scan with reduced occipital activity <input type="checkbox"/> Abnormal (low uptake) MIBG myocardial scintigraphy <input type="checkbox"/> Prominent slow wave activity on EEG with temporal lobe transient sharp waves		
<b>FINDINGS THAT DO NOT SUPPORT DLB</b> <input type="checkbox"/> Presence of cerebrovascular lesions on brain imaging (brain CT or MRI) or focal neurologic signs <input type="checkbox"/> Presence of any other physical illness or brain disorder sufficient to explain the clinical symptoms <input type="checkbox"/> Parkinsonism that occurs for the first time when dementia is severe		

Table 1. The clinical diagnostic criteria for dementia with Lewy bodies taken from the third international report of the DLB consortium (McKeith et al., 2005). SPECT: single photon emission computed tomography; PET: positron emission tomography; CT: computed tomography; MRI: magnetic resonance imaging; MIBG: 31-iodine metaiodobenzylguanidine single photon emission computed tomography; EEG: electroencephalography.

(Lippa et al., 2007). PDD should be the suspected diagnosis in patients with Parkinson's disease (PD) who develop cognitive deficits and/or behavioural disturbances such as hallucinations during the course of their illness (Emre et al., 2007). These two diseases are so closely related that they are distinguished by an arbitrary cut-off ("one year rule") in the timing of motor compared to cognitive dimensions (PDD can be diagnosed only when cognitive deterioration supervenes after one year of the motor symptoms onset). Their response to the treatment with acetylcholinesterase inhibitors (AChEI) and the side effects associated with administration of conventional neuroleptic drugs are similar. Whether the distinction between PDD and DLB is nowadays based on an arbitrary time criterion, the distinction between DLB and other types of dementias such as Alzheimer Disease (AD) at the onset (Watson et al., 2009) is not always straightforward. Particularly, clinical differentiation between DLB and AD is sometimes difficult in the early stage because the symptoms overlap and the cognitive decline can also appear without the parkinsonism. In case of clinical uncertainty some additional investigation for differential diagnosis can be helpful: neuropsychological evaluation with formal tests, neuroimaging tools such as magnetic resonance imaging (MRI) or nuclear medical procedures (PET/SPECT), electroencephalography (EEG) and cerebrospinal fluid analysis.

## 2. Neuroimaging techniques contribution to DLB diagnosis

In this chapter we propose a systematic literature review concerning the principal neuroimaging techniques used for the diagnosis of DLB and their results. In contrast to PET and SPECT analysis, MRI represents a non-invasive tool to assess changes in macroscopic tissue structure (conventional MRI), microstructure (diffusion tensor imaging, DTI), metabolism (MR Spectroscopy, MRS), and cerebral activity (functional MRI, fMRI), and could bring invaluable additional information for the diagnosis of the pathology. The systematic literature search was performed using the computer database MEDLINE accessed via the Web of Knowledge. Two searches were performed including the following terms: "radionuclide imaging"[MeSH Terms] AND "lewy body disease"[MeSH Terms] for the first and "magnetic resonance imaging"[MeSH Terms] AND "lewy body disease"[MeSH Terms] for the second search. We limited the results with these criteria: Humans studies, English language, and publication date of last five years (from 2005/01/01 to 2011/03/01). The period was limited to the last five years in order to include works published after the revision of the clinical criteria for DLB (McKeith et al., 2005). This search produced a total of 165 papers, which were screened individually by title and abstract, looking for information pertaining to PET/SPECT and MR studies in DLB. Moreover, the bibliographies of relevant papers were hand searched to find additional references. In this way, 84 original research papers were identified.

### 2.1 Functional nuclear imaging techniques to diagnose DLB

The above mentioned techniques PET and SPECT represent well-established, reliable imaging methods to assess the functional and metabolic brain changes in DLB (McKeith et al., 2005; McKeith et al., 2007). In Box A, technical aspects of these techniques are briefly summarized. The role of these techniques is well defined in the context of DLB (McKeith et al., 2007), although these procedures are very expensive and not widely used in common radiological settings. Moreover, the need of radioactive isotope injection limits the application of these exams only to cases of uncertain or difficult diagnosis.



**Box A: Functional Nuclear Imaging Techniques: PET and SPECT**

Positron Emission Tomography (PET) and Single Photon Emission Computed Tomography (SPECT) are highly specialized nuclear imaging techniques which provide a means to quantitatively study the metabolic processes within the body and reliably reveal functional abnormalities in the presence of various diseases.

PET acquisitions require firstly the injection of a short-lived radioactive isotope, which combines itself with a specific biologic molecule present in the body. This procedure permits to observe the concentration of that molecule in different structures. After a determined period of time, the isotope decays with the emission of a positron which immediately annihilates with an electron, producing a pair of gamma rays in opposite directions. Particular rings of detectors containing special crystals that produce light when hit by a gamma ray are included within the PET scanner, and the scanner's electronics record these detected gamma rays during the acquisition and map an image of the area where the radiopharmaceutical is located. This process allows the observation of the metabolic activity of the biologic molecule combined with the radiopharmaceutical. For example, glucose combined with a radioisotope will show the pathway followed by glucose in the brain, in the heart, or in a growing tumour.

SPECT procedure of image acquisition is similar to PET, but simpler, as particular radiopharmaceuticals are employed, which directly emit gamma rays during their decay. Larger detectors of gamma rays rotate around the patient.

In this way, nuclear medicine techniques of neuroimaging are able to measure the physiological functioning of the brain, and can be useful to diagnose a multitude of medical conditions, e.g. heart disease, infection, the spread of cancer, thyroid disease, but also stroke, head trauma, dementia. The results of the analysis are spatial colour maps of the radioactivity distribution within tissues and with these images it could be shown that maps of activated brain regions could be produced by detecting the indirect effects of neural activity on variables such as Cerebral Blood Flux (Fox et al., 1986), Cerebral Blood Volume (Fox and Raichle, 1985) and blood oxygenation (Fox and Raichle, 1985; Frostig et al., 1990). Thanks to the double photon emission in PET, the acquisition with PET generates results faster and therefore limits radiation exposure to the patient. The amount of radiation exposure the patient receives in PET is about the same as two chest X-rays.

In respect to fMRI, PET requires multiple acquisitions and the combination of multiple individual brain images in order to obtain a reliable signal. This results in an extension of the acquisition time.

Furthermore, PET and SPECT do not provide structural information about the inspected tissues, therefore the acquisition of images using other imaging techniques such as structural MRI is needed, to precisely localize the resulting activations. Alternatively, in modern PET-CT scans the combined acquisition of a computer tomography (CT) is performed.

**2.1.1 Single Photon Emission Computed Tomography (SPECT)**

SPECT studies on DLB have been mainly addressed to the investigation of: 1) efficiency of dopamine transporter (DAT) in the nigrostriatal pathway (usually referred to as DAT imaging); 2) the characteristics of perfusion within brain compartments.

DAT SPECT is useful in DLB for the investigation of dopaminergic neurons in basal ganglia (caudatum and putamen), as previous literature proved that a loss of dopaminergic neurostriatal neurons is detectable in DLB but not in AD (Piggott et al., 1999; Suzuki et al., 2002). The first ligand used in dopaminergic SPECT was [123I]-2b-carbomethoxy-3b-(4-iodophenyl) tropane (b-CIT). More recently, the ligand [123I] N-x-flouropropyl-2b-carbomethoxy-3b-(4-iodophenyl) nortropane (FP-CIT) was introduced, requiring a shorter time interval between injection and scanning (R. W. H. Walker and Z. Walker, 2009). SPECT with this ligand (FP-CIT SPECT) has been included in the last revision of the International Consensus Criteria for DLB (McKeith et al., 2005). In particular, in a phase III multicentre study among a large cohort of subjects, McKeith and co-workers (McKeith et al., 2007) determined the effectiveness of FP-CIT SPECT to distinguish DLB from other dementias (principally AD), revealing a sensitivity and specificity of respectively 78% and 90% respectively. So far, there have been published many studies that investigated DLB by dopaminergic SPECT (Colloby et al., 2005; David et al., 2008; Lim et al., 2009; O'brien et al., 2009; Roselli et al., 2009; Walker et al., 2007). All these works consistently show the diagnostic value of dopaminergic SPECT as applied to DLB, through the evaluation of the striatal dopaminergic innervations reduction, also in the distinction from other dementias (Soret et al., 2006). In particular, Lim and colleagues (Lim et al., 2009) compared b-CIT SPECT with FDG-PET in the investigation of patients with DLB and AD, concluding that SPECT shows higher accuracy than PET in improving the diagnostic confidence of DLB. Moreover, Roselli et al. (Roselli et al., 2009) found significant correlations between decreased striatal DAT levels and visual hallucinations in DLB patients. The association of behavioural disturbances and SPECT analysis was also investigated (David et al., 2008), in order to assess the relationship between apathy and DAT uptake in DLB and AD patients: a significant correlation was found between lack of initiative and bilateral putamen DAT uptake, demonstrating a relationship between apathy and DAT levels.

Perfusion SPECT studies, instead, use markers such as <sup>99m</sup>Tc- hexamethylpropyleneamine oxime to identify deficits in the functional pattern of brain activity. The majority of available studies highlighted a characteristic pattern of hypoperfusion in DLB patients in parietal and occipital brain areas (Brockhuis et al., 2006; Hanyu et al., 2006a; Lobotesis et al., 2001). However, other studies also suggested the presence of hypoperfusion in the frontal, parietal, and temporal cortex and in the thalamus (Chang et al., 2008). The differentiation between AD and DLB patients was often investigated by means of this second perfusion-based SPECT approach, in order to identify characteristic features allowing to distinguish between the two most common types of dementias (Colloby et al., 2010a; Colloby et al., 2010b; Goto et al., 2010; Kasama et al., 2005; Kemp et al., 2005; Mito et al., 2005; Shimizu et al., 2005; Shimizu et al., 2008; Tateno et al., 2008a). When compared with AD, DLB patients presented a preserved perfusion in the medial temporal lobe structures and a hypoperfusion in the occipital lobes, besides an increased perfusion in the striatum and thalamus bilaterally. In a recent study by Colloby and colleagues (Colloby et al., 2010a), the utility of <sup>99m</sup>Tc-exametazime SPECT in the distinction between AD and DLB was verified through a Region Of Interest (ROI) approach and the Principal Component Analysis (PCA). The ROI analysis showed decreased regional CBF in AD compared to DLB, in the medial temporal lobe, in the striatum bilaterally and in the right thalamus.

Moreover, a distinction between the two groups was possible through the analysis of the principal components (PCs). Two components, in fact, were identified as being differentially



affected in AD and DLB. The former revealed concomitant decreased perfusion in the medial temporal lobes and increased perfusion in the cerebellum of AD compared to DLB patients. Conversely, the latter represented a concomitant increase of regional CBF in thalamus bilaterally, and in the right striatum of DLB compared to AD patients.

Interestingly, SPECT imaging was also used in combination with other measures to better detect changes in DLB. Several studies (Hanyu et al., 2006b; Inui et al., 2007; Novellino et al., 2010; Tateno et al., 2008b) which combined SPECT and (1,2,3)I-metaiodobenzylguanidine myocardial (MIBG) scintigraphy reported that the accuracy power in the diagnostic process of DLB resulted increased. Furthermore, Goto and colleagues (Goto et al., 2010) proposed to combine the computation of ratios on perfusion SPECT with MRI volumetric data (hippocampal, occipital, and striatal structures) to discriminate between DLB and AD. They found that the striatal volume and the occipital SPECT ratio in the DLB group was lower than that in the AD group and concluded that the combination of SPECT and MRI might contribute to a successful differential diagnosis of DLB. Chang et al. (Chang et al., 2008), instead, demonstrated the efficacy of perfusion SPECT combined with neuropsychological evaluation to differentiate early stage DLB patients at early clinical stage from those suffering from PD. SPECT images analysed with a ROI approach resulted in a pattern of significant hypoperfusion in DLB compared with healthy controls in frontal, parietal, thalamic, and temporal areas; consistent to this imaging finding, neuropsychological tests revealed the presence of deficits in DLB patients with respect to controls including the following cognitive domains: mental manipulation, short-term memory, abstract thinking, drawing and semantic verbal fluencies. Compared with PD, DLB patients showed significantly reduced SPECT signals in temporal areas and had lower scores at neuropsychological evaluation for mental manipulation, drawing and semantic verbal fluency. Conversely, SPECT analyses (FP-CIT and DAT) were unable to discriminate DLB and PDD (Rossi et al., 2009), thus supporting the hypothesis that these two forms of dementia belong to a continuum spectrum of a unique disease.

In conclusion, the two different SPECT analyses (DAT and perfusion) have proven to be both useful, but DAT scan seems to be more robust and accurate for diagnostic purposes, as described in a recent study by Colloby and colleagues (Colloby et al., 2008). These authors directly compared the performances of the two SPECT approaches when applied to the differential diagnosis between AD and DLB, and identified dopaminergic SPECT as the technique with higher diagnostic accuracy (ROC curve area 0.83, sensitivity 78.6%, specificity 87.9% in respect to perfusion SPECT with ROC curve area 0.64, sensitivity 64.3%, specificity 63.6%).

### 2.1.2 Positron Emission Tomography (PET)

Together with SPECT, PET allows the functional investigation of brain activity and metabolism (see Box A) and therefore represents a powerful instrument for the early detection of dementia (Koeppe et al., 2005), since it was proven that brain function deficit in dementia occurs long before disease clinical evidences (Tartaglia et al., 2011). The use of different radioisotopes increases PET versatilities. Depending on the specific tracer used, in fact, PET imaging allows the representation of specific molecules, and therefore the analysis of different functioning systems (e.g. the neural energy metabolism with F-18 2-fluoro-2-deoxy-D-glucose; the cholinergic way with N-11C-methyl-4-piperidyl acetate; the dopaminergic with 18fluorodopa; the brain amyloid burden with Pittsburgh compound B).



The more common tracer used in PET clinical studies is the F-18 2-fluoro-2-deoxy-D-glucose (FDG), which provides information about neuronal energy metabolism, in terms of regional glucose uptake. In the context of DLB, previous FDG-PET studies revealed a pattern of hypometabolism in the medial occipital cortex (Klein et al., 2010; Perneczky et al., 2008a; Satoh et al., 2010), in agreement with the previously reported SPECT data of hypoperfusion. Furthermore, other literature data found a correlation between cerebral hypometabolism in right temporoparietal cortex, prefrontal cortex and the precuneus and patients' performance level of everyday competence (Perneczky et al., 2008b; Perneczky et al., 2009a). Moreover, a recent study by Miyazawa and co-workers (Miyazawa et al., 2010) introduced a new pattern of hypermetabolism in DLB regarding three different areas: the peri-motor area, the basal ganglia and the cerebellum. Interestingly, only patients with hypermetabolism in all these three areas experimented recurrent visual hallucinations, therefore authors concluded that this pattern may be related to the core features of this behavioural disturbance.

In recent years, these relationships between brain perfusion and symptoms domain were well investigated (Fujishiro et al., 2010; Miyazawa et al., 2010; Nagahama et al., 2008; Nagahama et al., 2010; O'Brien et al., 2005; O'Brien et al., 2008; Perneczky et al., 2010). The cognitive performances on visual spatial and attentional tasks in DLB were proved to be closely related to the frontal-subcortical network dysfunction of these patients (Nagahama et al., 2008; Perneczky et al., 2008a; Perneczky et al., 2009b; Perneczky et al., 2010). A recent FDG-PET study by Fujishiro and colleagues (Fujishiro et al., 2010) demonstrated the correlation between REM sleep behaviour disorder and the development of DLB, observing that the typical pattern of occipital hypometabolism on FDG-PET clearly manifested in patient with DLB also in prodromal stages. Furthermore, distinguishable cerebral networks were associated with different psychotic symptoms in DLB patients: dysfunctions of the parietal-occipital association cortices with visual hallucinations; dysfunctions of limbic and paralimbic structures with misidentification and relative hyperperfusion in the frontal cortex with delusions (Nagahama et al., 2010; Perneczky et al., 2008a; Perneczky et al., 2009b).

As to the comparison with PD, instead, a metabolic decrease was found in DLB in the inferior and medial frontal lobes and in the right parietal lobe (Yong et al., 2007). Moreover, a comparison with PDD revealed similar pattern of metabolism reduction for PDD and DLB, except for the anterior cingulate and these findings support the hypothesis that these types of dementias are closely related and may be included in a unique spectrum (Yong et al., 2007). These data are concordant with an innovative multitracer PET study on PDD, PD and DLB patients, which aims at highlighting the complex damage pattern at the base of these conditions (Klein et al., 2010). For the first time, a multidimensional approach was introduced to detect the complex issue of the neuropathological spectrum of Lewy Body dementias (see Fig. 1): besides FDG, 18fluorodopa (FDOPA) was used to study the dopaminergic system and N-11C-methyl-4-piperidyl acetate (MP4A) for the cholinergic one, aiming on identifying the different characteristics of these systems. The results did not succeed in the distinction between the two conditions of DLB and PDD, but allowed to identify the metabolic features of the observed neuronal systems. A dopaminergic deficit was showed in the amygdala, in the anterior cingulate and in the prefrontal cortex of patients compared to controls, whereas the analysis with MP4A highlighted a cholinergic deficit regarding the occipital cortex. As this cholinergic impairment did not regard PD patients without dementias, it seemed to be directly responsible for the development of dementia in addition to motor symptoms. In line with previous studies, FDG-PET

underlined a pattern of hypometabolism in correspondence of the cholinergic deficit, in the parieto-occipital brain regions. Taken together, in agreement with Klein and co-workers, these findings strengthen the concept that PDD and DLB represent two sides of the same coin in a continuum of Lewy Body Diseases.

When facing the issue of the comparison between DLB and AD, the FDOPA PET represent an interesting way to distinguish between the two pathologies, since differently from DLB, AD is not affected by a dopaminergic dysfunction. Moreover, in this context also FDG-PET demonstrated effectiveness, revealing a decrease in the occipitotemporal metabolism of DLB, in accordance with the visual processing problems that primarily DLB patients report (Gilman et al., 2005).

The recent development of new PET ligands which can bind amyloid, such as the radiolabeled Pittsburgh compound B ([11C]PiB), opened new frontiers on the study of amyloid metabolism through PET (Tartaglia et al., 2011). This aspect appears of importance in the study of DLB, since it was proven to be associated with amyloid deposition, as it happens in Alzheimer Disease (Brooks et al., 2009). Previous literature suggested a similar pattern of amyloid high cortical deposition in AD and DLB (Backsai et al., 2007; Fodero-Tavoletti et al., 2007; Maetzler et al., 2009), whereas conflicting data are reported about the comparison between DLB and PDD. In fact, ([11C]PiB)-PET studies reported a significant increase in the amyloid load in DLB compared to PDD (Edison et al., 2008; Gomperts et al., 2008), demonstrating the efficacy of this technique in the distinction between DLB and PDD. On the contrary, Foster and colleagues (Foster et al., 2010) showed that amyloid deposition did not allow differentiation between different subtypes of Lewy Body associated disorders. In conclusion, the power of PET as well as SPECT analysis is represented by the modalities versatility, allowing the study of the different and complex neuropathological substrates of DLB which is not possible with other imaging modalities without tracers (Herholz et al., 2007; Kemp et al., 2007). Nevertheless, the limits imposed by the use of radioactive isotope injection and high costs must be taken in consideration.

## **2.2 MRI-based analyses techniques: Adding useful information to clinicians**

The importance of introducing advanced MR imaging techniques in the DLB diagnosis beside nuclear imaging methods is due to their capability to non-invasively detect early changes which could be potential biomarkers of the pathology. These MRI-based techniques can be used in large-scale studies thanks to the wide availability of MR scanners in clinics. MRI is a complex field including different approaches which permit the investigation of several aspects of brain structure and function. The clinical utility of structural neuroimaging with MRI for diagnosis and differential diagnosis of dementias is well-established (Hentschel et al., 2005), however, conventional MRI in association with advanced methods of image processing (e.g. voxel-based morphometry) represent a powerful tool in tissue structure analysis. Moreover, the investigation of microstructural changes is permitted by DTI through the observation of water molecular displacements within tissues. Cerebral activity is also detectable by functional MRI (fMRI) techniques. In the following, we summarise the principal literature findings in the study of DLB obtained using the above mentioned MRI approaches.

### **2.2.1 Voxel Based Morphometry (VBM)**

The analysis with the technique of voxel based morphometry (VBM) on Magnetic Resonance images is one of the most widespread MRI-based approaches aimed at quantifying regional

differences across subjects in brain tissue volumes (see Box B for technical details). In the context of DLB, the use of VBM appears highly promising to investigate the pattern of gray and white matter (GM and WM) atrophy and the severity of the damage.

Several literature studies used VBM to demonstrate the differences between DLB and PDD, and converged to reveal a pattern of more pronounced gray matter atrophy in DLB compared to PDD. These results appear in concordance with the ([11C]PiB)-PET findings of greater structural cortical changes in DLB related to amyloid burden (Edison et al., 2008; Gomperts et al., 2008). However, the distribution of this GM loss appears very heterogeneous among the different studies, and regards: the temporal (Beyer et al., 2007; Tam et al., 2005), parietal and occipital lobes (Beyer et al., 2007; Lee et al., 2010a), striatal areas (Lee et al., 2010a), right premotor areas, right inferior frontal lobe and right superior frontal gyrus (Sanchez-Castaneda et al., 2009). In a recent study, Sanchez-Castaneda and colleagues (Sanchez-Castaneda et al., 2010) found a different pattern of structural and functional correlations between the two dementias, in particular: decreases in volume in associative visual areas, left precuneus and inferior frontal lobe which correlates with visual hallucinations only in DLB. A possible explanation for these different results is the heterogeneity (e.g. disease duration, stage of dementia) amongst patients with PDD (patients who developed dementia early or later in the course of their illness) who are included in these small size studies. Moreover, the same pattern of atrophy measured in GM of DLB in respect to PDD was found also in WM by Lee and co-workers (Lee et al., 2010a). In their recent study, they demonstrated a significant decrease of the WM density in DLB, specifically in the bilateral occipital and left occipito-parietal areas. Moreover, they found that the atrophy level of GM and WM was similar in DLB patients, whereas WM damage was observed to a lesser severity in respect to GM loss in PDD. Taken together, these data may reflect the different nature of neuropathological aspects or potentially the different neuropathological stages regarding PDD and DLB. Further studies including a better clinical characterisation of patients (e.g. matching for age, dementia duration, and treatments) are needed to clarify the topic and delete this potential bias.

As to the comparison between DLB and AD, the distinction in terms of cerebral atrophy between these two groups was not well defined. A few recent studies attempted to identify a pattern of cortical atrophy which could distinguish DLB patients from AD patients (Burton et al., 2009; Whitwell et al., 2007). Whitwell et al. (Whitwell et al., 2007) highlighted a more severe cortical atrophy in AD compared to DLB patients regarding the medial temporal lobe, inferior temporal regions, the hippocampus and the temporoparietal cortex. Both groups revealed a pattern of damage in the midbrain and substantia innominata, although DLB patients showed a greater loss regarding the midbrain whereas AD regarding the substantia innominata. Thus, the specific pattern of cortical atrophy able to characterize DLB from AD was identified by Whitwell as a relatively focused loss in midbrain, substantia innominata and hypothalamus, with a sparing in hippocampus and temporal cortex. Changes in substantia innominata suggesting cholinergic impairment of DLB were also detected by Hanyu and co-workers (Hanyu et al., 2005; Hanyu et al., 2007). Furthermore, other studies found that the temporal (Beyer et al., 2007; Burton et al., 2009; Takahashi et al., 2010) and frontal lobes (Beyer et al., 2007) are potentially interested by a more pronounced cortical loss in AD compared to DLB. In particular, Burton and colleagues (Burton et al., 2009) showed that medial temporal lobe atrophy on MRI had an important role by distinguishing AD and DLB in pathologically confirmed cases.



**Box B: Voxel Based Morphometry**

Voxel-based morphometry (VBM) of structural MRI data is a well-established technique of group analysis which allows the comparison of regionally specific differences in the local concentration of gray matter between two groups of subjects on a voxel by voxel basis. Typically T1-weighted MRI scans enter the VBM analysis and the compared groups consist in a group of subjects with a disorder and an age-matched control group of healthy subjects, in order to highlight the features characterizing pathology, in terms of brain volumes. The technique of VBM has become increasingly popular over the last few years since it is relatively easy to use. It has also been applied to assess the patterns of grey and white matter loss regarding many different pathologies (Whitwell et al., 2007). The importance of this approach is that it gives a comprehensive assessment of anatomical differences throughout the brain, without being biased to one particular structure (Ashburner and Friston, 2000), as it does not require any a priori assumptions concerning which structures to consider. This gives to the VBM a significant advantage over more traditional region of- interest (ROI) approaches, which involve the manual delineation of the structures of interest (Whitwell et al., 2007), being therefore extremely operator-dependent and scarcely reproducible.

The first step of the VBM analysis involves a spatial normalization of the images of all subjects to bring them to the same stereotactic space and perform voxel-wise comparisons. This is achieved by registering every image to one previously chosen template image, with the minimization of the residual sum of squared differences between them. Then, the gray matter is extracted from the normalized images by means of a segmentation of the different brain tissues from the images. The next step is the smoothing of gray matter images, in order to compensate for normalization errors and also to render the data more normally distributed, increasing thus the validity of parametric statistical tests. The accuracy of the gray matter segmentation step is essential in order to assure that the analysis of the proper structures of interest is performed.

After that, the voxel-wise statistical analysis is performed with the aim of identifying positions in the brain where the gray matter concentration differs significantly between groups. The General Linear Model (GLM) is used for the statistical analysis, allowing many different tests to be applied, as group comparisons and identification of regions of gray matter concentration that are related to particular covariates (e.g. pathology severity, age). The output from the method is a statistical parametric map showing regions where gray matter concentration differences between the compared groups appear statistically significant.

Obviously the image pre-processing of the VBM analysis is required to be extremely accurate and rigorous to avoid errors of interpretation caused by misclassification of non-brain voxels or voxels belonging to other tissues, and to allow precise statistical analyses.

One shortcoming of the VBM approach is in fact represented by the decrease in the sensitivity for the detection of group differences, associated with the variability among individuals both due to sample heterogeneity and to inaccuracies introduced with the image pre-processing. In addition, the smoothing step involves a trade off to be considered: while high levels of smoothing increase the ability of the technique to detect group differences by reducing the variance, excess smoothing diminishes the accuracy in the localization of changes.



In conclusion, the main findings of these studies can be summarised in the following key points: 1) the rate of cerebral cortical atrophy of DLB patients appears higher than PDD but at the same time lower than AD; 2) the medial temporal lobe structures are more preserved in both DLB and PDD in respect to AD (Beyer et al., 2007; Burton et al., 2009; Tam et al., 2005; Whitwell et al., 2007); 3) DLB and PDD show greater changes in respect to AD in subcortical structures and this is due to dopaminergic system dysfunction (Hanyu et al., 2007; Summerfield et al., 2005; Whitwell et al. 2007).

### 2.2.2 Diffusion Tensor Imaging (DTI)

Diffusion weighted and diffusion tensor imaging (DTI) could play an important role in the study of DLB, thanks to the unique capability of these techniques to investigate white matter microstructural damages, which could help in the definition of a characteristic neurodegenerative pattern and consequently in the differentiation of DLB patients from other dementias. White matter diffusion characteristics are primarily assessed by means of the computation of Mean Diffusivity (MD) and Fractional Anisotropy (FA) (see Box C for further technical details).

Previous DTI studies on DLB were implemented initially with Regions Of Interest (ROI) based methods or voxel-based DTI and found diffusion abnormalities of the corpus callosum, pericallosal areas and the frontal, parietal, occipital and, less prominently, temporal white matter of patients compared with controls (Bozzali et al., 2005; Firbank et al., 2007a; Firbank et al., 2007b; Lee et al., 2010b). These findings in regions with a high prevalence of long connecting fibre tracts might suggest the presence of neurodegeneration involving associative cortices. Moreover, the selective involvement of parietal, frontal and occipital lobes might explain some of the clinical and neuropsychological features of DLB, providing a possible distinctive marker for this disease. The modest involvement of the temporal lobe, according to previously described VBM studies (Beyer et al., 2007; Burton et al., 2009; Tam et al., 2005; Takahashi et al., 2009; Whitwell et al., 2007), is consistent with the relative preservation of global neuropsychological measures and memory tasks in the early stage of DLB. More recently, Kantarci and colleagues (Kantarci et al., 2010) found increased MD in the amygdala and decreased FA in the inferior longitudinal fasciculus in DLB with respect to controls. Authors suggested that the former result could reflect the typical microvacuolation associated with LBs pathology in this structure, whereas the latter may be due to the presence of core symptoms of visual hallucinations. The encountered inferior longitudinal fasciculus damage in concordance with a tractography based study by Ota and colleagues (Ota et al., 2009) correlates with the pathology, as this bundle is responsible for visuospatial cognition and DLB is thought to involve an impairment of the visual association area.

In the above mentioned study by Ota et al. (Ota et al., 2009) the findings were supported by the computation of eigenvalues ( $\lambda_1$ ,  $\lambda_2$ ,  $\lambda_3$ ), providing information about the magnitude of axial ( $\lambda_1$ ) and radial ( $\lambda_2$ ,  $\lambda_3$ ) diffusivity. They found significantly lowered  $\lambda_2$  and  $\lambda_3$  in the inferior longitudinal fasciculus of DLB patients in respect to healthy controls, however no difference was found in  $\lambda_1$ . Furthermore, a recent study (Kiuchi et al., 2011) introduced the tractographic reconstruction of white matter fiber bundles not only for the study of DLB but also for the comparison with AD. The analysis was focused on the uncinate fasciculus, inferior fronto-occipital fasciculus and inferior longitudinal fasciculus. Although no significant differences were seen between AD and DLB, some different features in the FA evaluation were found between each patient group and controls. In particular, significantly lowered FA values were found in bilateral uncinate fasciculus for both AD and DLB, and in bilateral inferior fronto-occipital

**Box C: Diffusion weighted and Diffusion Tensor Imaging**

Diffusion Weighted Imaging (DWI) is an advanced MRI technique providing invaluable information concerning tissue structure at a microscopic scale, thanks to the observation of the molecular diffusion. The image contrast in DWI depends, in fact, on the entity of water molecule diffusive displacements in tissues, and consequently on tissue microstructure. The basic principles of DWI, which has been an important area of research in the past decade, were introduced in the mid-1980s and combined conventional MR imaging principles with the use of sharp bipolar magnetic field gradient pulses in order to encode molecular diffusion effects in MR signal. The physical process of molecular diffusion, first formally described by Einstein in 1905, refers to the random motion of molecules, also called Brownian motion, which results from the thermal energy carried by these molecules (Beaulieu, 2002). The erratic motion of molecules in a homogeneous solution is statistically described by a displacement distribution, which represents the probability that a particular molecule travels a given distance in a given time interval, and is governed by the diffusion coefficient  $D$ . In biological tissues, compared to solutions, the movement of molecules is hindered by macromolecules and cellular organelles and is also restricted by the confinement created by membranes. The macroscopic result is a decreased coefficient of diffusion, named apparent diffusion coefficient (ADC). In biological tissues with a highly anisotropic structure, such as white matter fibre bundles, diffusion is characterized by a specific directionality, since the peculiar structural arrangement of the medium limits molecular movement in some directions. To fully describe the diffusion process, it is thus necessary to investigate displacements of molecules not only along one direction, but along multiple dimensions. This is possible using Diffusion Tensor Imaging (DTI), which describes diffusion in the three-dimensional space using a tensor quantity  $D$  instead of a single coefficient. This provides a detailed mathematical description of diffusion and allows to compute the principal direction of diffusion in every position of the explored tissue, as the principal eigenvector of the tensor. Moreover, from the tensor eigenvalues  $(\lambda_1, \lambda_2, \lambda_3)$  computed in every voxel of the image, two useful scalar measures providing information about the diffusion features can be computed: the Mean Diffusivity (1)

$$MD = \frac{(\lambda_1 + \lambda_2 + \lambda_3)}{3} \tag{1}$$

indicating the diffusion magnitude, and the Fractional Anisotropy (2)

$$FA = \sqrt{\frac{3}{2} \frac{\sqrt{(\lambda_1 - MD)^2 + (\lambda_2 - MD)^2 + (\lambda_3 - MD)^2}}{\sqrt{\lambda_1^2 + \lambda_2^2 + \lambda_3^2}}} \tag{2}$$

providing an estimate of the degree of diffusion directionality. These metrics are commonly used to quantitatively assess diffusion features in healthy population and abnormalities in pathological tissues. Furthermore, DTI is at the base of the advanced technique of tractography (or fiber tracking), i.e. the virtual reconstruction of brain white matter tracts, starting from the assumption that the direction of major diffusion would indicate the overall orientation of the fibres in the brain. This technique represents one of the most important area of current research and, in combination with fMRI, opens a window on the important issue of brain connectivity.



#### **Box D: BOLD signal and functional Magnetic Resonance Imaging**

The functional Magnetic Resonance Imaging (fMRI) analysis provides invaluable information about the localization of neuronal activations related to a task or in a condition of rest, and for this reason is one of the most widely used method for brain mapping and measuring behaviour-related neural activity in the human brain. The development of functional techniques gives to MRI the ability to observe both the structures and also which structures participate in specific functions, gaining great power in the mapping of functional connectivity. Different fMRI techniques can be employed to measure the hemodynamic response, however fMRI based on blood-oxygen level-dependent (BOLD) contrast has gained great success due to its high sensitivity and accessibility (Logothetis, 2002). This contrast was firstly described by Ogawa and colleagues in 1990 (Ogawa et al., 1990a; Ogawa et al., 1990b), with the introduction of a high resolution gradient-echo-pulse sequence accentuating the susceptibility effects of deoxygenated Hemoglobin (dHb) in the venous blood and obtaining therefore a signal dependent on the blood oxygen level. In fact, dHb owns a paramagnetic nature which induces a local alterations of the magnetic field in correspondence of the compartments containing dHb, and a consequent modification the T2\* weighted MRI signal. The increase in regional CBF caused by a neuronal activation does not correspond to an increase in the oxygen consumption rate (Fox & Raichle, 1985), thus a decreased oxygen extraction fraction is observable and this results in a lower dHb content per volume unit in activated tissues (Logothetis, 2002). For this reason, activated areas will be characterized by a higher BOLD signal in the image. However, it was demonstrated that BOLD contrast is actually a complex type of response controlled by several parameters, depending therefore not only on blood oxygenation, but also on cerebral blood flux and volume (Ogawa et al. 1993; Ogawa et al., 1998; Van Zijl et al. 1998; Weisskoff et al. 1994). Although the exact relation between the blood oxygen-level dependent (BOLD) signal and the underlying neural activity appears difficult to explicate, fMRI experiments allow to observe which brain areas activate in relation to the performance of a particular task. Patients are required to perform a specific task during the MRI acquisition, expecting the activation of specific corresponding brain areas during the task. This information is useful both in healthy subjects, to map the normal cerebral functions, and in presence of diseases, aiming on underlying possible changes of functionality in damaged brains. Moreover, fMRI opens a window on the complicated issue of neuronal connectivity, allowing the observation of functional connections between different areas in the brain, and of neuronal plasticity, i.e. the capability of the brain functions to change and adapt to external inputs, during life or in presence of pathologies. Recently, the fMRI analysis in a condition of resting (so called resting state condition) is gaining more attention in the current research, aiming on exploring the activated areas and their connections during rest. In respect to other techniques to map brain functional activity, some aspects characterizing fMRI can be listed as advantages of this technique: firstly, the signal does not require injections of radioactive isotopes as it happens for positron emission tomography (PET); the in-plane resolution of functional images could be less than 1 mm; furthermore, the total acquisition time can be very short, depending on the paradigm to perform.

fasciculus and left inferior longitudinal fasciculus for DLB with respect to controls, suggesting that DLB exhibited modifications in visual-related WM tracts.

From all these studies, we can argue that tractographic reconstruction proved to be helpful for a better understanding of WM connectivity in DLB patients and in particular for the detection of visual related damages in this dementia.

### **2.2.3 Functional Magnetic Resonance Imaging (fMRI)**

The most diffuse neuroimaging techniques for the evaluation of brain activity and function in DLB are undoubtedly the above mentioned PET and SPECT. Functional investigations with fMRI (details in Box D) in DLB are still developing and currently appears less widespread than nuclear imaging studies. A unique task-related fMRI study (Sauer et al., 2006) was conducted and investigated the pattern of activations in DLB and AD during visual colour, face and motor stimuli. A significantly greater activation of DLB compared to AD, independent on task performance, age or cognitive score, was found in the superior temporal sulcus during the motor task. Instead, performance-dependent differences were found in the activation patterns related to the motor and face task, in which the activity appeared higher for AD compared to DLB, and in the default mode network pattern, in which the effect was greater for AD and DLB with respect to controls. Authors concluded thus that fMRI can be reliably used for the detection of functional activity distribution patterns in these two conditions. However, the role of fMRI remains unclear in the study of those patients, as the significance of the found results are not completely understood. Further studies combining anatomical MRI, DTI, and resting state fMRI are needed, in order to verify the hypothesis that structural subcortico-cortical connections may provide integral routes for communication between cortical resting state networks, and that changes in the integrity of these connections have a role in this dementia.

## **3. Conclusion**

In this chapter, we reviewed the literature concerning the study of DLB through imaging techniques. We have shown that the use of neuro-imaging methods could noticeably improve the differential diagnosis of DLB when several doubts exist. To solve this problem, the nuclear imaging methods (PET/SPECT) play nowadays the principal role (O'Brien et al., 2007). However, MRI techniques revealed interesting results and although they are now limited to the research field, except for the assessment of medial temporal lobe preservation with structural MRI, they seem to be a promising measure for detecting early and potentially preclinical DLB changes and for the validation of surrogate markers to be applied in longitudinal studies and pharmacological trials (von Gunten & Meuli, 2009; Watson et al., 2009). We think that the combination of different MRI methods may contribute to a better understanding of this often misdiagnosed pathology.

## **4. Acknowledgments**

We are grateful to David T. Utriainen and Marco Bozzali for valuable advice on this chapter.



## 5. References

- Aarsland, D.; Kurz, M.; Beyer, M.; Bronnick, K.; Piepenstock Nore, S. & Ballard, C. (2008). Early discriminatory diagnosis of dementia with Lewy bodies. The emerging role of CSF and imaging biomarkers. *Dementia and Geriatric Cognitive Disorders*, Vol.25, No.3, pp. 195-205, ISSN 1421-9824; 1420-8008
- Ashburner, J. & Friston, K. J. (2000). Voxel-based morphometry--the methods. *NeuroImage*, Vol.11, No.6 Pt 1, pp. 805-821, ISSN 1053-8119; 1053-8119
- Bacsikai, B. J.; Frosch, M. P.; Freeman, S. H.; Raymond, S. B.; Augustinack, J. C.; Johnson, K. A.; Irizarry, M. C.; Klunk, W. E.; Mathis, C. A.; Dekosky, S. T.; Greenberg, S. M.; Hyman, B. T. & Growdon, J. H. (2007). Molecular imaging with Pittsburgh Compound B confirmed at autopsy: a case report. *Archives of Neurology*, Vol.64, No.3, pp. 431-434, ISSN 0003-9942; 0003-9942
- Beaulieu, C. (2002). The basis of anisotropic water diffusion in the nervous system - a technical review. *NMR in Biomedicine*, Vol.15, No.7-8, pp. 435-455, ISSN 0952-3480; 0952-3480
- Beyer, M. K.; Larsen, J. P. & Aarsland, D. (2007). Gray matter atrophy in Parkinson disease with dementia and dementia with Lewy bodies. *Neurology*, Vol.69, No.8, pp. 747-754, ISSN 1526-632X; 0028-3878
- Bozzali, M.; Falini, A.; Cercignani, M.; Baglio, F.; Farina, E.; Alberoni, M.; Vezzulli, P.; Olivetto, F.; Mantovani, F.; Shallice, T.; Scotti, G.; Canal, N. & Nemni, R. (2005). Brain tissue damage in dementia with Lewy bodies: an in vivo diffusion tensor MRI study. *Brain : A Journal of Neurology*, Vol.128, No.Pt 7, pp. 1595-1604, ISSN 1460-2156; 0006-8950
- Brockhuis, B.; Slawek, J.; Wieczorek, D.; Ussorowska, D.; Derejko, M.; Romanowicz, G.; Marks, W. & Dubaniewicz, M. (2006). Cerebral blood flow changes in patients with dementia with Lewy bodies (DLB). A study of 6 cases. *Nuclear Medicine Review.Central & Eastern Europe : Journal of Bulgarian, Czech, Macedonian, Polish, Romanian, Russian, Slovak, Yugoslav Societies of Nuclear Medicine and Ukrainian Society of Radiology*, Vol.9, No.2, pp. 114-118, ISSN 1506-9680; 1506-9680
- Brooks, D. J. (2009). Imaging amyloid in Parkinson's disease dementia and dementia with Lewy bodies with positron emission tomography. *Movement Disorders : Official Journal of the Movement Disorder Society*, Vol.24 Suppl 2, pp. S742-7, ISSN 1531-8257; 0885-3185
- Burton, E. J.; Barber, R.; Mukaetova-Ladinska, E. B.; Robson, J.; Perry, R. H.; Jaros, E.; Kalaria, R. N. & O'Brien, J. T. (2009). Medial temporal lobe atrophy on MRI differentiates Alzheimer's disease from dementia with Lewy bodies and vascular cognitive impairment: a prospective study with pathological verification of diagnosis. *Brain : A Journal of Neurology*, Vol.132, No.Pt 1, pp. 195-203, ISSN 1460-2156; 0006-8950
- Chang, C. C.; Liu, J. S.; Chang, Y. Y.; Chang, W. N.; Chen, S. S. & Lee, C. H. (2008). (99m)Tc-ethyl cysteinate dimer brain SPECT findings in early stage of dementia with Lewy bodies and Parkinson's disease patients: a correlation with neuropsychological tests. *European Journal of Neurology : The Official Journal of the European Federation of Neurological Societies*, Vol.15, No.1, pp. 61-65, ISSN 1468-1331; 1351-5101
- Colloby, S. J.; Williams, E. D.; Burn, D. J.; Lloyd, J. J.; McKeith, I. G. & O'Brien, J. T. (2005). Progression of dopaminergic degeneration in dementia with Lewy bodies and

- Parkinson's disease with and without dementia assessed using 123I-FP-CIT SPECT. *European Journal of Nuclear Medicine and Molecular Imaging*, Vol.32, No.10, pp. 1176-1185, ISSN 1619-7070; 1619-7070
- Colloby, S. J.; Firbank, M. J.; Pakrasi, S.; Lloyd, J. J.; Driver, I.; McKeith, I. G.; Williams, E. D. & O'Brien, J. T. (2008). A comparison of 99mTc-exametazime and 123I-FP-CIT SPECT imaging in the differential diagnosis of Alzheimer's disease and dementia with Lewy bodies. *International Psychogeriatrics / IPA*, Vol.20, No.6, pp. 1124-1140, ISSN 1041-6102; 1041-6102
- Colloby, S. J.; Taylor, J. P.; Firbank, M. J.; McKeith, I. G.; Williams, E. D. & O'Brien, J. T. (2010a). Covariance 99mTc-exametazime SPECT patterns in Alzheimer's disease and dementia with Lewy bodies: utility in differential diagnosis. *Journal of Geriatric Psychiatry and Neurology*, Vol.23, No.1, pp. 54-62, ISSN 0891-9887; 0891-9887
- Colloby, S. J.; Perry, E. K.; Pakrasi, S.; Pimlott, S. L.; Wyper, D. J.; McKeith, I. G.; Williams, E. D. & O'Brien, J. T. (2010b). Nicotinic 123I-5IA-85380 single photon emission computed tomography as a predictor of cognitive progression in Alzheimer's disease and dementia with Lewy bodies. *The American Journal of Geriatric Psychiatry : Official Journal of the American Association for Geriatric Psychiatry*, Vol.18, No.1, pp. 86-90, ISSN 1545-7214; 1064-7481
- David, R.; Koulibaly, M.; Benoit, M.; Garcia, R.; Caci, H.; Darcourt, J. & Robert, P. (2008). Striatal dopamine transporter levels correlate with apathy in neurodegenerative diseases A SPECT study with partial volume effect correction. *Clinical Neurology and Neurosurgery*, Vol.110, No.1, pp. 19-24, ISSN 0303-8467; 0303-8467
- de Silva, H. A.; Gunatilake, S. B. & Smith, A. D. (2003). Prevalence of dementia in a semi-urban population in Sri Lanka: report from a regional survey. *International Journal of Geriatric Psychiatry*, Vol.18, No.8, pp. 711-715, ISSN 0885-6230
- Edison, P.; Rowe, C. C.; Rinne, J. O.; Ng, S.; Ahmed, I.; Kemppainen, N.; Villemagne, V. L.; O'Keefe, G.; Nagren, K.; Chaudhury, K. R.; Masters, C. L. & Brooks, D. J. (2008). Amyloid load in Parkinson's disease dementia and Lewy body dementia measured with [11C]PIB positron emission tomography. *Journal of Neurology, Neurosurgery, and Psychiatry*, Vol.79, No.12, pp. 1331-1338, ISSN 1468-330X; 0022-3050
- Emre, M.; Aarsland, D.; Brown, R.; Burn, D. J.; Duyckaerts, C.; Mizuno, Y.; Broe, G. A.; Cummings, J.; Dickson, D. W.; Gauthier, S.; Goldman, J.; Goetz, C.; Korczyn, A.; Lees, A.; Levy, R.; Litvan, I.; McKeith, I.; Olanow, W.; Poewe, W.; Quinn, N.; Sampaio, C.; Tolosa, E. & Dubois, B. (2007). Clinical diagnostic criteria for dementia associated with Parkinson's disease. *Movement Disorders : Official Journal of the Movement Disorder Society*, Vol.22, No.12, pp. 1689-707; quiz 1837, ISSN 0885-3185
- Farina, E.; Baglio, F.; Caffarra, P.; Magnani, G.; Scarpini, E.; Appollonio, I.; Bascelli, C.; Cheldi, A.; Nemni, R.; Franceschi, M.; Italian Group for Lewy Body Dementia and Dementias Associated to Parkinsonism; Messa, G.; Mantovani, F.; Bellotti, M.; Olivetto, F.; Alberoni, M.; Isella, V.; Regazzoni, R.; Schiatti, E.; Vismara, C.; Falautano, M.; Barbieri, A.; Restelli, I.; Fetoni, V.; Donato, M.; Zuffi, M. & Castiglioni, S. (2009). Frequency and clinical features of Lewy body dementia in Italian memory clinics. *Acta Bio-Medica : Atenei Parmensis*, Vol.80, No.1, pp. 57-64, ISSN 0392-4203; 0392-4203
- Firbank, M. J.; Blamire, A. M.; Krishnan, M. S.; Teodorczuk, A.; English, P.; Gholkar, A.; Harrison, R. & O'Brien, J. T. (2007a). Atrophy is associated with posterior cingulate

- white matter disruption in dementia with Lewy bodies and Alzheimer's disease. *NeuroImage*, Vol.36, No.1, pp. 1-7, ISSN 1053-8119; 1053-8119
- Firbank, M. J.; Blamire, A. M.; Krishnan, M. S.; Teodorczuk, A.; English, P.; Gholkar, A.; Harrison, R. M. & O'Brien, J. T. (2007b). Diffusion tensor imaging in dementia with Lewy bodies and Alzheimer's disease. *Psychiatry Research*, Vol.155, No.2, pp. 135-145, ISSN 0165-1781; 0165-1781
- Fodero-Tavoletti, M. T.; Smith, D. P.; McLean, C. A.; Adlard, P. A.; Barnham, K. J.; Foster, L. E.; Leone, L.; Perez, K.; Cortes, M.; Culvenor, J. G.; Li, Q. X.; Laughton, K. M.; Rowe, C. C.; Masters, C. L.; Cappai, R. & Villemagne, V. L. (2007). In vitro characterization of Pittsburgh compound-B binding to Lewy bodies. *The Journal of Neuroscience : The Official Journal of the Society for Neuroscience*, Vol.27, No.39, pp. 10365-10371, ISSN 1529-2401; 0270-6474
- Foster, E. R.; Campbell, M. C.; Burack, M. A.; Hartlein, J.; Flores, H. P.; Cairns, N. J.; Hershey, T. & Perlmuter, J. S. (2010). Amyloid imaging of Lewy body-associated disorders. *Movement Disorders : Official Journal of the Movement Disorder Society*, Vol.25, No.15, pp. 2516-2523, ISSN 1531-8257; 0885-3185
- Fox, P. T. & Raichle, M. E. (1985). Stimulus rate determines regional brain blood flow in striate cortex. *Annals of Neurology*, Vol.17, No.3, pp. 303-305, ISSN 0364-5134; 0364-5134
- Fox, P. T.; Mintun, M. A.; Raichle, M. E.; Miezin, F. M.; Allman, J. M. & Van Essen, D. C. (1986). Mapping human visual cortex with positron emission tomography. *Nature*, Vol.323, No.6091, pp. 806-809, ISSN 0028-0836; 0028-0836
- Frostig, R. D.; Lieke, E. E.; Ts'o, D. Y. & Grinvald, A. (1990). Cortical functional architecture and local coupling between neuronal activity and the microcirculation revealed by in vivo high-resolution optical imaging of intrinsic signals. *Proceedings of the National Academy of Sciences of the United States of America*, Vol.87, No.16, pp. 6082-6086, ISSN 0027-8424; 0027-8424
- Fujishiro, H.; Iseki, E.; Murayama, N.; Yamamoto, R.; Higashi, S.; Kasanuki, K.; Suzuki, M.; Arai, H. & Sato, K. (2010). Diffuse occipital hypometabolism on [18 F]-FDG PET scans in patients with idiopathic REM sleep behavior disorder: prodromal dementia with Lewy bodies? *Psychogeriatrics : The Official Journal of the Japanese Psychogeriatric Society*, Vol.10, No.3, pp. 144-152, ISSN 1479-8301; 1346-3500
- Gilman, S.; Koeppe, R. A.; Little, R.; An, H.; Junck, L.; Giordani, B.; Persad, C.; Heumann, M. & Wernette, K. (2005). Differentiation of Alzheimer's disease from dementia with Lewy bodies utilizing positron emission tomography with [18F]fluorodeoxyglucose and neuropsychological testing. *Experimental Neurology*, Vol.191 Suppl 1, pp. S95-S103, ISSN 0014-4886; 0014-4886
- Gomperts, S. N.; Rentz, D. M.; Moran, E.; Becker, J. A.; Locascio, J. J.; Klunk, W. E.; Mathis, C. A.; Elmaleh, D. R.; Shoup, T.; Fischman, A. J.; Hyman, B. T.; Growdon, J. H. & Johnson, K. A. (2008). Imaging amyloid deposition in Lewy body diseases. *Neurology*, Vol.71, No.12, pp. 903-910, ISSN 1526-632X; 0028-3878
- Goto, H.; Ishii, K.; Uemura, T.; Miyamoto, N.; Yoshikawa, T.; Shimada, K. & Ohkawa, S. (2010). Differential diagnosis of dementia with Lewy Bodies and Alzheimer Disease using combined MR imaging and brain perfusion single-photon emission tomography. *AJNR.American Journal of Neuroradiology*, Vol.31, No.4, pp. 720-725, ISSN 1936-959X; 0195-6108

- Hanyu, H.; Tanaka, Y.; Shimizu, S.; Sakurai, H.; Iwamoto, T. & Abe, K. (2005). Differences in MR features of the substantia innominata between dementia with Lewy bodies and Alzheimer's disease. *Journal of Neurology*, Vol.252, No.4, pp. 482-484, ISSN 0340-5354
- Hanyu, H.; Shimizu, S.; Hirao, K.; Kanetaka, H.; Sakurai, H.; Iwamoto, T.; Koizumi, K. & Abe, K. (2006a). Differentiation of dementia with Lewy bodies from Alzheimer's disease using Mini-Mental State Examination and brain perfusion SPECT. *Journal of the Neurological Sciences*, Vol.250, No.1-2, pp. 97-102, ISSN 0022-510X; 0022-510X
- Hanyu, H.; Shimizu, S.; Hirao, K.; Kanetaka, H.; Iwamoto, T.; Chikamori, T.; Usui, Y.; Yamashina, A.; Koizumi, K. & Abe, K. (2006b). Comparative value of brain perfusion SPECT and [(123)I]MIBG myocardial scintigraphy in distinguishing between dementia with Lewy bodies and Alzheimer's disease. *European Journal of Nuclear Medicine and Molecular Imaging*, Vol.33, No.3, pp. 248-253, ISSN 1619-7070; 1619-7070
- Hanyu, H.; Shimizu, S.; Tanaka, Y.; Hirao, K.; Iwamoto, T. & Abe, K. (2007). MR features of the substantia innominata and therapeutic implications in dementias. *Neurobiology of Aging*, Vol.28, No.4, pp. 548-554, ISSN 1558-1497; 0197-4580
- Heidebrink, J. L. (2002). Is dementia with Lewy bodies the second most common cause of dementia? *Journal of Geriatric Psychiatry and Neurology*, Vol.15, No.4, pp. 182-187, ISSN 0891-9887; 0891-9887
- Hentschel, F.; Kreis, M.; Damian, M.; Krumm, B. & Frolich, L. (2005). The clinical utility of structural neuroimaging with MRI for diagnosis and differential diagnosis of dementia: a memory clinic study. *International Journal of Geriatric Psychiatry*, Vol.20, No.7, pp. 645-650, ISSN 0885-6230
- Herholz, K.; Carter, S. F. & Jones, M. (2007). Positron emission tomography imaging in dementia. *The British Journal of Radiology*, Vol.80 Spec No 2, pp. S160-7, ISSN 1748-880X; 0007-1285
- Herrera, E., Jr; Caramelli, P.; Silveira, A. S. & Nitrini, R. (2002). Epidemiologic survey of dementia in a community-dwelling Brazilian population. *Alzheimer Disease and Associated Disorders*, Vol.16, No.2, pp. 103-108, ISSN 0893-0341
- Inui, Y.; Toyama, H.; Manabe, Y.; Sato, T.; Sarai, M.; Kosaka, K.; Iwata, N. & Katada, K. (2007). Evaluation of probable or possible dementia with lewy bodies using 123I-IMP brain perfusion SPECT, 123I-MIBG, and 99mTc-MIBI myocardial SPECT. *Journal of Nuclear Medicine : Official Publication, Society of Nuclear Medicine*, Vol.48, No.10, pp. 1641-1650, ISSN 0161-5505
- Kantarci, K.; Avula, R.; Senjem, M. L.; Samikoglu, A. R.; Zhang, B.; Weigand, S. D.; Przybelski, S. A.; Edmonson, H. A.; Vemuri, P.; Knopman, D. S.; Ferman, T. J.; Boeve, B. F.; Petersen, R. C. & Jack, C. R., Jr. (2010). Dementia with Lewy bodies and Alzheimer disease: neurodegenerative patterns characterized by DTI. *Neurology*, Vol.74, No.22, pp. 1814-1821, ISSN 1526-632X; 0028-3878
- Kasama, S.; Tachibana, H.; Kawabata, K. & Yoshikawa, H. (2005). Cerebral blood flow in Parkinson's disease, dementia with Lewy bodies, and Alzheimer's disease according to three-dimensional stereotactic surface projection imaging. *Dementia and Geriatric Cognitive Disorders*, Vol.19, No.5-6, pp. 266-275, ISSN 1420-8008; 1420-8008
- Kemp, P. M.; Hoffmann, S. A.; Holmes, C.; Bolt, L.; Ward, T.; Holmes, R. B. & Fleming, J. S. (2005). The contribution of statistical parametric mapping in the assessment of



- precuneal and medial temporal lobe perfusion by  $^{99m}\text{Tc}$ -HMPAO SPECT in mild Alzheimer's and Lewy body dementia. *Nuclear Medicine Communications*, Vol.26, No.12, pp. 1099-1106, ISSN 0143-3636
- Kemp, P. M. & Holmes, C. (2007). Imaging in dementia with Lewy bodies: a review. *Nuclear Medicine Communications*, Vol.28, No.7, pp. 511-519, ISSN 0143-3636
- Kiuchi, K.; Morikawa, M.; Taoka, T.; Kitamura, S.; Nagashima, T.; Makinodan, M.; Nakagawa, K.; Fukusumi, M.; Ikeshita, K.; Inoue, M.; Kichikawa, K. & Kishimoto, T. (2011). White matter changes in dementia with Lewy bodies and Alzheimer's disease: A tractography-based study. *Journal of Psychiatric Research*, ISSN 1879-1379; 0022-3956
- Klein, J. C.; Eggers, C.; Kalbe, E.; Weisenbach, S.; Hohmann, C.; Vollmar, S.; Baudrexel, S.; Diederich, N. J.; Heiss, W. D. & Hilker, R. (2010). Neurotransmitter changes in dementia with Lewy bodies and Parkinson disease dementia in vivo. *Neurology*, Vol.74, No.11, pp. 885-892, ISSN 1526-632X; 0028-3878
- Koepppe, R. A.; Gilman, S.; Joshi, A.; Liu, S.; Little, R.; Junck, L.; Heumann, M.; Frey, K. A. & Albin, R. L. (2005).  $^{11}\text{C}$ -DTBZ and  $^{18}\text{F}$ -FDG PET measures in differentiating dementias. *Journal of Nuclear Medicine : Official Publication, Society of Nuclear Medicine*, Vol.46, No.6, pp. 936-944, ISSN 0161-5505
- Lee, J. E.; Park, B.; Song, S. K.; Sohn, Y. H.; Park, H. J. & Lee, P. H. (2010a). A comparison of gray and white matter density in patients with Parkinson's disease dementia and dementia with Lewy bodies using voxel-based morphometry. *Movement Disorders : Official Journal of the Movement Disorder Society*, Vol.25, No.1, pp. 28-34, ISSN 1531-8257; 0885-3185
- Lee, J. E.; Park, H. J.; Park, B.; Song, S. K.; Sohn, Y. H.; Lee, J. D. & Lee, P. H. (2010b). A comparative analysis of cognitive profiles and white-matter alterations using voxel-based diffusion tensor imaging between patients with Parkinson's disease dementia and dementia with Lewy bodies. *Journal of Neurology, Neurosurgery, and Psychiatry*, Vol.81, No.3, pp. 320-326, ISSN 1468-330X; 0022-3050
- Lim, S. M.; Katsifis, A.; Villemagne, V. L.; Best, R.; Jones, G.; Saling, M.; Bradshaw, J.; Merory, J.; Woodward, M.; Hopwood, M. & Rowe, C. C. (2009). The  $^{18}\text{F}$ -FDG PET cingulate island sign and comparison to  $^{123}\text{I}$ -beta-CIT SPECT for diagnosis of dementia with Lewy bodies. *Journal of Nuclear Medicine : Official Publication, Society of Nuclear Medicine*, Vol.50, No.10, pp. 1638-1645, ISSN 1535-5667; 0161-5505
- Lippa, C. F.; Duda, J. E.; Grossman, M.; Hurtig, H. I.; Aarsland, D.; Boeve, B. F.; Brooks, D. J.; Dickson, D. W.; Dubois, B.; Emre, M.; Fahn, S.; Farmer, J. M.; Galasko, D.; Galvin, J. E.; Goetz, C. G.; Growdon, J. H.; Gwinn-Hardy, K. A.; Hardy, J.; Heutink, P.; Iwatsubo, T.; Kosaka, K.; Lee, V. M.; Leverenz, J. B.; Masliah, E.; McKeith, I. G.; Nussbaum, R. L.; Olanow, C. W.; Ravina, B. M.; Singleton, A. B.; Tanner, C. M.; Trojanowski, J. Q.; Wszolek, Z. K. & DLB/PDD Working Group. (2007). DLB and PDD boundary issues: diagnosis, treatment, molecular pathology, and biomarkers. *Neurology*, Vol.68, No.11, pp. 812-819, ISSN 1526-632X; 0028-3878
- Lobotesis, K.; Fenwick, J. D.; Phipps, A.; Ryman, A.; Swann, A.; Ballard, C.; McKeith, I. G. & O'Brien, J. T. (2001). Occipital hypoperfusion on SPECT in dementia with Lewy bodies but not AD. *Neurology*, Vol.56, No.5, pp. 643-649, ISSN 0028-3878; 0028-3878
- Logothetis, N. K. (2002). The neural basis of the blood-oxygen-level-dependent functional magnetic resonance imaging signal. *Philosophical Transactions of the Royal Society of*

- London. *Series B, Biological Sciences*, Vol.357, No.1424, pp. 1003-1037, ISSN 0962-8436; 0962-8436
- Maetzler, W.; Liepelt, I.; Reimold, M.; Reischl, G.; Solbach, C.; Becker, C.; Schulte, C.; Leyhe, T.; Keller, S.; Melms, A.; Gasser, T. & Berg, D. (2009). Cortical PIB binding in Lewy body disease is associated with Alzheimer-like characteristics. *Neurobiology of Disease*, Vol.34, No.1, pp. 107-112, ISSN 1095-953X; 0969-9961
- McKeith, I.; O'Brien, J.; Walker, Z.; Tatsch, K.; Booi, J.; Darcourt, J.; Padovani, A.; Giubbini, R.; Bonuccelli, U.; Volterrani, D.; Holmes, C.; Kemp, P.; Tabet, N.; Meyer, I.; Reininger, C. & DLB Study Group. (2007). Sensitivity and specificity of dopamine transporter imaging with 123I-FP-CIT SPECT in dementia with Lewy bodies: a phase III, multicentre study. *Lancet Neurology*, Vol.6, No.4, pp. 305-313, ISSN 1474-4422; 1474-4422
- McKeith, I. (2004). Dementia with Lewy bodies and other difficult diagnoses. *International Psychogeriatrics / IPA*, Vol.16, No.2, pp. 123-127, ISSN 1041-6102; 1041-6102
- McKeith, I. G.; Dickson, D. W.; Lowe, J.; Emre, M.; O'Brien, J. T.; Feldman, H.; Cummings, J.; Duda, J. E.; Lippa, C.; Perry, E. K.; Aarsland, D.; Arai, H.; Ballard, C. G.; Boeve, B.; Burn, D. J.; Costa, D.; Del Ser, T.; Dubois, B.; Galasko, D.; Gauthier, S.; Goetz, C. G.; Gomez-Tortosa, E.; Halliday, G.; Hansen, L. A.; Hardy, J.; Iwatsubo, T.; Kalaria, R. N.; Kaufer, D.; Kenny, R. A.; Korczyn, A.; Kosaka, K.; Lee, V. M.; Lees, A.; Litvan, I.; Londos, E.; Lopez, O. L.; Minoshima, S.; Mizuno, Y.; Molina, J. A.; Mukaetova-Ladinska, E. B.; Pasquier, F.; Perry, R. H.; Schulz, J. B.; Trojanowski, J. Q.; Yamada, M. & Consortium on DLB. (2005). Diagnosis and management of dementia with Lewy bodies: third report of the DLB Consortium. *Neurology*, Vol.65, No.12, pp. 1863-1872, ISSN 1526-632X; 0028-3878
- McKeith, I. G.; Galasko, D.; Kosaka, K.; Perry, E. K.; Dickson, D. W.; Hansen, L. A.; Salmon, D. P.; Lowe, J.; Mirra, S. S.; Byrne, E. J.; Lennox, G.; Quinn, N. P.; Edwardson, J. A.; Ince, P. G.; Bergeron, C.; Burns, A.; Miller, B. L.; Lovestone, S.; Collerton, D.; Jansen, E. N.; Ballard, C.; de Vos, R. A.; Wilcock, G. K.; Jellinger, K. A. & Perry, R. H. (1996). Consensus guidelines for the clinical and pathologic diagnosis of dementia with Lewy bodies (DLB): report of the consortium on DLB international workshop. *Neurology*, Vol.47, No.5, pp. 1113-1124, ISSN 0028-3878; 0028-3878
- Mito, Y.; Yoshida, K.; Yabe, I.; Makino, K.; Hirotani, M.; Tashiro, K.; Kikuchi, S. & Sasaki, H. (2005). Brain 3D-SSP SPECT analysis in dementia with Lewy bodies, Parkinson's disease with and without dementia, and Alzheimer's disease. *Clinical Neurology and Neurosurgery*, Vol.107, No.5, pp. 396-403, ISSN 0303-8467
- Miyazawa, N.; Shinohara, T.; Nagasaka, T. & Hayashi, M. (2010). Hypermetabolism in patients with dementia with Lewy bodies. *Clinical Nuclear Medicine*, Vol.35, No.7, pp. 490-493, ISSN 1536-0229; 0363-9762
- Mollenhauer, B.; Forstl, H.; Deuschl, G.; Storch, A.; Oertel, W. & Trenkwalder, C. (2010). Lewy body and parkinsonian dementia: common, but often misdiagnosed conditions. *Deutsches Arzteblatt International*, Vol.107, No.39, pp. 684-691, ISSN 1866-0452; 1866-0452
- Nagahama, Y.; Okina, T.; Suzuki, N. & Matsuda, M. (2010). Neural correlates of psychotic symptoms in dementia with Lewy bodies. *Brain : A Journal of Neurology*, Vol.133, No. Pt 2, pp. 557-567, ISSN 1460-2156; 0006-8950

- Nagahama, Y.; Okina, T.; Suzuki, N. & Matsuda, M. (2008). Cerebral substrates related to impaired performance in the clock-drawing test in dementia with Lewy bodies. *Dementia and Geriatric Cognitive Disorders*, Vol.25, No.6, pp. 524-530, ISSN 1421-9824; 1420-8008
- Novellino, F.; Bagnato, A.; Salzone, M.; Cascini, G. L.; Nicoletti, G.; Arabia, G.; Pugliese, P.; Morelli, M.; Paglionico, S.; Cipullo, S.; Manna, I.; De Marco, E. V.; Condino, F.; Chiriaco, C.; Morgante, L.; Zappia, M. & Quattrone, A. (2010). Myocardial (123)I-MIBG scintigraphy for differentiation of Lewy bodies disease from FTD. *Neurobiology of Aging*, Vol.31, No.11, pp. 1903-1911, ISSN 1558-1497; 0197-4580
- O'Brien, J. T.; McKeith, I. G.; Walker, Z.; Tatsch, K.; Booij, J.; Darcourt, J.; Marquardt, M.; Reininger, C. & DLB Study Group. (2009). Diagnostic accuracy of 123I-FP-CIT SPECT in possible dementia with Lewy bodies. *The British Journal of Psychiatry : The Journal of Mental Science*, Vol.194, No.1, pp. 34-39, ISSN 1472-1465; 0007-1250
- O'Brien, J. T.; Colloby, S. J.; Pakrasi, S.; Perry, E. K.; Pimlott, S. L.; Wyper, D. J.; McKeith, I. G. & Williams, E. D. (2008). Nicotinic alpha4beta2 receptor binding in dementia with Lewy bodies using 123I-5IA-85380 SPECT demonstrates a link between occipital changes and visual hallucinations. *NeuroImage*, Vol.40, No.3, pp. 1056-1063, ISSN 1053-8119; 1053-8119
- O'Brien, J. T. (2007). Role of imaging techniques in the diagnosis of dementia. *The British Journal of Radiology*, Vol.80 Spec No 2, pp. S71-7, ISSN 1748-880X; 0007-1285
- O'Brien, J. T.; Firbank, M. J.; Mosimann, U. P.; Burn, D. J. & McKeith, I. G. (2005). Change in perfusion, hallucinations and fluctuations in consciousness in dementia with Lewy bodies. *Psychiatry Research*, Vol.139, No.2, pp. 79-88, ISSN 0165-1781; 0165-1781
- Ogawa, S.; Lee, T. M.; Kay, A. R. & Tank, D. W. (1990a). Brain magnetic resonance imaging with contrast dependent on blood oxygenation. *Proceedings of the National Academy of Sciences of the United States of America*, Vol.87, No.24, pp. 9868-9872, ISSN 0027-8424; 0027-8424
- Ogawa, S.; Lee, T. M.; Nayak, A. S. & Glynn, P. (1990b). Oxygenation-sensitive contrast in magnetic resonance image of rodent brain at high magnetic fields. *Magnetic Resonance in Medicine : Official Journal of the Society of Magnetic Resonance in Medicine / Society of Magnetic Resonance in Medicine*, Vol.14, No.1, pp. 68-78, ISSN 0740-3194; 0740-3194
- Ogawa, S.; Menon, R. S.; Tank, D. W.; Kim, S. G.; Merkle, H.; Ellermann, J. M. & Ugurbil, K. (1993). Functional brain mapping by blood oxygenation level-dependent contrast magnetic resonance imaging. A comparison of signal characteristics with a biophysical model. *Biophysical Journal*, Vol.64, No.3, pp. 803-812, ISSN 0006-3495; 0006-3495
- Ogawa, S.; Menon, R. S.; Kim, S. G. & Ugurbil, K. (1998). On the characteristics of functional magnetic resonance imaging of the brain. *Annual Review of Biophysics and Biomolecular Structure*, Vol.27, pp. 447-474, ISSN 1056-8700; 1056-8700
- Ota, M.; Sato, N.; Ogawa, M.; Murata, M.; Kuno, S.; Kida, J. & Asada, T. (2009). Degeneration of dementia with Lewy bodies measured by diffusion tensor imaging. *NMR in Biomedicine*, Vol.22, No.3, pp. 280-284, ISSN 0952-3480; 0952-3480
- Perneczky, R.; Drzezga, A.; Boecker, H.; Forstl, H.; Kurz, A. & Haussermann, P. (2008a). Cerebral metabolic dysfunction in patients with dementia with Lewy bodies and

- visual hallucinations. *Dementia and Geriatric Cognitive Disorders*, Vol.25, No.6, pp. 531-538, ISSN 1421-9824; 1420-8008
- Perneczky, R.; Drzezga, A.; Boecker, H.; Ceballos-Baumann, A. O.; Granert, O.; Forstl, H.; Kurz, A. & Haussermann, P. (2008b). Activities of daily living, cerebral glucose metabolism, and cognitive reserve in Lewy body and Parkinson's disease. *Dementia and Geriatric Cognitive Disorders*, Vol.26, No.5, pp. 475-481, ISSN 1421-9824; 1420-8008
- Perneczky, R.; Haussermann, P.; Drzezga, A.; Boecker, H.; Granert, O.; Feurer, R.; Forstl, H. & Kurz, A. (2009a). Fluoro-deoxy-glucose positron emission tomography correlates of impaired activities of daily living in dementia with Lewy bodies: implications for cognitive reserve. *The American Journal of Geriatric Psychiatry : Official Journal of the American Association for Geriatric Psychiatry*, Vol.17, No.3, pp. 188-195, ISSN 1545-7214; 1064-7481
- Perneczky, R.; Drzezga, A.; Boecker, H.; Wagenpfeil, S.; Forstl, H.; Kurz, A. & Haussermann, P. (2009b). Right prefrontal hypometabolism predicts delusions in dementia with Lewy bodies. *Neurobiology of Aging*, Vol.30, No.9, pp. 1420-1429, ISSN 1558-1497; 0197-4580
- Perneczky, R.; Drzezga, A.; Boecker, H.; Ceballos-Baumann, A. O.; Valet, M.; Feurer, R.; Forstl, H.; Kurz, A. & Haussermann, P. (2010). Metabolic alterations associated with impaired clock drawing in Lewy body dementia. *Psychiatry Research*, Vol.181, No.2, pp. 85-89, ISSN 0165-1781; 0165-1781
- Perry, R. H.; Irving, D. & Tomlinson, B. E. (1990). Lewy body prevalence in the aging brain: relationship to neuropsychiatric disorders, Alzheimer-type pathology and catecholaminergic nuclei. *Journal of the Neurological Sciences*, Vol.100, No.1-2, pp. 223-233, ISSN 0022-510X; 0022-510X
- Piggott, M. A.; Marshall, E. F.; Thomas, N.; Lloyd, S.; Court, J. A.; Jaros, E.; Burn, D.; Johnson, M.; Perry, R. H.; McKeith, I. G.; Ballard, C. & Perry, E. K. (1999). Striatal dopaminergic markers in dementia with Lewy bodies, Alzheimer's and Parkinson's diseases: rostrocaudal distribution. *Brain : A Journal of Neurology*, Vol.122 ( Pt 8), No.Pt 8, pp. 1449-1468, ISSN 0006-8950; 0006-8950
- Rahkonen, T.; Eloniemi-Sulkava, U.; Rissanen, S.; Vatanen, A.; Viramo, P. & Sulkava, R. (2003). Dementia with Lewy bodies according to the consensus criteria in a general population aged 75 years or older. *Journal of Neurology, Neurosurgery, and Psychiatry*, Vol.74, No.6, pp. 720-724, ISSN 0022-3050; 0022-3050
- Roselli, F.; Pisciotto, N. M.; Perneczky, R.; Pennelli, M.; Aniello, M. S.; De Caro, M. F.; Ferrannini, E.; Tartaglione, B.; Defazio, G.; Rubini, G. & Livrea, P. (2009). Severity of neuropsychiatric symptoms and dopamine transporter levels in dementia with Lewy bodies: a 123I-FP-CIT SPECT study. *Movement Disorders : Official Journal of the Movement Disorder Society*, Vol.24, No.14, pp. 2097-2103, ISSN 1531-8257; 0885-3185
- Rossi, C.; Volterrani, D.; Nicoletti, V.; Manca, G.; Frosini, D.; Kiferle, L.; Unti, E.; De Feo, P.; Bonuccelli, U. & Ceravolo, R. (2009). "Parkinson-dementia" diseases: a comparison by double tracer SPECT studies. *Parkinsonism & Related Disorders*, Vol.15, No.10, pp. 762-766, ISSN 1873-5126; 1353-8020
- Sanchez-Castaneda, C.; Rene, R.; Ramirez-Ruiz, B.; Campdelacreu, J.; Gascon, J.; Falcon, C.; Calopa, M.; Jauma, S.; Juncadella, M. & Junque, C. (2009). Correlations between gray matter reductions and cognitive deficits in dementia with Lewy Bodies and



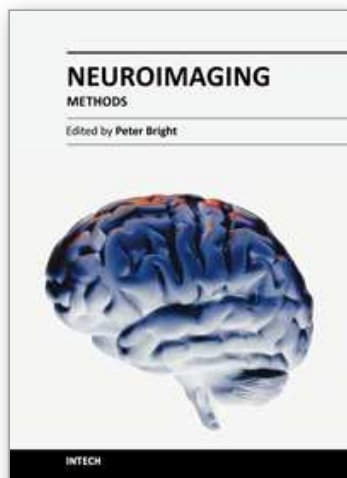
- Parkinson's disease with dementia. *Movement Disorders : Official Journal of the Movement Disorder Society*, Vol.24, No.12, pp. 1740-1746, ISSN 1531-8257; 0885-3185
- Sanchez-Castaneda, C.; Rene, R.; Ramirez-Ruiz, B.; Campdelacreu, J.; Gascon, J.; Falcon, C.; Calopa, M.; Jauma, S.; Juncadella, M. & Junque, C. (2010). Frontal and associative visual areas related to visual hallucinations in dementia with Lewy bodies and Parkinson's disease with dementia. *Movement Disorders : Official Journal of the Movement Disorder Society*, Vol.25, No.5, pp. 615-622, ISSN 1531-8257; 0885-3185
- Satoh, M.; Ishikawa, H.; Meguro, K.; Kasuya, M.; Ishii, H. & Yamaguchi, S. (2010). Improved visual hallucination by donepezil and occipital glucose metabolism in dementia with Lewy bodies: the Osaka-Tajiri project. *European Neurology*, Vol.64, No.6, pp. 337-344, ISSN 1421-9913; 0014-3022
- Sauer, J.; ffytche, D. H.; Ballard, C.; Brown, R. G. & Howard, R. (2006). Differences between Alzheimer's disease and dementia with Lewy bodies: an fMRI study of task-related brain activity. *Brain : A Journal of Neurology*, Vol.129, No.Pt 7, pp. 1780-1788, ISSN 1460-2156; 0006-8950
- Shimizu, S.; Hanyu, H.; Kanetaka, H.; Iwamoto, T.; Koizumi, K. & Abe, K. (2005). Differentiation of dementia with Lewy bodies from Alzheimer's disease using brain SPECT. *Dementia and Geriatric Cognitive Disorders*, Vol.20, No.1, pp. 25-30, ISSN 1420-8008; 1420-8008
- Shimizu, S.; Hanyu, H.; Hirao, K.; Sato, T.; Iwamoto, T. & Koizumi, K. (2008). Value of analyzing deep gray matter and occipital lobe perfusion to differentiate dementia with Lewy bodies from Alzheimer's disease. *Annals of Nuclear Medicine*, Vol.22, No.10, pp. 911-916, ISSN 0914-7187; 0914-7187
- Soret, M.; Koulibaly, P. M.; Darcourt, J. & Buvat, I. (2006). Partial volume effect correction in SPECT for striatal uptake measurements in patients with neurodegenerative diseases: impact upon patient classification. *European Journal of Nuclear Medicine and Molecular Imaging*, Vol.33, No.9, pp. 1062-1072, ISSN 1619-7070; 1619-7070
- Stevens, T.; Livingston, G.; Kitchen, G.; Manela, M.; Walker, Z. & Katona, C. (2002). Islington study of dementia subtypes in the community. *The British Journal of Psychiatry : The Journal of Mental Science*, Vol.180, pp. 270-276, ISSN 0007-1250; 0007-1250
- Summerfield, C.; Junque, C.; Tolosa, E.; Salgado-Pineda, P.; Gomez-Anson, B.; Marti, M. J.; Pastor, P.; Ramirez-Ruiz, B. & Mercader, J. (2005). Structural brain changes in Parkinson disease with dementia: a voxel-based morphometry study. *Archives of Neurology*, Vol.62, No.2, pp. 281-285, ISSN 0003-9942; 0003-9942
- Suzuki, M.; Desmond, T. J.; Albin, R. L. & Frey, K. A. (2002). Striatal monoaminergic terminals in Lewy body and Alzheimer's dementias. *Annals of Neurology*, Vol.51, No.6, pp. 767-771, ISSN 0364-5134; 0364-5134
- Takahashi, R.; Ishii, K.; Miyamoto, N.; Yoshikawa, T.; Shimada, K.; Ohkawa, S.; Kakigi, T. & Yokoyama, K. (2010). Measurement of gray and white matter atrophy in dementia with Lewy bodies using diffeomorphic anatomic registration through exponentiated lie algebra: A comparison with conventional voxel-based morphometry. *AJNR.American Journal of Neuroradiology*, Vol.31, No.10, pp. 1873-1878, ISSN 1936-959X; 0195-6108
- Takahashi, R.; Ishii, K.; Shimada, K.; Ohkawa, S. & Nishimura, Y. (2010). Hypoperfusion of the motor cortex associated with parkinsonism in dementia with Lewy bodies.

- Journal of the Neurological Sciences*, Vol.288, No.1-2, pp. 88-91, ISSN 1878-5883; 0022-510X
- Tam, C. W.; Burton, E. J.; McKeith, I. G.; Burn, D. J. & O'Brien, J. T. (2005). Temporal lobe atrophy on MRI in Parkinson disease with dementia: a comparison with Alzheimer disease and dementia with Lewy bodies. *Neurology*, Vol.64, No.5, pp. 861-865, ISSN 1526-632X; 0028-3878
- Tartaglia, M. C.; Rosen, H. J. & Miller, B. L. (2011). Neuroimaging in dementia. *Neurotherapeutics : The Journal of the American Society for Experimental NeuroTherapeutics*, Vol.8, No.1, pp. 82-92, ISSN 1878-7479; 1878-7479
- Tateno, M.; Utsumi, K.; Kobayashi, S.; Takahashi, A.; Saitoh, M.; Morii, H.; Fujii, K. & Teraoka, M. (2008a). Usefulness of a blood flow analyzing program 3DSRT to detect occipital hypoperfusion in dementia with Lewy bodies. *Progress in Neuro-Psychopharmacology & Biological Psychiatry*, Vol.32, No.5, pp. 1206-1209, ISSN 0278-5846; 0278-5846
- Tateno, M.; Kobayashi, S.; Shirasaka, T.; Furukawa, Y.; Fujii, K.; Morii, H.; Yasumura, S.; Utsumi, K. & Saito, T. (2008b). Comparison of the usefulness of brain perfusion SPECT and MIBG myocardial scintigraphy for the diagnosis of dementia with Lewy bodies. *Dementia and Geriatric Cognitive Disorders*, Vol.26, No.5, pp. 453-457, ISSN 1421-9824; 1420-8008
- van Zijl, P. C.; Eleff, S. M.; Ulatowski, J. A.; Oja, J. M.; Ulug, A. M.; Traystman, R. J. & Kauppinen, R. A. (1998). Quantitative assessment of blood flow, blood volume and blood oxygenation effects in functional magnetic resonance imaging. *Nature Medicine*, Vol.4, No.2, pp. 159-167, ISSN 1078-8956; 1078-8956
- von Gunten, A. & Meuli, R. (2009). Delineating dementia with lewy bodies: can magnetic resonance imaging help? *Frontiers of Neurology and Neuroscience*, Vol.24, pp. 126-134, ISSN 1660-4431; 0300-5186
- Walker, Z.; Jaros, E.; Walker, R. W.; Lee, L.; Costa, D. C.; Livingston, G.; Ince, P. G.; Perry, R.; McKeith, I. & Katona, C. L. (2007). Dementia with Lewy bodies: a comparison of clinical diagnosis, FP-CIT single photon emission computed tomography imaging and autopsy. *Journal of Neurology, Neurosurgery, and Psychiatry*, Vol.78, No.11, pp. 1176-1181, ISSN 1468-330X; 0022-3050
- Walker, R. W. & Walker, Z. (2009). Dopamine transporter single photon emission computerized tomography in the diagnosis of dementia with Lewy bodies. *Movement Disorders : Official Journal of the Movement Disorder Society*, Vol.24 Suppl 2, pp. S754-9, ISSN 1531-8257; 0885-3185
- Watson, R.; Blamire, A. M. & O'Brien, J. T. (2009). Magnetic resonance imaging in lewy body dementias. *Dementia and Geriatric Cognitive Disorders*, Vol.28, No.6, pp. 493-506, ISSN 1421-9824; 1420-8008
- Weisskoff, R. M.; Zuo, C. S.; Boxerman, J. L. & Rosen, B. R. (1994). Microscopic susceptibility variation and transverse relaxation: theory and experiment. *Magnetic Resonance in Medicine : Official Journal of the Society of Magnetic Resonance in Medicine / Society of Magnetic Resonance in Medicine*, Vol.31, No.6, pp. 601-610, ISSN 0740-3194; 0740-3194
- Whitwell, J. L.; Weigand, S. D.; Shiung, M. M.; Boeve, B. F.; Ferman, T. J.; Smith, G. E.; Knopman, D. S.; Petersen, R. C.; Benarroch, E. E.; Josephs, K. A. & Jack, C. R., Jr. (2007). Focal atrophy in dementia with Lewy bodies on MRI: a distinct pattern from

- Alzheimer's disease. *Brain : A Journal of Neurology*, Vol.130, No.Pt 3, pp. 708-719, ISSN 1460-2156; 0006-8950
- Yamada, T.; Hattori, H.; Miura, A.; Tanabe, M. & Yamori, Y. (2001). Prevalence of Alzheimer's disease, vascular dementia and dementia with Lewy bodies in a Japanese population. *Psychiatry and Clinical Neurosciences*, Vol.55, No.1, pp. 21-25, ISSN 1323-1316; 1323-1316
- Yamada, T.; Kadekaru, H.; Matsumoto, S.; Inada, H.; Tanabe, M.; Moriguchi, E. H.; Moriguchi, Y.; Ishikawa, P.; Ishikawa, A. G.; Taira, K. & Yamori, Y. (2002). Prevalence of dementia in the older Japanese-Brazilian population. *Psychiatry and Clinical Neurosciences*, Vol.56, No.1, pp. 71-75, ISSN 1323-1316; 1323-1316
- Yong, S. W.; Yoon, J. K.; An, Y. S. & Lee, P. H. (2007). A comparison of cerebral glucose metabolism in Parkinson's disease, Parkinson's disease dementia and dementia with Lewy bodies. *European Journal of Neurology : The Official Journal of the European Federation of Neurological Societies*, Vol.14, No.12, pp. 1357-1362, ISSN 1468-1331; 1351-5101
- Zaccai, J.; McCracken, C. & Brayne, C. (2005). A systematic review of prevalence and incidence studies of dementia with Lewy bodies. *Age and Ageing*, Vol.34, No.6, pp. 561-566, ISSN 0002-0729; 0002-0729

IntechOpen





## **Neuroimaging - Methods**

Edited by Prof. Peter Bright

ISBN 978-953-51-0097-3

Hard cover, 358 pages

**Publisher** InTech

**Published online** 17, February, 2012

**Published in print edition** February, 2012

Neuroimaging methodologies continue to develop at a remarkable rate, providing ever more sophisticated techniques for investigating brain structure and function. The scope of this book is not to provide a comprehensive overview of methods and applications but to provide a 'snapshot' of current approaches using well established and newly emerging techniques. Taken together, these chapters provide a broad sense of how the limits of what is achievable with neuroimaging methods are being stretched.

### **How to reference**

In order to correctly reference this scholarly work, feel free to copy and paste the following:

Francesca Baglio, Maria Giulia Preti and Elisabetta Farina (2012). Neuroimaging Findings in Dementia with Lewy Body: A Review, Neuroimaging - Methods, Prof. Peter Bright (Ed.), ISBN: 978-953-51-0097-3, InTech, Available from: <http://www.intechopen.com/books/neuroimaging-methods/neuroimaging-findings-in-dementia-with-lewy-body-a-review->

**INTech**  
open science | open minds

### **InTech Europe**

University Campus STeP Ri  
Slavka Krautzeka 83/A  
51000 Rijeka, Croatia  
Phone: +385 (51) 770 447  
Fax: +385 (51) 686 166  
[www.intechopen.com](http://www.intechopen.com)

### **InTech China**

Unit 405, Office Block, Hotel Equatorial Shanghai  
No.65, Yan An Road (West), Shanghai, 200040, China  
中国上海市延安西路65号上海国际贵都大饭店办公楼405单元  
Phone: +86-21-62489820  
Fax: +86-21-62489821

© 2012 The Author(s). Licensee IntechOpen. This is an open access article distributed under the terms of the [Creative Commons Attribution 3.0 License](https://creativecommons.org/licenses/by/3.0/), which permits unrestricted use, distribution, and reproduction in any medium, provided the original work is properly cited.

IntechOpen

IntechOpen