

We are IntechOpen, the world's leading publisher of Open Access books Built by scientists, for scientists

6,900

Open access books available

186,000

International authors and editors

200M

Downloads

Our authors are among the

154

Countries delivered to

TOP 1%

most cited scientists

12.2%

Contributors from top 500 universities



WEB OF SCIENCE™

Selection of our books indexed in the Book Citation Index
in Web of Science™ Core Collection (BKCI)

Interested in publishing with us?
Contact book.department@intechopen.com

Numbers displayed above are based on latest data collected.
For more information visit www.intechopen.com



Pathogenicity of Avian Paramyxovirus Serotype-3 in Chickens and Turkeys

Sachin Kumar and Siba K. Samal

Virginia-Maryland Regional College of Veterinary Medicine,
University of Maryland, College Park,
Maryland,
USA

1. Introduction

Members of the family *Paramyxoviridae* are pleomorphic enveloped viruses that contain a single-stranded, non-segmented RNA genome of 13-19 kilobases (Lamb and Parks, 2007). These viruses have been isolated from many species of avian, terrestrial and aquatic animals around the world. Some members of the family *Paramyxoviridae* are well known human (measles, mumps, respiratory syncytial virus and various human parainfluenza viruses) and animal (rinderpest virus, canine distemper virus and Newcastle disease virus [NDV]) pathogens, while the pathogenic potential of many others is still unknown. The family is divided into two subfamilies, *Paramyxovirinae* and *Pneumovirinae*. Subfamily *Paramyxovirinae* is further divided into five genera: *Rubulavirus*, *Respirovirus*, *Henipavirus*, *Morbillivirus* and *Avulavirus*. Subfamily *Pneumovirinae* is divided into two genera: *Pneumovirus* and *Metapneumovirus* (Mayo, 2002).

All paramyxoviruses that have been isolated to date from avian species are placed in the genus *Avulavirus* except for avian metapneumoviruses which are placed in the genus *Metapneumovirus* due to antigenic differences and differences in genetic organization. The avian paramyxoviruses (APMV) that comprise genus *Avulavirus* have been divided into nine different serotypes (APMV-1 through -9) based on haemagglutination inhibition (HI) and neuraminidase inhibition (NI) assays (Alexander and Collins, 1984). APMV-1 comprises all strains of NDV and is the most characterized serotype due to the severity of disease caused by virulent NDV strains in chickens. (Alexander, 1980a). The complete genome sequences and the molecular determinants of virulence have been determined for representative NDV strains (Krishnamurthy and Samal, 1998; de Leeuw and Peeters, 1999; Huang et al., 2004; Panda et al., 2004; Rout and Samal, 2008). As a first step in characterizing the other APMV serotypes, complete genome sequences of one or more representatives of APMV serotypes 2 to 9 were recently determined, expanding our knowledge about these viruses (Chang et al., 2001; Kumar et al., 2008; Nayak et al., 2008; Subbiah et al., 2008; Paldurai et al., 2009; Samuel et al., 2009; Xiao et al., 2009).

NDV causes respiratory, neurological or enteric disease in birds. Among poultry, chickens are the most susceptible while geese and ducks are the least susceptible (Wakamatsu et al.,

2006). NDV strains are classified into low virulent (lentogenic), moderately virulent (mesogenic), and highly virulent (velogenic) pathotypes based on severity of disease produced in chickens. In contrast very little is known about pathogenicity of APMV-2 to -9 in chickens and turkeys. APMV-2 has been shown to cause mild disease and drop in egg production in chickens and turkeys (Warke et al., 2008). APMV-6 and -7 have been associated with respiratory disease in turkeys (Shortridge et al., 1980; Saif et al., 1997). APMV-4, -8 and -9 have been isolated from different species of birds but the clinical signs of the disease in those birds were not apparent (Alexander et al., 1983; Gough and Alexander, 1984; Stallknecht et al., 1991; Maldonado et al., 1995; Capua et al., 2004). Recently, experimental infection of 1-day-old chicks with APMV-2, -4 and -6 showed viral infection in gastrointestinal tract, respiratory tract and pancreas (Warke et al., 2008).

APMV-3 has been isolated from wild and domesticated birds in different parts of the world (Tumova et al., 1979b; Alexander, 1980b; Macpherson et al., 1983; Alexander, 2003). Recently, APMV-3 was isolated from ostrich, indicating a wide host range for the virus (Kaleta et al.). The virus has been isolated from diseased turkeys associated with coughing, nasal discharge and swelling of the infra-orbital sinus (Redmann et al., 1991). APMV-3 has been associated with encephalitis and high mortality in caged birds (Tumova et al., 1979a). The virus causes acute pancreatitis and central nervous system (CNS) symptoms in *Psittacine* and *Passerine* birds (Beck et al., 2003). APMV-3 also infects chickens at an early age, with evidence of stunting growth that may be more marked in broiler chicken breeds (Alexander and Collins, 1982a). In terms of pathogenicity to domestic poultry birds, APMV-3 probably is second in importance to NDV. The exact economic impact of APMV-3 infection in poultry industry is not known. This is partly because the pathogenicity of APMV-3 in poultry is not well studied. There is a high degree of amino acid sequence variation between APMV-3 and APMV-1 (NDV), but by the HI test there is low level of cross reaction between APMV-3 and APMV-1 serum samples, which often leads to misdiagnosis of APMV-3 as APMV-1.

APMV-3 strain Wisconsin was first isolated from a turkey in 1968 in Wisconsin (Tumova et al., 1979b). APMV-3 strain Netherlands was isolated from a parakeet in 1975 in the Netherlands and is the prototype for the entire serotype (Alexander and Chettle, 1978). Initially, these two viruses were considered as two different strains of APMV-3 based on cross HI test using monoclonal antibodies (Anderson et al., 1987; Anderson and Russell, 1988). Recently, reciprocal cross HI and cross neutralization assays using post infection serum from chicken indicated that these two strains are antigenically distinct, although the difference was modest (Kumar et al., 2010b). However, complete genome sequence analysis revealed substantial genome-wide nucleotide and amino acid sequence differences that are consistent with the two strains representing distinct antigenic subgroups (Kumar et al., 2008; Kumar et al., 2010b). We have performed experimental infection of APMV-3 strains Wisconsin and Netherlands in 9-day-old embryonated chicken eggs, 1-day-old chicks and turkeys, and 2-week-old chickens and turkeys in order to investigate their tropism and pathogenicity. Birds were infected by the oculonasal route and the viral tropism and replication efficiency were evaluated by quantitative virology and immunohistochemistry of a wide range of possible target organs. In addition, a separate group of 1-day old chicks were infected intracerebrally to evaluate the potential of these viruses to replicate in neuronal tissue.

2. Methods used in the study

2.1 Viruses and cells

APMV-3 strains parakeet/Netherlands/449/75 and turkey/Wisconsin/68 (obtained from National Veterinary Service Laboratory, Ames, Iowa, USA) was propagated in 9-day-old specific pathogen free (SPF) embryonated chicken eggs via allantoic route of inoculation. The allantoic fluids from infected embryonated eggs were collected 96 h post-inoculation and virus titer was determined by hemagglutination (HA) assay with 0.5% chicken RBC. The virus titer in infected tissue samples was determined by the tissue culture infective dose (TCID₅₀) method and by plaque assay in chicken embryo fibroblast (DF-1) cells (ATCC, Manassas, VA, USA) (Reed and Muench, 1938). For the plaque assay, DF-1 cell monolayers in 12 well plates were infected with different dilutions of tissue homogenates. The tissue homogenates were allowed to adsorb for 1 h at 37 °C, washed with phosphate-buffered saline (PBS), and then overlaid with 1 mL DMEM containing 0.8% (wt/vol) methylcellulose. The virus plaques in the DF-1 cell monolayer were visualized 96 h PI after staining with 1% crystal violet.

2.2 Pathogenicity index tests

The pathogenicity of the APMV-3 strains Netherlands and Wisconsin was determined by two standard pathogenicity tests. These included the mean death time (MDT) in 9-day-old embryonated SPF chicken eggs and the intracerebral pathogenicity index (ICPI) in 1-day-old SPF chick (Alexander, 1998).

MDT value was determined following the standard procedure (Alexander, 1998). Briefly, a series of 10-fold (10^{-6} to 10^{-12}) dilutions of fresh infective allantoic fluid in sterile PBS were made and 0.1 mL of each dilution was inoculated into the allantoic cavities of five 9-day-old embryonated SPF chicken eggs, which were then incubated at 37 °C. Each egg was examined three times daily for 7 days, and the times of embryo deaths were recorded. The minimum lethal dose is the highest virus dilution that caused death of all the embryos. MDT is the mean time in hours for the minimum lethal dose to kill all inoculated embryos. The MDT has been used to characterize the NDV pathotypes as follows: velogenic (less than 60 h), mesogenic (60 to 90 h), and lentogenic (more than 90 h) (Alexander, 1980b).

For determining ICPI value, 0.05 mL of 1:10 dilution of fresh infective allantoic fluid (2^8 HA units) of each virus was inoculated into groups of 10 one-day-old SPF chicks via the intracerebral route. The birds were observed for clinical symptoms and mortality every 8 h for a period of 8 days. At each observation, the birds were scored as follows: 0, healthy; 1, sick; and 2, dead. The ICPI is the mean score for all of the birds in the group over the 8-day period. Highly virulent NDV (velogenic) viruses give values approaching 2 and avirulent NDV (lentogenic) viruses give values close to 0 (Alexander, 1998).

2.3 Pathogenesis assessment in chickens and turkeys

1-day-old and 2-week-old SPF chickens (Charles River, North Franklin, Connecticut, USA) and 1-day-old and 2-week-old turkeys (Murry-McMurry hatchery, Webster City, Iowa, USA) were housed in positive pressure isolators in our BSL-2 facility. Birds confirmed to be negative for APMV-3 specific antibody by HI assay were further selected for pathogenesis

experiments and housed in negative pressure isolators. The 1-day-old and 2-week-old chickens and turkeys, in groups of 12 for each species and age, were infected with 0.1 mL (10^3 PFU) per bird of APMV-3 strain Netherlands or Wisconsin through the oculonasal route. Infections with the different strains were performed at separate times to avoid cross infections. An additional six birds of each species/age group remained as uninfected controls and sacrificed 14 day post infection (DPI) after collection of serum. Birds were provided with food and water *ad libitum* and monitored daily for any visible signs and symptoms twice daily. Three birds from each infected group were euthanized on 3, 5, 7 and 14 DPI by rapid asphyxiation in a CO₂ chamber. The birds were swabbed orally and cloacally just before euthanasia. The following tissue samples were collected both for IHC and for virus isolation: brain, trachea, lung, spleen, kidney and pancreas. In addition serum samples were collected on day 14 when the three remaining birds in each group and the control birds were euthanized. Seroconversion was evaluated by HI assay (Alexander, 1980b).

3. Pathogenicity of avian paramyxovirus serotype-3

The mean death time (MDT) for APMV-3 strain Netherlands was 112 hr while that of APMV-3 strain Wisconsin was > 168 hr. The intracerebral pathogenicity index (ICPI) value for APMV-3 strain Netherlands was 0.39, while the ICPI for APMV-3 strain Wisconsin was zero, consistent with a lentogenic virus. Although, the ICPI and MDT values of strain Netherlands were higher than those of strain Wisconsin; their values indicate that both the APMV-3 strains are lentogenic viruses. These results indicated that APMV-3 strain Netherlands and Wisconsin are probably not highly pathogenic to chickens, similar to lentogenic NDV strains (Kumar et al., 2010a).

In order to evaluate the ability of APMV-3 to replicate in neuronal tissue, 1×10^3 PFU of each APMV-3 strain was inoculated intracerebrally into 1-day-old chicks. Our results showed that neither of the two APMV-3 strains produced any clinical signs nor did they kill any chicks during 5 DPI. Both of the APMV-3 strains were isolated from the brain homogenates of all of the chicks on days 1 to 5 day post inoculation, grew with similar kinetics, and reached similar maximum titers (Kumar et al., 2010a). Interestingly, while both the APMV-3 strains replicated more slowly than moderately virulent NDV, they achieved a similar final titer compared to NDV, but without causing noticeable neurological disease and with no mortality (Kumar et al., 2010a).

Infection of either APMV-3 strain in 1-day-old chickens and turkeys resulted in mild clinical signs that included altered gait, respiratory distress, dullness, ruffled-feathers, loss of appetite and weight loss. The other visible signs included diarrhea that was evident in 1-day-old chickens and turkeys at 4 DPI. The neurological signs were more evident in 1-day-old chicks and turkeys infected with APMV-3 strain Netherlands as compared to strain Wisconsin. In contrast, infection of 2-week-old chickens and turkeys with the APMV-3 strains did not result in any apparent clinical signs of disease. APMV-3 infection did not kill any of the 1-day-old or 2-week-old chickens and turkeys. The most remarkable finding upon postmortem examination of birds was enlargement of the pancreas with focal necrosis in the 2-week-old chickens and turkeys (Fig. 1). The foci of necrosis were distributed along the entire length of pancreas and the extent of necrosis was similar in both chickens and

turkeys. Gross examination of other organs including the brain, trachea, liver, kidney, spleen and lung showed normal tissue morphology with no noticeable gross lesions.

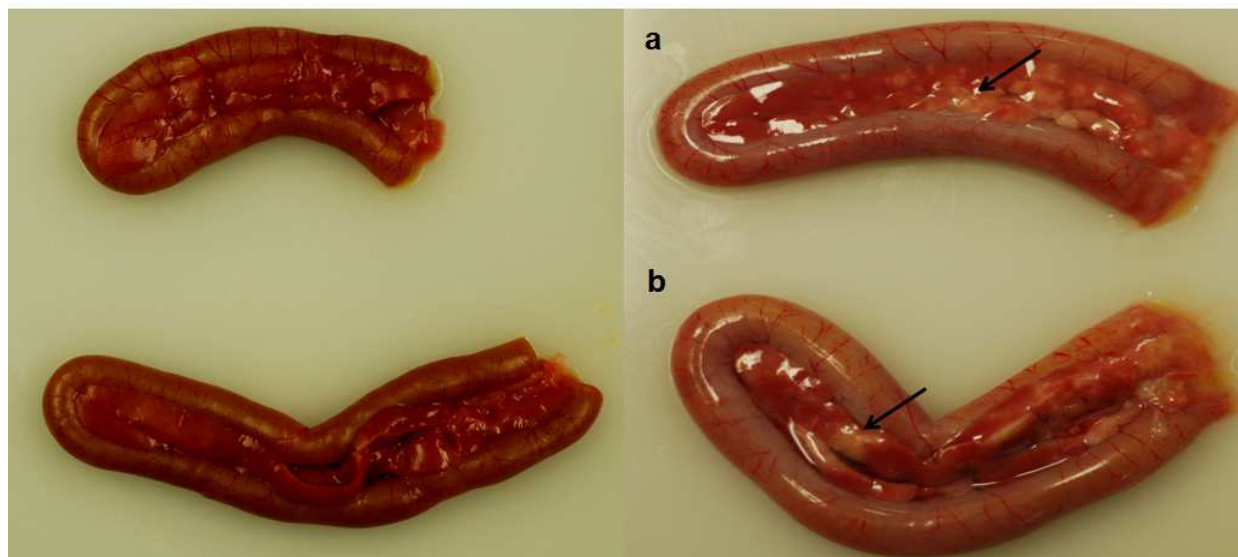


Fig. 1. Gross morphology of pancreas collected from 2-week-old turkeys infected with APMV-3 strain Netherlands (a) or Wisconsin (b): comparison with pancreas from uninfected controls (left panels) reveals necrotic foci along the length of the infected organ.

The brain, trachea, lung, spleen, kidney and pancreas showed the presence of viral antigen upon inoculation. Although APMV-3 strain Wisconsin replicated less efficiently in 2-week-old chickens, the titer of virus in lungs was somewhat higher than that of strain Netherlands, suggesting that it might be more respirotropic, whereas strain Netherlands appeared to be more neurotropic (Kumar et al., 2010a).

In general, infected turkeys had virus replication in fewer organs and for shorter duration than chickens of same age groups. Strain Netherlands was isolated from all of the tested organs except for the pancreas and kidneys in turkeys. Strain Wisconsin was isolated from all of the tested organs in turkeys. Results also suggested that turkeys are less susceptible to infection with either APMV-3 strain compared to chickens (Kumar et al., 2010a).

All the chickens and turkeys infected with either strain seroconverted 14 days post infection confirming virus replication. Extensive immunofluorescence was observed in the brain, trachea, lung and pancreas, suggesting extensive virus replication in these organs (Kumar et al., 2010a). The study also suggested that the epithelial lining in the lungs and trachea are more privileged site for virus replication.

4. Outcome of the study

APMV-3s are frequently isolated from wild and domestic birds around the world and have been placed into nine serotypes based on antigenic relatedness. Among these nine serotypes, APMV-1 (NDV) is the best studied because virulent NDV strains cause severe disease in chickens. APMV-2 to -9 are present in both free living and domestic birds, but

their disease potential is neither known in wild birds nor in domestic birds. It is probable that wild birds can transmit APMV-2 to -9 to domestic birds. APMV-2, -3, -4, -6, -7, -8, -9 have been isolated from domestic poultry birds and antibodies to these viruses have also been detected in domestic poultry (Alexander, 1980b; Alexander and D.J., 2003; Warke et al., 2008).

APMV-3 strains Netherlands and Wisconsin were first characterized by standard pathogenicity tests (MDT and ICPI). The results of the MDT test showed that APMV-3 strain Netherlands was slightly pathogenic (112 hr) compared to strain Wisconsin (>168 hr). Similar findings were also observed in ICPI test: APMV-3 strain Netherlands showed an ICPI value of 0.39, while the ICPI value of strain Wisconsin was zero. Although the results of pathogenicity index tests (MDT and ICPI) showed that APMV-3 strain Netherlands was slightly pathogenic to chickens, the pathogenicity of both the APMV-3 strains is similar to that of lentogenic NDV strains (Alexander, 1998).

The growth kinetics of APMV-3 strains in chicken brain showed that both the strains are equally competent to grow in brain tissue and the highest virus titer was observed 120 hr post inoculation. These results suggest that the low ICPI values of APMV-3 strains were due to nondestructive replication of the virus in brain tissue (Kumar et al., 2010a).

It has been shown previously by experimental infection that APMV-3 strain Netherlands is more virulent than strain Wisconsin (Alexander, 1980b). In another study, it was shown that the extent of disease and death in the birds after infection with APMV-3 strain Netherlands depends on dose as well as route of infection (Alexander and Collins, 1982b). The clinical signs of illness were more evident in 1-day-old birds compared to 2-weeks-old birds. In chickens, both the strains of APMV-3 were also isolated from tissues of respiratory, digestive and nervous systems. Similar findings were also observed in turkeys infected with both the APMV-3 strains. However, the titers of APMV-3 strain Netherlands in different organs were higher than those of strain Wisconsin in all the infected groups of birds. These results confirmed previous findings that chickens and turkeys are susceptible to APMV-3 infection. Furthermore, younger birds are more susceptible than older birds (Alexander and Collins, 1982b; Russell et al., 1989).

An interesting finding observed was the presence of large amounts of viral antigens at the epithelial cell linings, suggesting that these cells are highly permissive to APMV-3 replication. The study also suggested that APMV-3 has a tropism towards both epithelial and sub-epithelial cells (Kumar et al., 2010a). In addition, the detection of viral antigens, and in most cases infectious virus, in multiple internal organs of the birds indicates that both the viruses are capable of replicating in multiple organs rather than being restricted only to respiratory and alimentary tracts. Presumably, the virus reached the various internal organs through the blood stream. Nonetheless, this extensive amount of virus replication was not accompanied by severe disease in birds. These results show that APMV-3 strains are capable of infecting young and adult chickens and turkeys using an oculonasal route of infection. Serologic assays demonstrated a humoral response in all the birds inoculated with either APMV-3 strain, a further indication of successful replication. However, our findings suggest that chickens are comparatively more susceptible than turkeys to APMV-3 infection.

5. Conclusions

APMV-3 is capable of infecting young and adult SPF chickens and turkeys. The disease caused by APMV-3 is more severe in younger birds than in older birds, where it is mostly inapparent. Our results also showed that APMV-3 strains vary in pathogenicity. Strain Netherlands is more virulent than strain Wisconsin. This study has demonstrated that APMV-3 has an affinity for both epithelial as well as sub-epithelial cells of respiratory and alimentary tracts. In terms of pathogenicity for poultry, APMV-3 is probably second in importance only to NDV. However, in commercial chickens and turkeys the disease picture could be quite different depending on management practices, environmental conditions and other concomitant infections. Further studies are needed to understand the disease potential of this virus to commercial poultry.

6. Acknowledgments

We thank Daniel Rockemann and all our laboratory members for their excellent technical assistance and help.

7. References

- Alexander and D.J., Avian paramyxoviruses 2-9. Iowa State University Press, Ames (2003).
- Alexander, D., Paramyxoviridae, 11th ed. Iowa State University Press, Iowa (2003).
- Alexander, D.J. Avian paramyxoviruses *Vet Bull* 50 (1980a), pp. 737-752.
- Alexander, D.J. Avian paramyxoviruses. *Veterinary Bulletin* 50 (1980b), pp. 737-752.
- Alexander, D.J.: Alexander DJ: Newcastle disease and other avian paramyxoviruses. In: Swayne DE, G.J., Jackwood MW, Pearson JE, Reed WM, (Swayne DE, G.J., Jackwood MW, Pearson JE, Reed WM,) Swayne DE, G.J., Jackwood MW, Pearson JE, Reed WM, s), In: *A Laboratory Manual for the Isolation and Identification of Avian Pathogens*. . American Association of Avian Pathologists, .University of Pennsylvania, Kennett Square, PA, (1998), pp. 156-163.
- Alexander, D.J. and Chettle, N.J. Relationship of parakeet/Netherlands/449/75 virus to other avian paramyxovirus. *Res Vet Sci* 25 (1978), pp. 105-106.
- Alexander, D.J. and Collins, M.S. Pathogenicity of PMV-3/Parakeet/Netherlands/449/75 for chickens. *Avian Pathol* 11 (1982a), pp. 179-185.
- Alexander, D.J. and Collins, M.S. Pathogenicity of PMV-3/parakeet/Netherlands/449/75 for chickens. *Avian Pathol* 11 (1982b), pp. 179-85.
- Alexander, D.J. and Collins, M.S. Characterization of avian paramyxoviruses of serotype PMV-3 isolated from commercial turkey in Great Britain. . *Avian Pathol* 13 (1984), pp. 215-221.
- Alexander, D.J., Hinshaw, V.S., Collins, M.S. and Yamane, N. Characterization of viruses which represent further distinct serotypes (PMV-8 and PMV-9) of avian paramyxoviruses. *Arch Virol* 78 (1983), pp. 29-36.
- Anderson, C., Kearsley, R., Alexander, D.J. and Russell, P.H. Antigenic variation in avian paramyxovirus type 3 isolates detected by mouse monoclonal antibodies. *Avian Pathol* 16 (1987), pp. 691-8.
- Anderson, C.L. and Russell, P.H. Monoclonal antibodies against avian paramyxovirus-3: antigenic mapping and functional analysis of the haemagglutinin-neuraminidase


- protein and the characterization of nonspecific monoclonal antibodies. *Arch Virol* 101 (1988), pp. 49-63.
- Beck, I., Gerlach, H., Burkhardt, E. and Kaleta, E.F. Investigation of several selected adjuvants regarding their efficacy and side effects for the production of a vaccine for parakeets to prevent a disease caused by a paramyxovirus type 3. *Vaccine* 21 (2003), pp. 1006-22.
- Capua, I., De Nardi, R., Beato, M.S., Terregino, C., Scremin, M. and Guberti, V. Isolation of an avian paramyxovirus type 9 from migratory waterfowl in Italy. *Vet Rec* 155 (2004), p. 156.
- Chang, P.C., Hsieh, M.L., Shien, J.H., Graham, D.A., Lee, M.S. and Shieh, H.K. Complete nucleotide sequence of avian paramyxovirus type 6 isolated from ducks. *J Gen Virol* 82 (2001), pp. 2157-68.
- de Leeuw, O. and Peeters, B. Complete nucleotide sequence of Newcastle disease virus: evidence for the existence of a new genus within the subfamily Paramyxovirinae. *J Gen Virol* 80 (Pt 1) (1999), pp. 131-6.
- Gough, R.E. and Alexander, D.J. Avian paramyxovirus type 4 isolated from a ringed teal (*Calonetta leucophrys*). *Vet Rec* 115 (1984), p. 653.
- Huang, Z., Panda, A., Elankumaran, S., Govindarajan, D., Rockemann, D.D. and Samal, S.K. The hemagglutinin-neuraminidase protein of Newcastle disease virus determines tropism and virulence. *J Virol* 78 (2004), pp. 4176-84.
- Kaleta, E.F., Werner, O. and Hemberger, Y. Isolation and characterization of avian paramyxovirus type 3b from farmed Namibian ostriches (*Struthio camelus* f. dom.). *Berl Munch Tierarztl Wochenschr* 123, pp. 103-10.
- Krishnamurthy, S. and Samal, S.K. Nucleotide sequences of the trailer, nucleocapsid protein gene and intergenic regions of Newcastle disease virus strain Beaudette C and completion of the entire genome sequence. *J Gen Virol* 79 (Pt 10) (1998), pp. 2419-24.
- Kumar, S., Militino Dias, F., Nayak, B., Collins, P.L. and Samal, S.K. Experimental avian paramyxovirus serotype-3 infection in chickens and turkeys. *Vet Res* 41 (2010a), p. 72.
- Kumar, S., Nayak, B., Collins, P.L. and Samal, S.K. Complete genome sequence of avian paramyxovirus type 3 reveals an unusually long trailer region. *Virus Res* 137 (2008), pp. 189-97.
- Kumar, S., Nayak, B., Samuel, A.S., Xiao, S., Collins, P.L. and Samal, S.K. Complete genome sequence of avian paramyxovirus-3 strain Wisconsin: evidence for the existence of subgroups within the serotype. *Virus Res* 149 (2010b), pp. 78-85.
- Lamb, R. and Parks, G., In *Paramyxoviridae: The Viruses and Their Replication*. Lippincott Williams & Wilkins, Philadelphia (2007).
- Macpherson, I., Watt, R.G. and Alexander, D.J. Isolation of avian paramyxovirus other than Newcastle disease virus from commercial poultry in Great Britain. *Vet Rec* 112 (1983), pp. 479-80.
- Maldonado, A., Arenas, A., Tarradas, M.C., Luque, I., Astorga, R., Perea, J.A. and Miranda, A. Serological survey for avian paramyxoviruses from wildfowl in aquatic habitats in Andalusia. *J Wildl Dis* 31 (1995), pp. 66-9.
- Mayo, M.A. A summary of taxonomic changes recently approved by ICTV. *Arch Virol* 147 (2002), pp. 1655-63.

- Nayak, B., Kumar, S., Collins, P.L. and Samal, S.K. Molecular characterization and complete genome sequence of avian paramyxovirus type 4 prototype strain duck/Hong Kong/D3/75. *Virol J* 5 (2008), p. 124.
- Paldurai, A., Subbiah, M., Kumar, S., Collins, P.L. and Samal, S.K. Complete genome sequences of avian paramyxovirus type 8 strains goose/Delaware/1053/76 and pintail/Wakuya/20/78. *Virus Res* 142 (2009), pp. 144-53.
- Panda, A., Huang, Z., Elankumaran, S., Rockemann, D.D. and Samal, S.K. Role of fusion protein cleavage site in the virulence of Newcastle disease virus. *Microb Pathog* 36 (2004), pp. 1-10.
- Redmann, T., Zeydanli, M.M., Herbst, W. and Kaleta, E.F. [Isolation of a paramyxovirus-3 from turkeys with respiratory tract disease in Germany]. *Dtsch Tierarztl Wochenschr* 98 (1991), pp. 138-41.
- Reed, L.J. and Muench, H. A simple method of estimation of 50% end points. *Am J Hyg* 27 (1938), pp. 493-497.
- Rout, S.N. and Samal, S.K. The large polymerase protein is associated with the virulence of Newcastle disease virus. *J Virol* 82 (2008), pp. 7828-36.
- Russell, P.H., Awang, I.P., Parsons, G. and Alexander, D.J. Pathogenicity of PMV-3/Turkey/England/Midland poultry holdings/1981 for chickens and turkeys. *Avian Pathol* 18 (1989), pp. 125-34.
- Saif, Y.M., Mohan, R., Ward, L., Senne, D.A., Panigrahy, B. and Dearth, R.N. Natural and experimental infection of turkeys with avian paramyxovirus-7. *Avian Dis* 41 (1997), pp. 326-9.
- Samuel, A.S., Kumar, S., Madhuri, S., Collins, P.L. and Samal, S.K. Complete sequence of the genome of avian paramyxovirus type 9 and comparison with other paramyxoviruses. *Virus Res* 142 (2009), pp. 10-8.
- Shortridge, K.F., Alexander, D.J. and Collins, M.S. Isolation and properties of viruses from poultry in Hong Kong which represent a new (sixth) distinct group of avian paramyxoviruses. *J Gen Virol* 49 (1980), pp. 255-62.
- Stallknecht, D.E., Senne, D.A., Zwank, P.J., Shane, S.M. and Kearney, M.T. Avian paramyxoviruses from migrating and resident ducks in coastal Louisiana. *J Wildl Dis* 27 (1991), pp. 123-8.
- Subbiah, M., Xiao, S., Collins, P.L. and Samal, S.K. Complete sequence of the genome of avian paramyxovirus type 2 (strain Yucaipa) and comparison with other paramyxoviruses. *Virus Res* 137 (2008), pp. 40-8.
- Tumova, B., Robinson, J.H. and B.C.Easterday A hitherto unreported paramyxovirus of turkey. *Res in Vet Sci* 27 (1979a), pp. 135-140.
- Tumova, B., Robinson, J.H. and Easterday, B.C. A hitherto unreported paramyxovirus of turkeys. *Res Vet Sci* 27 (1979b), pp. 135-40.
- Wakamatsu, N., King, D.J., Kapczynski, D.R., Seal, B.S. and Brown, C.C. Experimental pathogenesis for chickens, turkeys, and pigeons of exotic Newcastle disease virus from an outbreak in California during 2002-2003. *Vet Pathol* 43 (2006), pp. 925-33.
- Warke, A., Stallknecht, D., Williams, S.M., Pritchard, N. and Mundt, E. Comparative study on the pathogenicity and immunogenicity of wild bird isolates of avian paramyxovirus 2, 4, and 6 in chickens. *Avian Pathol* 37 (2008), pp. 429-34.

Xiao, S., Paldurai, A., Nayak, B., Subbiah, M., Collins, P.L. and Samal, S.K. Complete genome sequence of avian paramyxovirus type 7 (strain Tennessee) and comparison with other paramyxoviruses. *Virus Res* 145 (2009), pp. 80-91.

IntechOpen

IntechOpen



A Bird's-Eye View of Veterinary Medicine

Edited by Dr. Carlos C. Perez-Marin

ISBN 978-953-51-0031-7

Hard cover, 626 pages

Publisher InTech

Published online 22, February, 2012

Published in print edition February, 2012

Veterinary medicine is advancing at a very rapid pace, particularly given the breadth of the discipline. This book examines new developments covering a wide range of issues from health and welfare in livestock, pets, and wild animals to public health supervision and biomedical research. As well as containing reviews offering fresh insight into specific issues, this book includes a selection of scientific articles which help to chart the advance of this science. The book is divided into several sections. The opening chapters cover the veterinary profession and veterinary science in general, while later chapters look at specific aspects of applied veterinary medicine in pets and in livestock. Finally, research papers are grouped by specialisms with a view to exploring progress in areas such as organ transplantation, therapeutic use of natural substances, and the use of new diagnostic techniques for disease control. This book was produced during World Veterinary Year 2011, which marked the 250th anniversary of the veterinary profession. It provides a fittingly concise and enjoyable overview of the whole science of veterinary medicine.

How to reference

In order to correctly reference this scholarly work, feel free to copy and paste the following:

Sachin Kumar and Siba K. Samal (2012). Pathogenicity of Avian Paramyxovirus Serotype-3 in Chickens and Turkeys, *A Bird's-Eye View of Veterinary Medicine*, Dr. Carlos C. Perez-Marin (Ed.), ISBN: 978-953-51-0031-7, InTech, Available from: <http://www.intechopen.com/books/a-bird-s-eye-view-of-veterinary-medicine/pathogenicity-of-avian-paramyxovirus-serotype-3-in-chickens-and-turkeys>

INTech
open science | open minds

InTech Europe

University Campus STeP Ri
Slavka Krautzeka 83/A
51000 Rijeka, Croatia
Phone: +385 (51) 770 447
Fax: +385 (51) 686 166
www.intechopen.com

InTech China

Unit 405, Office Block, Hotel Equatorial Shanghai
No.65, Yan An Road (West), Shanghai, 200040, China
中国上海市延安西路65号上海国际贵都大饭店办公楼405单元
Phone: +86-21-62489820
Fax: +86-21-62489821

© 2012 The Author(s). Licensee IntechOpen. This is an open access article distributed under the terms of the [Creative Commons Attribution 3.0 License](https://creativecommons.org/licenses/by/3.0/), which permits unrestricted use, distribution, and reproduction in any medium, provided the original work is properly cited.

IntechOpen

IntechOpen