

We are IntechOpen, the world's leading publisher of Open Access books Built by scientists, for scientists

6,900

Open access books available

186,000

International authors and editors

200M

Downloads

Our authors are among the

154

Countries delivered to

TOP 1%

most cited scientists

12.2%

Contributors from top 500 universities



WEB OF SCIENCE™

Selection of our books indexed in the Book Citation Index
in Web of Science™ Core Collection (BKCI)

Interested in publishing with us?
Contact book.department@intechopen.com

Numbers displayed above are based on latest data collected.
For more information visit www.intechopen.com



Treatment of Talar Osteochondral Lesions Using Local Osteochondral Talar Autograft – Long Term Results

Thanos Badekas, Evangelos Evangelou and Maria Takvorian
Department of Foot and Ankle Surgery, Metropolitan Hospital, Athens, Greece

1. Introduction

Osteochondral lesion of the talus (OLT) is a broad term used to describe an injury or abnormality of the talar articular cartilage and adjacent bone. A variety of terms have been used to refer to this clinical entity including osteochondritis dissecans, osteochondral fracture, and osteochondral defect. Whether OLT of the talus is a precursor to more generalized arthrosis of the ankle remain unclear, but the condition is often symptomatic enough to warrant treatment. Above one third of cases conservative treatment is not successful and a surgery is indicated. Several surgical options have been described including: debridement, isolated or combined with drilling, excision and curettage, abrasion arthroplasty, microfracture technique arthroscopically or not, internal fixation with screws, autologous chondrocyte implantation and implantation of osteochondral autograft using single or multiple cylinders of articular cartilage and subchondral bone. The optimal solution remains uncertain. Furthermore smaller lesions are symptomatic and untreated OCDs can progress, current treatment strategies have not solved the problem.

The goal of this study was to retrospectively evaluate the long-term results of 23 patients who underwent local osteochondral talar autograft for the treatment of OLT.

2. Materials and methods

From March 2005 to December 2008 a series of 58 patients were retrospectively evaluated. Thirty seven male and twenty one female with age ranged from 19 to 53 (mean 38) years. Sports related injury concerned 37 patients and the duration of symptoms was mean 65 months (range 6 to 98). Mean follow-up was 22,1 months (range 14 to 32). Preoperative evaluations included a clinical history, physical examination of the foot and recording of American Orthopaedic Foot and Ankle Society (AOFAS) Ankle- Hindfoot score. Special radiological studies performed preoperative, MRI (58 patients), CAT (58 patients), Bone Scan 3 patients (ordered by other doctors, because we don't need it for detection OLT) and weight-bearing radiographs to all of them to evaluate the injury. The majority of lesions n=41 were on the medial aspect of talus, 17 on the lateral talar dome and 4 medial and lateral lesions. The graft was harvested from the medial or lateral talar articular facet on the same side of the lesion depended by the geometry of the lesion. Graft sizes ranged from four

to eight millimeters in diameter. More specific 4 mm 6, 6mm 28, 8mm 24. So, this operation is used for stages 3 and 4 lesions according to Berndt and Hardy classification and for stages 1 and 2 in symptomatic patients that failed previous surgical treatment. (table 1).

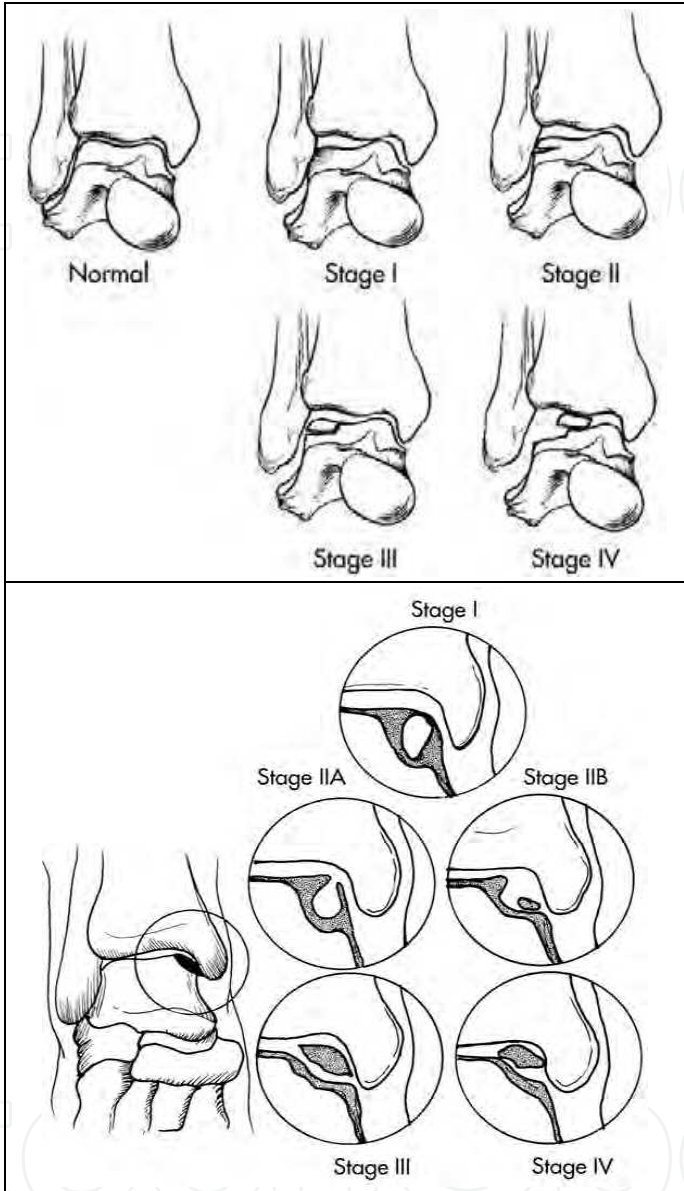


Table 1. Berndt and Hardy classification

Associated findings after the preoperative control (table2) was 17patients with Pes Planus, 11 patients with arthritis, 8 patients with Achilles tendinopathy, 3 with Tibialis Posterior Dysfunction, 3 with Hallux Rigidus, 13 with lateral ankle instability and 2 patient with previous pinning controlateral ankle. Additional procedures were an FHL tenosynovectomy and repair, excision of a lipoma, lateral ligaments reconstruction (Brostrom modification), TAL lengthening, synovectomy and AAI removal. Preoperative and postoperative results evaluated used the AOFAS hindfoot score. The result of the score was classified in excellent, good, fair and poor and additionally patients have been asked about their satisfaction following the procedure. Statistical analyses were performed using SPSS software.

Pes planus	17
Arthritis	11
Achilles tend	8
Tib.Post Dysf.	3
Hallux Rigidus	3
Lateral Ankle Instability	13
Previous pinning contr	2

Table 2. Associated Findings & History

3. Surgical technique

All procedures were performed with the patient in the supine position under tourniquet control. An arthrotomy was performed through a 7cm antero-medial or antero-lateral incision as required. The lesion is approached by removing a bone block from the tibia including the articular surface. To accomplish with this a wedge shaped bone block, 10mm wide, 20mm deep and 30mm in height is made at the distal anterior tibia articular surface on the side of the osteochondral lesion. Vertical parallel saw cuts are made with a high-speed micro oscillating saw. Care is taken to avoid injuring the uninvolved talar articular surface. The saw was then used to connect the two vertical parallel cuts proximally in the metaphysis. A 10mm wide thin osteotome is then driven from the superior portion of the transverse saw cut inferiorly to the articular surface of the tibial plafond 10 to 20mm deep depending on the location of the lesion on the talar dome. The tibial fragment is removed and set aside to be replaced later (figure 1). The defect created in the tibia following removal of the bone fragment permits direct access to the lesion from above. The lesion is delivered into the field by plantar-flexing the ankle. It is prepared by first debriding the loosened cartilage fragments. The lesion is then drilled using the appropriate size drill. Care is taken to ensure that the drill is perpendicular to the articular surface of the talus directly over the lesion. Drill sizes are matched to the diameter of the defect 4, 6 or 8mm to the size of the defect determined from the MRI. The osteochondral graft is harvested from the anterior aspect of the ipsilateral talar articular facet. A total of 15 grafts were harvested: two 4mm, six 6mm and seven 8mm (figure 2). This is performed through the same incision as the tibial osteotomy. The graft is harvested using the core-harvesting device (figure 3). The cutter was positioned over the talar facet near the anterior border ensuring that it was perpendicular to the articular surface. The inferior border of the talar facet flares outward slightly and the harvesting tube is oriented so that the flared margin can be identified and oriented toward the medial or lateral talar dome respectively. This ensures that the graft shape will approximate the saddle shape of the talar dome more closely. It is then tapped with a mallet until the cutter reaches the desired depth. The harvester is then rotated and removed with graft held in the harvester tube. The outer cutter is removed leaving the graft plug inside the harvester tube and a delivery guide is screwed onto the harvester tube. A plunger is inserted into the proximal end of the tube. The assembled harvester tube, guide and plunger

are positioned perpendicular to the talar done over the prepared site in the talus orienting the outer flair of the graft toward the outer edge of the dome. The plunger is tapped gently pressing the osteochondral graft plug into the hole (Figure 4). The graft is inserted until it is flush slightly proud to the surrounding cartilage overhanging. For the true medial lesions a Chevron-type medial malleolar osteotomy was performed at the end the osteotomy fixed with 2 screws. The approach to lateral lesions performed with anterolateral incision by taking down the ATFL and CFL. At the end a modified Brostrom performed. The postoperative treatment was immobilization for 4 weeks, walker boot for next 4 weeks and weight bearing at six weeks. Range of motion exercises was allowed once the surgical incision healed.

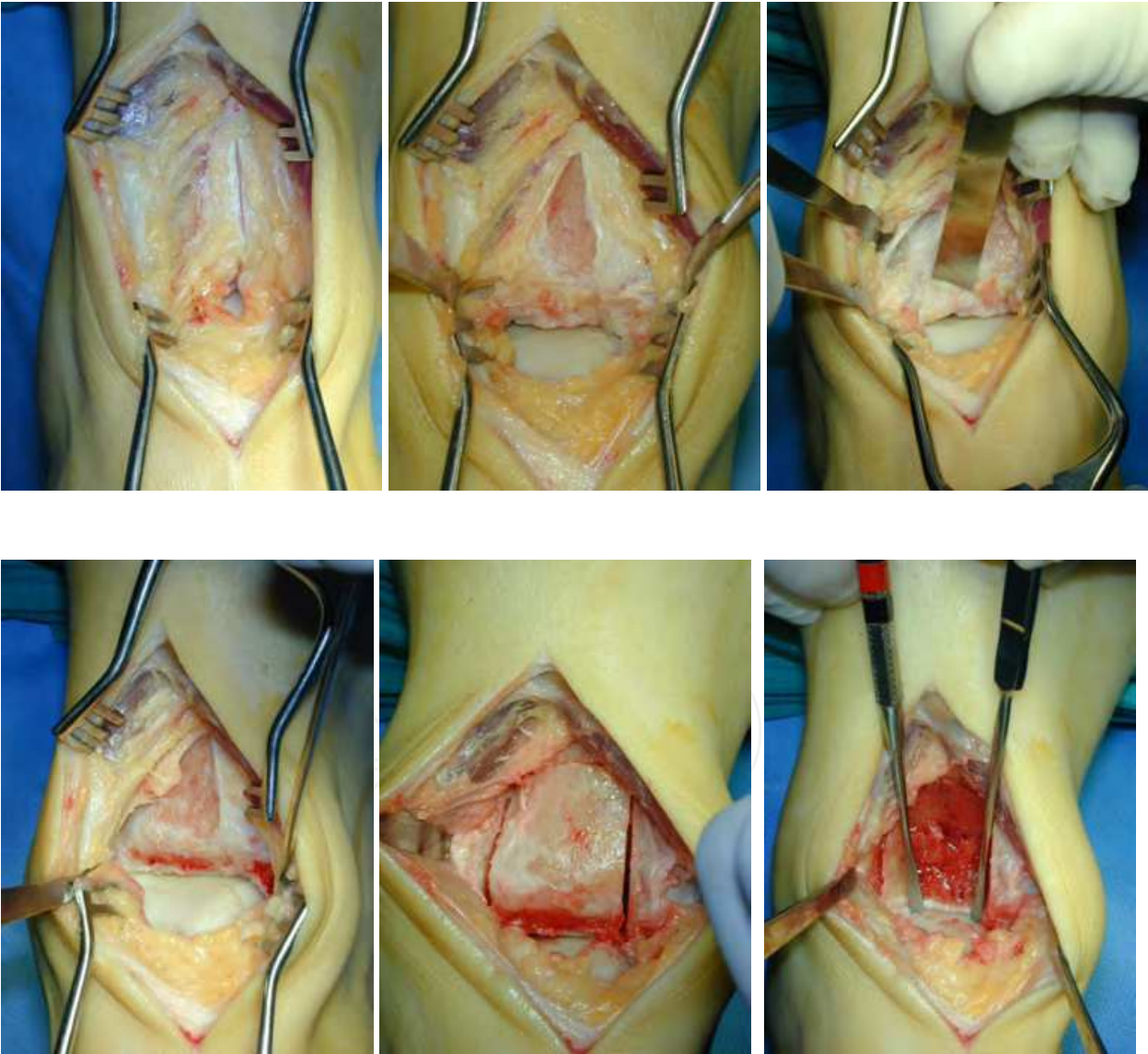


Fig. 1. Tibial osteotomy trapezoid wedge shape for perpendicular access to the recipient sit

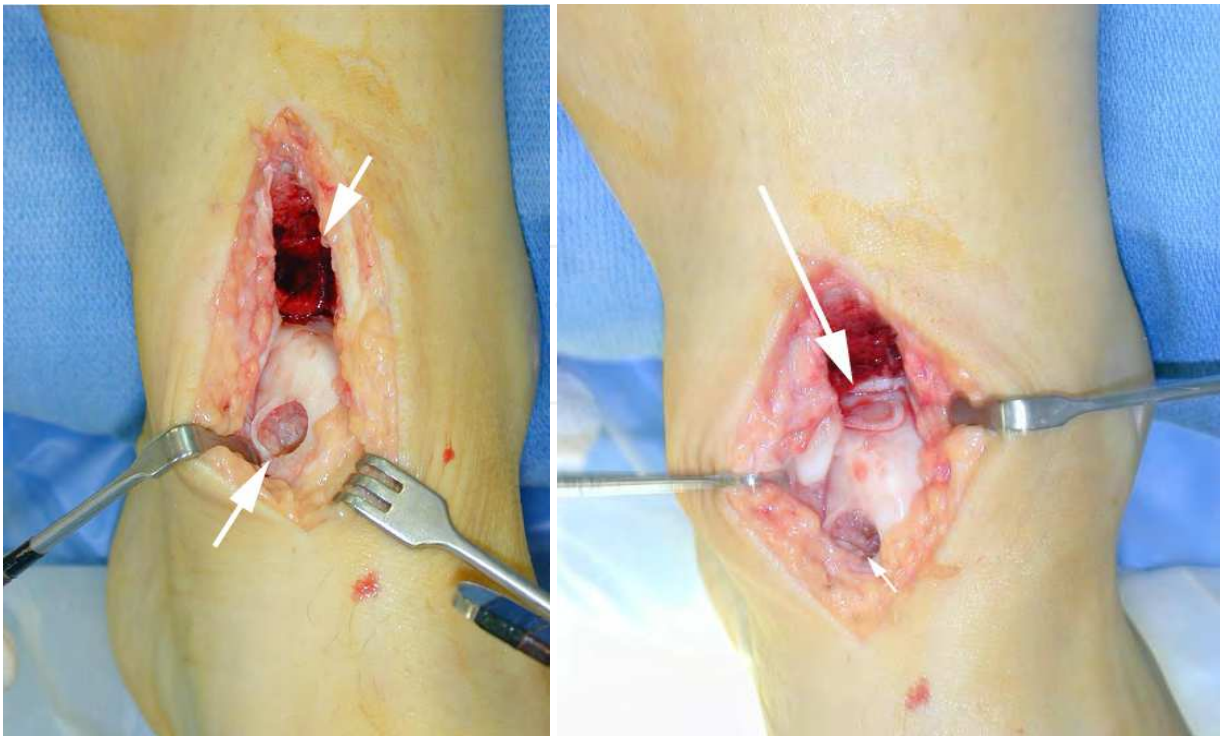

Fig. 2. Donor medial talar facet-recipient site with the local garft already inserted

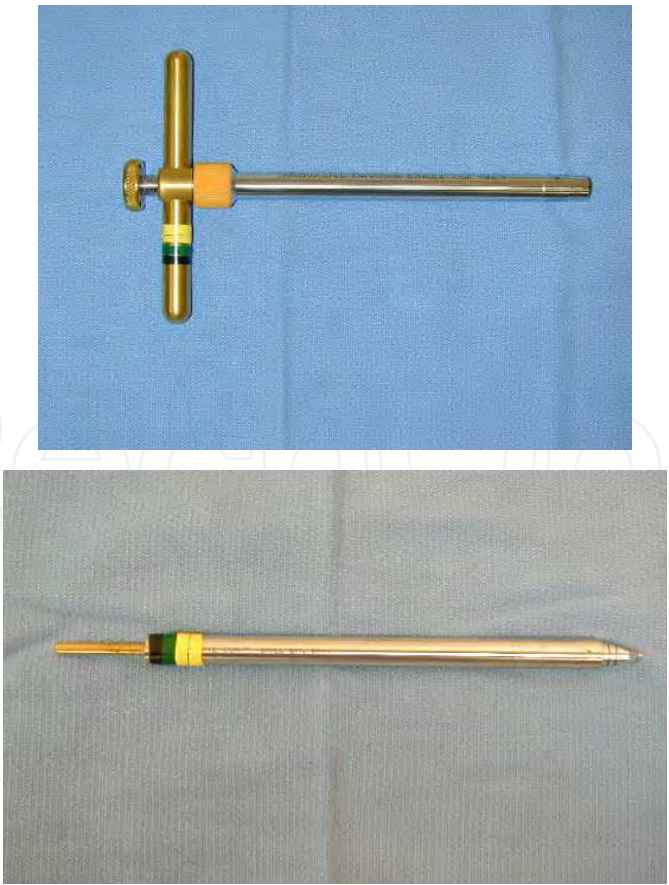


Fig. 3. Instrumentation

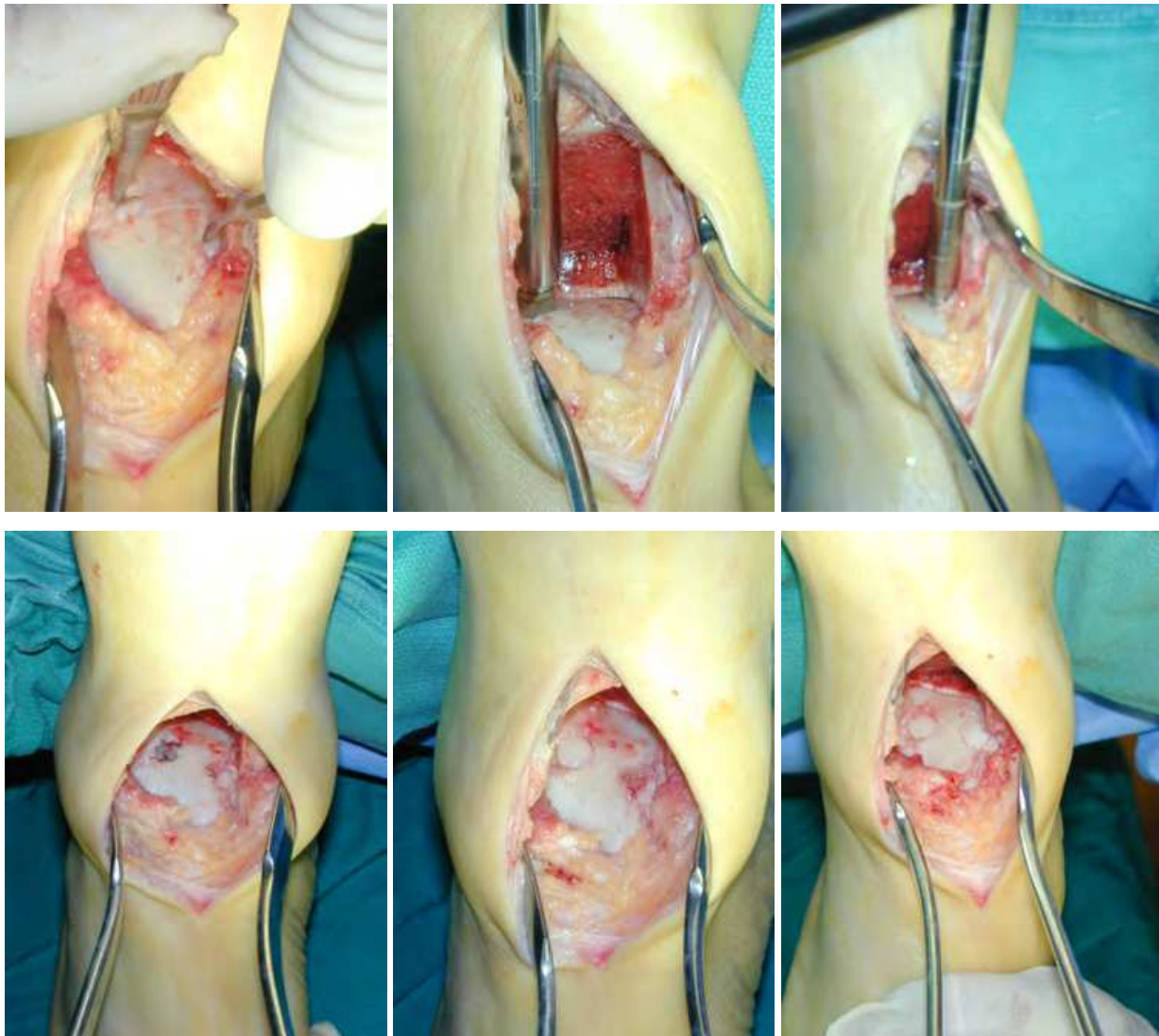


Fig. 4. Perpedicular access to the recipient site a case with 2 lesions

4. Results

Patients were evaluated both intraoperatively and postoperatively. Operative findings included: degenerative joint disease in six cases, lipoma in two cases and lateral ankle ligament instability in two cases.

Preoperative AOFAS scoring using the ankle and hindfoot score was 65 average. At follow up, 41 months (average). Postoperative was 89 average. The patients under the age of 40 had higher average AOFAS scores postoperatively, compared to the patients over the age of 40. (table 3) The presence of degenerative arthritis yielded a lower AOFAS score in. However, the difference between these small subgroups was not significant. No reciprocal “kissing lesions” were encountered on the tibial articular surface opposite the osteochondral lesion. There was no deterioration in the overall functional improvement in patients underwent additional procedures. There were no perioperative complications. Long term, the most common complaint in patients over time was mild aching over the anterior aspect of the ankle, although this did not decrease activities of daily living or sports. All patients stated they would undergo the procedure again.

	Pre-operative	Post-operative
AOFAS	65	89
Under 40 years	69	92
No Arthritis	68	91
Arthritis	63	86

Table 3.

Evaluation of postoperative x-rays revealed no evidence of decreased joint space in the ankle. X-ray findings also revealed that the cyst visible preoperatively was no longer visible at the last follow up visit. No increase in arthritis was noted. Clinical examination postoperatively revealed improved range of motion, muscle strength, gait pattern and endurance. Patients returned to their work 8 months following surgery, without restrictions. Two patients underwent surgery subsequent to the index procedure, one had arthroscopy and removal of impinging osteophytes from the lateral malleolus six months following surgery and one had arthroscopy with debridement of the anterior tibial margin at the site where the tibial bone block had been removed twelve months following surgery (Figure 5). In both cases the cartilage of the graft appeared to have grown into the surrounding cartilage of the talar dome. The tibial articular cartilage on the tibial plafond had also healed without articular surface defects. It appeared that the use of talar osteochondral graft does not adversely affect the joint surface and easily incorporates into the surrounding surface cartilage.

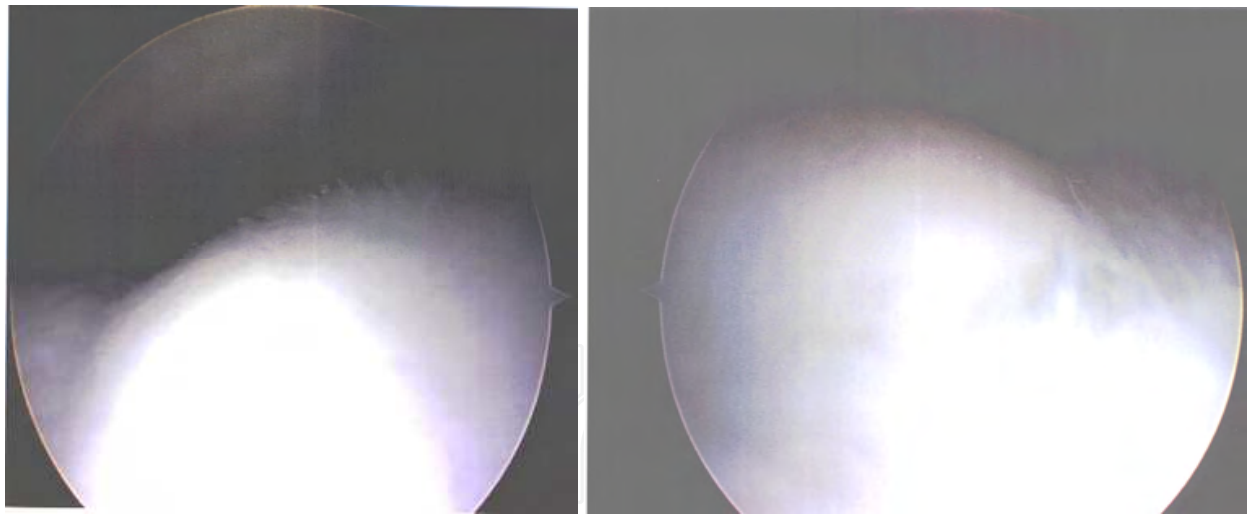


Fig. 5. Second look arthroscopy with a good incorporation of the local graft same quality and thickness cartilage

5. Discussion

The result of non-operative treatment of stage III and IV osteochondral lesions of the talus have been poor^{1, 3}. Berndt and Harty reviewing 200 cases from the literature and adding 24 of their own found 73.9% poor results with non-surgical treatment. Of the fifty-six treated surgically 78.6% had good results³. O’Farrell and Costello (1982)⁹ reported on 24 patients treated surgically and found the results were better with early diagnosis and treatment. This

report was further substantiated by Pettine and Morrey (1987)¹⁰ who retrospectively reviewed 68 patients at average follow-up of 7.5 years and concluded that a delay in diagnosis and surgery resulted in a poor outcome. Whilst a high percentage of satisfactory results can be obtained with non-surgical treatment for Stage I and II lesions most stage III and IV lesions require surgery. Canale and Belding (1980)⁴ recommended stage IV and III lateral lesions be treated surgically but that III medial lesions be treated non-surgically initially. All lesions in our study were stage III or IV and two-thirds were related to sports injuries. The surgical treatment for osteochondral lesions of the talus includes excision, excision and curettage with or without drilling, microfracture, cancellous bone grafting, internal fixation and osteochondral grafting. Review of the literature suggests a higher percentage of good and excellent results with excision and curettage with or without drilling the base of the lesion¹⁴. Mosaicplasty autogenous osteochondral grafting has been recently introduced and has evolved from treatment of osteochondral lesions of the knee. Hangody et al (1997)⁷ reported their results in 11 patients treated with mosaicplasty autogenous osteochondral grafting for talar dome lesions using the knee as a donor site with a high success rate. However donor site morbidity can occur in up to 15% -16% of cases in an asymptomatic joint⁸. We feel this increased morbidity can be avoided. By harvesting the graft from a location on the talar dome, which carries minimal loads, the risks of the procedure are reduced. The graft is taken from the anterior part of the medial or lateral talar facet. Since the graft size is relatively small the integrity anterior dome is maintained. There was no incidence of collapse of the talus either at the donor site or at the site of the lesion. The two patients on whom arthroscopy was performed revealed the graft well incorporated on the surface of the joint. The chondral border of the graft revealed no line of degeneration or necrosis. Also, there was no additional change noted on the medial or lateral facet either at the site of the lesion or at the donor site.

The removal of a portion of the anterior tibial plafond to access this lesion has been previously described⁶. However, osteochondritic lesions are often large and located farther back in the talar dome so that they are inaccessible unless a large portion of tibia is removed. This makes the method described by Flick and Gould⁶ impractical since the amount of bone needed to be removed is significant, ten mm. and will decrease the tibial load bearing capacity of tibial plafond if it not replaced. Moreover the location of such lesions is often so far posterior that removal without replacing tibial bone to access the lesion would significantly weaken the tibial plafond and medial malleolus. In addition, this method cannot be used laterally unless the lesion is located anteriorly. The use of a medial malleolar osteotomy carries the risk of nonunion and malunion and the results may deteriorate with time². The securing of the malleolus with screws leaves the heads of the screws at the tip of the malleolus and these may require removal later. Our method allows access to either side of the ankle directly even if the lesion is located toward the posterior third of the dome. The defect is visualized from above after the bone block has been removed. The bone block is then replaced and secured with an absorbable pin. There is no risk of malunion since the block is replaced in the same position from which it was removed. No fractures occurred in the tibia. The tibial graft held in place without any fixation only by gentle tapping, since it holds the bone block in place but not carry any loads.

Moreover we use same quality osteochondral graft, the cartilage of the knee is thicker than the talus cartilage hence cannot incorporate precisely like the talus cartilage.

There are some lesions that are difficult to access even with this method. These are located in the posterior 20 to 30% of the talar dome, particularly in the lateral posterior region of the talus. For these less common lesions, not included in this report, we expose the talus through a posterolateral incision and performed the grafting using a second anterior incision to harvest the graft.

Additionally for the true medial lesions we still perform an osteotomy of the medial malleolus (figure 6) because it is difficult to have perpendicular access to the recipient site through the wedge shaped bone block, at the distal anterior tibia articular surface on the side of the osteochondral lesion.

For the true lateral lesions sometimes is needed to approach the lesion through an anterolateral incision we have to take down the anterior tibiofibular ligament (ATFL) and the calcaneofibular ligament (CFL) in order to have perpendicular access again to the recipient site (figure 7), then we have to reconstruct the ligament with a standard modified Brostrom technique.

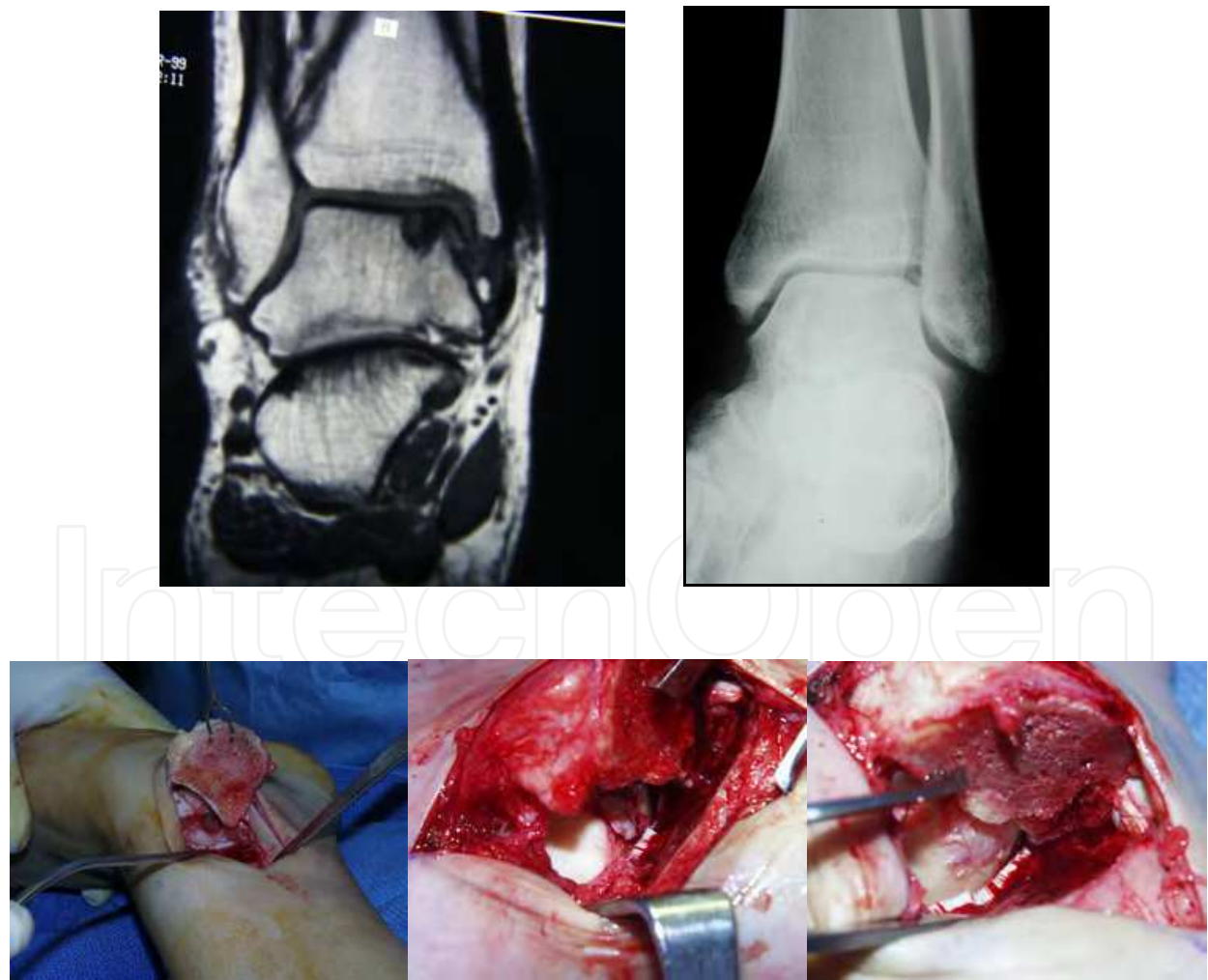


Fig. 6. Medial malleolus osteotomy for true medial site lesions

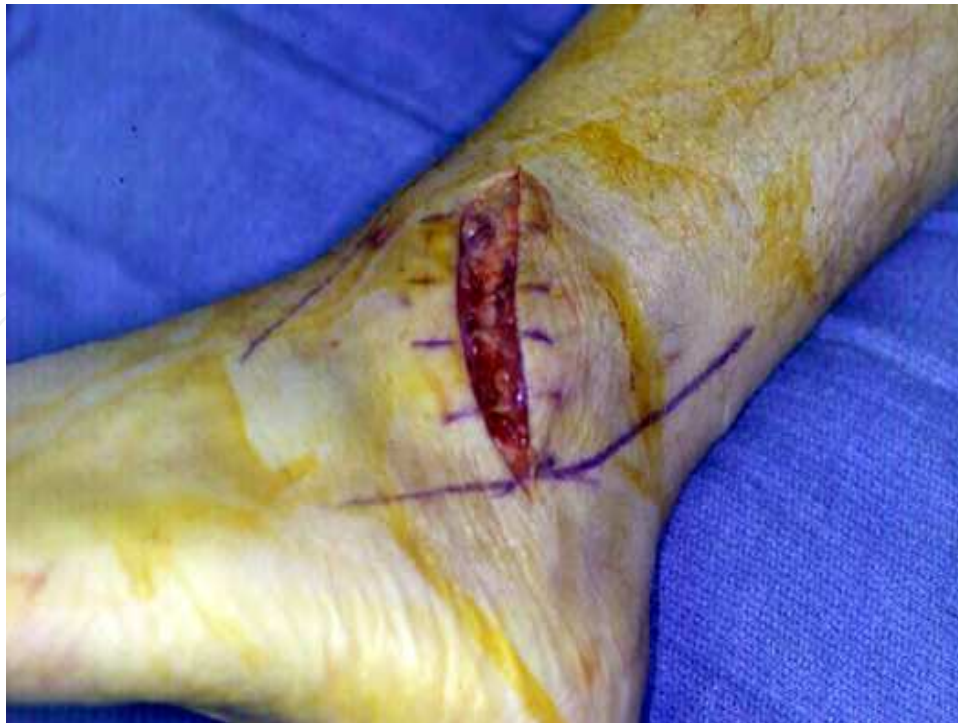

Fig. 7. Lateral OLT Approached through an anterolateral incision, with takedown of ATFL and CFL. Reconstruction with modified Brostrom

The overall improvement in the AOFAS score in our study was 24 points at an average follow up of 41 months. Improvement can be expected for as long as eighteen months postoperatively¹². Canale and Belding (1980)⁴ found 15 out of 31 cases (50%) developed degenerative joint changes at an average 11.2 years. The long-term success of preventing late joint degenerative changes has yet to be determined using our technique.

In this study our mid term results suggest that stage III and IV talar dome lesions can be treated successfully using local autogenous osteochondral grafts from the medial or lateral talar articular facet This procedure is combined with removal of a tibial bone block and its subsequent replacement and does not yield complications experienced with other procedures.


6. References

- [1] Al Shaikh, RA; Chou, LB; Mann, JA; Dreeben, SM; Prieskorn D: Autologous osteochondral grafting for talar cartilage defects. *Foot Ankle Int.* 23(5): 381 - 389, 2002.
- [2] Baker, CL; Andrews, JR; Ryan JB: Arthroscopic treatment of transchondral talar dome fractures. *Arthroscopy.* 2(2): 82 - 87, 1986. [http://dx.doi.org/10.1016/S0749-8063\(86\)80017-2](http://dx.doi.org/10.1016/S0749-8063(86)80017-2).
- [3] Barnes, CJ; Ferkel RD: Arthroscopic debridement and drilling of osteochondral lesions of the talus. *Foot Ankle Clin.* 8(2): 243 - 257, 2003. [http://dx.doi.org/10.1016/S1083-7515\(03\)00016-0](http://dx.doi.org/10.1016/S1083-7515(03)00016-0).
- [4] Bartlett, W; Skinner, JA; Gooding, CR; et al.: Autologous chondrocyte implantation versus matrix - induced autologous chondrocyte implantation for osteochondral

- defects of the knee: a prospective, randomised study. *J Bone Joint Surg Br.* 87(5):640 – 645, 2005. <http://dx.doi.org/10.1302/0301-620X.87B5.15905>.
- [5] Bauer, M; Jonsson, K; Lindén, B: Osteochondrosis dissecans of the ankle: A 20-year followup study. *J Bone Joint Surg Br.* 69(1): 93 – 96, 1987.
- [6] Brittberg, M; Sjögren-Jansson, E; Lindahl, A; Peterson, L: Influence of fibrin sealant (Tisseel) on osteochondral defect repair in the rabbit knee. *Biomaterials.* 18(3): 235 – 242, 1997. [http://dx.doi.org/10.1016/S0142-9612\(96\)00117-2](http://dx.doi.org/10.1016/S0142-9612(96)00117-2).
- [7] Browne, JE; Branch, TP: Surgical alternatives for treatment of articular cartilage lesions. *J Am Acad Orthop Surg.* 8(3): 180 – 189, 2000.
- [8] Campbell, CJ; Ranawat, CS: Osteochondritis dissecans: the question of etiology. *J Trauma.* 6(2): 201 – 221, 1966. <http://dx.doi.org/10.1097/00005373-196606020-00007>.
- [9] Cherubino, P; Grassi, FA; Bulgheroni, P; Ronga, M: Autologous chondrocyte implantation using a bilayer collagen membrane: a preliminary report. *J Orthop Surg (Hong Kong).* 11(1): 10 – 15, 2003.
- [10] Chiroff, RT; Cooke, CP 3rd: Osteochondritis dissecans: a histologic and microradiographic analysis of surgically excised lesions. *J Trauma.* 15(8): 689 – 696, 1975.
- [11] Ewing, JW: Arthroscopic management of transchondral talar-dome fractures (osteochondritis dissecans) and anterior impingement lesions of the ankle joint. *Clin Sports Med.* 10(3): 677 – 687, 1991.
- [12] Finsen, V; Saetermo, R; Kibsgaard, L; et al.: Early postoperative weight-bearing and muscle activity in patients who have a fracture of the ankle. *J Bone Joint Surg Am.* 71(1): 23 – 27, 1989.
- [13] Hangody, L; Kish, G; Krpáti, Z; Szerb, I; Eberhardt, R: Treatment of osteochondritis dissecans of the talus by the mosaicplasty technique – A series of the talus: *Ua Int.* 18(10): 628 – 634, 1997. preliminary report. *Foot Ankle*
- [14] Hangody, L; Kish, G; Mody, L; et al.: Mosaicplasty for the treatment of osteochondritis dissecans of the talus. : two to seven year results in 36 patients. *Foot Ankle Int.* 22(7): 552 – 558, 2001.
- [15] Kitaoka, HB; Alexander, IJ; Adelaar, RS; et al.: Clinical rating systems for the ankle-hindfoot, midfoot, hallux, and lesser toes. *Foot Ankle Int.* 15(7): 349 – 353, 1994.
- [16] Koulalis, D; Schultz, W; Heyden M: Autologous chondrocyte transplantation for osteochondritis dissecans of the talus. *Clin Orthop Relat Res.* 395:186 – 192, 2002. <http://dx.doi.org/10.1097/00003086-200202000-00021>.
- [17] Kumai, T; Takakura, Y; Higashiyama, I; Tamai, S: Arthroscopic drilling for the treatment of osteochondral lesions of the talus. *J Bone Joint Surg Am.* 81(9): 1229 – 1235, 1999.
- [18] Lee, CH; Chao, KH; Huang, GS; Wu, SS: Osteochondral autografts for osteochondritis dissecans of the talus. *Foot Ankle Int.* 24(11): 815 – 822, 2003.
- [19] Myles, P; Gin, T: *Statistical Methods for Anaesthesia and Intensive Care.* First Edition, Butterworth Heinemann Oxford, 2000.
- [20] Robinson, DE; Winson, IG; Harries, WJ; Kelly, AJ: Arthroscopic treatment of osteochondral lesions of the talus. *J Bone Joint Surg Br.* 85(7): 989 – 993, 2003. <http://dx.doi.org/10.1302/0301-620X.85B7.13959>.

- [21] Schenk, RC; Goodknight, JM: Current concepts review: Osteochondritis dissecans. J Bone Joint Surg. 78A: 439 – 456, 1996.
- [22] Taranow, WS; Bisignani, GA; Towers, JD; Conti, SF: Retrograde drilling of osteochondral lesions of the medial talar dome. Foot Ankle Int. 20(8): 474 – 480, 1999.
- [23] Thompson, JP; Loomer, RL: Osteochondral lesions of the talus in a sports medicine clinic. A new radiographic technique and surgical approach. Am J Sports Med. 12(6): 460 – 463, 1984. <http://dx.doi.org/10.1177/036354658401200611>
- [24] Tol, JL; Struijs, PA; Bossuyt, PM; Verhagen, RA; van Dijk, CN: Treatment strategies in osteochondral defects of the talar dome: a systematic review: Foot Ankle Int. 21(2): 119 – 126, 2000.
- [25] Whittaker, JP; Smith, G; Makwana, N; et al.: Early results of autologous chondrocyte implantation in the talus. J Bone Joint Surg Br. 87(2): 179 – 183, 2005. <http://dx.doi.org/10.1302/0301-620X.87B2.15376>.
- [26] Willers, C; Wood, DJ; Zheng, MH: A current review of the biology and treatment of articular cartilage defects (part I & part III). J Musculoskeletal Res. 7:157 – 181, 2003. <http://dx.doi.org/10.1142/S0218957703001125>
- [27] Zheng, MH; King, E; Kirilak, Y; et al.: Molecular characterisation of chondrocytes in autologous chondrocyte implantation. Int J Mol Med. 13(5):623 – 628, 2004.

IntechOpen



An International Perspective on Topics in Sports Medicine and Sports Injury

Edited by Dr. Kenneth R. Zaslav

ISBN 978-953-51-0005-8

Hard cover, 534 pages

Publisher InTech

Published online 17, February, 2012

Published in print edition February, 2012

For the past two decades, Sports Medicine has been a burgeoning science in the USA and Western Europe. Great strides have been made in understanding the basic physiology of exercise, energy consumption and the mechanisms of sports injury. Additionally, through advances in minimally invasive surgical treatment and physical rehabilitation, athletes have been returning to sports quicker and at higher levels after injury. This book contains new information from basic scientists on the physiology of exercise and sports performance, updates on medical diseases treated in athletes and excellent summaries of treatment options for common sports-related injuries to the skeletal system.

How to reference

In order to correctly reference this scholarly work, feel free to copy and paste the following:

Thanos Badekas, Evangelos Evangelou and Maria Takvorian (2012). Treatment of Talar Osteochondral Lesions Using Local Osteochondral Talar Autograft – Long Term Results, An International Perspective on Topics in Sports Medicine and Sports Injury, Dr. Kenneth R. Zaslav (Ed.), ISBN: 978-953-51-0005-8, InTech, Available from: <http://www.intechopen.com/books/an-international-perspective-on-topics-in-sports-medicine-and-sports-injury/treatment-of-talar-osteochondral-lesions-using-local-osteochondral-talar-autograft-long-term-results>

INTECH
open science | open minds

InTech Europe

University Campus STeP Ri
Slavka Krautzeka 83/A
51000 Rijeka, Croatia
Phone: +385 (51) 770 447
Fax: +385 (51) 686 166
www.intechopen.com

InTech China

Unit 405, Office Block, Hotel Equatorial Shanghai
No.65, Yan An Road (West), Shanghai, 200040, China
中国上海市延安西路65号上海国际贵都大饭店办公楼405单元
Phone: +86-21-62489820
Fax: +86-21-62489821

© 2012 The Author(s). Licensee IntechOpen. This is an open access article distributed under the terms of the [Creative Commons Attribution 3.0 License](https://creativecommons.org/licenses/by/3.0/), which permits unrestricted use, distribution, and reproduction in any medium, provided the original work is properly cited.

IntechOpen

IntechOpen