

We are IntechOpen, the world's leading publisher of Open Access books Built by scientists, for scientists

6,900

Open access books available

186,000

International authors and editors

200M

Downloads

Our authors are among the

154

Countries delivered to

TOP 1%

most cited scientists

12.2%

Contributors from top 500 universities



WEB OF SCIENCE™

Selection of our books indexed in the Book Citation Index
in Web of Science™ Core Collection (BKCI)

Interested in publishing with us?
Contact book.department@intechopen.com

Numbers displayed above are based on latest data collected.
For more information visit www.intechopen.com



Nail Psoriasis

Eckart Haneke

¹*Dept Dermatol, Inselspital, Univ Bern, Bern,*

²*Practice of Dermatology Dermaticum, Freiburg,*

³*Centro de Dermatología Epidermis, Instituto CUF, Porto,*

⁴*Dept Dermatol, Acad Hosp, Univ Gent, Gent,*

¹*Switzerland*

²*Germany*

³*Portugal*

⁴*Belgium*

1. Introduction

During the 8th gestational week, a condensation of cells develops on the distal dorsal aspect of the digital tip. At week 9, this migrates proximally to form a flat groove, the nail field. At week 11, an invagination develops from the proximal groove, which later forms the nail pocket or cul-de-sac, with the matrix at its bottom. Nail production starts around week 13. At the age of 20 weeks, the nail production is similar to that of an adult. From week 32 on, all nail components can be recognized (Lewis, 1954, Zaias, 1963).

The nail apparatus consists of epithelial and connective tissue components and covers the tip of the fingers and toes (Figure 1) (Lewin, 1965, Morgan et al, 2001, Zook et al, 1980). Its functions are support, protection and maintenance of the digital tips as well as enhancement of the sensory functions of the digital pulps, and the nail is a tool for scratching, defense, fine manual work, etc. The cosmetic-aesthetic and social functions of the nail have attained a lot of attention in recent years.

The nail has four epithelial components:

- The matrix epithelium is the sole structure to produce the nail plate. It is commonly divided into the proximal, medial and distal matrix (Figure 2). The existence of a so-called dorsal matrix is controversial. Most of the matrix is covered by the proximal nail fold. Under normal circumstances, its distal portion, the whitish lunula, is only seen in the thumb, index and middle finger as well as the great toe; however, manicure with pushing the free margin of the proximal nail fold back makes more of the matrix visible through the nail and lets the nail plate appear longer.

The matrix epithelium consists of a basal compartment seen as cuboid basophilic cells that migrate up to form the more eosinophilic superficial compartment (Perrin et al, 2004). Whenever a nail is avulsed the superficial compartment remains attached to it. During onychotisation, the superficial cells undergo nuclear fragmentation. Under normal circumstances, there is no granular layer.

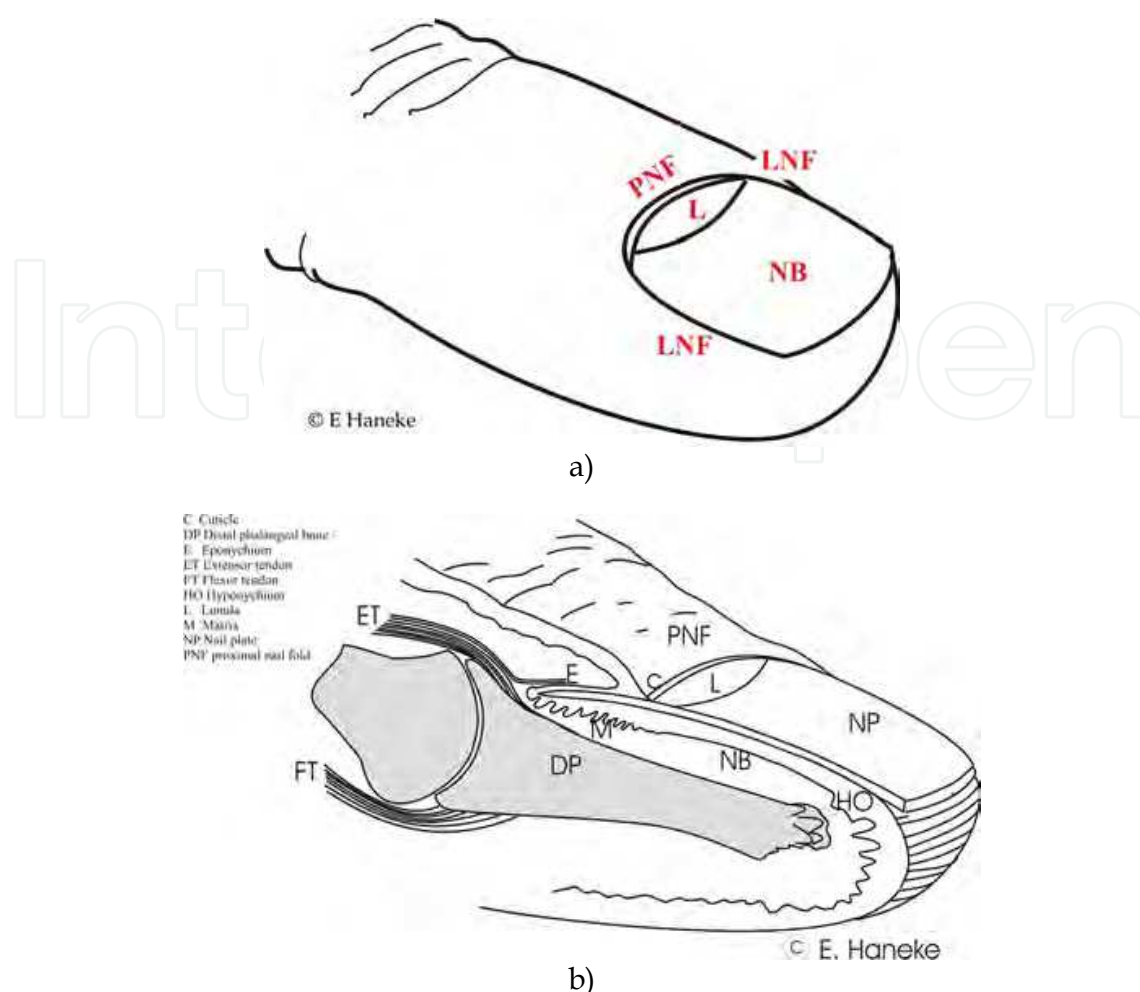


Fig. 1. Anatomy of the nail apparatus. Oblique view (A) and sagittal section (B) through the distal phalanx.

The matrix contains melanocytes most of which are located suprabasally. In light-skinned individuals, they remain functionally inactive. Independent from the skin type, the distal matrix contains more melanocytes than the proximal one (Tosti et al, 1994, Perrin et al, 1997).

The matrix connective tissue is relatively loose containing blood vessels and a considerable number of glomus bodies. Recent studies have found that matrix fibroblasts are CD 10+ similar to perifollicular fibroblasts (Lee et al, 2007- 2010). The matrix dermis has an important morphogenetic capacity allowing it to reproduce matrix epithelium when enough of it is left after trauma or superficial surgical removal. The distance from the most proximal matrix epithelium to the bone of the terminal phalanx is about 0.8 – 1 mm (Haneke, 2006, Kim et al, 2011).

- The nail bed epithelium is a relatively thin layer of keratinocytes structurally similar to tricholemmal cells. It firmly attaches the nail to the underlying distal phalanx and produces a tiny amount of nail bed keratin, which allows the nail plate to virtually slide over the nail bed without being detached from it. The nail bed keratin is structurally different from the nail plate keratin. The nail bed does not produce nail plate (de Berker

and Angus, 1996, Nishi et al, 1996, Zaias and Alvarez, 1968) although this is also controversial (Johnson et al, 1991). A normal nail bed does not form a granular layer.

The nail bed epithelium-connective tissue interface is characterized by unique longitudinal rete ridges, in which 3 to 6 layers of longitudinally running capillaries are arranged one above the other. Trauma to these capillaries may produce the characteristic splinter haemorrhages, which in nail psoriasis are equivalent to Auspitz' phenomenon of the skin. The connective tissue of the nail bed is a firm layer directly attached to the bone without any subdermal fat. This and the abundance of nervous structures in the nail bed and matrix are probably the reason for the extraordinary pain elicited by trauma to the nail apparatus.

- The hyponychium is localized at the distal end of the nail bed and forms a particular structure allowing the plate to get detached from the bed without injury. It seals the virtual space between the nail and the nail bed. The normal hyponychium shows a broad granular layer (Hanno et al, 1986, Perrin, 2008). Distal to it, digital pulp skin is present.
- The eponychium is a thin layer of keratin produced by the undersurface of the proximal nail fold (PNF). Approximately halfway it divides into the true eponychium remaining firmly attached to the dorsal surface of the nail plate and the false eponychium attached to the epidermis of the PNF's ventral surface. It forms the bulk of the cuticle, the function of which is to seal the cul-de-sac or nail pocket.

Proximally and laterally, the nail is ensheathed by the proximal and two lateral nail folds, which form a frame leaving the distal margin of the nail plate free. This allows the nail plate to grow out and not up. The proximal nail fold is a continuation of the dorsal aspect of the skin of the tip of the digit, which folds on itself thereby producing a cover for most of the matrix. Its free margin forms an acute angle, which bears the cuticle. This is the most distal portion of the false eponychium. When the distal free margin of the proximal nail fold rounds up it loses its ability to form a cuticle, and within usually a relatively short period of time the undersurface of the proximal nailfold detaches from the underlying nail plate.

The lateral nail folds are rolls of connective tissue covered with normal epithelium. Their border to the nail bed is the lateral nail groove. This is firmly attached to the nail plate preventing foreign substances from getting under the nail plate. The lateral grooves are important to guide the nails during their forward growth.

The nail plate – commonly called “the nail” – is the product of the matrix. It is made up of keratin which is a sulfur-rich fibrous keratin embedded in a sulfur-rich amorphous matrix. The fibrous protein structure is seen clearly under polarized light. In contrast to hair, which is made up of exactly the same material, it has no special outer structure like a cuticle of scales and the nail grows continuously from birth to death without a cyclical pattern. The plate exhibits a slight longitudinal and a more pronounced transverse curvature, the degree of which varies between different fingers and toes, during age and some diseases, and has a concave border proximally and a convex free margin. The lunula border reflects the shape of the matrix as it runs parallel to the proximal border of the nail. Usually three layers of the nail plate are distinguished (Figure 2): dorsal (superficial), middle, and deep (ventral). The dorsal nail plate layer is produced by the proximal matrix. Its cells are considerably flatter and thus, despite its lesser thickness, it has approximately as many cell layers as the considerably thicker middle nail plate layer with its higher cells. The dorsal nail plate is

responsible for the nail shine. The ventral layer is not true nail but keratin derived from the nail bed. Histologically, it is easily distinguished from nail plate.

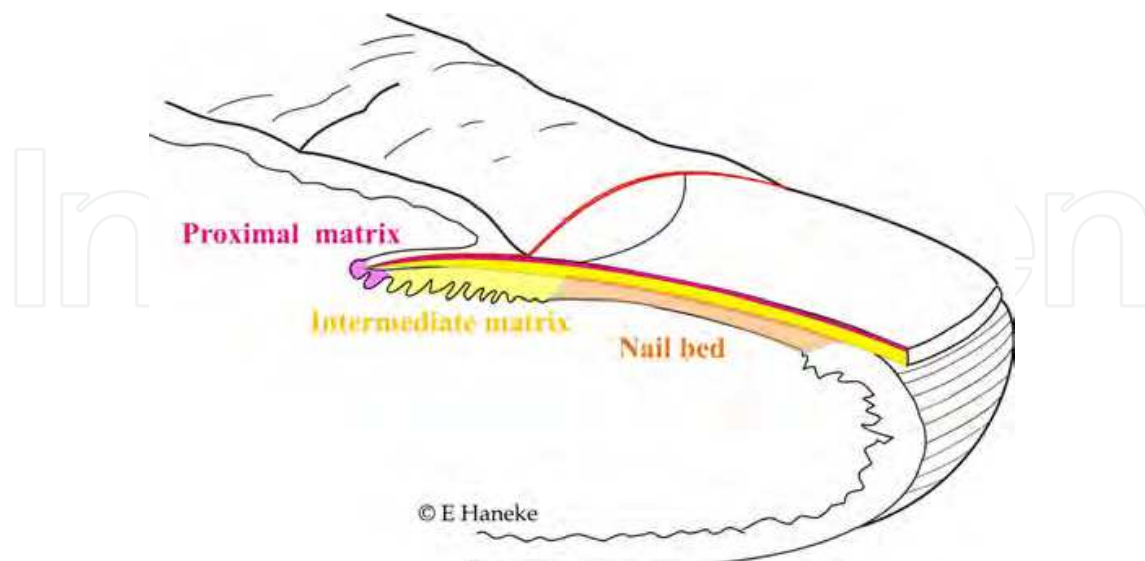


Fig. 2. Origin of the nail plate layers: The dorsal layer is produced by the proximal matrix (pink), the main intermediate and deep nail layer by the intermediate matrix (yellow) and the so-called ventral nail layer is the keratin produced by the nail bed (orange).

The nail organ is an integral part of the functional and sensory finger tip unit (Morgan et al, 2001). This is formed by the nail apparatus itself, all constituents of the finger tip, the distal interphalangeal joints with their capsule, tendons and ligaments. The entheses, insertion structures of bone with ligaments and tendons, play an important role for the functional and aesthetic integrity of the nail and have recently been found to be of utmost importance in psoriatic arthritis and nail psoriasis (McGonagle et al, 2010, 2011). The proximal tip of the matrix is just 0.8 to 1 mm from the bone of the terminal phalanx and also very close to the distal interphalangeal joint (Haneke, 2006). The joint capsule is enforced by the flexor and extensor tendons which form the dorsal and volar aponeuroses. They insert mostly at the base of the distal phalanx, but there are also fibers radiating to the more distal dorsal surface of the bone and into the connective tissue of the proximal nail fold (Frentz et al, 2000). This led some authors to call the nail a musculo-skeletal appendage (McGonagle et al, 2009a, b). Thus not only do the complex blood supply of the distal joint and nail, but also the anatomic vicinity of matrix and joint give a possible explanation why nail involvement is so frequent in psoriatic arthritis patients.

Nails grow continuously, finger nails about 3 times faster than those of the toes. The middle finger of the dominant hand has the fastest growing nail, growing between 3 to 5 mm per month. A big toenail grows about 1 mm per month. In summer and at daytime, the nails grow faster, during winter, at night, in high altitude slower. In psoriatic subjects, the nail growth rate is slightly increased. Some drugs also enhance nail growth, such as high-dose itraconazole and fluconazole, possibly also cyclosporine. Most cytostatic drugs including methotrexate, which is often used as a systemic drug for psoriasis treatment, slow down the nail growth rate. Fast growing nails are more prone to develop psoriatic pits.

2. Histopathologic nail reactions

In contrast to skin, the nail demonstrates a variety of specific reactions that are sometimes opposite to the rest of the skin. Whereas irritation and a number of inflammatory reactions cause parakeratosis in skin they may induce a granular layer in the nail, some psoriatic reactions included. Several dermatoses that are not characterized by spongiosis, may exhibit marked intercellular oedema of matrix and nail bed epithelium, e.g. in ungual lichen planus and psoriasis.

As the dorsal layer of the nail plate is produced by the most proximal portion of the matrix any alterations of the proximal matrix will translate into changes of the nail surface and uppermost layers. The bulk of the nail is produced by the middle matrix portion; alterations here will modify the nail plate both in its thickness as well as optical coherence. When the distal matrix is involved the resulting nail alterations will appear at the undersurface of the nail (Figure 2). All matrix-derived alterations will grow out with the nail. In contrast, nail bed alterations will be seen through the nail, but will not be integrated into the nail. As the nail bed keratin moves slower than the nail plate nail bed alterations remain longer or may even appear non-migratory.

Psoriasis of the nails induces characteristic histopathological changes that are pathognomonic in the vast majority of cases; however, in the beginning and with less pronounced changes it may mimic a spongiotic dermatitis or may be indistinguishable from onychomycosis if there is no proof of fungal invasion.

3. Histopathology of nail psoriasis

Whereas the main criteria for psoriasis of the skin also apply for ungual psoriasis there are some differences and, above all, there are signs not seen in the rest of the skin.

Pits are the most frequent lesions in nail psoriasis (Figs. 3, 4) with roughly 70% of the patients presenting at least some of these characteristic tiny depressions (Zaias, 1969, Tham et al, 1988). Histologically, their appearance varies slightly. In the distal nail plate, they are seen as a depression in the nail plate surface that may be lined by some parakeratotic nail cells. The more proximal the biopsy is taken, the more parakeratosis is left. Under the proximal nail fold there are not yet pits but saucer-shaped small areas of parakeratosis. When these do not break out as it most commonly happens tiny white spots remain visible giving rise to spotted nails. Usually the rest of the nail organ appears normal and only in rare circumstances is a tiny inflammatory psoriatic lesion seen at the proximal tip of the matrix. Whether or not the pits may also originate from the most proximal portion of the ventral surface of the proximal nail fold (Zaias, 1990) remains a matter of dispute. Anyhow, it is surprising how rarely the original inflammatory matrix lesions giving rise to spots and pits are seen in histopathological slides.

Nail bed changes are the second most common ungual sign of psoriasis. They may present as salmon or oil spots, which represent a small psoriatic plaque of the nailbed entirely covered by the nail plate, as onycholysis when the psoriatic plaque extends to the hyponychium, or as subungual hyperkeratosis representing a hyperkeratotic psoriatic plaque. A typical salmon spot shows slight acanthosis of the nail bed epithelium, an inflammatory infiltrate mainly made up of lymphocytes that tend to migrate into the epithelium and cause spongiosis, as well as parakeratosis on top of the epithelium, which

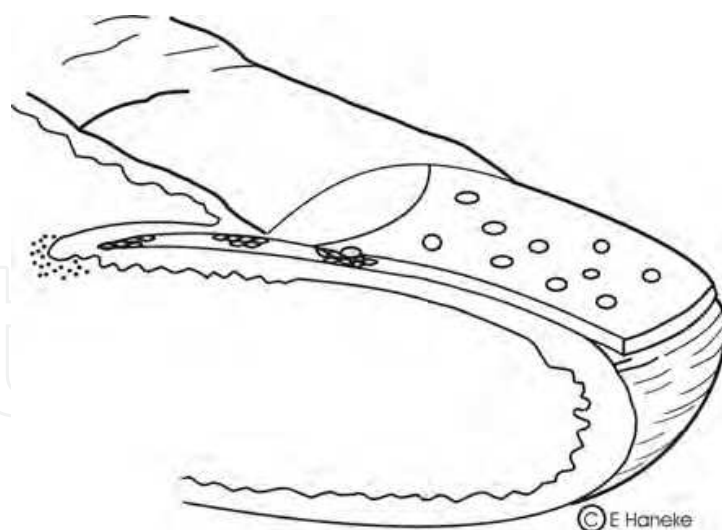


Fig. 3. Formation of psoriatic pits from a tiny inflammatory focus at the most proximal matrix.

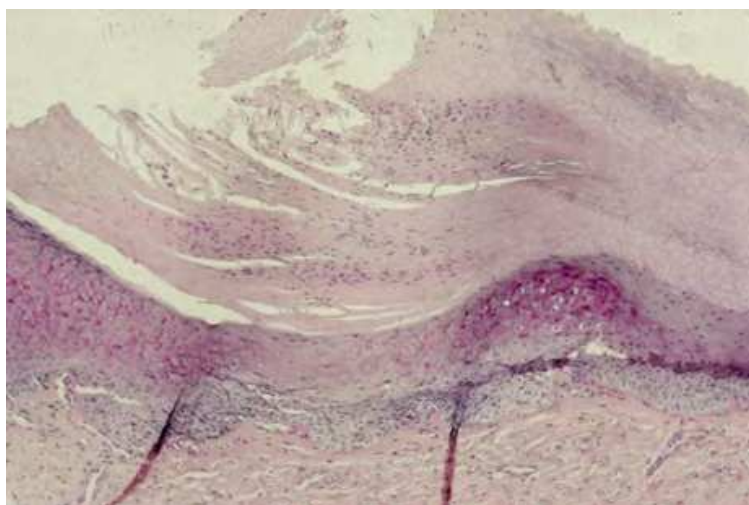


Fig. 4. Histological picture of an incipient pit, which is seen as a saucer-shaped mass of parakeratosis on the matrix epithelium.

often contains neutrophils. In more pronounced acute lesions, Munro's microabscesses may be seen. Typical for psoriasis is the arrangement of parakeratosis in obliquely ascending columns. This and the lack of fungal elements in PAS stained slides helps to distinguish this pattern from onychomycosis, which also often exhibits neutrophil collections as seen in Munro's microabscesses. Psoriatic onycholysis is located more distally in the nail bed, but principally very similar to oil spots. The neutrophil exocytosis may be less pronounced, and in old lesions it may be difficult to make the diagnosis of nail psoriasis at all as the nailbed may develop a granular layer and layered orthokeratotic hyperkeratosis. Subungual hyperkeratosis in psoriasis may sometimes be extreme mimicking even pachyonychia congenita. Huge thickening of the keratosis with parakeratosis both in horizontal layers and oblique columns may be present along with serum inclusions. The latter may form large round to oval globules, but also present as very small longitudinal structures. These serum inclusions are PAS positive and may be difficult to be differentiated by the non-experienced;

however, in contrast to fungal elements they are homogeneously positive and have no membrane staining like fungi.

At the hyponychium, the normal granular layer is lost and the tight connection of the nail plate with the most distal portion of the nail bed is loosened. Parakeratosis develops without attachment with the nail plate.

Both the matrix and nail bed may transform to an epidermis-like pattern of differentiation in old lesions with development of a granular layer and some orthokeratosis.

Isolated involvement of the middle matrix appears to be less frequent. It leads to nail plate changes clinically often seen as psoriatic leukonychia. Histopathologically, the matrix shows acanthosis and spongiosis, a dense subepithelial inflammatory infiltrate mainly of lymphocytes that also migrate into the matrix epithelium. Neutrophils may be present and sometimes concentrate under the nail plate to form spongiform pustule-like collections. There may also be parakeratotic layers in the nail plate; these “paronychotic” cell layers are distinct from areas of incomplete nuclear disintegration, which are not infrequently seen in avulsed nail strips of ingrown nails. These inclusions of parakeratosis in the nail plate give rise to the clinical picture of leukonychia (Fig. 5, 6, 7).

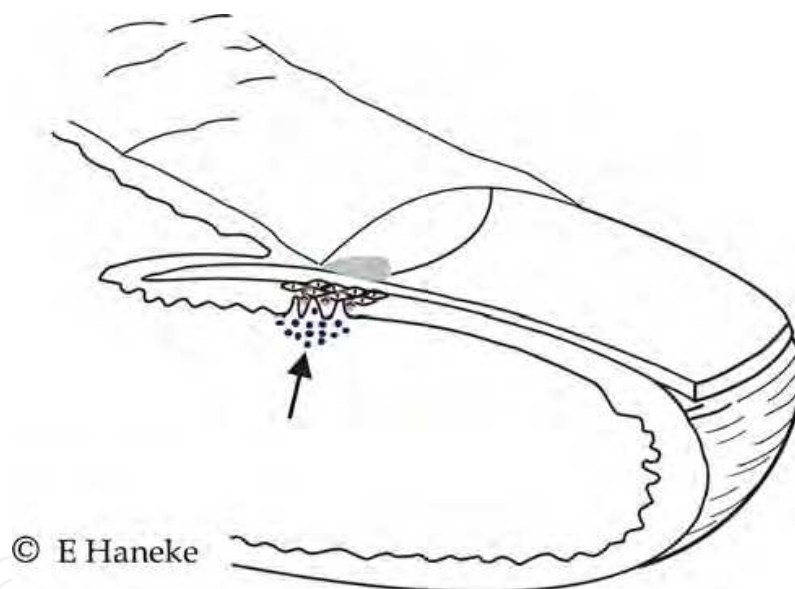


Fig. 5. Psoriatic leukonychia is seen when there is a psoriatic lesion in the middle or distal matrix

Splinter haemorrhages are a characteristic of nail psoriasis not seen in onychomycosis. They are analogous to Auspitz' phenomenon of the skin. When the fragile thinned suprapapillary epithelial plate of a psoriasis lesion is traumatized a minute droplet of blood is seen to appear in a skin lesion because the epidermis has rete pegs and finger like dermal papillae. In contrast, the nail bed is unique to have rete ridges in parallel arrangement; when a microbleeding develops it forms a narrow stripe of haemorrhage, about 0.5 – 1mm wide and 3 – maximally 10 mm long (Fig. 8, 9). They are soon included by newly produced nail bed keratin and seen as small blood lakes between the papillomatous appearing keratosis of the nail bed and the undersurface of the nail plate.

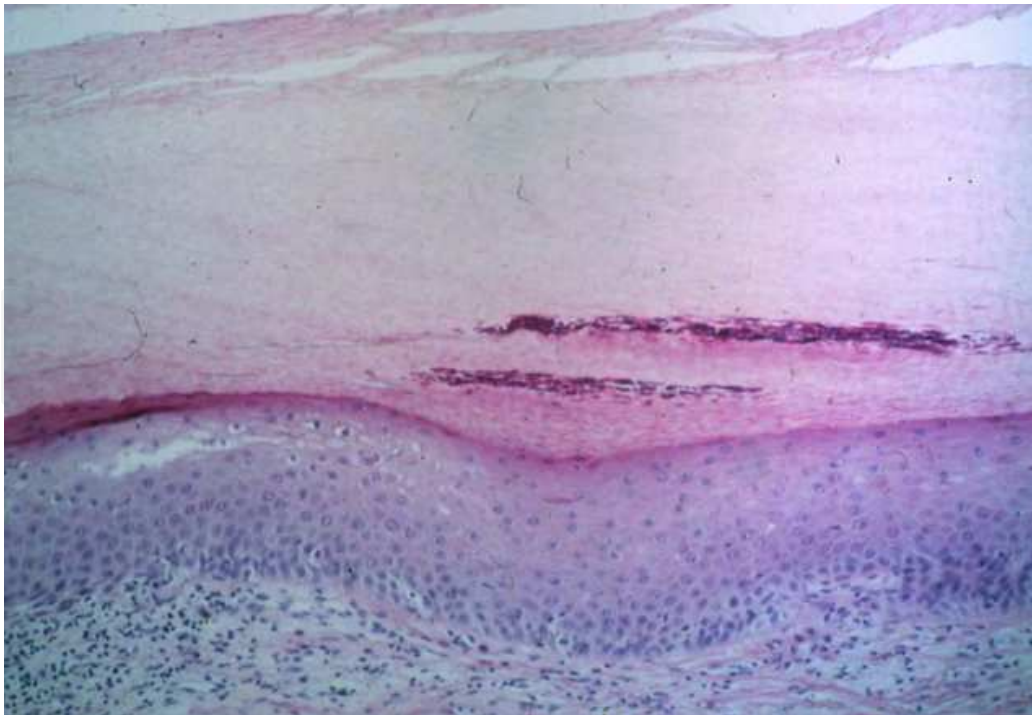


Fig. 6. Munro's microabscesses in the deep nail plate appear as leukonychic spots in the nail

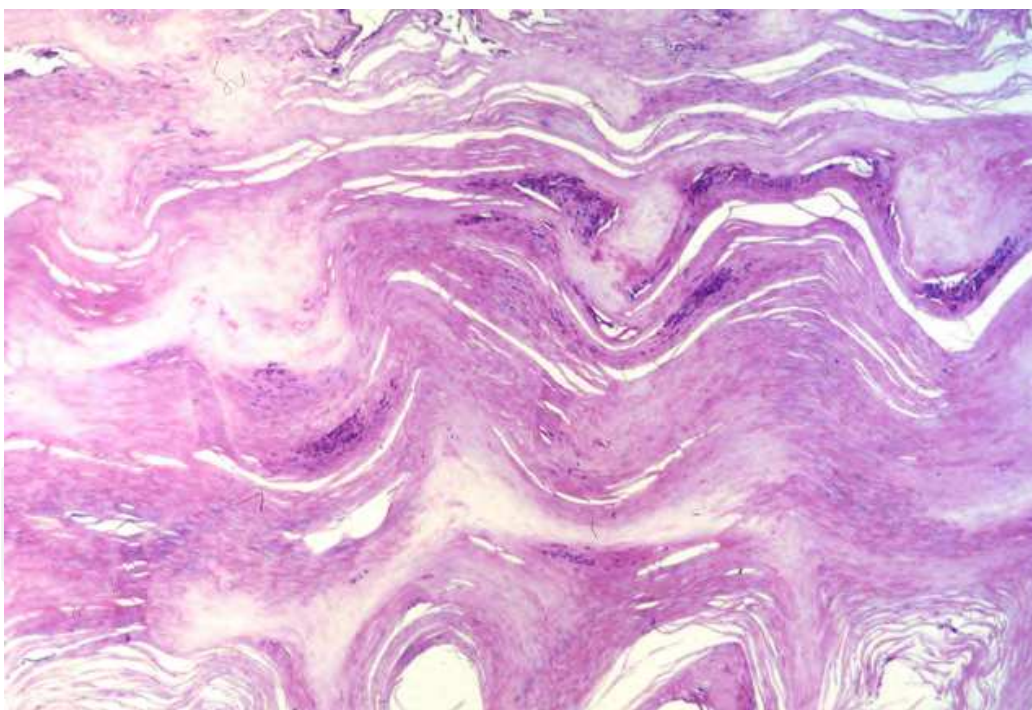


Fig. 7. This nail plate is irregular in its structure and contains many Munro's microabscesses making it appear intransparent and grayish-white

Acrodermatitis continua suppurativa is a particular form of pustular psoriasis; however, histopathologically three forms exist: with characteristic spongiform pustules, with marked spongiosis and even spongiotic vesicles, and a mixed form with spongiform pustules and spongiosis.

In pustular psoriasis, spongiform pustule formation is usually seen with collection of neutrophils gradually increasing in density toward the superficial layers of both the matrix and nail bed epithelium (Fig. 10).

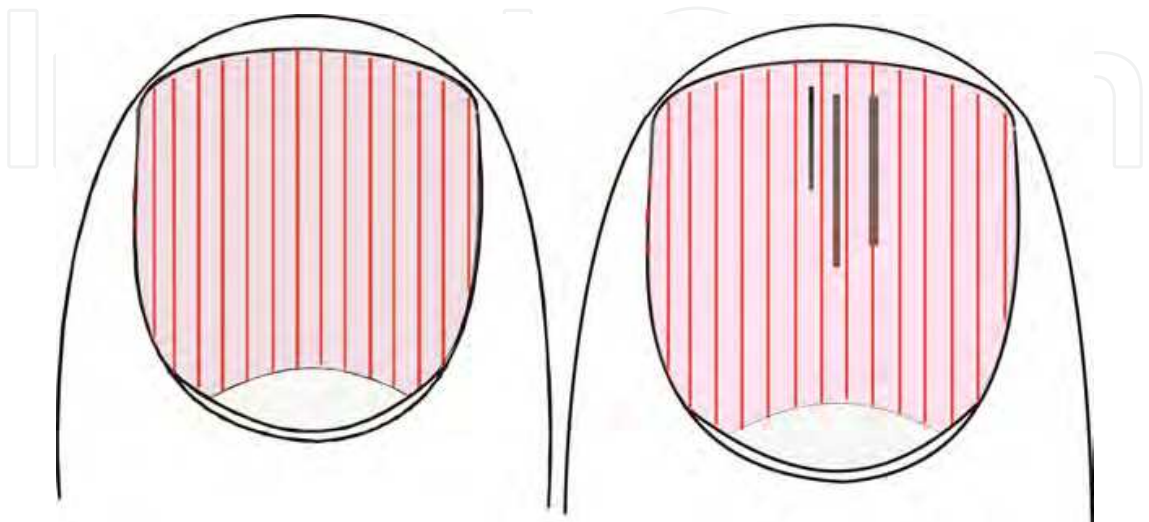


Fig. 8. Splinter haemorrhages develop when there is haemorrhage in the papillary rete ridges or when the horizontally running capillaries thrombose.

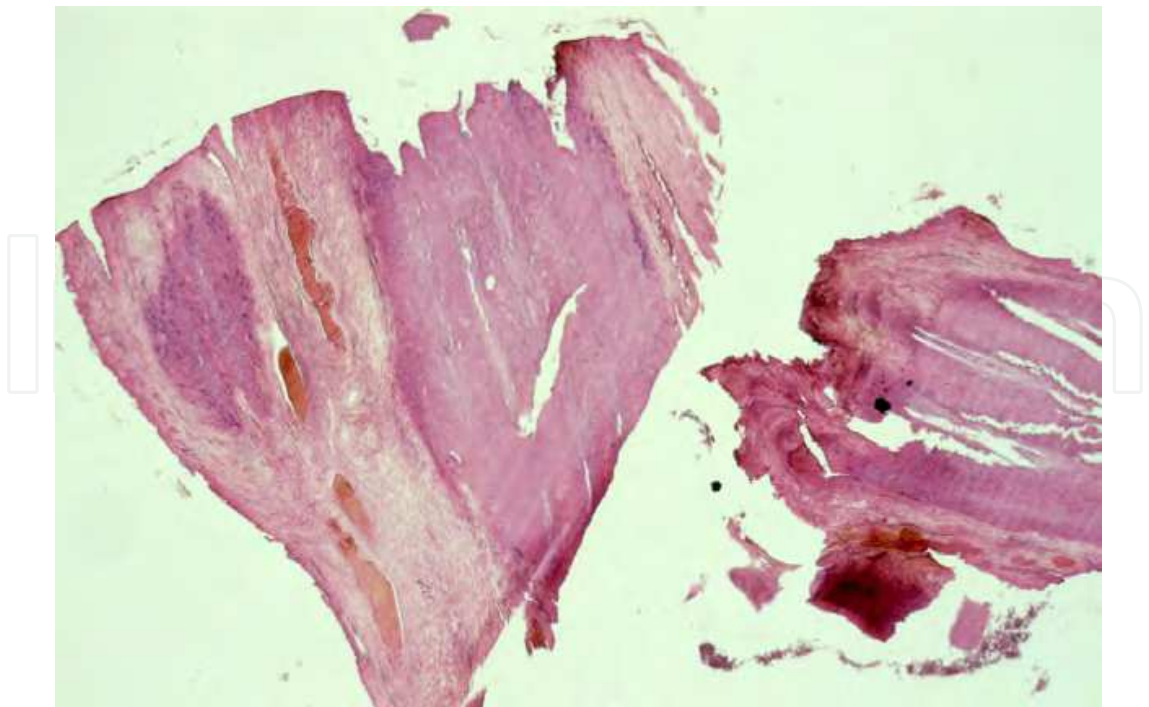
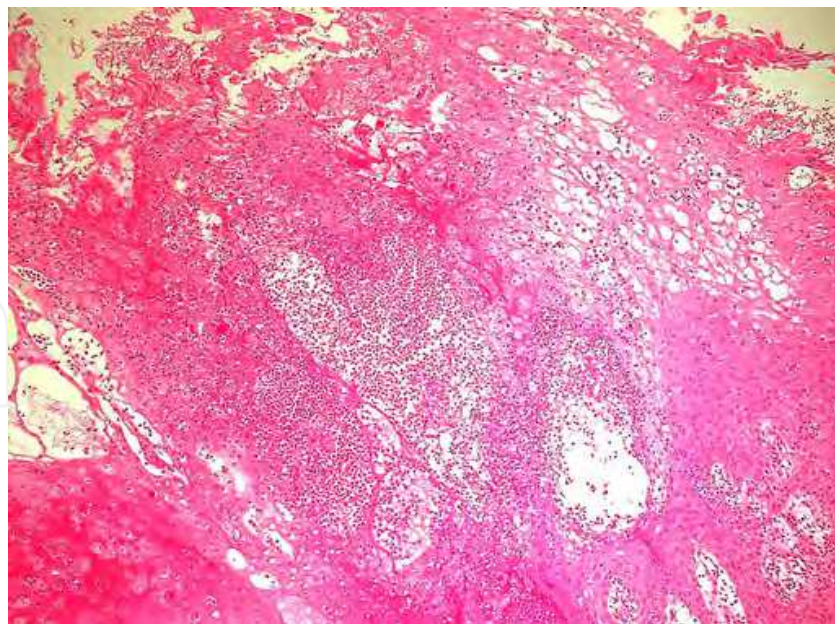
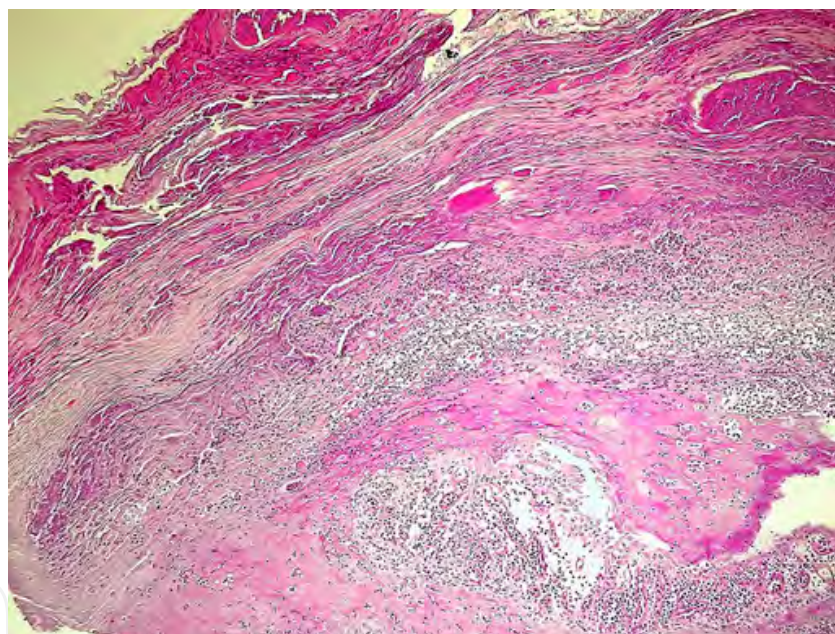


Fig. 9. Longitudinal section of a nail bed biopsy showing oval lakes of blood as sign of splinter haemorrhages.



a)



b)

Fig. 10. Acrodermatitis continua suppurativa of Hallopeau with massive spongiform pustule formation; a. Huge amounts of neutrophils are seen in the nail bed epithelium, b. Collections of neutrophils are embedded in a matrix of cornified nail bed keratinocytes.

4. Frequency

Psoriasis prevalence is about 2% in Central Europe and 1-3% worldwide. At any given time point, about 10 – 50% of the psoriatics present nail changes (Scher, 1985, Augustin et al, 2010), but approximately 90% of all psoriatic subjects will have developed nail alterations during life time. The prevalence of nail psoriasis in men is about 11% higher than in women (Augustin et al, 2010). Isolated nail psoriasis is seen in 1 – 5% (Lavaroni et al, 1994).

In a Swiss cohort of 1222 psoriasis patients, 9.4% suffered from nail involvement (Ruprecht et al, 2011).

Whereas there is a striking difference in the frequency of familial cases between psoriasis in Caucasian children (83%) as compared to Asian children (13.4%)) nail psoriasis is insignificantly more frequent in Singaporean (35.8%) than in Dutch children (22.2%). Pitting is the most common nail sign (Chiam et al, 2011). The frequency of nail psoriasis appears to be similar in Indian children (Nanda et al, 1990).

Nail psoriasis is more common in psoriatic arthritis, the prevalence is usually greater than 80%.

It appears that nail disease is relatively more frequent in males than in females (Wittkowski et al, 2011).

5. Immunogenetics

Psoriasis is a multifactorial disorder with a strong genetic background. Environmental co-factors play an important role in its manifestation. Various psoriasis susceptibility (PSORS) factors have been identified, of which PSORS1 on chromosome 6p21 has been reproduced in all studies.

Nail psoriasis has more frequently a positive family history as compared to psoriasis of the skin (52.7% vs. 43.8%), is more often associated with psoriatic arthritis (29.7% vs. 11.5%), is more often linked to early onset psoriasis (74.1% vs. 65.5%) and is fewer positive for the HLA allele Cw*0602 (33% vs. 50.3%) (Armesto et al, 2011, Gudjonsson et al, 2006). It may also be speculated that the IL23R polymorphism that is a common susceptibility factor for psoriasis (Cargill et al, 2007) and is not or only rarely found in Han Chinese may account for the higher rate of familiarity of psoriasis in Caucasians as compared to Asians (Chiam et al, 2011).

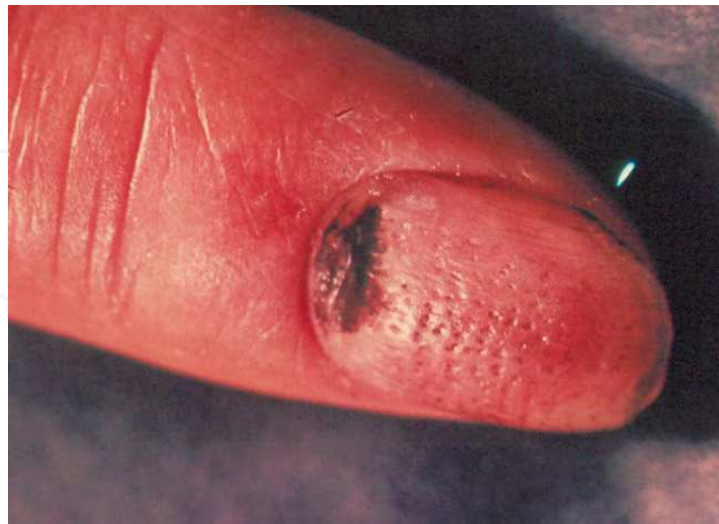Nail psoriasis is associated with a higher frequency of psoriatic arthritis and a more progressive form of the disease (Williamson et al, 2004, Serarslan et al, 2007). The skin and nail lesion usually manifest before the arthritis (Mease , 2002).

6. Clinical lesions of nail psoriasis

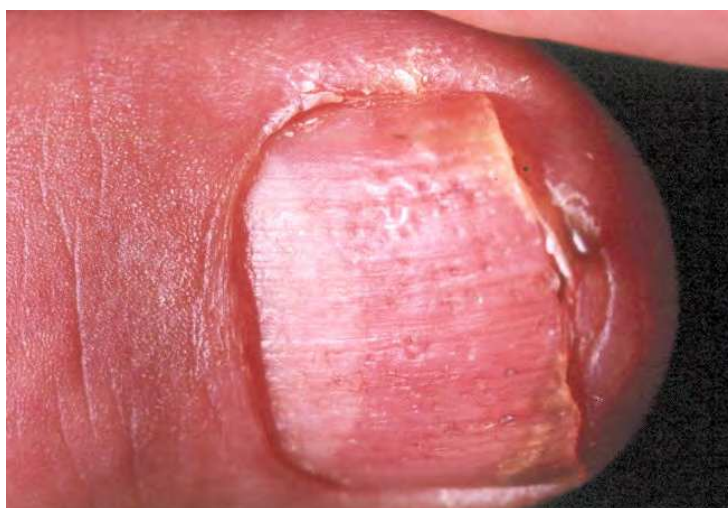Psoriasis patients with nail involvement have a longer disease duration, higher disease severity, more than double the frequency of psoriatic arthritis, more pronounced impairment of disease related quality of life, they were statistically significantly longer off work, and had a 2.5 fold higher rate of in-hospital treatments (Augustin et al, 2010).

Nail psoriasis is characterized by pits, salmon spots, onycholysis, subungual hyperkeratosis and some more signs that are less frequent. The psoriatic nail changes may be classified according to their origin: Pitting, leukonychia, nail plate thickening, crumbling and red spots in the lunula originate in the matrix whereas oil drop discoloration (salmon spots), nail bed hyperkeratosis, onycholysis and splinter haemorrhages derive from the nail bed. Swelling of the proximal nail fold reflects paronychia and swelling of the distal interphalangeal joint is suggestive of psoriatic arthritis. Psoriatic pachydermoperiostosis leads to enlargement of the entire distal phalanx.

Pits are generally said to be the most frequent signs. They are small, well delimited depressions on the surface of the nail plate with usually equal size and depth (Figs 11-12).



a)



b)

Fig. 11. Psoriatic pits are small depressions of the nail surface of equal size and depth. The pits in a are artificially stained by dithranol treatment, b shows distal onycholysis in addition.

Analogous lesions are small white to yellowish spots that are mainly seen in the proximal nail plate when the parakeratosis does not break off the plate. This is called spotted nails (Tüpfelnägel in German), a term not commonly used in the Anglo-American literature. A number of ten or more pits per nail or more than 60 pits in all nails is commonly seen as proof of psoriasis (Baran & Haneke, 2007). Both pits and spots derive from tiny lesions in the most proximal matrix and possibly the most proximal part of the ventral surface of the proximal nail fold (Zaias, 1990). The length of a pit represents the length of time of the psoriatic matrix lesion, its width is indicative of the width of the lesions and the depth either of the severity of the lesion or a lesion that extends a bit into the intermediate matrix. Pits are usually arranged irregularly but sometimes they form longitudinal or even

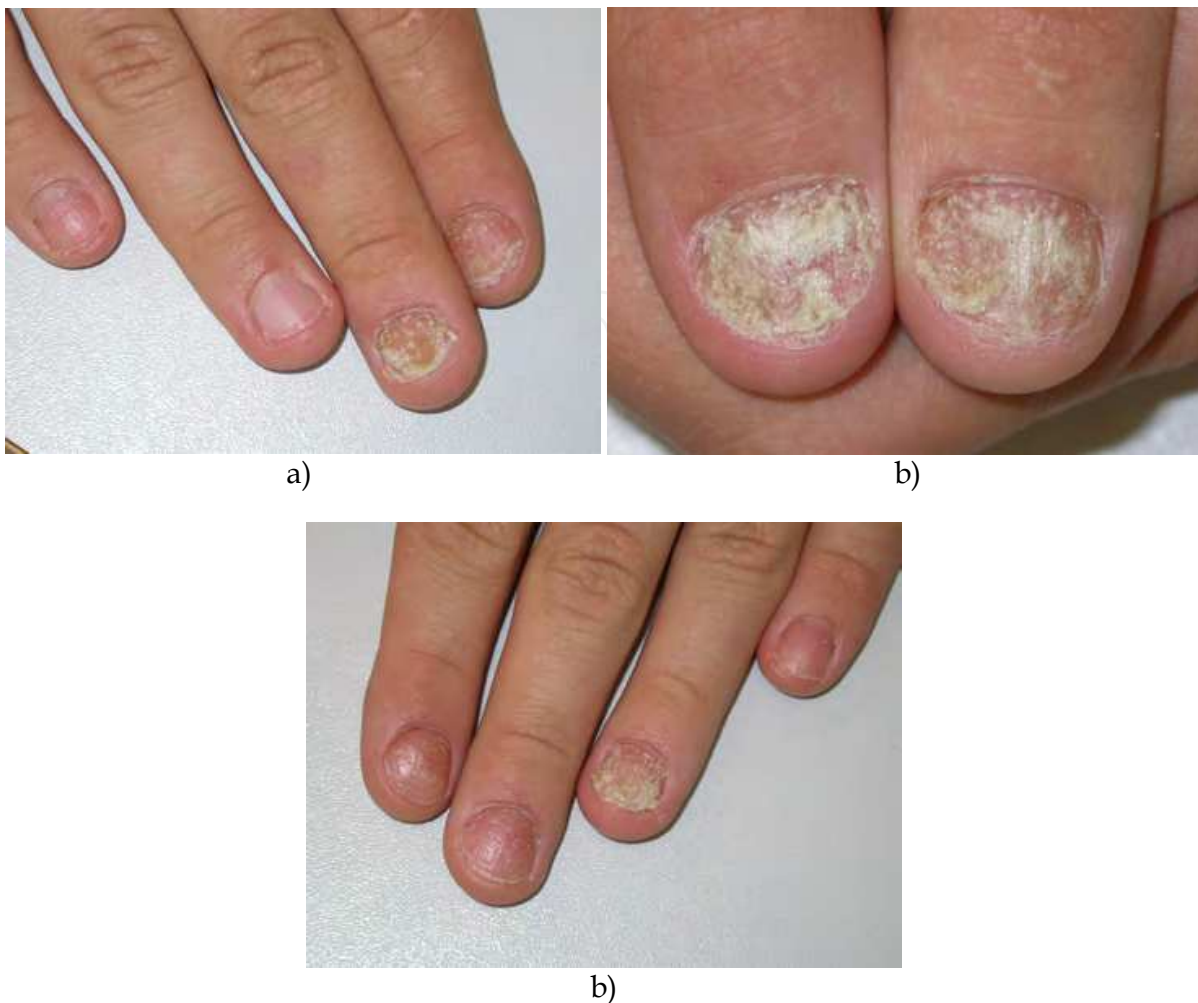


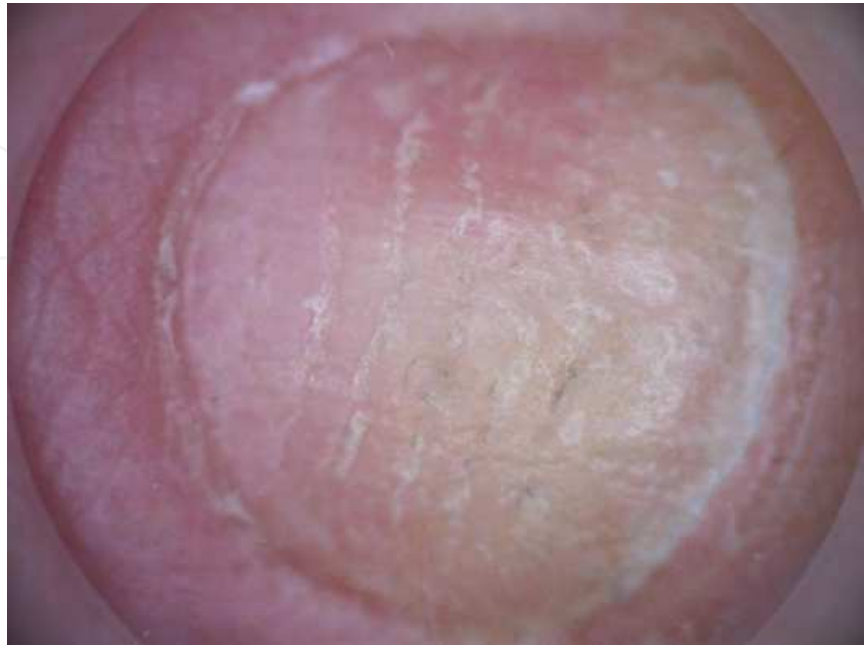Fig. 12. a - c. 16-year-old boy with marked nail psoriasis. Note that some nails are almost destroyed, other are much less involved.

transverse rows. Longitudinal rows of pits are due to repeated minor trauma at exactly the same location of the proximal matrix whereas transverse ones may reflect a trauma that elicited a Köbner phenomenon at many spots at the same time. Rarely, shallow transverse lines are seen indicating a microtrauma to the entire width of the matrix. The variable arrangement of the pits may cause a clinical picture that varies within a relatively short period of time. It is now thought that pits may be due to microtrauma of the proximal matrix, which is the closest to the articulation, from the distal interphalangeal joint. Pits in horizontal rows are equivalent to Beau's lines (Fig. 13).

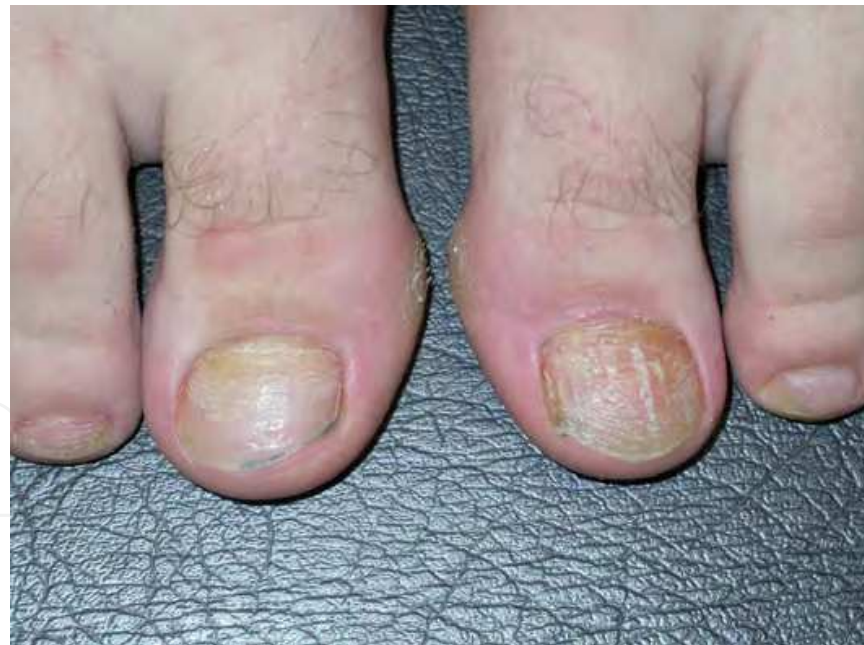In pustular psoriasis, pits may occur that are much larger than usual pits (Fig. 14); they are also called elkonyxis.

Salmon or oil spots represent circumscribed psoriasis plaques of the nail bed. Their specific colour is due to the fact that the psoriatic scales are compressed under the nail plate and imbibed with serum that makes them appear yellowish-reddish mimicking a drop of oil on a sheet of paper. Once a psoriatic plaque has reached the hyponychium or when it started at the hyponychium the scales are not or no longer compressed by the overlying nail plate and may break out giving rise to onycholysis (Fig 15).

Small lesions in the intermediate and distal matrix may appear as red spots whereas extensive lesions may cause a red lunula before the resultant nail plate changes obscure these alterations.



a)



b)

Fig. 13. Pits arranged in horizontal rows. On finger nails, which grow faster they are still identifiable as single pits (A) whereas on toenails, due to their slow growth rate they appear as transverse furrows and lines (B).

Sometimes, psoriasis of the nail bed may cause important hyperkeratosis that may in extreme cases resemble pachyonychia congenita. In addition to subungual hyperkeratosis

there may also be a thickening of the nail plate itself. Clinically this looks like a rough nail with irregular surface and loss of transparency, which is mainly due to wavy arrangement of the nail lamellae as well as inclusion of serum and neutrophilic abscesses.

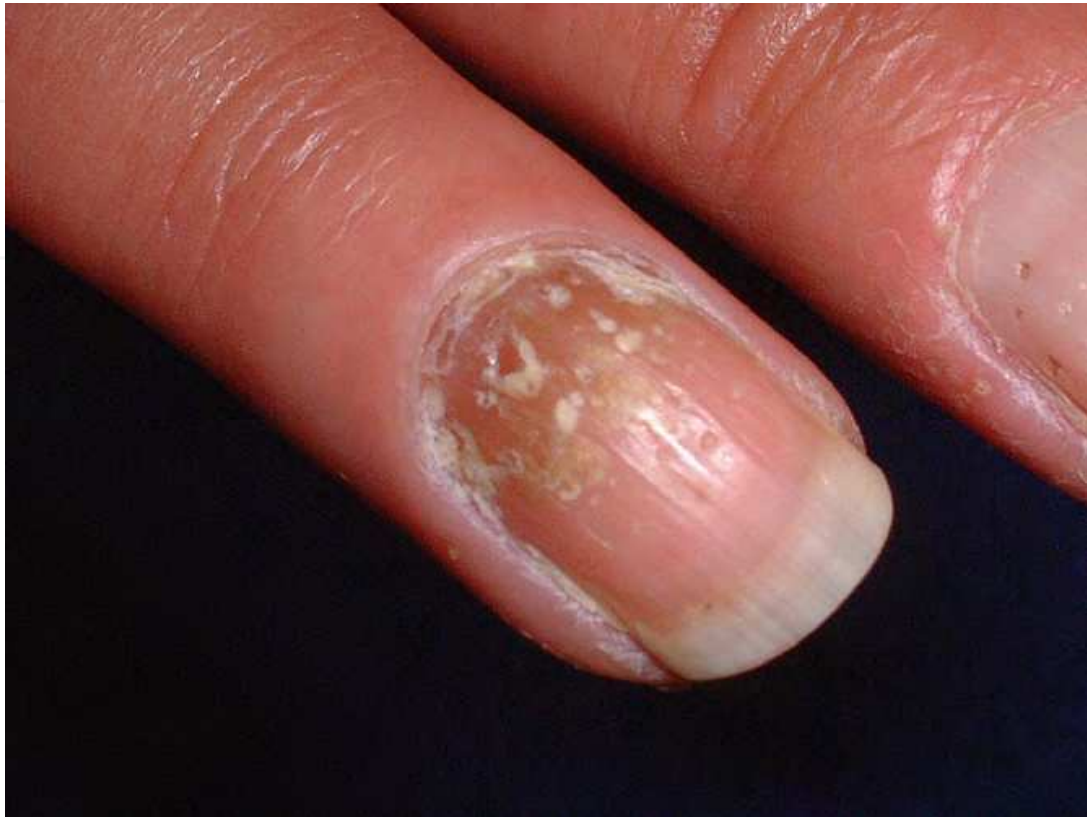

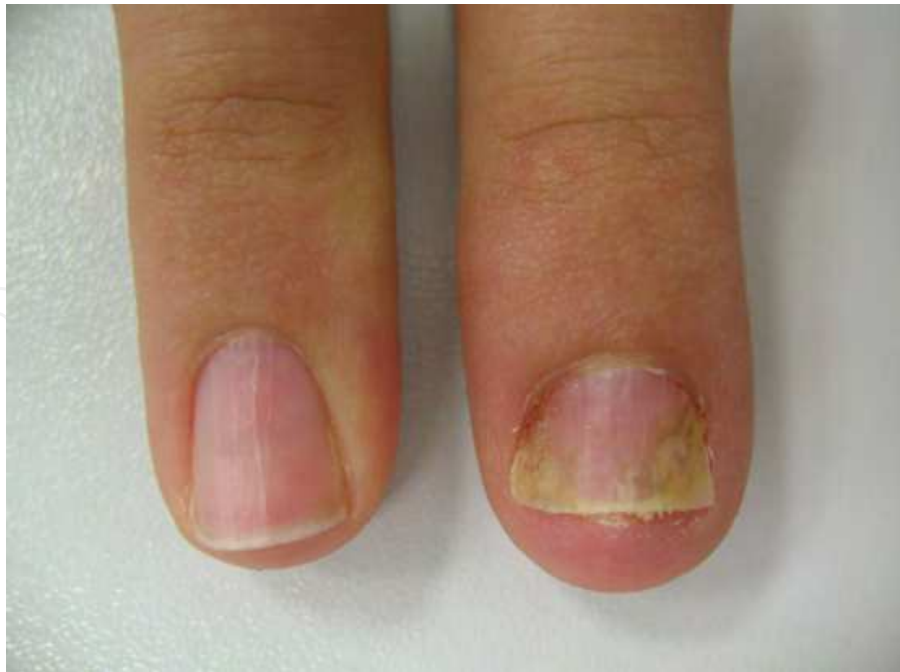Fig. 14. Nail involvement in pustular psoriasis of the palms and soles (Barber-Königsbeck type). Note the relatively large pits and some ivory-coloured spots. These large surface depressions are called elkonyxis.

Small dark-brown to black longitudinal streaks in the nail bed, mainly in distal location, are called splinter haemorrhages (Fig 16). They are due to thromboses of the dilated capillaries of the nail bed papillary ridges, which run all along the nail bed with 3 to 5 layers of capillaries one above the other.

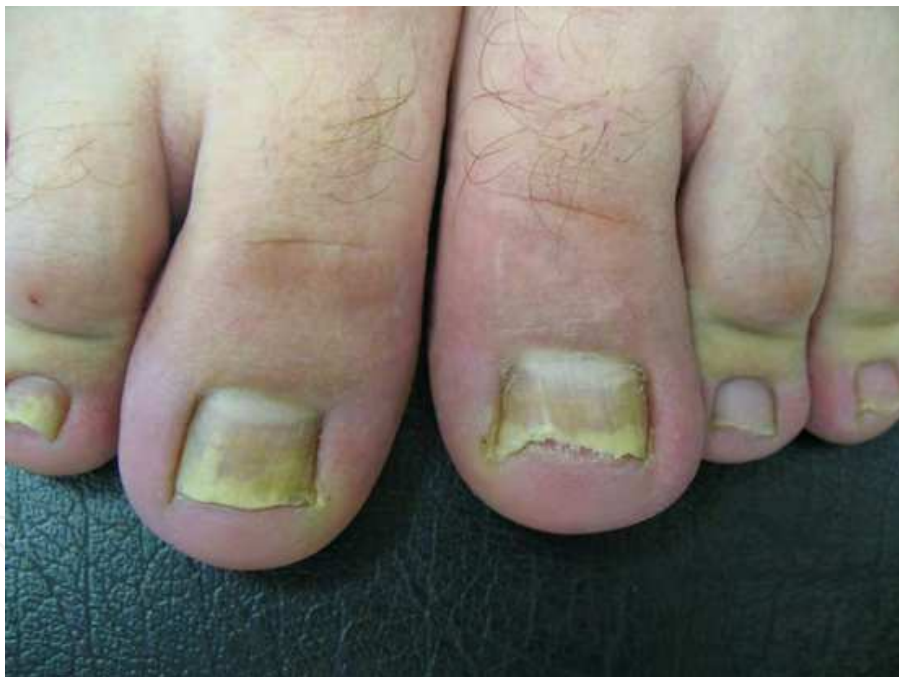Psoriatic leukonychia is relatively rare. It usually represents a focus of parakeratosis in the intermediate nail layers. It is often associated with other signs of nail psoriasis and may be seen as an advancing edge in acute-onset nail psoriasis.

Larger psoriatic lesions of the nail matrix cause crumbly nails, even complete nail destruction. They are often associated with psoriatic arthritis.

Pustular psoriasis of the nails is seen in palmar plantar pustular psoriasis of Barber-Königsbeck (Figures 14, 17), in generalized pustular psoriasis of von Zumbusch and in Hallopeau's acrodermatitis continua suppurativa. In palmar plantar pustular psoriasis, nail involvement is commonly seen as yellow lakes of pus under the nail plate. This is often associated with elkonyxis. In generalized pustular psoriasis, nail involvement usually leads to nail dystrophy.



a)



b)

Fig. 15. Subungual hyperkeratosis in distal nail bed psoriasis. A. Fingernails, B toe nails.

Acrodermatitis continua suppurativa of Hallopeau is an insidiously developing disease of the tip of the finger commonly commencing dorsally and slowly involving the nail apparatus (Figs. 18, 19 a, b). The diagnosis is often only made late when there is already a certain degree of nail dystrophy. In very typical cases, the finger or toe tip rounds up, loses its nail, the skin is fiercely red with some tiny pustules. Radiographically, resorption of the corona unguicularis becomes evident. In acute cases, the skin may appear superficially necrotic.

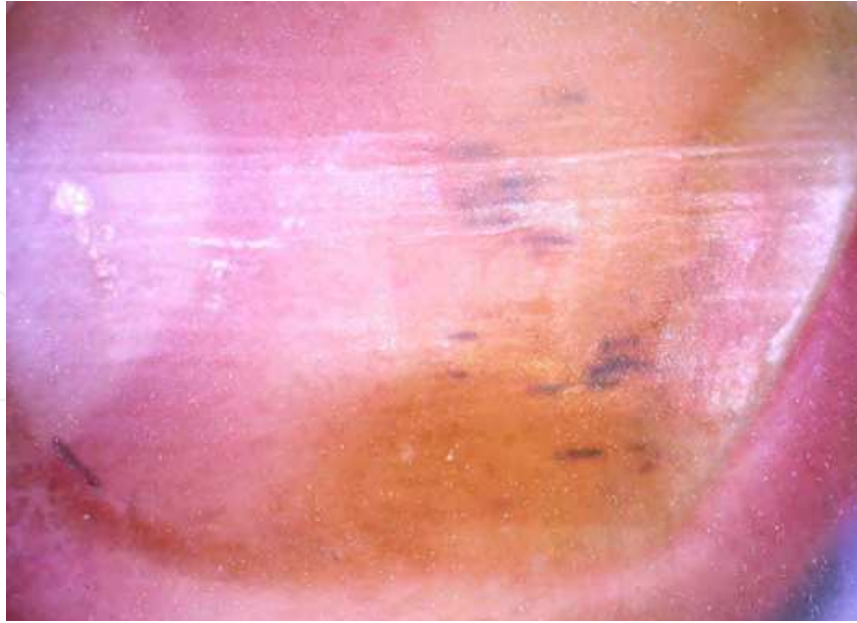


Fig. 16. Splinter haemorrhages in a nail with salmon spot

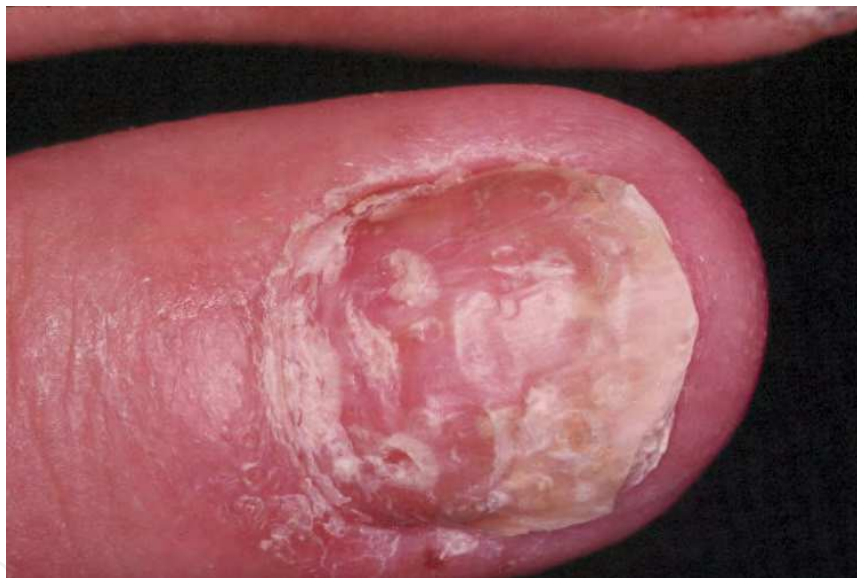

Fig. 17. Psoriasis pustulosa of Barber-Königsbeck

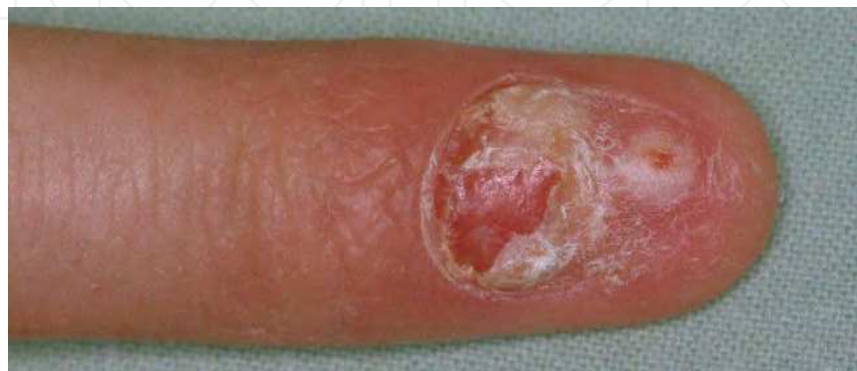
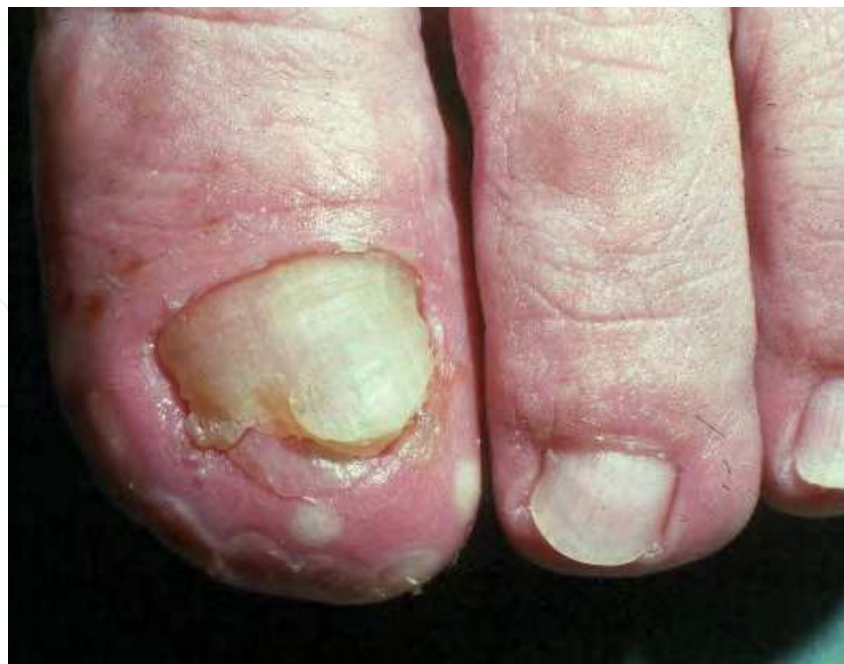
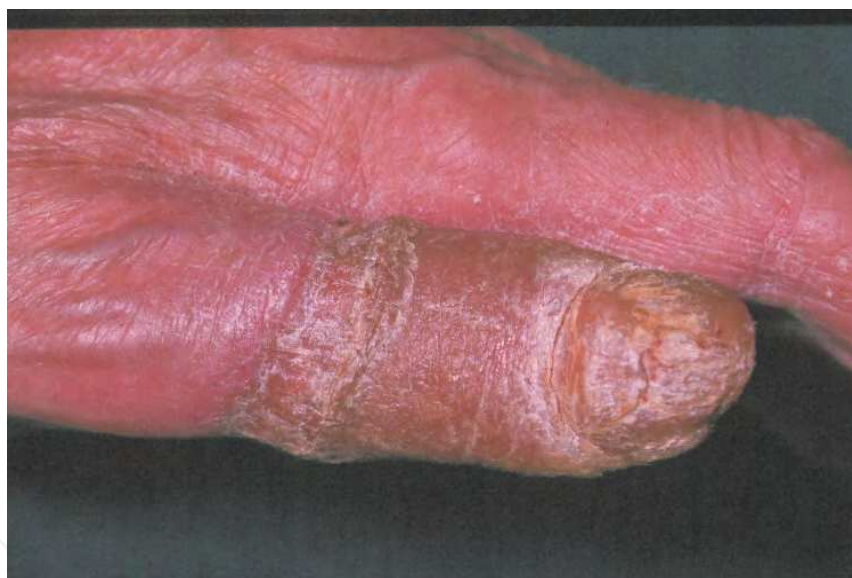Fig. 18. Early acrodermatitis continua suppurativa



a)



b)

Fig. 19. Acrodermatitis continua suppurativa. A. Pustules have been present for more than 12 years in this elderly lady. B. Relatively acute onset of acrodermatitis continua suppurativa in a patient with bronchial carcinoma; whether this is a causal or accidental association is not clear.

Psoriatic paronychia develops when the periungual skin is affected by psoriasis, but it is also commonly seen in psoriatic arthritis with nail involvement (Fig. 20). The chronic inflammation causes thickening of the free edge of the proximal nail fold with consecutive loss of the cuticle and later loss of attachment of the nail fold's ventral surface to the underlying nail plate. This allows foreign material such as dirt, microorganisms or allergenic substances to enter the space under the nail fold where they may aggravate the inflammation.

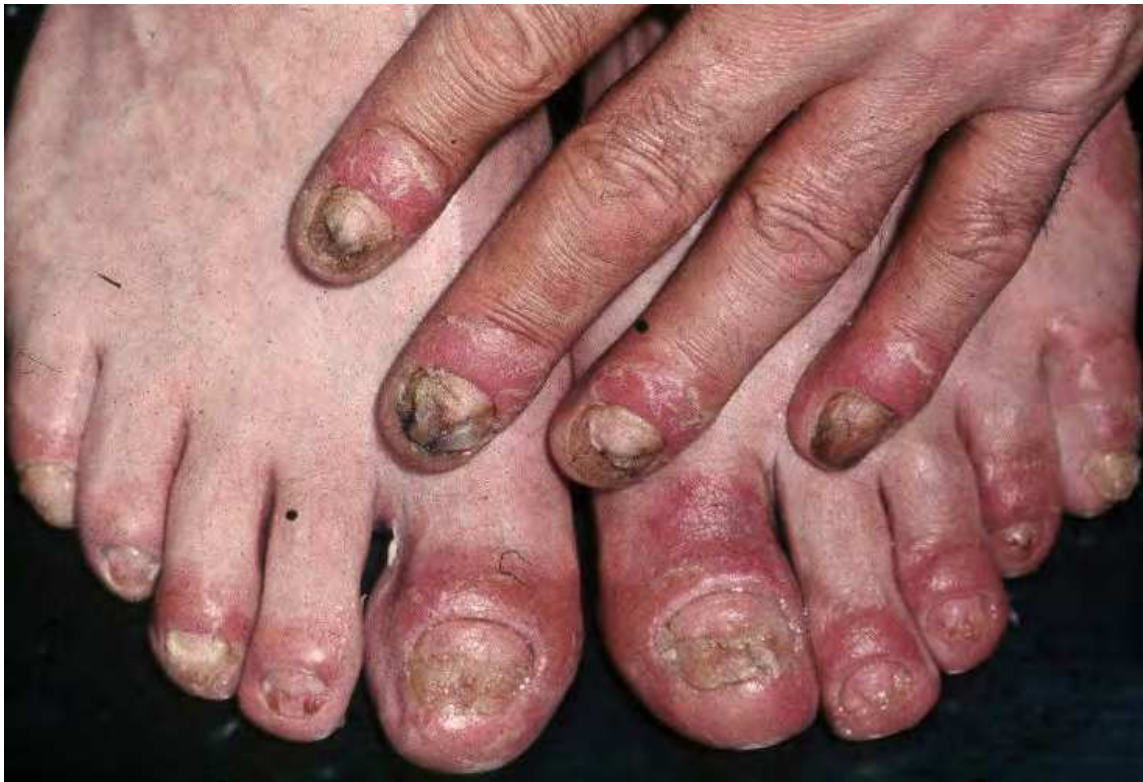

Fig. 20. Psoriatic paronychia in a patient with psoriasis arthropathy.

Psoriatic enthesitis of the distal interphalangeal joint is a painful inflammation of the insertions of tendons and ligaments mainly at the base of the distal phalanx. This may cause swelling of the distal joint with stiffness and loss of the dorsal creases of the distal interphalangeal joint and a shiny skin.

Psoriatic pachydermoperiostosis is a rare event. It is associated with bone appositions which also lead to a widening of the base of the distal phalanx with consecutive widening of the nail plate.

In almost a quarter of the patients with latent psoriatic arthritis, radiological assessment will detect changes not seen clinically (Khan et al, 2003).

7. Quality of life

Nail psoriasis has been shown to severely impair quality of life (see Scoring of nail psoriasis). Pain, cosmetic embarrassment, impaired function, loss of dexterity are just some of the complaints brought forward by the patients (De Jong et al, 1996). More than 90% of the patients consider their nail psoriasis to be a significant social problem affecting their professional work, and more than half of them experienced pain (de Berker, 2009, Gupta and Cooper, 2009).

7.1 Scoring of nail psoriasis

To score the extent and severity of nail psoriasis the **nail psoriasis severity index** (NAPSI) was developed (Rich and Scher, 2003). Each nail is divided into 4 quadrants by a horizontal

and a vertical line. Nail matrix and nail bed are scored independently. Any of the matrix signs – pitting, leukonychia, red lunula spots and crumbling – as well as the nail bed signs – onycholysis, salmon or oil spots, subungual hyperkeratosis, splinter hemorrhage – are counted. Absence is given 0, presence in one quadrant 1, presence in two quadrants 2 etc up to 4 quadrants receiving 4. Matrix and nail bed signs are added resulting in a maximum score of 8 per nail. All finger nails can have a maximum NAPS I score of 80, finger and toenails of 160. All of the 8 individual features of matrix and nail bed psoriasis are just given one score independent from their number per quadrant. For a target nail, the same technique can be used to evaluate all 8 parameters (pitting, leukonychia, red spots in lunula, crumbling, oil drop, onycholysis, hyperkeratosis, and splinter hemorrhages) in each quadrant of the nail, giving that one nail a score of 0-32. The NAPS I is a useful tool for nail evaluation in the course of therapeutic studies, both for the effect on all nails as well as for the judgment of a target nail (Rich and Scher, 2003). Interobserver reliability for the total NAPS I score is good whereas the nail score only shows moderate agreement (Aktan et al, 2006).

The NAPS I has some limitations. It does not consider the number of pits or red spots of the lunula per quadrant nor the size of an oil spot or the thickness of subungual hyperkeratosis. This limits its use to assess improvement in the course of a treatment (Parrish et al, 2004). Therefore, an additional gradation was proposed for each sign from absent (= 0), mild (= 1), moderate (= 2) and severe (=3) as a qualitative scale similar to that used in the Psoriasis Area and Severity Index (PASI). Nail crumbling is given the same score like a pit, but is considerably more severe. Pustular psoriasis and psoriatic arthritis are not included in the NAPS I.

A **modified NAPS I** was developed for patients with psoriatic arthritis (Maejima et al, 2010). This modified NAPS I is higher in patients with psoriasis of the proximal nail fold, distal interphalangeal (DIP) joint arthritis whereas there was no correlation with the modified NAPS I and other systemic signs. Nail psoriasis was assumed to be related to the Koebner phenomenon and local inflammatory DIP joint arthritis in PsA patients, and nail involvement in PsA was suggested to be among the disorders indicative of distal phalanx enthesitis (Tan et al, 2007, Elder et al, 2010).

Nail psoriasis has both a physical and psychological impact on the patients negatively influencing their quality of life (QoL). A **nail psoriasis quality of life index** (NPQ10) was developed to measure life quality impairment due to nail psoriasis and its modification in the course of treatment (Ortonne et al, 2010). Again, psoriatic arthritis patients are not included in the NPQ10. Of the 17000 members of the French Association pour la lutte contre le psoriasis, 4000 were asked to fill in a questionnaire regarding the physical aspects of nail psoriasis. Roughly one third responded and 795 of them had nail psoriasis. The items were elaborated by physicians and patients alike. The patients rated their nail psoriasis as bothersome in 86%, as unsightly in 87%, and as painful in 59%. The number of nails involved significantly affected the pain, aesthetic and functional impairment. Whereas 86% received therapy, 72% were dissatisfied with their treatment. From these facts, 10 questions were created, only one of which concerned pain, the other 9 were related to functional handicaps in daily life. Answers are scored from 0 to 2 with 0 being 'no without hesitation' (absent) or 'not painful', 1 not for 'yes sometimes' or 'not very painful', and 2 for 'yes

without hesitation’ or ‘very painful’. Item 2 and 6 are specific for toe and finger nail psoriasis, respectively. Item 7 relates only to patients driving a car. Scores are transferred into percentages in order to be able to compare them always resulting in a maximum of 100. A test-retest questionnaire was sent out to a few patients yielding a very good reproducibility. NPQ10 scores are significantly higher in patients having both finger and toe nail psoriasis, in female psoriatics, and in patients with a shorter history of psoriasis (Ortonne et al, 2010). The NPQ10 score shows good correlation with the dermatology life quality index (DLQI) (Finlay and Khan, 1994).

State the location of your psoriasis of the nails		
1. Fingernails	2. Toenails	3. Both
<div><div>1. Would you say that your psoriasis of the nails is mostly:</div><div><div>1. Very painful</div><div>2. Not very painful</div><div>3. Not painful</div></div></div> <div><div>2. Because of my psoriasis of the nails, I have difficulty putting my shoes on:</div><div><div>1. Always</div><div>2. Sometimes</div><div>3. Never</div></div></div> <div><div>3. Because of my psoriasis of the nails, I don't do any of the jobs I usually do around the house:</div><div><div>1. Always</div><div>2. Sometimes</div><div>3. Never</div></div></div> <div><div>4. Because of my psoriasis of the nails, I get dressed more slowly than usual:</div><div><div>1. Always</div><div>2. Sometimes</div><div>3. Never</div></div></div> <div><div>5. Because of my psoriasis of the nails, I have trouble putting on my socks (or stockings or tights):</div><div><div>1. Always</div><div>2. Sometimes</div><div>3. Never</div></div></div> <div><div>6. Because of my psoriasis of the nails, I have trouble turning my door key:</div><div><div>1. Always</div><div>2. Sometimes</div><div>3. Never</div></div></div> <div><div>7. Because of my psoriasis of the nails, I have trouble driving my car:</div><div><div>1. Always</div><div>2. Sometimes</div><div>3. Never</div></div></div> <div><div>8. Because of my psoriasis of the nails, someone helps me to get dressed:</div><div><div>1. Always</div><div>2. Sometimes</div><div>3. Never</div></div></div> <div><div>9. Because of my psoriasis of the nails, I avoid doing big jobs around the house:</div><div><div>1. Always</div><div>2. Sometimes</div><div>3. Never</div></div></div> <div><div>10. Because of my psoriasis of the nails, I am more irritable than usual, and bad-tempered with people:</div><div><div>1. Always</div><div>2. Sometimes</div><div>3. Never</div></div></div>		

Table 1. Questionnaire of the NPQ10 (Ortonne et al, 2010)

The **psoriasis weighted extent and severity index (PWESI)** evaluates the skin disease on a scale from 0 (none) to 4 (extensive) and severity of skin disease on a scale of 0 to 4 (intensely inflamed). Ten areas are assessed, among them hands/fingers/fingernails (Wittkowski et al, 2011).

The **extended 10-area linear psoriasis area and severity index (XL-PASI)** combines the PASI and PWESI scoring methods (Feldman and Krueger, 2005) and includes the assessment of surface area involved as well as dimension for scaling, erythema, thickness and joint involvement for specific areas of psoriatic involvement. As with the PASI, severity

is graded from 0 to 4 and body surface is divided into ten areas and each is quantified. The XL-PASI scale ranges from 0 to 148 (Wittkowski et al, 2011).

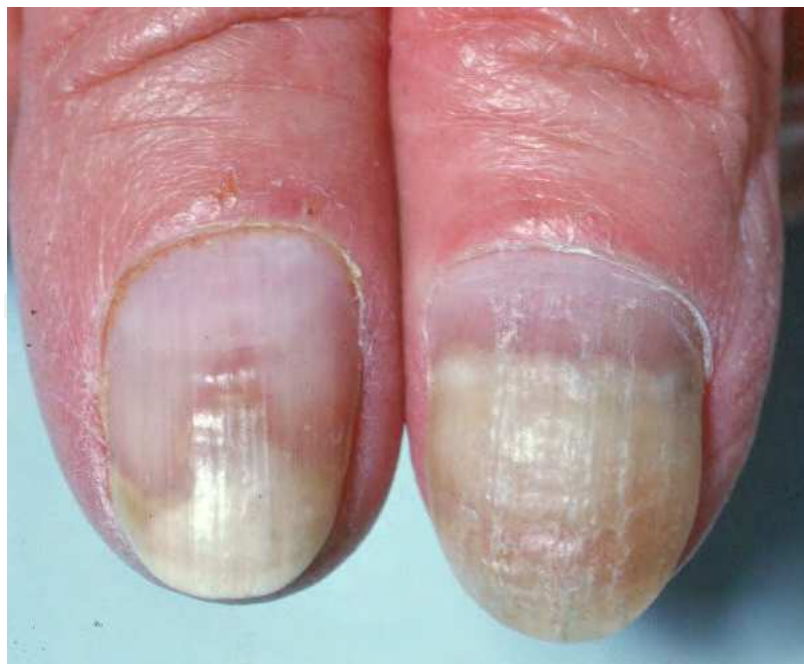8. Differential diagnosis of nail psoriasis

There is a wide range of potential differential diagnoses, the most important of which are onychomycoses (Table 2) and nail dystrophies after minor trauma, in chronic venous insufficiency and impairment of the peripheral circulation.

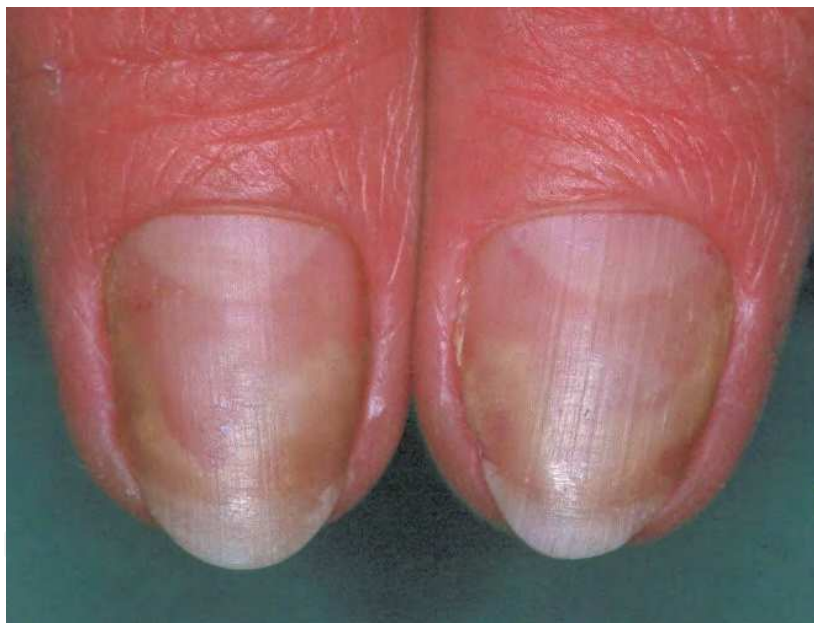Onychomycoses are the most frequent nail disorders. Distal and distal-lateral subungual onychomycosis (DLSO) are mainly due to dermatophytes with *Trichophyton rubrum* being the most frequent pathogen although *T mentagrophytes* (interdigitale) also plays an important role. All other dermatophytes are rather rare and the role of most yeasts and non-dermatophyte moulds as primary nail pathogens remains disputed. DLSO begins at the hyponychium from where the fungus slowly invades the nail bed in the direction toward the matrix. The infection apparently irritates the nail bed epithelium that produces a reactive hyperkeratosis, which harbours most of the fungal elements whereas the nail plate rather acts as a barrier. In contrast to psoriatic onycholysis that exhibits the classical salmon spot colour at its proximal margin, mycotic onycholysis has no reddish-brown margin (Fig 21 a&b). Nail psoriasis and onychomycosis may coexist (Natarajan et al, 2010).

	Onychomycosis	Psoriasis
Pits	Rare	Very frequent
Onycholysis	Frequent	Frequent
Discoloration	Yellow - brown	None - yellow
Loss of nail transparency	Frequent	Less frequent
Fungi	Very frequent, depends on type of OM	rare
Transverse ridges	Rare	Rare
Splinter haemorrhages	Almost never	Rare
Leuconychia	Depends on onychomycosis type: Superficial white OM Proximal white subungual OM	Rare
Paronychia	In onychomycoses due to moulds	In psoriatic arthritis and periungual psoriasis
Finger vs. toe involvement	Toe nails 7 to 10 times more often infected	Finger nails more often affected by psoriatic alterations
Other skin lesions	Tinea pedum and/or manuum	Psoriasis elsewhere
Heredity	Autosomal dominant susceptibility to get a dermatophyte nail infection	Frequent familiarity, particularly in early onset psoriasis and HLA-Cw6 positive subjects

Table 2. Differential diagnostic clinical signs in onychomycosis (OM) and nail psoriasis



a)



b)

Fig. 21. Psoriatic onycholysis demonstrates a livid-red proximal margin (A), which is not seen in mycotic onycholysis (B).

There are also many histopathological signs in common of onychomycosis and nail psoriasis (Table 3). This may render the differential diagnosis between these two frequent nail conditions very difficult if not impossible. Furthermore, it is possible that both onychomycosis and psoriasis are present in the same subject in different digits as well as in the same nail (Fig.22). It is therefore self-evident that a specimen sent for histopathological diagnosis of nail psoriasis is also stained with periodic acid-Schiff (PAS) or another fungal stain like silver-methene amine (Grocott).

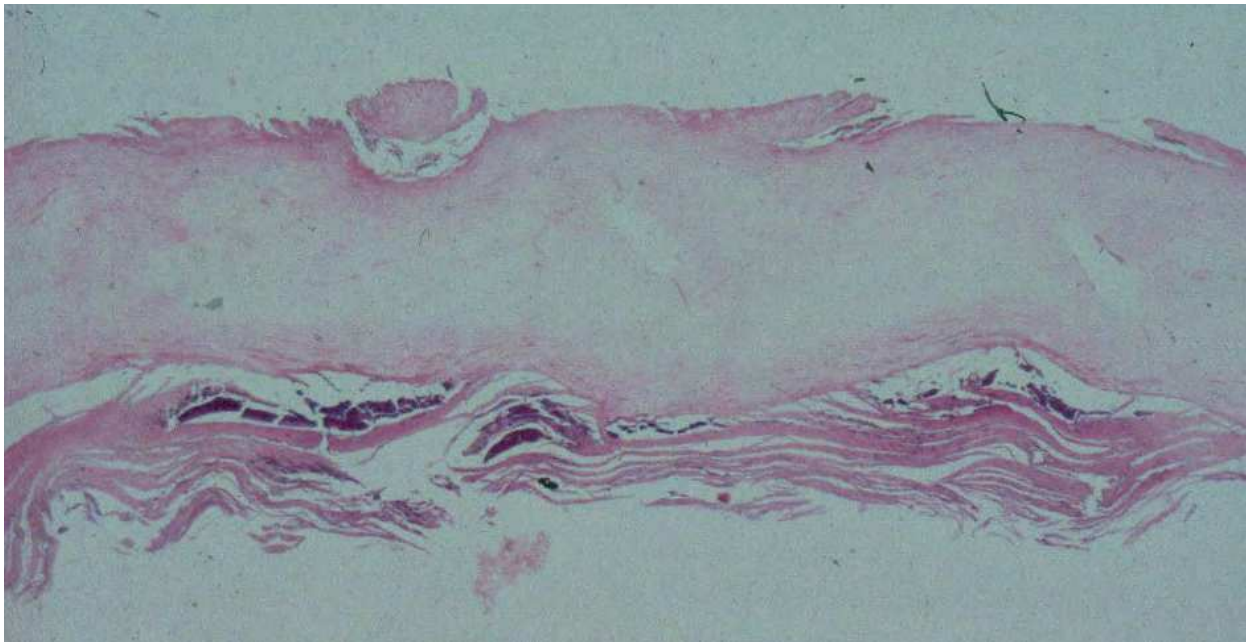


Fig. 22. This nail histopathology shows both psoriasis and onychomycosis: on the surface, 2 pits are seen; the nail itself is a bit wavy and displays fungal hyphae seen as fine eosinophilic lines in the deep layer of the nail in this haematoxylin & eosin stain section; at the undersurface of the nail there is loose keratin, which is mostly parakeratotic and contains several Munro's microabscesses.

	Onychomycosis	Psoriasis
Subungual hyperkeratosis	Marked hyperkeratosis with accumulation of neutrophils and serum globules	Marked hyperkeratosis with accumulation of neutrophils and serum globules
Nail bed and matrix granulosis	Patchy hypergranulosis	Patchy hypergranulosis
Nail bed hyperplasia	Papillomatous hyperplasia of nail bed	Papillomatous hyperplasia of nail bed
Spongiosis and exocytosis	Spongiosis and mononuclear exocytosis	Spongiosis and mononuclear exocytosis
Surface alterations	Usually not present	Cup-shaped depression of nail plate surface with parakeratosis: psoriatic pit
Demonstration of fungi	Hyphae and spores in subungual hyperkeratosis and undersurface of nail plate	May be present in double pathology

Table 3. Histopathological differential diagnosis of nail psoriasis and onychomycosis

Reiter’s disease is an infrequent reactive arthritis with changes of the ocular, genital and oral mucosae such as conjunctivitis, blepharitis, scleritis or iridocyclitis, balanitis, vulvitis or stomatitis circinata, which are virtually indistinguishable from lingua geographica and its very rare extralingual analogues, and painful inflammation of joints and the vertebral column. Many patients are HLA-B27 positive. Nail changes often start with pits and salmon patches remaining indistinguishable for a long time from nail psoriasis (Pajarre et al, 1977, Lovy et al, 1980) before the nails become destroyed (Fig. 23) (Table 4).

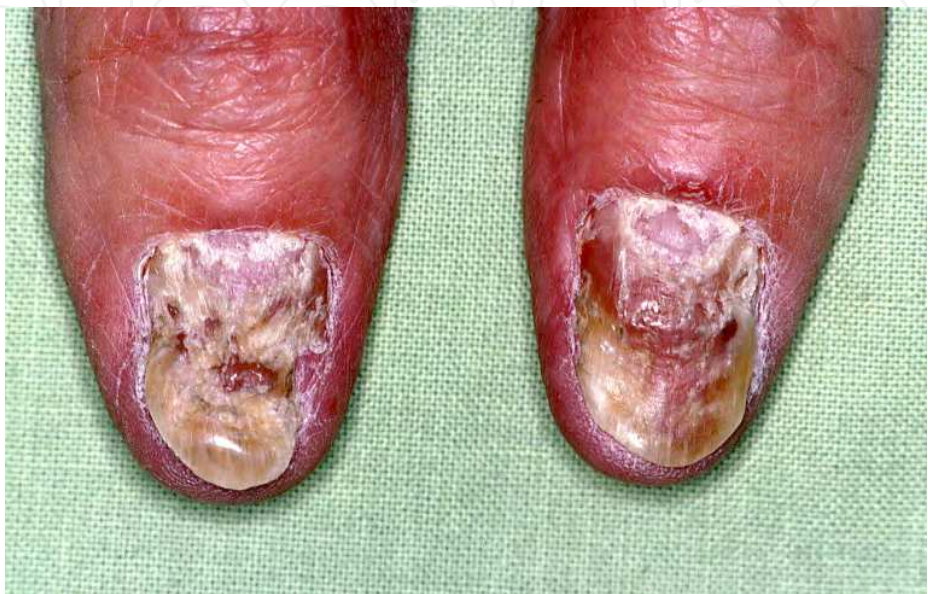

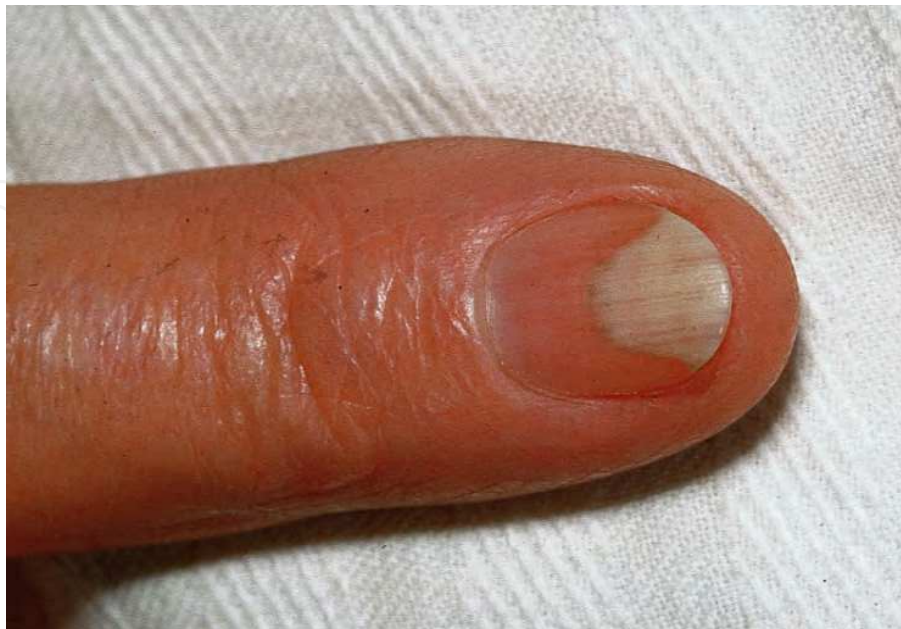Fig. 23. Reiter’s disease of the nails (Courtesy T Ruzicka, Munich)

	Psoriasis	Reiter’s disease
Pitting	Very frequent	Less frequent
Onycholysis	Frequent	Frequent
Subungual keratosis	Variable	Pronounced
Salmon patch	Reddish	More brown
Nail destruction	Rare	Marked
Skin lesions elsewhere	Frequent	Palmar and plantar lesions, joint changes, mucosal lesions

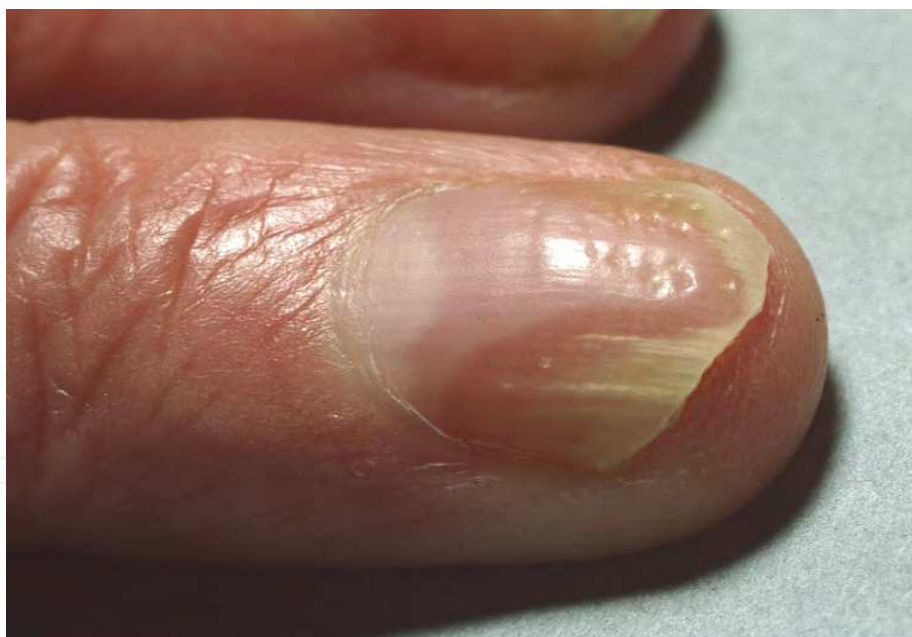Table 4. Differential diagnosis of nail psoriasis and nail changes in Reiter’s disease

Onycholysis is often due to overzealous manicure, but psoriasis of the nails renders them more susceptible to develop onycholysis due to minor trauma. Again, psoriatic onycholysis has usually a reddish proximal margin, which is lacking in onycholysis semilunaris (Fig. 24). Eczema involving the nail apparatus usually causes pit-like depressions leading to a rough nail surface called trachyonychia as well as to irregular transverse lines. The depressions are commonly less deep and less regular in size than in psoriasis. Although these depressions are more common in allergic contact dermatitis and nummular eczema they are also seen in atopic eczema (Nnoruka et al, 2004). Despite the trachyonychia, the nail may still retain its shine. In contrast, subungual contact dermatitis, e.g. as seen in acrylate allergy, causes

subungual hyperkeratosis and later onycholysis as well as loss of nail transparency and shine (Hemmer et al, 1996).



a)



b)

Fig. 24. Onycholysis semilunaris (A) is characterized by its half-moon shape and clear border whereas psoriatic onycholysis has the typical appearance of an oil spot at its proximal margin (B).

When many or even all nails are affected the condition is called twenty nail dystrophy; this may, however, be a manifestation of ungual lichen planus, alopecia areata, eczema or psoriasis and the exact diagnosis often requires a histopathological examination of a nail biopsy.

Irritant contact dermatitis was also estimated to mimic nail psoriasis (Takeuchi et al, 2010).

Alopecia areata is known to be associated with rough nails. The more extensive the alopecia areata is the more likely the patients also get nail changes. Most probably, isolated alopecia areata of the nails does exist (Tan et al, 2002, Nanda et al. 2002). Alopecia areata nails grow slower than psoriatic nails. They are often indistinguishable from eczema nails, and in fact, both have a microscopical spongiotic dermatitis in common. Serum is in the spongiotic vesicles and becomes included into the nail; when it is very superficial it may break out and leave a depression, but when the origin is in the intermediate matrix the dried serum will remain in the nail and be the reason for the loss of nail transparency, nail thickening and brittleness.

When almost all nails are affected the so-called twenty-nail dystrophy is diagnosed (Samman, 1979). Even though this term does not denote a specific condition it is still widely used, particularly for 20-nail dystrophy of children (Horn and Odom, 1980, Baran and Dawber, 1987).

9. Treatment of nail psoriasis

Psoriasis of the nails is an often neglected or overlooked disease as is evidenced by the most recent 100-page strong guidelines on psoriasis treatment (Nast et al, 2011), and it has a serious impact on the individual's daily life.

The therapy of nail psoriasis is difficult, particularly that of isolated nail psoriasis as one usually hesitates to treat it systemically. In general, systemic treatment regimens that are effective in cutaneous psoriasis also improve nail lesions. There is a general lack of well-documented studies and they are often not or difficult to compare (Jiaravuthisan et al, 2007) and few evidence-based treatments exist (Cassell and Kavanaugh, 2006). A standardized therapeutic approach does therefore not exist and preferred treatment regimens also differ between various countries. The treatment also depends on the nail structure involved, how severe the nail dystrophy is, whether there are extraungual lesions, the time needed for applying a specific therapy, and not the least also on its cost.

9.1 Topical therapy

Topical treatments are generally held not to be very effective. This has several simple reasons: Pits come from the depth of the nail pocket where the lesions are protected by the overlying proximal nail fold from being treated; lesions in the intermediate matrix are both hidden by the proximal nail fold and the nail plate; nail bed lesions are under the nail plate, which is a considerable obstacle to penetration of drugs. Ointments applied on finger nails may interfere with paper work. There are very few controlled studies on topical therapies.

Urea (carbamide) is known for its keratolytic property. A paste containing 40% urea (Onyster®) softens fungus infected nails to a degree that it can be atraumatically removed; this may be a starting point for topical treatment. A 10% urea nail varnish was shown to improve the biophysical properties of the nail (Krüger et al, 2006). A 15% stable urea nail lacquer (Onypso®) is advertised as "the only specific topical treatment for nail psoriasis" as it is claimed to reduce subungual hyperkeratosis. No controlled studies are available.

Anthralin (dithranol, cignoline) suppresses cell proliferation, inhibits neutrophils and monocytes, neutrophile migration and lymphocyte proliferation. It exerts a strong antiproliferative action on keratinocytes (Schröder et al, 1985). It is an old, extremely safe and very effective psoriasis remedy. Anthraline 0.4 to 2% in petrolatum was used in a study of 20 patients over a period of approximately 5 months (Yamamoto et al, 1998). There was no response in 8 and little to fair response on onycholysis, subungual hyperkeratosis and pitting in 12 individuals. Anthraline is not popular because it stains skin and clothes. Therefore the patients washed the anthraline ointment off after 30 minutes and applied 10% triethanol amine. However, nail staining cannot be completely avoided making the lesions even more obvious and embarrassing.

There are no studies on anthralin in combination with ultraviolet (Ingram regimen) or coal tar without or with UV (Goeckerman regimen) in nail psoriasis.

5-Fluorouracil (5-FU) is a cytostatic agent inhibiting nucleic acid synthesis and thus reducing cellular renewal. It was mainly used for the treatment of actinic keratoses and superficial basal carcinomas, but the application under occlusion or twice daily until an erosive reaction was achieved did not make it popular amongst the patients. A prospective study on 20 patients with very long-standing psoriatic pitting, hyperkeratosis or onycholysis was conducted with 1% 5-FU solution twice daily. This had to be massaged into the skin immediately adjacent to the nail for 6 months. Seventeen of the 20 subjects experienced marked improvement in pitting and subungual hyperkeratosis (Fredriksson, 1974). One patient with onycholysis lost all affected nails that finally regrew but with the same onycholysis as before.

In a double blind controlled study, 5-FU in a penetration enhancer consisting of urea and propylene glycol was compared to the penetration enhancer solution alone. The preparation was applied once daily over a period of 12 weeks. There was a statistically significant improvement of the total nail area severity (NAS) score comprised of the number of pits, degree of pitting, subungual hyperkeratosis, onycholysis and salmon spots, for both preparations with no superior results seen in the 5-FU group (de Jong et al, 1999). Six subjects in the 5-FU group experienced side effects such as pain, swelling, inflammation, discoloration, onycholysis, and nail perforations. 5-FU is not widely used anymore.

Topical steroids have been and continue to be the most commonly used therapeutic agents for local treatment of nail psoriasis. They exert an anti-inflammatory and immunosuppressive action, inhibit leukocyte migration into the skin, decrease vascular permeability, reduce the effect of pro-inflammatory cytokines, and have an antiproliferative action. All these effects taken together make them a good treatment of nail psoriasis provided they can reach the psoriatic lesion of the nail. However, no standard therapeutic regimes exist for topical steroid therapy of nail psoriasis (Jiaravuthisan et al, 2007) as there are very few controlled studies with their use in nail psoriasis. Generally, high-potency topical steroids are prescribed that are applied once or even twice daily to the nail folds and nail bed either as a cream, ointment or solution. Once an effect has been achieved the frequency of application is reduced until about twice weekly. A proactive treatment approach may be superior although there are no controlled studies in nail psoriasis. Side effects of long-term potent topical steroid use are hypopigmentation and skin atrophy with development of telangiectasiae. It may be wise to have the patient apply antiseptics once daily during this treatment as the risk of microbial growth, particularly of *Candida spp*, may

be considerable. Topical corticosteroid application has even been linked to tapering of the digits and to phalangeal bone resorption (Wolf et al, 1990).

A study on 10 nail psoriasis patients with 8% clobetasol nail lacquer resulted in reduced pitting, onycholysis and salmon spots after only 3 months of treatment. The treatment was found to be safe, effective and cosmetically acceptable (Sánchez Regaña et al, 2005).

Betamethasone dipropionate – salicylic acid ointment over 3 to 9 months reduced the nail bed hyperkeratosis by about one half (Tosti et al, 1996), which was virtually identical to the effect of **calcipotriol**. The authors' conclusion was that calcipotriol is a safe alternative to topical steroids in nail bed psoriasis.

A combination treatment with calcipotriol cream and clobetasol cream was shown to reduce subungual keratosis by 72% after 6 months and 81% after 12 months in finger nails whereas the improvement was 70 and 72.5% in toe nails, respectively (Rigopoulos et al, 2002). For the first 6 months, calcipotriol cream was applied on weekday evenings and clobetasol cream on weekend evenings, the next 6 months only clobetasol cream was used. Side effects of calcipotriol in the treatment of nail psoriasis are rare and mild, they mainly consist of irritation, burning, erythema and diffuse urticaria (Tosti et al, 1996, Rigopoulos et al, 2002).

Cyclosporine is an immunosuppressive calcineurin inhibitor ultimately decreasing T cell growth and migration (Baker et al, 1987). A 10% formulation in maize oil was used in three fingers of a patient (Tosti et al, 1990) with marked improvement after 2 months and almost complete clearing after 3 months. No adverse effects were observed. Cyclosporine is a hydrophobic, large molecule of 1.5 kD and difficult to incorporate into a topical preparation, but the newer calcineurin inhibitors tacrolimus and pimecrolimus are available as ointment or cream, respectively. Curiously, no controlled study with any of these two potent drugs has been conducted in nail psoriasis. Tacrolimus was found to be ineffective in plaque psoriasis, most probably due to insufficient penetration because of its large molecular weight of 802 Da, and this might have discouraged investigators to try it in nail psoriasis.

Tazarotene is a third-generation topical retinoid for the treatment of acne and psoriasis. It binds to the nuclear retin acid receptors RAR- β and RAR- γ exerting an effect on epidermal proliferation and differentiation. Its action in psoriasis is mainly normalization of abnormal keratinocyte proliferation and control of inflammation (Kang et al, 1996). In addition to some case reports on tazarotene use in periungual psoriasis, a double-blind controlled study was performed with the vehicle as the control. Both tazarotene 0.1% under occlusion as well as without occlusion yielded a statistically significant better reduction in onycholysis and pitting (Scher et al, 2001). Erythema, peeling of the paronychia, irritation of the finger skin and paronychia were the side effects seen in the tazarotene group whereas the vehicle was tolerated without adverse effects.

Indigo naturalis is a dark-blue powder from the leaves of indigo-bearing plants. It inhibits proliferation, promotes differentiation of epidermal keratinocytes, inhibits neutrophil proinflammatory responses and suppresses TNF- α induced vascular cell adhesion molecule 1 expression in endothelial cells thereby exerting an antipsoriatic effect (Lin et al, 2009). Six patients with psoriasis who had been treated for 4 years with indigo naturalis ointment or systemic Chinese herbs and whose skin lesions had responded well whereas the nails remained unchanged were treated twice daily with 1 to 2 drops of indigo naturalis oil extract onto the nail plate, fold and hyponychium. After three months, the mean reduction

in PASI was 51%, and two patients had even PASI reductions of 89 and 82%, respectively. No adverse side effects were noted (Lin, 2011).

9.2 Intralesional treatments

Intralesional injections of **corticosteroids** are widely used, either with an injection needle or by a high-pressure injector (Dermojet®, Port-O-Jet®). In most cases, crystal suspensions of triamcinolone acetonide are used with variable concentrations of 1 mg/mL (Zaias, 1990) to 10 mg/mL (Scher and Daniels, 2003, de Berker and Lawrence 1998). Injections ranged from a single one (Gerstein, 1962) to once every 3 to 4 weeks for 4 to 6 months (Abell and Samman, 1973, Zaias, 1990) or monthly for the first 6 months and then 4 injections over the next 6 months followed by once every two months for the next 6 to 12 months (Norton, 1982). It appears that the number of affected nails may be a limiting factor as many patients complain of discomfort and pain. In our experience, even though most patients prefer the needle-less high pressure air gun they admitted that injection with a 30-gauge needle is less painful (unpubl. observation). The sort of high pressure injector appears to be important as there are good results with some devices and disappointing ones with others. Side effects of high pressure devices are subungual haematomas, short-term paraesthesias, atrophy at the injection site, epidermoid inclusion cysts (de Berker, 2000), tattooing with minute rubber particles and blood splash back on the instrument and the physician.

Most intralesional injections are given into the proximal nail fold, best one each into each side of it with sparing the central area where the extensor tendon inserts in order to avoid steroid-induced tendolysis. These injection sites are good for lesions originating from the matrix, i.e. pits, ridges and severe nail plate dystrophy whereas nail bed-derived lesions such as subungual hyperkeratosis and salmon spots profit from sub-nailbed injections. These are, however, even more painful and usually require an anaesthesia to be applied.

The concentration of triamcinolon per mL does not appear to be critical as there are variations from 1mg/mL to 10 mg/mL in the literature. Higher concentrations allow smaller volumes to be injected, which then is less painful. It is still a matter of debate whether lidocaine or another local anaesthetic should be used to dilute the triamcinolone solution. In our opinion, it is both the needle prick and the pressure from the injection that are felt as uncomfortable to painful and no local anaesthetic can prevent this. Topical anaesthesia may be used, for instance with lidocaine-prilocain mixture (EMLA®), to alleviate the needle prick.

Intralesional methotrexate (MTX) has recently been used in a single patient (Saricaoglu et al, 2011). MTX is a folic acid analogue irreversibly binding to dehydrofolate reductase thus blocking deoxyribonucleic acid synthesis. In addition, it was shown to exhibit an anti-inflammatory effect by inhibiting the polyamine pathway in autoimmune diseases. Intralesional MTX has been shown to be effective and safe in a variety of conditions (Agostini et al, 2007). This was the rationale to use it in a psoriatic patient with pitting and subungual hyperkeratosis of only one nail. MTX 2.5 mg was injected into each side of the proximal nail fold once weekly for 6 weeks. Pain was tolerable. During the 4-month follow-up, the psoriatic nail alterations improved and no clinical or laboratory side effects were noted. No recurrence of the nail lesions was observed in the following two years.

Although **intralesional cyclosporine** has shown good effects in cutaneous psoriasis there are no reports on intralesional cyclosporine in nail psoriasis.

9.3 Physical treatment modalities

9.3.1 Phototherapy and photochemotherapy

Phototherapy has been used for psoriasis for more than 100 years. Ultraviolet (UV) is known to exert an immunosuppressive effect through an effect on local and circulating immune cells, particularly on dendritic cells. Narrow band UV B of 311 nm has been shown to be most effective. Photochemotherapy combines the use of UV, usually UV A, with the topical or systemic administration of a photosensitizing agent, most commonly a psoralen. In contrast to skin psoriasis, nail psoriasis barely responds. In a study with oral PUVA on 10 patients, the skin of the proximal nail fold improved, but pitting did not improve. Nail plate crumbling cleared in three out of 4 individuals whereas onycholysis and oil drops improved slightly by approximately 50% (Marx and Scher, 1980). In contrast, in a retrospective study on the effect of different systemic treatments, PUVA improved the NAPS score after 12, 24 and 48 weeks by 21%, 51% and 69%, Re-PUVA (combination of a retinoid with PUVA) by 27%, 65%, and 85%, ReNUVB (retinoid plus narrow-band UV B) by 21%, 48% and 64%, respectively, whereas narrow-band UV B alone had no beneficial effect (Regana et al, 2011). Topical PUVA resulted in clearing of 2 subjects with pitting and 2 with onycholysis improved substantially (Handfield-Jones et al, 1987). Even these results are surprising as the nail is a very efficient UV shield (Stern et al, 2011).

9.3.2 Laser treatment

Various studies have shown efficacy of laser treatments on cutaneous psoriasis. As angiogenesis was found to be one of the driving factors in psoriasis pathogenesis (Heidenreich et al, 2009) most studies were performed with the pulsed dye laser, which specifically targets blood vessels (Taibjee et al, 2005, Bovenschen et al, 2006). Two recent studies used the pulsed dye laser for nail psoriasis, one in comparison with photodynamic treatment (Fernández-Guarino et al, 2009), the other evaluated the effect of PDL on nail psoriasis (Oram et al, 2010). A third study not yet published (Treewittayapoom et al, in press) used two different pulse widths. All studies used a 595-nm pulsed dye laser with a spot size of 7 mm. The pulse duration in the Spanish study was 6 ms, in the Turkish one 1.5, and the Thai one compared the efficacy of 6 ms with 0.45 ms pulse width, fluences were 9, 8 – 10, and 9 and 6 J/cm², respectively. Both the PDT and the PDL group showed a decrease in the NAPS score with no difference between the two groups (Fernández-Guarino et al, 2009). The Turkish study showed an improvement mainly of the nail bed NAPS (Oram et al, 2010). The Thai study did not demonstrate a difference in treatment outcome between the long 6 ms pulse with 9 J/cm² group and the short 0.45 ms pulse duration with 6 J/cm² group; however, the pain was statistically significantly more intense in the longer pulse group (Treewittayapoom et al, in press).

9.3.3 Ionising radiation

Superficial radiotherapy delivers the radiation energy mainly to the skin surface. Three patients were treated with 400 to 600 cGy. Although no changes were noted during the 4-

month treatment interval the nails regrew normally in the following 8 to 14 months, and one patient had disease-free nails even 20 years after cessation of the irradiation (Finnerty, 1979). Another ten patients were treated in a randomized prospective double-blind study with twice fractionated doses of 150 cGy superficial radiotherapy each a week apart. One hand was treated and the other left for comparison. After 10 and 15 weeks posttreatment, the irradiated hand was significantly better concerning pitting, subungual hyperkeratosis, onycholysis, total nail destruction and nail thickness, but after 20 weeks no difference was seen anymore between the treated and untreated hands (Yu and King, 1992).

Grenz rays are very soft X-rays not penetrating the skin. In a randomized, double-blind study of 22 patients, 5 Gy of Grenz rays were applied in ten weekly courses to one hand only. Only 1 patient showed complete clearance, 7 mild improvement and 14 remained unchanged. Only non-hyperkeratotic lesions responded, which might have to be expected as Grenz rays do not penetrate the skin and hyperkeratosis. Six months after the irradiation, 2 patients were improved, two had worsened, and 18 remained unchanged. Slight nail fold pigmentation was the only adverse effect (Lindelöf, 1989).

Electron beam therapy was chosen by another group as the electrons are able to penetrate the nail bed (Kwang et al, 1995). Twelve patients were treated on one hand with a weekly dose of 750 cGy for a period of 8 weeks. Assessment at 3, 6 and 12 months showed improvement in 3 patients, slight improvement in 6 subjects, and a complete failure in 3 individuals after 3 months. At 6 and 12 months, only one patient continued to improve, 9 regressed to pretreatment conditions. A temporary deep brown-black discoloration of the treated nails was observed in some subjects.

All ionizing treatments have to be used with utmost care as long-term side effects may occur, often so late that the patient does not remember to have been treated with this modality.

9.3.4 Climatotherapy

Climatotherapy, in particular balneotherapy in sunny regions, is very popular in countries with little sunshine. It often has a positive effect on the skin and the emotional aspect of the patients. Although some patients claim that also their nails improve there are no systematic evaluations of the treatment modality on psoriatic nails.

9.4 Systemic therapies

Systemic treatments are indicated when there is wide-spread skin involvement. Isolated nail psoriasis is rarely seen as an indication for systemic therapy. All systemic treatments known to reduce skin lesions will also have a beneficial effect on nail lesions. Controlled studies are as a whole rather rare.

9.4.1 Immunosuppressive treatments

Corticosteroids have for a long time been given to psoriatics although their disadvantages such as general steroid adverse effects, tachyphylaxis and rebound phenomenon have been known for decades. There are no controlled trials of systemic steroids in nail psoriasis.

Cyclosporine is a powerful immunosuppressive agent used successfully in wide-spread psoriasis. Nail lesions usually also respond favorably. In a median dose of 2.5 mg/kg bodyweight daily, cyclosporine effectively reduces skin and nail psoriasis. In a comparative trial, cyclosporine versus etretinate were given to 210 patients two thirds of whom had nail involvement. At the end of 10 weeks, both groups showed slight improvement of their nails which continued in the group that continued with tapered cyclosporine (Mahrle et al, 1995). Another patient was treated for her severe nail psoriasis with cyclosporine 3mg/kg/d, and the dose was increased twice by one mg after 4 weeks each. After 16 weeks, both skin and nails had improved with the nail improvement having been considerably faster. "Proximal nail clearing" was observed to be 45 to 60%. The patient stopped cyclosporine on her own because of drug-induced hypertrichosis (Arnold et al, 1993). In a retrospective evaluation, cyclosporine was found to improve the NAPSI score after 12, 24 and 48 weeks by 40%, 72%, and 89%, respectively (Sánchez-Regaña et al, 2011).

Cyclosporine adverse effects, such as gastrointestinal symptoms, fatigue, leg cramps, diastolic blood pressure increase, and peripheral oedema were more common than in the etretinate group that suffered more skin symptoms like dry skin, cheilitis, and dry mouth (Mahrle et al, 1995).

Even though there are many reports on treatment of moderate to severe skin psoriasis with methotrexate, tacrolimus, mycophenolate mofetil, hydroxyurea, 6-thioguanine, sulfasalazine, fumaric esters, azathioprine, carbamazepine, calcitriol, and propylthiouracil, controlled studies concerning nail lesions in these patient cohorts are lacking. However, one may assume that they might also improve nail lesions when they are able to improve the skin.

Methotrexate is still often administered for wide-spread skin psoriasis although lung, liver and kidney fibrosis are well documented adverse effects of long-term treatment. There is only one report specifically relating to MTX low dose therapy for 20-nail psoriasis (Lee, 2009). In an evaluation of patients with nail psoriasis treated systemically, MTX produced NAPSI score improvements of 7%, 31%, and 35%, respectively, after 12, 24 and 48 weeks (Sánchez-Regaña et al, 2011). MTX as a classical cytostatic drug not only inhibits the inflammatory and hyperproliferative processes of psoriasis but may also slow down nail growth speed making it difficult to observe a positive effect in a reasonable time period.

9.4.2 Retinoids

Retinoids are vitamin A derivatives that are used for disorders of keratinisation. Their use in skin psoriasis is well documented with a number of studies. However, their potentials in nail psoriasis have not independently and systematically be studied (Tosti et al, 2009). In a comparative evaluation, acitretin was found to reduce the NAPSI score after 12, 24 and 48 weeks by 19%, 41%, and 52%, respectively during the treatment of moderate to severe skin psoriasis (Sánchez-Regaña et al, 2011). Acitretin is a first-line drug in pustular psoriasis, reduces subungual hyperkeratosis and improves symptoms in severe nail psoriasis (Duhard-Brohan, 1999, Piraccini et al, 2001, Tosti et al, 2009). Apart from the many potential side effects of retinoids, they may be onychodestructive in high doses as is high-dose vitamin A (Baran 1986).

9.4.3 Nimesulide

Nimesulide is a non-steroidal anti-inflammatory agent. After first positive experience (Piraccini e al 1994) it was given to 13 patients with pustular nail psoriasis of whom 4 responded well to twice daily 100 mg. All these 4 responders relapsed after withdrawal of the drug (Piraccini et al 2001). It was judged as not being superior to other drugs.

9.4.4 Biologics

An increasing number of “biologics” have been developed in the last decade. They counteract extremely potent immunological targets such as tumor necrosis factor- α (TNF- α), T cells, B cells, various cytokines, some immunoglobulins and key enzymes. A variety of them has been used in psoriasis, often with astonishing success (Lawry, 2007). Also nail psoriasis was the object of some studies. This chapter is, however, not suited to discuss all as this will be discussed in the psoriasis treatment chapters.

9.4.4.1 TNF- α inhibitors

TNF- α promotes cytokine secretion, such as interleukin (IL)-1, IL-6, IL-8, by macrophages and other inflammatory cells, activates T cells and induces adhesion molecule expression by vascular endothelial cells which in turn promote angiogenesis and keratinocyte proliferation, both key events in the pathogenesis of psoriasis (Smolen and Emery, 2011).

	Infliximab Remicade®	Adalimumab Humira®	Etanercept Enbrel®
Structure	Chimaeric antibody	Human monoclonal antibody	Human fusion protein
Application	Intravenous infusion	Subcutaneous	Subcutaneous
Dosage	5 mg/kg at weeks 0, 2, 6, then every 8 weeks	Loading dose: week 0 2x40 mg, week 1 40 mg, then 40 mg every 2 weeks	50 mg/week, or 2x50mg/week for 12 weeks
Indications	Psoriasis, psoriatic arthritis	Psoriasis, psoriatic arthritis	Psoriasis, psoriatic arthritis

Table 5. Application, dosage and indications of the commonly used TNF- α antagonists

Infliximab (Remicade®) is an inhibitor of TNF- α , which is a proinflammatory cytokine in psoriasis, psoriatic arthritis, ankylosing spondylitis, Reiter’s disease and several more chronic inflammatory diseases. Given as an intravenous infusion of 5 mg/kg at weeks 0, 2, 6, and then every 8 weeks, infliximab, a chimeric monoclonal antibody, is effective in psoriasis, psoriatic nail lesions (Reich et al, 2005), psoriatic arthritis and Reiter’s disease including its nail changes (Gaylis, 2003). Many reports have described the dramatic infliximab-induced improvement of both psoriatic skin and nail lesions (Antoni et al, 2005a, 2005b, Rich et al, 2008, Hussain et al, 2008, Reich, 2009). Another study showed a reduction of the mean NAPSI of 55.8 at baseline to 29.8 at week 14 and 3.3 at 38 (Rigopoulos et al, 2008). In the evaluation mentioned above, NAPSI improvement after 12,

24 and 48 weeks was 50%, 81%, and 92%, respectively (Sánchez-Regaña et al 2011). There appears to be general agreement that infliximab is the most potent antipsoriatic biologic (Noiles and Vender, 2009).

Adalimumab (Humira®) is a human antibody. In an open study, significant NAPSI reductions were obtained for finger and toe nails both in patients with cutaneous psoriasis as well as with psoriatic arthritis (Rigopoulos et al, 2010). In a large cohort of 442 patients with psoriatic arthritis, the mean NAPSI was reduced by 44% (Van den Bosch et al, 2010). Nail psoriasis response may be rapid (Irla and Yawalkar, 2009) although some authors found skin lesions to respond less than articular inflammation (Otten et al, 2011). In a group of ankylosing spondylitis and psoriatic arthritis patients, the NAPSI score was demonstrated to be reduced by 6 points (Rudwaleit et al, 2010). Adalimumab-induced improvement in nail psoriasis correlated with a good response in palmar plantar psoriasis (Langley et al, 2011). In the Spanish study, NAPSI improvement after 12, 24 and 48 weeks was 37%, 73%, 84%, respectively. Adalimumab was also beneficial for nail psoriasis after etanercept treatment (Puig et al, 2010).

Etanercept, a fully human TNF- α receptor fusion protein, binds TNF- α with greater affinity than natural receptors. The bound TNF- α is biologically inactive and many of the proinflammatory pathways responsible for initiation, maintenance, and recurrence of skin lesions in psoriasis are inhibited (Weinberg, 2003). The starting dose is twice weekly 50 mg subcutaneously, which may be reduced to once weekly 50 mg or twice weekly 25 mg. In a comparison of systemic nail psoriasis treatments, NAPSI improvement after 12, 24 and 48 weeks was 24%, 68%, and 87%, respectively (Sánchez-Regaña et al, 2011). The commonest adverse effect is an irritation reaction at the injection site. Infections and reactivations may occur as in infliximab treatment though probably less commonly. It should not be combined with systemic corticosteroids (Sanchez et al, 2006, Scheinfeld, 2004). There are some otherwise rare skin diseases that have been observed during etanercept treatment, such as lupus erythematosus, vasculitis, eosinophilic cellulitis like inflammation and interstitial granulomatous dermatitis (Scheinfeld, 2004, Winfield et al, 2006, Deng et al, 2006).

Golimumab (Simponi®) is a new human monoclonal antibody against TNF- α binding with high affinity and specificity to soluble and transmembrane TNF- α . It was studied once in psoriasis and nail psoriasis and showed an improvement in the NAPSI score of 25% and 43% after 14 weeks and 33% and 54% after 24 weeks in a dose of 50mg or 100 mg subcutaneously, respectively, at weeks 0, 4, 8, 12, 16, and 20 (Kavanaugh et al, 2009).

Certulizumab (Cimzia®) has not been used in nail psoriasis (Gartlehner et al, 2009).

All TNF- α inhibitors were reported to have induced psoriasis or psoriasiform skin and nail lesions (Sfikakis et al, 2005, Wollina et al, 2010). The spectrum of conditions induced by TNF- α is very wide and it apparently does not depend on the specific disease treated nor on the anti-TNF- α agent used (Pine et al, 2010, Conrad et al, 2011; Lee et al 2011). In more than half of the cases, the TNF- α induced skin lesions were successfully suppressed despite continuation of the drug. It is speculated that as TNF- α blockade is one of the strongest inducers of interferon- α production an unabated IFN- α production by plasmacytoid dendritic cells might result in these paradoxical psoriasis flares under anti-TNF- α treatment (Conrad et al, 2011).

Serious adverse events of all TNF- α inhibitors include the development of viral, bacterial, mycobacterial, and fungal infections (Lowther et al, 2007), reactivation of tuberculosis, hepatitis B and C, allergic infusion reactions, malignancies, autoantibody formation with lupus erythematosus, pancytopenia and aplastic anaemia, neurological disorders and worsening of congestive heart failure (Smolen and Emery, 2011). Experience in pregnancy is lacking. Further, infliximab comes with an information what to look for before starting a treatment. Paradoxical sarcoidosis while on anti-TNF- α treatment was also reported (Pine et al, 2010).

9.4.4.2 T cell inhibitors

Alefacept (Amevive®) is a human recombinant fusion protein composed of LFA-3 with the Fc portion of human IgG. In psoriasis, the inflammatory response is amplified when LFA-3 molecule-containing antigen presenting cells bind to the CD2+ receptor of T cells, the result being T cell activation and the release of proinflammatory cytokines. Alefacept binds to the CD2+ receptor of T cells via its LFA-3, thus blocking this interaction with antigen-presenting cells. Furthermore, alefacept triggers apoptosis of memory T cells. Through these two mechanisms, alefacept decreases the number of pathogenic T cells in psoriasis (Weinberg, 2003, Lawry 2007).

Alefacept is usually given in a dose of 15 mg per week for a period of 12 weeks; intravenous administration is also possible. At baseline, the CD4+ T cells should be monitored and then every 2 weeks. A CD4+ count below 250/ μ l should prompt to withhold the treatment until it has recovered. As alefacept has proven to be very safe the 2-weekly CD4 cell count may be delayed. Side effects include pruritus, headache, fatigue, nausea, viral upper respiratory infections, and arthralgias. Malignancy and serious infections do not appear to occur more frequently with alefacept use (Scheinfeld, 2005).

There are few studies and reports on alefacept use in nail psoriasis (Körver et al, 2006, Parrish et al, 2006). In moderate nail psoriasis, 2 patients improved, 2 remained unchanged and one worsened (Körver et al, 2006).

Efalizumab (Raptiva®) is a humanized monoclonal antibody against the CD11 portion of the LFA-1 molecule on lymphocytes. LFA-1 usually binds to intercellular adhesion molecule and promotes lymphocyte migration. The binding of efalizumab to CD11a cells is reversible and does not deplete T cells, but it prevents them from migrating into the skin (Weinberg, 2003). It has shown efficacy in the treatment of cutaneous and nail psoriasis but the European Medicines Agency (EMA) recommended its suspension of the marketing authorization after the occurrence of cases of progressive multifocal leukoencephalopathy (19 February 2009 Doc. Ref. EMEA/CHMP/20857/2009).

Cytokine inhibitors

Ustekinumab (Stelara®) is a new human IgG1k monoclonal antibody to the p40 epitope common to both IL-12 and IL-23. It blocks the differentiation and expansion of T helper cells 1 and 17 (Leonardi et al, 2008). It is indicated in moderate-to-severe psoriasis resistant to other therapies or with contraindications or intolerance to other systemic treatments. Ustekinumab is given in a dose of 45 mg for individuals under 100 kg body weight. In a patient who had earlier etanercept and failed to respond later ustekinumab was given and a

marked improvement of his nail signs was noted after 4 weeks. A complete cure was achieved 4 weeks later after the second injection (Rallis et al, 2010).

Tocilizumab (Actemra®) is an IL-6 receptor inhibitor. No reports on nail psoriasis treatment have been published hitherto.

T cell inhibitors

Abatacept (Orencia®) is a soluble chimeric protein consisting of the extracellular domain of human CD152 linked to the modified Fc portion of human IgG1. By binding to B7-1 (CD80) and B7-2 (CD86) molecules on antigen presenting cells, CTLA4Ig blocks the CD28-mediated costimulatory signal for T cell activation. Success with abatacept has been noted in psoriasis. Abatacept was administered to two patients with refractory psoriasis and psoriatic arthritis after the patients had failed all conventional treatment methods. Both patients experienced very brief improvement in disease (Altmeyer et al, 2011).

Rituximab, a B cell depleting chimeric antibody has no place in the treatment of nail psoriasis.

9.5 Combined treatments

In clinical routine, different treatments are often combined as one is either insufficient or too slow. The combination should always consist of drugs with different mechanisms of action. In contrast to skin psoriasis, there are almost no studies on the effect of combination therapy on nail psoriasis (Jiaravuthisan et al 2007). A single-blinded study on 54 patients with nail psoriasis examined the effects of cyclosporine monotherapy versus cyclosporine systemically plus calcipotriol cream topically (Feliciani et al 2004). The cyclosporine dose was 3.5 to 4.5 mg/d, calcipotriol was applied twice daily. After 3 months, the combined treatment showed significant improvement of pitting, subungual hyperkeratosis and onycholysis in 79%, whereas the cyclosporine monotherapy group showed 48% marked improvement. Six months after treatment, the cyclosporine monotherapy group showed a relapse rate of 52.9% (9/17), whereas only 37% (10/27) of patients in the combined therapy group had any signs of recurrence.

10. Conclusion

Nail psoriasis is frequent in psoriatic subjects with about 50% of psoriasis patients presenting with nail changes at any time and a life-time prevalence of up to 90%. Nail psoriasis has a strong genetic background and a frequent association with psoriatic arthritis. The most frequent signs of nail matrix involvement are pitting, leukonychia, crumbling and red spots in the lunula, whereas salmon or oil spots, subungual hyperkeratosis, onycholysis and splinter haemorrhages represent changes of nail bed involvement. Understanding the mechanism of psoriatic nail sign development requires some basic knowledge of the nail organ, its specific reaction patterns and of nail histopathology. Nail psoriasis has a serious impact on the quality of life interfering particularly with manual work but also being cosmetically embarrassing. Treatment of nail psoriasis is difficult as the matrix pathology is hidden by the proximal nail fold and the nail bed changes are protected against treatment by the overlying nail plate and nail bed hyperkeratosis. Progress has been made with the new biologic drugs, which are however, usually only administered for skin plus nail involvement.

11. References

- [1] Agostini A, De Lapparent T, Collette E, Capelle M, Cravello L, Blanc B. In situ methotrexate injection for treatment of recurrent endometriotic cysts. *Gynecol Reprod Biol* 2007;130:129-131
- [2] Aktan Ş, İlknur T, Akin Ç, Özkan Ş. Interobserver reliability of the Nail Psoriasis Severity Index. *Clin Exp Dermatol* 2006;32:141-144
- [3] Armesto S, Esteve A, Coto-Segura P, Drake M, Galache C, Martínez-Borra J, Santos-Juanes J. Nail psoriasis in individuals with psoriasis vulgaris: A study of 661 patients. *Actas Dermosifiliogr* 2011;102:365-372
- [4] Augustin M, Reich K, Blome C, Schäfer I, Laass A, Radtke MA. Nail psoriasis in Germany: epidemiology and burden of disease. *Br J Dermatol* 2010;163:580-585
- [5] Baker BS, Griffiths CE, Lambert S, Powles AV, Leonard JN, Valdimarsson H, Fry L. The effects of cyclosporine A on lymphocyte and dendritic cell sub-populations in psoriasis. *Br J Dermatol* 1987;116:503-510
- [6] Baran R. Etretinate and the nails (study of 130 cases): possible mechanisms of some side-effects. *Clin Exp Dermatol* 1986;11:148-152
- [7] Baran R, Dawber R. Twenty-nail dystrophy of childhood: a misnamed syndrome. *Cutis* 1987; 39:481-2.
- [8] Baran R, Haneke E. *The Nail in Differential Diagnosis*. Informa Healthcare, Abingdon, Oxon 2007
- [9] Bovenschen HJ, Erceg A, Vlijmen-Willems I, van de Kerkhof PC, Seyger MM. Pulsed dye laser versus treatment with calcipotriol/betamethasone dipropionate for localized refractory plaque psoriasis: effects on T-cell infiltration, epidermal proliferation and keratinization. *J Dermatol Treat* 2007; 18:32-39
- [10] Cargill M, Schrodi SJ, Chang M, Garcia VE, Brandon R, Callis KP, Matsunami N, Ardlie KG, Civello D, Catanese JJ, Leong DU, Panko JM, McAllister LB, Hansen CB, Papenfuss J, Prescott SM, White TJ, Leppert MF, Krueger GG, Begovich AB. A large-scale genetic association study confirms IL12B and leads to the identification of IL23R as psoriasis-risk genes. *Am J Hum Genet* 2007; 80:273-290
- [11] Cassell S, Kavanaugh A. Therapies for psoriatic nail disease. A systematic review. *J Rheumatol* 2006;33: 1452-1456
- [12] Cassetty CT, Alexis AF, Shupack JL, Strober BE. Alefacept in the treatment of psoriatic nail disease: a small case series. *J Am Acad Dermatol* 2005; 52: 1101-1102
- [13] Chan ES, Cronstein BN. Methotrexate - how does it really work? *Nat Rev Rheumatol* 2010;6:175-178
- [14] Chiam LYT, de Jager MEA, Giam YC, de Jong EMGJ, van de Kerkhof PCM, Seyger MMB. Juvenile psoriasis in European and Asian children: similarities and differences. *Br J Dermatol* 2011; 164, 1101-1103
- [15] Coelho JD, Diamantino F, Lestre S, Ferreira AM. Treatment of severe nail psoriasis with etanercept. *Indian J Dermatol Venereol Leprol* 2011;77:72-74
- [16] Conrad C, Lapointe AK, Gilliet M. Paradoxical psoriasis induced by anti-TNF treatment - A report of 8 cases and evidence for a new pathogenic mechanism. 93rd Ann Meet Swiss Soc Dermatol Venereol, Geneva, 2011, FC 11, *Dermatol Helv* 2011;6:30
- [17] Davidson SI, Wu X, Liu Y, Wei M, Danoy PA, Thomas G, Cai Q, Sun L, Duncan E, Wang N, Yu Q, Xu A, Fu Y, Brown MA, Xu H. Association of ERAP1, but not

- IL23R, with ankylosing spondylitis in a Han Chinese population. *Arthritis Rheum* 2009; 60:3263–3268
- [18] De Berker D. Management of psoriatic nail disease. *Sem Cut Med Surg* 2009;28:39-43
- [19] de Berker DAR, Lawrence CM. A simplified protocol of steroid injection for psoriatic nail dystrophy. *Br J Dermatol* 1998;138:90-95
- [20] De Jong EM, Seegers BA, Gulinck MK, Boezeman JB, van de Kerkhof PC.. Psoriasis of the nails associated with disability in a large number of patients: results of a recent interview with 1,728 patients. *Dermatology* 1996;193:300-303
- [21] Deng A, Harvey V, Sina B, Strobel D, Badros A, Junkins-Hopkins JM, Samuels A, Oghilikhan M, Gaspari A. Interstitial granulomatous dermatitis associated with the use of tumor necrosis factor alpha inhibitors. *Arch Dermatol* 2006;142: 198–202
- [22] Duhard-Brohan E. Psoriasis unguéal. *Ann Dermatol Vénéréol* 1999;126:445-449
- [23] Elder JT, Bruce AT, Gudjonsson JE, Jonstohn A, Stuart PE, Tejasvi T, Voorhees JJ, Molecular Dissection of Psoriasis: Integrating Genetics and biology. Consistent spelling: Molecular dissection of psoriasis: Integrating genetics and biology. *J Invest Dermatol* 2010;130:1213-1226
- [24] European Medicines Agency. European Medicines Agency recommends suspension of the marketing authorisation of Raptiva (efalizumab).
<http://de.wikipedia.org/wiki/Efalizumab> assessed 10 July 2011
- [25] Feldman SR, Krueger GG. Psoriasis assessment tools in clinical trials. *Ann Rheum Dis* 2005;64:ii65-68
- [26] Feliciani C, Zampetti A, Forleo P, Cerritelli L, Amerio P, Proietto G, Tulli A, Amerio P. Nail psoriasis: combined therapy with systemic cyclosporine and topical calcipotriol. *J Cutan Med Surg* 2004;8:122-5.
- [27] Fernández-Guarino M, Harto A, Sánchez-Ronco M, García-Morales I, Jaén P. Pulsed dye laser vs photodynamic therapy in the treatment of refractory nail psoriasis: a comparative pilot study. *J Eur Acad Dermatol Venereol* 2009;23:891-895
- [28] Finlay AY, Khan GK. Dermatology Life Quality Index (DLQI) – a simple practical measure for routine clinical use. *Clin Exp Dermatol* 1994; 19: 210–216
- [29] Finnerty EF. Successful treatment of psoriasis of the nails. *Cutis* 1979;23:43-44
- [30] Frenz C, Fritsch H, Hoch J: Plastination histologic investigations on the inserting pars terminalis aponeurosis dorsalis of three-sectioned fingers (in German). *Ann Anat* 2000;182: 69–73
- [31] Gartlehner G, Thieda P, Morgan LC, Thaler K, Hansen RA, Jonas B. Drug Class Review; Targeted Immune Modulators. Update 2 final report.
<http://www.ohsu.edu/drugeffectiveness/reports/final.cfm>, assessed 8 July 2011
- [32] Gaylis N. Infliximab in the treatment of an HIV positive patient with Reiter's syndrome. *J Rheumatol* 2003;30:407-411
- [33] Gregoriou S, Kalogeromitros D, Kosionis N, Gkouvi A, Rigopoulos D. Treatment options for nail psoriasis. *Exp Rev Dermatol* 2008; 3: 339–344
- [34] Gudjonsson JE Karason A, Runarsdottir EH, Antonsdottir AA, Hauksson VB, Jónsson HH, Gulcher J, Stefansson K, Valdimarsson H. Distinct clinical differences between HLA-Cw*0602 positive and negative psoriasis patients – an analysis of 1019 HLA-C and HLA-B typed patients. *J Invest Dermatol* 2006;126: 740–745
- [35] Gümüşel M, Ozdemir M, Mevlitoğlu I, Bodur S. Evaluation of the efficacy of methotrexate and cyclosporine therapies on psoriatic nails: a one-blind,

- randomized study. *J Eur Acad Dermatol Venereol*. 2011;25:1080-1084 [Epub ahead of print]
- [36] Gupta AK, Cooper EA. Psoriatic nail disease: quality of life and treatment. *J Cutan Med Surg* 2009;13 Suppl 2:S102-106
- [37] Handfield-Jones SE, Boyle J, Harman RRM. Local PUVA treatment for nail psoriasis. *Br J Dermatol* 1987;116:280-281
- [38] Haneke E. Surgical anatomy of the nail apparatus. *Dermatol Clin* 2006;24:291-296
- [39] Hanno R, Mathes BM, Krull EA. Longitudinal nail biopsy in evaluation of acquired nail dystrophies. *J Am Acad Dermatol* 1986;14:803-809
- [40] Heidenreich R, Röcken M, Ghoreschi K. Angiogenesis drives psoriasis pathogenesis. *Int J Exp Path* 2009;232-248
- [41] Hemmer W, Focke M, Wantke F, Götz M, Jarisch R. Allergic contact dermatitis to artificial fingernails prepared from UV light-cured acrylates. *J Am Acad Dermatol* 1996; 35: 377-380
- [42] Higashi N. Melanocytes of nail matrix and nail pigmentation. *Arch Dermatol* 1968;97:570-574
- [43] Horn RT Jr, Odom RB. Twenty nail dystrophy of alopecia areata. *Arch Dermatol* 1981; 116:573-574
- [44] Hussain W, Coulson I, Owen C. Severe recalcitrant nail psoriasis responding dramatically to infliximab: report of two patients. *Clin Exp Dermatol* 2008;33:520-520
- [45] Kang S, Li SY, Voorhees JJ. Pharmacology and molecular action of retinoids and vitamin D in skin. *J Invest Dermatol Symposium Proc* 1996;1:15-21
- [46] Khan M, Schentag C, Gladman DD. Clinical and radiological changes during psoriatic arthritis disease progression. *J Rheumatol* 2003;30:1022-1026
- [47] Kim JY, Jung HJ, Lee WJ, Kim DW, Yoon GS, Kim DS, Park MJ, Lee SJ. Is the distance enough to eradicate in situ or early invasive subungual melanoma by wide local excision from the point of view of matrix-to-bone distance for safe inferior surgical margin in Koreans. *Dermatology* 2011 Aug 16. [Epub ahead of print]
- [48] Körver JE, van de Kerkhof PC, Pasch MC. Alefacept treatment of psoriatic nail disease: how severe should nail psoriasis be? *J Am Acad Dermatol* 2006; 54: 742-743
- [49] Körver J, Langewouters A, van de Kerkhof P, Pasch M. Therapeutic effects of a 12-week course of alefacept on nail psoriasis. *J Eur Acad Dermatol Venerol* 2006;20:1252-1255
- [50] Krüger N, Reuther T, Williams S, Kerscher M. Einfluss eines ureahaltigen Lackes auf die Nagelqualität: Evaluation mittels klinischer Scores und biophysikalischer Parameter. *Hautarzt* 2006;57:1089-1094
- [51] Kwang TY, Nee TS, Seng KTH. A therapeutic study of nail psoriasis using electron beams. *Acta Dermatol Venereol* 1995;75:90
- [52] Jiaravuthisan MM, Sasseville D, Vender RB, Murphy F, Muhn CY. Psoriasis of the nail: Anatomy, pathology, clinical presentation, and a review of the literature on therapy. *J Am Acad Dermatol* 2007;57:1-27
- [53] Johnson M, Comaish JS, Shuster S. Nail is produced by the normal nail bed: a controversy resolved. *Br J Dermatol* 1991;125:27-29
- [54] Lamerson C, Stevens G, Sax K. Treatment of nail psoriasis with efalizumab: a preliminary study. *Cutis* 2008; 82: 217-220

- [55] Langley R, Crowley J, Unnebrink K, Goldblum O. Improvement in nail psoriasis is associated with improved outcomes in hand and/or foot psoriasis in adalimumab-treated patients: subanalysis of REACH. *J Am Acad Dermatol* 2011;64 Supp 1:AB7
- [56] Lavaroni G, Kokelj F, Pauluzzi P, Trevisan G. The nails in psoriatic arthritis. *Acta Derm Venereol (Suppl) (Stockh)* 1994; 186:113
- [57] Lawry M. Biological therapy and nail psoriasis. *Dermatol Ther* 2007;20:60-67
- [58] Lee DY. Severe 20-nail psoriasis successfully treated by low dose methotrexate. *Dermatol Online J* 2009;15:8
- [59] Lee KJ, Kim WS, Lee JH, Yang JM, Lee ES, Mun GH, Jang KT, Lee DY. CD10, a marker for specialized mesenchymal cells (onychofibroblasts) in the nail unit. *J Dermatol Sci* 2006;42:65-67
- [60] Lee DY, Lee KJ, Kim WS, Yang JM. Presence of specialized mesenchymal cells (onychofibroblasts) in the nail unit: implications for ingrown nail surgery. *J Eur Acad Dermatol Venereol* 2007;21:575-576
- [61] Lee DY, Lee JH, Yang JM, Lee ES, Mun GH, Jang KT. Versican is localized to nail mesenchyme containing onychofibroblasts. *J Eur Acad Dermatol Venereol* 2009;23:1328-1329
- [62] Lee DY, Yang JM, Mun GH. Onychofibroblasts induce hard keratin in skin keratinocytes in vitro. *Br J Dermatol* 2009;161:960-962
- [63] Lee DY, Yang JM, Mun GH, Jang KT, Cho KH. Immunohistochemical study of specialized nail mesenchyme containing onychofibroblasts in transverse sections of the nail unit. *Am J Dermatopathol* 2011;33:266-270
- [64] Lee YH, Pelivani N, Beltraminelli H, Hegyi I, Yawalkar N, Borradori L. Antimicrobial pustulosis-like rash in a patient with Crohn's disease under anti-TNF-alpha blocker. *Dermatology* 2011 DOI10.1159/000329428
- [65] Leonardi CL, Kimball AB, Papp KA, Yeilding N, Guzzo C, Wang Y, Li S, Dooley LT, Gordon KB, PHOENIX 1 study investigators. Efficacy and safety of ustekinumab, a human interleukin-12/23 monoclonal antibody, in patients with psoriasis: 76-week results from a randomised, double-blind, placebo-controlled trial (PHOENIX 1). *Lancet*. 2008;371:1665-1674.
- [66] Lewin K. The normal finger nail. *Br J Dermatol* 1965;77:421-430
- [67] Lewis BL. Microscopic studies of fetal and mature nail and surrounding soft tissue. *Arch Dermatol Syph* 1954;70:732-734
- [68] Lin YK. Indigo naturalis oil extract drops in the treatment of moderate to severe nail psoriasis: a small case series. *Arch Dermatol* 2011;147:627-629
- [69] Lin YK, Leu YL, Yang SH, Chen HW, Wang CT, Pang JH. Antipsoriatic effects of indigo naturalis on the proliferation and differentiation of keratinocytes with indirubin as the active component. *J Dermatol Sci* 2009;54:168-174
- [70] Lindelöf B. Psoriasis of the nails treated with Grenz rays: a double-blind bilateral trial. *Acta Dermatol Venereol* 1989;69:80-82
- [71] Lovy M, Bluhm G, Morales A. The occurrence of pitting in Reiter's syndrome. *J Am Acad Dermatol* 1980; 2: 66-68
- [72] Lowther AL, Somani AK, Camouse M, Florentino FT, Somach SC. Invasive *Trichophyton rubrum* infection occurring with infliximab and long-term prednisone treatment. *J Cutan Med Surg* 2007;11:84-88

- [73] Maejima H, Taniguchi T, Watarai A, Katsuoka K. Evaluation of nail disease in psoriatic arthritis by using a modified nail psoriasis severity score index. *Int J Dermatol*. 2010;49:901-906
- [74] Mahrle G, Schulze HJ, Färber L, Weidinger G, Steigleder GK. Low dose short term cyclosporin versus etretinate in psoriasis: improvement of skin, nail and joint involvement. *J Am Acad Dermatol* 1995;32:78-88
- [75] Marx JL, Scher RK. Response of psoriatic nails to oral photochemotherapy. *Arch Dermatol* 1980;116:1023-1024
- [76] McGonagle D, Tan AL, Benjamin M. The nail as a musculoskeletal appendage – implications for an improved understanding of the link between psoriasis and arthritis *Dermatology* 2009;218:97-102
- [77] McGonagle D. Enthesitis: an autoinflammatory lesion linking nail and joint involvement in psoriatic disease. *J Eur Acad Dermatol Venereol* 2009;23 (Suppl 1):9-13
- [78] McGonagle D, Ash Z, Dickie L, McDermott M, Aydin S Z. The early phase of psoriatic arthritis. *Ann Rheum Dis*. 2011 Mar;70 Suppl 1:i71-6
- [79] McGonagle D, Palmou Fontana N, Tan AL, Benjamin M. Nailing down the genetic and immunological basis for psoriatic disease. *Dermatology*. 2010;221 Suppl 1:15-22
- [80] Morgan AM, Baran R, Haneke E. Anatomy of the nail unit in relation to the distal digit. In Krull EA, Zook EG, Baran R, Haneke E. *Nail Surgery. A Text and Atlas*. Lippincott Williams & Wilkins, Philadelphia 2001:1-28
- [81] Nanda A, Kaur S, Kaur I, Kumar B. Childhood psoriasis: an epidemiologic survey of 112 patients. *Pediatr Dermatol* 1990; 7:19-21
- [82] Nanda A, Al-Fouzan AS, Al-Hasawi F. Alopecia areata in children: a clinical profile. *Pediatr Dermatol* 2002; 19:482-485
- [83] Nast A, Boehncke W-H, Mrowietz U, Ockenfels H-M, Philipp S, Reich K, Rosenbach T, Sammain A, Schlaeger M, Sebastian M, Sterry W, Streit V, Augustin M, Erdmann R, Klaus J, Koza J, Müller S, Orzechowski H-D, Rosumeck S, Schmd-Ott G, Weberschock T, Rzany B. S3-Leitlinie zur Therapie der Psoriasis vulgaris. Update 2011. *J Dtsch Ges Dermatol* 2011;) Suppl 2:1-104
- [84] Natarajan V, Nath AK, Thappa DM, Singh R, Verma SK. Coexistence of onychomycosis in psoriatic nails: a descriptive study. *Indian J Dermatol Venereol Leprol* 2010;76:723.
- [85] Nishi G, Shibata Y, Tago K, Kubota M, Suzuki M. Nail regeneration in digits replanted after amputation through the distal phalanx. *J Hand Surg Am* 1996;21:229-233
- [86] Nnoruka EN. Current epidemiology of atopic dermatitis in south-eastern Nigeria. *Int J Dermatol* 2004; 43: 739-744
- [87] Noiles K, Vender R. Nail psoriasis and biologics. *J Cutan Med Surg* 2009;13:1-5
- [88] Norton LA. Disease of the nails. In: Conn HF, editor. *Current therapy*. Philadelphia: WB Saunders; 1982: 664-668.
- [89] Oram Y, Karincioğlu Y, Koyuncu E, Kaharaman F. Pulsed dye laser in the treatment of nail psoriasis. *Dermatol Surg* 2010; 36:377-381
- [90] Ortonne JP, Baran R, Corvest M, Schmitt C, Voisard JJ, Taieb C. Development and validation of nail psoriasis quality of life scale (NPQ10). *J Eur Acad Dermatol Venereol* 2010; 24: 22-27


- [91] Otten MH, Prince FH, Ten Cate R, van Rossum MA, Twilt M, Hoppenreijns EP, Koopman-Keemink Y, Oranje AP, de Waard-van der Spek FB, Gorter SL, Armbrust W, Dolman KM, Wulffraat NM, van Suijlekom-Smit LW. Tumour necrosis factor (TNF)-blocking agents in juvenile psoriatic arthritis: are they effective? *Ann Rheum Dis* 2011;70:337-340
- [92] Pajarre R, Kero M. Nail changes as the first manifestation of the HLA-B27 inheritance. A case report. *Dermatologica* 1977; 154: 350-354
- [93] Parrish, CA, Sobera JO, Elewski BE. Modification of the nail psoriasis severity index. *J Am Acad Dermatol* 2004;53:745-746
- [94] Parrish CA, Sobera JO, Robbins CM, Cantrell WC, Desmond RA, Elewski BE. Alefacept in the treatment of psoriatic nail disease: a proof of concept study. *J Drugs Dermatol* 2006;5:339-340
- [95] Perrin C. The 2 clinical subbands of the distal nail unit and the nail isthmus. Anatomical explanation and new physiological observations in relation to the nail growth. *Am J Dermatopathol* 2008;30:216-221
- [96] Perrin C, Michiels JF, Pisani A, Ortonne JP. Anatomic distribution of melanocytes in normal nail unit: an immunohistochemical investigation. *Am J Dermatopathol* 1997;19:462-467
- [97] Perrin C, Langbein L, Schweizer J. Expression of hair keratins in the adult nail unit: an immunohistochemical analysis of the onychogenesis in the proximal nail fold, matrix and nail bed. *Br J Dermatol*. 2004;151(2):362-371
- [98] Pink AE, Foni A, Smith CH, Barker JNWN. The development of sarcoidosis on antitumour necrosis factor therapy: a paradox. *Br J of Dermatol* 2010; 163:641-666
- [99] Piraccini BM, Fanti PA, Morelli R, Tosti A. Hallopeau's acrodermatitis continua of the nail apparatus: a clinical and pathological study of 20 patients. *Acta Derm Venereol* 1994;74:65-67
- [100] Piraccini BM, Tosti A, Jorizzo M, Misciali C. Pustular psoriasis of the nails: treatment and long-term follow-up of 46 patients. *Br J Dermatol* 2001;144:1000-1005
- [101] Puig L, Barco D, Vilarrasa E, Alomar A. Treatment of acrodermatitis continua of Hallopeau with TNF-blocking agents: case report and review. *Dermatology* 2010;220:154-158
- [102] Rallis E, Kintzoglou S, Verros C. Ustekinumab for rapid treatment of nail psoriasis. *Arch Dermatol* 2010;146:1315-1316
- [103] Reich K. Approach to managing patients with nail psoriasis. *J Eur Acad Dermatol Venereol* 2009;23 Suppl 1:15-21
- [104] Reich K, Nestle FO, Papp K, Ortonne JP, Evans R, Guzzo C, Li S, Dooley LT, Griffiths CE, EXPRES study investigators. Infliximab induction and maintenance therapy for moderate-to-severe psoriasis: a phase III, multicentre, double-blind trial. *Lancet* 2005;366:1367-1374
- [105] Rich P, Scher R. Nail psoriasis severity index: a useful tool for evaluation of nail psoriasis. *J Am Acad Dermatol* 2003;49:206-212
- [106] Rigopoulos D, Ioannides D, Prastitis N, Katsambas A. Nail psoriasis: a combined treatment using calcipotriol cream and clobetasol propionate cream. *Acta Derm Venereol* 2002;82:140
- [107] Rigopoulos D, Gregoriou S, Stratigos A, Larios G, Kortitis C, Papaioannou D, Antoniou C, Ioannides D. Evaluation of the efficacy and safety of infliximab on psoriatic

- nails: an unblinded, nonrandomized, open-label study. *Br J Dermatol* 2008; 159: 453–456
- [108] Rigopoulos D, Gregoriou S, Lazaridou E, Belyayeva E, Apalla Z, Makris M, Katsambas A, Ioannides D. Treatment of nail psoriasis with adalimumab: an open label unblinded study *J Eur Acad Dermatol Venereol* 2010;24:530-534
- [109] Rudwaleit M, Van den Bosch F, Kron M, Kary S, Kupper H. Effectiveness and safety of adalimumab in patients with ankylosing spondylitis or psoriatic arthritis and history of anti-tumor necrosis factor therapy. *Arthritis Res Ther* 2010;12(3):R117
- [110] Ruprecht M, French LE, Navarini AA, Swiss Dermatol Network Targeted Ther. Psoriasis patient population and biologic treatment outcome at one Swiss department of dermatology. 93rd Ann Meet Swiss Soc Dermatol Venereol, Geneva, 2011: P40. *Dermatol Helv* 2011;6:40
- [111] Safa G, Darrieux I: Dramatic response of nail psoriasis to infliximab. *Case Rep Med* 2011;107928
- [112] Samman PD. Trachyonychia (rough nails). *Br J Dermatol* 1979; 101: 701–705
- [113] Sanchez CJL, Mahiques SL, Oliver MV. Safety of etanercept in psoriasis: a critical review. *Drug Saf* 2006;29: 675–685
- [114] Sánchez-Regaña M, Martín Ezquerro G, Umbert Millet P, Llambí Mateos F. Treatment of nail psoriasis with 8% clobetasol lacquer: positive experience in 10 patients. *J Eur Acad Dermatol Venereol* 2005;19:573-577
- [115] Sánchez-Regaña M, Sola-Ortigosa J, Alsina-Gibert M, Vidal-Fernández M, Umbert-Millet P. Nail psoriasis: a retrospective study on the effectiveness of systemic treatments (classical and biological therapy). *J Eur Acad Dermatol Venereol* 2011;25:579-586
- [116] Sarıcaoglu H, Oz A, Turan H. Nail psoriasis successfully treated with intralesional methotrexate: case report. *Dermatology* 2011;222:5-7
- [117] Scheinfeld N. The medical uses and side effects of etanercept with a focus on cutaneous disease. *J Drugs Dermatol* 2004;3: 653–659
- [118] Scher RK. Psoriasis of the nail. *Dermatol Clin* 1985;3:387-394
- [119] Scher RK, Daniel CR III. Nails: therapy, diagnosis, surgery. Philadelphia: WB Saunders Company; 2003
- [120] Scher RK, Stiller M, Zhu YI. Tazarotene 0.1% gel in the treatment of fingernail psoriasis: a double-blind, randomized, vehicle-controlled study. *Cutis* 2001;68:355-358
- [121] Schröder JM, Kosfeld U, Christophers E. Multifunctional inhibition by anthralin in nonstimulated and chemotactic factor stimulated human neutrophils. *J Invest Dermatol* 1985;85:30-34
- [122] Sfrikakis PP, Iliopoulos A, Elezoglou A, Kittas C, Stratigos A. Psoriasis induced by anti-tumor necrosis factor therapy: a paradoxical adverse reaction. *Arthritis Rheum* 2005;52:2513-2518
- [123] Smolen JS, Emery P. Infliximab: 12 years of experience. *Arthritis Res Ther* 2011;13 Suppl 1:S2
- [124] Stern DK, Creasey AA, Quijije J, Lebwohl MG. UV-A and UV-B penetration of normal human cadaveric fingernail plate. *Arch Dermatol* 2011;147:439-441
- [125] Taibjee SM, Cheung ST, Laube S, Lanigan SW. Controlled study of excimer and pulsed dye lasers in the treatment of psoriasis. *Br J Dermatol* 2005; 153:960-966

- [126] Takahashi MD, Chouela EN, Dorantes GL, Roselino AM, Santamaria J, Allevato MA, Cestari T, de Allaud ME, Stengel FM, Licu D. Efalizumab in the treatment of scalp, palmoplantar and nail psoriasis: Results of a 24-week Latin American study. *Arch Drug Inf* 2010;3:1-8
- [127] Takeuchi S, Matsuzaki Y, Ikenaga S, Nishikawa Y, Kimura K, Nakano H, Sawamura D. Garlic-induced irritant contact dermatitis mimicking nail psoriasis. *J Dermatol* 2011;38:280-282
- [128] Tan AL, Benjamin M, Toumi H, Grainger AJ, Tanner SF, Emery P et al. (2007) The relationship between the extensor tendon enthesis and the nail in distal interphalangeal joint disease in psoriatic arthritis – a high-resolution MRI and histological study. *Rheumatology (Oxford)* 46:253
- [129] Tan E, Tay YK, Goh CL, Chin Giam Y. The pattern and profile of alopecia areata in Singapore – a study of 219 Asians. *Int J Dermatol* 2002; 41: 748-51.
- [130] Tham SN, Lim JJ, Tay SH, Chiew YF, Chua TN, Tan E, Tan T. Clinical observations on nail changes in psoriasis. *Ann Acad Med Singapore* 1988;17:482-485
- [131] Tosti A, Cameli N, Piraccini BM, Fanti PA, Ortonne JP. Characterization of nail matrix melanocytes with anti-PEP1, anti-PEP8, TMH-1, and HMB-45 antibodies. *J Am Acad Dermatol*. 1994;31:193-196
- [132] Tosti A, Ricotti C, Romanelli P, Cameli N, Piraccini BM. Evaluation of the efficacy of acitretin therapy for nail psoriasis. *Arch Dermatol* 2009;145:269-271
- [133] Treewittayapoom C, Singvahanont P, Prabudhanitsarn K, Haneke E. The effect of different pulse duration in the treatment of nail psoriasis with 595-nm pulsed dye laser: A randomized, double-blind, intra-patient left-to-right study. *J Am Acad Dermatol*, accepted
- [134] Van den Bosch F, Manger B, Goupille P, McHugh N, Rødevand E, Holck P, van Vollenhoven RF, Leirisalo-Repo M, Fitzgerald O, Kron M, Frank M, Kary S, Kupper H. Effectiveness of adalimumab in treating patients with active psoriatic arthritis and predictors of good clinical responses for arthritis, skin and nail lesions. *Ann Rheum Dis* 2010;69:394-399
- [135] Weinberg JM. An overview of infliximab, etanercept, efalizumab, and alefacept as biological therapy for psoriasis. *Clin Therapeutics* 2003;25: 2487-2505
- [136] Williamson L, Dalbeth N, Dockerty JL, Gee BC, Weatherall R, Wordsworth BP. Extended report: nail disease in psoriatic arthritis-clinically important, potentially treatable and often overlooked. *Rheumatology* 2004;43:790-794
- [137] Winfield H, Lain E, Horn T, Hoskyn J. Eosinophilic cellulitis like reaction to subcutaneous etanercept injection. *Arch Dermatol* 2006;142: 218-220
- [138] Wittkowski KM, Leonardi C, Gottlieb A, Menter A, Krueger GG, Tebbey PW, Belasco J, Soltani-Arabshahi R, Gray J, Horn L, Krueger JG; for the International Psoriasis Council. Clinical symptoms of skin, nails and joints manifest independently in patients with concomitant psoriasis and psoriatic arthritis. *PLoS ONE* 2011;6(6):e20279
- [139] Wolf R, Tur E, Brenner S. Corticosteroid-induced 'disappearing digit'. *J Am Acad Dermatol* 1990;23:755-756
- [140] Wollina U, Hansel G, Koch A, Schönlebe J, Köstler E, Haroske G. Tumor necrosis factor- α inhibitor-induced psoriasis or psoriasiform exanthemata. First 120 cases

- from the literature including a series of 6 new cases. *Am J Clin Dermatol* 2008;9:1-14
- [141] Yamamoto T, Katayama I, Nishioka K. Topical anthralin therapy for refractory nail psoriasis. *J Dermatol* 1998;25:231-233
- [142] Yu RCH, King CM. A double-blind study of superficial radiotherapy in psoriatic nail dystrophy. *Acta Derm Venereol (Stockh)* 1992;72:124-136
- [143] Zaias N. The embryology of the human nail. *Arch Dermatol* 1963;87:37-53.
- [144] Zaias N. Psoriasis of the nail: a clinical-pathologic study. *Arch Dermatol* 1969;99:567-579
- [145] Zaias N. *The Nail in Health and Disease*, 2nd ed. Norwalk: Appleton & Lange; 1990
- [146] Zaias N, Alvarez J. The formation of the primate nail plate. An autoradiographic study in the squirrel monkey. *J Invest Dermatol* 1968, 51:120-136
- [147] Zook EG, Van Beek AL, Russell RC, Beatty ME. Anatomy and physiology of the perionychium: a review of the literature and anatomic study. *J Hand Surg* 1980;5:528-536

IntechOpen



Psoriasis

Edited by Dr. Jennifer Soung

ISBN 978-953-307-878-6

Hard cover, 372 pages

Publisher InTech

Published online 15, February, 2012

Published in print edition February, 2012

We hope you enjoy and find the information provided in this book useful in your research or practice. We urge that you continue to keep abreast of the new developments in psoriasis and share your knowledge so that we may advance treatment and cures of psoriasis.

How to reference

In order to correctly reference this scholarly work, feel free to copy and paste the following:

Eckart Haneke (2012). Nail Psoriasis, Psoriasis, Dr. Jennifer Soung (Ed.), ISBN: 978-953-307-878-6, InTech, Available from: <http://www.intechopen.com/books/psoriasis/nail-psoriasis>

INTECH
open science | open minds

InTech Europe

University Campus STeP Ri
Slavka Krautzeka 83/A
51000 Rijeka, Croatia
Phone: +385 (51) 770 447
Fax: +385 (51) 686 166
www.intechopen.com

InTech China

Unit 405, Office Block, Hotel Equatorial Shanghai
No.65, Yan An Road (West), Shanghai, 200040, China
中国上海市延安西路65号上海国际贵都大饭店办公楼405单元
Phone: +86-21-62489820
Fax: +86-21-62489821

© 2012 The Author(s). Licensee IntechOpen. This is an open access article distributed under the terms of the [Creative Commons Attribution 3.0 License](https://creativecommons.org/licenses/by/3.0/), which permits unrestricted use, distribution, and reproduction in any medium, provided the original work is properly cited.

IntechOpen

IntechOpen