

We are IntechOpen, the world's leading publisher of Open Access books Built by scientists, for scientists

6,900

Open access books available

186,000

International authors and editors

200M

Downloads

Our authors are among the

154

Countries delivered to

TOP 1%

most cited scientists

12.2%

Contributors from top 500 universities



WEB OF SCIENCE™

Selection of our books indexed in the Book Citation Index
in Web of Science™ Core Collection (BKCI)

Interested in publishing with us?
Contact book.department@intechopen.com

Numbers displayed above are based on latest data collected.
For more information visit www.intechopen.com



Biliary Complications in Liver Transplantation

Ilka de Fatima Santana Ferreira Boin, Fernando Romani de Araujo,
Elaine Cristina de Ataíde, Anaisa Portes Ramos and Ciro Garcia Montes
*Unit of Liver Transplantation – State University of Campinas – Unicamp
Brazil*

1. Introduction

Orthotopic Liver Transplantation (OLT) is the only treatment capable to reverse end-stage chronic liver disease, and is also indicated for the treatment of hepatocellular carcinoma, acute liver failure and a series of metabolic disorders caused by liver dysfunction, even those that do not course with cirrhosis. The evolution of surgical techniques, the proper selection of potential recipients, perioperative and ICU care, and better organ preservation solutions and immunosuppressive medications currently available, greatly increase success rates and survival after liver transplantation. Despite these many advances liver transplantation continues to have a high number of postoperative complications, with significant morbidity and mortality. These include biliary complications, that because of their high incidence have been called the Achilles' heel of liver transplantation. In initial reports the complication rates in the biliary tree range from 34 to 50%, with mortality reaching up to 30% of transplanted patients. In more recent series these complications have been reduced to 10 from 30% and associated mortality to about 10% (Welling et al. 2008).

Biliary complications can occur both in the area of the anastomosis or be intrahepatic. The forms of biliary fistula or stenosis are different not only in clinical presentation and treatment, but also in the period in which they occur. The association with vascular complications, arterial thrombosis specifically, makes treatment even more complicated. The incidence following transplants with living donors is greater, given the wide anatomical variation and smaller size of bile ducts in this situation.

2. Types of biliary reconstruction

Biliary anastomosis is the final step in a liver transplant, being performed after the completion of vascular reconstruction and graft reperfusion. [Figure 1] The technique of end-to-end duct-to-duct anastomosis is the widely accepted standard, although some controversy exists on whether or not the bile duct T-tube drains should be used. [Table 1] This type of reconstruction has the advantage of maintaining the physiological mechanism of biliary excretion and be easily accessible by endoscopy, which is very useful in the case of anastomotic or intrahepatic biliary complications. There are reports of some groups that vary this form of reconstruction with side-to-side anastomosis, in order to enlarge the anastomosis, thus trying to prevent stenosis (O'Connor et al. 1995).

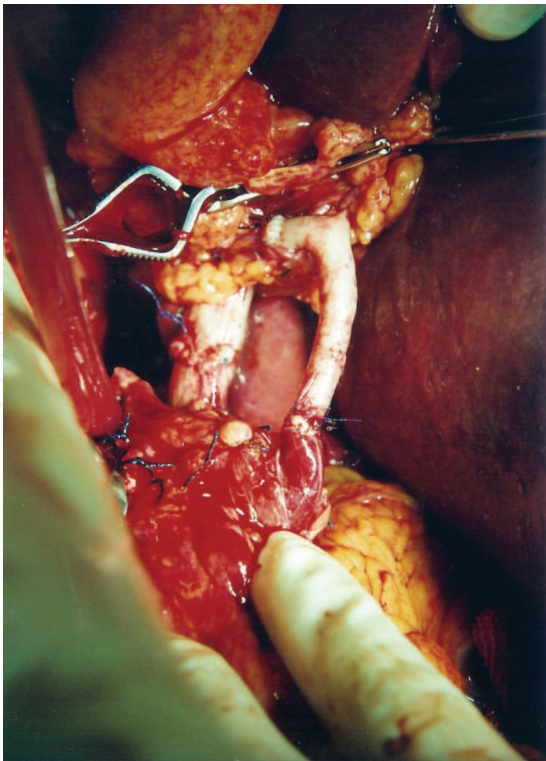


Fig. 1. Identification of patients’ biliary tract for duct-to-duct anastomosis after vascular anastomosis and graft reperfusion

The choice for Roux-en-Y hepaticojejunostomy is an exception in transplants with deceased donors. It is indicated when there is some anomaly in the recipient bile duct, such as obstruction, atresia, sclerosing cholangitis, or large size difference between the donor and recipient bile ducts. In the case of living donor transplantation or the use of spit liver, hepaticojejunostomy has been considered the standard, due to the small size, anatomical variation and the presence of multiple ducts to be drained.

| Types of Biliary Reconstruction |
|---------------------------------|
| With or without T-tube drains |
| Duct-to-Duct: |
| End-to-End |
| Side-to-Side |
| Roux-en-Y Hepaticojejunostomy |

Table 1. Types of biliary reconstruction

In right lobe living donor liver transplantation (LDLT) there are several reports of duct-to-duct anastomosis, and this type of reconstruction is already well accepted. In the case of left lobe LDLT there is still a tendency to perform Roux-en-Y hepaticojejunostomy in published reviews. However, there are reports of successful transplants carried out with multiple duct-to-duct anastomosis for drainage of various liver segments, which uses the right and left recipient hepatic branch ducts, or sometimes even the cystic duct to obtain the drainage path for reconstruction (Azoulay et al. 2001).

3. Bile duct drainage

In the first series of liver transplantation bile duct drainage with the use of T-tubes was performed routinely. The aim was to decompress the bile flow and reduce pressure on the anastomosis, allowing greater control over the excretory function of the liver and easy access for performing contrasted studies of the biliary tree during the postoperative period. [Figure 2] The presence of T-tube drains in the area of anastomosis prevents the formation of cicatricial stenosis, ensuring a minimum diameter molded into the drain.

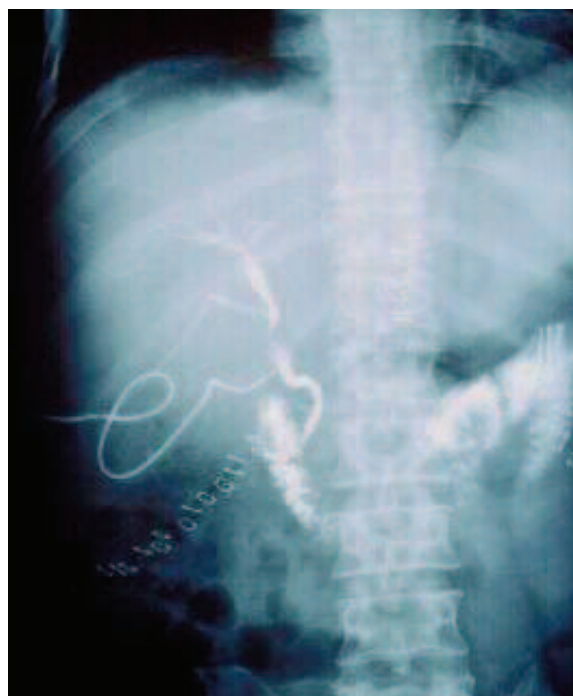

Fig. 2. T-tube drain cholangiography with short, anastomotic type stricture

The occurrence of various complications related to T-tube drain and its removal led to questioning of its real benefit. The occurrence of bile leaks after the drain removal occurs in up to 15% of cases. When added to other complications such as obstruction, displacement and cholangitis, complications directly related to the drain reach between 10 and 22% of patients (Gantxegi et al. 2011).

The use of immunosuppressive drugs and high-dose corticosteroids in liver transplantation delays fibrogenesis, preventing the formation of a fibrous path around the drain, which justifies such a high number of complications. Several attempts to reduce these numbers have been tried, such as using rubber tubes instead of silicone ones and late removal of the drain, between 4 to 6 months post transplant. A prospective randomized trial in the late '90s demonstrated objectively that duct-to-duct anastomosis without bile duct T-tube drains was possible, with lower complication rates and cost-effectiveness (Verran et al. 1997).

Currently, the use of bile duct drains after deceased donor liver transplantation (DDLT) is carried out selectively. In the case of partial liver transplants, either by LDLT or split DDLT, bile duct T-tube drain has the advantage of relieving the pressure in the biliary tree, preventing fistula formation in the liver cut surface. Because of this, drain use is still more frequent in this type of transplantation.

4. Types of biliary complications

Occurrence of fistulas and stenosis account for about 80% of all biliary complications, and the remaining 20% are due to less frequent causes, such as extrinsic compression, hemobilia, mucocoeles, and obstructions caused by biliomas, stones, biliary sludge or nematodes.

These complications are related to a number of factors such as technical errors, thrombosis or stenosis of the hepatic artery, recurrence of underlying disease and ischemic-type lesions. In case of partial liver grafts there is also the risk of inadvertent injury during duct dissection and section of hepatic parenchyma, leading to cicatricial strictures or fistulas, and the risk of bile leak in the cut surface (Noujaim et al. 2003).

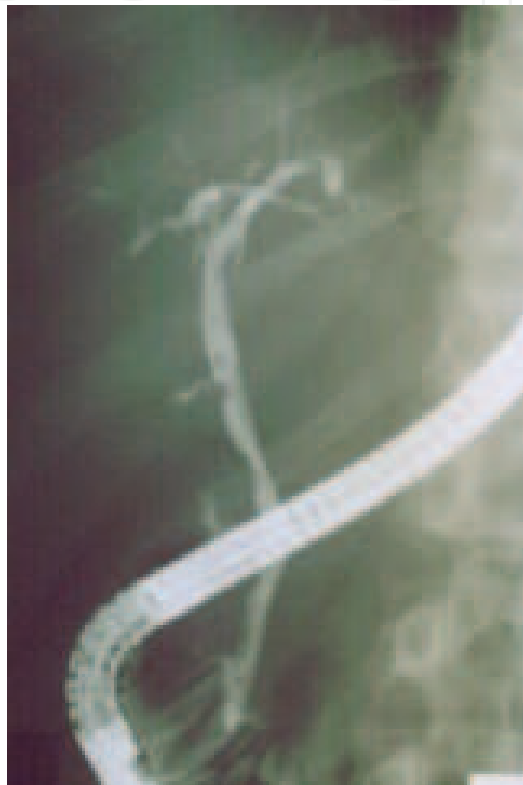

Fig. 3. Endoscopic Retrograde Cholangiography with short segmental stricture

The type of injury varies according to etiology. In case of technical errors in the anastomosis confection single and short extrahepatic stenosis is the rule. [Figure 3] Because of the peculiarities of biliary tree vasculature, in a radial manner, the excessive dissection of the duct in the recipient or in the graft may lead to ischemia in the anastomosis area, resulting in necrosis and fistula or late cicatricial retraction. [Figure 4]

Strictures of the ischemic type are characterized by multiple areas of stenosis within the liver, interspersed with areas of dilation. The main cause of this type of injury is the occurrence of stenosis and thrombosis of the hepatic artery. However several other factors may be involved, such as prolonged cold and hot ischemia periods, poor preservation of the graft, delayed arterialization of the liver, recurrence of underlying disease, and toxicity of drugs and immune-mediated injury. Among the causes immune-mediated chronic rejection, ABO incompatibility and cytomegalovirus infection must be remembered. It is also suggested that the presence of bile salts in contact with the epithelium during cold ischemia

period is toxic, leading to autolysis of the mucosal lining. So the practice of washing the biliary tract with saline before arterial clamping and cold perfusion of the graft during the donor's removal procedure can prevent this type of complication.



Fig. 4. Necrotic biliary tree

5. Clinical presentation

Most biliary complications occur early after liver transplant, with 60% occurring in the first six months postoperatively. The clinical presentation can be very varied, ranging from jaundice or bile leaks through abdominal drains to unspecific pictures of worsening liver tests and infections.

The presence of bile in abdominal drain in early postoperative is diagnosis of fistula, but is not always present. Formation of biliomas or choleperitonitis may occur even without significant clinical manifestations, a fact due to immunosuppression and high doses of corticosteroids used in the initial postoperative phase.

The occurrence of postoperative cholestasis is a common signal for a series of complications, not to specific abnormalities in the biliary tree. Common causes of cholestasis include acute cellular rejection, liver graft dysfunction, preservation injury, medication toxicity, recurrence of viral hepatitis, vascular thrombosis or stenosis of the hepatic artery and portal vein, ascending cholangitis, or simply be due to severe sepsis.

Changes in postoperative evolution of a transplanted patient such as detection of altered liver function tests or clinical deterioration with development of sepsis should be investigated with specific protocols to detect the most common complications. The performance of Doppler ultrasound examination is a good initial measure, because it allows the evaluation of arterial and portal blood flow, presence of bile ducts dilation and assessment of liver parenchyma for its surface and texture, and also is a good initial method to identify liver abscesses and biliomas or extrahepatic collections. The absence of dilatation of the bile ducts should not be a factor sufficient to preclude the existence of complications such as biliary strictures, as there are several related cases of significant stenosis that do not course with biliary dilation. This can be explained by the presence of greater peri-duct fibrosis in transplanted livers.

When suspicion of biliary complications cannot be ruled out by the initial screening or when persistent cholestasis occurs even after exclusion of acute and chronic rejection or viral hepatitis recurrence a more detailed evaluation of the biliary tract should be performed.

Magnetic Resonance Imaging (MRI) Cholangiography allows detailed images of the biliary tract anatomy, with identification of areas of narrowing, presence of gallstones and bile leakage points, and is a good method for diagnosis and treatment planning. Endoscopic Retrograde Cholangiography (ERCP) and Percutaneous Transhepatic Cholangiography (PTC) allow not only the diagnosis of biliary lesions but also their treatment, either with endoscopic sphincterotomy, placement of biliary drains and external naso-biliary catheters or direct manipulation of lesions, with stricture dilation and passage of various types of biliary prostheses.

The strong association of biliary injury with the occurrence of hepatic artery thrombosis or stenosis should be remembered. Research with angio-CT or MRI should be performed whenever there is suspicion after the initial screening with Doppler ultrasound.

6. Biliary fistulas

Bile leaks usually occur in the early period after liver transplantation. Its presentation can be very variable, from a bile leak from abdominal drains to biliomas formation without further clinical repercussions, until the occurrence of diffuse choleperitonitis and sepsis.

Bile leak incidence varies between 0.5 and 20% and is often related to technical error in the biliary anastomosis. Its origin can be in the anastomosis itself or in areas of injury to the bile duct during dissection. Devascularization of end bile ducts in the area of anastomosis due to excessive dissection can progress to necrosis of the duct and fistula formation. In cases of partial liver grafts, from LDLT or split DDLT, there may be damage to the ducts on the cut surface of the parenchyma, leading to fistula formation.

The initial goal of treatment is to control sepsis. Percutaneous ultrasound or CT-guided drainage of biliomas can be performed. In cases of massive leaks and choleperitonitis it could be necessary to perform laparotomy. The definitive treatment of fistulas depends on the type of transplant performed, as well as the form of biliary reconstruction and the placement or not of T-tube drain in the biliary tract.

In transplants performed with whole liver grafts from deceased donors, fistulas originate almost exclusively from the anastomosis. Other less frequent causes are due to common bile duct injuries during dissection or fistula originating from areas of laceration in liver parenchyma due to prior trauma. In transplants performed with partial liver grafts, due to LDLT or split DDLT, fistulas originating from intra-parenchymal ducts or from the cut surface area of liver section have major significance.

When reconstruction is performed with duct-to-duct anastomosis ECPR treatment is usually the first option. [Figure 5] The performance of sphincterotomy and biliary stenting often induces the closure of fistulas in most cases, with mean treatment duration ranging from 60 to 90 days according to some series (Londono et al. 2008). Another option is the passage of naso-biliary tubes, with the advantage of easy access to perform contrast-enhanced studies of the biliary tract. When a T-tube drain is left during the transplantation procedure simply opening the drain should be sufficient to resolve the fistula. Surgery, as a definitive treatment, is usually indicated only in case of failure of the initial endoscopic treatment, in this case the conversion of the anastomosis to hepaticojejunostomy to be resolute.

In fistula occurring after reconstruction with Roux-en-Y hepaticojejunostomy the treatment is more complicated. This type of anastomosis is virtually inaccessible by endoscopy, forcing

early surgery indication. The reconfiguration of the anastomosis is usually effective for the resolution of this picture. One controversial option is to perform a jejunostomy stoma, to allow endoscopic access to the anastomosis if necessary in the future. This stoma could be closed a few months after resolution of symptoms.

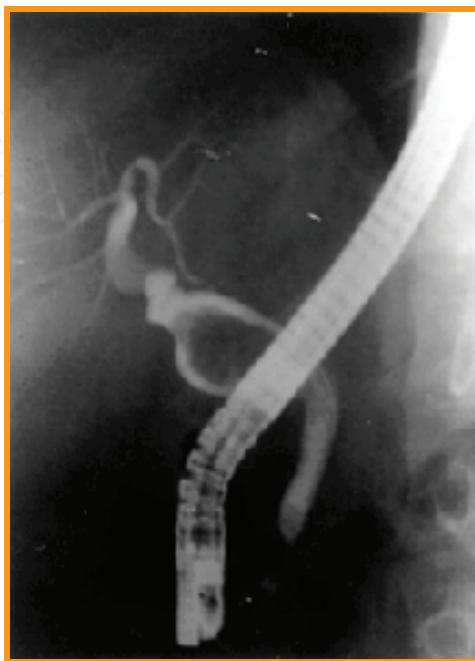


Fig. 5. Bile leak in duct-to-duct anastomosis

Fistulas originating after removal of biliary drains are also initially treated with endoscopic papillotomy. Primary surgical indication to suture the drain hole, allows faster resolution of the fistula, but with higher associated morbidity.

The occurrence of bile leaks leads to significant morbidity and mortality after orthotopic liver transplantation. Although not altering the function or long-term survival of the liver graft after its resolution, it is a risk factor for the occurrence of cicatricial stenosis.

7. Biliary strictures

The occurrence of biliary strictures after liver transplantation has declined over the years due to improved surgical materials, better organ preservation and postoperative care. Incidence of up to 40% initially reported fell from 5 to 15% in recent reviews. In LDLT it still occurs in about 30 to 35%, according to published series (Renz et al. 2004). While the vast majority of stenosis occur within the first year after transplantation, with peak incidence between 5 and 8 months, it is known that the incidence is progressively increased with longer follow-up periods. The early occurrence of stenosis is related to technical conditions, such as improper suture materials, tension at the anastomosis and duct size difference between recipient and donor. Late presenting strictures are usually related to ischemic or immunologic events or inadequate organ preservation.

Strictures can be of two types, anastomotic or non-anastomotic. Strictures that occur in the region of the anastomosis are influenced by local factors and are usually short and unique. [Figure 6] The incidence appears to be greater after the completion of Roux-en-Y

hepaticojejunostomy than after duct-to-duct anastomosis. The use of T-tube bile drains seems to have a protective effect on the occurrence of stenosis, while the occurrence of fistula is an independent risk factor for stricture development.

| Risk factors for Biliary Strictures | |
|-------------------------------------|--|
| Anastomotic | Suture technique Bile leaks Bile duct dissection |
| Ischemic type | Hepatic artery Thrombosis Prolonged cold ischemia period Prolonged arterialization time Donor related: Age High dose vasoactive drugs Cardiac arrest Immune-mediated: Chronic ductopenic rejection ABO incompatibility Bile salts toxicity Infection Citomegalovirus Viral hepatitis recurrence |

Table 2. Risk factor for biliary stricture

Strictures of late onset usually are related to ischemic or immunological events. The ischemic causes may be related or not to hepatic artery thrombosis, other causes being long cold or hot ischemia period, prolonged graft arterialization time, removal of the organ after donor cardiac arrest, excessive use of vasoactive drugs or high age of the donor. Root causes are mostly alo-immune ABO incompatibility, chronic ductopenic rejection, recurrence of underlying disease such as sclerosing cholangitis and autoimmune hepatitis, bile salts toxicity to the epithelium, recurrent viral hepatitis and cytomegalovirus infection (Suarez et al. 2008). These types of stenosis, classified as ischemic type, usually are long, multiple, interspersed with areas of dilation and can occur both intra and extra hepatic. [Table 2]

There may be asymptomatic presentation or only with vague symptoms like fatigue, itching and jaundice. The change in liver function markers, such as elevated bilirubin, gamma-glutamyl transferase, alkaline phosphatase and serum aminotransferases should raise suspicion for biliary stenosis or obstructions.

Doppler ultrasound evaluation should be performed to evaluate the presence of hepatic blood flow. If stenosis or artery obstruction is suspected, complete evaluation by angiography or angio-MRI should be performed.

The assessment of biliary obstruction by ultrasonography has poor accuracy in transplanted patients and is not a reliable marker of good biliary drainage. The sensitivity for detection of obstructions varies from 40 to 65%, with a high number of false negatives. The biliary tree in transplanted livers may not dilate, even in the presence of significant obstruction. This is explained by the possible presence of peri-ductal fibrosis that can occur in these patients.

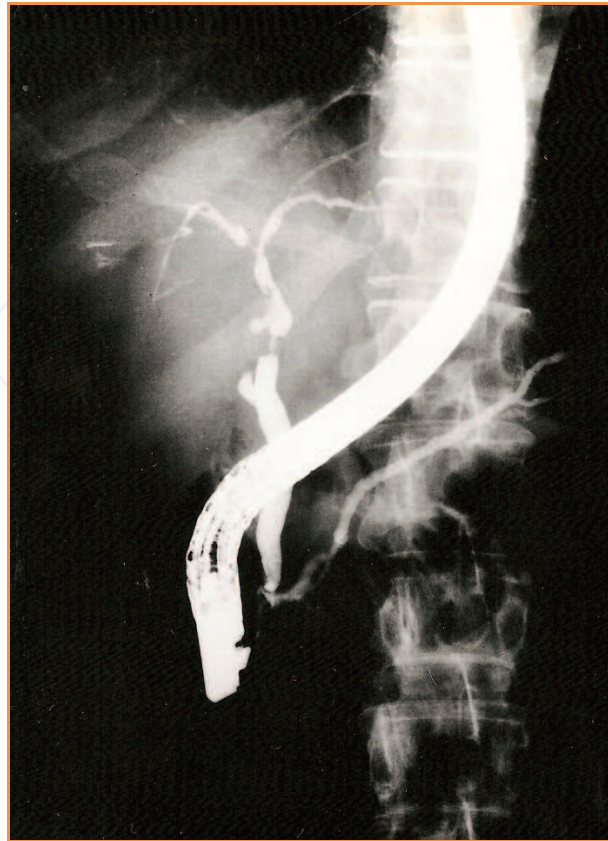


Fig. 6. Anastomotic type biliary stricture, shown in ERCP

The gold standard test for the detection of biliary strictures is cholangiography, both when percutaneous or endoscopic. This test allows proper identification of the cause of obstruction to bile flow and allows therapeutic measures, such as stone removal, dilation and biliary stent insertion. The preference is for performing endoscopic procedure (ERCP) because it is less invasive, with lower bleeding or fistula risk when compared with percutaneous procedure (PTC). The existence of anastomosis in Roux-en-Y is an impediment to the conduct of endoscopic procedure. Although there are series that could demonstrate factual ERCP using ballon-enteroscopy or through previously made stomas, this is not usually available in clinical practice. When ERCP is not possible or when it is not adequate PTC could be tried.

The performance of MRI-cholangiography shows results comparable to ERCP in diagnostic aspect. In a prospective trial, MRI-cholangiography achieved 95% accuracy and 98% sensitivity, when compared to ERCP. The lack of therapeutic capability is a major drawback of the method, serving as an intermediate examination prior to invasive procedures in interventional radiology.

Treatment of biliary obstruction is time consuming, requiring multiple interventions and with high risk of relapse. The initial therapeutic option is interventional radiology procedures, endoscopic or percutaneous whenever possible. Dilation of strictures with balloon dilators when performed alone has a long-term success rate of only 40%. The placement of biliary prostheses, ranging between 7 and 10fr increases the effectiveness to about 75%. Studies with the placement of multiple parallel plastic stents solved up to 90% of cases of strictures (Williams & Draganov, 2009). The procedure should be repeated at

regular intervals to prevent obstruction of the stents and cholangitis. Intervals of three to six months are well accepted, but the carrying out of more aggressive treatments at intervals of two weeks, has shown good results.

Recurrence of stenosis is the rule, with multiple procedures being needed to settle the case, with treatment periods ranging from one to two years. The use of self-expandable metal stents seems to allow a longer period of symptom relief, with need of fewer procedures, but there are still not many published results (Kusano et al. 2005).

Endoscopic treatment failure leads to the need for a surgical approach. In cases of anastomotic stenosis the resolution and prognosis are good. If the primary reconstruction is duct-to-duct anastomosis, the procedure is the conversion to Roux-en-Y hepaticojejunostomy. If the obstruction occurs on a previously performed enteric bypass the anastomosis should be reconfigured. In selected cases, some services choose to make a jejunostomy stoma to allow access to future possible endoscopic interventions in the biliary tree, if needed.

Ischemic stenosis type has a worse prognosis and lower resolvability even with surgical treatment. The failure to obtain adequate biliary drainage has a strong association with decreased graft survival. Patients with unresolved biliary strictures evolve to liver failure, with up to 30 to 50% progressing to death or retransplantation, despite continuous endoscopic and percutaneous drainage (Yazumi et al. 2006).

Retransplantation is indicated especially in cases associated with arterial thrombosis, or in cases that progress to cirrhosis secondary to chronic biliary obstruction. The mortality associated with this procedure is significantly higher than in the first transplant (Verdonk et al. 2006).

8. Other complications

In addition to fistulas and strictures, several other forms of complications can occur in the bile ducts after liver transplantation. Obstruction of the biliary tract by extrinsic causes, bleeding and recurrence of pre-existing diseases are most common (Wojcickia et al. 2008).

Extrinsic compression of the bile ducts can occur by several factors, such as hepatic hilar lymph nodes, recurrence of hepatic neoplasms, compression by other anatomical structures such as the hepatic artery and pseudoaneurysms, and because of mucocèles. Treatment of this type of compression can be with interventional radiology stenting or Roux-en-Y hepaticojejunostomy in refractory cases.

Mucocèle of the cystic duct stump is infrequent, occurring when the donor cystic duct is blindly sutured to the anastomosis. The accumulation of mucus produced by the biliary epithelium leads to expansion of this segment, with compression of the common bile duct. The prevention of this complication should be performed by complete excision of the cystic duct of the donor or by section of the septum and communication of both ducts before the anastomosis. Cholangiography with typical findings of external compression and thinning of the distal bile duct make the diagnosis. The treatment is excision of the cystic duct remnant and biliary bypass with hepaticojejunostomy.

Cases of jaundice and dilatation of the distal bile duct without an obstructive factor identified on cholangiography may be due to sphincter of Oddi or ampullary dysfunction.

This variation can occur in up to 3% of transplanted patients and is justified due to denervation of autonomic plexus during the surgery. Although the diagnosis can only be confirmed with duodenal papilla manometry, the resolution after endoscopic papillotomy strongly supports this hypothesis.

The occurrence of spontaneous hemobilia is rare after liver transplantation and may occur due to rupture of pseudoaneurysms of the hepatic artery. Bleeding is more common after invasive procedures such as liver biopsies and percutaneous transhepatic cholangiography, in these cases with an incidence of 2%. The clinical presentation is of upper gastrointestinal bleeding and the diagnosis made by endoscopy. In cases of major bleeding or lack of spontaneous resolution arteriography with selective embolization of the responsible branches should be performed. Endoscopic retrograde cholangiography may be indicated for the removal of blood clots and passage of biliary stent.

Recurrent disease after liver transplant may be up to 20% of patients with autoimmune hepatitis, primary biliary cirrhosis and sclerosing cholangitis. The development of multiple biliary strictures can occur and are often difficult to differentiate from ischemic injury. In patients with confirmed diagnosis of sclerosing cholangitis prior to liver transplantation, biliary reconstruction is done preferably by Roux-en-Y hepaticojejunostomy, aiming for the prevention of recurrent disease in the receptor distal common bile duct remnant. Duct-to-duct anastomosis has been performed selectively in patients who show no signs of stenoses or inflammation in the distal bile duct during the transplant. However, a recent multicenter review showed higher risk of stenosis and lower graft survival rates in patients with primary sclerosing cholangitis undergoing duct-to-duct anastomosis compared to those submitted to Roux-en-Y hepaticojejunostomy (Welling et al. 2008).

9. Experience at unit of liver transplantation – Unicamp

Between September/1991 and May/2011 528 orthotopic liver transplants from deceased donors were conducted. Follow-up period ranged from 1 month to 19 years.

The type of biliary reconstruction used was end-to-end duct-to-duct anastomosis in 477 patients (90.4%). Biliary T-tube drains were used in only 17 patients (3.5%). Patients undergoing Roux-en-Y hepaticojejunostomy represented 9.6% of the total (51 patients). [Table 3]

We identified 95 cases of complications in the biliary tract, representing an incidence of 17.9%, consistent with the literature. Among these complications 86.3% were stenosis and 13.7% were bile leaks. The association of arterial thrombosis with biliary complications was

| Type of Reconstruction | Number | (%) |
|-------------------------------|--------|---------|
| Duct-to-Duct | 447 | (90,4%) |
| with T-tube | 17 | (3,2%) |
| without T-tube | 460 | (87,2%) |
| Roux-en-Y Hepaticojejunostomy | 51 | (9,6%) |
| Total | 528 | (100%) |

Table 3. Biliary reconstruction at Unit of Liver Transplantation – Unicamp

consistent with recent reports published by various centers, with 32.6% of all leaks and strictures due to ischemic events.

The analysis of incidence of complications in relation to the type of reconstruction employed had a slightly higher complication rate of 21.5% in the group undergoing hepaticojejunostomy against 17.6% in the group with duct-to-duct anastomosis. The highest incidence of fistulas was observed after Roux-en-Y reconstruction, 36.4% versus 10.8%. But the small number of patients undergoing this type of anastomosis precluded a more detailed analysis. [Table 4]

| Type of Reconstruction | Duct-to-Duct | | Hepaticojejunostomy | | Total | |
|------------------------|--------------|---------|---------------------|---------|--------|---------|
| Complications | 84/477 | (17,6%) | 11/51 | (21,5%) | 95/528 | (17,9%) |
| Bile Leaks | 9 | (1,9%) | 4 | (7,8%) | 13 | (2,4%) |
| Strictures | 75 | (15,7%) | 7 | (13,7%) | 82 | (15,5%) |
| Artery Thrombosis | 28/84 | (33,3%) | 3/11 | (27,2%) | 31/95 | (32,6%) |

Table 4. Complications incidence related to reconstruction technique

Complications after duct-to-duct anastomosis were initially treated with endoscopic retrograde cholangiography (ERCP) in 72.6% of cases, and in about 35% of the patients this was the only treatment employed. [Figure 7] Reference to percutaneous cholangiography (PTC) was restricted in this group, in only 3.5%. Surgical treatment had to be carried out in 54% of these patients, including percutaneous drainage, laparotomy for peritonitis and sepsis and hepaticojejunostomy anastomosis conversion. [Table 5]

In the group with Roux-en-Y bileo-enteric shunt, indication of initial surgical treatment was approximately 64% and in about 20% of cases percutaneous cholangiography was performed. The main indication for surgery as initial treatment in this group is consistent with the difficulty in addressing this anastomosis by interventional radiological techniques.

Retransplant was indicated in approximately 8% of patients with biliary strictures, all of which were associated with hepatic artery thrombosis. In 85% of these patients, other forms of treatment had been tried before retransplantation. The cumulative mortality of patients undergoing retransplantation was 50%.

| Treatment | Duct-to-Duct | | Hepaticojejunostomy | | Deaths | |
|--------------|--------------|---------|---------------------|---------|--------|---------|
| ERCP | 61 | (72,6%) | 0 | - | 16 | (26,2%) |
| PTC | 3 | (3,5%) | 2 | (18,2%) | 2 | (40%) |
| Surgery | 46 | (54,7%) | 7 | (63,6%) | 9 | (17%) |
| Retransplant | 6 | (7,1%) | 2 | (18,2%) | 4 | (50%) |
| Total | 84 | | 11 | | 26 | (27,4%) |

Table 5. Treatment of biliary complications at Unit of Liver Transplantation – Unicamp

The group undergoing combined surgical and endoscopic treatment showed the highest resolution rate of the complications, achieved in 75% of the cases. Despite the various forms

of treatment employed, the mortality from biliary complications remained high, 27.4%, consistent with the data in the literature.

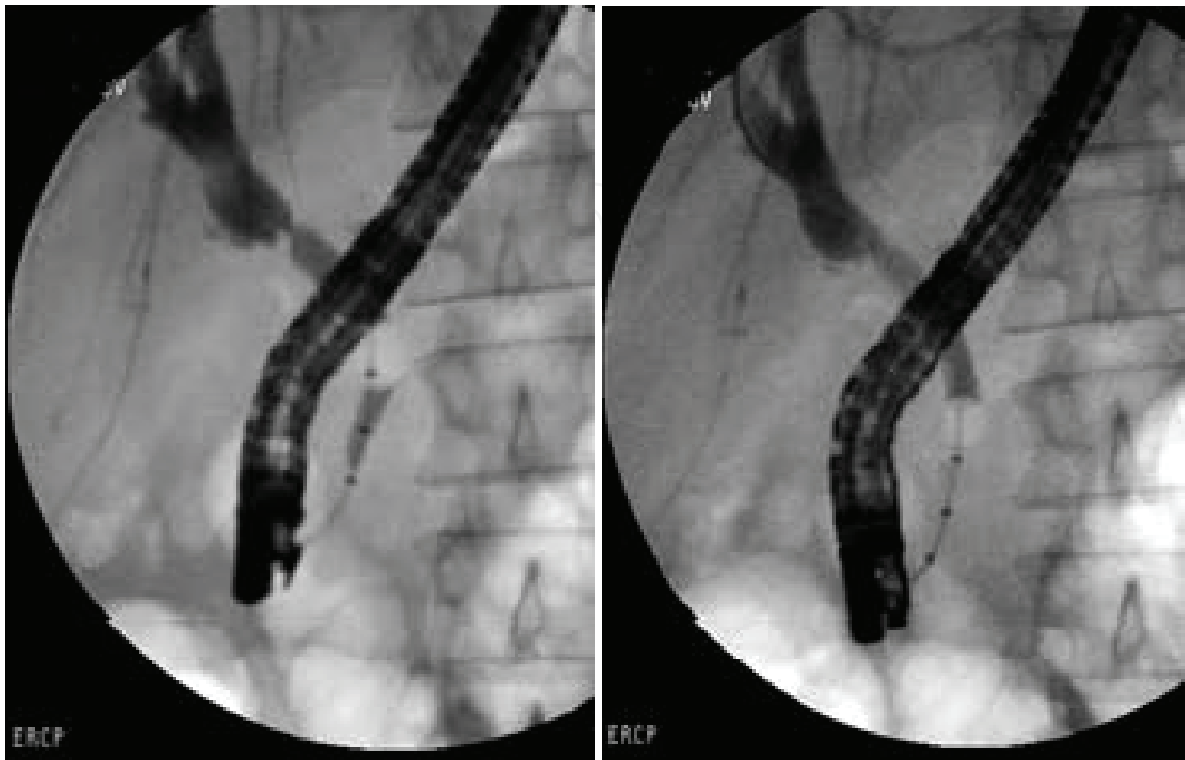


Fig. 7. Endoscopic treatment of biliary stricture. Left: Pre-procedure cholangiography with short segmental stricture. Right: Radiological control after stent placement

10. Conclusions

Several advances in the care of patients undergoing liver transplantation have increased the survival of grafts and recipients. Despite this, the complications arising in the bile ducts are still of great importance to its incidence, difficulty of treatment, morbidity and mortality.


The proper technical care in the anastomosis confection and in the selection of donors, organ preservation, reduction in the ischemic period and arterialization time are the best ways to prevent this type of complication. A fact demonstrated by the lower incidence and the increasing role of hepatic artery thrombosis in the development of biliary complications as the transplant teams gain more experience.

The diagnosis and treatment of biliary leakage and stenosis depend on a large number of imaging and interventional procedures. So the care of such patients should be individualized, depending on experience and availability of local resources.

11. References

- A. Gantxegi, M. Caralt, I. Bilbao, L. Castells, J.L. Lázaro, L. Llopart, I. Díez, C. Dopazo, G. Sapisochín, M. Pérez, and R. Charco Evolution of Biliary Complications After Liver Transplantation: A Single European Series Transplantation Proceedings, 43, 745–748 (2011)

- Azoulay D, Marin-Hargreaves G, Castaing D, Rene A, Bismuth H: Duct-to-duct biliary anastomosis in living related liver transplantation. *Arch Surg* 2001;136:1197-1200.
- Emmanuelle D Williams, Peter V Draganov Endoscopic management of biliary strictures after liver transplantation *World J Gastroenterol* 2009 August 14; 15(30): 3725-3733
- Kusano T, Randall HB, Roberts JP, Ascher NL: The use of stents for duct-to-duct anastomoses of biliary reconstruction in orthotopic liver transplantation. *Hepatogastroenterology* 2005;52:695-699.
- Londono MC, Balderramo D, Cardenas A. Management of biliary complications after orthotopic liver transplantation: the role of endoscopy. *World J Gastroenterol* 2008; 14: 493-497
- Maciej Wojcicka, Piotr Milkiewicz, b Michael Silvac: Biliary Tract Complications after Liver Transplantation: A Review *Dig Surg* 2008;25:245-257
- Noujaim HM, Gunson B, Mayer DA, Mirza DF, Candinas D, Buckels JA, McMaster P, de Ville de Goyet J: Worth continuing doing ex situ liver graft splitting? A single-center analysis. *Am J Transplant* 2003;3:318-323.
- O'Connor TP, Lewis WD, Jenkins RL: Biliary tract complications after liver transplantation. *Ann Surg* 1995;130:312-317.
- Renz JF, Emond JC, Yersiz H, Ascher NL, Buscetta RW: Split-liver transplantation in the United States. Outcome of a national survey. *Ann Surg* 2004;239:172-181.
- Scotte M, Dousset B, Calmus Y, Conti F, Houssin D, Chapuis Y: The influence of cold ischemia time on biliary complications following liver transplantation. *J Hepatol* 1994; 21:340-346.
- Suarez F, Otero A, Solla M, Arnal F, Lorenzo MJ, Marini M, Vazquez-Iglesias JL, Gomez M: Biliary complications after liver transplantation from Maastricht category-2 non-heart-beating donors. *Transplantation* 2008; 85:9-14.
- Testa G, Malago M, Valentin-Gamazo C, Lindell G, Broelsch CE: Biliary anastomosis in living related liver transplantation using the right liver lobe: Techniques and complications. *Liver Transpl* 2000;6:710-714.
- Verdonk RC, Buis CI, Porte RJ, Van der Jagt EJ, Limburg AJ, Van den Berg AP, Slooff MJ, Peeters PM, de Jong KP, Kleibeuker JH, Haagsma EB: Anastomotic biliary strictures after liver transplantation: causes and consequences. *Liver Transpl* 2006;12:726-735.
- Verran DJ, Asfar SK, Ghent CN, Grant DR, Wall WJ: Biliary reconstruction without T-tubes or stents in liver transplantation: report of 502 consecutive cases. *Liver Transpl Surg* 1997;3:365-373.
- Welling TH, Heidt DG, Englesbe MJ, Magee JC, Sung RS, Campbell DA, Punch JD, Pelletier SJ. Biliary complications following liver transplantation in the model for end-stage liver disease era: effect of donor, recipient, and technical 35 factors. *Liver Transpl* 2008; 14: 73-80
- Welling TH, Heidt DG, Englesbe MJ, Magee JC, Sung RS, Campbell DA, Punch JD, Pelletier SJ: Biliary complications following liver transplantation in the model for end-stage liver disease era: effect of donor, recipient, and technical factors. *Liver Transpl* 2008;14: 73-80.
- Yazumi S, Yoshimoto T, Hisatsune H, Hasegawa K, Kiola M, Tada S, Uenoyama Y, Yamauchi J, Shio S, Kasahara M, Ogawa K, Egawa H, Tanaka K, Chiba T: Endoscopic treatment of biliary complications after right-lobe living-donor liver transplantation with duct-to-duct biliary anastomosis. *J Hepatobiliary Pancreat Surg* 2006;13:502-510.



Liver Transplantation - Technical Issues and Complications

Edited by Prof. Hesham Abdeldayem

ISBN 978-953-51-0015-7

Hard cover, 454 pages

Publisher InTech

Published online 10, February, 2012

Published in print edition February, 2012

This book covers a wide spectrum of topics including, but not limited to, the technical issues in living and deceased donor liver transplant procedures, cell and experimental liver transplantation, and the complications of liver transplantation. Some of the very important topics, such as the arterial reconstruction in living donor liver transplantation, biliary complications, and the post-transplant-lymphoproliferative disorders (PTLD), have been covered in more than one chapter.

How to reference

In order to correctly reference this scholarly work, feel free to copy and paste the following:

Ilka Boin, Fernando Romani De Araujo, Elaine Ataide, Anaisa Portes Ramos and Ciro Montes (2012). Biliary Complications in Liver Transplantation, Liver Transplantation - Technical Issues and Complications, Prof. Hesham Abdeldayem (Ed.), ISBN: 978-953-51-0015-7, InTech, Available from: <http://www.intechopen.com/books/liver-transplantation-technical-issues-and-complications/biliary-complications-in-liver-transplantation>

INTECH
open science | open minds

InTech Europe

University Campus STeP Ri
Slavka Krautzeka 83/A
51000 Rijeka, Croatia
Phone: +385 (51) 770 447
Fax: +385 (51) 686 166
www.intechopen.com

InTech China

Unit 405, Office Block, Hotel Equatorial Shanghai
No.65, Yan An Road (West), Shanghai, 200040, China
中国上海市延安西路65号上海国际贵都大饭店办公楼405单元
Phone: +86-21-62489820
Fax: +86-21-62489821

© 2012 The Author(s). Licensee IntechOpen. This is an open access article distributed under the terms of the [Creative Commons Attribution 3.0 License](https://creativecommons.org/licenses/by/3.0/), which permits unrestricted use, distribution, and reproduction in any medium, provided the original work is properly cited.

IntechOpen

IntechOpen