

We are IntechOpen, the world's leading publisher of Open Access books Built by scientists, for scientists

6,900

Open access books available

186,000

International authors and editors

200M

Downloads

Our authors are among the

154

Countries delivered to

TOP 1%

most cited scientists

12.2%

Contributors from top 500 universities



WEB OF SCIENCE™

Selection of our books indexed in the Book Citation Index
in Web of Science™ Core Collection (BKCI)

Interested in publishing with us?
Contact book.department@intechopen.com

Numbers displayed above are based on latest data collected.
For more information visit www.intechopen.com



The Routinely Use of “Piggyback” Technique in Adult Orthotopic Liver Transplantation

Luis Herrera et al.*

*Hospital Universitario “Marqués de Valdecilla”
Spain*

1. Introduction

1.1 Liver transplantation relevance

Liver transplantation is a surgical technique designed for the treatment of patients suffering from end stage liver disease and who would not otherwise have a chance to survive. After the first liver transplantation, performed by Thomas Earl Starzl on the first of March, 1963 in Denver, Colorado, thousands of procedures have been performed all around the world. 5300 liver transplantations were performed in the USA during 2002 and 5142 in Europe. The European liver transplantation registry has 93634 transplantations registered until December 2009 (www.eltr.org).

The evolution of liver transplantation was not easy initially, and survival was inferior to one year until 1967. Liver transplantation was not considered as the gold standard treatment for end stage liver diseases by National Institutes of Health until 1984 (National Institutes of Health Consensus Development Conference on Liver Transplantation, 1984). Two years later, this procedure was included by the Public Health department of the USA as a treatment modality (U.S. Department of Health and Human Services, Public Health Service, Health Resources and Services, 1986).

2. Principles and techniques for liver transplantation

Orthotopic liver transplantation requires total hepatectomy and substitution of the native liver by another one in the right hypochondrium. Vascular reconstruction is needed for the inferior vena cava, portal vein, and the hepatic artery. Biliary reconstruction is also needed, by either an end to end biliary anastomosis or a biliodigestive anastomosis.

Classic technique for orthotopic liver transplantation requires resection of the intrahepatic part of the inferior vena cava, and the use of a veno-venous bypass to keep venous return to the heart. This technique has a considerable morbidity and mortality in some cases, and can

* Federico Castillo, Marcos Gómez, Gonzalo Gutiérrez, Roberto Fernández, Elena García, Antonio López, Mónica González, Juan Carlos Rodríguez, Francisco González, Fernando Casafont and Manuel G. Fleitas
Hospital Universitario “Marqués de Valdecilla” Spain

be avoided if resection of the inferior vena cava is not done, preserving it during the procedure.

3. Anatomy of hepatic veins

Couinaud described eight segments of the liver in which each segment has an independent vascular inflow and outflow and biliary drainage. Based on the location of the hepatic veins, the right liver is divided into the anterior section (segments V and VIII) and the posterior section (segments VI and VII). On the left, the falciform ligament demarcates the left lateral section (segments II and III) from the left medial section (segment IV). The caudate lobe (segment I) lies anterior to the IVC.

The venous drainage of the liver is through the hepatic veins that ultimately coalesce into three hepatic veins that drain into the IVC superiorly. The left and middle hepatic veins may drain directly into the IVC but more commonly form a short common trunk before draining into the IVC. The right hepatic vein is typically larger, with a short extra hepatic course and drains directly into the IVC. Additional drainage occurs directly into the IVC via short retro hepatic veins and, on occasion, an inferior right accessory hepatic vein. The hepatic veins within the parenchyma are unique in that, unlike the portal venous system, they lack the fibrous, protective, encasing the Glisson capsule (Ger, 1989)

The liver has a rather constant anatomic pattern, the knowledge of which allows for a safe surgical approach. There are some anatomic irregularities, in these cases a computed three-dimensional reconstruction of anatomic detail is possible following computed tomographic or magnetic resonance imaging contrast scan. Software packages are currently available that allow for the mapping of the individual anatomy as well as for the calculation of volumes corresponding to the whole liver, liver sectors, and segments (Molmenti, 2007)

Ultrasonography facilitates intraoperative mapping of the internal anatomy of the liver. The portal venous anatomy can readily be identified by the hyperechogenic Glisson capsule surrounding the portal veins, whereas the hepatic veins lack this.

The IVC maintains an important and intimate association with the liver as it courses in a cranial-caudal direction to the right of the aorta. As the IVC travels cranially, it courses posterior to the duodenum, pancreas, porta hepatis, caudate lobe, and posterior surface of the liver as it approaches the bare area where it receives the hepatic venous outflow from the hepatic veins. Multiple small retro hepatic veins enter the IVC along its course, mostly from the right hepatic lobe. Hence, in mobilizing the liver or during major hepatic resections, it is imperative to maintain awareness of the IVC and its vascular tributaries at all times (Abdel-Misih, 2010)

4. Recipient implantation

In the Classic technique of orthotopic liver transplantation (OLT) the retrohepatic inferior vena cava (IVC) is included in the hepatectomy of the native liver (Starzl, 1968). To limit the hemodynamic complications associated with complete caval clamping, the routine use of the veno-venous bypass (VVB) was accepted particularly in noncirrhotic patients. (Shaw, 1984). Although VVB has been proposed in order to reduce these hemodynamic disorders it is associated with high morbidity and increased operation time (Veroli, 1992 & Khoury, 1987, 1990)

Preservation of the inferior vena cava (IVC) during orthotopic liver transplantation (OLT), described by Calne and Williams in 1968, was popularized in 1989 by Tzakis as the piggyback procedure (PB). The main advantages of this procedure were to avoid retrocaval dissection, to reduce the risk for bleeding and facilitate caval anastomosis in patients receiving large-for-size grafts (Tzakis, 1989 & Parrilla, 1999).

5. Caval anastomosis

Several methods of graft-to-inferior vena cava (IVC) implantation during orthotopic liver transplantation with preservation of the caval flow have been described. Large studies have shown that optimal outflow is essential to a successful piggyback procedure (Navarro & Parrilla, 1999). In the series by Tzakis (Tzakis, 1989) the caval anastomosis was performed between the supra hepatic part of donor IVC and the common orifice of all three hepatic veins or the common orifice of two hepatic veins (left and middle or right and middle). This is the so-called PB technique.

In 1992, Belghiti developed a technique of caval anastomosis in a side-to-side fashion (Belghiti, 1992). In this technique, both ends of the donor IVC are closed. Anastomosis is made between two newly created openings: one on the anterior wall of the recipient IVC and one on the posterior wall of the donor IVC, but because of insufficient exposure during implantation of large grafts and to facilitate postoperative trans-jugular biopsy, they used an end-to-side fashion after 1993. (Belghiti, 1995)

The third type of caval anastomosis is the end-to-side (ES) technique and can be found in the literature some modifications of this technique. Cherqui et al. described in their series, the distal end of the donor infra hepatic IVC was closed and the anastomosis was made between the end of the donor supra hepatic IVC and a longitudinal incision on the anterior wall of the recipient IVC. Additionally, a temporary portocaval shunt was routinely used (Cherqui, 1994). Other authors report several variations of the technique, the middle and left hepatic veins are exposed and a Satinsky side clamp is applied to the caval side with partial IVC occlusion. The middle and left hepatic veins are divided, and the recipient liver is removed. A single hepatic venous outflow orifice is created from the middle and left hepatic venous trunks, and this orifice can be extended caudally (Fleitas, 1994 & Belghiti, 1995).

Some authors suggest that the technique the 3-vein appears to be the most physiological way of achieving this goal. Although it has often been mentioned, the approach to creating a large 3-vein stoma without complete occlusion of the IVC is difficult. As Tayar reported (Tayar, 2011), anastomosis of the graft IVC to the joined orifice of the 3 main hepatic veins with partial caval occlusion was first mentioned by Lazaro (Lazaro, 1997).

PB technique can be associated with some disadvantages and complications, including hepatic venous outflow obstruction (Cescon, 2005) and thrombosis in up to 10%, because of the inappropriate size of the hepatic vein outlet, which results in venous congestion of the liver allograft. This congestion increases the chance of post-transplant ascites and Budd-Chiari syndrome (BCS) (Bilbao & Cirera, 2000; Mehrabi, 2009)

6. History of the “piggyback” technique

During the 5th and the 6th decade of 20th century, two pioneers in liver transplantation, Francis Daniels Moore and Thomas Earl Starzl, in Boston and Chicago respectively, were

trying to perform with success an experimental transplantation. Unfortunately, their model in dogs, did not tolerate blood flow interruption neither at the IVC, nor at the portal vein because they supposed half of the venous return of the animal. Bypass dispositive had to be developed to avoid the hemodynamic compromise that the total hepatectomy supposed in the animal (Moore, 1959) and, in the end, they were included as routine tools for transplantation surgery in the first era. Nevertheless, Calne and Starzl noticed that in human adults, it was not always necessary to bypass neither portal nor inferior cava vein blood flow during the anhepatic phase of the transplantation (Calne, 2008).

Liver transplantation with IVC preservation was first performed by Sir Roy Calne in February 1968, at the Addenbrooke's Hospital in Cambridge (UK) (Calne, 1968). Patient was a 46 year old female suffering from cholangiocarcinoma and donor was a 5 year old child that had virus related encephalitis. Because of the anatomical difference, Calne had to drain liver graft to the supra hepatic veins of the patient, completely preserving inferior cava vein during the procedure. The patient survived for 11 weeks, and it was the 3rd liver transplantation in Europe, and the 19th all around the world.

Later, Tzakis and cols. (Tzakis, 1989) described this technique in 24 cases, in the early 1988 with an indication index of 19%. They reported a greater technical difficulty of the procedure, the possibility of affected margins in the oncological indications at that moment, and a case with transitory thrombosis of the infra hepatic remnant cava vein, not recommending the routine use of inferior cava vein preservation.

7. Our technique for venous outflow drainage in orthotropic liver transplantation

In order to avoid the use of veno-venous bypass and to routinely preserve the IVC in our liver transplantation program, we adjusted our technique to the anatomical differences in the venous drainage of the liver. We designed our own model as follows (G. Fleitas, 1994):

7.1 Total hepatectomy with complete preservation of the IVC

Once identified and isolated, the liver pedicle elements are dissected adequately. With the vascular exclusion performed, we practice complete section of the falciform and triangular ligament in order to expose the confluence of the right hepatic vein and the left set (medial and left hepatic veins that usually drain together). After that, through the cavo-hepatic space, we perform a caudo-cranial dissection of the caudate lobe, with selective ligation of the hepatic veins. Their number varies, but the lesser the caliber, the greater the number is. The presence of a greater "inferior hepatic vein" that drains segment VI is very frequent. Usually, dissection extends by the left side of the IVC; dividing IVC and the caudate lobe until the arcuate ligament of the cavodiaphragmatic hiatus, very close to the mouth of the left phrenic vein, which usually has no venous drainage.

Once this space has been dissected, and the anterior hepatic veins have been tied and cut (usually sagittal to the IVC) and inferior and medial part of caudate lobe is dissected (usually hypertrophied because of cirrhosis) it is possible to easily pass in between both hepatic veins, at their mouth in the IVC. We isolate and clamp the left venous set and cut it, leaving enough margins for a safe cavo-caval anastomosis. After this, usually the right hepatic vein mouth in to the liver is exposed at a coronal level of the IVC, approximately

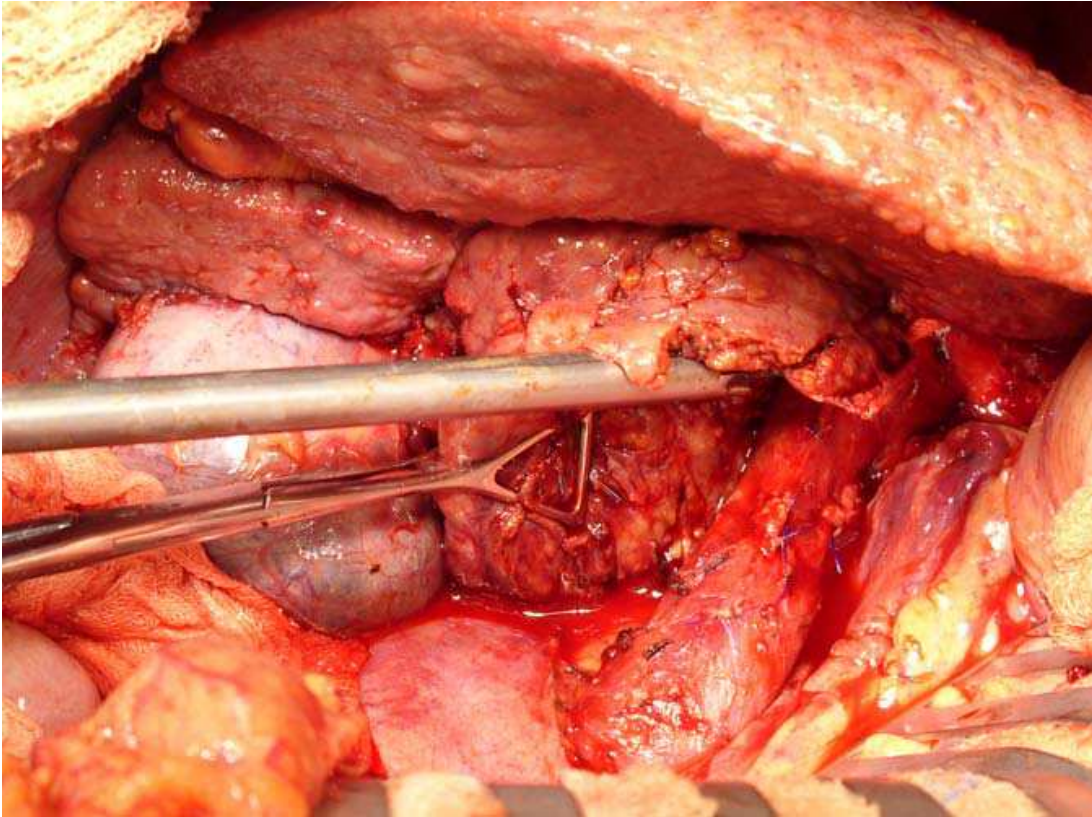


Fig. 1. Dissection of the infrahepatic IVC and left caudate lobule

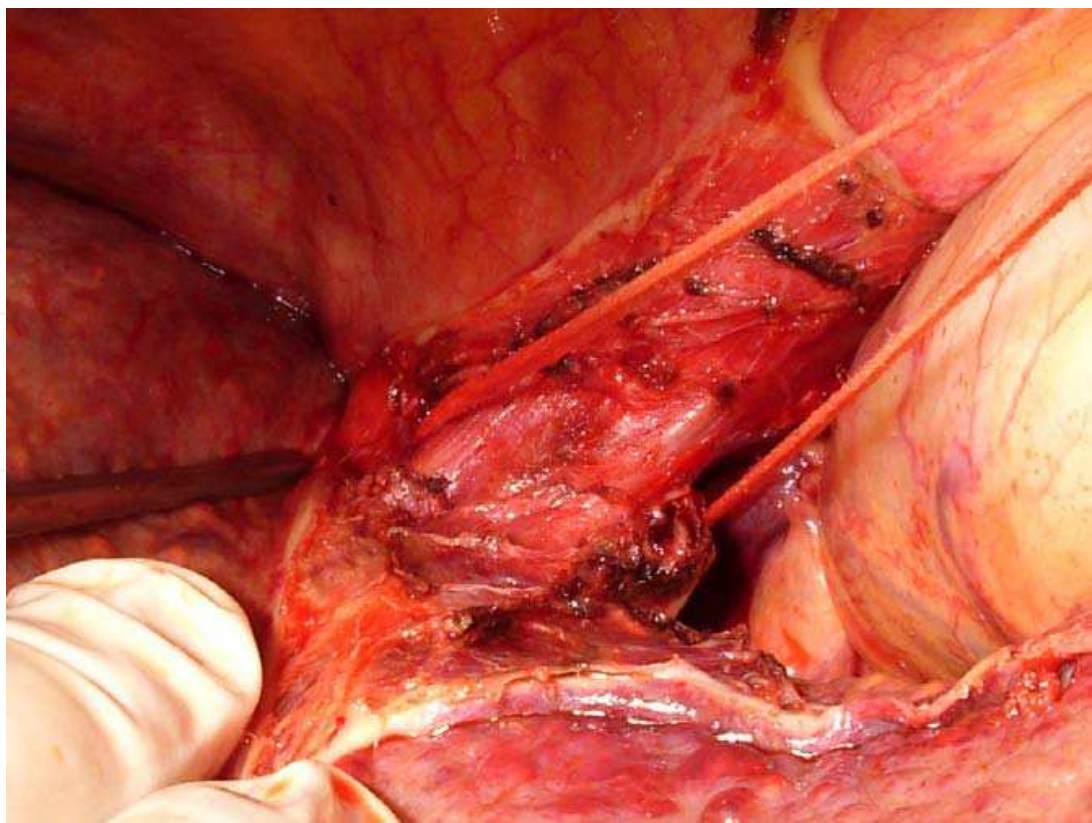


Fig. 2. Suprahepatic left and middle hepatic veins dissection

3 cm. far from the left venous set, suturing it with a continuous 3/0 polypropylene. After that, the right triangular ligament is cut, and right side of the IVC is dissected, cutting the corresponding veins, until caudate lobe is completely free from the IVC. This is the way how total hepatectomy is completed.

7.2 Carving liver graft drain mouth

This is an essential part of our technique. During this part, we clean the IVC of the graft, removing the tissues that are around its supra hepatic portion, cutting it at a level next to the supra hepatic veins mouth, at the level of the phrenic veins mouth, leaving a vascular sleeve to avoid the supra hepatic veins mouth being involved in the anastomosis.

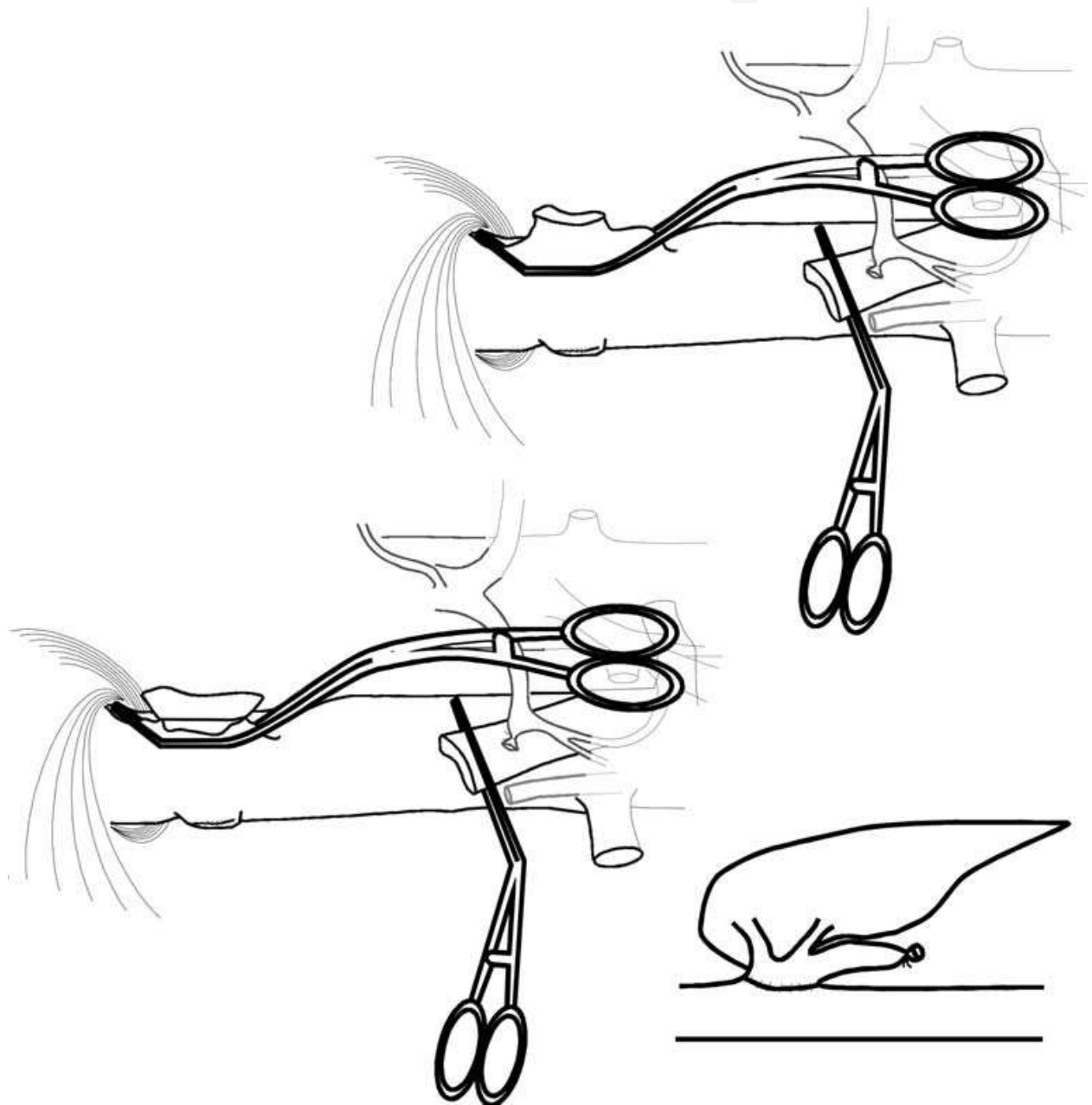


Fig. 3. Schematic lateral caval vein clamping and final result

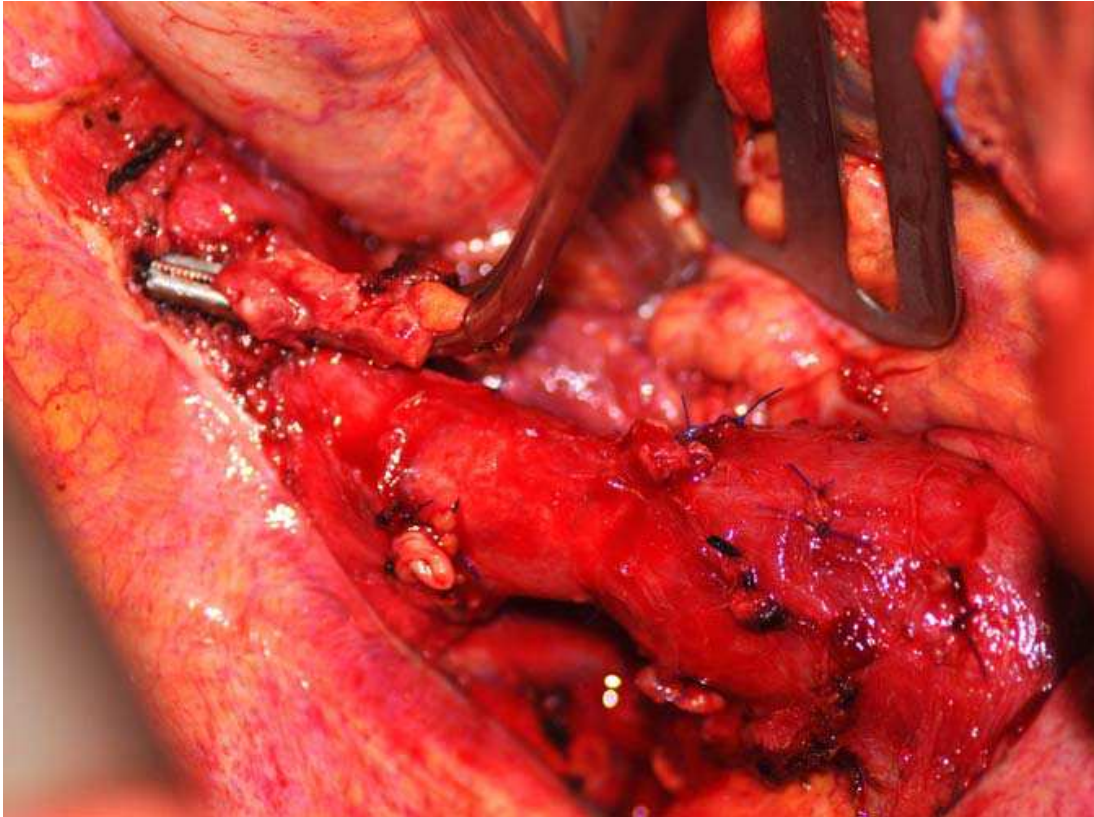


Fig. 4. Total Hepatectomy completed. Clamping of the left and middle hepatic veins

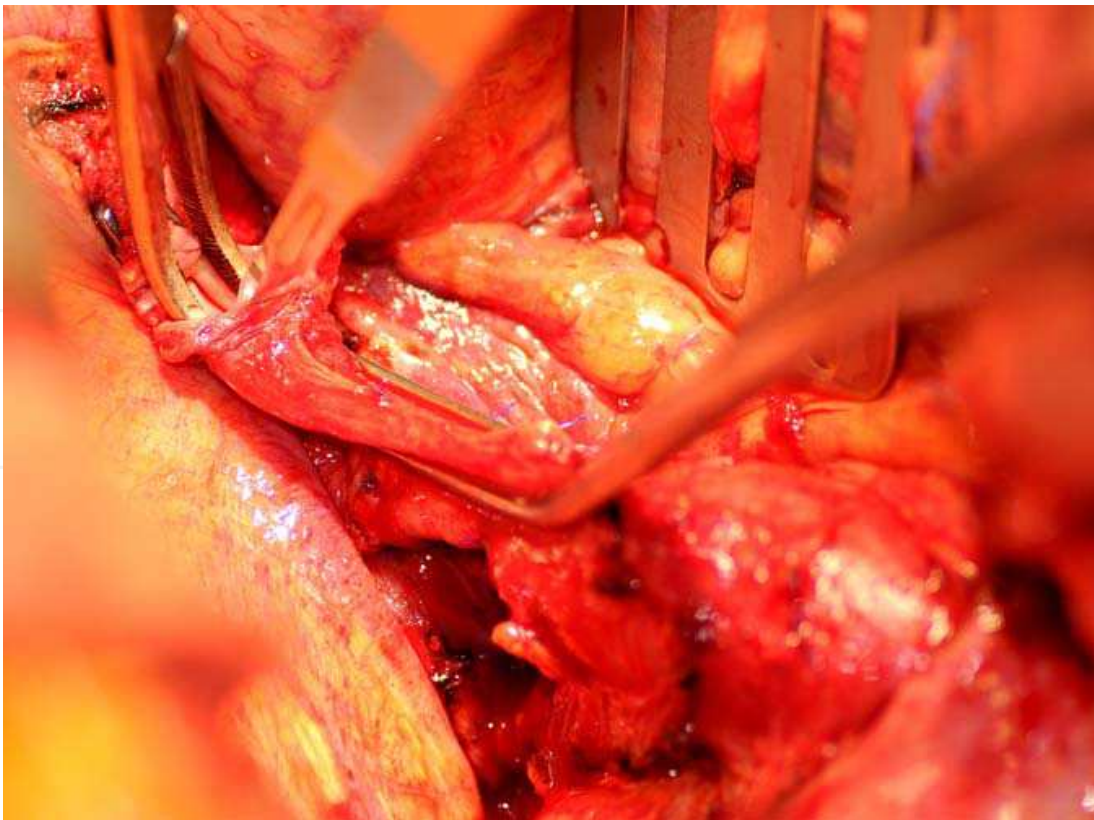


Fig. 5. Inferior caval vein cavotomy

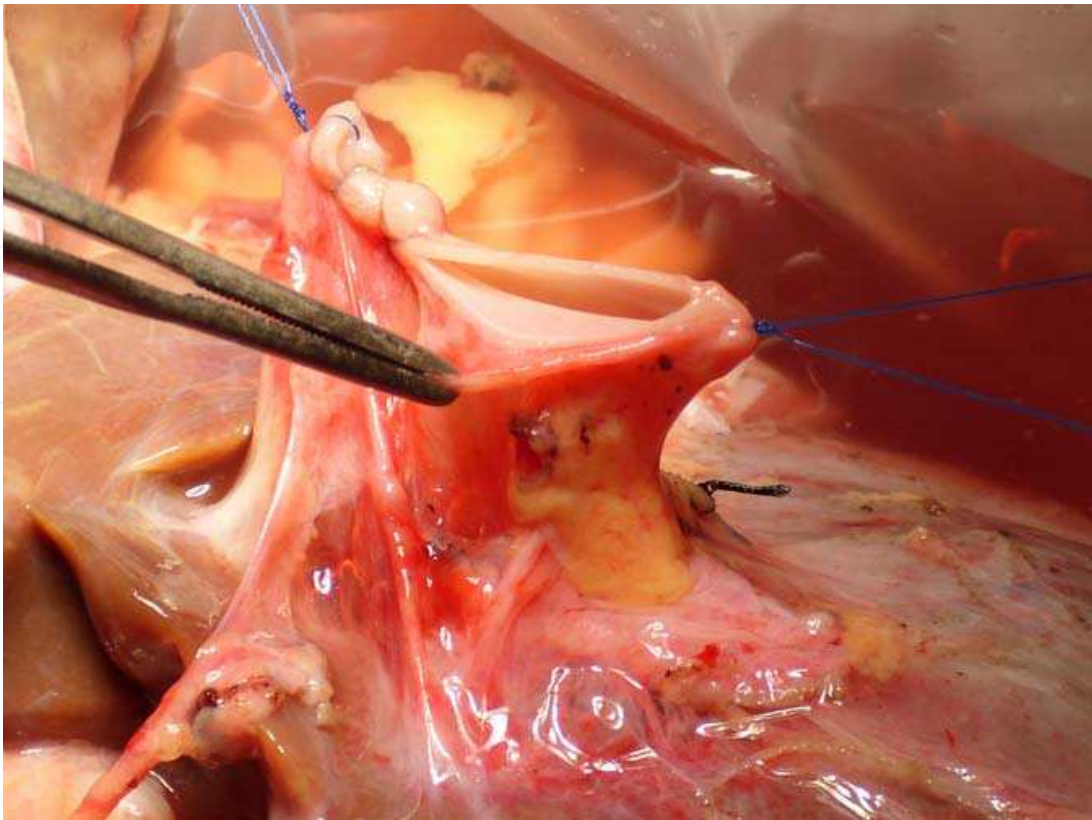


Fig. 6. Preparing liver graft. Infra hepatic caval vein stump partial closure

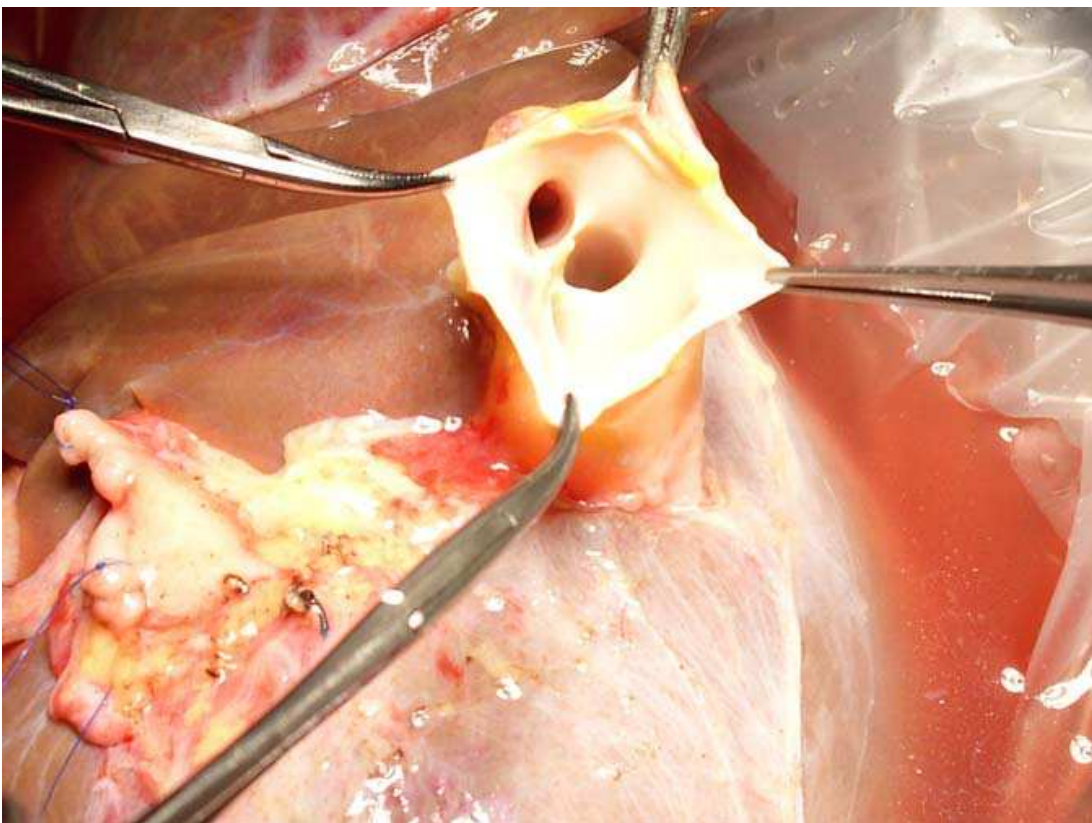


Fig. 7. The outlet and the entire graft IVC prepared for implantation

7.3 Left supra hepatic veins set cavoplasty

While monitoring hemodynamic parameters (Cardiac output and pressure at the inferior cava vein), we perform a lateral partial clamp of the cava vein, enough to carve a good venous sleeve made at the confluence of the left and medial supra hepatic veins, concordant in size to the graft venous sleeve made before. This clamping also allows temporal porto-cava anastomosis in case it is required without hemodynamic damage.

7.4 Inferior vena cavotomy

In some cases, when a left venous set can not be well defined or does not exist, and replace by a group of tiny veins interfering with safe anastomosis with a good drainage, we perform a craneocaudal cavotomy “de novo” in the IVC, as close to the right atrium as possible to achieve a negative pressure that allows better venous drainage of the liver graft, particularly in cases of Budd-Chiari Syndrome.

7.5 Enlargement of the venous outflow orifice of the graft

In order to achieve wider drainage of the supra hepatic veins, caudal cavotomy can be performed in the medial posterior side of the graft IVC, until supra hepatic veins orifices can be easily seen.

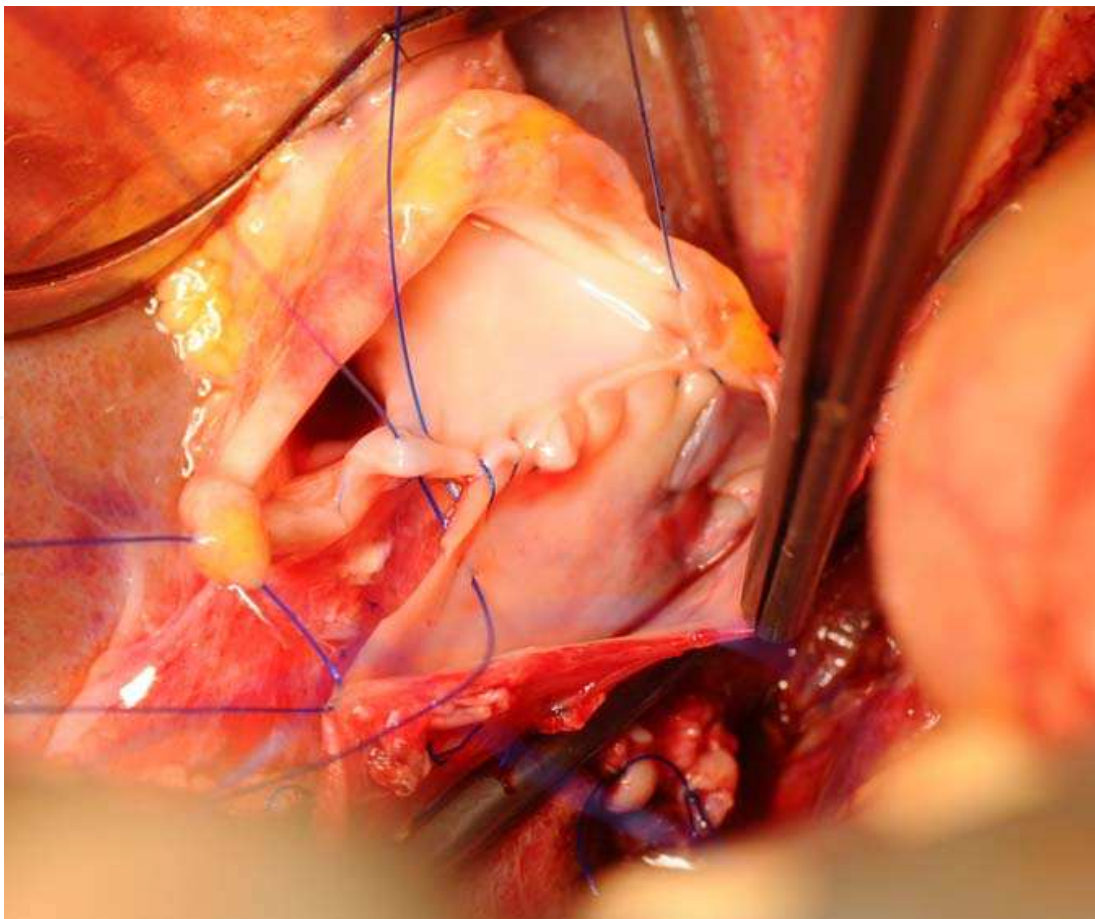


Fig. 8. Piggyback posterior side anastomosis close to right hepatic vein outlet

7.6 Graft implantation

Once adequate corresponding anastomotic orifices are achieved, and while keeping the vascular clamp on the recipient side of the IVC, we perform end to side, cavo-caval anastomosis using continuous 3/0 polypropylene. The aim is to provide wide anastomosis trying to achieve good outflow drainage of the graft. The distal end of the graft IVC is left open to allow “washing” of the graft after reperfusion, once the porto-portal anastomosis is done.

8. Advantages of the piggyback technique

Although initial attempts at preservation of the inferior vena cava in orthotopic liver transplantation by Sir Roy Calne, the so-called piggyback (PB) technique, was not initially worldwide accepted, it has become the most commonly used procedure in liver transplantation. Twenty years were necessary for Tzakis to describe the technique and its advantages over the classical caval reconstruction technique. Progressively in the 90's more transplant groups reported the utility and feasibility of the piggyback.

In addition, some modifications of the initial technique has been described, as the latero-lateral cavoplasty which added some benefits as well as the use of different types venovenous bypass or portocaval shunts. These two options are controversial, with some benefits and drawbacks, and are not widely used. (G. Fleitas, 1994; Ducerf, 1996; Lai & Vieira, 2011).

The advantages of the piggyback come from the disadvantages of the classical technique, due to clamping of the IVC next to the diaphragm and above the renal veins, during the anhepatic phase. This results in decreased venous return to the heart and reduction in cardiac output by as much as 50% and in blood pressure (Vieira, 2011). On the contrary, PB technique preserves caval flow, reduces hemodynamic instability, the needs of transfusions with less hemorrhage and allows shorter ischemia and operative times as will be explained.

During the anhepatic phase, the PB technique allows adequate venous return to the heart, which maintains the patient hemodynamics and renal venous outflow (Lázaro, 1997). Partial clamping of the cava at the level of the hepatic veins does not usually cause significant changes in the mean arterial pressure, IVC pressure, systemic vascular resistance index and cardiac index. The urine output before, during and after revascularization do not change significantly (G. Fleitas, 1994). Acute renal failure is less frequent (Sakai, 2010), and, cyclosporine or tacrolimus therapy can be started early. (Busque, 1998)

The PB procedure shortens the time of the liver transplant procedure, specially the warm ischemia time. Most groups report that with PB, and its modifications, no porto-caval shunt is needed. Even though there may be some exceptions, (situations in which no porto-systemic collaterals exist as fulminant hepatitis). The significant reduction in the time improves the patient and graft survival (Lai, 2011; Nishida, 2006; Busque, 1998). This permits early extubation and shorter intensive care unit stay. In fact there is a 30% shorter intensive care unit stay and a similar reduction in the overall hospital stay. Moreover, these advantages have an impact on total hospital charges for about 85% of the transplants procedures, with a significant mean reduction of \$23500 (Hosseini, 2000).

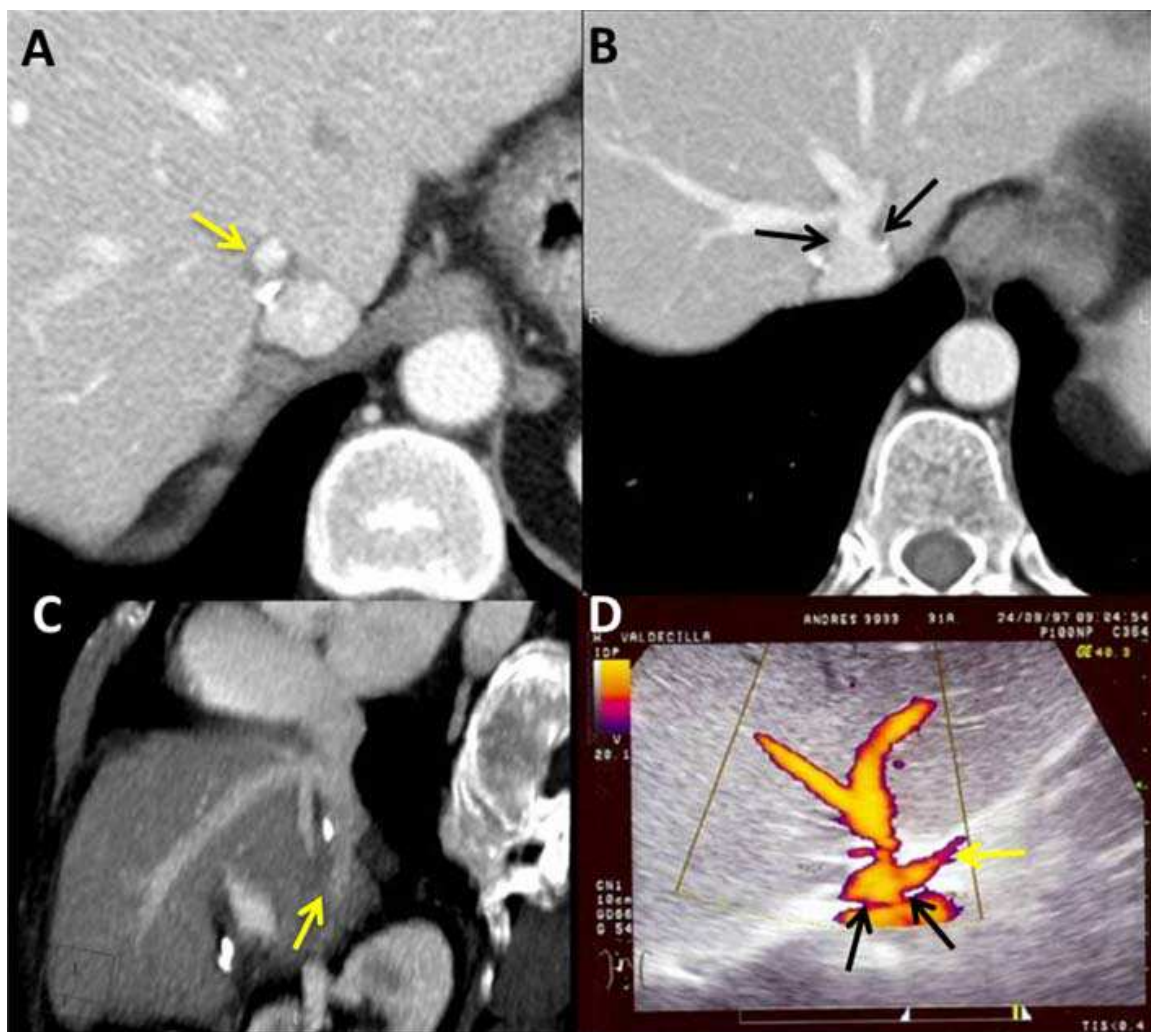


Fig. 9. Duplex-Doppler and CT Image showing the appearance of the normal caval stump. Yellow arrows pointing normal appearance of the graft caval stump and the black ones show the caval anastomotic outlet with adequate graft venous outflow drainage

Comparing the classical and the PB techniques, the more extensive dissection involving the cava and suprarenal veins from the liver causes more profuse bleeding with the former technique. The latter is associated with less extensive dissection which shortens the procedure and reduces the blood loss (Vieira, 2011). According to this, several papers confirmed that PB technique decreases blood requirements (Busque, 1998; Hossein, 2000; Nishida, 2006), and therefore the incidence post-transfusion problems are much less. Other advantages of PB technique include, better maintenance of core body temperature, avoidance of external venous bypass which is usually required in the classical technique with its associated intraoperative coagulopathy and third-spacing of fluid are significantly reduced, and in turn, the needs for transfusion is reduced (Hossein, 2000)

In addition, retransplantation may be easier if PB technique has been performed. Lateral clamping of the cava is again possible, and usually sufficient part of the wall of the IVC will be available for the anastomosis (Busque, 1998). This technique also makes easier to solve problems posed by mismatched recipient and donor IVC size, particularly in pediatrics, reduced-size, split, or living donor liver transplantation (Figueras, 2001; Calne, 1968).

In summary, adoptions of surgical techniques that minimize ischemia time, blood loss and shortens surgical times represent a surgical goal. PB technique seems to achieve the target. However some controversial points exist. General agreement is that PB technique can be used in almost any case of liver transplant. However, the exact procedure whether latero-lateral cavoplasty or bypass porto-caval shunt, remains unclear or at least, lacks of definitive evidence. As pointed out by (Gurusamy, 2011) in a Cochrane review, there are very few prospective randomized papers comparing the classical with the PB technique and the existing ones present important bias. According to this paper no important differences exist between both procedures.

9. Complications of piggyback technique

Complications of PB technique are well described in the literature although some distinction should be done according to the type of modification within the PB technique.

The reported morbidity is as low as 4% and the overall mortality is 0.7% (Navarro, 1999).

The main concern about PB technique is venous outflow obstruction. However, some other adverse effects related to PB technique and its modifications must be taken into consideration.

Intraoperative complications are basically related to bleeding or malposition of the graft and account for 2.5 %. Tears in the cava and release of the anastomosis running suture, were described as well as congestion of the graft after portal revascularization due to graft rotation. All of these complications can be satisfactorily resolved during the operation (Parrilla, 1999).

The most significant complication of the PB technique in the postoperative period is the occlusion of the venous outflow. This can be a dramatic situation and may occur in the perioperative, immediate postoperative period, after the first postoperative week (25%) (Horton, 2008) or years after the transplant (Brosstoff, 2008). The incidence is rather low, 0.54-7%, but the mortality rate in such cases may be as high as 24% (Navarro, 1999; Nishida, 2006). The causes of outflow obstruction include inappropriate size of the hepatic anastomosis, malrotation or twisting of the anastomosis, direct compression of the graft, excessively tight sutures, and caval thrombosis. Late causes are likely secondary to intimal hyperplasia and fibrotic changes resulting in anastomotic stricture formation.

Hepatic venous outflow obstruction results in Budd-Chiari syndrome. The patient presents with, abdominal pain, weight gain, ascites, lower extremity edema, pleural effusion, hepatosplenomegaly, worsening hepatic function and eventually loss of the graft (Wang, 2005). A recurrent Budd-Chiari syndrome has been also described with an incidence as high as 27% (Horton, 2008). In these cases lifelong anticoagulation is recommended. A chronic outflow obstruction may occur after several weeks with massive ascites as main symptom (Parrilla, 1999).

In order to prevent this adverse event some modifications of the piggyback technique have been described in the last decades. One modification consists on a side-to-side anastomosis at the anterior face of the recipient cava (Belghiti, 1992). The incidence of Budd-Chiari syndrome is reported to be lower, 0.7% compared to 2.4% in the classic PB technique (Navarro, 1999) and 7 out of 500 cases in Meherabi series (Meherabi, 2009). Parrilla also

reported a decrease in the incidence from 1.6 to 0.28% when using a patch obtained by joining three instead of two hepatic veins when doing the anastomosis (Parrilla, 1999). The anastomosis performed, as previously described by the authors, is wide enough to allow a good flow and the liver is anchored securely.

After graft reperfusion the restoration of the venous return results in a sudden central volume overload that can cause pulmonary edema. A decrease greater of 50% in median arterial pressure for more than one minute is described as “reperfusion syndrome” and has been reported in 30% of cases (Figueras, 2001) and two cases out of 1361 transplants presented with hemodynamic shock on reperfusion (Navarro, 1999). The PB technique has been found to be associated with more pulmonary infiltrates (Isern, 2004), but this was not clinically relevant or statistically significant when compared with the classic technique (Gurusamy, 2011).

10. Treatment of complications of piggyback technique

Hemorrhagic complications during the anastomosis performance or in the early postoperative are usually well controlled. Tears, anastomotic bleeding, loose running sutures are repaired. However in some cases, new anastomosis or modifications must be done, as a new side-to-side cavo-caval reanastomosis. Special care must be taken in these situations since gaseous embolism and graft ischemia due to vascular clamping have been reported with negative consequences. (Navarro, 1999)

Intraoperative liver simple congestion due to outflow problems because of malrotation or excessive tension of the anastomosis for discrepancies in size of the graft might be resolved by accommodating the liver to recipient bed, suturing the falciform ligament to the diaphragm or even using breast prosthesis as the authors have used in a case with poor positional drainage (Fig. 10.).

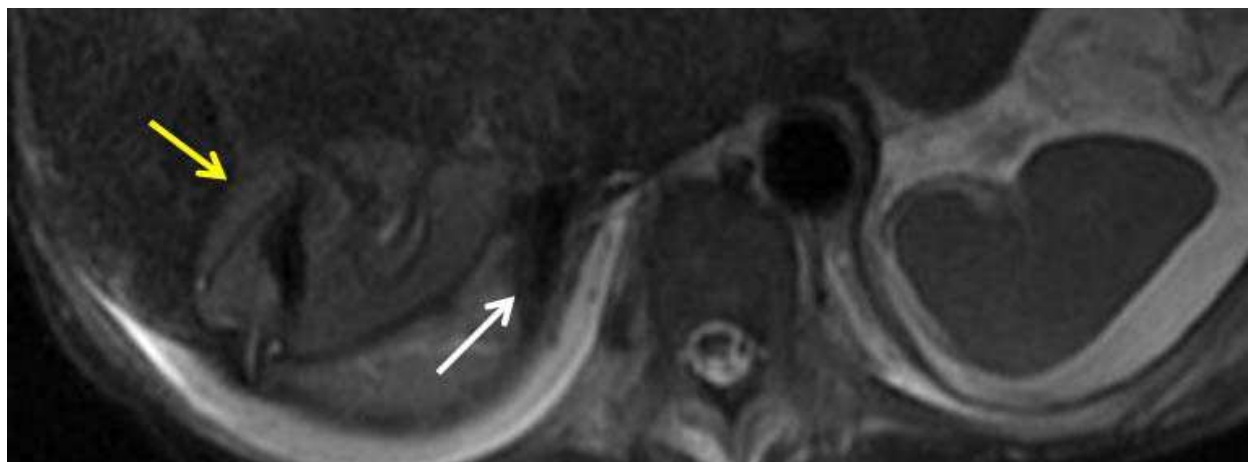


Fig. 10. Picture showing the breast prosthesis (yellow arrow) and the partially compromised caval flow (white arrow)

Treatment of Budd-Chiari syndrome varies from simple rotation of the graft to re-transplantation. Nevertheless, depending on the mode of onset of the syndrome the therapeutic procedure will vary. Acute presentation, in the first hours-days, will be more suitable for open surgery. This may involve re-anastomosis (with thrombectomy if

necessary), conversion to standard liver transplant technique or emergency retransplantation, if the graft is seriously injured. Also a “bridge” end-to-side anastomosis with infrahepatic caval stump (Stieberg, 1997) could be performed, as we had performed twice before this technical solution was reported (Fig. 11.).

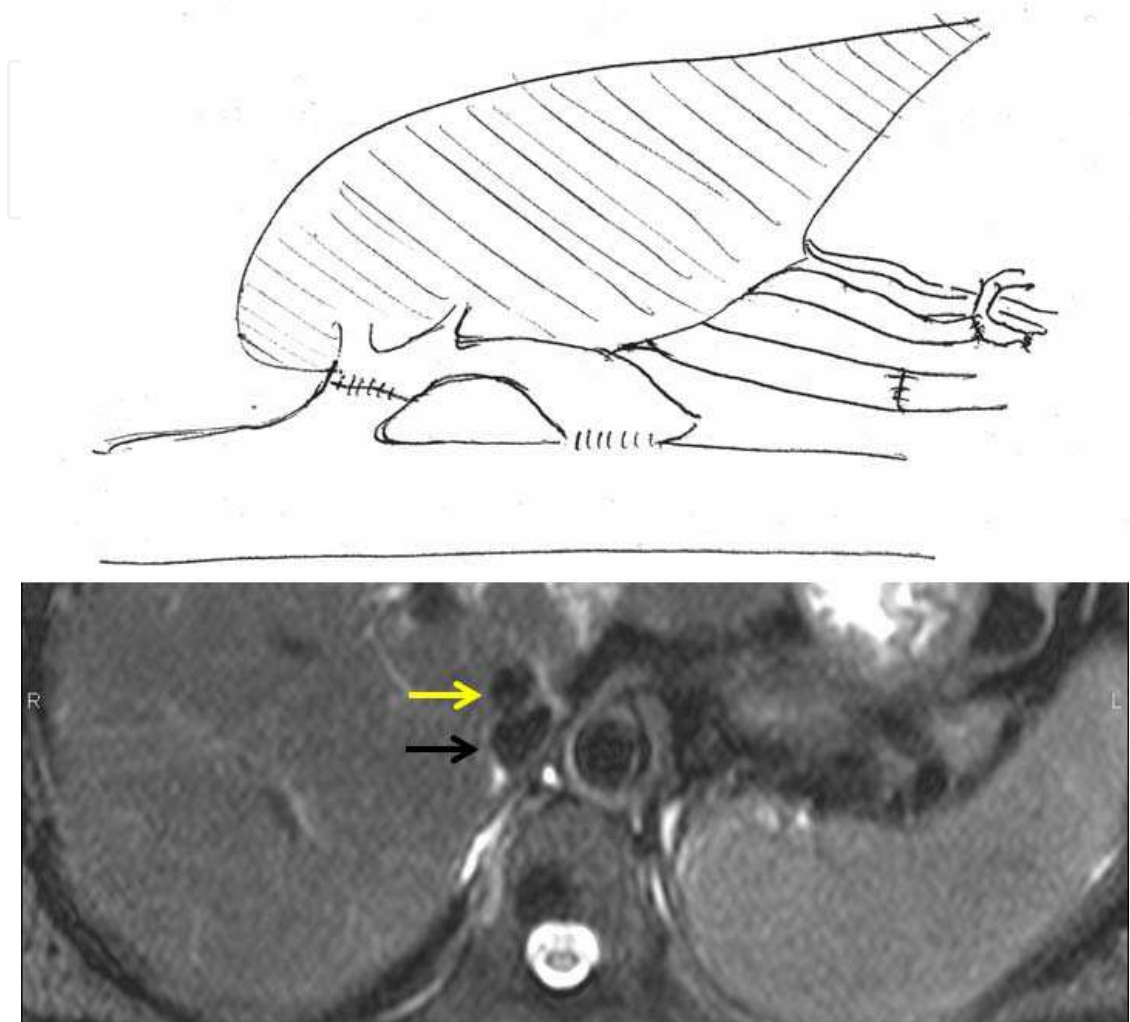


Fig. 11. Above: Drawing from operation report form of our first “bridge” case on November, 23th 1993. Below: Cholangio-NMR, 173 months after the transplant showing adequate flow through graft’s caval stump. Black arrow: Recipient’s cava. Yellow arrow: Graft’s caval stump, functioning as bridge flow (compare with Fig. 9. Image A)

In a later onset of the obstruction, or even in an acute phase, non-surgical approaches have been described. A variety of treatment options have been proved useful. Thrombolysis with streptokinase was successfully used in a caval thrombosis. Diuretics can be used to control late and chronic BCS that manifests as massive ascites (Parrilla, 1999). However, the most commonly reported non-surgical approach is endovascular stent placement and endoluminal anastomotic dilatation (venoplasty). In the setting of a scarring and fibrotic stenosis, the endovascular route represents a less invasive and less risky option (Sze, 1999) and 100% success rate has been reported. The only reported complication is stent migration. Balloon dilatation can be repeated, if single dilatation does not resolve the stenosis permanently.

Late diagnosis is the most important single factor that affects the outcome. Delayed diagnosis can lead to a hepatic failure that will in turn make the treatment ineffective. In fact the best way to treat outflow problems is to prevent its occurrence. The length of the upper IVC of the graft should be kept short to prevent kinking; the length of the anastomosis is also important to allow good venous outflow. In addition, when the anastomosis is constructed using two hepatic veins (middle and left) instead of the three hepatic veins, the incidence of intraoperative congestion and acute and chronic BCS are significantly higher 2.4% vs. 0.7% (Parrilla, 1999).

In summary, outflow obstructions related to PB technique must be rapidly addressed and resolved since the risks of liver failure and mortality are high. Surgical approach may be inevitable but less aggressive non-surgical measures can be also effective, even in the first postoperative days, with a fresh anastomosis (Wang, 2005)

11. Evolution of IVC preservation as the technique of choice for venous outflow drainage in the OLT

Since the first case of our transplantation program on November 1990, we have performed 503 orthotopic liver transplantations. Piggyback technique was performed in 502. The “classic” technique was performed in only one case with a huge liver due to polycystic disease.

Since 1994, there were no series in the literature supporting the routine use of the piggyback technique although it seemed to us that it could be routinely used in a safe way (G. Fleitas, 1994). Subsequently, larger series have demonstrated its utility (Parrilla, 1999), although the variability of the technique, mainly regarding to the venous outflow handling is very big.

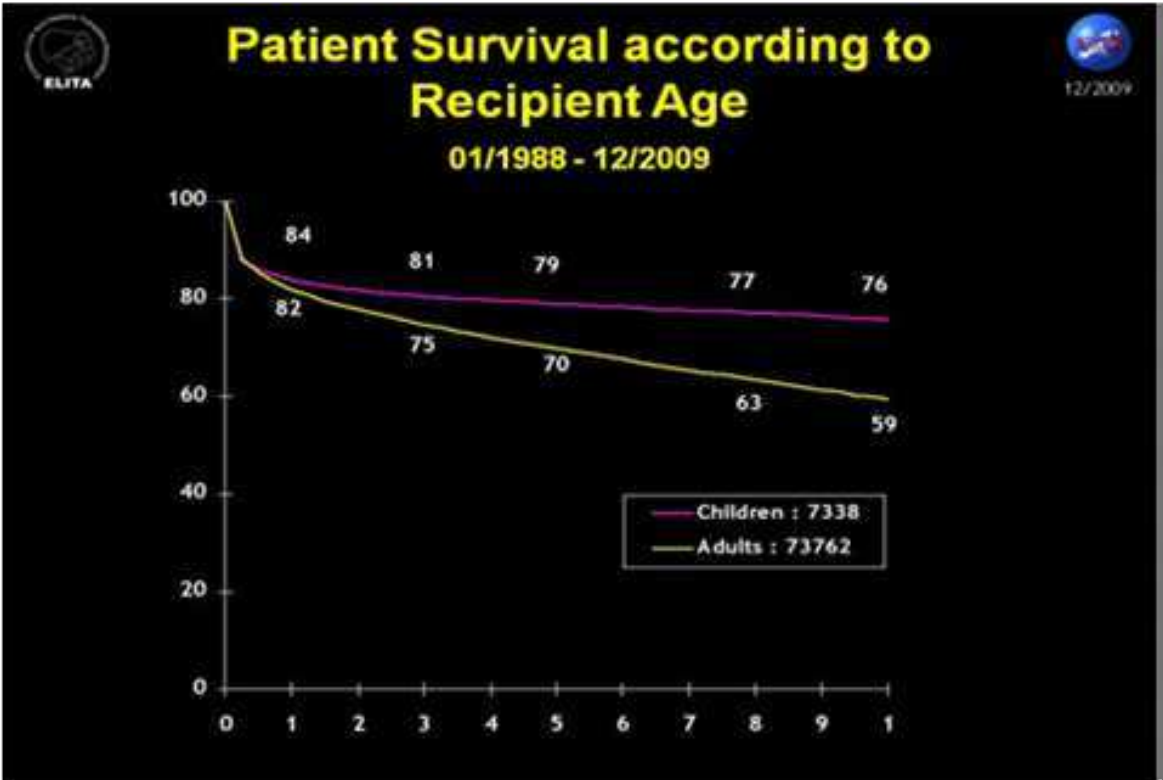


Fig. 12. European group patient survival (Source: European Liver Transplant Registry)

12. Valdecilla liver transplantation program

Our liver transplantation series started in November 1990, having already performed until 24 August 2011, 503 liver transplantations in adult patients (460 transplants, 41 retransplantations and 2 third transplantations). Their main characteristics are summarized in the following table, being similar to the other Spanish and European groups.

DONOR AGE n = 503	media (SD)	46.5 (18.8)
	median (Range)	47 (30-62)
RECEPTOR AGE n = 460	media (SD)	59 (11)
	median (Range)	65 (27-84)
INDICATIONS n = 503	OH related Cirrhosis	35.5%
	Virus Related Cirrhosis	22.25% (Ratio CVRC/BVRC = 8:1)
	Hepatocellular carcinoma	29.75%
	Fulminant Hepatitis	4.75%
	Others	7.75%
RE-TRANSPLANTATION	Normal Re-Transplantation	43 (8.54%)
	Urgent Re-Transplantation	5 (0.99%)

SD=Standard deviation; CVRC=C Virus Related Cirrhosis; BVRC=B Virus Related Cirrhosis

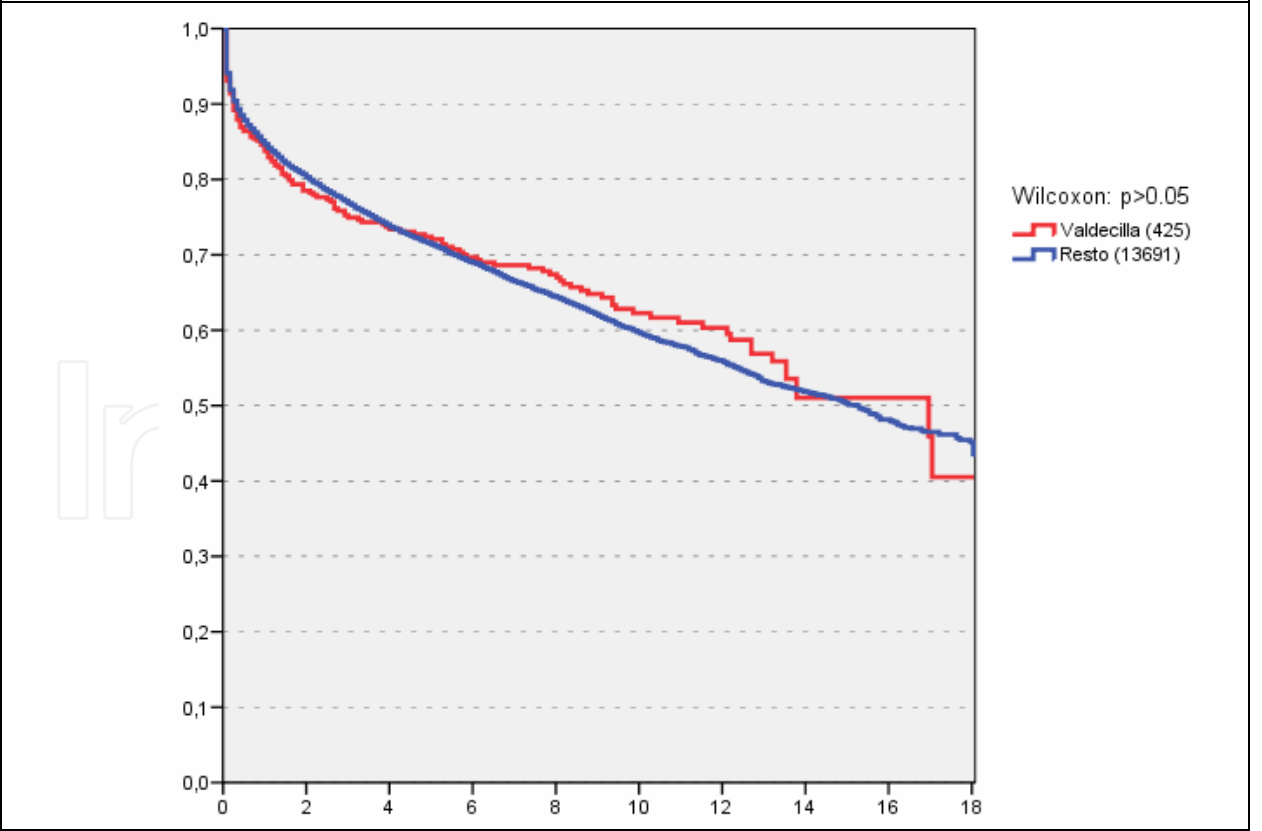


Table 1. Year survival rate comparing our series with the rest of the spanish liver transplant team (Source: Spanish Liver Transplant Registry; Dec. 2009). Resto=Others

In all cases of our series, the piggyback technique has been used, with the exception of one case of polycystosis and inflammatory adhesions at the retrohepatic IVC. There was a case of the “situs inversus”; the donor, graft implantation was made to the right hepatic vein of the recipient by making necessary the caudal cavotomy enlargement (Herrera, 1996). In five cases, “de novo” cavotomy was performed, because of hypoplasia or “malposition” of the hepatic veins.

CASE	PROBLEM	SOLUTION	RESULT	SURVIVAL
1º	Huge graft	Re Tx 48 h.	Alive	241 months
2º	Technical	Hanging liver and Re Tx	Dead	8 days
3º	Technical	Bridge	Alive	226 months
4º	Unknown	Bridge	Alive	221 months
5º	Huge graft	Re Tx	Alive	74 months
6º	Poor drain	Breast Prosthesis	Dead (HCC recurrence)	73 months
7º	Budd-Chiari	Endo-prosthesis cava	Dead	1 month

(Re Tx=Retransplantation; HCC=Hepatocellular carcinoma)

Table 2. Complications and mortality related to a bad drain of the graft in our series

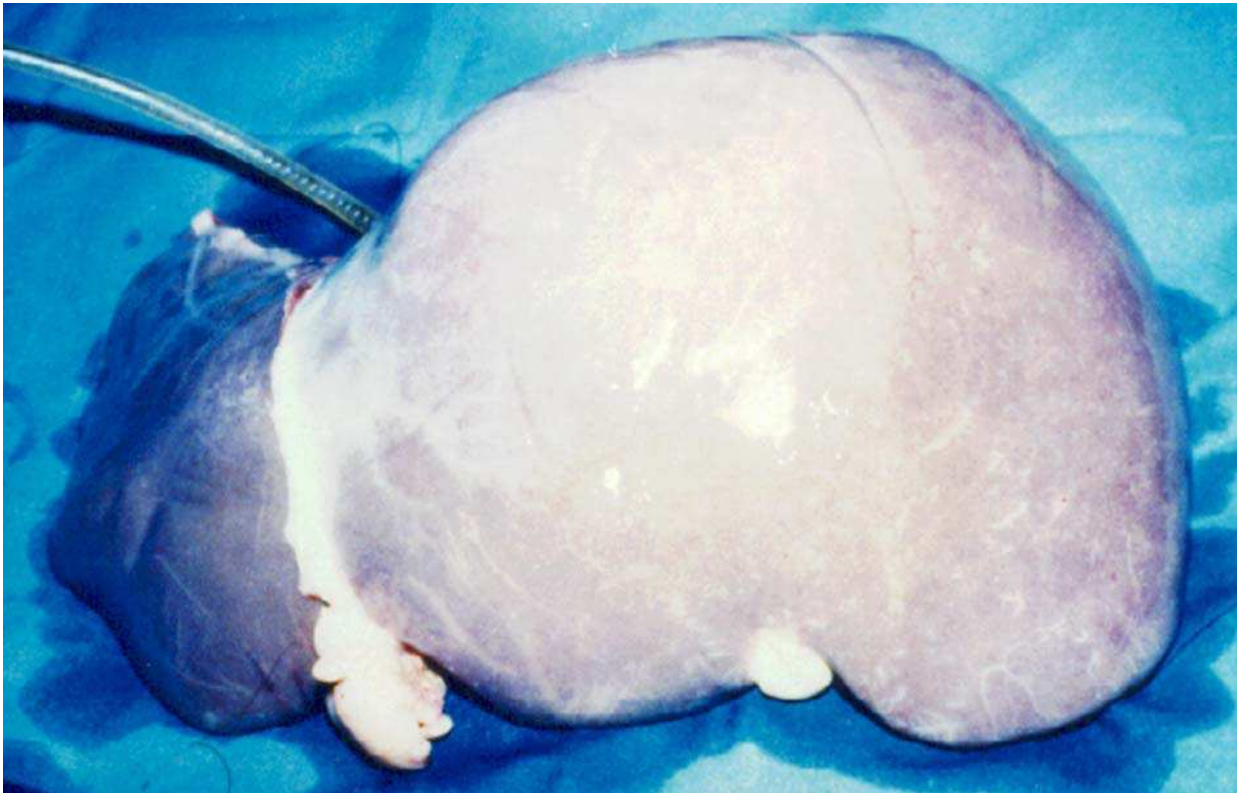

Fig. 13. Liver graft from a “situs inversus” donor

13. Conclusion

The main advantage of liver transplantation with caval preservation are of hemodynamic nature including, maintenance of the venous return to the heart during the procedure, thus

providing, considerable hemodynamic stability, and avoiding the use of the veno-venous bypass to keep a good infrarenal venous pressure that provides an adequate renal filtration (Casanova, 2002). The extended use of piggyback technique in liver transplantation is mainly due to its hemodynamic advantages (Moreno, 2003). It has allowed to the performance of liver transplantation without the need for temporary veno-venous bypass. Although controversial issues have been raised, the use of veno-venous bypass is related to the preferences in each institution (Fonouni, 2008) rather than to its advantages, for which there is no supporting evidence nowadays (Gurusamy, 2011). In addition, avoiding the use of veno-venous bypass, minimizes the coagulation problems that happen on the surface of the bypass tubings. Another important advantage of the Piggyback technique is the better exploitation of grafts that allows using smaller grafts, with the accompanying disparity in the size or with unfavorable anatomy, as the case in “situs inversus” donors (Herrera, 1996) (Fig. 13.).

14. Acknowledgment

The authors would like to thank the transplantation nursing team at our institution for their support and dedicated profession: Carmen García, M^a Eugenia Bustillo, M^a Antonia Barros, Laura Briones, Sagrario Espinosa, Concepción Fernández, M^a José Gómez, M^a Jesús Larrañaga, Guiomar Ortiz, Claribel Ortiz, M^a José Velasco and Isabel Villaverde.

15. References

- Abdel-Misih, R. & Bloomston, M. (2010). Liver anatomy. *Surg Clin North Am.*, Vol. 90, No. 4, (August 2010), pp. (643-53), ISSN 0039-6109
- Belghiti, J; Panis, Y; Sauvanet, A; Gayet, B. & Fékété, F. (1992). A new technique of side to side caval anastomosis during orthotopic hepatic transplantation without inferior vena caval occlusion. *Surg Gynecol Obstet*, Vol.175 No.3, (Sep 1992), pp. (270-2), ISSN 0039-6087
- Belghiti, J; Noun, R. & Sauvanet, A. (1995). Temporary portocaval anastomosis with preservation of caval flow during orthotopic liver transplantation. *Am J Surg*. Vol. 169, No. 2, (February 1995), pp. (277-9), ISSN 0002-9610
- Bilbao, J; Herrero, J; Martinez-Cuesta, A; Quiroga, J; Pueyo, J; Vivas, I; Delgado, C. & Pardo, F. (2000) Ascites due to anastomotic stenosis after liver transplantation using the piggyback technique: treatment with endovascular prosthesis. *Cardiovasc Intervent Radiol*, Vol. 23, No. 2, (March-April 2000), pp. (149-151), ISSN 0174-1551
- Brostoff, J; Bhati, C & Syn, W. (2008). Late venous outflow obstruction after liver transplant: The 'piggy-back' syndrome. *Eur J Intern Med*, Vol. 19, No. 5, (Jul 2008), pp. (374-6), ISSN 0953-6205
- Busque, S; Esquivel, C; Concepcion, W & So, S. (1998). Experience with the piggyback technique without caval occlusion in adult orthotopic liver transplantation. *Transplantation*, Vol. 65, No. 1, (Jan 1998), pp. (77-82), ISSN 0041-1337
- Calne, R. & Williams, R. (1968). Liver transplantation in man. I. Observations on technique and organization in five cases. *British Medical Journal*, Vol. 4, 1968, pp. (535-540), ISSN 0959 8138

- Calne, R. (2008) Early Days of Liver Transplantation. *American Journal of Transplantation*, Vol.8, No. 9, (September 2008), pp. (1775-1778), ISSN 1600-6135.
- Casanova, D; Rabanal, J; Solares, D; G.Fleitas, M; Martino, E; Herrera, L; Hernanz, F; Castillo, J; Rodriguez, J; Casanueva, J & Izquierdo, M. (2002) Inferior Vena Cava Preservation Technique in Orthotopic Liver Transplantation: Haemodynamic Advantages. *Transplantation Proceedings*, Vol. 34, No. 1 (February 2002), p. (259), ISSN 0041-1345
- Cecchis, L; Hribnik, M; Ravnik, D & Gadzijev, EM. (2000). Anatomical variations in the pattern of the right hepatic veins: possibilities for type classification. *J. Anat*, Vol.197, 2000, pp. (487-493), ISSN 0021-8782
- Cherqui, D; Lauzet, J; Rotman, N; Duvoux, C; Dhumeaux, D; Julien, M. & Fagniez, P. (1994). Orthotopic liver transplantation with preservation of the caval and portal flows. Technique and results in 62 cases. *Transplantation*, Vol. 58, No. 7, (October 1994), pp. (793-796), ISSN 0041-1337
- Cirera, I; Navasa, M; Rimola, A; Garcia-Pagan, JC; Grande, L; Garcia-Valdecasas, J; Fuster, J; Bosch, J. & Rodes, J. (2000). Ascites after liver transplantation. *Liver Transpl.*, Vol. 6 No. 2 (March 2000), pp. (157-162), ISSN 1525-6465
- Ducerf, C; Rode, A; Adham, M; De la Roche, E; Bizollon, T; Baulieux, J & Pouyet, M. (1996). Hepatic outflow study after piggyback liver transplantation. *Surgery*. Vol.120, No.3, (Sep 1996), pp. (484-7), ISSN 0039-6060
- Figueras, J; Llado, L; Ramos, E; Jaurrieta, E; Rafecas, A; Fabrega, J; Torras, J; Sabate, A. & Dalmau, A. (2001). Temporary portocaval shunt during liver transplantation with vena cava preservation. Results of a prospective randomized study. *Liver Transp*, Vol.7, No.10, (October 2001), pp. (904-11), ISSN 1527-6465
- Fonouni, H; Mehrabi, A; Soleimani, M; Mu" Ller, S; Bu" Chler, M & Schmidt, J. (2008). The need for venovenous bypass in liver transplantation. *HPB (Oxford)*, Vol.10, 2008, pp. (196-203), ISSN 1365-182X
- Ger R. (1989). Surgical anatomy of the liver. *Surg Clin North Am*, Vol.69, No.2 (April 1989), pp. 179-92, ISSN 0039-6109
- G.Fleitas, M; Casanova, D; Martino, E; Maestre, J; Herrera, L; Hernanz, F; Rabanal, J; Pulgar, S & Solares, G. (1994). Could the Piggyback Operation in Liver Transplantation Be Routinely Used? *Arch. Surg*, Vol.129, No. 1, (July 1994), pp. (842-845), ISSN 0004-0010
- Gurusamy, K; Pamecha, V. & Davidson B. (2011). Piggy-back graft for liver transplantation. *Cochrane Database Syst Rev*. Vol.19, No.1 (Jan 2011), ISSN 1469-493X (Electronic)
- Gurusamy, KS; Koti, R; Pamecha, V. & Davidson, BR. (2011) Veno-venous bypass versus none for liver transplantation. *Cochrane Database of Systematic Reviews* 2011, Issue 3. Art. No.: CD007712. DOI: 10.1002/14651858.CD007712.pub2. ISSN 1469-493X (Electronic)
- Herrera, L; Castillo, J; Martino, E; Rabanal, J & G.Fleitas, M (1996) Orthotopic liver transplantation from a donor with abdominal situs inversus. *Transplantation*, Vol.62, 1996 pp. (133-135), ISSN 0041-1337
- Horton, J; San Miguel, F; Membreno, F; Wright, F; Paima, J; Foster, P. & Ortiz, J. (2008). Budd-Chiari syndrome: illustrated review of current management. *Liver Int*, Vol.28, No.4, (Apr 2008), pp. (455-66), ISSN 1478-3223

- Hosseini, M; Osama, A; Bagous, W; Grewal, H; Hathaway, D; Vera, S; Stratta, R; Bagous, T. & Kizilisik T. (2000). Choice of surgical technique influences perioperative outcomes in liver transplantation. *Ann Surg*, Vol. 231, No.6, (Jun 2000), pp. (814-23), ISSN 0003-4932
- Isern, MR; Massarollo, PC; de Carvalho, EM; Vaía, C; Kavakama, J; de Andrade, P. & Mies, S. (2004). Randomized trial comparing pulmonary alterations after conventional with venovenous bypass versus piggyback liver transplantation. *Liver Transpl*, Vol.10, No.3, (Mar 2004), pp. (425-33), ISSN 1527-6465
- Khoury, G; Mann, M; Porot, M; Abdul-Rasool, I. & Busuttil, R. (1987). Air embolism associated with venovenous bypass during orthotopic liver transplantation. *Anesthesiology*, Vol. 67 No. 5, (November 1987), pp. (848-851), ISSN 0003-3022
- Khoury, G; Kaufman, R. & Musich, J. (1990). Hypothermia related to the use of veno-venous bypass during liver transplantation in man. *Eur J Anaesthesiol*. Vol. 7 No. 6 (November 1990) pp. (501-503), ISSN 0265-0215
- Lai, Q; Nudo, F; Molinaro, A; Mennini, G; Spoletini, G; Melandro, F; Guglielmo, N; Parlati, L; Mordenti, M; Ginanni, S; Berloco, PB & Rossi, M. (2011) Does caval reconstruction technique affect early graft function after liver transplantation? A preliminary analysis. *Transplantation Proceedings*, Vol.43, No.4, (May 2011), pp. (1103-6), ISSN 0041-1345
- Lázaro, J; Charco, R; Revhaug, A; Murio, E; Balsells, J; Hidalgo, E; Mora, A; Cortés, C & Margarit, C. (1997). Hemodynamics in human liver transplantation with inferior vena cava preservation. techniques *Transplantation Proceedings*, Vol.29, No. 7, (Nov 1997), pp. (2851-2), ISSN 0041-1345
- Mehrabi, A; Mood, ZA; Fonouni, H; Kashfi, A; Hillebrand, N; Müller, S; Encke, J; Büchler, M. & Schmidt J. (2009). A single-center experience of 500 liver transplants using the modified piggyback technique by Belghiti. *Liver Transpl*, Vol.15, No.5, (May 2009), pp. (466-74), ISSN 1527-6465
- Molmenti, P; Radtke, A; Sotiropoulos, C. & Malago, M. (2007). Anatomy and physiology of the liver. In: Shackelford's Surgery of the Alimentary Tract, 6th Ed., Yeo, C; Dempsey, D; Klein, A; Pemberton, J. & Peters, J. (Ed), pp. (1597-1610), Saunders Elsevier, ISSN 9781416023579, Philadelphia.
- Moore, F, Smith, L, Burnap, T, Dallenbach, F, Dammin, G, Gruber, U, Shoemaker, W, Steenburg, R, Ball, M. & Belko, J. (1959). One-stage homotransplantation of the liver following total hepatectomy in dogs. *Transpl Bull*, Vol.6, No.1, (Jan 1959), pp. (103-7), ISSN 0564-1217
- Moreno-Gonzalez, M; Meneu-Diaz, J; Fundora, Y; Ortega, P; Moreno, A; García I; Jimenez C, Loinaz, C.; Gomez, R. & Abradelo, M. (2003). Advantages of the Piggy Back Technique on Intraoperative Transfusion, Fluid Consumption, and Vasoactive Drugs Requirements in Liver Transplantation: A Comparative Study. *Transplantation Proceedings*, Vol.35, No.5, (August 2003) pp. (1918-9), ISSN 0041-1345
- National Institutes of Health Consensus Development Conference Statement: Liver transplantation—June 20-23, 1983. (1984) *Hepatology*, Vol.4, (1Suppl) pp. (107-110), ISSN 0270-9139


- Navarro, F; Le Moine, M; Fabre, J; Belghiti, J; Cherqui D; Adam, R; Pruvot, F; Letoublon, C. & Domergue J. (1999). Specific vascular complications of orthotopic liver transplantation with preservation of the retro hepatic vena cava: review of 1361 cases. *Transplantation*, Vol.68, No.5, (Sep 1999), pp. (646-50), ISSN 0041-1337
- Nishida, S; Nakamura, N; Vaidya, A; Levi, D; Kato, T; Nery, J; Madariaga, J; Molina, E; Ruiz, P; Gyamfi, A. & Tzakis A. (2006). Piggyback technique in adult liver transplantation: an analysis of 1067 liver transplants at a single center. *HPB (Oxford)*, Vol.8, No.3, 2006 pp. (182-8), ISSN 1365-182X
- Parrilla, P; Sánchez-Bueno, F; Figueras, J; Jaurrieta, E; Mir, J; Margarit, C; Lázaro, J; Herrera, L; G.Fleitas, M; Varo, E; Vicente, E; Robles, R & Ramirez, P. (1999). Analysis of the complications of the piggy-back technique in 1112 liver transplants. *Transplantation*, Vol.67, No.9, (May 1999), pp. (1214-7), ISSN 0041-133
- Sakai, T; Matsusaki, T; Marsh, J; Hilmi, I. & Planinsic, R. (2010). Comparison of surgical methods in liver transplantation: retro hepatic caval resection with venovenous bypass (VVB) versus piggyback (PB) with VVB versus PB without VVB. *Transpl Int*, Vol.23, No.12, (December 2010), pp. (1247-58), ISSN 0934-0874
- Stieber, C; Gordon D. & Bassi, N. (1997). A simple solution to a technical complication in "piggyback" liver transplantation. *Transplantation*, Vol.64, No.4, (August 1997), pp. (653-654), ISSN 0041-1337
- Shaw, B; Martin, D; Marquez, J; Kang, Y; Bugbee, A; Iwatsuki, S; Griffith, BP; Hardesty, R; Bahnson, H. & Starzl T. (1984), Venous bypass in clinical liver transplantation. *Ann Surg*, Vol. 200 No. 4, (October 1984) pp. (524-34), ISSN 0003-4932
- Starzl, T; Groth, C; Brettschneider, L; Penn, I; Fulginiti, V; Moon, J; Blanchard, H; Martin, A. & Porter, K. (1968). Orthotopic homotransplantation of the human liver. *Ann Surg*, Vol. 168 No. 3, (September 1968), pp. (392-415), ISSN 0003-4932
- Sze, DY; Semba, CP; Razavi, MK; Kee, ST; Dake, MD. (1999). Endovascular treatment of hepatic venous outflow obstruction after piggyback technique liver transplantation. *Transplantation*, Vol.68, No.3, (August 1999), pp. (446-9), ISSN 0041-1337
- Tayar, C; Kluger, M; Laurent, A. & Cherqui D. (2011). Optimizing Outflow in Piggyback Liver Transplantation Without Caval Occlusion: The Three-Vein Technique. *Liver Transpl.*, Vol. 17, No. 1, (January 2011), pp. (88-92), ISSN 1525-6465
- Tzakis A, Todo S & Starzl TE. (1989). Orthotopic liver transplantation with preservation of the inferior vena cava. *Ann Surg*, Vol.210, No. 5, (November 1989), pp. (649-652), ISSN 0003-4932
- United States, Task Force on Organ Transplantation. (1986). Organ transplantation: issues and recommendations: report of the Task Force on Organ Transplantation U.S. Dept. of Health & Human Services, Public Health Service, Health Resources and Services, Administration, Office of Organ Transplantation, April 1986, pp. 141-152.
- Veroli, P; El Hage, C. & Ecoffrey, C. (1992). Does adult liver transplantation without venovenous bypass result in renal failure? *Anesth Anal.*, Vol. 75, No. 4, (October 1992), pp. (489-494), ISSN 003-2999
- Vieira, P; Miranda, L; Batista, L; Neto, O; Amorim, A; Sabat, B; Candido, H; Adeodato, L; Lemos, R; Carvalho, G. & Lacerda, C. (2011). Orthotopic liver transplantation without venovenous bypass using the conventional and piggyback techniques

Transplantation Proceedings, Vol.43, No.4, (May 2011), pp. (1327-33), ISSN 0041-1345

Wang, SL; Sze, D; Busque, S; Razavi, M; Kee, S; Frisoli, J. & Dake, D.(2005). Treatment of hepatic venous outflow obstruction after piggyback liver transplantation. *Radiology*, Vol.236, No.1, (July 2005), pp. (352-9), ISSN 0033-8419

IntechOpen

IntechOpen



Liver Transplantation - Technical Issues and Complications

Edited by Prof. Hesham Abdeldayem

ISBN 978-953-51-0015-7

Hard cover, 454 pages

Publisher InTech

Published online 10, February, 2012

Published in print edition February, 2012

This book covers a wide spectrum of topics including, but not limited to, the technical issues in living and deceased donor liver transplant procedures, cell and experimental liver transplantation, and the complications of liver transplantation. Some of the very important topics, such as the arterial reconstruction in living donor liver transplantation, biliary complications, and the post-transplant-lymphoproliferative disorders (PTLD), have been covered in more than one chapter.

How to reference

In order to correctly reference this scholarly work, feel free to copy and paste the following:

Luis Herrera, Federico Castillo, Marcos Gomez, Gonzalo Gutierrez, Roberto F. Santiago, Juan Carlos R. Sanjuan, Elena G. Somacarrera, Antonio L. Useros, Monica G. Noriega, Fernando Casafont, Francisco Gonzalez and Manuel G. Fleitas (2012). The Routinely Use of “Piggyback” Technique in Adult Orthotopic Liver Transplantation, Liver Transplantation - Technical Issues and Complications, Prof. Hesham Abdeldayem (Ed.), ISBN: 978-953-51-0015-7, InTech, Available from: <http://www.intechopen.com/books/liver-transplantation-technical-issues-and-complications/the-routinely-use-of-piggyback-technique-in-adult-orthotopic-liver-transplantation>

INTECH
open science | open minds

InTech Europe

University Campus STeP Ri
Slavka Krautzeka 83/A
51000 Rijeka, Croatia
Phone: +385 (51) 770 447
Fax: +385 (51) 686 166
www.intechopen.com

InTech China

Unit 405, Office Block, Hotel Equatorial Shanghai
No.65, Yan An Road (West), Shanghai, 200040, China
中国上海市延安西路65号上海国际贵都大饭店办公楼405单元
Phone: +86-21-62489820
Fax: +86-21-62489821

© 2012 The Author(s). Licensee IntechOpen. This is an open access article distributed under the terms of the [Creative Commons Attribution 3.0 License](https://creativecommons.org/licenses/by/3.0/), which permits unrestricted use, distribution, and reproduction in any medium, provided the original work is properly cited.

IntechOpen

IntechOpen