

We are IntechOpen, the world's leading publisher of Open Access books Built by scientists, for scientists

6,900

Open access books available

186,000

International authors and editors

200M

Downloads

Our authors are among the

154

Countries delivered to

TOP 1%

most cited scientists

12.2%

Contributors from top 500 universities



WEB OF SCIENCE™

Selection of our books indexed in the Book Citation Index
in Web of Science™ Core Collection (BKCI)

Interested in publishing with us?
Contact book.department@intechopen.com

Numbers displayed above are based on latest data collected.
For more information visit www.intechopen.com



Stereotactic Radiosurgery for Pituitary Adenomas

Ricardo H. Brau and David Lozada

*University of Puerto Rico / Medical Sciences Campus/ Department of Surgery/
Neurosurgery Section
Puerto Rico*

1. Introduction

Stereotactic Radiosurgery (SRS) is a technology that utilizes externally generated ionizing radiation to treat (a) defined target(s) in the head or spine without the need to make an incision. The target is defined by high-resolution stereotactic imaging. It uses multiple convergent beams aimed to the target. The beams deliver a maximal dose to the target (with precision of less than 1mm), while minimizing irradiation of the surrounding tissues. The treatment is performed in a single session. The procedure requires a multidisciplinary team consisting of a neurosurgeon, radiation oncologist and medical physicist. Technologies that are used to perform SRS include linear accelerators, particle beam accelerators and multisource Cobalt 60 units. In order to enhance precision, various devices may incorporate robotics and real time digital imaging. (*Stereotactic Radiosurgery Task Force AANS/CNS/ASTRO, March 20, 2006*).

“Stereotactic Radiosurgery” was invented by the Swedish neurosurgeon Lars Leksell in 1951. Since its introduction, stereotactic radiosurgery (SRS) has evolved from an investigational concept into a recognized neurosurgical procedure for the management of a wide variety of brain disorders. Currently, radiosurgery can be employed as an adjuvant or definite treatment modality for pituitary adenomas.

The three major sources of radiation used today to perform SRS are the multi-source Cobalt 60 units, modified linear accelerators and the particle beam accelerators. These machines provide extremely accurate targeting and precise treatment for brain tumors. They treat brain tumors and other cerebral conditions in a one-day treatment. The original system is the Gamma Knife® System (GKS). Its clinical efficacy has been well documented, with more than 550,312 cases treated worldwide by December 2009 providing the data for over 2,500 publications in peer-reviewed medical literature. The GKS is ideal for tumors less than 3.5 cm, and functional disorders of the brain.

The modified linear accelerator (m-LINAC) based radiosurgery machines are prevalent throughout the world. The modified linear accelerator systems use similar principles as the GKS to treat the patient, but the source of the radiation is a linear accelerator. Modified Linear accelerator-based radiosurgery generally utilizes a stereotactic head-frame, floor-stand and a 6-megavolt (MV) linear accelerator. The linear accelerator systems utilize

radiation beams that are redirected in many "arcs" centered over an isocenter to lessen the adverse effects on healthy tissue. These machines can perform radiosurgery on tumors smaller than 3.5cm in diameter with the same range of precision of the GKS. Most of the GKS and m-LINAC systems employ a stereotactic head frame (ring). The head frame allows a precise localization of the lesion to be treated. The head frame, which is attached to the skull with four small screws, ensures that the radiation beams are precisely targeted. The frame also prevents head motion during the treatment procedure, which ensures that only the target area receives the prescribed radiation. However, modern localization techniques using bony landmarks identified by diagnostic X-Rays system has allowed some systems of m-LINAC to avoid the use of the stereotactic head frame. One of the advantages of these systems is that patients can be treated over more than one day without the need of wearing a head frame over extended periods of time, and in a few special situations can treat tumors slightly larger than 3.5 cm in diameter with this hypofractionating technique. Another advantage of the m-LINAC system is that they can use Intensity-Modulated Radiation Therapy (IMRT) and Image Guided Radiotherapy (IGRT) dosimetries algorithms to treat critically located lesions. In IMRT, the intensity of the radiation beam is non-uniform (i.e., modulated) across the treatment field, rather than producing a single, uniform, intensity beam. When combining this technique with the imaging done in the pre-plan, it further improves the delivery of radiation. These systems can provide treatment to lesions outside the brain.

A special type of m-LINAC is the CyberKnife® Robotic Radiosurgery System. It utilizes a 6 MV compact linear accelerator mounted on a computer-controlled six-axis robotic manipulator that permits a wide range of beam orientations and takes advantage of intelligent robotics to enable the effective treatment of tumors in the brain and anywhere in the body. To date, an estimated over 80,000 patients have been treated with the CyberKnife® System and currently more than 50 percent of all CyberKnife® procedures in the United States are extra cranial.

The proton beam radiosurgery systems employ a stream of protons to treat lesions. As of June 2011, there were a total of 37 proton therapy centers in Canada, China, England, France, Germany, Italy, Japan, Korea, Poland, Russia, South Africa, Sweden, Switzerland, and USA and more than 73,800 patients had been treated (Particle Therapy Co-Operative Group, 2011). One hindrance to universal use of the proton in cancer treatment is the size and cost of the cyclotron or synchrotron equipment necessary to produce the protons.

The authors have used a modified linear accelerator-based system to provide radiosurgery treatment to pituitary adenomas. The initial radiosurgery system installed in 1999 was manufactured by Radionics®. In 2003 this system was upgraded to a Brain Lab System® that incorporated a multileaf collimator.

2. The radiobiology of radiosurgery

The basic principle of ionizing radiation is the creation of ions or free radicals in the irradiated tissues. These ions or free radicals interact with the cell's molecules producing damage to them. The radiation dose is usually measured in grays, where one gray (Gy) is the absorption of one joule per kilogram of mass. These ions and radicals, which may be formed from the water and oxygen in the cell or from the tissue substance, can produce

irreparable damage to DNA, proteins, membranes, and lipids that can evolve into the cell's death. The radiation effects can be seen in the order of minutes to years (Figure 1).

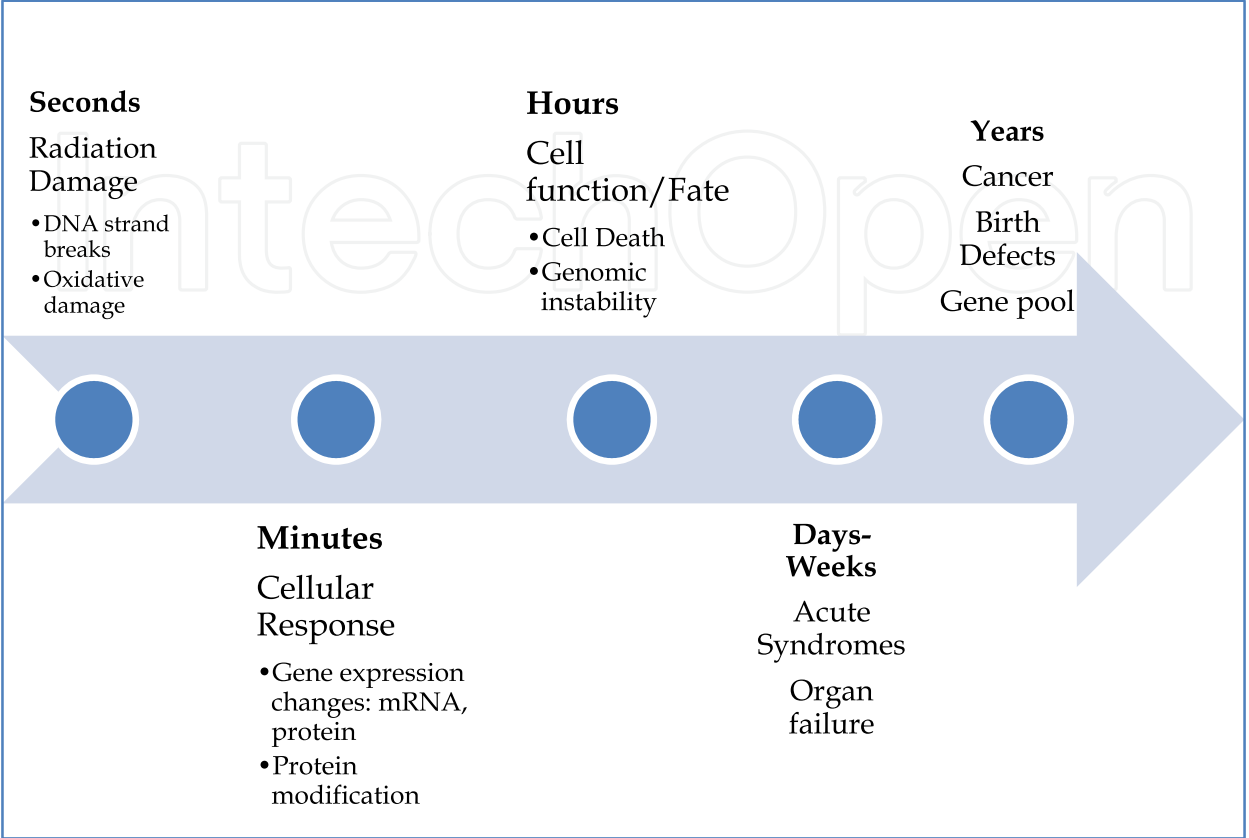


Fig. 1. Effects of Ionizing radiation over time.

Radiation damages the cell’s structures of tumor cells as well of normal cells in the radiation beam path. Normal tissue, however, is generally more proficient repairing sublethal damage than tumors cells. In general terms, tumors cells have altered repair mechanisms tolerating less irradiation damage than normal cells. Cells require time to repair DNA damage and one of the normal responses of the cell is delaying the cell cycle, delaying G2 phase. In radiotherapy where daily treatments with sublethal doses of radiation are given for several days, the difference in proficiency to repair the damage between normal and tumoral tissues is essential. Therefore, the radiobiology of the cell cycle and differences in cell repair are of great importance for fractionated radiotherapy. In radiosurgery, were a lethal dose of radiation is given in a single treatment, the repairing capacity of different tissues play a less critical role. Radiosurgery in many instances activates the apoptosis cascade resulting in cell death. The rate of proliferation of cells can determine the response to radiation, resulting in increased sensitivity of endothelial, glial and subependymal cells. Vascular endothelial cell damage tends to produce vessels obliteration that could play a role in the death of tumor cells as well.

The radiation doses prescribed for radiotherapy have been developed from decades of clinical experience. However, the radiobiological principles of multifraction treatments do not necessarily apply to high dose ionizing beams as used in radiosurgery. Radiosurgery specifies a precise delivery of a high single fraction dose of ionizing beams to a defined

target volume. Normal tissue is excluded from the target as much as possible and a steep dose gradient at the margin of the target volume assures that the surrounding tissue receives a minimal dosage. Therefore, repair capacity of normal tissue during treatment is less critical in radiosurgery.

3. Pituitary adenomas

Pituitary adenomas represent nearly 10-20% of all intracranial tumors. Multimodal treatment includes microsurgery, medical management, radiotherapy and radiosurgery. Pituitary adenomas are broadly classified into two groups—functioning (secretory) and nonfunctioning. Microsurgery is the primary recommendation for nonfunctioning and most of functioning adenomas, except for prolactinomas that are usually managed with dopamine agonist drugs. Long-term tumor control rates after microsurgery alone range from 50 to 80%. For both functioning and nonfunctioning pituitary adenomas, incomplete tumor resection or recurrence because of tumor invasion into surrounding structures (for example, the dura mater or cavernous sinus) is common. Postsurgical residual secretory adenoma results in the persistence of a hypersecretory state and the associated deleterious clinical features. Moreover, about 30% of patients require additional treatment after microsurgery for recurrent or residual tumors. In patients with recurrent or residual pituitary adenomas, treatment options include repeat resection, radiation therapy, medical management, and radiosurgery. More recently, radiosurgery has been established as a treatment option. Radiosurgery allows the delivery of prescribed dose with high precision strictly to the target and spares the surrounding tissues. Therefore, the risks of hypopituitarism, visual damage and vasculopathy are significantly lower. Furthermore, the latency of the radiation response after radiosurgery is substantially shorter than that of fractionated radiotherapy.

4. Planning and technique

All patients suspected of harboring a pituitary tumor should undergo a complete neurologic, ophthalmologic, endocrinologic, and radiologic work-up (Laws & Sheehan, 2006; Laws & Thapar 1996). This includes formal visual fields, an acuity testing and a detailed fundoscopic examination. Each facet of the hypothalamic-pituitary-end organ axis should be assessed by an endocrinologist and re-assessed by the neurosurgeon. (Table 1)

Evaluation of the sellar region is best accomplished by using a thin slice pre- and post-contrast magnetic resonance (MR) imaging. When there is a contraindication to MR or is not available, a computed tomography (CT) imaging can be useful (Jagannathan et al., 2005; Kanter et al., 2005).

If a patient has a neurological deficit attributable to an adenoma, surgery is the initial treatment of choice for all tumors except prolactinomas. Transsphenoidal microsurgery (endoscopic or microscopic) affords the best chance of rapid relief of mass effect and reduction in excessive hormone levels in patients with Cushing's disease and acromegaly (Laws & Sheehan, 2006; Laws & Thapar 1996; Laws et al., 1985a, 1985b, 2000). This approach is associated with a low rate of complications in the hands of experienced neurosurgeons (Ciric, 1997). For this reason, tumors located in areas such as the sellar floor or sphenoid that can be safely accessed surgically should undergo surgical removal, with radiosurgery being

reserved for tumor residuals or recurrences. For tumors that cannot be removed completely depending on the size, location, and invasiveness of surrounding tissues by the tumor, one surgical goal could be to create a safe distance of 2 to 5 mm between the lesion and optic apparatus so that an adequate radiosurgery dose can be delivered to the adenoma with minimal risk of radiation injury to the optic pathways.

Hormone	Test	Results and Additional Evaluations
Prolactin function	Serum Levels	Elevated prolactin, usually with serum levels > 75 ng/ml
Thyroid function	Free thyroxine and thyroid stimulating hormone	
Adrenal function	Morning fasting and afternoon serum cortisol and ACTH level. Salivary cortisol levels.	In Cushing’s syndrome, a 24 h urine free cortisol and a dexamethasone suppression test.
Growth Hormone (GH)	Growth hormone and insulin-like growth factor (IGF)-1.	Oral glucose tolerance test with growth hormone measurements for GH secreting tumors.

Table 1. Minimal basic endocrine workup for pituitary adenomas.

Patients harboring secretory pituitary tumors warrant a special consideration regarding radiosurgery pre-planning. Since 2000, several studies have documented that cessation of suppressive medication before radiosurgery is recommended to offer the best normalization of hormone values after the treatment (Landolt 2000a, 2000b; Pouratian et al., 2006; Pollock et al., 2007). The optimal time period to temporarily halt anti-secretory medications is unclear and class I evidence is still unavailable to support temporary cessation of antiseactory medications as a standard of care.

5. Radiosurgery procedure

When medical and surgical treatments are not curative or cannot control the tumor growth or symptoms, radiosurgery needs to be considered. Prior to considering radiosurgery, the neurosurgeon and the radiation oncologist of the radiosurgery team evaluate the patient, both need to agree that radiosurgery is an optimal option. Then, the patient is scheduled for the procedure. On the day of the treatment or the day before, a MR study is obtained, with 3 mm thick slices of the brain including the sella and skull base. On the day of treatment a stereotactic head frame is applied under local anesthesia and/or IV sedation. Subsequently, stereotactic CT scanning is performed with the CT scan localizer on. Three-millimeter thick slices are obtained throughout the entire head. The stereotactic CT scan and MR images are transferred to the treatment-planning computer. The CT scan and MR images are fused electronically. The tumor, optic apparatus and critical surrounding structures are delineated in the planning computer. (Figure 2) The plan is carefully examined and adjusted to generate the actual treatment plan, maximizing the dose delivery to the tumor and minimizing irradiation of the optic apparatus and the surrounding tissues.

The radiation oncologist and the neurosurgeon review and approve the plan. Four or more sagittally oriented irradiation arcs are typically delivered using multileaf collimators. The

multileaf collimator is adjusted every 15 degrees to achieve a conformal treatment to the lesion. The head ring is removed on the same day of treatment. After a short observation period, the patient is discharged. Close clinical and radiological neuroimaging follow-up examination is arranged at appropriate intervals depending on the entity treated and the condition of the patient.

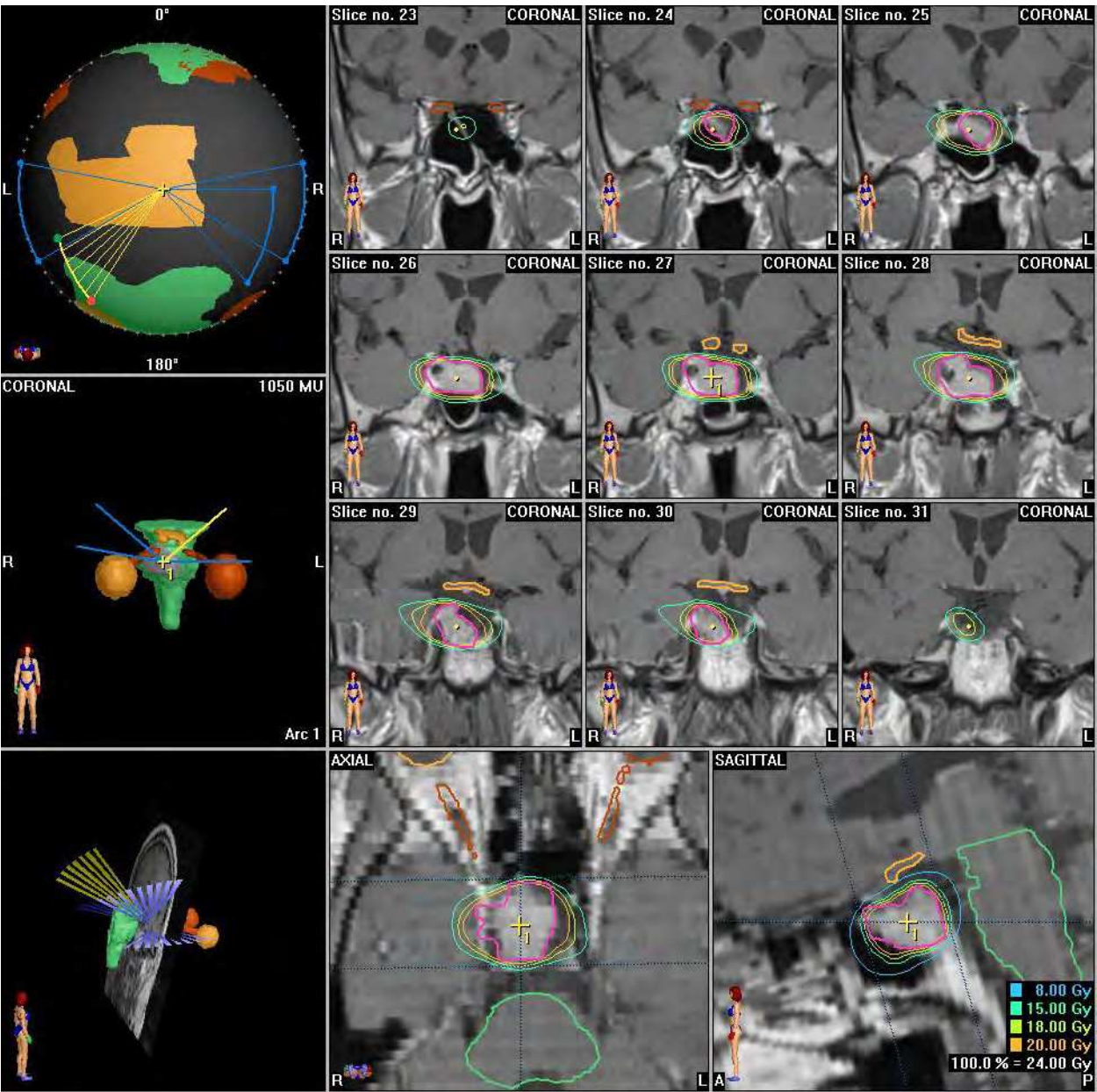


Fig. 2. Radiosurgical planning which includes protection of important structures and inclusion of treatment area.

6. Toxicity and side effects

Like any other medical intervention radiosurgery has side effects. The main concern is radionecrosis of structures adjacent to the pituitary gland; optic apparatus, cranial nerves within the cavernous sinus, hypothalamus, brainstem and medial temporal lobes. The

toxicity of fractionated external beam radiotherapy is low; with 1.5% risk of radiation optic neuropathy (Brada et al., 1993; Tsang et al., 1994) and 0.2% risk of necrosis of normal brain structures (Becker et al., 2002). The most frequent late consequence of radiation is hypopituitarism likely to be primarily due to hypothalamic injury or primary pituitary gland injury. In patients with normal pituitary function around the time of radiotherapy, hormone replacement therapy is required in 20–40% of patients at 10 years. A rare late effect of radiation for pituitary adenoma is the development of second radiation-induced brain tumor. The reported frequency is in the region of 2% at 10–20 years (Brada et al., 1992; Tsang et al., 1993; Erfurth et al., 2001). Although there is an increased incidence of cerebrovascular accidents and excess cerebrovascular mortality in patients with pituitary adenoma treated with radiation, the influence of radiation on its frequency is not well defined (Brada et al., 1999, 2002; Tomlinson et al., 2001; Erfurth et al., 2002).

The radiation effects on the optic apparatus, other cranial nerves and brainstem are of critical importance. Most of the damage is thought to be a result of secondary damage of the endothelium of small vessels and protective Schwann cells or oligodendroglia. There is a difference in the tolerance of different cranial nerves; with sensory nerves (optic and acoustic) tolerating the least radiation. The nerves in the parasellar region, the facial nerves and the lower cranial nerves usually tolerate higher doses. Clinical experience suggests that these specialized sensory nerves do not show a great capacity to recover from injury. Although the precise dose tolerance of the cranial nerves is unclear, the anterior visual pathways seem to be the least radio-resistant, and single doses above 8 Gy should be avoided (Jagannathan et al., 2007; Leber et al., 1995, 1998). To minimize the risk of irradiation injuries to the optic apparatus, the distance between optic nerves and chiasm and the lesion being treated should be carefully assessed. A distance of 5 mm between the tumor and the optic apparatus is ideal, but a distance of as little as 2 mm may be acceptable. It appears that the risk may be related to the volume of the optic apparatus receiving the dose (Chen et al., 2001; Lim et al., 1998; Sheehan et al., 2000; Witt et al., 1998). However, a specific critical volume has not been agreed. This distance is critical to design a dose plan that delivers a lethal radiation dose to the tumor yet spare the optic apparatus. When all these precautions and considerations are taken care the patient is treated accordingly.

7. Radiosurgery for pituitary adenomas

The goals of radiosurgery for pituitary tumors are control of tumor growth, and in secretory adenomas to normalize hormonal hypersecretion. In addition to the above mention, these goals need to be carried out avoiding acute and delay radiation injury to neural structures and preventing secondary tumor formation.

7.1 Non-secreting tumors

In our experience of twelve patients treated for nonfunctioning pituitary tumors (with mean follow-up of 47 months), tumor volume decreased in three patients (25%), remained unchanged in eight (66%), and there was no increased in size. One patient was lost to follow-up. Regarding tumor control, eleven patients achieved tumor control (91%) except for the patient who was lost to follow-up. All of our patients were treated with LINAC Radiosurgery as secondary therapy. The average prescription peripheral dose (Gy) was 15.8Gy with a range from 8 to 22.5Gy. This is similar to previously published data. The

median time of tumor shrinkage on MR-imaging was 12 months (range, 8-68 months) following radiosurgery. This is consistent with a recently published series that demonstrated pituitary adenomas were 90%, 80%, and 70% of their initial volume at 1, 2, and 3 years post-GK radiosurgery (Sheehan et al., 2002). Tumors involving the parasellar space require special consideration, as they would be otherwise untreatable.

Most other contemporary series involving stereotactic radiosurgery for non-functioning tumors (Table 2) have demonstrated excellent control of tumor growth, with a mean tumor control rate of 95.6% (range, 87%–100%) (Hayashi et al., 1999; Losa et al., 2004; Mitsumori et al., 1998; Morky et al., 1999; Muramatsu et al., 2003; Pollock & Carpenter, 2003; Pollock et al., 2008; Sheehan et al., 2002; Witt et al., 1998;).

In patients with four or more years of follow-up, the reported mean control rate is 95% (range, 83–100%) (Yoon et al., 1998; Morky et al., 1999; Feigl et al., 2002; Hoybye et al., 2001; Ikeda et al., 2001; Kobayashi et al., 2002; Shin et al., 2000; Wowra et al., 2002). Some series have even demonstrated improvement in visual function following radiosurgery after shrinkage of the tumor (Abe et al., 2002; Chen et al., 2001; Hayashi et al., 2005; Yoon et al., 1998). Nevertheless, prevention of tumor growth, without volume reduction, is still considered a radiosurgical goal.

The CyberKnife (Accuray, Calif., USA), is a newer radiosurgical device that is mounted on a maneuverable robotic manipulator and tracks the target with the aid of real-time guidance (Adler et al., 1997; Chang et al., 1998). Early experience with the Cyberknife has been promising for nonfunctioning adenomas, with a growth control rate of 95%, and lower prescription doses (14–16 Gy) than described for the Gamma Knife, although long-term clinical follow-up is still lacking (Kajiwara et al., 2005).

Authors and Year	Radiosurgery Unit	No. of Patients	Mean/Median FU (months)	Max Dose (Gy)	Tumor Margin Dose(Gy)	Growth Control (%)
Mitsumori, et al., 1998	LINAC	7	47	19	15	100
Witt, et al., 1998	GK	24	32	38	19	94
Yoon, et al., 1998	LINAC	8	49	21	17	96
Hayashi, et al., 1999	GK	18	16	NR	20	92
Mokry, et al., 1999	GK	31	21	28	14	98
Sheehan, et al., 2002	GK	42	31	32	16	98
Muramatsu, et al., 2003	LINAC	8	30	26.9	15	100
Pollock & Carpenter, 2003	GK	33	43	36	16	97
Losa, et al., 2004	GK	54	41	33	17	96
Iwai 2004	GK	34	60		14	87
Mingione 2006	GK	90	45		18.5	92
Pollock 2008	GK	62	45		16	97
Brau 2011*	LINAC	12	47	21.7	15.8	91

Table 2. Summary of cases treated with Radiosurgery on Non-functioning pituitary adenomas. (*Unpublished manuscript in writing)

7.2 Secretory tumors

Most published results on radiosurgery for secretory adenomas have differed based on methodology, endocrine criteria for remission, the study population and length of follow-up. Most series typically report a higher prescription (margin) dose to patients with functioning adenomas, with a range between 20 Gy and 25 Gy in most reports (Jagannathan et al., 2007; Kim et al., 1999a, 1999b; Pouratian et al., 2006). Because hormone normalization has been followed in some cases by relapse, we prefer the term “remission” to “cure.”

7.2.1 Acromegaly

In our experience of fifteen patients treated for acromegaly (with mean follow-up of 37.2 months), tumor volume decreased in five patients (33.3%), remained unchanged in nine (60%), and there was one (6.6%) patient that showed an increase in tumor size. Tumor control was achieved in fourteen (93.3%) patients. All of our patients were treated with LINAC Radiosurgery as secondary therapy. The average prescription peripheral dose (Gy) was 19.4Gy with a range from 12 to 25Gy. In our experience, the rate of hormone normalization after radiosurgery for Acromegaly was seen in six (41.6%) patients. Hormone normalization in these five patients was observed at mean follow-up of 28 months. Tumor control was achieved in most patients correlating with hormone remission, except for one patient, which despite hormone remission there was a slight increase in tumor size.

The most widely accepted guidelines for endocrine remission in acromegaly consist of a GH level less than 1 ng/ml in response to an oral glucose challenge and a normal serum IGF-1 when matched for age [Giustina et al., 2000; Vance, 1998].

Published remission rates following radiosurgery for acromegaly vary widely from 0% to 100%, with the majority of patients achieving tumor growth control (Table 3) (Buchfelder et al., 1991; Cozzi et al., 2001; Freda, 2003; Fukuoka et al., 2001; Horvath et al., 1983; Landolt et al., 1998, 2000; Pouratian et al., 2006; Witt et al., 1998). Jezkova et al. reported a remission rate of 50% at 42 months follow-up in 96 patients with acromegaly who received

Author and Year	RSx Unit	Pt No	F/U (mos)	Peripheral Dose (Gy)	IGF-1 Normalization (%)	Tumor Control (%)
Muramatsu, 2003	LINAC	4	30	15	50	100
Attanasio 2003	GK	30	46	20	23	100
Castinetti 2005	GK	82	49.5	12-40	40	NR
Voges 2006	LINAC	64	54.3	15.3	49.8	97
Jezkova 2007	GK	96	53.7	32	50	100
Pollock 2007	GK	46	63	20	50	100
Vik-Mo 2007	GK	53	66	26.5	58	89
Losa 2008	GK	83	69	21.5	60.2	98
Jagannathan 2008	GK	95	57	22	53	98
Brau 2011*	LINAC	15	37.2	19.4	41.6	93.3

Table 3. Summary of cases treated with Radiosurgery for Acromegaly. (*Unpublished manuscript in writing)

radiosurgery (Jezkova et al., 2006). Nearly one-third of these patients, however, had radiosurgery as primary treatment, without surgical extirpation of the adenoma. Pollock et al., (2007) demonstrated a remission rate of 50% in 46 patients with a higher remission rate in patients who were off suppressive medications at the time of radiosurgery. Pollock’s group also stated that maximal radiosurgery effects may be delayed up to 5 years after treatment, therefore no other surgical treatment or additional radiosurgery should be considered within that period unless there is unequivocal evidence of tumor enlargement and progressive elevation of HGH and ILGF-1.

7.2.2 Cushing’s disease

Cushing’s disease is one of the most devastating pituitary disorders, and is associated with significant morbidity and premature death. Even after transsphenoidal surgery, up to 30% of patients may have persistent or recurrent disease (Ciric et al., 1997; Laws & Thapar, 1996; Mampalam et al., 1988). Most centers define an endocrine remission as a urine free-cortisol (UFC) level in the normal range associated with the resolution of clinical stigmata or a series of normal post-operative serum cortisol levels obtained throughout the day (Nieman, 2002; Sheehan et al., 2000). We have treated ten patients with Cushing’s disease, with 40% of patients achieving normalization of hormones levels with a mean margin dose of 20.7Gy. The rate of remission statistically correlated with tumor volume, but not with tumor invasion into the cavernous sinus or the suprasellar region.

In our experience, the rate of hormone normalization after radiosurgery for Cushing’s disease is difficult to predict, with remission occurring as early as 17months and as late as five years after LINAC Radiosurgery. Most patients who have remission, however, will do so within the first 2-3 years following radiosurgery. Patients with persistent disease should thus consider alternative treatments such as repeat TSS, or repeat radiosurgery (although this may be associated with a higher rate of cranial nerve damage) (Jagannathan et al., 2007).

Published endocrine remission rates following radiosurgery (Table 4) vary considerably, from 10% to 100%, with higher remission rates when radiosurgery follows surgical debulking (Arnaldi et al., 2003; Chu et al., 2001; Izawa et al., 2000; Jackson & Noren, 1999;

Author and Year	RSx Unit	Pt No	F/U (mos)	Peripheral Dose (Gy)	Hormone Normalization (%)	Tumor Control (%)
Laws 1999	LINAC	50	---	22	58	---
Izawa 2000	GK	12	28	22	17	94
Sheehan 2000	GK	43	44	20	63	100
Hoybye 2001	LINAC	18	204	---	83	83
Kobayashi 2003	---	20	64	29	35	100
Devin 2004	GK	35	42	15	49	91
Castinetti 2007	GK	40	55	29.5	42	100
Jagannathan 2007	GK	90	45	25	42	100
Brau 2011*	LINAC	10	50	20.7	40	90

Table 4. Summary of cases involving Radiosurgery in patients with Cushing’s disease. (*Unpublished manuscript in writing)

Jagannathan et al., 2007; Kobayashi et al., 2002; Morange-Ramos et al., 1998; Petrovich et al., 2003; Witt et al., 1998). In series with at least ten patients and a median follow-up of 2 years, endocrine remission rates range from 17% to 83% (Kobayashi et al., 2002; Mahmoud-Ahmed & Suh, 2002; Morange-Ramos et al., 1998, Petrovich et al., 2003). Rähn and associates (Flickenger et al., 1992) reported their experience at the Karolinska Institute involving 59 patients with Cushing’s disease who were treated using the Gamma Knife and followed for 2–15 years. The efficacy rate of the initial treatment was 50%, with retreatment eventually providing normalization of cortisol production in 76% of patients (Rahn et al, 1980).

7.2.3 Prolactin-secreting adenomas

We use radiosurgery as a treatment for prolactinomas after failure of medical and/or surgical treatment. Ideally most of the prolactinomas should be treated with medication. Prolactinomas tumor control with medications has been reported around 80-90% (Ferone et al., 2007). Despite having good control, some patients do not tolerate the medications due to side effects and other turnout to be allergic to it.

In our series two patients were treated as primary therapy for medical reasons. Most of the patients were treated following microsurgery. Of the seven patients treated at our institution, complete normalization of prolactin levels occurred in only 14.2%, at an average time of 22 months, with a mean prescription dose of 18.7Gy. Tumor control was achieved in 100% of the cases, but did not correlate with hormone remission.

In published studies of radiosurgery for prolactinomas, the mean prescription dose has varied from 13.3 Gy to 33 Gy, and remission rates varied from 0% to 84% (Table 5) (Kim et al., 1999, 2007; Landolt & Lomax, 2000; Laws & Vance, 1999; Post & Habas, 1990; Pouratian et al., 2006; Yildiz et al., 1999). Variations in success rate are likely related to the dose delivered to the tumor as well as other factors. Witt et al. noted no remissions with a prescription dose of 19 Gy (Witt et al., 1998; Witt, 2003). Pan et al. (Pan et al., 2000) reported a 52% endocrine “cure” rate in a retrospective study of 128 patients in whom GKRS was used as first-line treatment for prolactinomas with a prescription dose of 30 Gy. This study is on a large sample size, and is interesting in that GKRS was used as a first-line treatment before medical therapy.

Author and Year	RSx Unit	Pt No	F/U (mos)	Peripheral Dose (Gy)	Hormone Normalization (%)	Tumor Control (%)
Mitsumori 1998	LINAC	4	47	15	0	100
Yoon 1998	LINAC	11	49	17	84	96
Mokry 1999	GK	21	31	14	21	NR
Pan 2000	GK	128	33	31.5	52	98.4
Choi 2003	GK	21	42.5	28.5	24	100
Muramatsu 2003	LINAC	1	30	15	0	100
Pouratian 2006	GK	23	58	18.6	24	89
Brau 2011*	LINAC	7	35.7	18.7	14.2	100

Table 5. Summary of cases involving Radiosurgery in patients with prolactinomas.
(*Unpublished manuscript in writing)

7.2.4 Nelson’s syndrome

Compared with nonfunctioning and other functioning pituitary adenomas, much less information is available about the efficacy of stereotactic radiosurgery for the treatment of Nelson syndrome. A subset of Cushing’s patients do not achieve hormone normalization following microsurgery and radiosurgery, and undergo adrenalectomy as a “salvage” treatment for their disease. Although adrenalectomy is the definitive treatment for cortisol overproduction, a subset of patients may develop Nelson’s syndrome, characterized by rapid adenoma growth, hyper-pigmentation and tumor invasion into the parasellar structures (Nagesser et al., 2000). This is thought to be related to the lack of feedback on the hypothalamus and the pituitary gland by the lack of cortisol.

Author and Year	RSx Unit	Pt No	F/U (mos)	Peripheral Dose (Gy)	Hormone Normalization (%)	Tumor Control (%)
Ganz 1993	GKS	3	18	NR	0	100
Wolffenbittel 1998	GKS	1	33	12	0	100
Kobayashi 2002	GKS	6	63	28.7	33	100
Pollock 2002	GKS	11	37	20	24	82
Vogues 2006	LINAC	9	63/47a	15.3	16.7	89
Mauerman 2007	GKS	23	20/50a	25	17/60b	91

Table 6. Endocrine and radiographic outcomes of GKRS for Nelson’s syndrome. (a) Mean imaging follow-up/mean endocrine follow-up (b)ACTH levels decreased/ ACTH reduced to normal values (50 pg/ml)

Pollock and Young reported on 11 patients who underwent GKRS for Nelson’s syndrome. They reported control of tumor growth in 9 of 11 patients, with ACTH normalization in four patients (36%) (Pollock & Young, 2002).

There are relatively few studies detailing the results of radiosurgery for Nelson’s syndrome (Table 6) (Ganz, 2000; Ganz et al., 1993; Kobayashi et al., 2002; Laws & Vance, 1999; Levy et al., 1991; Mauermann et al., 2007; Pollock & Wolffenbittel et al., 1998; Young, 2002). These studies report a mean tumor dose from between 12 Gy to 28.7 Gy, and an endocrine remission rate ranging from 0% to 36%, although only a minority of these studies defined what was meant by endocrine remission. Even cases where endocrine remission was not achieved, tumor growth control rates were favorable, ranging from 82% to 100%.

8. Complications following radiosurgery for pituitary adenomas

As previously stated, the most common problem after radiosurgery is development of hypopituitarism. Several groups have reported a low incidence (0–36%) of pituitary dysfunction following radiosurgery (Jagannathan et al., 2007; Jane et al., 2003; Sheehan et al., 2006; Pollock et al., 1994). This incidence is likely higher when patients are followed long-term, with the Karolinska Institute reporting a 72% incidence of hypopituitarism when patients were followed over 10 years (Hoybye et al., 2001). We have observed an overall risk of 20–30% for development of new hormone deficiency following radiosurgery without a significant difference across tumor pathologies. Recent studies using the Cyberknife for secretory adenomas, points to a significantly lower (9.5%) rate of endocrinopathy, although

these studies are limited by follow-up of 12 months and less in some cases (Adler et al., 2006; Kajiwarra et al., 2005; Pham et al., 2004).

Ultimately, total dose prescribed and the prescription (margin) doses are likely the major factors determining the risk and onset of radiation induced hypopituitarism. The sequence of hormone loss following pituitary radiosurgery is unknown. The difficulty with determining the exact incidence of radiosurgery-induced hypopituitarism stems in part from the fact that many of the patients have previously undergone resection and some fractionated radiotherapy. In addition, pituitary deficiencies may result in part from aging. Thus, it is likely that hypopituitarism in the post-radiosurgical population is multifactorial in cause and related to radiosurgery as well as age-related changes and previous treatments (for example, microsurgery and radiotherapy). In spite of this, however, some have argued that the GH axis is the most sensitive to the late effects of radiation, with the radiation induced defect likely occurring at the hypothalamic level (Blacklay et al., 1986; Shalet, 1993). The gonadotropin and corticotrophin axes are also thought to be sensitive to radiation damage. Diabetes insipidus appears to be uncommon after radiosurgery with only sporadic case reports (Piedra et al., 2004). A well-controlled, long-term study focusing on this issue is needed to determine definitively the incidence of radiosurgery-induced hypopituitarism.

Cranial neuropathies following radiosurgery are exceedingly rare following the first procedure, although the incidence may increase on re-treatment (Jagannathan et al., 2007). Visual injury in general can be avoided if the dose to the optic apparatus is restricted to less than 8 Gy (see previous discussion).

Injury to the cavernous segment of the carotid artery or brain parenchyma is uncommon following radiosurgery. Pollock and associates have recommended that the prescription dose should be limited to less than 50% of the intracavernous CA vessel diameter (Pollock & Carpenter, 2003). Shin recommended restricting the dose to the internal CA to less than 30 Gy (Shin et al., 2000).

Parenchymal brain injury can be present especially in the hypothalamic and temporal regions. Patients with injuries to medial temporal lobes can present with complex partial seizures or if the injury is bilateral with recent memory impairment. Induction of cavernous malformations following radiosurgery to the sellar region is also theoretically possible but thus far has not been reported.

The exact incidence of radiosurgical-induced neoplasm is unknown at present, although we have not seen one in our series of pituitary patients treated with m-LINAC system. Loeffler and colleagues recently reported on 6 patients, including 2 patients with pituitary adenomas who developed new tumors following radiosurgery (Loeffler et al., 2003). They concluded that although the risk of new tumor formation after radiosurgery appears to be significantly less than that seen following fractionated radiotherapy, new tumors can develop in the full dose region as well as in the low-dose periphery of the radiosurgical field. The latency to new tumor formation in this small series (between 6 years and 20 years) was similar to that seen after conventional radiation therapy.

9. Prognosis and follow-up

Prognosis for pituitary adenoma patients is largely dependent upon the adenoma size and functionality as well as the patients' pre-radiosurgical status. Patients being treated for

pituitary adenomas must be followed long-term with serial clinical, ophthalmological, endocrine and radiological evaluations.

Serial visual field examinations and hormonal screening should be performed. In the majority of cases serial testing of adrenal, thyroid function and GH reserves may be required as well. Patients receiving hormone replacement should have their replacement therapy adjusted as necessary.

Finally, serial MR imaging should be performed to assess for tumor recurrence. It is our practice to perform an initial post-radiosurgical MRI at 6 months after treatment with follow-up MRI's yearly thereafter, unless otherwise indicated. Endocrine and ophthalmologic follow-up should typically occur at the same time to provide adequate correlation with the treatment. There should be a good communication with every discipline involved in the treatment of these patients.

10. Conclusions

Multimodality treatment is often used to manage pituitary adenomas. Therapeutic options include medical management, microsurgery, radiosurgery, and radiotherapy. Except for prolactinomas, microsurgery remains the primary treatment for sellar lesions in surgically fit patients, particularly when the lesion is exerting a mass effect on the optic apparatus or producing hormone overproduction. Nevertheless, 20 to 50% of patients experience recurrence of their adenomas, and adjuvant treatment is recommended for these patients.

Stereotactic radiosurgery has been demonstrated to be a safe and highly effective treatment for patients with recurrent or residual pituitary adenomas. Radiosurgery affords effective growth control and hormone normalization for patients and has a generally shorter latency period than that of fractionated radiotherapy. This shorter latency period with radiosurgery can typically be managed with hormone-suppressive medications. Furthermore, the complications (for example, radiation-induced neoplasia and cerebral vasculopathy) associated with radiosurgery appear to occur less frequently than those associated with radiotherapy. Radiosurgery may even serve as a primary treatment for those patients deemed unfit for microsurgical tumor removal because they have other co morbidities or demonstrable tumors in a surgically inaccessible location. Radiosurgery can frequently preserve and, at times, even restore neurological and hormone function.

Radiosurgery is a useful tool in the treatment of both secretory and non-secretory pituitary adenomas. In most patients, radiosurgery controls adenoma growth. However, normalization of hormone overproduction can vary considerably depending on the patients' presenting condition. Challenges for the future include delineating the optimal timing for the administration of antiseecretory medications and identifying factors that can improve the response of pituitary adenomas to radiosurgery. Finally, physicians caring for patients with pituitary disorders should establish uniform endocrinological criteria and diagnostic testing for pre- and post-radiosurgical evaluations.

11. References

- Abe T, Yamamoto M, Taniyama M, Tanioka D, Izumiyama H, Matsumoto K (2002) Early palliation of oculomotor nerve palsy following gamma knife radiosurgery for pituitary adenoma. *Eur Neurol* 47:61-63.

- Adler JR Jr, Chang SD, Murphy MJ, Doty J, Geis P, Hancock SL (1997) The Cyberknife: a frameless robotic system for radiosurgery. *Funct Neurosurg* 69: 124–128.
- Adler JR Jr, Gibbs IC, Puataweepong P, Chang SD (2006) Visual field preservation after multisession cyberknife radiosurgery for perioptic lesions. *Neurosurgery* 59:244–254 discussion 244–254
- Arnaldi G, Angeli A, Atkinson AB, Bertagna X, Cavagnini F, Chrousos GP, Fava GA, Findling JW, Gaillard RC, Grossman AB, Kola B, Lacroix A, Mancini T, Mantero F, Newell-Price J, Nieman LK, Sonino N, Vance ML, Giustina A, Boscaro M (2003) Diagnosis and complications of Cushing's syndrome: a consensus statement. *J Clin Endocrinol Metab* 88:5593–5602.
- Becker, G., Kocher, M., Kortmann, R.D., Paulsen, F., Jeremic, B., Muller, R.P. & Bamberg, M. (2002) Radiation therapy in the multimodal treatment approach of pituitary adenoma. *Strahlentherapie und Onkologie*, 178, 173–186.
- Blacklay A, Grossman A, Ross RJ, Savage MO, Davies PS, Plowman PN, Coy DH, Besser GM (1986) Cranial irradiation for cerebral and nasopharyngeal tumors in children: evidence for the production of a hypothalamic defect in growth hormone release. *J Endocrinol* 108:25–29
- Brada, M., Burchell, L., Ashley, S. & Traish, D. (1999) The incidence of cerebrovascular accidents in patients with pituitary adenoma. *International Journal of Radiation Oncology, Biology, Physics*, 45, 693–698.
- Brada, M., Ford, D., Ashley, S., Bliss, J.M., Crowley, S., Mason, M., Rajan, B. & Traish, D. (1992) Risk of second brain tumor after conservative surgery and radiotherapy for pituitary adenoma. *British Medical Journal*, 304, 1343–1346.
- Brada, M., Rajan, B., Traish, D., Ashley, S., Holmes-Sellers, P.J., Nussey, S. & Uttley, D. (1993) The long-term efficacy of conservative surgery and radiotherapy in the control of pituitary adenomas. *Clinical Endocrinology*, 38, 571–578.
- Brada, M., Ashley, S., Ford, D., Traish, D., Burchell, L. & Rajan, B. (2002) Cerebrovascular mortality in patients with pituitary adenoma. *Clinical Endocrinology*, 57, 713–717.
- Buchfelder M, Fahlbusch R, Schott W, Honegger J (1991) Long term follow-up results in hormonally active pituitary adenomas after primary successful transsphenoidal surgery. *Acta Neurochir Suppl (Wien)* 53:72–76
- Chang SD, Murphy M, Geis P, Martin DP, Hancock SL, Doty JR, Adler JR Jr (1998) Clinical experience with image-guided robotic radiosurgery (the Cyberknife) in the treatment of brain and spinal cord tumors. *Neurol Med Chir* 38:780–783.
- Chen JC, Giannotta SL, Yu C, Petrovich Z, Levy ML, Apuzzo ML (2001) Radiosurgical management of benign cavernous sinus tumors: dose profiles and acute complications. *Neurosurgery* 48:1022–1030 discussion 1030–1022
- Chen JC, Giannotta SL, Yu C, Petrovich Z, Levy ML, Apuzzo ML (2001) Radiosurgical management of benign cavernous sinus tumors: dose profiles and acute complications. *Neurosurgery* 48:1022–1030 discussion 1030–1022
- Chu JW, Matthias DF, Belanoff J, Schatzberg A, Hoffman AR, Feldman D (2001) Successful long-term treatment of refractory Cushing's disease with high-dose mifepristone (RU 486). *J Clin Endocrinol Metab* 86:3568–3573.
- Ciric I, Ragin A, Baumgartner C, Pierce D (1997) Complications of transsphenoidal surgery: results of a national survey, review of the literature, and personal experience. *Neurosurgery* 40:225–236 discussion 236–227

- Cozzi R, Barausse M, Asnaghi D, Dallabonzana D, Lodrini S, Attanasio R (2001) Failure of radiotherapy in acromegaly. *Eur J Endocrinol* 145:717–726.
- Erfurth, E.M., Bulow, B., Mikoczy, Z., Svahn-Tapper, G. & Hagmar, L. (2001) Is there an increase in second brain tumours after surgery and irradiation for a pituitary tumour? *Clinical Endocrinology*, 55, 613–616.
- Erfurth, E.M., Bulow, B., Svahn-Tapper, G., Norrving, B., Odh, K., Mikoczy, Z., Bjork, J. & Hagmar, L. (2002) Risk factors for cerebrovascular deaths in patients operated and irradiated for pituitary tumors. *Journal of Clinical Endocrinology and Metabolism*, 87, 4892–4899.
- Feigl GC, Bonelli CM, Berghold A, Mokry M (2002) Effects of gamma knife radiosurgery of pituitary adenomas on pituitary function. *J Neurosurg* 97:415–421
- Ferone D, Pivonello R, Resmini E, Boschetti M, Rebora A, Albertelli M, Albanese V, Colao A, Culler MD, Minuto F. Preclinical and clinical experiences with the role of dopamine receptors in the treatment of pituitary adenomas. *Eur J Endocrinol*. 2007 Apr; 156 Suppl 1:S37-43.
- Flickinger JC, Lunsford LD, Kondziolka D (1992) Dose prescription and dose-volume effects in radiosurgery. *Neurosurg Clin N Am* 3:51–59
- Freda PU (2003) How effective are current therapies for acromegaly? *Growth Horm IGF Res* 13(Suppl A): S144–S151
- Fukuoka S, Ito T, Takanashi M, Hojo A, Nakamura H (2001) Gamma knife radiosurgery for growth hormone-secreting pituitary adenomas invading the cavernous sinus. *Stereotact Funct Neurosurg* 76:213–217.
- Ganz JC (2002) Gamma knife radiosurgery and its possible relationship to malignancy: a review. *J Neurosurg* 97:644–652
- Ganz JC, Backlund EO, Thorsen FA (1993) The effects of Gamma Knife surgery of pituitary adenomas on tumor growth and endocrinopathies. *Stereotact Funct Neurosurg* 61(Suppl 1):30–37.
- Giustina A, Barkan A, Casanueva FF, Cavagnini F, Frohman L, Ho K, Veldhuis J, Wass J, Von Werder K, Melmed S (2000) Criteria for cure of acromegaly: a consensus statement. *J Clin Endocrinol Metab* 85:526–529
- Hayashi M, Izawa M, Hiyama H, Nakamura S, Atsuchi S, Sato H, et al: Gamma knife radiosurgery for pituitary adenomas. *Stereotact Funct Neurosurg* 72 (Suppl 1):111–118, 1999
- Hayashi M, Taira T, Ochiai T, Chernov M, Takasu Y, Izawa M, Kouyama N, Tomida M, Tokumaru O, Katayama Y, Kawakami Y, Hori T, Takakura K (2005) Gamma knife surgery of the pituitary: new treatment for thalamic pain syndrome. *J Neurosurg* 102:38–41 Suppl
- Horvath E, Kovacs K, Scheithauer BW, Randall RV, Laws ER Jr, Thorner MO, Tindall GT, Barrow DL (1983) Pituitary adenomas producing growth hormone, prolactin, and one or more glycoprotein hormones: a histologic, immunohistochemical, and ultrastructural study of four surgically removed tumors. *Ultrastruct Pathol* 5:171–183.
- Hoybye C, Grenback E, Rahn T, Degerblad M, Thoren M, Hulting AL (2001) Adrenocorticotrophic hormone-producing pituitary tumors: 12- to 22-year follow-up after treatment with stereotactic radiosurgery. *Neurosurgery* 49:284–291 discussion 291–282


- Ikedda H, Jokura H, Yoshimoto T (2001) Transsphenoidal surgery and adjuvant gamma knife treatment for growth hormone-secreting pituitary adenoma. *J Neurosurg* 95:285–291
- Izawa M, Hayashi M, Nakaya K, Satoh H, Ochiai T, Hori T, Takakura K (2000) Gamma knife radiosurgery for pituitary adenomas. *J Neurosurg* 93(Suppl 3):19–22
- Jackson IM, Noren G (1999) Gamma knife radiosurgery for pituitary tumors. *Best Pract Res Clin Endocrinol Metab* 13:461–469.
- Jagannathan J, Dumont AS, Jane JA Jr, Laws ER Jr (2005) Pediatric sellar tumors: diagnostic procedures and management. *Neurosurg Focus* 18:6.
- Jagannathan J, Sheehan JP, Pouratian N, Laws ER, Steiner L, Vance ML (2007) Gamma knife surgery for Cushing's disease. *J Neurosurg* 106:980–987.
- Jane JA Jr, Vance ML, Woodburn CJ, Laws ER Jr (2003) Stereotactic radiosurgery for hypersecreting pituitary tumors: part of a multimodality approach. *Neurosurg Focus* 14:e12.
- Jezkova J, Marek J, Hana V, Krsek M, Weiss V, Vladyka V, Lisak R, Vymazal J, Pecen L (2006) Gamma knife Radiosurgery for acromegaly – long-term experience. *Clin Endocrinol* 64:588–595.
- Kajiwarra K, Saito K, Yoshikawa K, Kato S, Akimura T, Nomura S, Ishihara H, Suzuki M (2005) Image-guided stereotactic radiosurgery with the CyberKnife for pituitary adenomas. *Minim Invasive Neurosurg* 48:91–96.
- Kajiwarra K, Saito K, Yoshikawa K, Kato S, Akimura T, Nomura S, Ishihara H, Suzuki M (2005) Image-guided stereotactic radiosurgery with the CyberKnife for pituitary adenomas. *Minim Invasive Neurosurg* 48:91–96.
- Kanter AS, Diallo AO, Jane JA Jr, Sheehan JP, Asthagiri AR, Oskouian RJ, Okonkwo DO, Sansur CA, Vance ML, Rogol AD, Laws ER Jr (2005) Single-center experience with pediatric Cushing's disease. *J Neurosurg* 103:413–420
- Kim MS, Lee SI, Sim JH (1999) Gamma Knife radiosurgery for functioning pituitary microadenoma. *Stereotact Funct Neurosurg* 72(Suppl 1):119–124.
- Kim SH, Huh R, Chang JW, Park YG, Chung SS (1999) Gamma Knife radiosurgery for functioning pituitary adenomas. *Stereotact Funct Neurosurg* 72(Suppl 1):101–110.
- Kobayashi T, Kida Y, Mori Y (2002) Gamma knife Radiosurgery in the treatment of Cushing disease: long-term results. *J Neurosurg* 97:422–428
- Landolt AM, Haller D, Lomax N, Scheib S, Schubiger O, Siegfried J, Wellis G (2000) Octreotide may act as a radio protective agent in acromegaly. *J Clin Endocrinol Metab* 85:1287–1289.
- Landolt AM, Haller D, Lomax N, Scheib S, Schubiger O, Siegfried J, Wellis G (1998) Stereotactic radiosurgery for recurrent surgically treated acromegaly: comparison with fractionated radiotherapy. *J Neurosurg* 88:1002–1008
- Landolt AM, Lomax N (2000) Gamma knife radiosurgery for prolactinomas. *J Neurosurg* 93(Suppl 3):14–18.
- Laws ER Jr, Ebersold MJ, Piepgras DG, Randall RV, Salassa RM (1985) The results of transsphenoidal surgery in specific clinical entities. In: *Management of pituitary adenomas and related lesions with emphasis on Transsphenoidal microsurgery*. Laws ER Jr, Randall RV, Kern EB et al (eds) Appleton-Century-Crofts, New York, pp 277–305
- Laws ER Jr, Fode NC, Redmond MJ (1985) Transsphenoidalsurgery following unsuccessful prior therapy. An assessment of benefits and risks in 158 patients. *J Neurosurg* 63:823–829

- Laws ER Jr, Thapar K (1996) Recurrent pituitary adenomas. In: *Pituitary adenomas*. Landolt AM, Vance ML, Reilly PL (eds) Churchill-Livingstone, Edinburgh, pp 385–394
- Laws ER Jr, Vance ML (1999) Radiosurgery for pituitary tumors and craniopharyngiomas. *Neurosurg Clin N Am* 10:327–336
- Laws ER, Sheehan JP (2006) Pituitary surgery: a modern approach. *Front Horm Res*. Basel, Karger vol 34, pp I-X
- Laws ER, Vance ML, Thapar K (2000) Pituitary surgery for the management of acromegaly. *Horm Res* 53(Suppl 3):71–75.
- Leber KA, Bergloff J, Langmann G, Mokry M, Schrottnner O, Pendl G (1995) Radiation sensitivity of visual and oculomotor pathways. *Stereotact Funct Neurosurg* 64(Suppl 1):233–238
- Leber KA, Bergloff J, Pendl G (1998) Dose-response tolerance of the visual pathways and cranial nerves of the cavernous sinus to stereotactic radiosurgery. *J Neurosurg* 88:43–50.
- Levy RP, Fabrikant JL, Frankel KA, Phillips MH, Lyman JT, Lawrence JH, Tobias CA (1991) Heavy-charged-particle Radiosurgery of the pituitary gland: clinical results of 840 patients. *Stereotact Funct Neurosurg* 57:22–35.
- Lim YL, Leem W, Kim TS, Rhee BA, Kim GK (1998) Four years' experiences in the treatment of pituitary adenomas with gamma knife radiosurgery. *Stereotact Funct Neurosurg* 70(Suppl1):95–109.
- Loeffler JS, Niemierko A, Chapman PH (2003) Second tumors after radiosurgery: tip of the iceberg or a bump in the road? *Neurosurgery* 52:1436–1440 discussion 1440–1432
- Losa M, Valle M, Mortini P, Franzin A, Da Passano CF, Cenzato M, et al. (2004) Gamma Knife surgery for treatment of residual nonfunctioning pituitary adenomas after surgical debulking. *J Neurosurg* 100:438–444
- Mahmoud-Ahmed AS, Suh JH (2002) Radiation therapy for Cushing's disease: a review. *Pituitary* 5:175–180.
- Mampalam TJ, Tyrrell JB, Wilson CB (1988) Transsphenoidal microsurgery for Cushing disease. A report of 216 cases. *Ann Intern Med* 109:487–493
- Mauermann WJ, Sheehan JP, Chernavvsky DR, Laws ER, Steiner L, Vance ML (2007) Gamma Knife surgery for adrenocorticotrophic hormone-producing pituitary adenomas after bilateral adrenalectomy. *J Neurosurg* 106:988–993.
- Mitsumori M, Shrieve DC, Alexander E III, Kaiser UB, Richardson GE, Black PM, et al. (1998): Initial clinical results of LINAC-based stereotactic radiosurgery and stereotactic radiotherapy for pituitary adenomas. *Int J Radiat Oncol Biol Phys* 42:573–580
- Mokry M, Ramschak-Schwarzer S, Simbrunner J, Ganz JC, Pendl G (1999): A six year experience with the postoperative radiosurgical management of pituitary adenomas. *Stereotact Funct Neurosurg* 72 (Suppl 1):88–100
- Morange-Ramos I, Regis J, Dufour H, Andrieu JM, Grisoli F, Jaquet P, Peragut JC (1998) Gamma-knife surgery for secreting pituitary adenomas. *Acta Neurochir (Wien)* 140:437–443.
- Muramatsu J, Yoshida M, Shioura H, Kawamura Y, Ito H, Takeuchi H, et al. (2003): [Clinical results of LINAC-based stereotactic Radiosurgery for pituitary adenoma.] *Nippon Igaku Hoshasen Gakkai Zasshi* 63:225–230

- Nagesser SK, van Seters AP, Kievit J, Hermans J, Krans HM, van de Velde CJ (2000) Long-term results of total adrenalectomy for Cushing's disease. *World J Surg* 24:108–113.
- Nieman LK (2002) Medical therapy of Cushing's disease. *Pituitary* 5:77–82.
- Pan L, Zhang N, Wang EM, Wang BJ, Dai JZ, Cai PW (2000) Gamma knife radiosurgery as a primary treatment for prolactinomas. *J Neurosurg* 93(Suppl 3):10–13
- Petrovich Z, Yu C, Giannotta SL, Zee CS, Apuzzo ML (2003) Gamma knife radiosurgery for pituitary adenoma: early results. *Neurosurgery* 53:51–59 discussion 59–61
- Pham CJ, Chang SD, Gibbs IC, Jones P, Heilbrun MP, Adler JR Jr (2004) Preliminary visual field preservation after staged CyberKnife radiosurgery for perioptic lesions. *Neurosurgery* 54:799–810 discussion 810–812
- Piedra MP, Brown PD, Carpenter PC, Link MJ (2004) Resolution of diabetes insipidus following gamma knife surgery for a solitary metastasis to the pituitary stalk. Case report. *J Neurosurg* 101:1053–1056
- Pollock BE, Carpenter PC: Stereotactic radiosurgery as an alternative to fractionated radiotherapy for patients with recurrent or residual nonfunctioning pituitary adenomas. *Neurosurgery* 53: 1086–1094, 2003
- Pollock BE, Cochran J, Nat N, Brown PD, Erickson D, Link MJ, Garces YI, Foote RL, Stafford SL, Shomberg PJ. (2008) Gamma knife Radiosurgery for patients with nonfunctioning pituitary adenomas: results from a 15 year experience. *Int J Radiat Oncol Biol Phys.* 70(5): 1325–9.
- Pollock BE, Jacob JT, Brown PD, Nippoldt TB (2007) Radiosurgery of growth hormone-producing pituitary adenomas: factors associated with biochemical remission. *J Neurosurg* 106:833–838.
- Pollock BE, Kondziolka D, Lunsford LD, Flickinger JC (1994) Stereotactic radiosurgery for pituitary adenomas: imaging, visual and endocrine results. *Acta Neurochir Suppl* (Wien) 62:33–38
- Pollock BE, Young WF Jr (2002) Stereotactic radiosurgery for patients with ACTH-producing pituitary adenomas after prior adrenalectomy. *Int J Radiat Oncol Biol Phys* 54:839–841.
- Post KD, Habas JE (1990) Comparison of long term results between prolactin secreting adenomas and ACTH secreting adenomas. *Can J Neurol Sci* 17:74–77
- Pouratian N, Sheehan J, Jagannathan J, Laws ER Jr, Steiner L, Vance ML (2006) Gamma knife radiosurgery for medically and surgically refractory prolactinomas. *Neurosurgery* 59:255–266 discussion 255–266.
- Rahn T, Thoren M, Hall K, Backlund EO (1980) Stereotactic radiosurgery in Cushing's syndrome: acute radiation effects. *Surg Neurol* 14:85–92
- Shalet SM (1993) Radiation and pituitary dysfunction. *N Engl J Med* 328:131–133.
- Sheehan JM, Vance ML, Sheehan JP, Ellegala DB, Laws ER Jr (2000) Radiosurgery for Cushing's disease after failed transsphenoidal surgery. *J Neurosurg* 93:738–742
- Sheehan JP, Jagannathan J, Pouratian N, Steiner L (2006) Stereotactic radiosurgery for pituitary adenomas: a review of the literature and our experience. *Front Horm Res* 34:185–205
- Sheehan JP, Kondziolka D, Flickinger J, Lunsford LD (2002) Radiosurgery for residual or recurrent nonfunctioning pituitary adenoma. *J Neurosurg* 97:408–414
- Sheehan JP, Kondziolka D, Flickinger J, Lunsford LD (2002): Radiosurgery for residual or recurrent nonfunctioning pituitary adenoma. *J Neurosurg* 97 (Suppl 5):408–414

- Shin M, Kurita H, Sasaki T, Tago M, Morita A, Ueki K, Kirino T (2000) Stereotactic radiosurgery for pituitary adenoma invading the cavernous sinus. *J Neurosurg* 93(Suppl 3):2-5
- Tomlinson, J.W., Holden, N., Hills, R.K., Wheatley, K., Clayton, R.N., Bates, A.S., Sheppard, M.C. & Stewart, P.M. (2001) Association between premature mortality and hypopituitarism. West Midlands Prospective Hypopituitary Study Group. *Lancet*, 357, 425-431.
- Tsang, R.W., Brierley, J.D., Panzarella, T., Gospodarowicz, M.K., Sutcliffe, S.B. & Simpson, W.J. (1994) Radiation therapy for pituitary adenoma: treatment outcome and prognostic factors. *International Journal of Radiation Oncology, Biology, Physics*, 30, 557-565
- Vance ML (1998) Endocrinological evaluation of acromegaly. *J Neurosurg* 89:499-500
- Witt TC (2003) Stereotactic radiosurgery for pituitary tumors. *Neurosurg Focus* 14:e10.
- Witt TC, Kondziolka D, Flickinger JC, Lunsford LD (1998) Gamma knife radiosurgery for pituitary tumors. In: *Gamma knife brain surgery progress in neurological surgery*. Lunsford LD, Kondziolka D, Flickinger J (eds) Karger, Basel, pp114-127.
- Wolffenbittel BH, Kitz K, Beuls EM (1998) Beneficial gammaknife radiosurgery in a patient with Nelson's syndrome. *Clin Neurol Neurosurg* 100:60-63.
- Wowra B, Stummer W (2002) Efficacy of gamma knife Radiosurgery for nonfunctioning pituitary adenomas: a quantitative follow up with magnetic resonance imaging-based volumetric analysis. *J Neurosurg* 97:429-432
- Yildiz F, Zorlu F, Erbas T, Atahan L (1999) Radiotherapy in the management of giant pituitary adenomas. *Radiother Oncol* 52:233-237.
- Yoon SC, Suh TS, Jang HS, Chung SM, Kim YS, Ryu MR, et al. 1998 Clinical results of 24 pituitary macroadenomas with linac based stereotactic radiosurgery. *Int J Radiat Onc Biol Phys* 41:849-853

IntechOpen



Pituitary Adenomas

Edited by Prof. Vafa Rahimi-Movaghar

ISBN 978-953-51-0041-6

Hard cover, 86 pages

Publisher InTech

Published online 10, February, 2012

Published in print edition February, 2012

Pituitary Adenomas is a comprehensive book about the most common pathology of the pituitary gland in the sellar region. The book chapters include epidemiology, symptoms and signs, clinical, imaging, immunohistochemical and ultrastructural pathological diagnosis, therapeutic approaches and outcome of the functional and non-functional pituitary tumors. Therapies include medications, endoscopic transphenoidal and open surgeries; radiotherapy includes gamma knife radiosurgery. Visual symptoms has important and characteristic patterns which has discussed in one specific chapter. Endocrine secretion is another characteristic in 40% of pituitary adenomas. Therefore, another chapter presents it. Stereotactic radiosurgery and endoscopic surgery both have special role in recent decades. Thus, they have considered specifically, too. Authors expect to give excellent insight in pituitary adenoma to the book readers.

How to reference

In order to correctly reference this scholarly work, feel free to copy and paste the following:

Ricardo H. Brau and David Lozada (2012). Stereotactic Radiosurgery for Pituitary Adenomas, Pituitary Adenomas, Prof. Vafa Rahimi-Movaghar (Ed.), ISBN: 978-953-51-0041-6, InTech, Available from: <http://www.intechopen.com/books/pituitary-adenomas/stereotactic-radiosurgery-for-pituitary-adenomas->

INTech
open science | open minds

InTech Europe

University Campus STeP Ri
Slavka Krautzeka 83/A
51000 Rijeka, Croatia
Phone: +385 (51) 770 447
Fax: +385 (51) 686 166
www.intechopen.com

InTech China

Unit 405, Office Block, Hotel Equatorial Shanghai
No.65, Yan An Road (West), Shanghai, 200040, China
中国上海市延安西路65号上海国际贵都大饭店办公楼405单元
Phone: +86-21-62489820
Fax: +86-21-62489821

© 2012 The Author(s). Licensee IntechOpen. This is an open access article distributed under the terms of the [Creative Commons Attribution 3.0 License](https://creativecommons.org/licenses/by/3.0/), which permits unrestricted use, distribution, and reproduction in any medium, provided the original work is properly cited.

IntechOpen

IntechOpen