

We are IntechOpen, the world's leading publisher of Open Access books Built by scientists, for scientists

6,900

Open access books available

186,000

International authors and editors

200M

Downloads

Our authors are among the

154

Countries delivered to

TOP 1%

most cited scientists

12.2%

Contributors from top 500 universities



WEB OF SCIENCE™

Selection of our books indexed in the Book Citation Index
in Web of Science™ Core Collection (BKCI)

Interested in publishing with us?
Contact book.department@intechopen.com

Numbers displayed above are based on latest data collected.
For more information visit www.intechopen.com



Functional MRI-Based Strategy of Therapeutic rTMS Application: A Novel Approach for Post-Stroke Aphasic Patients

Wataru Kakuda and Masahiro Abo

Department of Rehabilitation Medicine, Jikei University School of Medicine, Tokyo, Japan

1. Introduction

In this chapter, we first discuss the concept of therapeutic application of repetitive transcranial magnetic stimulation (rTMS) in post-stroke aphasic patients. Second, we describe our protocol of functional MRI-based therapeutic rTMS for this patient population and report the clinical results of the treatment. Finally, we comment on future directions of therapeutic application of rTMS in research and clinical practice.

2. Case illustration

A 56-year-old right-handed male patient was referred to our department for further rehabilitation because of long-standing aphasia after stroke. He was a native Japanese speaker (born and grown up in Tokyo, Japan) and could not speak any other language. He was working as a cook at a Japanese restaurant before the onset of stroke. Three years before the referral, he suffered cerebral infarction in the cortical area of the left middle cerebral artery territory (including mainly the left frontal cortex), which resulted in moderate non-fluent aphasia and right hemiparesis. Neurological examination following referral/admission to our department showed he was alert and able to follow verbal commands in a short sentence. However, his speech was non-fluent and not easily understandable. He had some difficulties at the beginning of speaking and was sometimes unable to find appropriate words easily. He was able to name some nouns frequently used in daily living, although it was usually impossible for him to repeat aloud a long sentence consisting of more than five words. He could walk with a T-shaped cane despite the presence of right hemiparesis.

3. Study questions

- What is therapeutic rTMS after stroke?
- What is the concept of therapeutic rTMS application for aphasia?
- What is functional MRI-based rTMS strategy for aphasic patients?
- What is the future direction of therapeutic rTMS for aphasia?

4. Key terms

Repetitive transcranial magnetic stimulation, Functional MRI, Stroke, Compensatory area for impaired language function, Non-fluent aphasia

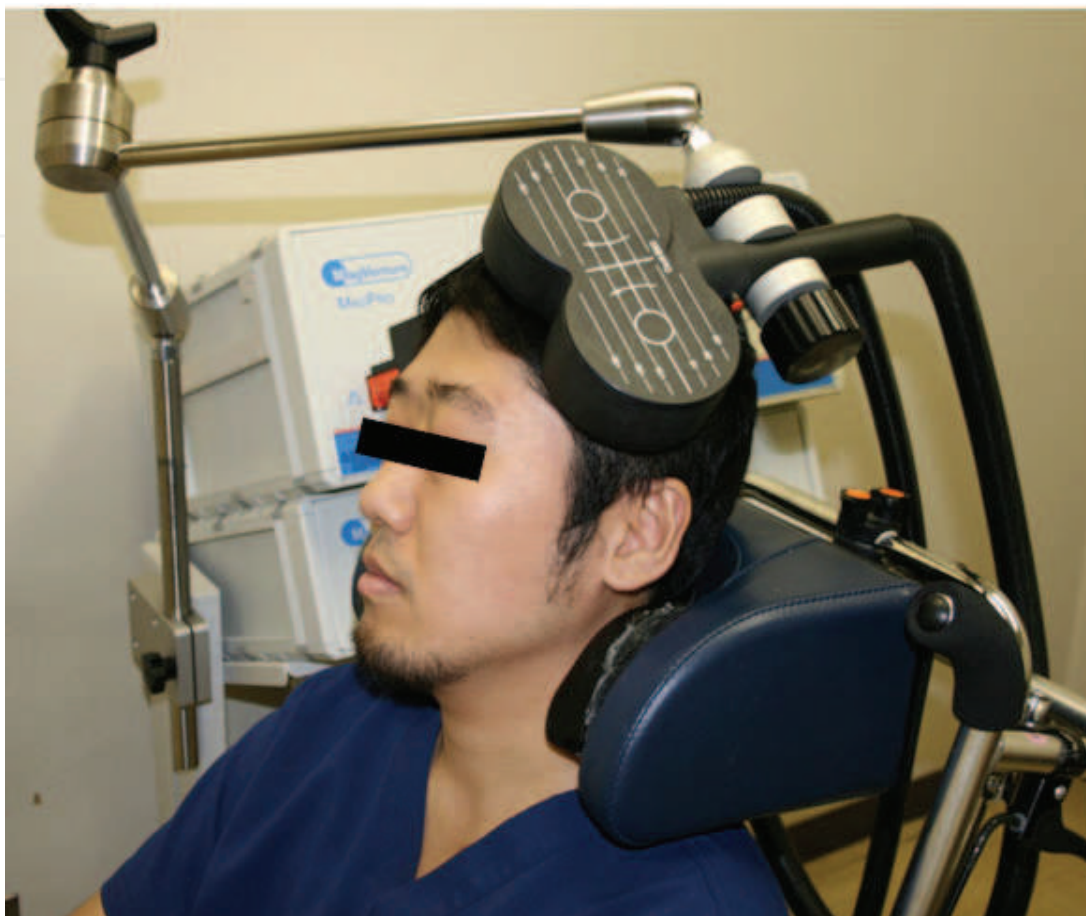

Fig. 1. Application of rTMS to the F7 site using a figure-8 coil and MagPro R30 stimulator. Patients were asked to relax while sitting in the chair during the stimulation.

5. What is therapeutic rTMS after stroke?

Transcranial magnetic stimulation (TMS) is a painless, safe procedure involving non-invasive brain stimulation (Hallett, 2007). The mechanism of TMS is based on Faraday's principle of electromagnetic induction. A pulse of current passing through a coil placed over the head generates rapidly changing magnetic pulses that penetrate the scalp. After reaching the brain, the pulses induce an ionic current in the cerebral cortex, which stimulate cortical neurons. Application of TMS in a repetitive manner, i.e., repetitive TMS (rTMS), can modulate local cortical neuronal excitability. It has been reported that the effect of rTMS can range from upregulation (facilitation) to downregulation (suppression) of neuronal activity, depending on the stimulation parameters (mainly the frequency of stimulation) (Hummel and Cohen, 2006). High-frequency rTMS i.e., ≥ 5 Hz) facilitates local neural activity, whereas low-frequency rTMS (i.e., ≤ 1 Hz) suppresses the activity (Pascual-Leone et al., 1994; Chen et al., 1997; Maeda et al., 2000a; Maeda et al, 2000b; Wu et al., 2000). Basically, the rTMS is applied as a therapy for post-stroke impaired neural function to activate the compensatory

cortical areas for the impaired function. Based on this concept, two therapeutic approaches for activating the compensatory areas have been suggested; the direct approach and indirect approach. In the direct approach, excitatory high-frequency rTMS is applied over the cerebral hemisphere including the compensatory areas, to directly upregulate the neural excitability of the compensatory areas. On the other hand, in the indirect approach, inhibitory low-frequency rTMS is applied to the cerebral hemisphere contralateral to the compensatory areas. In the latter approach, since the neural activity of the hemisphere stimulated with rTMS is downregulated, interhemispheric inhibition towards the hemisphere including the compensatory areas is reduced. Consequently, the compensatory areas are disinhibited from the interhemispheric inhibition, resulting in the upregulation of neural activity of the compensatory areas. So far, the indirect approach using low-frequency rTMS seems to be more widely applied as a therapeutic intervention after stroke compared with the direct approach with high-frequency rTMS, although further research is needed to determine the best approach with regard to the clinical benefits including functional recovery. In randomized controlled trials, for example, some groups have already shown that low-frequency rTMS to the non-lesional hemisphere significantly improved motor function of the affected upper limb in post-stroke hemiparetic patients, via indirect activation of the lesional hemisphere (Mansur et al., 2005; Takeuchi et al., 2005; Fregni et al., 2006).

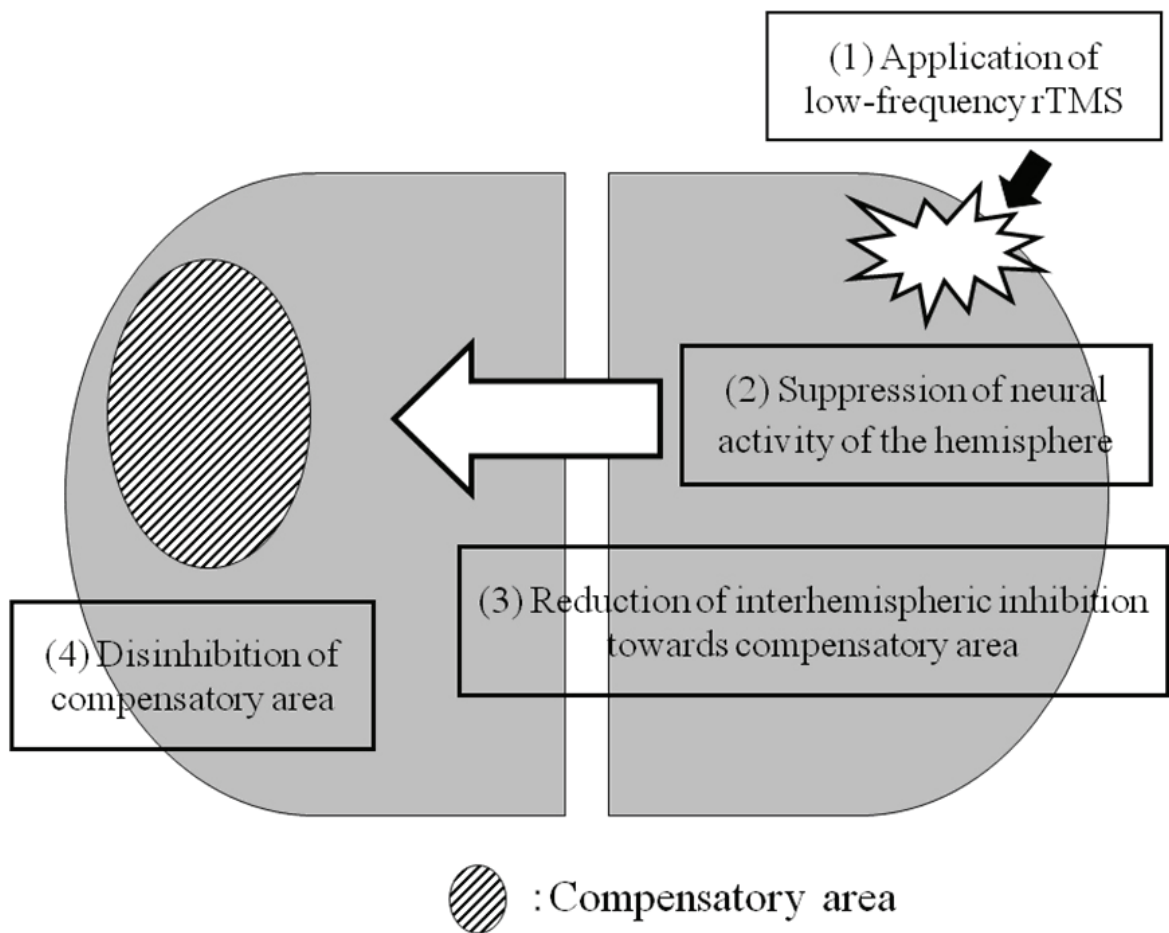


Fig. 2. Indirect approach with low-frequency rTMS. Inhibitory low-frequency rTMS reduced interhemispheric inhibition towards the compensatory areas.

6. Application of low-frequency rTMS to the right hemisphere for aphasia after stroke

The first report describing the therapeutic use of rTMS in post-stroke aphasic patients was published by in 2005 by Naeser et al. from Boston University School of Medicine (Naeser et al., 2005a; Naeser et al., 2005b). Prior to the publication of that report, some researchers reported significant activation of the right frontal cortex on functional imaging in non-fluent aphasic patients, and commented that over-activation in the right hemisphere might impede the functional reorganization of the left hemispheric language circuits that are necessary for the recovery of language function (i.e., a maladaptive response) (Belin et al., 1996; Rosen et al., 2000). Therefore, Naeser et al. hypothesized that neural suppression of the *over-activated* right hemisphere by inhibitory low-frequency rTMS can lead to language functional recovery, by reducing interhemispheric inhibition from the right hemisphere towards the left hemisphere. Their pilot study included four right-handed patients with a 5-11 year history of stroke (left hemispheric stroke) and non-fluent aphasia (Naeser et al., 2005b). They applied slow 1 Hz rTMS to the right pars triangularis (anterior portion of the homologous area of the left Broca area) for 20 minutes per day (1,200 pulses per day) at 90% of motor threshold, five days a week for two weeks (10 sessions in total). The clinical influence of this

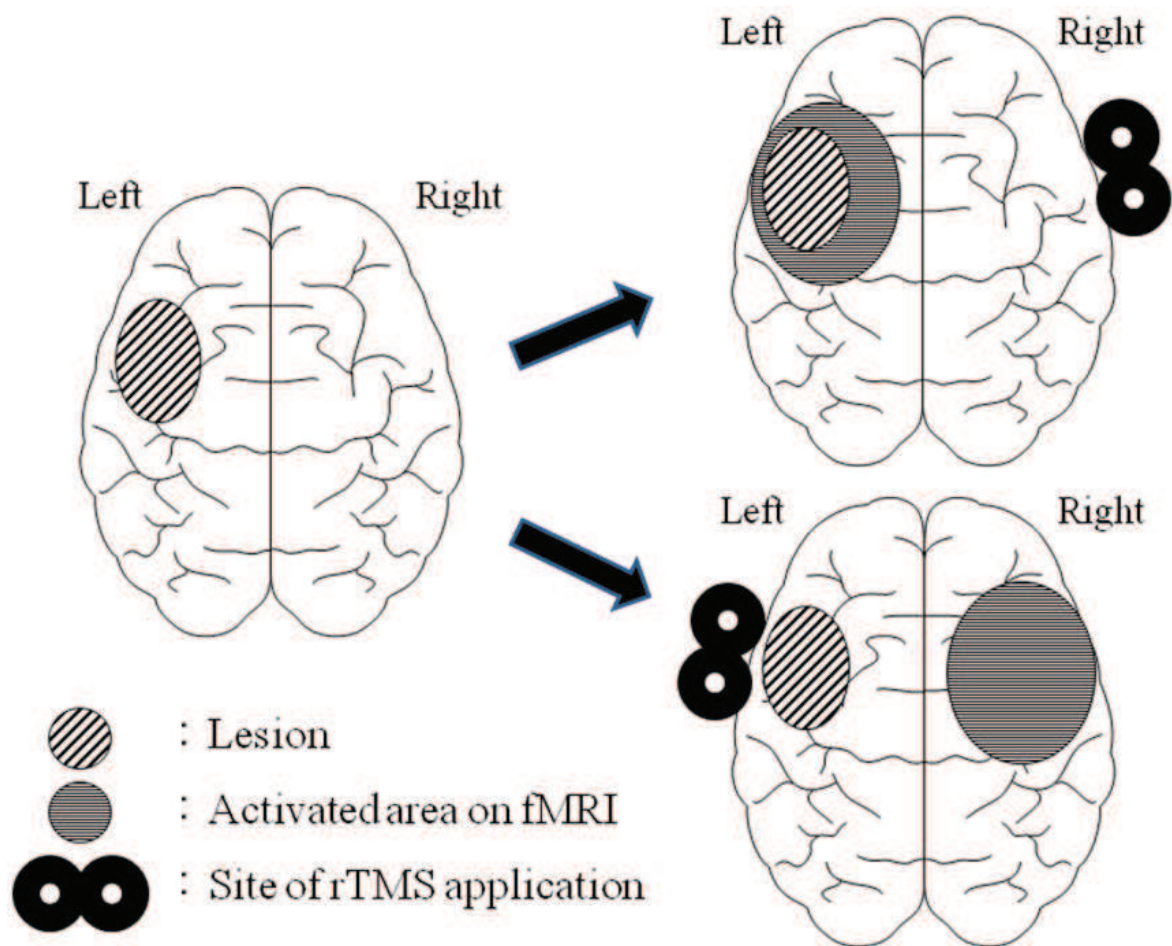


Fig. 3. Determination of the site of rTMS application based on functional MRI. Low-frequency rTMS was applied to the F8 site and the F7 site in patients with left and right hemispheric activation, respectively.

intervention was evaluated using the Boston Diagnostic Aphasia Exam (BDAE) within 1-2 weeks before the first application of rTMS, and at two and eight months after the intervention. After the intervention, the studied patients named significantly more pictures and their reaction time to naming these pictures was significantly reduced compared to the baseline (before the intervention). These beneficial effects were also found at eight months after the intervention. Following the publication of their report, some randomized controlled trials were conducted by other groups to confirm the beneficial effect of low-frequency rTMS to the right hemisphere in post-stroke aphasic patients. Barwood et al. (2011) compared language outcome in six post-stroke aphasic patients treated with low-frequency rTMS to the right hemisphere for 10 days with that of six sham-stimulated patients. The results showed better improvement in certain language functions, such as naming, at two months after the intervention, compared with sham-treated patients. In the report of Weiduschat et al. (2011), language functional improvement was noted in post-stroke aphasic patients after a two-week intervention treatment with low-frequency rTMS applied to the right hemisphere, compared with the control group. Furthermore, they also demonstrated a significant activation of the left hemisphere on positron emission tomography in rTMS-treated patients.

7. Are the compensatory areas for impaired language function uniform in aphasic patients?

The therapeutic strategy of Naeser's approach is based on the concept that the left hemisphere plays an important role in language functional recovery after left hemispheric stroke and that over-activation of the right hemisphere on functional MRI is a maladaptive response. In fact, many researchers have published clinical papers in support of the important role of left hemisphere (especially the peri-lesional area of the hemisphere) in the process of language functional recovery (Heiss et al., 1999; Warburton et al., 1999; Fernandez et al., 2004). On the other hand, however, other reports have also emphasized the involvement of the right hemisphere in some language functional recovery in a subgroup of post-stroke patients. For example, in the PET study by Ohyama et al. (1996), language functional recovery correlated significantly with the activation of the right hemisphere in non-fluent aphasic post-stroke patients. Using functional MRI with language tasks, Abo et al. (2004) showed that complete recovery of aphasic symptoms was associated with significant activation of the right hemisphere. Furthermore, Richter et al. (2008) identified a stronger neural activation in the right hemisphere on functional MRI during language tasks in aphasic patients compared to normal subjects. Taking into consideration the results of these reports, one can conclude that the compensatory areas for impaired language function vary among aphasic patients with left hemispheric stroke. In other words, over-activation of the right hemisphere on functional MRI in post-stroke aphasic patients does not necessarily represent maladaptive response and that some patients show right hemispheric compensation for the impairment.

8. MRI-based therapeutic rTMS for post-stroke aphasic patients

8.1 Our concept of therapeutic rTMS for post-stroke aphasic patients

With regard to the variability in the location of the compensatory areas for impaired language function among aphasic patients with left hemispheric lesions, we consider that it

is important to determine the exact brain areas that compensate for the impaired language function before any application of rTMS can be made. For example, if low-frequency rTMS is applied to the right hemisphere of aphasic patients in whom the right hemisphere plays the dominant role in recovery, it could result in deterioration of language function. Unfortunately, there are no specific clinical features that can help localize the compensatory areas for impaired language function. In addition, conventional neuroimaging does not seem helpful for this purpose. In this regard, functional MRI with a language task seems to be useful for evaluation of functional reorganization in aphasic patients (Cherney and Small, 2006; Crinion and Leff, 2007; Vitali P, et al., 2007). As mentioned above, a number of centers have used functional MRI with language tasks to localize activated areas in aphasic post-stroke patients, based on the principle that such areas represent the compensatory areas for impaired language function. Thus, it seems that functional MRI is useful for identifying the compensatory areas prior to therapeutic rTMS application, so that low-frequency rTMS can be applied to the hemisphere contralateral to the activated areas, with the expectation that the rTMS would reduce interhemispheric inhibition towards the compensatory areas and facilitate neural activity of the areas. In a recent report, Naeser et al. (2010) also commented on the clinical significance of functional MRI findings in the therapeutic application of rTMS in aphasic patients. They used functional MRI during overt naming to identify the activated areas, then applied 1 Hz low-frequency rTMS to the right frontal cortex in two right handed non-fluent aphasic patients with left hemispheric stroke. Subsequently, they assessed the relationship between the language functional recovery and the findings of functional MRI during overt naming between the patients. Patient 1 showed activation of the bilateral supplementary motor area (SMA), bilateral sensorimotor cortex and right inferior frontal gyrus at baseline. Treatment with rTMS significantly increased the activation in the left SMA, with a shift in activation from the right hemisphere to the left hemisphere. These results correlated with the significant improvement in naming (good responder). On the other hand, Patient 2 who was labeled a poor responder based on the poor functional improvement, showed significant activation in the right inferior frontal gyrus (IFG) with no activation in the left hemisphere on functional MRI at baseline. After rTMS application, no newly activated area was found in the left hemisphere and the significant activation in the right IFG was no longer seen. These results suggested that functional MRI conducted at baseline can help identify aphasic patients who can successfully respond to their therapeutic protocol and that low-frequency rTMS applied to the right hemisphere does not seem to be an appropriate therapeutic intervention for aphasic patients with right hemisphere activation. The results of their study add support to our concept of the need to perform functional MRI prior to the application of rTMS to determine the compensatory areas for impaired language function.

8.2 Functional MRI with language tasks

Four weeks prior to the application of rTMS, functional MRI was performed with repetition tasks to determine the site of the compensatory areas for impaired language function. Functional MRI was conducted using a 1.5 T scanner capable of echo planar imaging (EPI) (Turner, 1994). All functional MRIs were obtained with an EPI gradient echo sequence (parameters for functional MRI: 6 mm slice thickness, field of view 240 mm, TR 5000 ms, TE 90.5 ms, 80 degree flip angle, and matrix 128×128 and oriented identical to the anatomical images). With regard to the repetition task, patients were asked to repeat aloud a series of

words (common nouns frequently used in daily usual conversation) that were delivered every three seconds through earphones, after confirmation that the patient was able to repeat correctly more than half of the words of the tasks (Abo et al., 2004). Axial and coronal images of conventional T1-weighted scans were also taken to anatomically coregister with images of functional MRI and accurately localize the activated areas (parameters for T1-weighted images: 2 mm slice thickness, field of view 240 mm, TR 26 ms, TE 2.4 ms, and matrix 256×256). Functional MRI was analyzed using the SPM2 implemented in the MATLAB and the analyzed slices were overlaid on the axial and coronal images of T1-weighted scans. The areas with threshold p values for activation of less than 0.01 were marked on functional MRI as activated areas, and the T values of each activated area were computed automatically. Using this technique, we determined the most activated site (site with the highest T value) on functional MRI, and identified the cerebral hemisphere containing the most activated sites, which plays a more important role in the compensatory mechanisms compared with the other hemisphere.

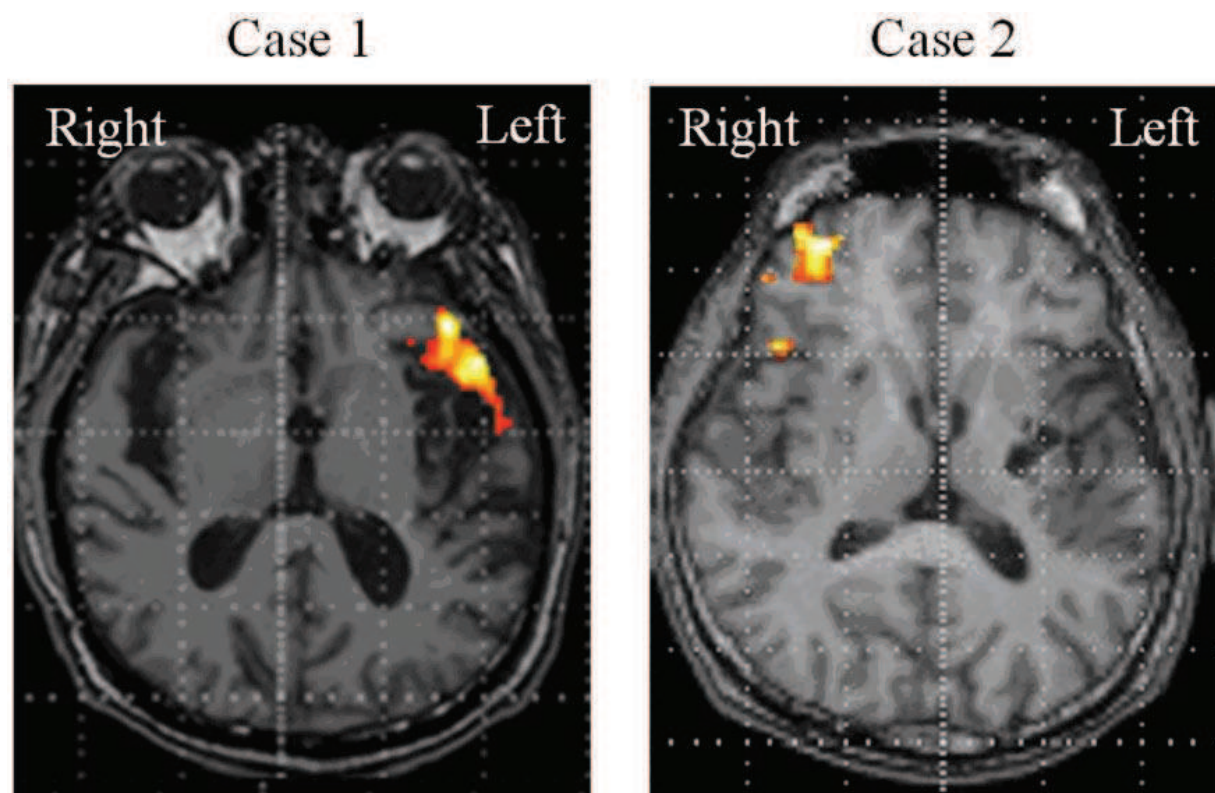


Fig. 4. Axial images of functional MRI with repetition tasks prior to rTMS. Activation on functional MRI was found in the peri-lesional area of the left hemisphere in Case 1 and in the right frontal cortex in Case 2.

8.3 Criteria used for selection of patients appropriate for rTMS

The criteria used in our department for selection of patients for treatment with rTMS were as follow: (1) mild-to-moderate non-fluent aphasia diagnosed clinically (ability, at least, to speak short sentences comprising of 2-4 Japanese words, to repeat aloud nouns frequently used in daily living settings, to understand and follow simple verbal commands). (2) Age at application of treatment between 18 and 80 years. (3) The latency between the onset of

stroke and application of treatment is more than 12 months. (4) History of a single stroke only (no bilateral cerebrovascular lesion). (5) No apparent cognitive impairment other than aphasia. (6) Clinical confirmation of the plateau state of language functional recovery, diagnosed by physicians from our department (no apparent changes in language function over at least three months). (7) No active physical or mental illness requiring medical management. (8) No pathological conditions known to be contraindications for rTMS in the guidelines suggested by Wassermann (e.g., cardiac pacemaker, intracranial metals) (1998). (9) No recent history of seizure, documented epileptic discharge on recent electroencephalography or current use of antiepileptic medications for the prevention of seizure. These criteria were arbitrarily selected based on experience in the field rather being based on rigorous scientific analysis of previous cases treated with the protocol (Kakuda et al., 2010).

8.4 Application of low-frequency rTMS

According to the current safety recommendation, focal 1 Hz rTMS was delivered with a 70-mm figure-8 coil and MagPro R30 stimulator (MagVenture Company, Farum, Denmark). Each rTMS session consisted of 1,200 pulses, lasting for 20 minutes. In a series of studies, we determined and verified the target area for rTMS in aphasic patients using functional MRI with repetition tasks combined with repeated conventional T1-weighted images (Kakuda et al., 2010). Based on the functional MRI images, a tentative target area was selected that corresponded to the most activated site. The anatomic site was marked by placing a small liquid-filled capsule on the scalp. We also confirmed the appropriateness of the selected target area by depicting the position of capsule on repeated conventional T-weighted images. However, this method was complicated and seemed difficult and troublesome to duplicate in real clinical settings. Therefore, for therapeutic application of rTMS in non-fluent aphasic patients, we currently consider the inferior frontal gyrus (IFG) as an appropriate target area for therapeutic rTMS. Accordingly, we determine the target area for application of rTMS based on the location of scalp markers placed according to the International 10-20 System for the electroencephalographic recording, after selecting the most important cerebral hemisphere in the compensatory process by functional MRI with language tasks. Using brain CT or MRI, two groups separately studied the relationship between cranial landmarks and cerebral structures (Homan et al., 1987; Okamoto et al., 2004). Both groups found that F7/8 in the International 10-20 System correlated with the location of IFG. Therefore, the F8 and F7 of the system were chosen as the stimulation sites in patients with left and right hemispheric activation on functional MRI, respectively. After confirmation of the site, the target area is marked with a small circular sticker (diameter 5 mm) for accurate placement of the stimulator across the sessions. To determine the intensity of stimulation, the motor threshold of the right hemisphere (the lowest intensity that elicits a visible twitch in the non-paretic left thenar muscles) is determined. The intensity of rTMS is then set at 90% of the motor threshold. The position of the stimulating coil, which is placed on the sticker tangential to the scalp, was frequently checked to ensure it remained stable throughout each rTMS session.

8.5 Therapeutic in-patient protocol

The treatment was provided during 15 day admission to the hospital. Two sessions of 20-min low-frequency rTMS (1,200 pulses per session) were provided every day excluding the days of

admission and discharge, and Sundays. Following each rTMS session, 60-min “intensive” speech therapy (ST) was provided as one-to-one therapy (120 minutes per day). The ST program was tailored according to the severity of aphasic symptoms in the individual patient. In principal, the program included three tasks designed to improve expressive modality. First, patients were asked to describe verbally and answer some questions about photos showing typical situation in daily life and a short cartoon. Second, patients were asked to repeat aloud target words and short sentences spoken by the therapists. The third task was writing down words or sentences spoken by the therapists. The problems associated with achieving the tasks were aggressively approached in the following session. We evaluated patients’ language function four weeks before the admission and on the day of discharge using the Standard Language Test of Aphasia (SLTA), supplementary test of SLTA (SLTA-ST) and the Japanese version of the Western Aphasia Battery (WAB). SLTA is a standard test battery of language function for individuals whose mother language is Japanese (Kawanishi et al., 2002). SLTA can evaluate seven categories of language functions including speech, naming, repetition, writing, auditory comprehension. The SLTA-ST consists of more complex tasks than those of the SLTA. The structure of tasks tested by the Japanese version of WAB is similar to the original version in English (Bakheit et al., 2005). For this study, four categories (speech, naming, repetition, writing) of SLTA, naming category of SLTA-ST and repetition category of WAB were serially applied. With regard to safety issues, the development of adverse effects such as seizures and headache, or deterioration of language function were continuously monitored by the physician and speech therapist.

8.6 Clinical results

Since 2009, we have applied this therapeutic protocol in 12 post-stroke aphasic patients. Table 1 lists the clinical characteristics of these patients. All patients were right-handed and had left hemispheric (unilateral) cerebrovascular lesions. Their first language was Japanese and none could speak other foreign language fluently to communicate verbally with others. The mean age at the start of treatment was 55 ± 7 years (\pm SD) and the latency between onset of stroke and the intervention was 38 ± 27 months. Based on the neurological findings before study entry, the type of aphasia was classified as non-fluent type in all the patients. Functional MRI identified brain activated areas in all patients. The most activated area was found in the left hemisphere in 9 patients and in the right hemisphere in 3 patients. Therefore, low-frequency rTMS was applied to the F8 site in 9 patients and to the F7 site in 3 patients. All studied patients completed the protocol and none showed any adverse effects. Language function did not deteriorate in any patient. Table 2 lists changes in the correct answer rates in the applied language test battery after completion of the treatment. Significant increases in the correct answer rates were found in the speech category and naming category of SLTA ($p < 0.05$, each), naming category of SLTA-ST ($p < 0.05$) and repetition category of WAB ($p < 0.01$). Thus, the results indicate that the applied protocol is safe and significantly improved certain expressive modalities of language functions. Based on these results, we speculate that rTMS successfully activated the compensatory areas for impaired language function without suppressing such areas, although follow-up functional MRI was not performed to further confirm the findings. It is possible that the “intensive” ST facilitated language functional recovery after rTMS preconditioned the brain to be more responsive to the rehabilitative program. To confirm the beneficial effects of the rTMS combined with ST, randomized controlled trials with a larger number of patients are needed.

Case	Gender	Age at intervention (yrs)	Time between stroke onset and intervention (m)	Type of stroke	Site of lesion on T2-weighted MRI	Side of hemisphere containing the most activated area	Site of rTMS application
1	M	49	31	ICH	Lt putamen	Lt	F8
2	M	58	15	ICH	Lt putamen	Rt	F7
3	M	58	27	ICH	Lt putamen	Lt	F8
4	M	57	51	CI	Lt MCA territory	Lt	F8
5	M	61	15	CI	Lt MCA territory	Lt	F8
6	F	56	30	CI	Lt MCA territory	Lt	F8
7	M	66	115	ICH	Lt putamen	Rt	F7
8	M	49	41	CI	Lt MCA territory	Lt	F8
9	M	62	48	CI	Lt MCA territory	Rt	F7
10	M	59	33	ICH	Lt putamen	Lt	F8
11	M	46	19	CI	Lt MCA territory	Lt	F8
12	F	44	28	ICH	Lt putamen	Lt	F8

ICH: Intracerebral hemorrhage, CI: Cerebral infarction, MCA: Middle cerebral artery, Rt: Right, Lt: Left

Table 1. Clinical characteristics of studied patients.

Category of language function		Pre-intervention (%)	Post-intervention (%)	P value by paired Student's t-test
SLTA	Speech	59.7±24.4	66.1±23.6	< 0.05
	Naming	77.5±18.3	84.6±15.3	< 0.05
	Repetition	75.1±17.9	78.4±15.0	0.082
	Writing	70.4±34.6	73.3±30.1	0.22
SLTA-ST	Naming	74.9±21.4	79.5±21.5	< 0.05
WAB	Repetition	68.7±27.0	75.7±25.9	< 0.01

Values are mean ± SD. SLTA: Standard Language Test of Aphasia, SLTA-ST: Supplementary test of SLTA,
WAB: Japanese version of Western Aphasia Battery

Table 2. Changes in correct answer rates of the language test.

Future directions of rTMS for treatment of aphasia in research and clinical practice

We propose a few new ideas that can be introduced clinically. First, a more potent modality of inhibitory TMS to modulate neural excitability should be attempted, instead of the current protocol of low-frequency rTMS. This recommendation is based on some recent studies that demonstrated more potent suppression of local neural activity with longer after-effects with 6-Hz primed low-frequency rTMS and continuous theta burst stimulation, compared with low-frequency rTMS (Iyer et al., 2003; Huang et al., 2005). We have also started to use 6-Hz primed low-frequency rTMS in post-stroke non-fluent aphasic patients (Kakuda et al., 2011). In one session of rTMS, intermittent 6-Hz rTMS of 5-sec trains with 25-sec intervals between trains for 10 minutes were applied to the hemisphere contralateral to the most activated area on pre-treatment functional MRI, immediately followed by continuous low-frequency pulses of 1-Hz for 20 minutes. The studied patients were scheduled to receive 18 sessions of rTMS (two sessions per day) over 11 days. The study results showed that application of 6-Hz primed low-frequency rTMS for aphasic patients was safe and seemed potentially more potent neurorehabilitative approach for such patients. Second, it may be worthy applying excitatory rTMS in some aphasic patients. Szaflarski et al. (2011) reported significant beneficial effect of excitatory intermittent theta burst stimulation applied to the left Broca’s area in aphasic patients after left hemispheric stroke. In patients with right hemispheric activation at baseline, it may be also beneficial for language recovery to apply excitatory rTMS to the right frontal cortex as an alternative approach, instead of applying low-frequency rTMS to the left hemisphere. Third, certain pharmacological treatments could be introduced to enhance cortical neuronal plasticity. The beneficial effects of levodopa, amantadine, donepezil and fluvoxamine, which act on dopamine and other transmitter systems, have already been described in some clinical trials of post-stroke patients (Bakheit, 2004; de Boissezon et al., 2007; Lieport, 2008). These agents could be introduced concomitantly with rTMS application, with the hope that they increase the responsiveness of the brain to rTMS treatment.

9. Discussion of the “case-based problem”

The functional MRI with repetition tasks at baseline of the patient showed significant activation in the peri-lesional area in the left hemisphere. Therefore, the patient was treated

in 22 sessions with 20-min 1 Hz low-frequency rTMS applied to the F8 site of the International 10-20 System combined with 60-min speech therapy (two sessions per day, excluding the days of admission and discharge, and Sundays) over 15 days. The treatment had no adverse effects, but increased the rate of correct answers in the repetition category (from 53 to 67 %) and the writing category (from 21 to 28%) of SLTA. Improvement of language function was still noted at four weeks after the completion of treatment.

10. Conclusions

The initial results from our laboratories have demonstrated that low-frequency rTMS applied to the frontal cortex contralateral to the most activated area detected by functional MRI, combined with ST, is feasible, safe and resulted in significant improvement of language function in post-stroke non-fluent aphasic patients. We emphasize that the outcome of rTMS therapy depends on accurate localization of the compensatory areas for impaired language function. Our functional MRI-based low-frequency rTMS for post-stroke patients with aphasia is a potentially promising neurorehabilitative program with low-risk, although the usefulness of this strategy should still be confirmed further in a large number of patients.


11. References

- Abo M, et al (2004). Language-related brain function during word repetition in post-stroke aphasics. *Neuroreport*. Vol. 15, No. 12, pp. 1891-1894
- Bakheit AM (2004). Drug treatment of poststroke aphasia. *Expert Rev Neurotherapeutics*. Vol. 4, No. 2, pp. 211-217
- Bakheit AM, et al (2005). High scores on the Western Aphasia Battery correlate with good functional communication skills (as measured with the Communicative Effectiveness Index) in aphasic stroke patients. *Disabil Rehabil*. Vol. 27, No. 6, pp. 287-291
- Barwood CH, et al (2011). Improved language performance subsequent to low-frequency rTMS in patients with chronic non-fluent aphasia post-stroke. *Eur J Neurol*. Vol. 18, No. 7, pp. 935-943
- Belin P, et al (1996). Recovery from nonfluent aphasia after melodic intonation therapy: a PET study. *Neurology*. Vol. 47, No. 6, pp. 1504-1511
- Chen R, et al (1997). Depression of motor cortex excitability by low-frequency transcranial magnetic stimulation. *Neurology*. Vol. 48, No. 5, pp. 1398-1403
- Cherney LR and Small SL (2006). Task-dependent changes in brain activation following therapy for nonfluent aphasia: discussion of two individual cases. *J Int Neuropsychol Soc*. Vol. 12, No. 6, pp. 828-842
- Crinion JT and Leff AP (2007). Recovery and treatment of aphasia after stroke: functional imaging studies. *Curr Opin Neurol*. Vol. 20, No. 6, pp. 667-673
- de Boissezon X, et al (2007). Pharmacotherapy of aphasia: Myth or reality? *Brain and Language*. Vol. 102, No. 1, pp. 114-125
- Fernandez B, et al (2004). Functional MRI follow-up study of language processes in healthy subjects and during recovery in a case of aphasia. *Stroke*. Vol. 35, No. 9, pp. 2171-2176

- Fregni F, et al (2006). A sham-controlled trial of a 5-day course of repetitive transcranial magnetic stimulation of the unaffected hemisphere in stroke patients. *Stroke*. Vol. 37, No. 8, pp. 2115-2122
- Hallett M (2007). Transcranial magnetic stimulation: A primer. *Neuron*. Vol. 55, No. 2, pp. 187-199
- Heiss WD, et al (1999). Differential capacity of left and right hemispheric areas for compensation of poststroke aphasia. *Ann Neurol*. Vol. 45, No. 4, pp. 430-438
- Homan RW, et al (1987). Cerebral location of international 10-20 system electrode placement. *Electroencephalography and clinical neurophysiology*. Vol. 66, No. 4, pp. 376-382
- Huang YZ, et al (2005). Theta burst stimulation of the human motor cortex. *Neuron*. Vol. 45, No. 2, pp. 201-206
- Hummel FC and Cohen LG (2006). Non-invasive brain stimulation: a new strategy to improve neurorehabilitation after stroke? *Lancet Neurology*. Vol. 5, No. 8, pp. 708-712
- Iyer MB, et al (2003). Priming stimulation enhances the depressant effect of low-frequency repetitive transcranial magnetic stimulation. *J Neurosci*. Vol. 23, No. 34, pp. 10867-10872
- Kakuda W, et al (2010). Functional MRI-based therapeutic rTMS strategy for aphasic stroke patients: a case series pilot study. *Int J Neurosci*. Vol. 120, No. 1, pp. 60-66
- Kakuda W, et al.(2011). Therapeutic application of 6-Hz primed low-frequency rTMS combined with intensive speech therapy for post-stroke aphasia. *Brain Injury*. Vol. 25, No. 12, pp. 1242-1248
- Kawanishi M, et al (2002). Aphasia following left putaminal hemorrhage. Statistical analysis of factors affecting prognosis. *Neurol Res*. Vol. 24, No. 8, pp. 817-821
- Lieport J (2008). Pharmacotherapy in restorative neurology. *Curr Opin Neurol*. Vol. 21, No. 6, pp. 639-643
- Maeda F, et al (2000a). Modulation of corticospinal excitability by repetitive transcranial magnetic stimulation. *Clin Neurophysiol*. Vol. 111, No. 5, pp. 800-805
- Maeda F, et al (2000b). Interindividual variability of the modulatory effects of repetitive transcranial magnetic stimulation on cortical excitability. *Exp Brain Res*. Vol. 133, No. 4, pp. 425-430
- Mansur CG, et al (2005). A sham stimulation-controlled trial of rTMS of the unaffected hemisphere in stroke patients. *Neurology*. Vol. 64, No. 10, pp. 1802-1804
- Naeser MA, et al (2005a). Improved naming after TMS treatments in a chronic, global aphasia patient--case report. *Neurocase*. Vol. 11, No. 3, pp. 182-93
- Naeser MA, et al (2005b). Improved picture naming in chronic aphasia after TMS to part of right Broca's area: an open-protocol study. *Brain Lang*. Vol. 93, No. 1, pp. 95-105
- Naeser MA, et al (2010). Research with rTMS in the treatment of aphasia. *Restorative Neurology and Neuroscience*. Vol. 28, No. 4, pp. 511-529
- Ohyama M, et al (1996). Role of the nondominant hemisphere and un-damaged area during word repetition in poststroke aphasics: A PET activation study. *Stroke*. Vol. 27, No. 5, pp. 897-903
- Okamoto M, et al (2004). Three-dimensional probabilistic anatomical cranio-cerebral correlation via the international 10-20 system oriented for transcranial functional brain mapping. *NeuroImage*. Vol. 21, No. 1, pp. 99-111

- Pascual-Leone A, et al (1994). Responses to rapid-rate transcranial magnetic stimulation of the human motor cortex. *Brain*. Vol. 117, Pt. 4, pp. 847-858
- Richter M, et al (2008). Association between therapy outcome and right-hemisphere activation in chronic aphasia. *Brain*. Vol. 131, Pt. 5, pp. 1391-1401
- Rosen HJ, et al (2000). Neural correlates of recovery from aphasia after damage to left inferior frontal cortex. *Neurology*. Vol. 55, No. 12, pp. 1883-1894
- Szaflarski JP, et al (2011). Excitatory repetitive transcranial magnetic stimulation induces improvements in chronic post-stroke aphasia. *Med Sci Monit*. Vol. 17, No. 3, pp. CR132-139
- Takeuchi N, et al (2005). Repetitive transcranial magnetic stimulation of contralesional primary motor cortex improves hand function after stroke. *Stroke*. Vol. 36, No. 12, pp. 2681-2686
- Turner R (1994). Magnetic resonance imaging of brain function. *Annals of Neurology*. Vol. 35, No. 6, pp. 637-638
- Vitali P, et al (2007). Training-induced brain remapping in chronic aphasia: A pilot study. *Neurorehabil Neural Repair*. Vol. 21, No. 2, pp. 152-160
- Warburton E, et al (1999). Mechanisms of recovery from aphasia: evidence from positron emission tomography studies. *J Neurol Neurosurg Psychiatry*. Vol. 66, No. 2, pp. 155-161
- Wassermann EM (1998). Risk and safety of repetitive transcranial magnetic stimulation: report and suggested guidelines from the International Workshop on the Safety of Repetitive Transcranial Magnetic Stimulation, June 5-7, 1996. *Electroencephalogr Clin Neurophysiol*. Vol. 108, No. 1, pp. 1-16
- Weiduschat N, et al (2011). Effects of repetitive transcranial magnetic stimulation in aphasic stroke: a randomized controlled pilot study. *Stroke*. Vol. 42, No. 2, pp. 409-415
- Wu T, et al (2000). Lasting influence of repetitive transcranial magnetic stimulation on intracortical excitability in human subjects. *Neurosci Lett*. Vol. 287, No. 1, pp. 37-40

IntechOpen



Latest Findings in Intellectual and Developmental Disabilities Research

Edited by Prof. Uner Tan

ISBN 978-953-307-865-6

Hard cover, 404 pages

Publisher InTech

Published online 15, February, 2012

Published in print edition February, 2012

Intellectual and Developmental Disabilities presents reports on a wide range of areas in the field of neurological and intellectual disability, including habitual human quadrupedal locomotion with associated cognitive disabilities, Fragile X syndrome, autism spectrum disorders, Down syndrome, and intellectual developmental disability among children in an African setting. Studies are presented from researchers around the world, looking at aspects as wide-ranging as the genetics behind the conditions to new and innovative therapeutic approaches.

How to reference

In order to correctly reference this scholarly work, feel free to copy and paste the following:

Wataru Kakuda and Masahiro Abo (2012). Functional MRI-Based Strategy of Therapeutic rTMS Application: A Novel Approach for Post-Stroke Aphasic Patients, Latest Findings in Intellectual and Developmental Disabilities Research, Prof. Uner Tan (Ed.), ISBN: 978-953-307-865-6, InTech, Available from:
<http://www.intechopen.com/books/latest-findings-in-intellectual-and-developmental-disabilities-research/functional-mri-based-strategy-of-therapeutic-rtms-application-a-novel-approach-for-post-stroke-aphasi>

INTECH
open science | open minds

InTech Europe

University Campus STeP Ri
Slavka Krautzeka 83/A
51000 Rijeka, Croatia
Phone: +385 (51) 770 447
Fax: +385 (51) 686 166
www.intechopen.com

InTech China

Unit 405, Office Block, Hotel Equatorial Shanghai
No.65, Yan An Road (West), Shanghai, 200040, China
中国上海市延安西路65号上海国际贵都大饭店办公楼405单元
Phone: +86-21-62489820
Fax: +86-21-62489821

© 2012 The Author(s). Licensee IntechOpen. This is an open access article distributed under the terms of the [Creative Commons Attribution 3.0 License](#), which permits unrestricted use, distribution, and reproduction in any medium, provided the original work is properly cited.

IntechOpen

IntechOpen