

We are IntechOpen, the world's leading publisher of Open Access books Built by scientists, for scientists

6,900

Open access books available

186,000

International authors and editors

200M

Downloads

Our authors are among the

154

Countries delivered to

TOP 1%

most cited scientists

12.2%

Contributors from top 500 universities



WEB OF SCIENCE™

Selection of our books indexed in the Book Citation Index
in Web of Science™ Core Collection (BKCI)

Interested in publishing with us?
Contact book.department@intechopen.com

Numbers displayed above are based on latest data collected.
For more information visit www.intechopen.com



Laparoscopic Transperitoneal and Retroperitoneal Nephrectomies in Children: A Change of Practice

Julio J. Báez¹, Gaston F. Mesples² and Alfredo E. Benito³

¹*Department of Pediatric Surgery and Pediatric Urology
Municipal Children's Hospital of Cordoba, National University of Cordoba, Cordoba*

²*Department of Pediatric Surgery and Pediatric Urology
Childrens Hospital Dr Lucio Molas, La Pampa*

³*Editor, Scientific Photography Specialist
Editorial Director of Recfot, Recursos Fotográficos - Córdoba
Argentina*

1. Introduction

Over the past decade, nothing has changed the practice of pediatric urology as much as the expansion in the minimally invasive techniques for routine operations. The breadth of urologic pathology, which can be managed via the laparoscopic approach, continues to expand as technologies and surgical experience mature.

Mounting evidence has demonstrated that for many urologic procedures, pathology can be managed efficiently and effectively while significantly decreasing the pain and convalescence, traditionally associated with ablative and reconstructive open urologic procedures. The blossoming of laparoscopic surgery within urology has resulted in some challenges as the most common procedure, laparoscopic nephrectomy, remains technically demanding. The total nephrectomy with or without ureterectomy, might be indicated for multicystic dysplastic kidney, for destructed kidney by obstructive uropathy and for small kidney with hypertension. We discuss after the usefulness to remove or not multicystic dysplastic kidneys but this congenital malformation represents an excellent indication to begin our experience with laparoscopic surgery because the dissection is easy and hemostasis problems are quite nil.

Laparoscopic nephrectomy offers distinct benefits over standard open nephrectomy for nonmalignant disease in terms of cosmesis, reduced postoperative stay and less need for analgesia, and has become an increasingly popular method since its first report by Clayman et al in 1991 (Clayman et al., 1991) in adults and by Figenshau and associates in 1994 in children (Figenshau et al., 1994).

With the evolution of the endoscopic and minimally invasive techniques these conventional incisions have either been abandoned or significantly modified to reduce the morbidity to the child.

Renal dysplasia is a common kidney disorder, frequently associated with congenital uropathy that leads to renal failure in children with an incidence estimated in 1:3000 to

1:4300; they may arise de novo (primary) or be found in association with congenital obstruction of the urinary tract or vesico-ureteric reflux (VUR) (secondary).

The histologic term defining a malformed part or the whole kidney and the presence of primitive ducts lined with undifferentiated columnar epithelium and surrounded by undifferentiated fibromuscular collar with sometimes metaplastic elements such as cartilage. (Figure 1)

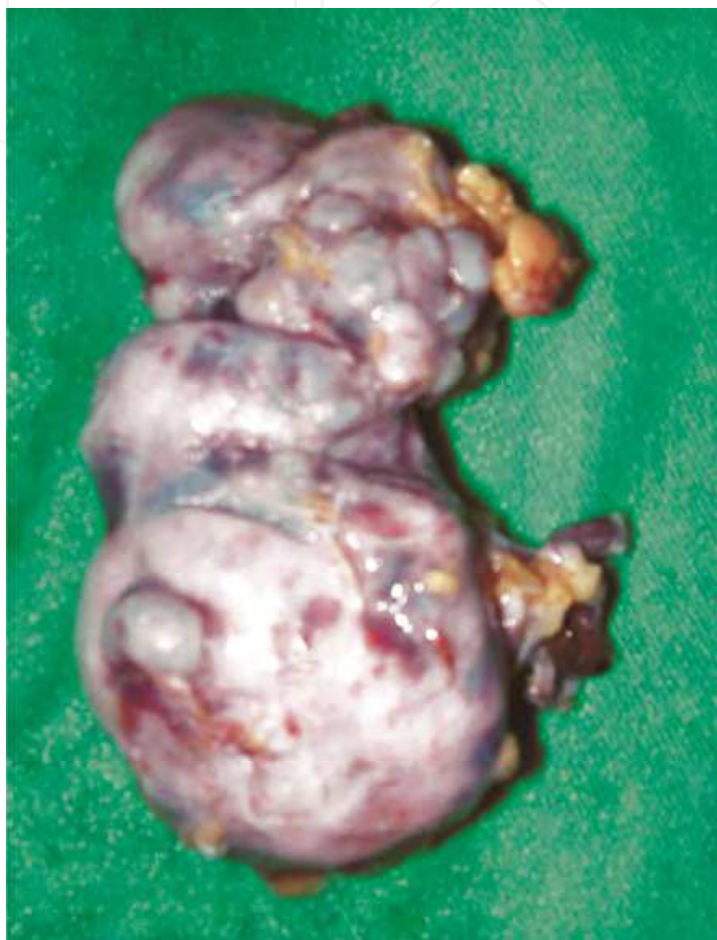

Fig. 1. Renal dysplasia is a kidney disorder defined as a malformed part or the whole kidney and the presence of primitive ducts lined with undifferentiated columnar epithelium and surrounded by undifferentiated fibromuscular collar with sometimes metaplastic elements such as cartilage.

In 1936, Schwartz (Schwartz, 1936) was the first to describe a "unilateral multicystic kidney in a specimen removed from a 7 month old boy suspected to have Wilms tumor or massive hydronephrosis.

In 1964 Pathak and Williams (Pathak & Williams, 1964) added the descriptive term dysplastic to these lesions citing the presence of embryonic mesenchyme and primitive renal components (cartilage and muscle).

Despite the frequent occurrence of renal dysplasia in association with obstructive uropathy, its pathogenesis remains unknown.

Abnormal metanephric differentiation in cases of renal dysplasia results in abnormal renal organization and poor development of renal elements.

Felson and Cussen (Felson & Cussen, 1975) in 1975 viewed the multicystic kidney as an extreme form of hydronephrosis that occurs secondary to atresia of the ureter or renal pelvis.

Cystic dysplasia of an entire upper pole can be seen in kidneys with duplicated collecting systems, especially associated with ureteroceles and bilateral cystic dysplasia also may be seen secondary to posterior urethral valves.

Shibata and Nagata (Shibata et al., 2001) report that nephron induction with filtrating function occurs before the development of cysts; early fetal urinary tract obstruction causes cystic formation in the developing nephrons, which subsequently disrupts nephron induction and tubular development and also cited the importance of abnormalities in the activity of transcription factor PAX2 and antiapoptosis protein bcl2 in the pathogenesis of renal dysplasia.

Matsell and colleagues (Matsell et al., 1996) propose that it may be abnormalities in branching of the ureteral bud that are responsible for progressive local histopathologic changes, supported by previous findings of abnormal metanephric development with ectopic ureteral orifices reported by Mackie and Stephens (Mackie & Stephens, 1975).

More recently, Spencer and Maizel (Spencer & Maizel, 1987) discovered that alterations in ureteral epithelial and mesenchymal cells by inhibition of glycosylation of the extracellular matrix could induced dysplasia without obstruction, that support the theory that dysplasia is the result of disruption in normal epithelial-mesenchymal interaction during the induction of renal tubules.

Recent studies have focused on finding the genes involved with renal development whose abnormal expressions are responsible for renal dysplasia.

Classically, kidney malformations including dysplasia are classified based on histology.

Recent advances in molecular biology and genetics have led Woolf and Winyard (Wolf & Winyard, 1998) to suggest a more straightforward classification to describe kidney malformations. The abnormalities can be divided into groups, based on the underlying cell biology, such as aberrant early development or defect in terminal maturation (Winyard & Chitty, 2001). The aberrant early development group, include dysplastic kidneys, whether large multicystic dysplastic kidneys or small organs with combination of hypoplasia-dysplasia and some obstructed kidneys.

Defects in terminal maturation are observed in polycystic kidney disease.

This category of renal disease is usually not associated with an obstructive uropathy and is mainly managed by nephrologists for the development of renal failure and hypertension. Dysplastic kidneys can be any size, ranging between massive kidney with multiple large cyst up to 9 cm, to normal or small kidneys with or without cyst. (figure 2)

Dysplasia can be unilateral, bilateral, or segmental affecting only part of the kidney.

2. Diagnosis

The current classic presentation is the prenatal sonographic diagnosis, that could be made at 15 weeks of gestation, with typical appearance of multiloculated abdominal mass consisting of multiple thin walled cysts, which do not appear to connect, or circumferential cysts in kidneys of more normal size, associated with lower urinary tract obstruction, particularly in bilateral cases.

The amniotic fluid volume is usually normal in unilateral cases and with oligo or anhydramnios in bilateral cases. Small kidneys are difficult to detect prenatally and are

commonly misdiagnosed as renal agenesis. Even with evident prenatal diagnosis, a post natal follow up is needed to confirm the diagnosis and search for associated anomalies (heart, spine, extremities, face, and umbilical cord, as up to 35% may have extrarenal anomalies and these are more frequent in bilateral disease).

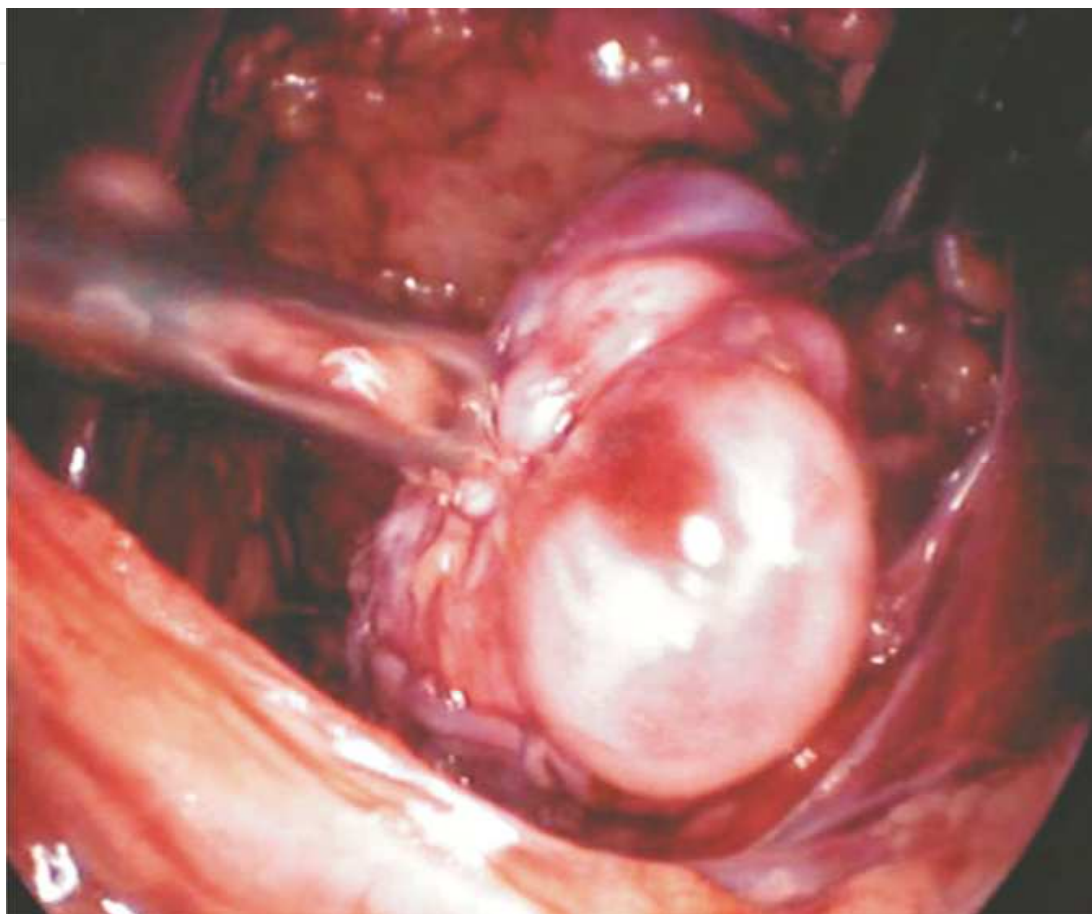


Fig. 2. Dysplastic kidneys can be any size, ranging between massive kidney with multiple large cyst up to 9 cm, to normal or small kidneys with or without cyst (typical multicystic dysplastic kidney appearing as a "bunch of grapes").

Previously before the routine antenatal ultrasound, the diagnosis was most often made in infancy in the presence of a palpable abdominal mass, which is found in 22% to 37% of the cases(12-13), flank pain, urinary tract infection or hypertension.

Ultrasound in combination with renal scintigraphy yields an accurate diagnosis of MCDK disease in 93% of suspected cases (Stuck et al., 1982).

Stuck et al have characterized ultrasound features of dysplastic kidney: presence of sharp interfaces between multiple, randomly arranged, and variable size cysts, the largest with nonmedial location; a lack of an identifiable renal sinus; and an absence of renal parenchyma (Strife et al., 1993). (figure 3)

Parenchymal imaging with Tc99m DMSA provide an excellent picture of functional parenchyma or defects indicating nonfunctioning parenchyma, but it has the inability to assess the excretory phase of renal function that makes it impossible to distinguish MCDK from hydronephrosis caused by UPJ obstruction. (Koff et al., 1980; Tyrrell et al., 1994) (figure 4)

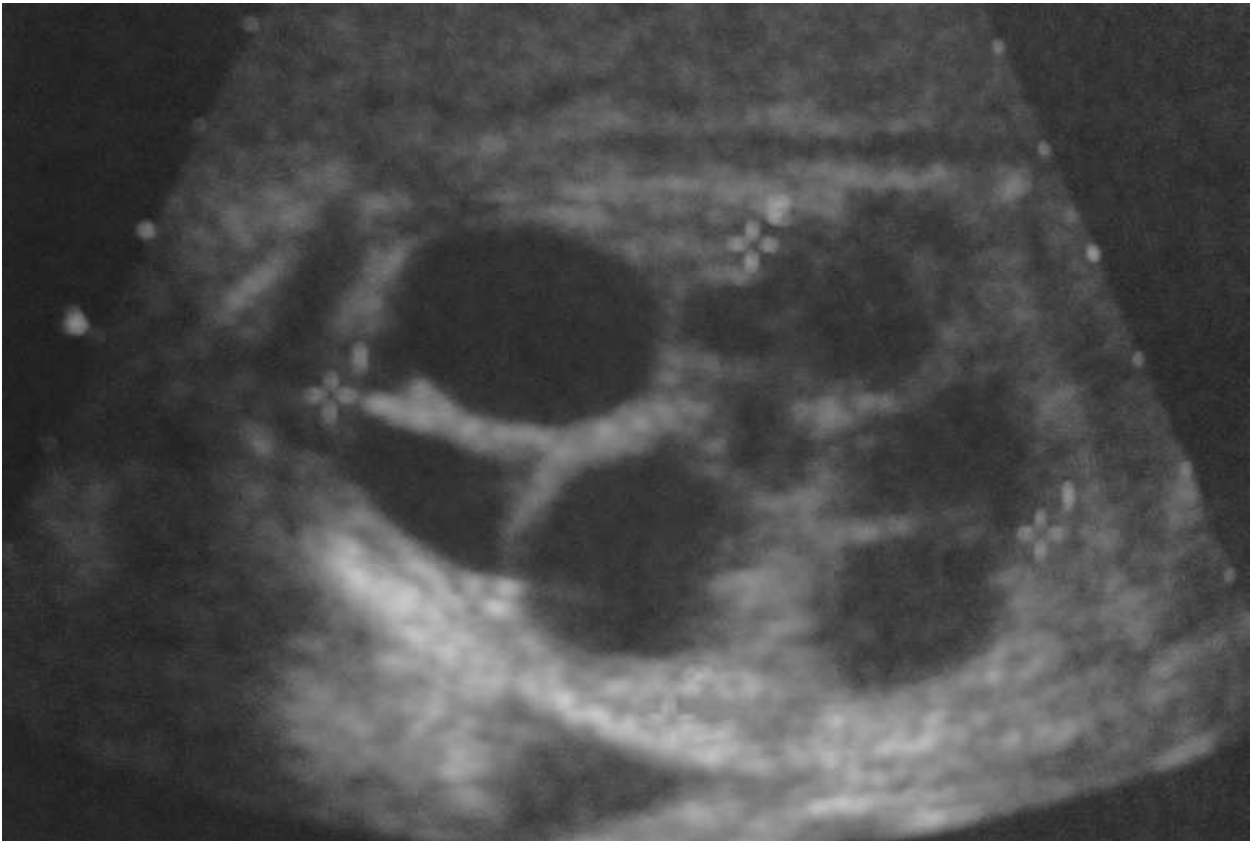

Fig. 3. Prenatal sonographic diagnosis of M.C.D.K. (presence of sharp interfaces between multiple, randomly arranged, and variable size cysts, the largest with nonmedial location; a lack of an identifiable renal sinus; and an absence of renal parenchyma).

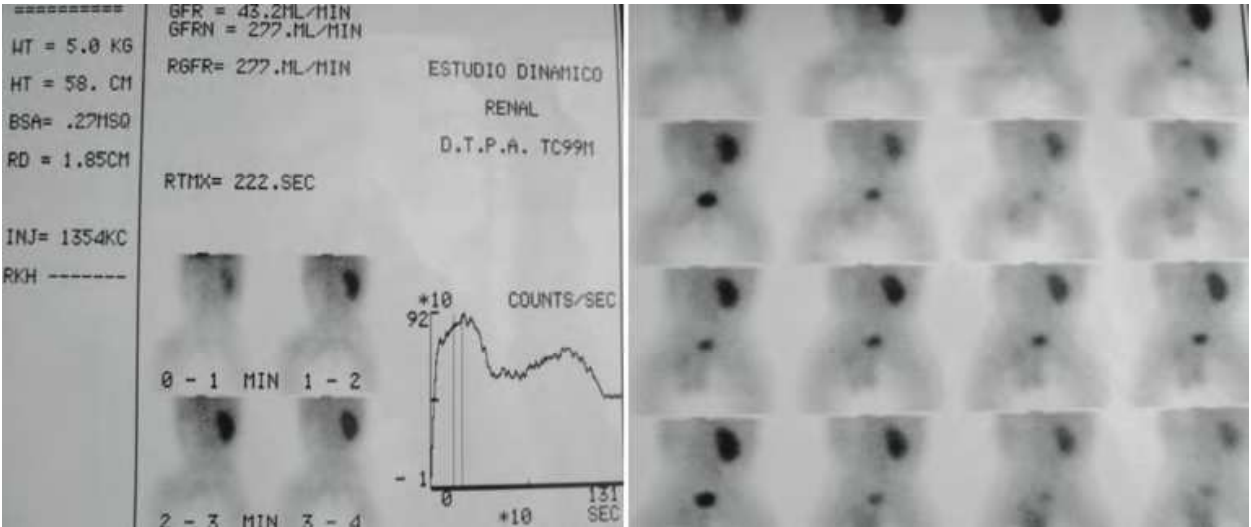


Fig. 4. Renal scintigraphy. All the kidneys removed showed renal function lower than 10% in D.T.P.A. (Parenchymal imaging with Tc 99mDMSA provide an excellent picture of functional parenchyma or defects indicating nonfunctioning parenchyma, but it has the inability to assess the excretory phase of renal function that makes impossible distinguish MCDK from hydronephrosis caused by UPJ obstruction).

If the diagnosis is unclear, a Nephro TAC or Uro MRI to differentiate MCDK from obstructive uropathy or duplex system is performed. (figure 5) (figure 6)

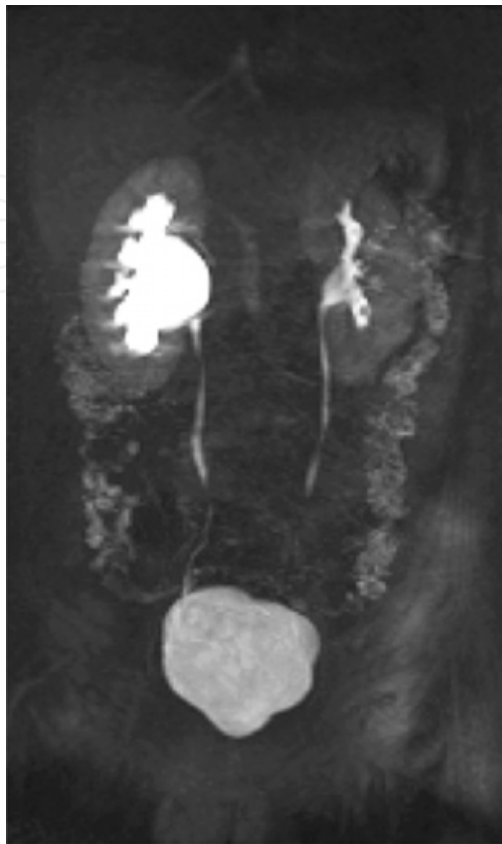

Fig. 5. Hydronephrosis in the right kidney with ureteropelvic junction obstruction by Uro MRI.

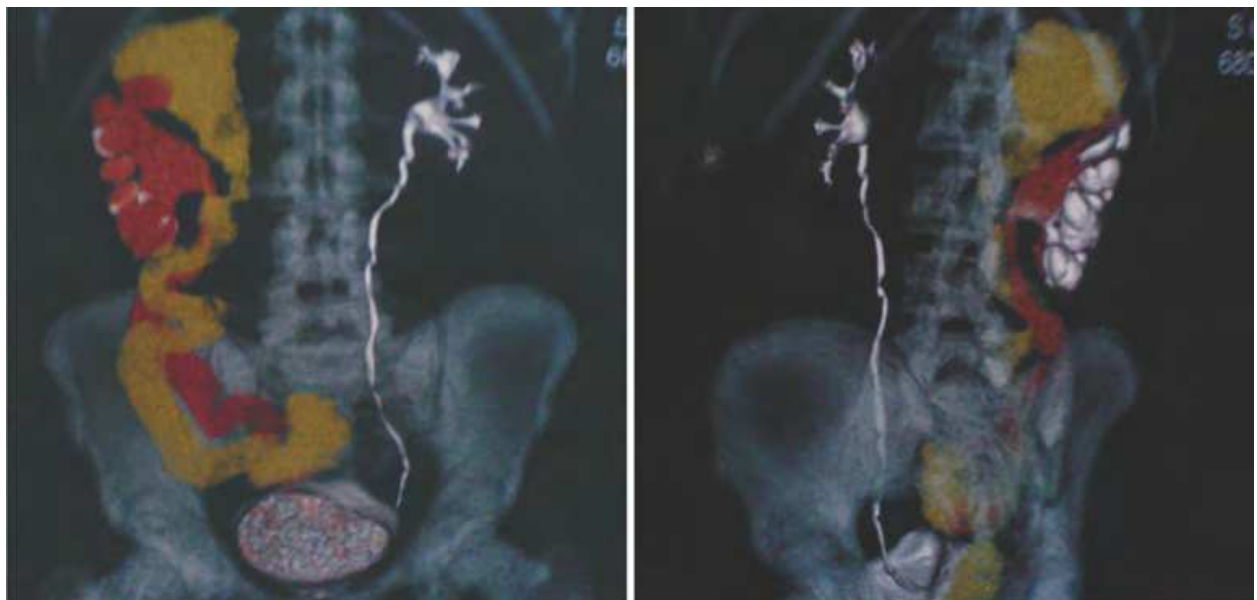


Fig. 6. Nephro TAC with 3 D reconstruction to differentiate MCDK from obstructive uropathy or duplex system.

Complete evaluation include VCUG; contralateral v.u.r has been reported to be associated in 15% to 28% of cases in literature.(Al-Khaldi et al., 1994; Aslam & Watson, 2006; Atiyeh et al., 1992; Karmazyn & Zerin, 1997) (figure 7)

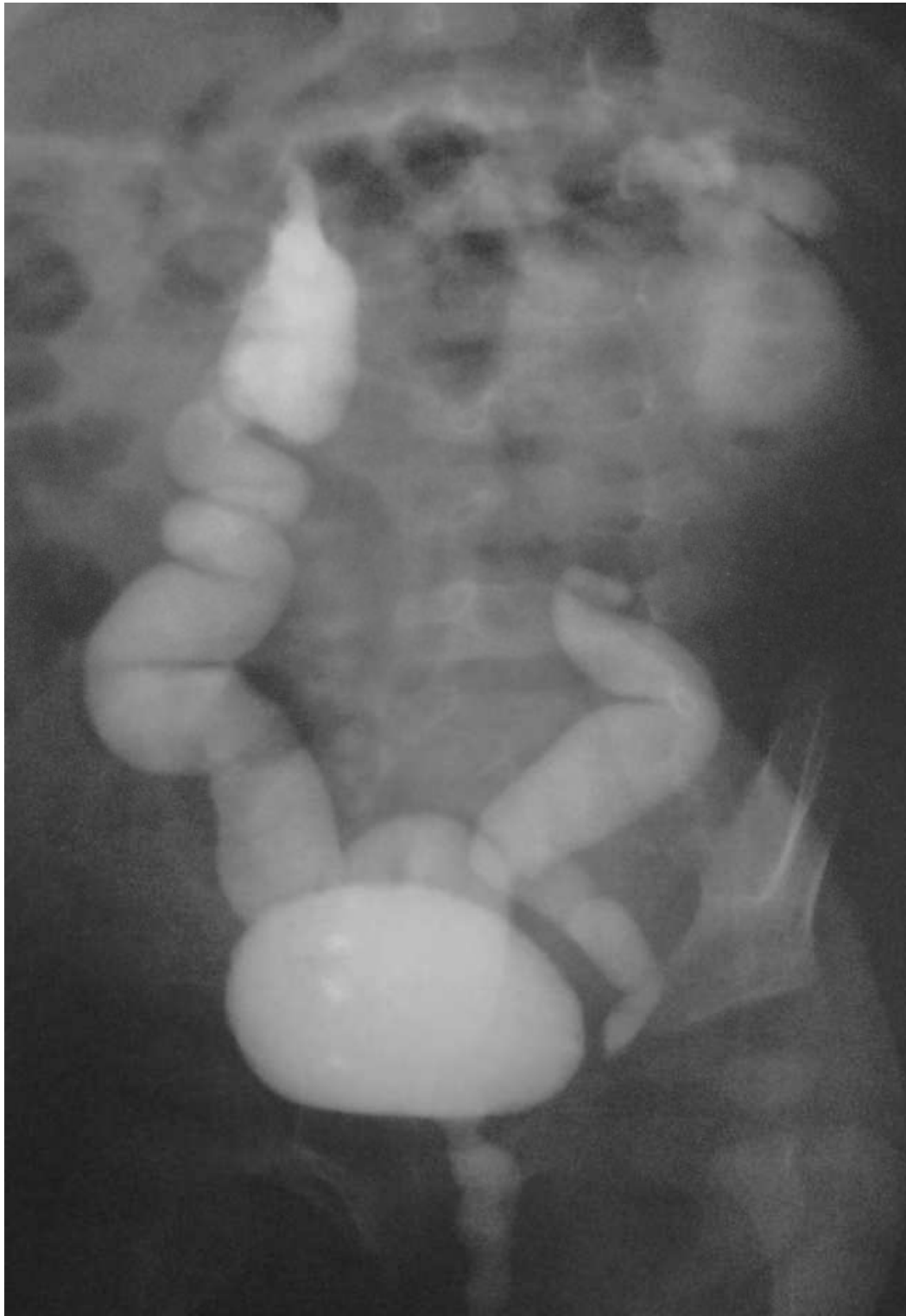

Fig. 7. Contralateral V.U.R has been reported to be associated in 15% to 28% of cases of M.C.D.K. in literature.

The improvement in our understanding of the natural history of some congenital renal anomalies, such as multicystic dysplastic kidney (MCDK), has caused some changes in management approach.

The treatment of MCDK has passed through different phases. It was originally suggested that dysplastic kidneys must be removed to avoid rare complications such as hypertension, infection or possible malignant transformation until the mid-1980s.

In the last decade, there has been a shift in the management of dysplastic kidneys from surgical removal to a conservative approach using serial US examination (Wacksman & Phipps, 1993; Gordon et al., 1988). This change in treatment is due to the perception that malignant transformation is a rare occurrence, and sequential US imaging of a large number of infants diagnosed with this problem has revealed that most of these structures involute over time without causing any problems.

In 2001 Oliveira et al found partial involution in 68%, complete involution in 21% and increase in unit size in 11%. The mean age at complete or partial involution of the lesion was 18 months.

In unilateral cases, there is often a compensatory hypertrophy of the contralateral kidney. (Oliveira et al., 2001)

In recent years, the argument has emerged again with regard to the management of dysplastic kidneys; several studies have recommended surgical removal because the natural history of the condition in the long term is still uncertain, and nephrectomy is more cost effective than conservative management, however an elective nephrectomy is no longer routinely performed in most of centers.

Patients with bilateral disease or associated genitourinary anomalies had a higher incidence of urinary tract infection and progression to renal failure (22% with obstruction and 14% with contralateral reflux). Rare complications as pain was reported as the only symptom in older patient with resolution after nephrectomy. (Ambrose et al., 1982)

Holloway et al report a huge cyst, that need percutaneous decompression to relieve the respiratory distress in infant. (Holloway & Weinstein, 1990)

In the registry of the American Academy of Pediatrics for dysplastic kidney 2.6% were associated with infection, hypertension was found in less than 1% (older reports have demonstrated its resolution after nephrectomy).

Seeman et al (Seeman et al., 2001), monitored blood pressure in children and found anomalies only in those who had ultrasonographic, and or laboratory signs of contralateral kidney abnormalities.

In children neoplasia represents 25% of indications. This is to be expected in view of the higher incidence of malignancy in older patients and the higher proportion of children who present with congenital malformations. In a review of the literature, Perez (Perez et al., 1998) found multiple reports of malignancy arising in MCDK, including renal cell carcinoma (5 cases), malignant mesothelioma (1 case) and Wilms tumor (11 cases).

Narchi (Narchi, 2005) performed a systematic review of the literature managed conservatively; no children developed a Wilms tumor. But there is another argument favouring the association between Wilms tumor and MCDK; the finding of nephrogenic rest, recognized as precursors to nephroblastoma, which may remain quiescent or become hyperplastic, forming a nodule (adenomatous focus or nodular renal blastema) is possibly an early stage in tumor formation. (Beckwith et al., 1990)

Even though this association or the malignant degeneration is exceptional, a careful initial ultrasound examination is mandatory and any equivocal diagnosis with suspicious nature of the cyst should lead to surgical removal of the kidney.

Conservative follow up includes renal ultrasound every 3 to 4 months to age 3 years, every 6 months to age 5 years, and then every year to age 8 years. (Onal & Kogan, 2006)

The regimen would be costly when considered on a level compared with early nephrectomy. In some cases close long term follow up, with ultrasound and physical examination may be easier said than done, and rigid compliance may be unrealistic. In these cases, early surgical excision may be the best treatment.

We thought it pertinent to assess the effects of the last changes on the indications for nephrectomy in the paediatric age group.

A literature review revealed a limited number of publications on the indications for nephrectomy in children.

A few reports reviewed the indications in various age groups without any special mention of paediatric patients (Scott (Jr) & Selzman, 1966; Beisland et al., 2000).

Others reported on a small number of nephrectomies in children (Schmidt et al., 1992; Pearlman & Kobashigawa, 1968).

Laparoscopic nephrectomy offers advantages similar to the retroperitoneal approach for open surgery; Hamilton et al (Hamilton et al., 2000) found comparable results on transperitoneal laparoscopic nephrectomy with significant decrease in hospital stay after laparoscopic compared with open nephrectomy (22.5 vs 42.3 hours) with longer operative time in laparoscopic group (175.6 vs 120.2 min).

In laparoscopy the peritoneal cavity and its contents are avoided, minimizing risk of injury that may occur when mobilizing bowel, and avoiding potential future complications associated with intraperitoneal adhesions.

Here, we report our initial series of laparoscopic nephrectomies in paediatric patients, their indications, and the clinical presentation of this particular group of patients with various renal abnormalities that required nephrectomy.

In our experience, most MCDK's have ultimately been removed, reflux nephropathy was the second major indication for nephrectomy; whether VUR is associated with congenital dysplasia/hypoplasia that is not amenable to any form of postnatal therapy, or whether this form of treatment is unsuccessful in preventing further renal damage; has yet to be clarified.

The decrease in the proportion of nephrectomies performed for PUJ (third main indication) obstruction is probably due to the vigorous use of antenatal scan to detect these cases as early as possible thus allowing proper follow up and intervention when required.

This is in agreement with the findings of Capolicchio and colleagues who demonstrated that early diagnosis of hydronephrosis provided by prenatal Ultrasonography is associated with less obstructive nephropathy (Capolicchio et al., 1999).

Laparoscopy is considered to be the standard technique in performing nephrectomies in children with renal benign disorders.

Many studies have shown the advantage of this, against open technique.

Nowadays, a laparoscopic nephrectomy can be performed in two ways, transperitoneal or retroperitoneal. (Collar R et al., 2001; Baez et al., 2003)

The first laparoscopic nephrectomy was performed by Clayman in 1991 using the transperitoneal technique on an 85 years old female patient.

The first to perform a retroperitoneoscopy with insufflation were Roberts (Roberts, 1976) in 1978 and Wickham (Wickham & Miller, 1979) in 1979.

Gaur and Kerbl in 1992 published the first cases of retroperitoneal laparoscopic nephrectomies in adults (Gaur et al., 1993; Kerbl et al., 1993), whereas Chandoke, Rassweiller and Valla did

the same with children in 1993, 1994 and 1996 respectively. (Chandhoke et al., 1993; Rasweiller et al., 1994; Valla et al., 1996)

Since then a large amount of result have been published using both laparoscopic nephrectomy techniques.

The renal benign disorder continues to be the main indication for nephrectomy in children for non-functioning kidneys secondary to obstructive uropathy or reflux. Although laparoscopy nephrectomy is an easy and safe procedure, the indications for nephrectomy are still debatable. The acceptable indications for these cases are the increase in size of cysts or the rare complications of hypertension and infection.

Malignant renal tumors in children are not considered for laparoscopy (the most common is nephroblastoma that is large in size, frequently extending outside the kidney and with high risk of rupture during dissection), although recently cases of extractions of kidneys tumors have been published using both techniques. (Duarte et al., 2004; Etcheverry et al., 2002) In spite of this we have not included in our statistics oncologist indications, and in not one of the extracted materials malignant signs of tumors were found.

3. Technique

For the transperitoneal approach ,with patient in dorsal decubitus three ports were placed, one in the navel (10 mm optic device)the second and third ports(5 mm working ports) on the half clavicular line below the rib cage ,and one the same side, 2 cms above the level of the superior iliac spine; respectively; has shown the advantage of working in a wide space and with easier identifiable anatomic repairs and a more direct view of intraabdominal organs to avoid, and the umbilical port is well concealed, particularly for specimen removal. Nevertheless the access to the renal hilar region requires a considerable mobilization and retraction of the bowel.

Like other adult and paediatric surgeons (Lorenzo Gomez & Gonzales, 2003) used to working laparoscopically in the abdominal cavity, we opted for the transperitoneal approach to start our experience, which could affect the final results because these were the first patients in our learning curve.

Retroperitoneoscopic nephrectomy in children has several advantages over transperitoneal approaches .There is less risk of injury to adjacent organs such as the bowel, liver or spleen, with little risk of formation of intraperitoneal adhesions; and the retroperitoneum can be drained more effectively than the peritoneum.

Guilloneau and col demonstrated a lesser average time in performing nephrectomies by lumboscopy and comparing them with the laparoscopic approach (Guilloneau et al., 1996) this probably due to a direct entry via retroperitoneal in the renal cell without the necessity of abdominal dissection.

Lorenzo Gomez and R Gonzales, carried out an investigation comparing more than 330 procedures performed using both methods, were, the operating time for the retroperitoneal approach was also less. (Lorenzo Gomez & Gonzales, 2003)

The retroperitoneal approach needs a good anatomical knowledge that has been viewed by Himpens (Himpens, 1996). It has the disadvantage of smaller active space with an absence of intraabdominal structures easy to recognize like the liver or spleen. At the same time provides a direct and faster to the renal hilus avoiding bowel manipulation that could produce ileus and delay the recovery of the patient.

By this direct access to the kidney in an anatomic orientation with gravity facilitating exposure of the renal hilum, the artery lies posterior so it can be controlled without manipulating the vein, and this allows control of arteries prior to veins, according to the accepted practice, to prevent engorgement of the kidney and easier control of veins with less blood in them. The renal pelvis is posterior as well facilitating mobilization and exposure as needed. If open access to the kidney becomes urgent, it can be performed through a lumbotomy incision.

With the patient in the lateral decubitus and hyper extension of the problem side getting a better active place, on the lower end of the 12th rib a 10 mm port were placed for optic device, and the two working 5 mm ports, one above the of the iliac crests upper line and the other resting the external side of the lumbar complex muscle equidistant to the others. (figure 8)

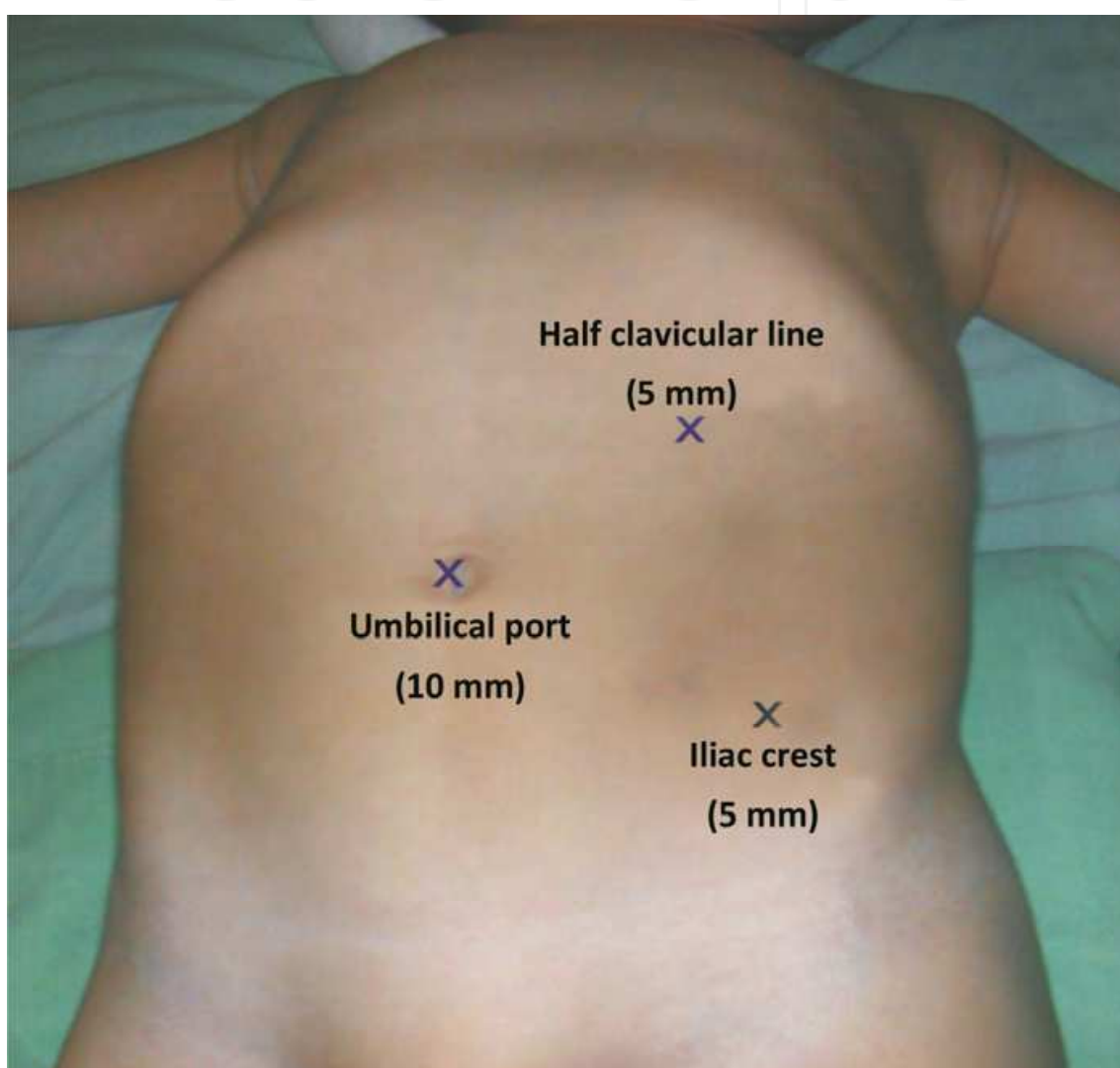


Fig. 8. Patient positioning for transperitoneal approach with the surgeon standing in the front of the abdomen, the child is positioned with the flank of the involved side elevated at 30 degree angle to facilitate the exposure after reflecting the colon. Three ports were placed, one in the navel (10 mm optic device) the second and third ports (5 mm working ports) on the half clavicular line below the rib cage ,and one the same side, 2 cms above the level of the superior iliac spine; respectively. A fourth trocar could be placed in the midaxillary line for exposure to retract the liver or spleen if needed.

After the introduction of the 10 mm port, the two main landmarks- anterior part of the psoas muscle and the lower pole of the kidney, mobile with respiration-are recognized. (figure 9)

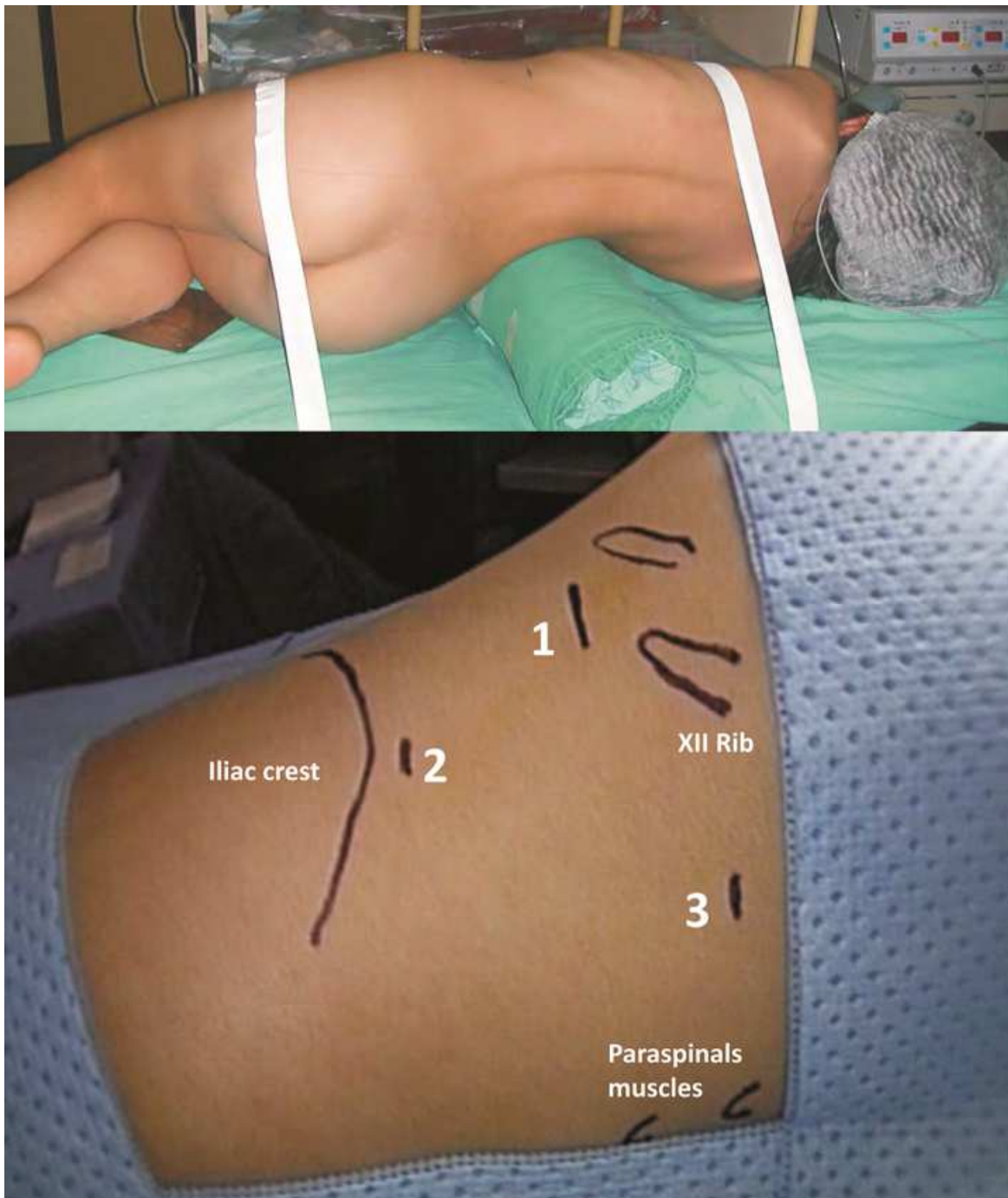


Fig. 9. Position for retroperitoneal approach. The patient is placed in the lateral decubitus position, exposing the involved side as in position for an open simple nephrectomy, with sufficient flexion of the operating table so as to expose the area of trocars placement: on the lower end of the 12th rib a 10 mm port were placed for optic device, and the two working 5 mm ports, one above the iliac crests upper line and the other resting on the external side of the lumbar complex muscle equidistant to the others.

The working space is progressively created by moving the tip of the telescope to free retroperitoneal fibrous tissues, taking care not to injury the peritoneum.

After the two faces and the two poles are completely freed, the kidney is mobilized to the top, and the renal vessel dissected via posterior approach, in the inferior part of the field where there are only one artery and one vein and not too close to the kidney where the vessels are divided in several branches. (figure 10)

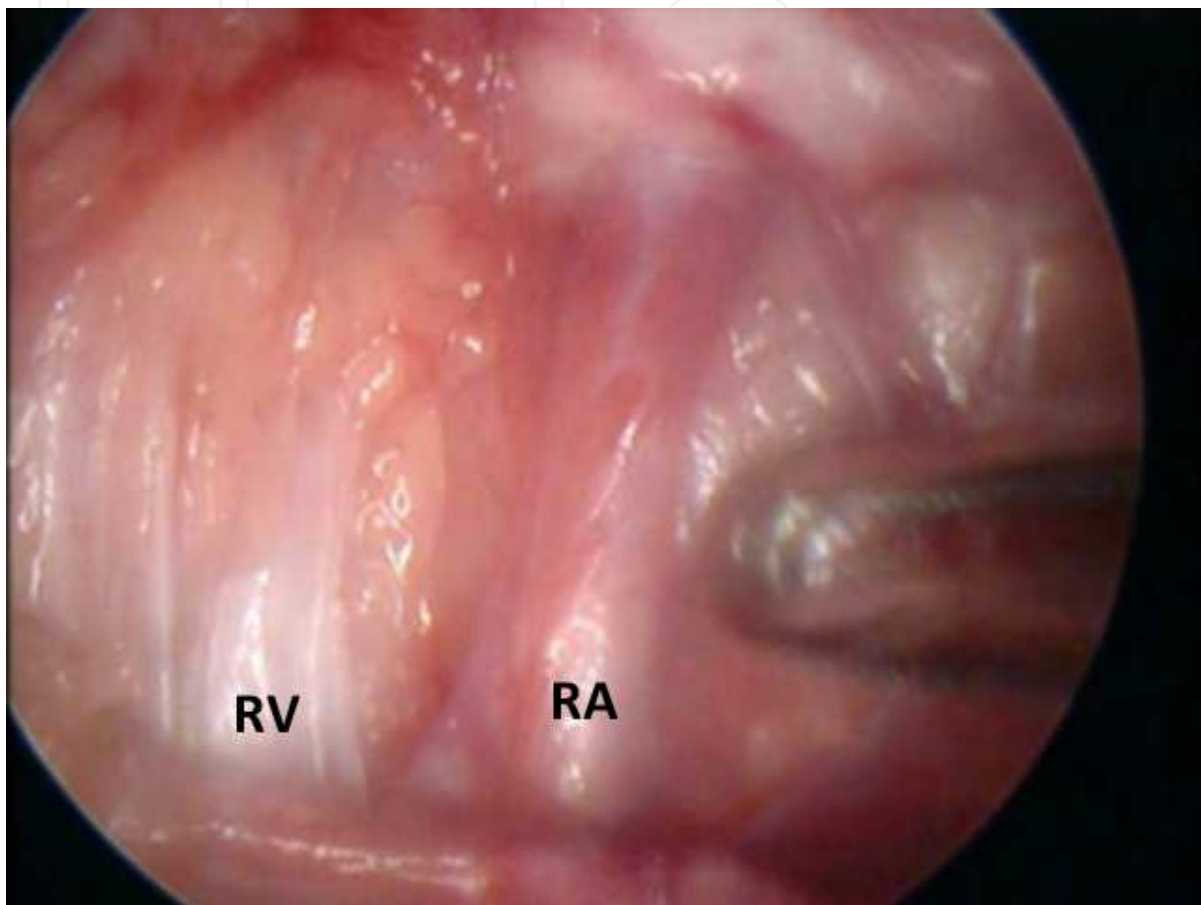


Fig. 10. Exposure and ligature of the renal pedicle which is identified and approached posteriorly. The kidney drops under gravity keeping the vessels under stretch. This allows careful two-instrument dissection of the vascular pedicle. At the left side the artery is dissected close the junction with the aorta and vena cava, and at the right side the renal vein is also exposed of it full length.

If the ilium dissection is difficult the ureter may serve as main reference it's easy to recognize in the retroperitoneal space and its dissection up to the kidney leads to the renal vessels.

After dissection of the renal pedicle, the vessels are clipped, ligated or coagulated, depending of the vessel diameter and the surgeon experience. (figure 11)

The ureterectomy could be limited to the lumbar portion in non-refluxing ureter; in presence of reflux or dilated ureter the dissection is distally followed and the ureter is ligated s close as possible to the ureterovesical junction.

For the material extraction in all cases the renal tissue was sufficiently thin enough to allow the extraction through the incision of the initial port without morcellation. (figure 12)

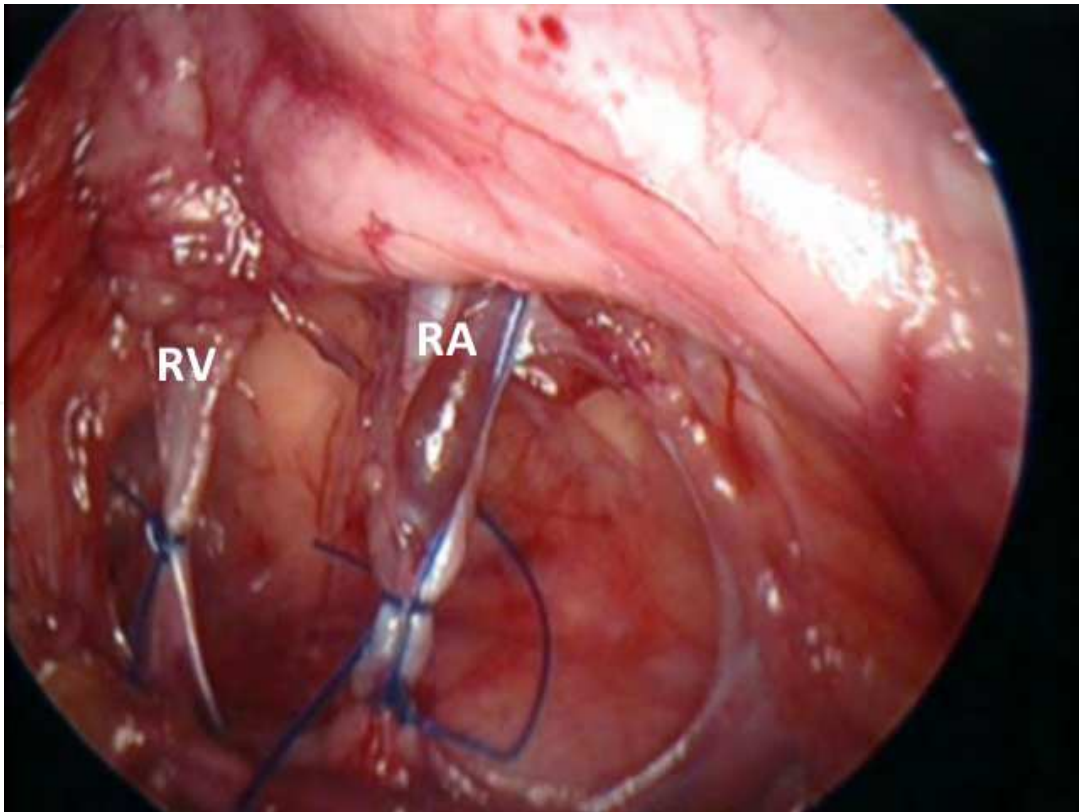


Fig. 11. After dissection of the renal pedicle, the vessels could be clipped, ligated or coagulated depending of the vessel diameter and the surgeon experience (in this case ligation of the renal pedicle with extracorporeal knots).

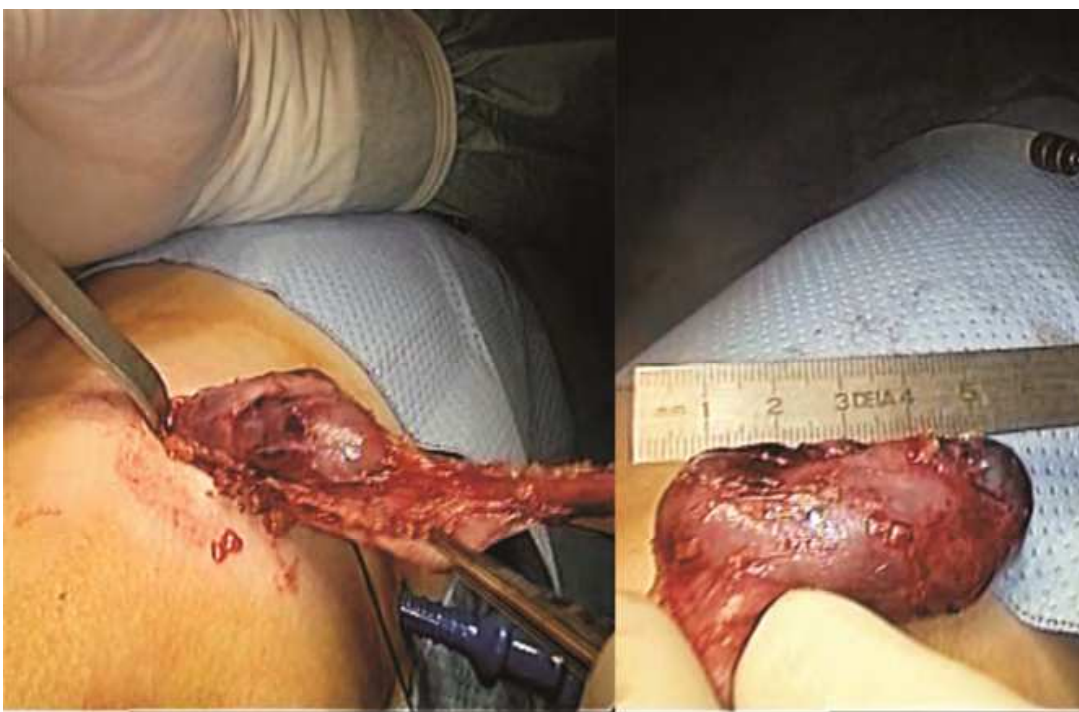


Fig. 12. For the material extraction in all cases the renal tissue was sufficiently thin enough to allow the extraction through the incision of the initial port without morcellation.

In our initial experience thirty two laparoscopic total nephrectomies were performed. On the beginning of our learning curve the first ten (10) patients were treated using the transperitoneal technique (group 1) whereas the rest using retroperitoneal technique(group 2).The indications for both groups were similar: V.U.R. 4 patients for group 1 and 6 for 2, hydronephrosis 3 patients for T.P. and 6 for R.P. and M.C.D.K. 3 patients for group 1 and 8 patients for group 2. (figure 13)

Indications		
	Group 1	Group 2
V.U.R	4 patients	6 patients
Hydronephrosis	3 patients	6 patients
M.C.D.K.	3 patients	8 patients

Fig. 13. Main surgical indications for laparoscopic nephrectomy by both procedures (V.U.R.: vesicoureteral reflux, M.C.D.K.: Multi Cystic Dysplasic Kidney).

Two patients underwent upper pole laparoscopic heminephrectomies using the retroperitoneal approach have not been included in the final results.

1 case of retroperitoneal had to be converted due to massive hydronephrosis with perirrenal fibrosis.

Rasweiller et al. report a longer operating time in similar cases with a high probability of conversion for severe adhesions and fibrosis (Rasweiller et al., 1998), but Hemal et al. demonstrated that is feasible to perform retroperitoneal nephrectomies with massive hydronephrosis (more than 1000 mL of liquid in system). (Hemal et al., 1999)

But nevertheless like Valla et al. don't recommend the initial retroperitoneal practice on these types of patients. (Valla et al., 1996)

In the other case a transperitoneal nephrectomy changed into an open technique due to a problem with the equipment that occurred during surgery.

In the rest 28 laparoscopic operations performed there were no complications during surgery. During 2 retroperitoneal operations we had peritoneal perforations that did not cause any consequences, emphysema or pneumothorax. Hemodynamic changes and CO₂ diffusion were equal with the two laparoscopic techniques, in our results.

Postoperative management after transperitoneal or retroperitoneal nephrectomy does not require specific cares.

Both approaches were statistically similar with respect to complications during and after surgery, hospitalization and analgesic requirements.

All the patients could eat again within the first 24 hours .However those operated on using the retroperitoneal method were able to eat earlier than those the transabdominal way. It is important to clarify that in the first cases for all laparoscopic surgeries with intraabdominal technique, the post-surgery tolerance could have been delayed because of more conservative approach. Nevertheless 2 patients of the group 1 (T.P.) vomited at 10 and 12 hours after

surgery delaying the return to oral feeding. It is interesting to note, in many publications (Poddoubny et al., 2003; Ehrlich et al., 1994) in nephrectomies performed intraabdominally there are no details of events like nausea or vomiting early on after surgery, despite the fact that all achieve tolerance within the first 12-24 hrs.

A prospective and comparative study by Desai et al (Desai et al., 2005) using both techniques, in 5 out of 50 patients resulted in ileus that lasted longer than 48 hs in transabdominal nephrectomies.

However they could not associate this approach with a large incidence of ileus.

It is for this reason that today in our institution the laparoscopic retroperitoneal approach is the preferred method to perform nephrectomies. Despite this preference we have achieved our learning curve with transperitoneal approach and now we are quite willing to recommend it to those starting urologic laparoscopy.

The main advantage of a retroperitoneal approach is more direct and faster exposure (Doublet et al., 1996) without peritoneal transgression and without dissection and handling of intraperitoneal structures; avoid the risk of shoulder pain, omental evisceration or intestinal adhesions (Moore et al., 1995) and can be easily performed even after previous abdominal surgery.

The retroperitoneal approach had the disadvantage in the lack of natural cavity; the working space should be created with the risk of accidental peritoneal tear (Morgan (Jr) & Rader, 1992; Kumar et al., 2001) that induces pneumoperitoneum and reduces the working space and visibility. This incident could be avoided by careful preparation of the retroperitoneal space for insertion of anterior working ports. If that occurs at the beginning of the procedure, it is useful to close with purse string suture of the perforation or if it not possible, by inserting a Verress needle in the peritoneal cavity to desufflate the pneumoperitoneum continuously during the surgery.

The second disadvantage is that ergonomics of work is less, with reduced surgical field and it requires a greater learning curve and better surgical skills to perform. This problem was exposed by Erlich et al. (Ehrlich et al., 1994) who in the first retroperitoneal surgery stated that the limited working space precluded introduction of other retroperitoneal instrument.

Finally this initial study shows that there is comparable security and efficacy in both approaches but probably there exist specific situations in which a particular method is more suitable.

We believe that the option of the laparoscopic approach for the nephrectomy must depend on the preference and the individual training of each surgeon, and the choice of approach must be in accordance with each clinical situation emphasizing and recommending retroperitoneal procedures while the surgical skills of the surgeon can.

There has been an improvement in our understanding of the natural history of some congenital renal anomalies, such as multicystic dysplastic kidney (M.C.D.K.), which has caused some changes in management approach.

Minimally invasive procedures emphasize our goals of improving patient comfort and safety while adapting the laparoscopic procedures as closely as possible to the conventional surgical techniques. (El-Gonehimi et al., 2002)

Actually laparoscopic is considered to be the standard technique in performing nephrectomies in children with renal benign disorders.

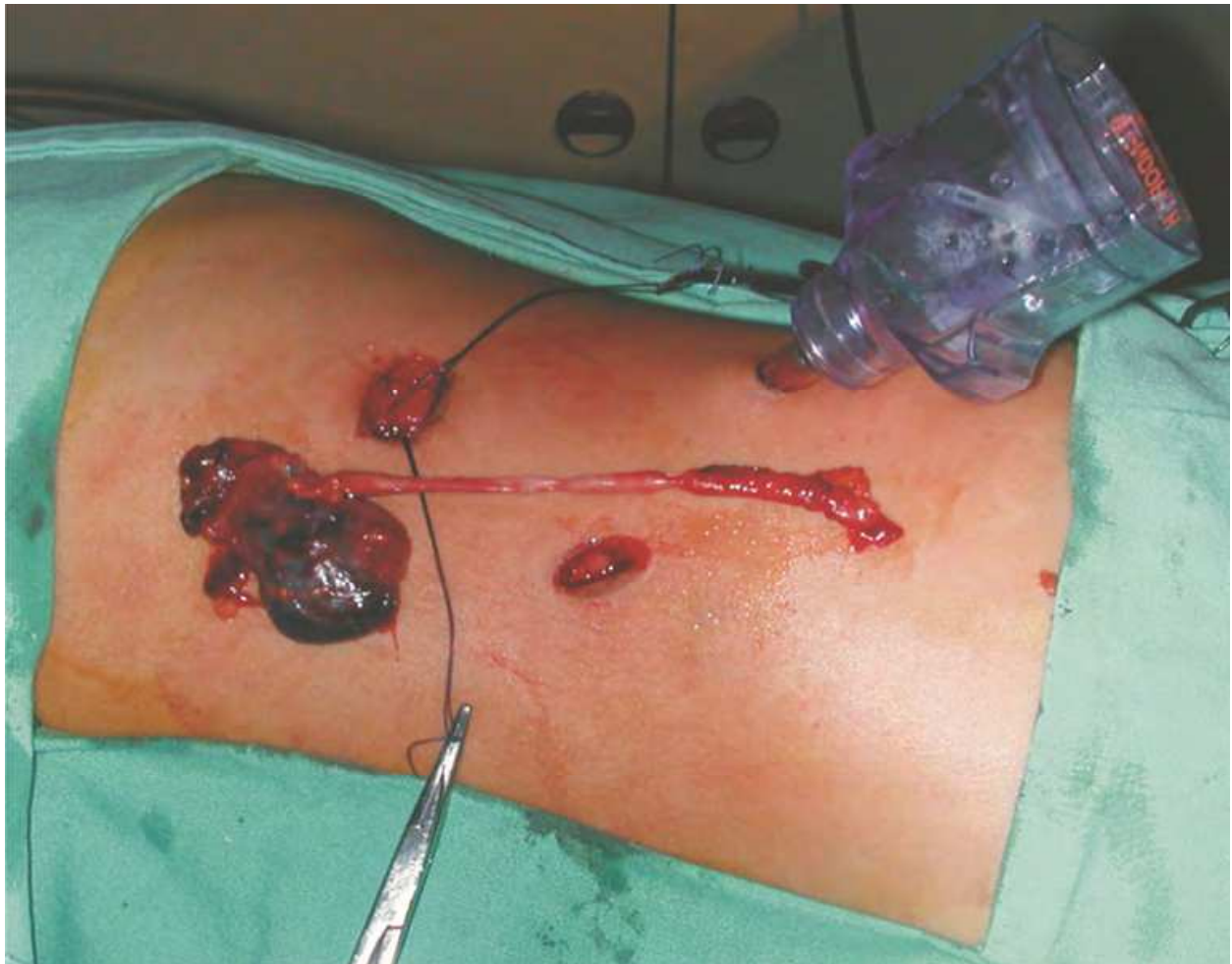

Fig. 14. In our institution the laparoscopic retroperitoneal approach is the preferred method to perform nephrectomies, but there is comparable security and efficacy in both approaches.

Conflict of interest

The authors have nothing to disclose.

Ethical approval

Ethical approval was not required.

4. References

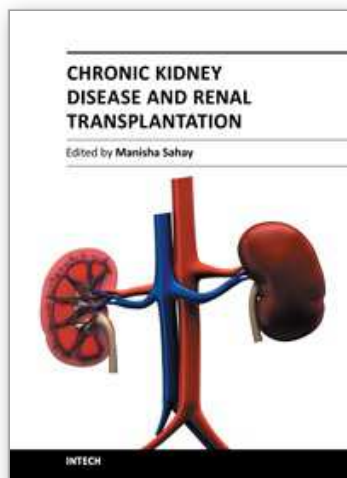
- [1] Clayman RV, Kavoussi LR, Soper NJ, et al (1991). *Laparoscopy nephrectomy*. N Engl J Med; 324:1370.
- [2] Figenshau RS, Clayman RV, Kerbl D, et al (1994). *Laparoscopic nephrectomy in the child: initial report*. J Urol; 151:740-741.
- [3] Schwartz J (1936). *An unusual unilateral multicystic kidney in an infant*. J Urol; 35:259.
- [4] Pathak IG, Williams DI (1964). *Multicystic and cystic dysplastic kidneys*. Br J Urol; 36:318.
- [5] Felson B, Cussen LJ (1975). *The hydronephrotic type of congenital multicystic disease of the kidney*. Semin Roentgenol; 10:113.
- [6] Shibata S, Shigeta M, Shu U, et al (2001). *Initial pathological events in renal dysplasia with urinary tract obstruction in utero*. Virchows Arch; 439:560.

- [7] Matsell DG, Bennett T, Goodyer P, et al (1996). *The pathogenesis of multicystic dysplastic kidney disease: insights from the study of fetal kidneys*. Lab Invest; 74:883.
- [8] Mackie CG, Stephens SD (1975). *Duplex kidneys: a correlation of renal dysplasia with position of the ureteral orifice*. J Urol; 114:274
- [9] Spencer JR, Maizel M (1987). *Inhibition of protein glycosylation causes renal dysplasia in the chick embryo*. J Urol; 138:94.
- [10] Wolf AS, Winyard PJD (1998). *Advances in the cell biology and genetics of human kidney malformations*. J Am Soc Nephrol; 9:114-1125.
- [11] Winyard P, Chitty L (2001). *Dysplastic and polycystic kidneys: diagnosis, associations and managements*. Prenat Diagn; 21:924-935.
- [12] Gordon AC, Thomas DFM, Arthur RJ, et al (1988). *Multicystic dysplastic kidney: is nephrectomy still appropriate?* J Urol; 140:1231.
- [13] Kessler OJ, Ziv N, Livne PM, et al (1998). *Involution rate of multicystic renal dysplasia*. Pediatrics; 102:1472.
- [14] Stuck KJ, Koff SA, Silver TM (1982). *Ultrasonic features of multicystic dysplastic kidney: expanded diagnostic criteria*. Radiology; 143:217.
- [15] Strife JL, Souza AS, Kirks DR, et al (1993). *Multicystic dysplastic kidney in children: US follow-up*. Radiology; 186:785.
- [16] Koff SA, Thrall JH, Keyes (Jr) JW (1980). *Assessment of hydroureteronephrosis in children using diuretic radionuclide urography*. J Urol; 123:531.
- [17] Tyrrell PNM, Boivin CM, Burrell DN, et al (1994). *Multicystic dysplastic kidney: another application of 99mTc MAG3*. Clin Radiol; 49:400.
- [18] Al-Khaldi N, Watson AR, Zuccollo J, et al (1994). *Outcome of antenatally detected cystic dysplastic kidney disease*. Arch Dis Child; 70:520.
- [19] Aslam M, Watson AR (2006). *Unilateral multicystic dysplastic kidney: long term outcomes*. Arch Dis Child; 91:820
- [20] Atiyeh B, Husmann D, Baum M (1992). *Contralateral renal abnormalities in multicystic-dysplastic kidney disease*. J Pediatr; 121:65.
- [21] Karmazyn B, Zerlin JM (1997). *Lower urinary tract abnormalities in children with multicystic dysplastic kidney*. Radiology; 203:223
- [22] Wacksman J, Phipps L (1993). *Report of the Multicystic Kidney Registry preliminary findings*. J Urol; 150:1870e2.
- [23] Gordon AC, Thomas DF, Arthur RJ, Irving HC (1988). *Multicystic dysplastic kidney: is nephrectomy still appropriate?* J Urol; 140(5 Pt 2):1231e4.
- [24] Oliveira EA, Diniz JS, Vilasboas AS, et al (2001). *Multicystic dysplastic kidney detected by fetal sonography: conservative management and follow up*. Pediatr Surg Int; 17:54-7.
- [25] Ambrose SS, Gould RA, Trulock TS, Parrot TS (1982). *Unilateral multicystic renal disease in adults*. J Urol; 128:366-369
- [26] Holloway WR, Weinstein SH (1990). *Percutaneous descompression :treatment for respiratory distress secondary to multicystic dysplastic kidney*. J Urol; 144:113-115.
- [27] Seeman T, John U, Blahova K et al (2001). *Ambulatory blood pressure monitoring in children with unilateral multicystic dysplastic kidney*. Eur J Pediatr; 160:78-83.
- [28] Perez LM, Naidu SI, Joseph DB (1998). *Outcome and cost analysis of operative versus nonoperative management of neonatal multicystic dysplastic kidneys*. J Urol; 160:1207.
- [29] Narchi H (2005). *Risk of Wilms' tumour with multicystic kidney disease: a systematic review*. Arch Dis Child; 90:147.

- [30] Beckwith JB, Kiviat NB, Bonadio JF (1990). *Nephrogenic rests, nephroblastomatosis, and the pathogenesis of Wilms' tumor*. *Pediatr Pathol*; 10:1.
- [31] Onal B, Kogan B (2006). *Natural history of patients with multicystic dysplastic kidney – what follow-up is needed?*. *J Urol*; 176:1607.
- [32] Scott (Jr) RF, Selzman HM (1966). *Complications of nephrectomy: review of 450 patients and a description of a modification of the transperitoneal approach*. *J Urol*; 95:307e12.
- [33] Beisland C, Medby PC, Sander S, Beisland HO (2000). *Nephrectomy e indications, complications and postoperative mortality in 646 consecutive patients*. *Eur Urol*; 37: 58e64.
- [34] Schmidt A, Dietz HG, Schneider K (1992). *Long-term results after partial and unilateral nephrectomy in childhood*. *Eur J Pediatr Surg*; 2:269e73.
- [35] Pearlman CK, Kobashigawa L. *Nephrectomy: review of 200 cases*. *Am Surg* 1968; 34:438e41.
- [36] Hamilton BD, Gatti JM, Cartwright PC, Snow BW (2000). *Comparison of laparoscopic versus open nephrectomy in the pediatric population*. *J Urol*; 163:937-939.
- [37] Capolicchio G, Leonard MP, Wong C, et al (1999). *Prenatal diagnosis of hydronephrosis: impact on renal function and its recovery after pyeloplasty*. *J Urol*; 162:1029e32.
- [38] Collar R, Etcheverry R, Urrutia A, et al (2001). *Nefrectomía laparoscópica retroperitoneal en pediatría*. *Rev de Cir Inf*; 12(2):169-171.
- [39] Baez JJN, Betolli M, Sentagne A, et al (2003). *Nefrectomía vía laparoscópica transperitoneal*. *Rev Cir Inf*; 13(3 y 4): 152-154.
- [40] Roberts JA (1976). *Retroperitoneal endoscopy*. *J Med Primatol*; 5:124-127.
- [41] Wickham JEA, Miller RA. *Urinary calculus disease. The surgical treatment of urolithiasis 1979*: 145-198.
- [42] Gaur DD, Agarwal DR, Purhoit KC (1993). *Retroperitoneal laparoscopic nephrectomy: Initial case report*. *J Urol*; 149: 103-105.
- [43] Kerbl K, Figenshau RS, Clayman RV, et al (1993). *Retroperitoneal laparoscopic nephrectomy: Laboratory and clinical experience*. *J Endourol*; 7:23-26.
- [44] Chandhoke RS, Glansky S, Koyle M, Kaula NF (1993). *Pediatric retroperitoneal laparoscopic nephrectomy*. *J Endourol*; 138(suppl 7): 12.
- [45] Rasweiler JJ, Henkel TO, Stoch D, et al (1994). *Retroperitoneal laparoscopic nephrectomy and other procedures in the upper retroperitoneum using a ballon dissection technique*. *Eur Urol*; 25:229-236.
- [46] Valla JS, Guilloneau B, Montupet Ph, et al (1996). *Retroperitoneal laparoscopic nephrectomy in children: preliminary report of 18 cases*. *It J Ped Surg Sci*; 10(1-2):35-37.
- [47] Duarte JD, Denes F, Cristofani LM, et al (2004). *Laparoscopic nephrectomy for Wilms tumor after chemotherapy. Initial experience*. *J Urol*; 172:1438-1440.
- [48] Etcheverry R, Collar R, Tobia Gonzales S, et al (2002). *Nefroma quístico en pediatría. Manejo quirúrgico con técnica videolaparoscópica retroperitoneal*. *Rev de Cir Inf*; 12(2):117-119.
- [49] Lorenzo Gomez MF, Gonzales R (2003). *Laparoscopic nephrectomy in children: the transperitoneal vs the retroperitoneal approach*. *Arch Esp urol*; 56(4):401-413.
- [50] Guilloneau B, Ballanger P, Lugagne PM, Valla JS, Vallancien G (1996). *Laparoscopic vs lumboscopic nephrectomy*. *Eur Urol*; 29(3):288-291.
- [51] Himpens H (1996). *Technique, equipment and exposure for endoscopic retroperitoneal surgery*. *Seminars in Laparoscopic surgery*; 3-2; 109-116.

- [52] Rasweiller J, Fornara P, Weber M, et al (1998). *Laparoscopic nephrectomy: the experience of the laparoscopy working group of the German Urologic Association*. J Urol; 160(1):28.
- [53] Hemal AK, Wadhwa SN, Kumar M, Gupta NP (1999). *Transperitoneal and retroperitoneal laparoscopic nephrectomy for giant hydronephrosis*. J Urol; 162:35-35.
- [54] Valla JS, Guilloneau B, Montupet Ph, et al (1996). *Retroperitoneal laparoscopic nephrectomy in children: preliminary report of 18 cases*. It J Ped Surg Sci; 0(1-2):35-37.
- [55] Poddoubny IV, Dronov AF, Kovarsky SL, et al (2003). *Laparoscopic nephrectomy and nephroureterectomy in 90 pediatric patients*. Ped Endosurg Inn Tech; 7(2):135-140.
- [56] Ehrlich RM, Gershman A, Fuchs G (1994). *Laparoscopic renal surgery in children*. J Urol; 151:735-739.
- [57] Desai MM, Strzempkowski B, Matin SF, et al (2005). *Prospective randomized comparison of transperitoneal versus retroperitoneal laparoscopic radical nephrectomy*. J Urol; 173(1):38-41.
- [58] Doublet JD, Barretto HS, Degremont AC, Gattegno B, Thibault P (1996). *Retroperitoneal nephrectomy: comparison of laparoscopy with open surgery*. World J Surg; 713-716.
- [59] Moore RG, Kavoussi LS, Bloom DA, et al (1995). *Postoperative adhesion formation after urological laparoscopy in the pediatric population*. J Urol; 153:792-795.
- [60] Morgan C (Jr), Rader D (1992). *Laparoscopic unroofing of a renal cyst*. J Urol; 148:1835-1836.
- [61] Kumar M, Kumar R, Hemal AK, Gupta NP (2001). *Complications of retroperitoneoscopic surgery at one centre*. BJU Int; 87:607-612.
- [62] Ehrlich RM, Gershman A, Fuchs G (1994). *Laparoscopic renal surgery in children*. J Urol; 151:735-739.
- [63] El-Gonehimi A, Farhat W, Bagli D, et al (2002). *Mentored retroperitoneal laparoscopic renal surgery in children: a safe approach to learning*. BJU Int; 89(s2):78.

IntechOpen



Chronic Kidney Disease and Renal Transplantation

Edited by Prof. Manisha Sahay

ISBN 978-953-51-0003-4

Hard cover, 226 pages

Publisher InTech

Published online 10, February, 2012

Published in print edition February, 2012

This valuable resource covers inpatient and outpatient approaches to chronic renal disease and renal transplant with clinical practicality. This first section of the book discusses chronic disease under distinct topics, each providing the readers with state-of-the-art information about the disease and its management. It discusses the fresh perspectives on the current state of chronic kidney disease. The text highlights not just the medical aspects but also the psychosocial issues associated with chronic kidney disease. The latest approaches are reviewed through line diagrams that clearly depict recent advances. The second section of the book deals with issues related to transplant. It provides effective and up-to-date insight into caring for your transplant patients.

How to reference

In order to correctly reference this scholarly work, feel free to copy and paste the following:

Julio J. Báez, Gaston F. Mesples and Alfredo E. Benito (2012). Laparoscopic Transperitoneal and Retroperitoneal Nephrectomies in Children: A Change of Practice, Chronic Kidney Disease and Renal Transplantation, Prof. Manisha Sahay (Ed.), ISBN: 978-953-51-0003-4, InTech, Available from: <http://www.intechopen.com/books/chronic-kidney-disease-and-renal-transplantation/laparoscopic-transperitoneal-and-retroperitoneal-nephrectomies-in-children-a-change-of-practice>

INTECH
open science | open minds

InTech Europe

University Campus STeP Ri
Slavka Krautzeka 83/A
51000 Rijeka, Croatia
Phone: +385 (51) 770 447
Fax: +385 (51) 686 166
www.intechopen.com

InTech China

Unit 405, Office Block, Hotel Equatorial Shanghai
No.65, Yan An Road (West), Shanghai, 200040, China
中国上海市延安西路65号上海国际贵都大饭店办公楼405单元
Phone: +86-21-62489820
Fax: +86-21-62489821

© 2012 The Author(s). Licensee IntechOpen. This is an open access article distributed under the terms of the [Creative Commons Attribution 3.0 License](https://creativecommons.org/licenses/by/3.0/), which permits unrestricted use, distribution, and reproduction in any medium, provided the original work is properly cited.

IntechOpen

IntechOpen