

We are IntechOpen, the world's leading publisher of Open Access books Built by scientists, for scientists

6,900

Open access books available

185,000

International authors and editors

200M

Downloads

Our authors are among the

154

Countries delivered to

TOP 1%

most cited scientists

12.2%

Contributors from top 500 universities



WEB OF SCIENCE™

Selection of our books indexed in the Book Citation Index
in Web of Science™ Core Collection (BKCI)

Interested in publishing with us?
Contact book.department@intechopen.com

Numbers displayed above are based on latest data collected.
For more information visit www.intechopen.com



Breast Reconstruction Approach to Conservative Surgery

Egidio Riggio and Valentina Visintini Cividin

*Unit of Plastic Reconstructive Surgery,
Fondazione IRCCS Istituto Nazionale dei Tumori, Milano,
Italy*

1. Introduction

Breast conservative treatment (BCT) can be advantageous compared with skin-sparing (SSM) or nipple-sparing mastectomy for many patients affected by unicentric ductal carcinoma in situ (DCIS), Paget's disease, invasive lobular carcinoma (ILC) and invasive ductal carcinoma (IDC) up to 2-3 cm as diameter and without extension to skin (T1; part of T2 in larger breast), and more recently T2 up to 5 cm previously treated by neoadjuvant chemotherapy with positive effect on tumor size reduction. Partial or segmental mastectomy, i.e. quadrantectomy, should include 1.5–3cm excision of normal tissue around the tumour, including the ductal tree, and the removal of a portion of overlying skin and underlying fascia when indicated. Contrary to what happens in Europe and in Italy, lumpectomy is largely preferred in the United States because of the higher cosmetic result without the help of plastic remodelling. Quadrantectomy associated to axillary dissection with radiation therapy (QUART) or without it (QUAD), likely shows three advantages: 1) preservation of healthy breast with satisfying cosmetic appearance if reshaped by the plastic surgeon; 2) preservation of vascular supply and innervation of the nipple-areola complex except of central quadrantectomy; 3) maintenance of some average symmetry improvable with the reshaping reduction of the contralateral breast. Unfortunately many breast surgeons use to perform more lumpectomies rather than ask for plastic surgery aid in order to reshape a quadrantectomy. Disadvantages are given by the radiation effects on soft tissues and the long-term higher rate of local recurrences compared to mastectomy. May radiation be avoided in patients with DCIS? There are no extra-benefit for survival or distant metastases compared to excision alone; patients with high-grade DCIS lesions and positive margins benefited most from the addition of radiotherapy (Viani, 2007). Even if many trials suggest significant reduction of absolute local recurrence after radiation, many unicentric DCIS are conventionally treated by local excision alone. The unsolved problem remains how to identify subgroups of patients with DCIS with different rates of local recurrence incidence (Silverstein, 2006). Annual risk for in-breast recurrence is rated 1.97 per 100 patients even in the most favourable subgroup with clear margins and minimal amount of comedonecrosis without radiation (Fisher, 1995). At least clear margins of 1 cm for tumour size of ≤ 1.5 cm are considered wide excisions with a good Van Nuys Prognostic Index (Silverstein, 1996). Local control can be achieved without radiation therapy when margins widths of ≥ 1 cm are obtained, regardless of nuclear grade, comedonecrosis, or

tumour size within 2.5 cm (Silverstein, 1999). It becomes mandatory marking all margins of the surgical specimen in order not to find positive margins. May DCIS of ≥ 3 cm be untreated by radiation therapy if clear margins should be more than 2cm with the same benefit? Avoiding radiation is fundamental for both the techniques and outcomes of plastic surgery. Reconstruction after BCT are more risky because of the damaged tissues of the breast. In addition the salvage mastectomy necessary in presence of further recurrence complicates the reconstructive chances and generates a worse psychological trauma in the patients more severely than a primary mastectomy with implant reconstruction.

End points of any breast-conserving treatment are: local control of disease and good cosmetic result. Based on our Institute's experience, successful BCT was always related to radical excision with wide clear margins along with expertise in mastopexy techniques. Medium and large breast-size can facilitate oncoplastic resections with optimal morphologic-cosmetic compliance. On the contrary in case of small breast, SSM or nipple-sparing mastectomy followed by reconstruction with expander or permanent silicone implant can give better perspectives concerning longer disease-free survival rate and more cosmetic results although the nipple will lose sensibility and the nipple-areola displacement could likely bring to asymmetry difficult to be corrected. The BCT reduction of a breast already small could become for many women unacceptable independently from the occurrence of permanent scarring deformity (Fig.1). The reconstruction after mastectomy can also permit to augment the contralateral breast according to the patient's wishes. Nowadays our rate of BCT reconstruction is decreasing because of the always earlier detection of smaller tumours and smaller resections as well as because of the increasing rate of nipple-sparing mastectomies especially for the younger patients with IDC, that are more exposed to a long-term relapse of disease.

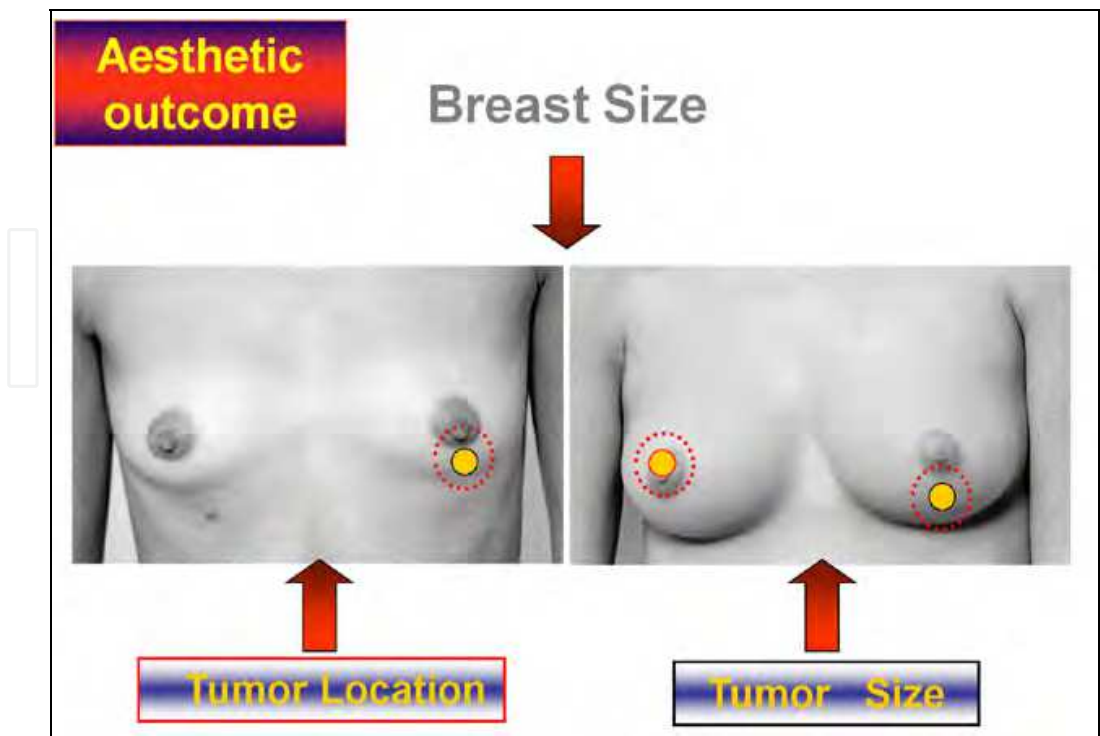


Fig. 1. Cancer localization and size related to the breast size

1.1 Historical focus on QUART

The idea of conserving the breast started forty years ago in our Institute (Fig.2): Milan Trial I (1973-1980; 701 patients; tumours up to 2-cm diameter; Halstedian mastectomy versus QUART). Disease-free and overall survival curves presented no difference between the two groups at 8 years: disease-free survival 77% for Halsted patients and 80% for the QUART patients, while overall survival was 83% and 85%, respectively (Veronesi, 1981-1986). The cumulative incidence of recurrences was 8.8 percent (QUART) versus 2.3 percent respectively, after a median follow-up of 20 years (Veronesi, 2002).

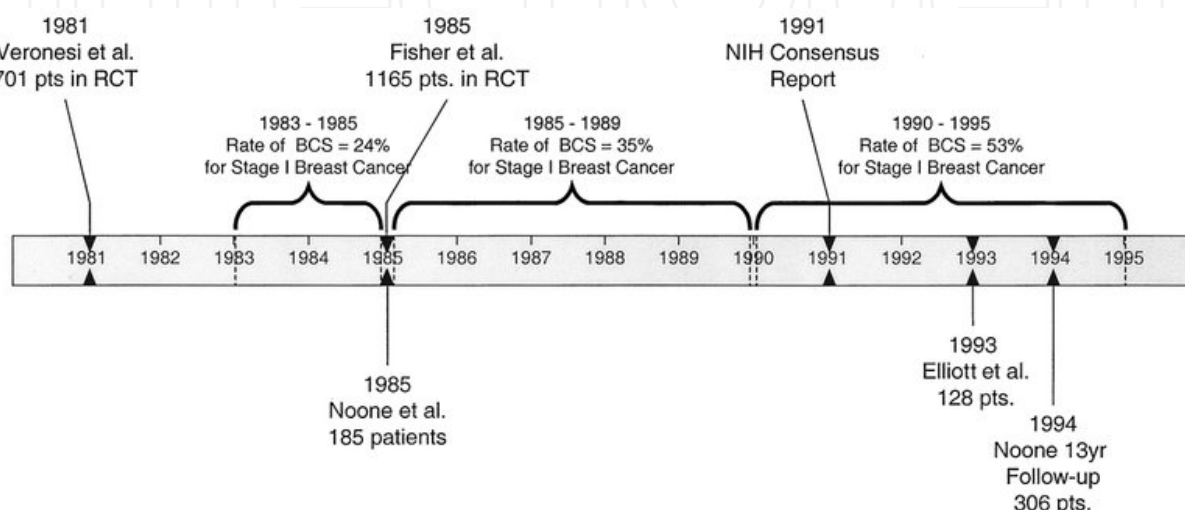


Fig. 2. Positive development of the breast-conserving treatment at the end of the last century. The first operations did use no techniques of plastic surgery and the contralateral breast was frequently reduced by a “mirror quadrantectomy” with evident scars. Plastic surgery was introduced earlier than 1985 through procedures of dermaglandular reshaping or silicone implant insertion, in the last two decades discontinued.

The Milan Trial II (1985-1987; 705 patients; tumours up to 2.5 cm; 345 TART - tumorectomy, axillary dissection, and radiation therapy - versus 360 QUART,) demonstrated higher frequency of local recurrences after tumorectomy (7.0 vs. 2.2%) (Veronesi, 1990). The importance of irradiation was supported by the Milan Trial III (1987-1989; 579 patients; tumours less than 2.5 cm; QUART (299) versus QUAD (280). After breast-conserving surgery, radiotherapy was indicated in all patients up to 55 years of age, in patients with positive axillary nodes, and in patients with extensive intraductal component at histology. The study suggested that irradiation may be avoided in patients older than 65, and be optional in women aged 56-65 years with negative nodes (Veronesi, 2001).

The oncological safety was confirmed by others studies: NSABP B-06 trial (Fisher, 1985). A total of 92.3 per cent of women treated with radiation remained free of breast tumor at five years. The BCT efficiency provided that the specimen margins were free of tumor and cosmetic outcome were acceptable (Fisher, 2002). After twenty-year follow-up, the cumulative incidence of recurrences in the ipsilateral breast was 14.3 percent.

The EORTC trial (Van Dongen, 1992) did show a significant difference about the rate of locoregional recurrence at 10 years: 12% of the mastectomy and 20% of the BCT patients. The locoregional recurrence rate for patients with a microscopically complete excision was

17.6% (95% CI = 11.2%–22.3%); for patients with microscopic margin involvement, it was 26.5.% (95% CI = 22.2%–33.0%). The locoregional recurrence rate progressively increased: the rate was 11.8% (95% CI = 8.5%–15.1%) at 5 years and 19.7% (95% CI = 15.4%–24.0%) at 10 years. After a median follow-up of 13.4 years, BCT and mastectomy still demonstrate similar survival rates for patients with tumors up to 5 cm (Joop - Van Dongen, 2000).

Even if the overall survival after QUART is equivalent to mastectomy, local recurrence rate is higher in the conserved breast. A significant predicting factor is young age of 40 years or less. Younger patients had a five-fold increased risk of developing a breast recurrence compared with patients older than 60 years (Arriagada, 2002; 717 patients treated by lumpectomy and breast irradiation and 1289 patients by total mastectomy for T up to 2.5 cm; most patients did not receive adjuvant chemotherapy or additive hormonal treatments; mean follow-up of 20 years).

BCT is still considered a valid choice for small tumors after meta-analysis of the main randomized controlled trials (Yang, 2008) despite the local recurrence rate not less than 1% per year and the early local recurrence (<5 years) associated with worse prognosis. Many relapses occur in the vicinity of the tumour bed, but the percentage of recurrences occurring in other quadrants increases over time and those after 10 years are considered new primary tumours. Open question remains how much is convenient to risk salvage mastectomy after irradiation to the aims of guaranteeing either the cosmetic result primarily fixed with BCT or the minor invasiveness of the elective reconstructive procedures.

1.2 Reconstruction after quadrantectomy

Glandular excision volume is the first element to determine the most appropriate oncoplastic treatment. This is the most predictive factor of surgical outcome and related breast deformity; if more than 20% of breast volume must be excised, risk for breast deformity becomes high.

The immediate and delayed reconstructions were developed after these trials performed in our Institute. The first Author coordinated a retrospective study of reconstructions after partial mastectomy, i.e. quadrantectomy. The first 100 patients’ histories were detected in 1987 and 1992 (Table 1).

Patient number	100
Average age	50 (17-67)years
Tumor size	1.95 + 0.21 (0.4-2.7 cm)
Skin resection	4.5 x 3.0 cm
Breast glandular resection	6 x 5 x 4 cm
Adjuvant chemotherapy	10 patients
breast irradiation (50Gy+10Gy boost)	89 patients

Table 1. Clinical data per 100 patients

Tumours are IDC for the 45% (Table 2) and the most frequent sites of reconstruction are the upper-external and the central quadrants (Fig.3). The distribution per breast areas is different compared with the cancer incidence per site.

D I C	44
L I C	18
DIC + LIC	11
DISC	6
Paget	3
Paget + DISC	1
Paget + LIC	1
Adenocarcinoma	1
Sarcoma	2
Dysplasia	11

Table 2. Tumour hystology

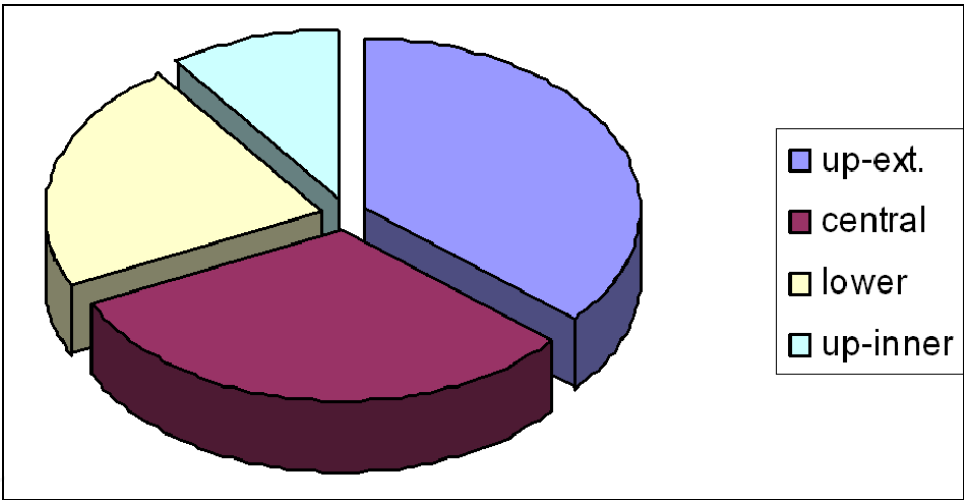


Fig. 3. Distribution of reconstruction per site of quadrantectomy

Even if the upper-external tumours show the larger incidence (50%), reconstructive procedures were applied in 35% of them, >20% immediate (Fig.4). On the contrary, the cancer centrally located occurs in 20% of the total breast cancer incidence, but the reconstructions are numerous and represents the 51% of the total, 1% is delayed. Immediate reconstructions are crucial: the 75% is immediate and 25% is delayed above all. Primary aim is the restitution of shape and symmetry to the breast before irradiation; for this reason the complimentary aid among general and breast surgeons is important. The 89% of patients with BCT reconstruction underwent radiotherapy. Hence immediate reconstruction should be furthermore increased. Delayed reconstructions are usually performed after three years from radiation therapy and must be carefully selected because of higher complication rate related to irradiated tissues.

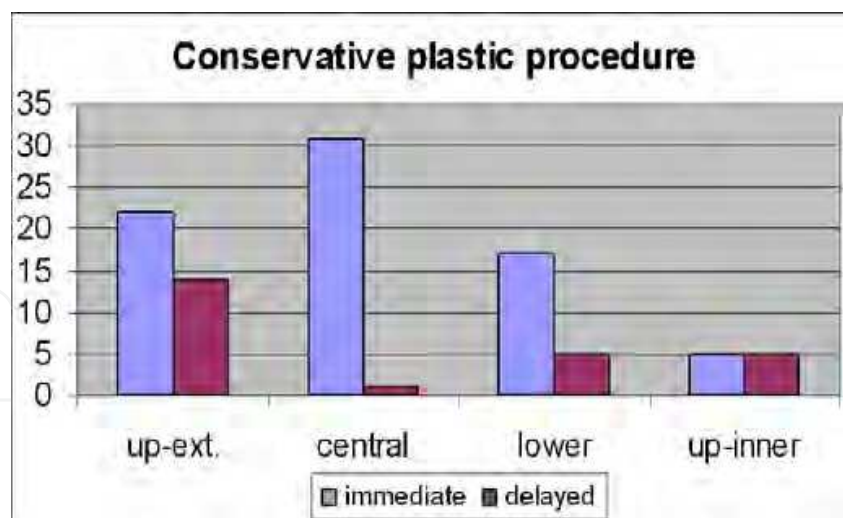


Fig. 4. Different distribution for immediate and delayed reconstructions

The choice for silicone implant is seriously disadvantageous after irradiation : 67% of severe capsular contracture and 55.5% of cases were surgically revised in our series. No significant differences were found in surgical timing, i.e. implant before or after radiotherapy.

The tissue loss generated by quadrantectomy can be immediately restored using a variety of mastopexy techniques, mostly based on lower pedicle or round-block, with different skin incisions in relationship with the anatomical site of tumour excision, breast size, thorax length and breast ptosis (especially the jugulum-nipple distance).

In delayed steps, multiple z-plasty and/or areola-nipple replacement can be performed in the upper internal or external region of the breast. On the contrary, a defect at the mid-upper region is more difficult to be repaired especially when associated to areola-nipple cranial displacement. In the last condition, autologous tissue transfer can be indicated for the larger defects while fat injections can be preferred for middle/lower defects with minimal skin loss. Latissimus dorsi and TRAM flaps were mostly used, in a delayed time.

Before the end of the last century, the different rates of surgical procedures were: dermaglandular flaps, 68%; breast silicone implants 20%; autologous flaps, 12% (latissimus dorsi 10%, 2 with implants, TRAM 2%). Nowadays, implants were discontinued for irradiation complications and were substituted by lipofillings, after a 3-year follow-up and in patients at minor risk of recurrence. The autologous flaps are less necessary and then decreased due to: a) the major number of immediate dermaglandular remodelling and b) the preference for the removal of the remaining breast, before performing a composite flap, instead of retaining the higher risk of local recurrence and consequent salvage mastectomy and new flap reconstruction.

2. Immediate reconstruction

One crucial question is the decision about the timing of reconstruction following conservative treatment and successive radiotherapy. Ideally, reconstruction should be both immediate and definitive so as to avoid patients undergoing further surgery later. It is now generally considered, from an oncological point of view, that there are no contraindications

to reconstruction, even if it is immediate, in that it does not interfere with the progress of the disease. In many cases it is only for organisational reasons (absence of a surgeon specialised in reconstruction, insufficient time, lack of material for reconstruction-prosthesis) that reconstructive surgery must be scheduled after the quadrantectomy time. From a surgical point of view it is "always" possible to carry out immediate reconstruction provided that the general conditions of the patient permit so, yet it might not always be opportune to do so. In most cases reconstruction must be immediate if we wish to restore by rotating local flaps. Extensive mobilization of the local flaps is indeed much more difficult and riskier when carried out at a secondary time after radiotherapy. Nowadays the gold standard is to use a fast technique which also assures a good final outcome. The tendency and general opinion regarding restoration timing following conservative treatment agree on performing immediate breast reconstruction in all cases where it is possible.

The cases of partial mastectomy are multifarious. This variability mainly depends on the extent of resection of the mammary volume, the quadrant involved, and then direction and length of the surgical incision. Moreover the results of quadrantectomy depend on the size of the tumour removed, on the effects of radiotherapy, on the administration of adjuvant chemotherapy and on the surgeon skill. The reconstructive technique is chosen on the basis of these factors.

The amount of breast tissue removed, which is conditioned by the size of the tumour, is the most important factor and the smaller the breast the more evident is its effect. The larger the breast, the better the final result will be in aesthetic terms.

Scarring, an important aesthetic issue, generally depends on the type of surgical incision, on the primary site of tumour, on the patient characteristics, on the radiotherapy and on any complications post-surgery (infections, hematoma). The main radial axis of the incision typically extends from the area of the areola to the periphery of the breast. Unless required by the lesion, the incision should not over-extend peripherally, towards the axilla, or arrive too closely to the nipple. For lesions behind the areola it is usually necessary to comprise areola and nipple. The tissue deficit depends on the amount removed, including skin, mammary gland and areola-nipple part.

Unless reconstructed at the same time as surgical removal, a quadrantectomy sums the above deficits to the damage caused by radiotherapy, which leads to alterations in the skin and glands of the breast treated. Irradiated tissue becomes fibrotic, and hence inelastic. In these cases it is often necessary to remove a further part of radio-damaged tissue, hence increasing the deficit. At this point it is necessary to resort to myocutaneous flaps.

Mammary prostheses can only be used in selected cases when other techniques (local reshaping, transfer of distance flaps or contralateral procedures) have been refused by the patient. Periprosthetic fibrosis in irradiated tissue can be highly aggressive and lead to serious distortion of the prosthesis. The presence of a prosthesis could interfere with instrumental examinations (mammography) and with the diagnosis of intramammary recurrences but the potential problem could also exist for inner scars after reshaping.

A contralateral mammoplasty (pexy or reduction), that substitutes the old concept of "mirror quadrantectomy," is aimed to reach a good symmetry of the breast. It can be carried

out both at the same time as the quadrantectomy or successively as the patient wishes or as oncoplastic reasons could suggest.

2.1 The reconstruction after upper quadrantectomy

Half of the breast tumours involved the upper-external zone where most defects do not require a particular reconstruction technique but simply undermining. Nevertheless the general surgeon must be conscious that some defects about tissue loss or scar will appear later, and very often after radiation (Fig. 5). It is often sufficient to mobilize slightly the dermoglandular flaps adjacent to the resection and to balance areola and nipple position. Aesthetic results are easily better in upper-external quadrant than in other quadrants.

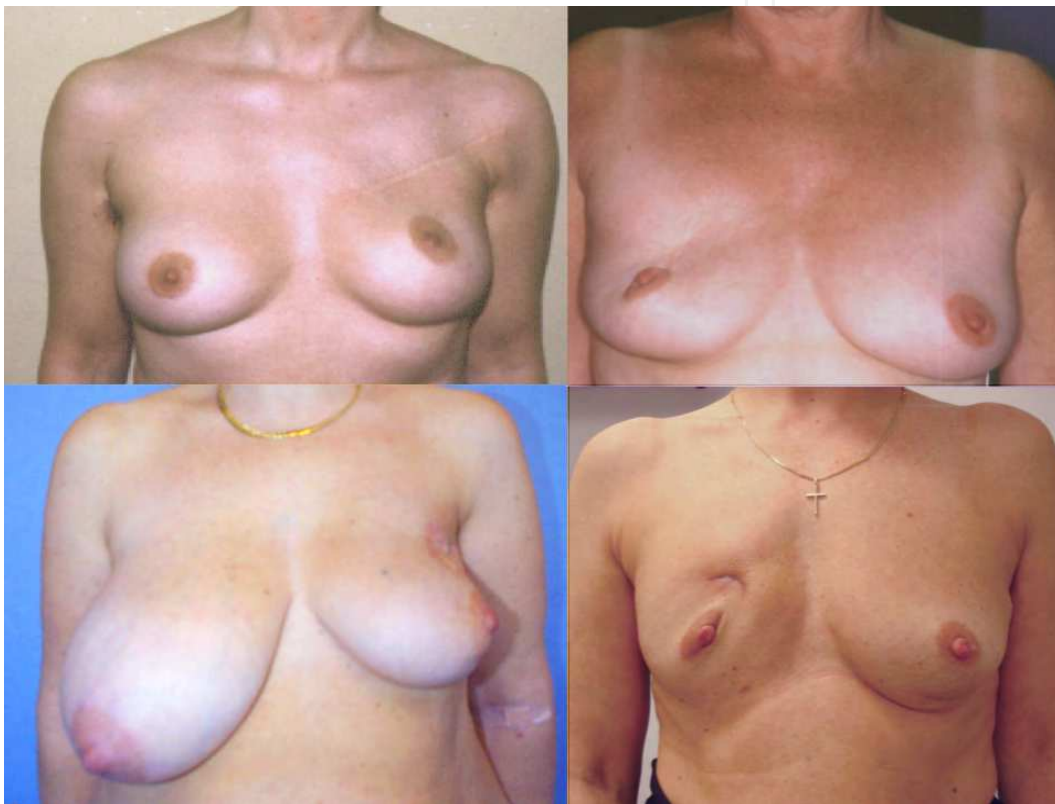

Fig. 5. Results after upper quadrantectomy without immediate reconstruction

Reconstruction is always advisable because of the volume loss of the mammary gland and the visibility of scarring, especially in case of upper-medial quadrantectomy. Local reshaping via dermaglandular flaps is the technique most frequently used except when the breast is small and without signs of ptosis. Areola upper edge cannot be placed at a length shorter than 16 cm from the sternal notch and 7-9 cm from the sternal midline because it can represent a severe cosmetic damage highly difficult to be solved. Upper-inner position of the nipple-areola complex cannot be displaced out of this zone, known as “no man’s land”, without further worse scars. It is much better repair the quadrantectomy defect using a linear suture rather than jeopardising the areola position. The figures 6a-b-c show the uppermost advancement that may be considered as acceptable, at least half centimetre less could be the optimum. When the preoperative plan is drawn it is basic to take into account some grade of post-op bottoming-out of the breast gland.

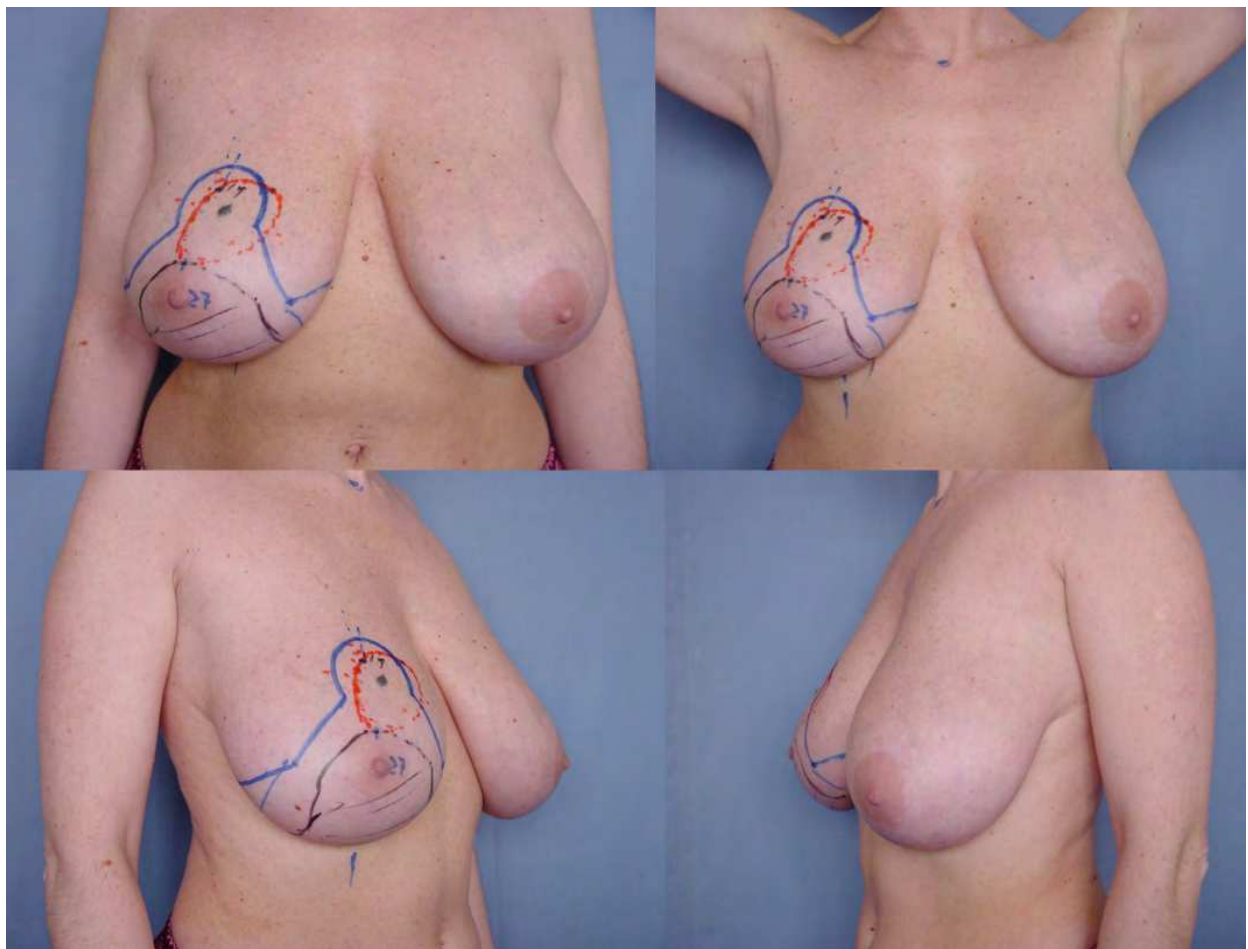


Fig. 6a. Preoperative marks of an inferior dermaglandular flap harvesting for right breast reshaping immediate to superior quadrantectomy. Above: Frontal view. Below: Lateral view

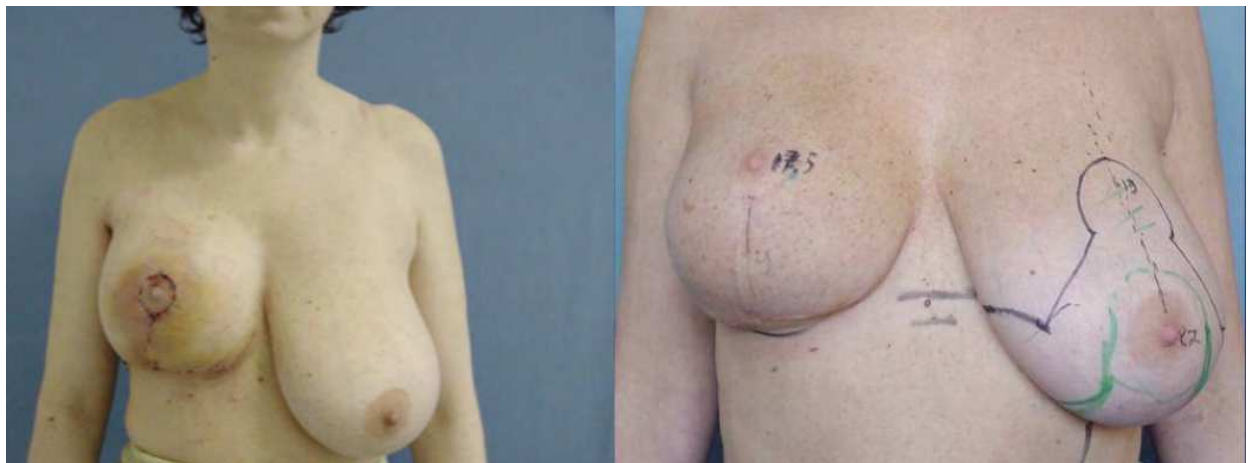

Fig. 6b. Inferior flap for right breast reshaping after superior quadrantectomy. Left : Result. Right: Preoperative marks for left breast mirror mammaplasty by similar inferior pedicle flap. Nipple was placed at 17.5 cm from the sternal notch; in the other breast, it was planned at 19 cm.

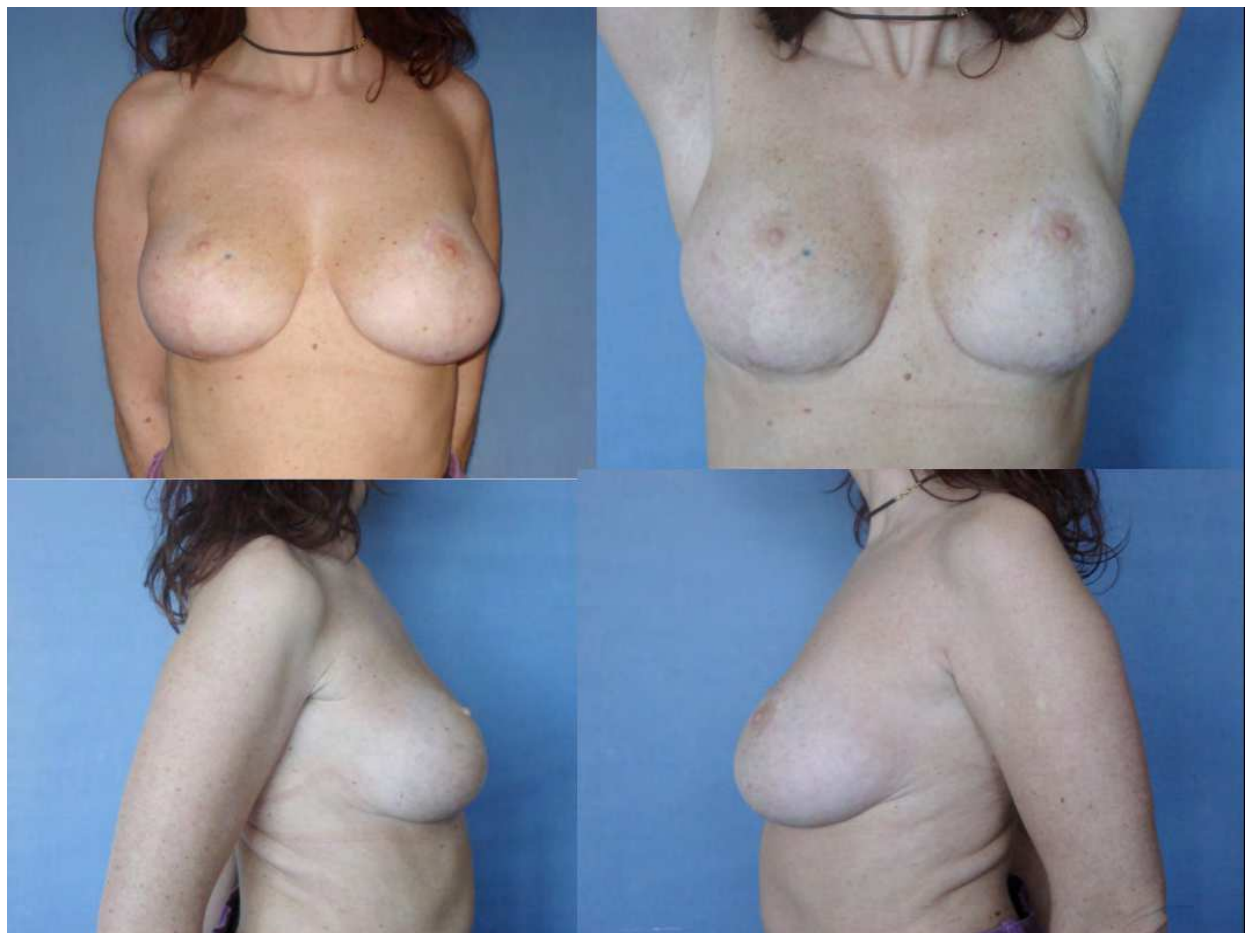


Fig. 6c. Final breast shape and symmetry after right upper quadrantectomy reshaping and left breast reduction after 2.9 years. Above: Frontal view. Below: Lateral view

2.1.1 Surgical techniques

The procedures are several depending on size and fine localization of resection (Fig. 7).

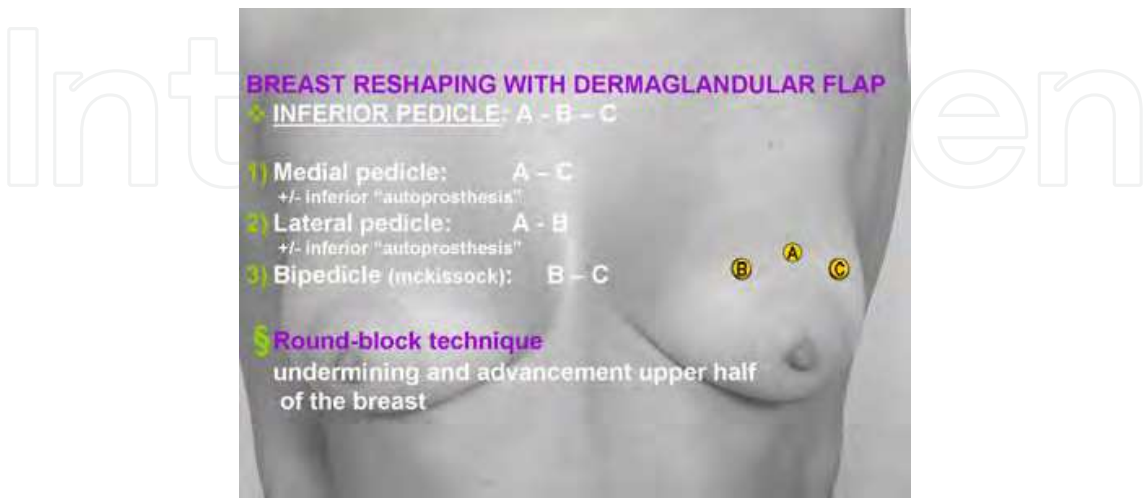


Fig. 7. Different techniques for upper quadrantectomy related to specific site (A. upper central, B. inner, C. external).

The most used technique includes the harvest of a dermagladular flap inferiorly-based to supply the nipple-areola complex (Fig. 8). The flap better fills a upper median tissue loss in a large and ptotic breast (Fig. 6). If the resection is placed in the “no man’s land,” it is prudently better associate minor cranial advancement of nipple-areola to a direct vertical closure of the uppermost part of resection (Fig. 9-10).

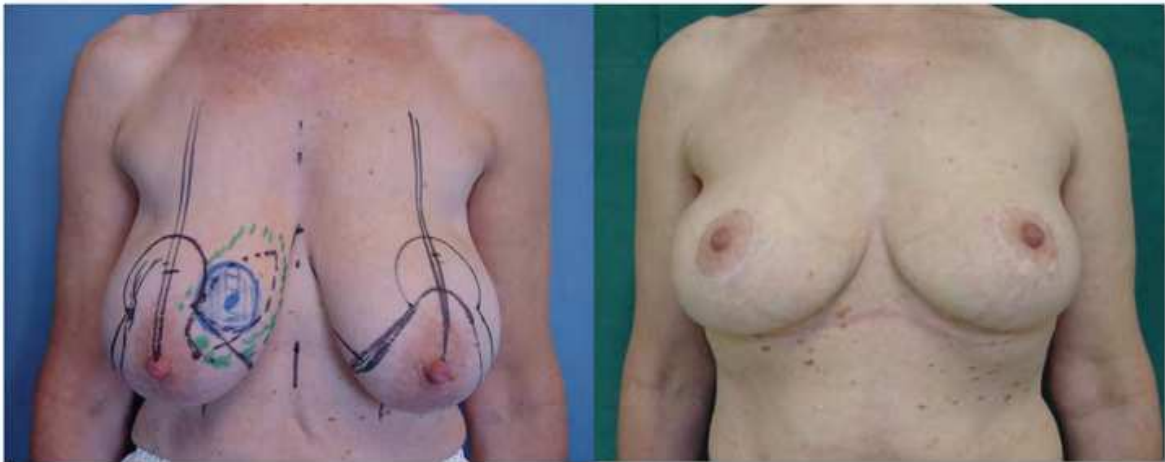


Fig. 8. Inferior dermaglandular flap for reshaping after superior inner quadrantectomy and mirror reduction mammoplasty. Left: Preoperative view. Right: Postoperative view after 2 years.

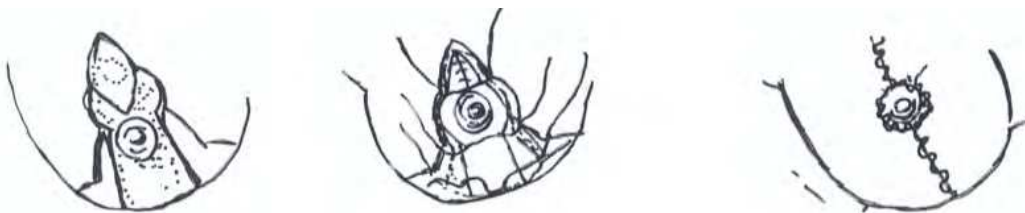


Fig. 9. Drawing of inferior dermaglandular flap with vertical direct closure upwards, in superior central quadrantectomy

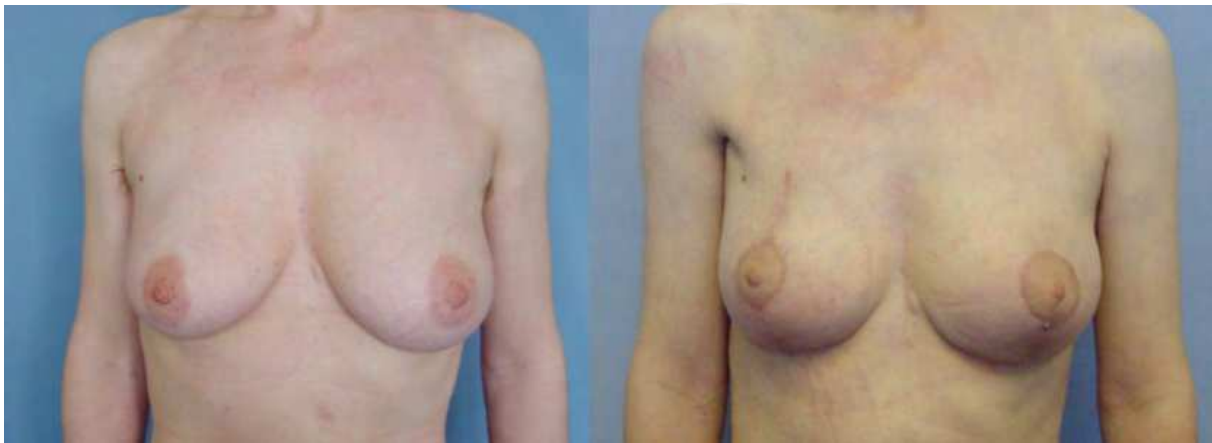

Fig. 10. Breast reshaping after superior central quadrantectomy with reconstructive technique illustrated in Fig. 9. Left: Preoperative view. Right: Postoperative view after right breast reshaping and left breast mirror mammoplasty.

In case of breast with no or moderate ptosis a round-block technique is advisable (Fig. 11a-b); a radial skin closure is associated to the periareolar pexy in smaller breast or with skin excision (Fig. 12). When the quadrantectomy is upper-medial or upper-lateral, a different technique at medial or lateral pedicle flap is preferred. These last procedures can be combined with an inferior dermaglandular flap inferiorly-based that fits the central deep part of the breast to give more projection (Fig. 13).

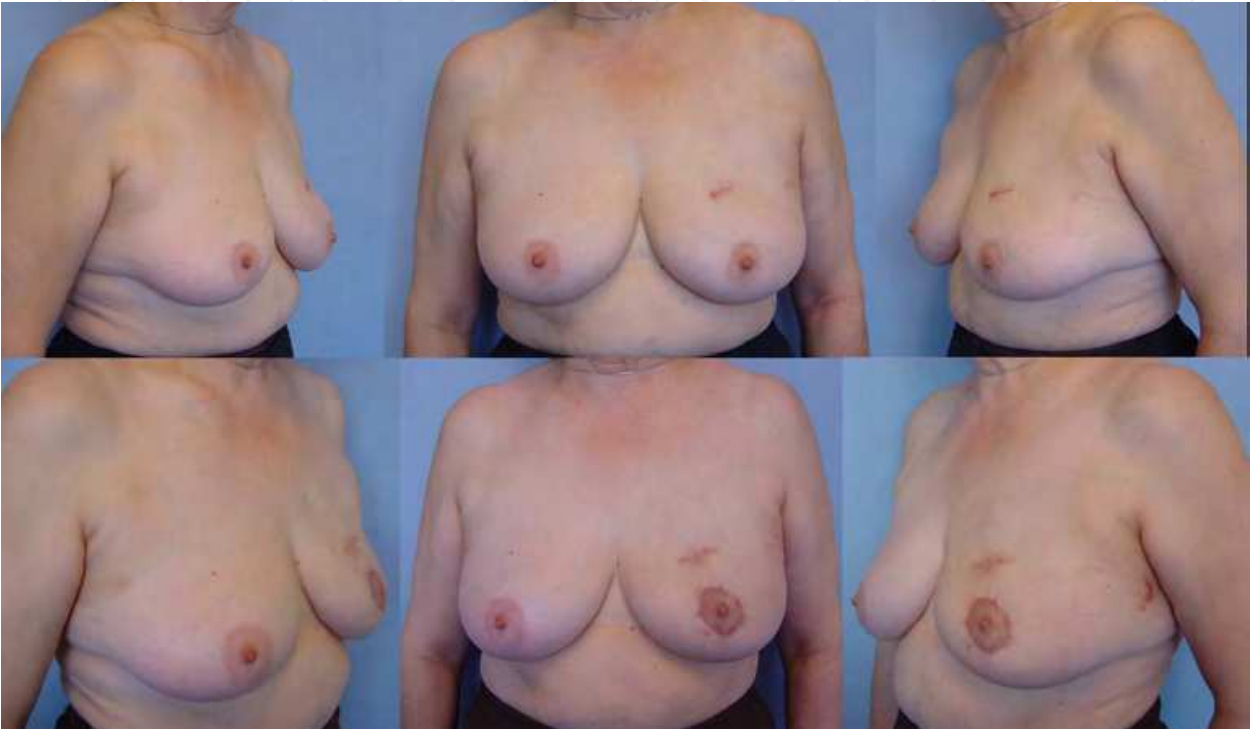


Fig. 11a. Breast reshaping after superior quadrantectomy using round-block pexy and harvesting of adjacent sliding flaps. Above: Preoperative view. Below: Postoperative view

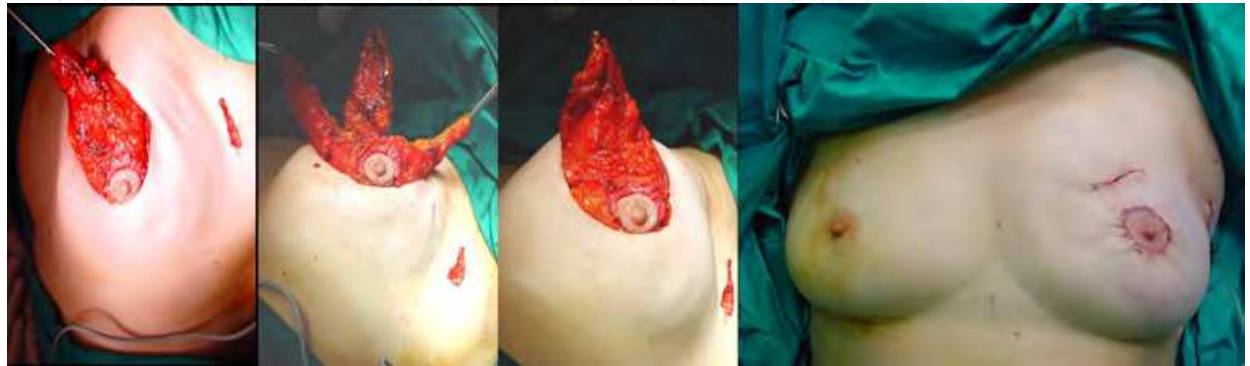

Fig. 11b. The same breast reshaping after superior quadrantectomy using round-block pexy and harvesting of adjacent sliding flaps. Intraoperative view

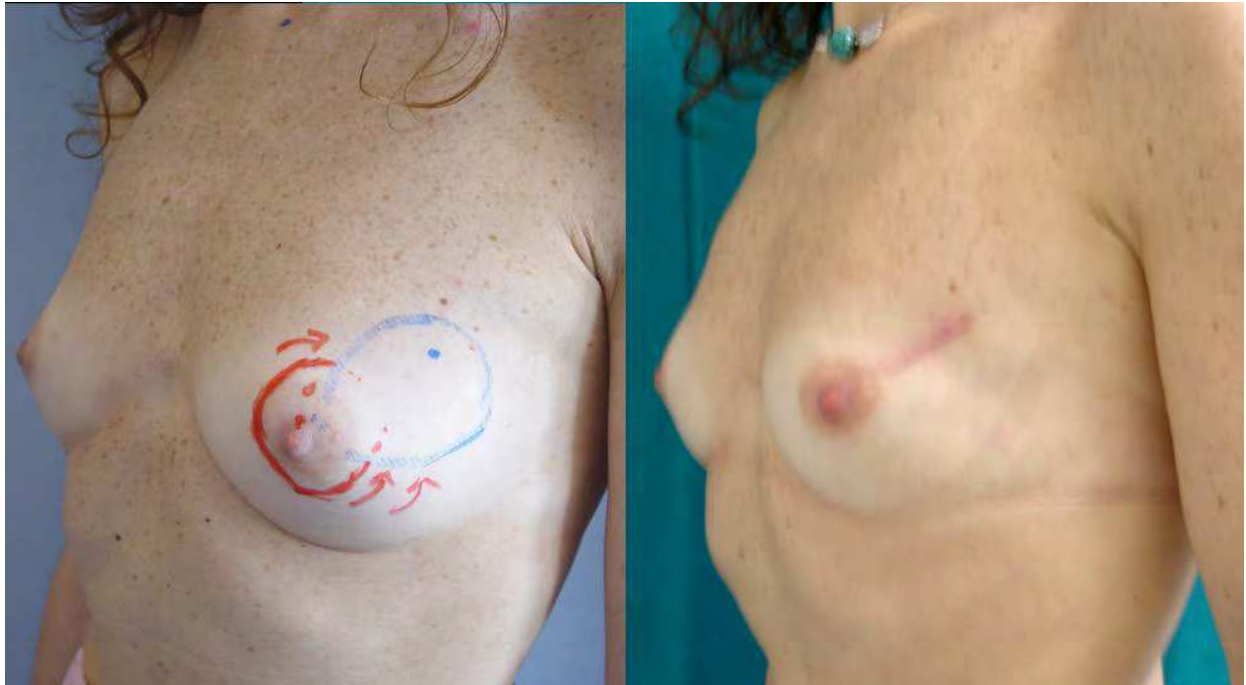

Fig. 12. Periareolar reshaping associated to radial skin closure, for upper lateral quadrantectomy. Left: Preoperative view. Right: Postoperative view

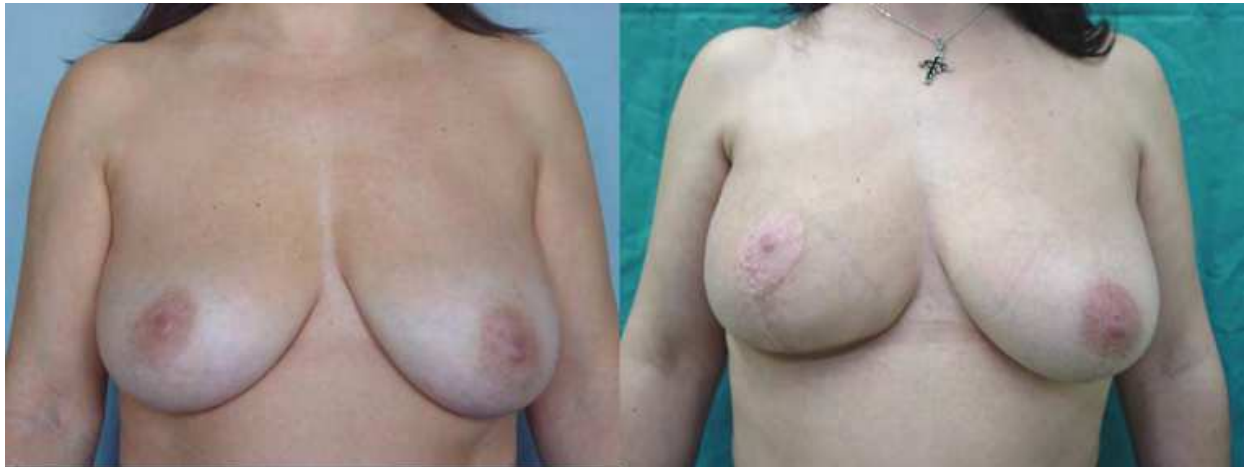

Fig. 13. Breast reshaping after superior quadrantectomy using lateral dermaglandular flap supporting nipple-areola and inferior pedicle as an endoprosthesis. Left: Preoperative view. Right: Postoperative view after 1 year

The reconstruction with dermaglandular flap inferiorly-based or with round-block technique can maintain the prior breast shape with a size moderately smaller. On the contrary, the reconstruction with dermaglandular flap medially- or laterally-based with endoprosthesis tries more frequently to modify shape, consistence and projection of the breast mould. Furthermore, these technique can be modulated to be used for very large resections (Fig. 14a-b) or for secondary surgery (Fig. 15).

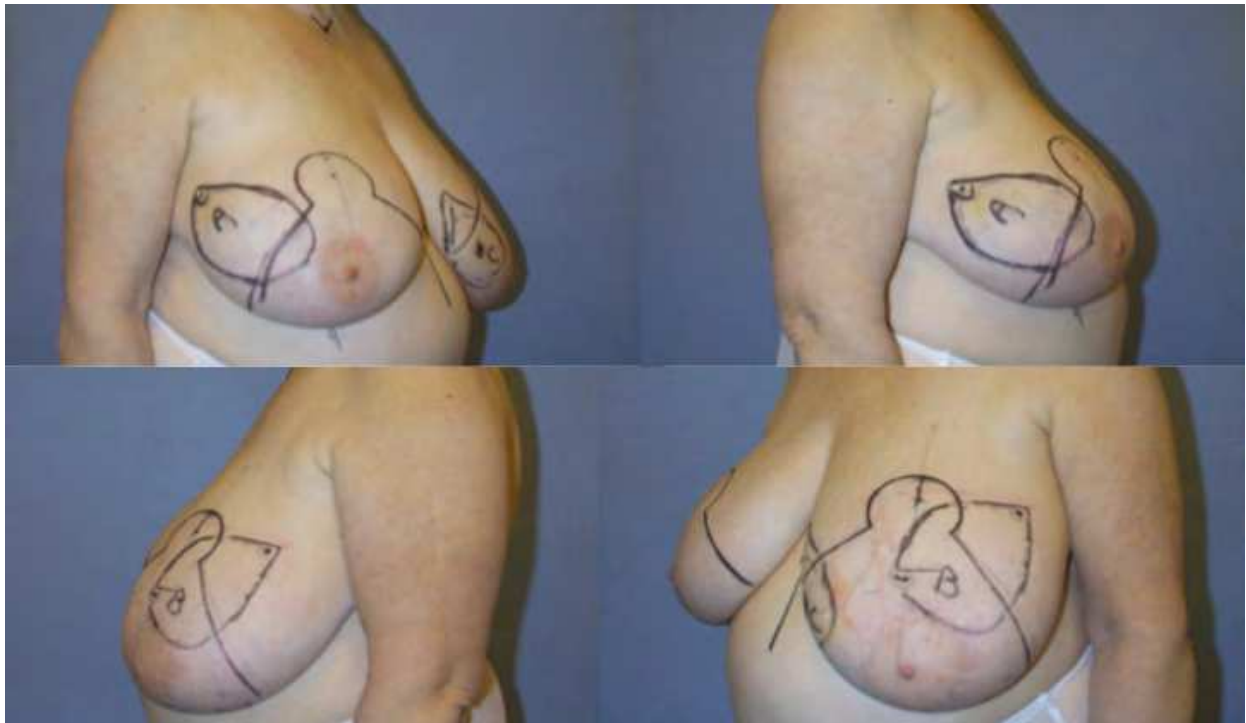


Fig. 14a. Breast reshaping after lateral quadrantectomy, on the right, and bifocal lateral-medial quadrantectomy, on the left: inferior pedicle flaps. Preoperative drawing. Above: right breast. Below: left breast

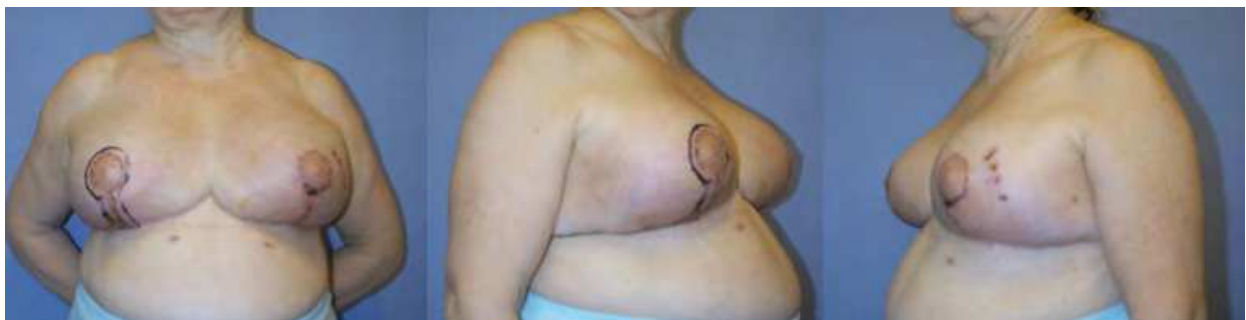

Fig. 14b. The same breast reshaping after extended quadrantectomies: immediate result. Left: Frontal view. Center: Right breast. Right: Left breast

2.2 The reconstruction after central quadrantectomy

Reconstruction of central quadrants is mandatory not only for the loss of the mammary gland but above all of the areola-nipple, generally involved in case of Paget and sub-areolar IDC/DCIS tumours. The only reason not to switch to a mastectomy is given by the chance of rebuilding a breast mould with nice shape and adequate volume. The breast seems to be amputated after central resection if no valid reconstruction is applied (Fig. 16). Otherwise it is better a skin-sparing mastectomy with implant. The reconstruction of the nipple is advisable to carry out immediately, or however before irradiation in order to reduce the risk of complications. The tattooing of the areola should be carried out after six months when the result may be considered definitive.

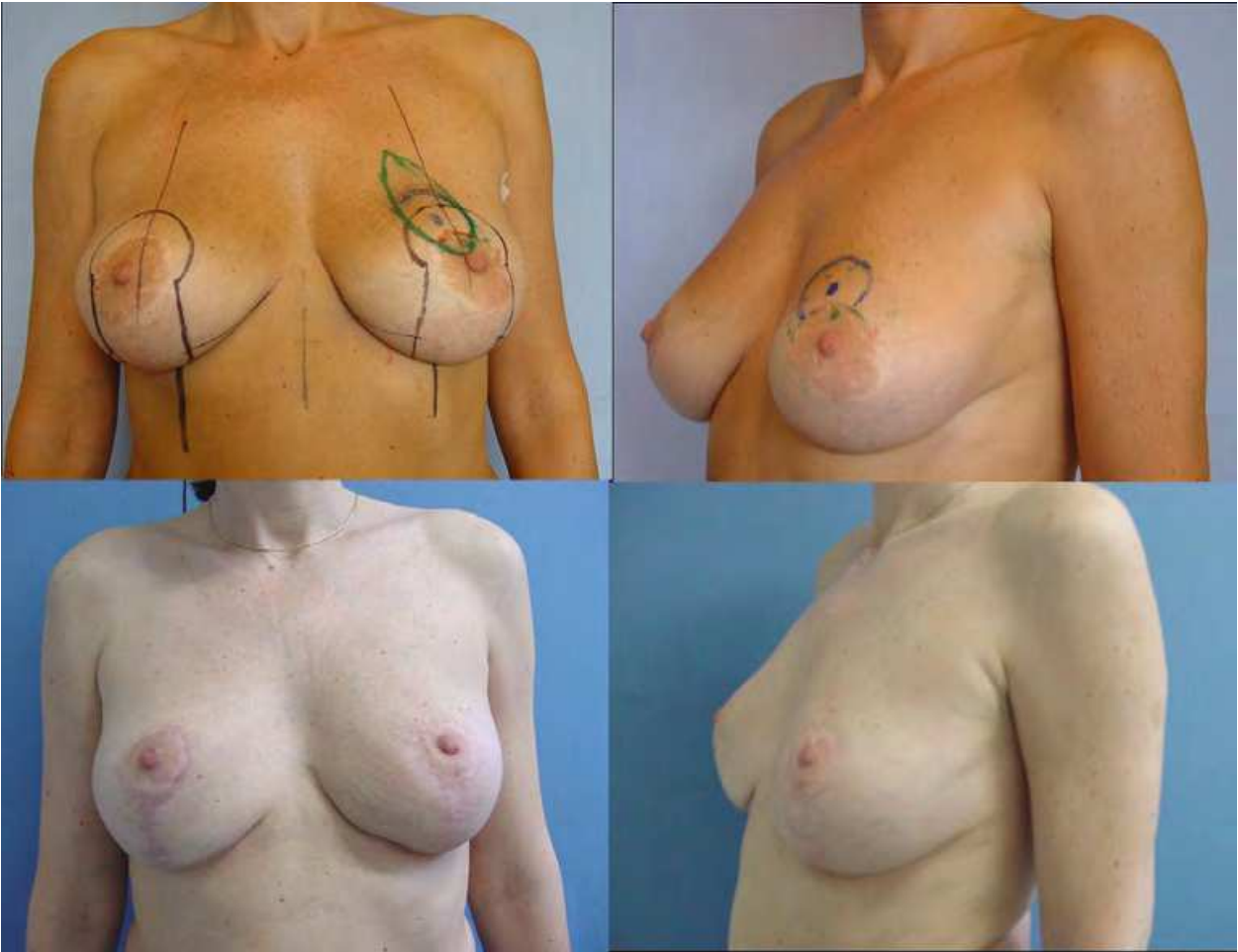


Fig. 15. Left breast reshaping for upper quadrantectomy after prior cosmetic bilateral mastopexy and contemporary contralateral pexy revision. Above: Preoperative view. Below: Postoperative view

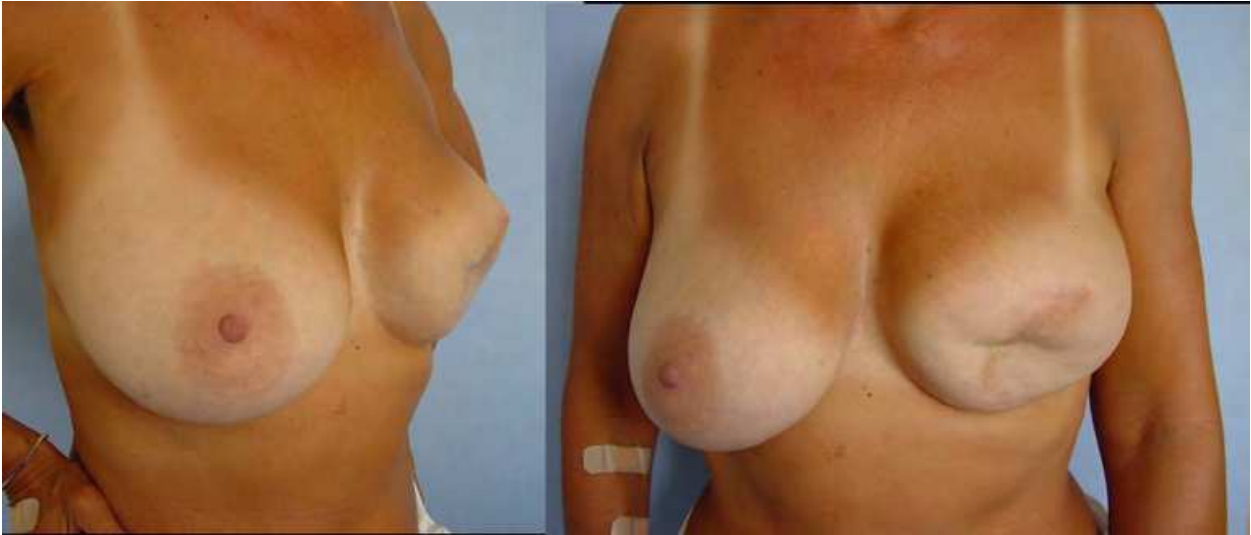

Fig. 16. Results after central quadrantectomy without immediate reconstruction

2.2.1 Surgical techniques

The gold standard technique is a mastopexy, with a B-pattern incision. The reshaping occurs through the rotation-advancement of the dermaglandular flap based on an inferior-lateral pedicle and conserving an island of integral skin for the areola (Fig. 17). The medial border of the deepithelialised flap is cut down to the fasciomuscular plane and the lateral dermoglandular flap along this plane is detached off and completely mobilized (Fig.18). This technique was firstly applied in our Institute (Grisotti, 1994). This has the following advantages compared to other techniques: minor reshaping, good maintenance of prior breast shape and ptosis, satisfactory symmetry (Fig.19-20).

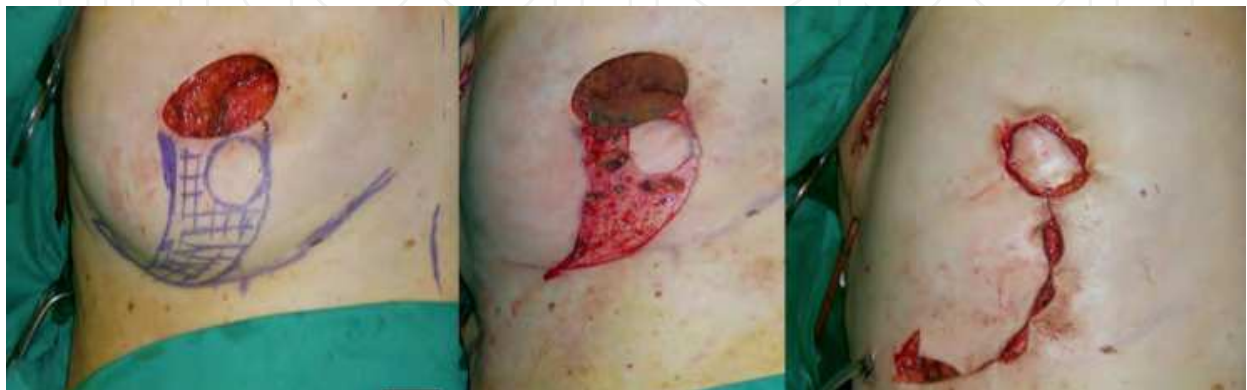

Fig. 17. Breast reshaping after central quadrantectomy. Left: Dermaglandular inferior-lateral flap marks. Center: Intraoperative harvesting of the flap with the skin island. Right: Intraoperative result.

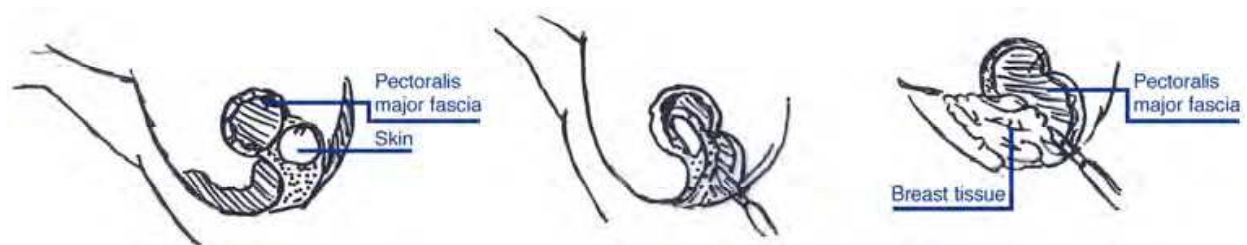


Fig. 18. Drawing of the dermaglandular inferior-lateral flap: Dissection and advancement.

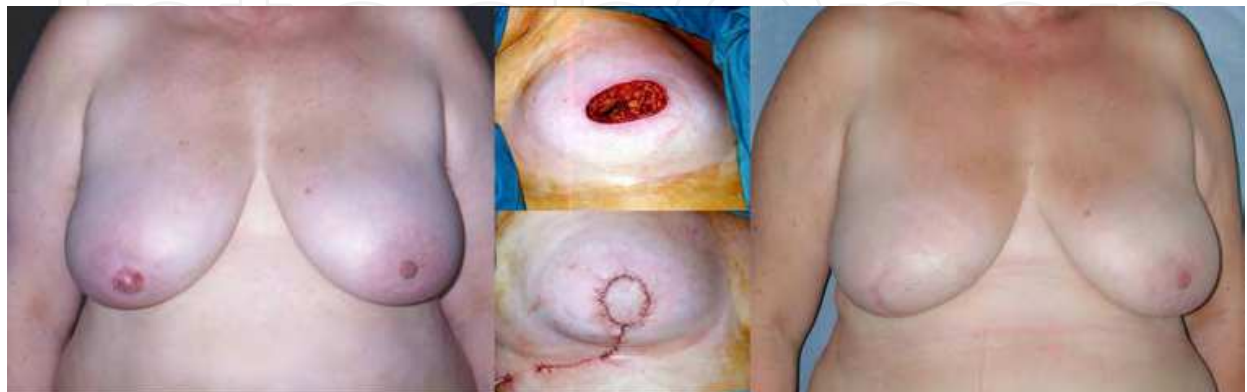

Fig. 19. Paget’s disease. Reshaping of the breast after central quadrantectomy using the inferior-lateral pedicle with skin island pro areola. Left: Preoperative view. Center: Intraoperative result. Right: Result at long-term.

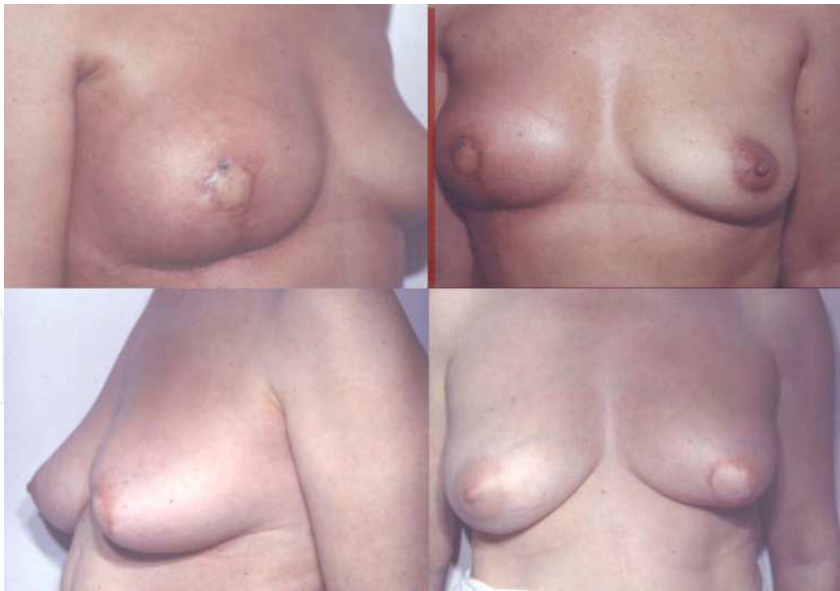

Fig. 20. Reshaping of the breast after central quadrantectomy with the same Grisotti's technique. Evident signs of radiodermatitis. Above : Right breast central quadrantectomy and inferior skin glandular flap, postop. Below: Left breast central quadrantectomy and inferior skin glandular flap.

In large breasts, a technique similar to the reduction based inferiorly pedicle can facilitate the closure of the residual breast and make it possible concurrently to reconstruct the areola (Fig. 21). A personal (Riggio) variant consisted of an inferior-medial pedicle supporting an inferior-lateral skin island, that can be free of being transposed upwards (Fig. 22).

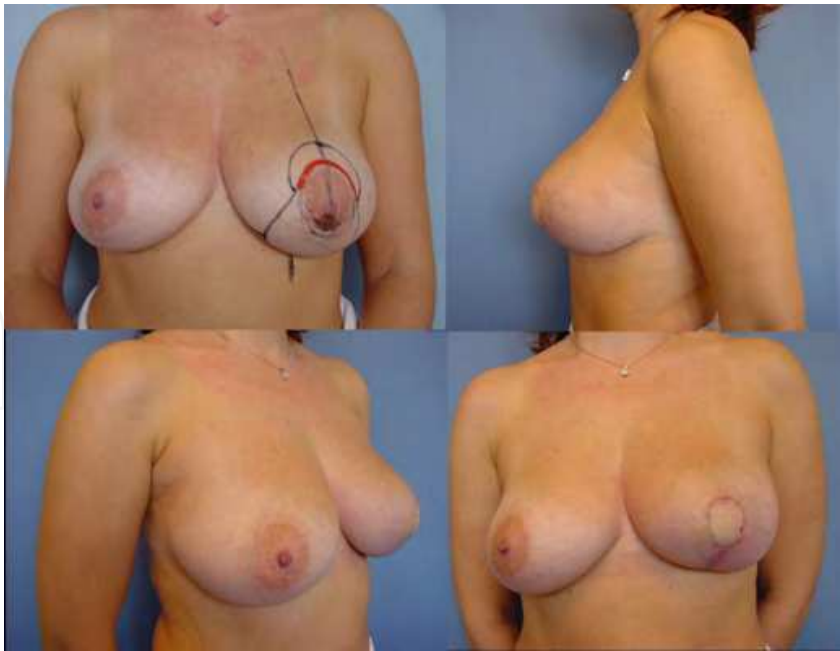


Fig. 21. Reshaping of the breast after central quadrantectomy using a standard dermaglandular flap pedicle supporting the skin island pro areola. Above, left: preoperative marks. Above, right: Lateral postoperative flap. Below: Lateral and frontal postoperative views.

Another type of dermaglandular reshaping, developed by Nava in our Institute, regards the use of a superior pedicle supporting the skin island and overlapped to an inferior flap placed deeply as an endoprosthesis that greatly increases breast projection (Fig.23a-b, 24). This technique better improve the aesthetic result and necessitates of a contralateral mirror mammoplasty using the same or different pedicled technique. In other cases, a similar procedure can be performed without skin island, with a linear T-inverted scar (Fig.25a-b centrale). The variants of techniques are several and can be customized for specific oncologic cases (Fig. 26).

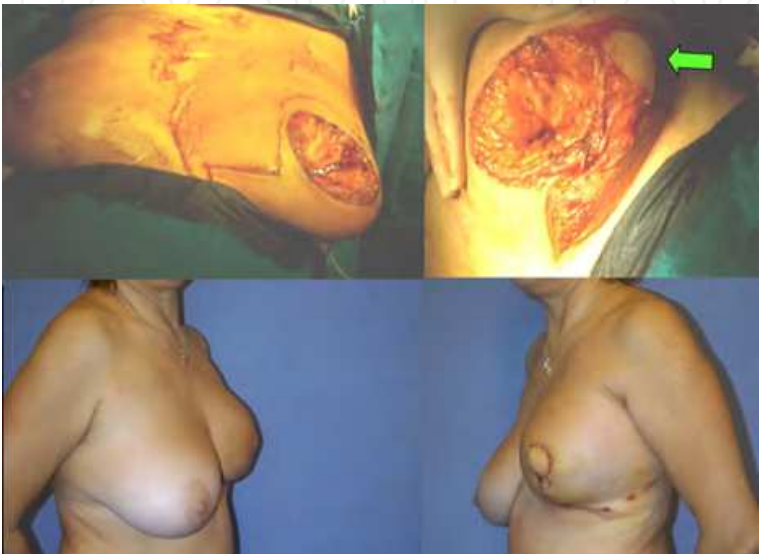

Fig. 22. Reshaping of the breast after central quadrantectomy by inferior-medial pedicle supporting an inferior-lateral skin island (see arrow). Above, Intraoperative view. Below, Postoperative view.

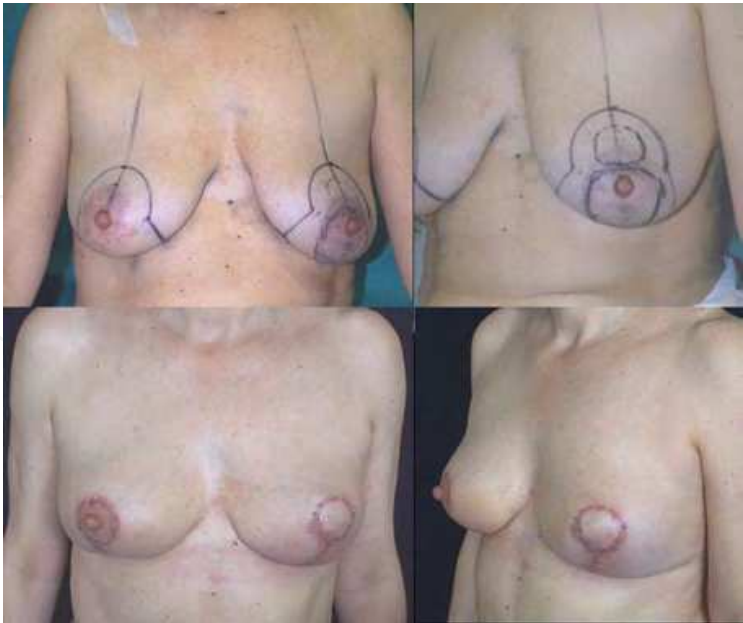


Fig. 23a. Reshaping of the left breast after central quadrantectomy using a superior pedicle supporting the skin island associated to an inferior flap as endoprosthesis; mirror mastopexy with similar technique. Above: Preoperative view. Below: Postoperative view.

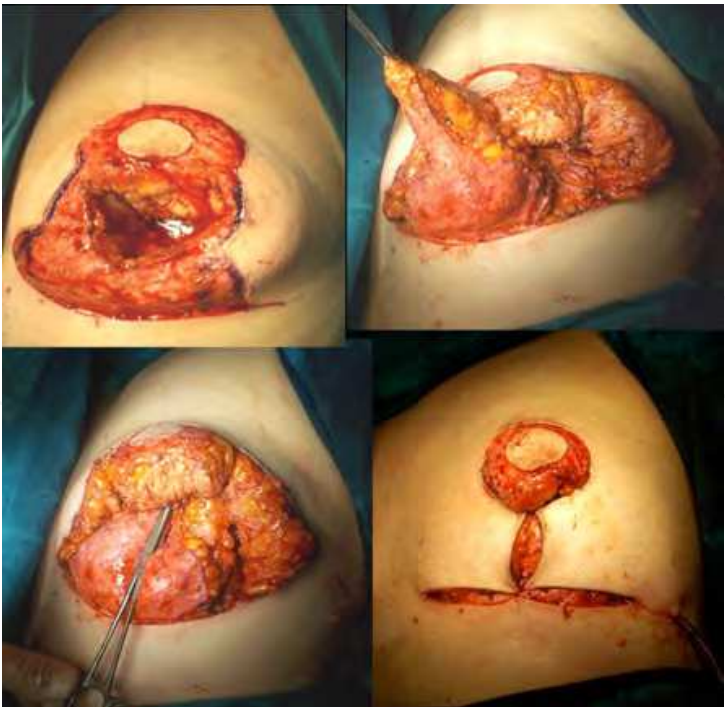

Fig. 23b. Reshaping of the left breast after central quadrantectomy using a superior pedicle supporting the skin island associated to an inferior flap as endoprosthesis. Above: Intraoperative view.

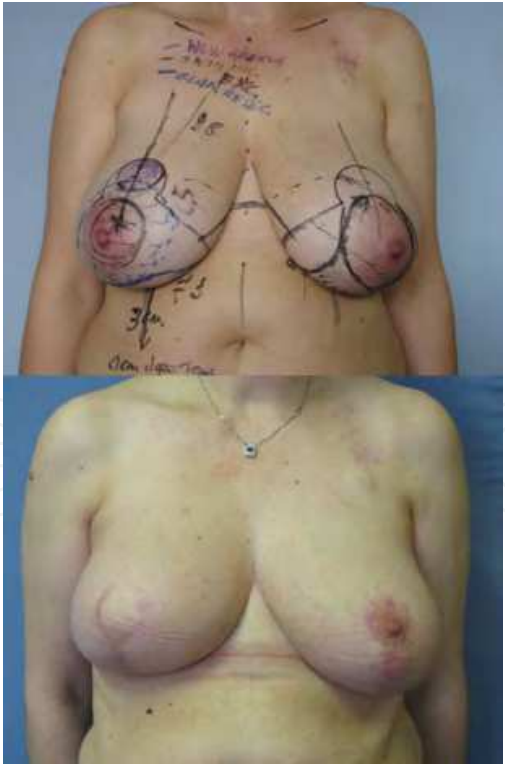


Fig. 24. Reshaping of the right breast after central quadrantectomy using a superior pedicle supporting the skin island associated to an inferior flap as endoprosthesis (introduced by Nava); mirror mammaplasty mastopexy with inferior pedicle flap. Above: Preoperative view. Below: Postoperative view.

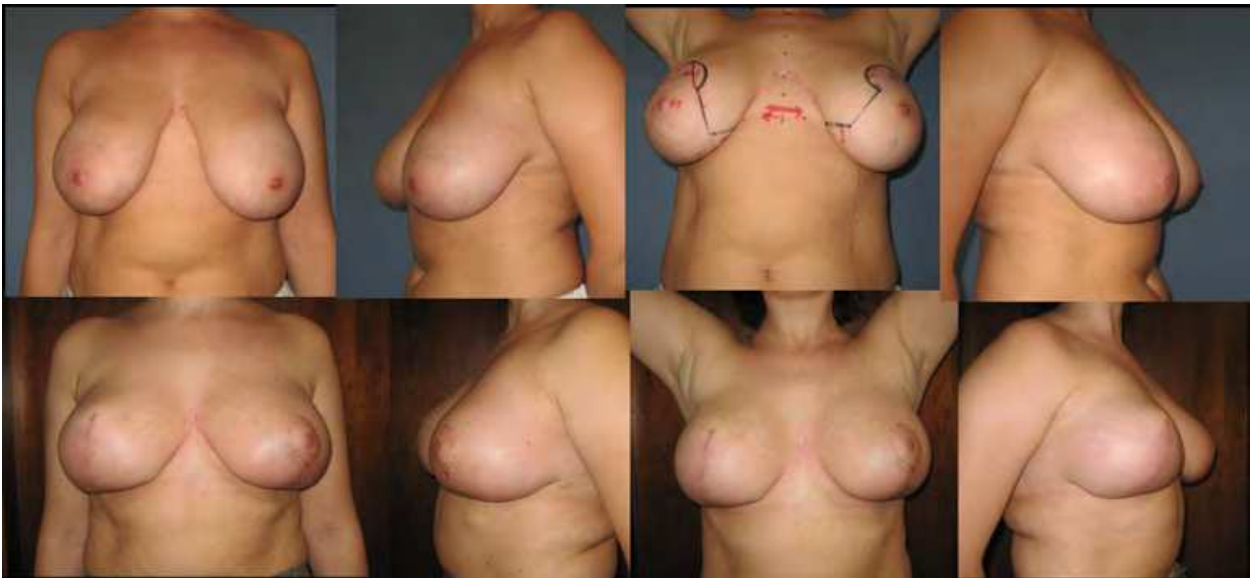

Fig. 25a. Reshaping of the right breast after central quadrantectomy using a superior pedicle without skin island, with a linear T-inverted, associated to an inferior flap as endoprosthesis; mirror mammaplasty mastopexy with medial-posterior pedicle flap, a variant of upper-medial flap designed by Riggio. Above: Preoperative view. Below: Postoperative view.

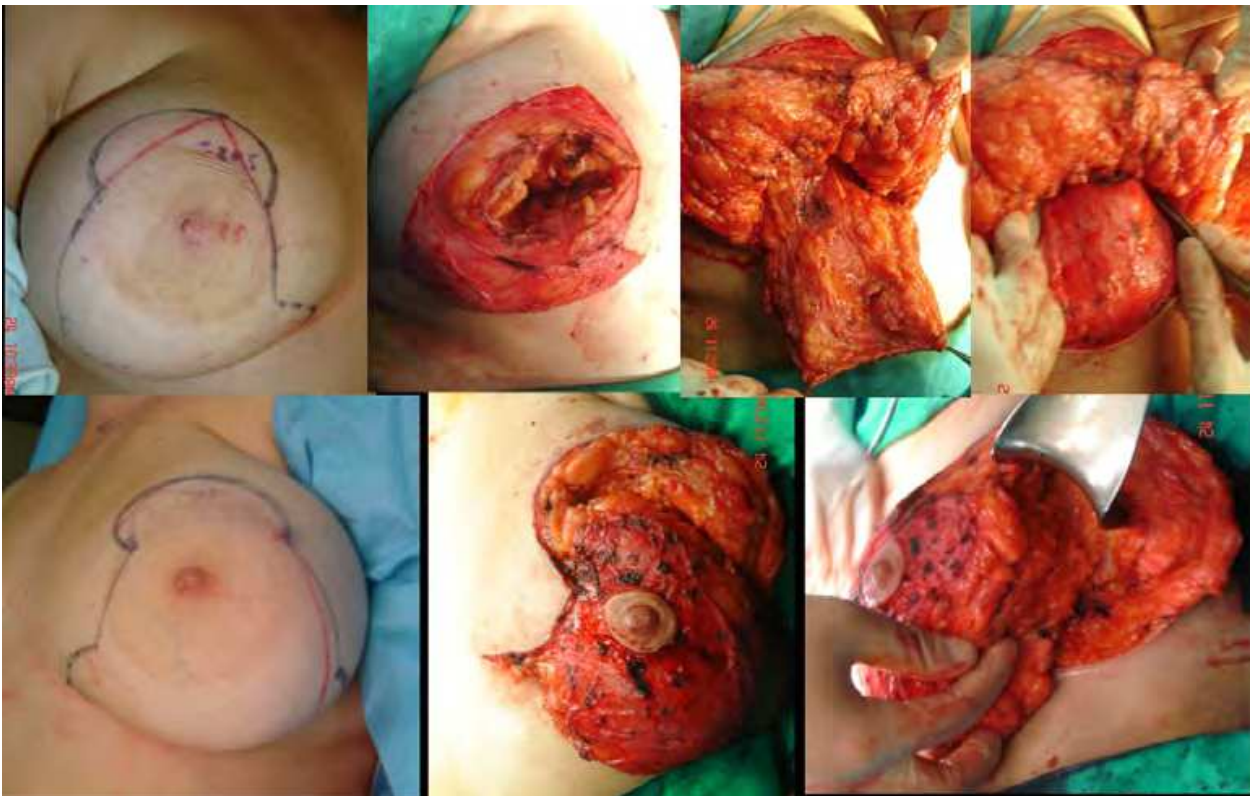

Fig. 25b. Reshaping of the right breast after central quadrantectomy using a superior pedicle without skin island, with a linear T-inverted, associated to an inferior flap as endoprosthesis; mirror mammaplasty mastopexy with the medial-posterior pedicle flap. Above: Intraoperative view of the right breast. Below: Intraoperative view of the left breast.

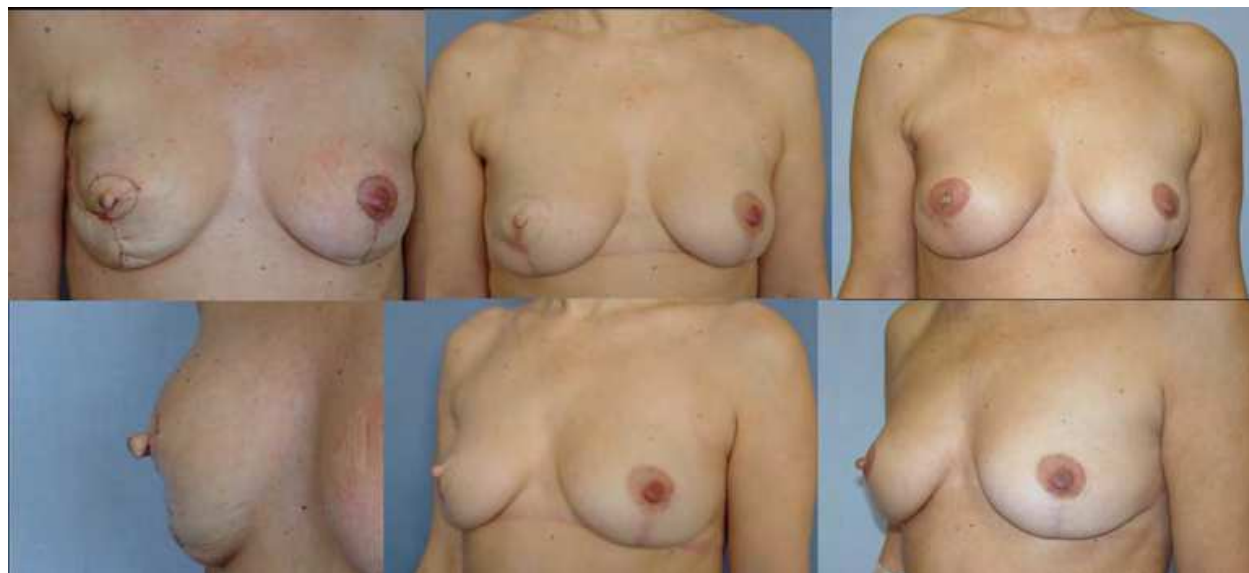


Fig. 26. Immediate right breast reshaping after bifocal central/upper-external quadrantectomy and nipple reconstruction; contralateral mirror mammoplasty. Left: short-term postoperative view. Center: medium-term postoperative view. Right: long-term postoperative view after areola tattoo.

2.3 The reconstruction after para-central inferior quadrantectomy

Tissue loss shows peculiar features at this level. There are both defects of areola skin and of the basement of nipple-areola complex. At least 7% of immediate reshaping involves this area. The retracting scar is a permanent cosmetic damage, if any correction is not immediately performed (Fig. 27).

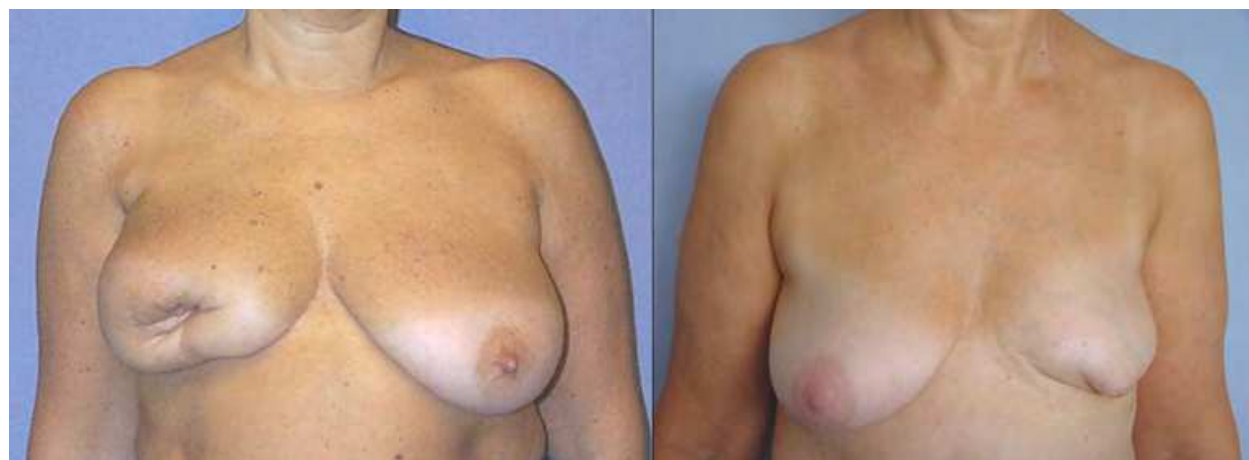


Fig. 27. Severe results after para-central/inferior quadrantectomy without immediate reconstruction. Collapse of nipple-areola complex.

2.3.1 Surgical techniques

The defect can be repaired with the same techniques used for central quadrant but with no or partial skin island. Fig. 28, 29, 30 demonstrate different applications.

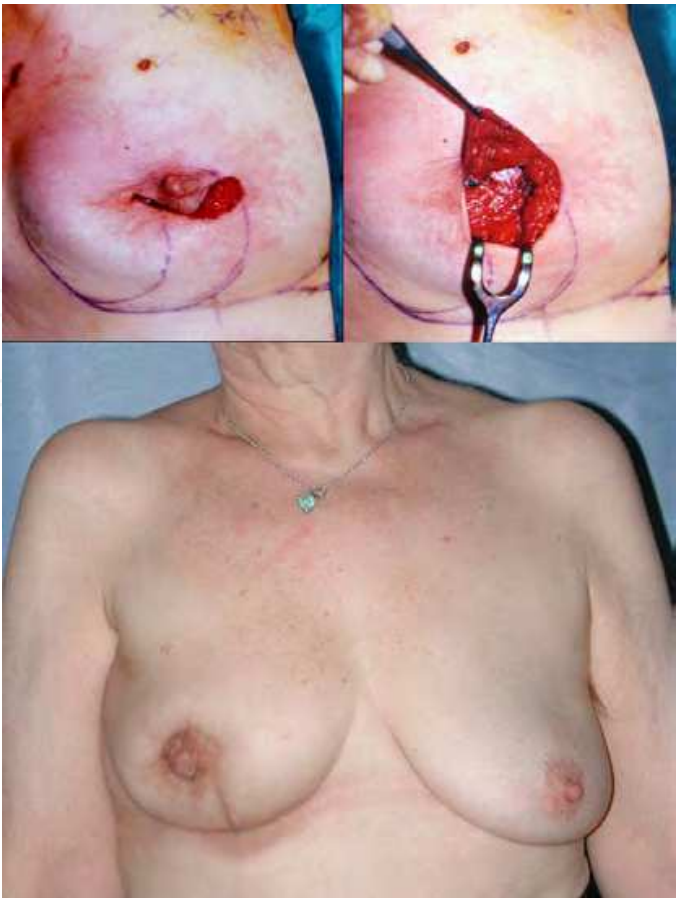


Fig. 28. Inferior-lateral pedicle flap according to Grisotti for reshaping after paracentral/inferior quadrantectomy. Above: Preoperative view. Below: Postoperative view

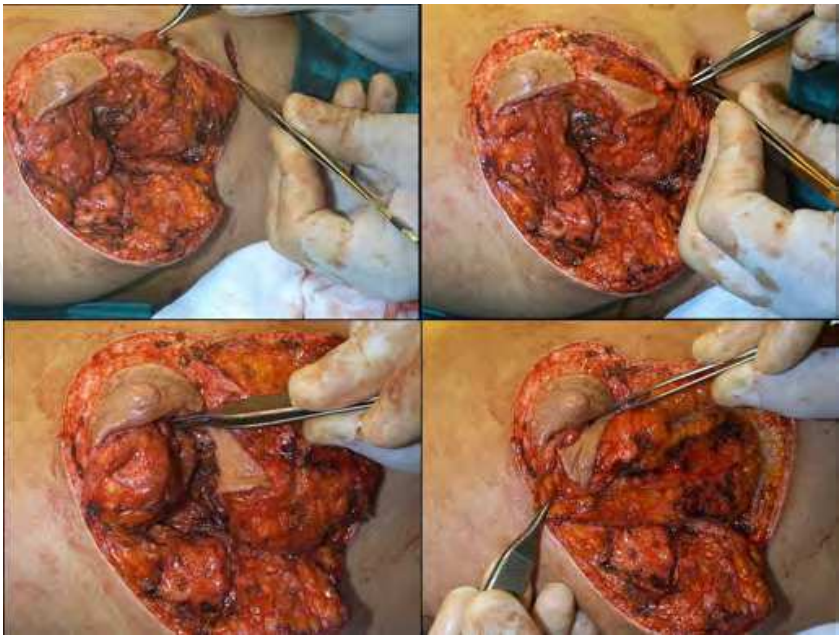


Fig. 29. Paracentral/inferior-external quadrantectomy repaired by superior dermaglandular pedicle combined to a small medial flap supporting partial skin island pro areola (special technique by Nava). Intraoperative view.

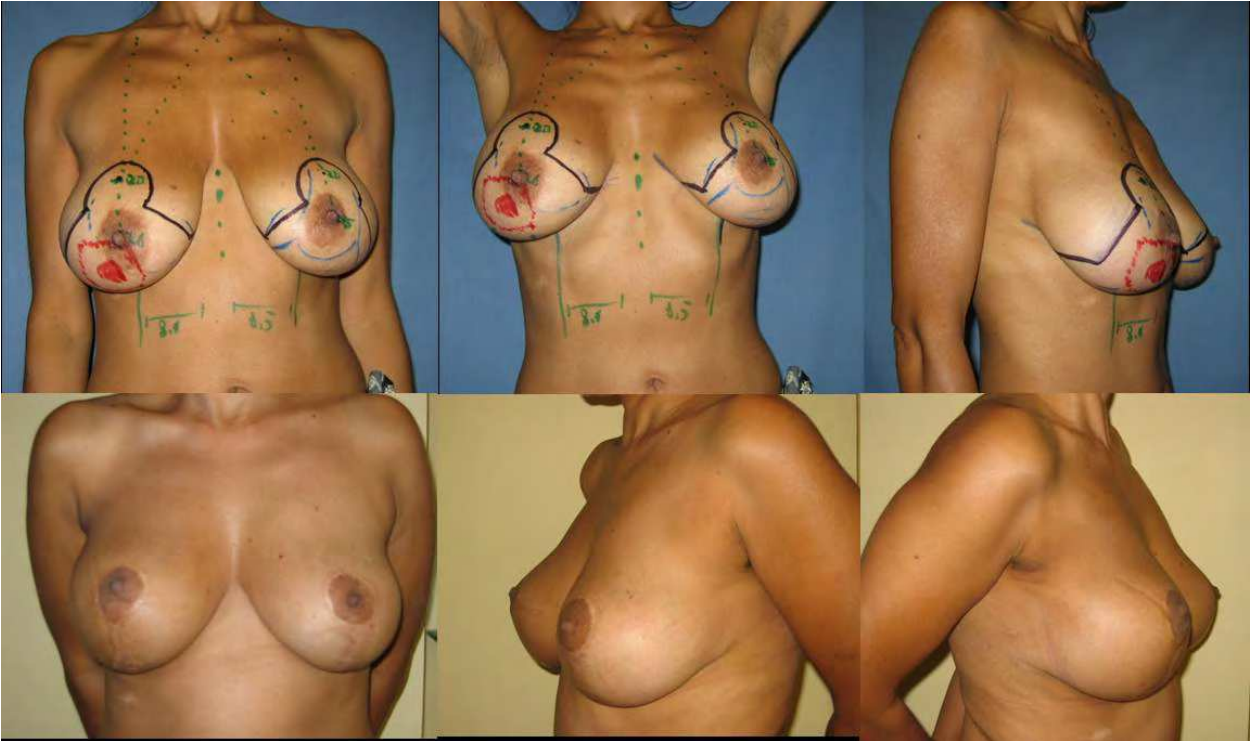


Fig. 30. Right breast paracentral/inferior-external quadrantectomy, with no areola skin excision, and reshaping by superior-medial dermaglandular pedicle combined to inferior pedicle as endoprosthesis. Contralateral mammoplasty using a superior pedicle combined to inferior endoprosthesis. Above: Pre-op view. Below: Post-op view at long-term.

2.4 The reconstruction after inferior quadrantectomy

After the central quadrant where the rate of immediate reconstruction overcomes the 95% in our experience, it is the inferior quadrant to have the highest rate of immediate reconstruction, at least 70% of total reconstructions including immediate and delayed. The inferior quadrantectomy produces a dramatic deformation if not reconstructed (Fig. 31).

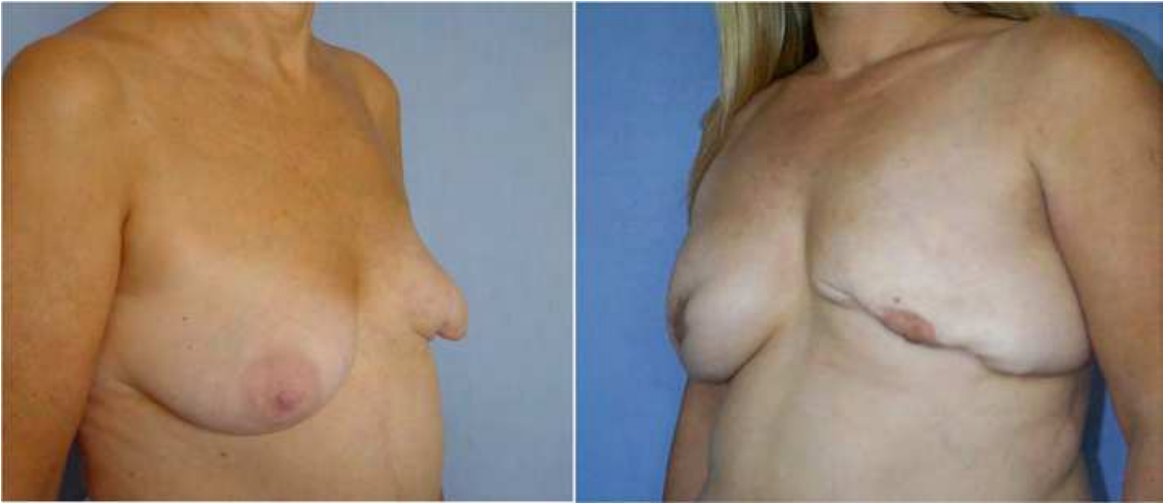

Fig. 31. Scar retraction and severe tissue loss in two patients after inferior quadrantectomy with no reconstruction.

2.4.1 Surgical techniques

The techniques are similar to those used in aesthetic surgery when a reduction mammoplasty is carried out through the resection of the inferior breast (Fig. 32). Nipple-areola is supported by a dermaglandular pedicle based superiorly.

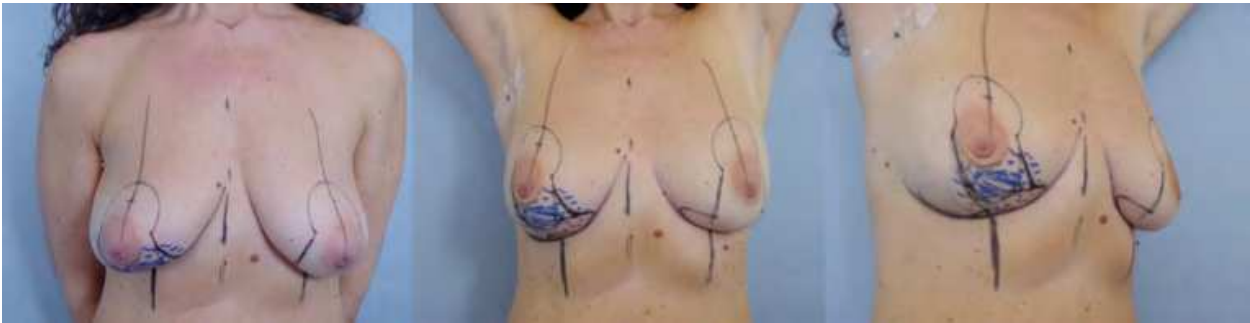

Fig. 32. Right breast reshaping deformities after inferior quadrantectomy using mastopexy at upper dermoglandular flap. Mirror mastopexy. Preoperative marks, details. Left: Frontal view. Center: Lifted arms. Right : Lateral Right view.

Skin incision can be as T-inverted or J or B; all the residual gland is dissected off the deep fascia and muscle plane and then mobilized(Fig. 33. 34, 35). The surgical difference consists of the direction of the wise-pattern that can be moved medially or laterally to include the cancer site (Fig. 36).



Fig. 33. Drawing of the flap harvesting for breast reshaping after inferior medial quadrantectomy. The incision pattern can be at T-inverted (Left) or at B (Center). All the residual gland is separated from the fascio-muscular plane and mobilized. The final scar must end alongside the inframammary fold (Right).



Fig. 34. Drawing of the flap harvesting for breast reshaping after inferior-lateral quadrantectomy

Another technical solution is given by the placement of the medial or lateral segment of the horizontal incision line from the inframmary fold to the tumour site (Fig. 37). This may occur in the clinical case where tumour is located more medially or laterally, overlying skin must be removed due to surgery or prior scar, or the breast is less ptotic and large.



Fig. 35. Drawing of the flap harvesting for breast reshaping after inferior median quadrantectomy

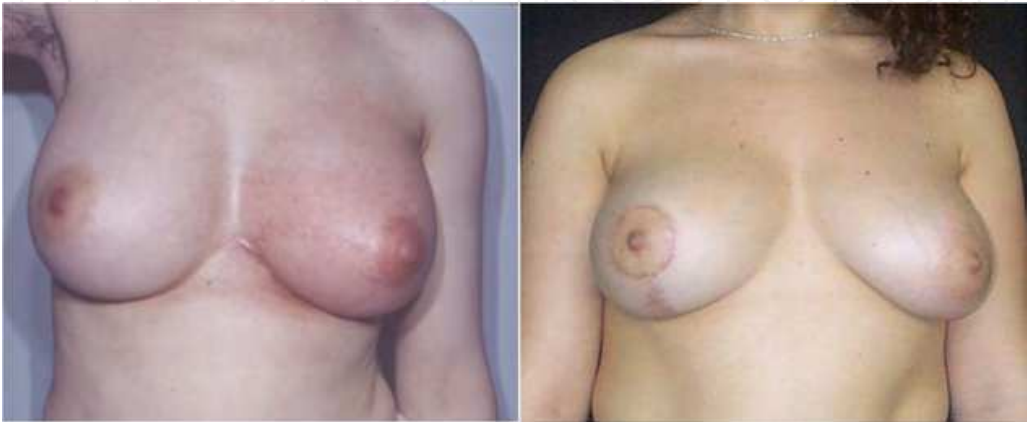

Fig. 36. Breast reshaping after inferior quadrantectomy using upper dermoglandular flap. Two final results different for cancer site. Left, inferior-medial quadrantectomy in the left breast with B-pattern. Right: inferior-medial quadrantectomy in the right breast with T-inverted scar.

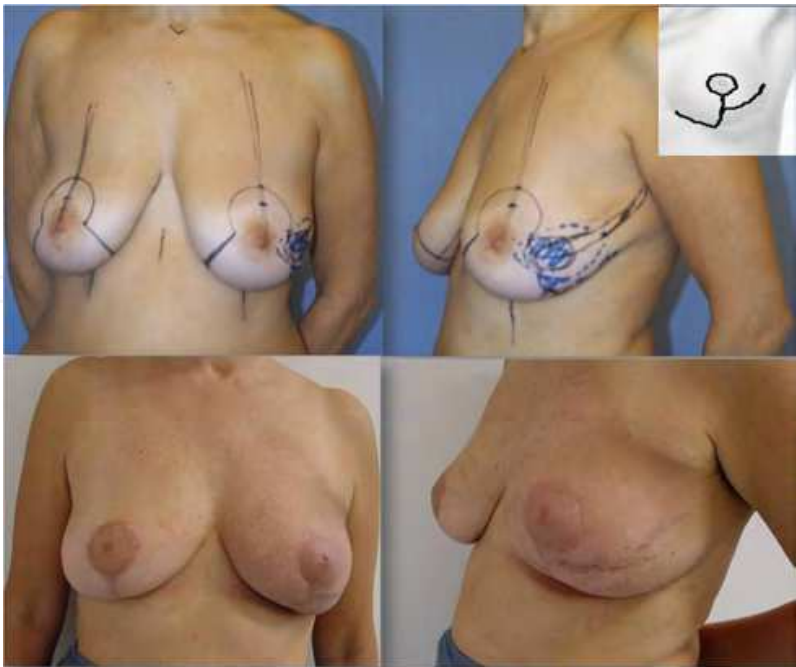


Fig. 37. Breast reshaping after inferior quadrantectomy using upper dermoglandular flap. Replacement of the lateral segment of horizontal incision line from the inframmary fold to the inframmary fold to the tumour site

As occurred in other quadrants, oncoplastic surgery can present operative situations outside the usual rules of aesthetic technique concerning breast reduction and pexy. There are items that can make breast reshaping much more difficult : deformities for prior tumorectomy and fibrotic retraction, or planning of wide skin excision. The first Author found a solution for the breast that needs for severe skin deformities to be repaired: an inferior skin-glandular flap to be transposed (Fig.38a, b, c).

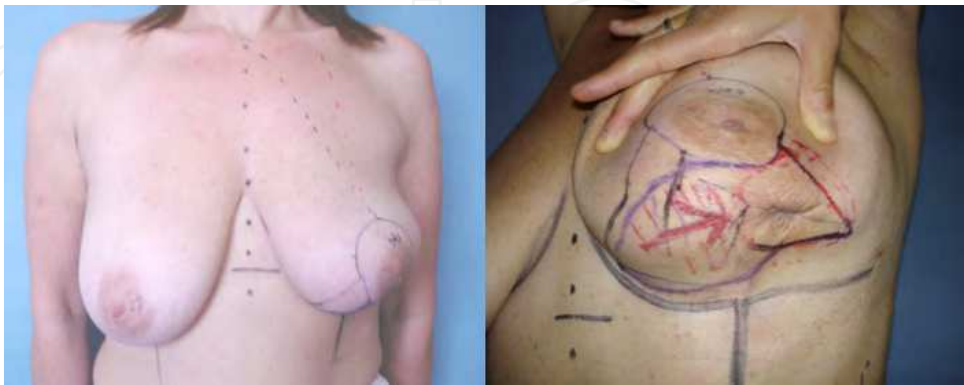


Fig. 38a. Inferior rotation skin-glandular flap, first performed by Riggio, for reshaping of deformities after inferior quadrantectomy, left breast. Left : Preoperative frontal view. Right: Preoperative close-up with marking details.

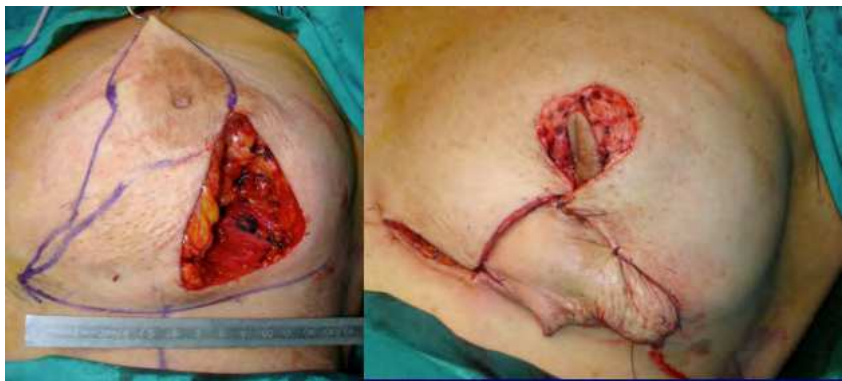

Fig. 38b. Inferior rotation skin-glandular flap, for reshaping of deformities after inferior quadrantectomy, left breast. Left: Intraoperative technical step. Right: Intraoperative result.

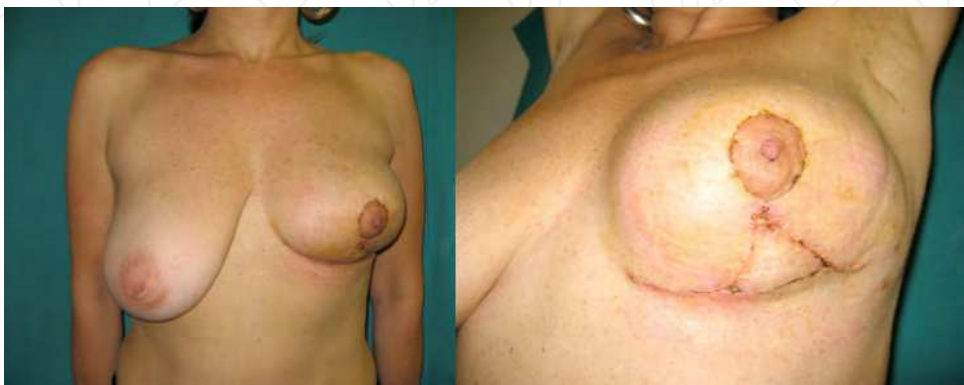

Fig. 38c. Inferior rotation skin-glandular flap, for reshaping of deformities after inferior quadrantectomy, left breast. Left : immediate result after surgery, frontal view. Right: Immediate result after surgery, close-up.

2.5 Reconstruction by prosthesis insertion

The experience started in the '80s of the last century - with round, semilunar, and tear-drop shapes and volume (range 40-400cc) - and suggested not to treat quadrantectomy defects using silicone implant, either immediately or secondarily. Result were mostly unsatisfactory. The 56% of capsular contracture (Baker 3-4) in all implant cases with/without irradiation) is to be compared with the 67% of severe contracture in the group of irradiated patients. Other complications were infection, seroma, and implant extrusion. Secondary surgery was necessary in the 55.5% of our series.

3. Delayed reconstruction

The analysis of the deformity should comprise: a) classification, b) surgical plan, c) reconstructive chance in case of recurrences. The type of previous surgery must be known: lumpectomy, extended tylectomy, partial mastectomy, quadrantectomy, and sectorial mastectomy.

The larger part of delayed reconstruction is consisted of autologous distant flaps (48%). Nevertheless this surgery finds minor indications for two reasons: 1) high rate of complication after breast irradiation; 2) increasing risk of local recurrence per year. The last issue leads to a dilemma in case of major reconstruction by distant or free flaps. Is it more advisable to preserve flap reconstruction in the case of future recurrences, if salvage mastectomy after QUART would require mandatory reconstruction with flap? Or else, to provide for a prophylactic mastectomy and consequent reconstruction by myocutaneous flap?

Most BCT deformities include partial breast resection and irradiation. Nearly 10% was excluded by radiotherapy due to the less malignant diagnosis (all severe dysplasia; a few carcinoma in situ). The breast not irradiated can be freely managed with secondary breast reshaping and implant augmentation with no increased risk for complications. Augmentation can be feasible and reliable in particular cases but requires higher skill in breast reconstruction as usual (Fig. 39).

Irradiated tissues (skin and parenchyma) requires extreme care to be surgically treated and is advisable to manage secondary corrections after three post-op years. Reshaping by pexy-technique is feasible for minor defects, but always risky for tissue necrosis. Reliable techniques utilise scar lengthening (multiple Z-plasty) and nipple-areola advancement to improve shape. As well, all the aesthetic procedures can be used in the contralateral breast in order to improve simmetry. Micro-fat injections, i.e. lipofilling, can be used for small tissue loss and skin scarring.

3.1 Autologous flap reconstruction

The prevalence of flap reconstruction is also decreased depending on the improvement of the general surgeon's care of cosmetic results and the higher rate of immediate plastic reshaping, but it still maintains a real capacity of sculpting an acquired deformity as no other can do it. Fig. 40 demonstrates how a latissimus dorsi flap - performed by the first Author - is able to be shaped and customized into the neighbouring scar tissues. In our experience, it is better isolate and cut the motor nerve of the muscle proximally. Irradiated tissues must be debrided, prudently dissected and carefully removed if necessary, in order

to obtain optimal symmetry as volume and contouring. Breast perforators coming from the chest wall should be preserved as much as possible in order to reduce the risk for increased parenchyma post-surgical fibrosis or even necrosis.

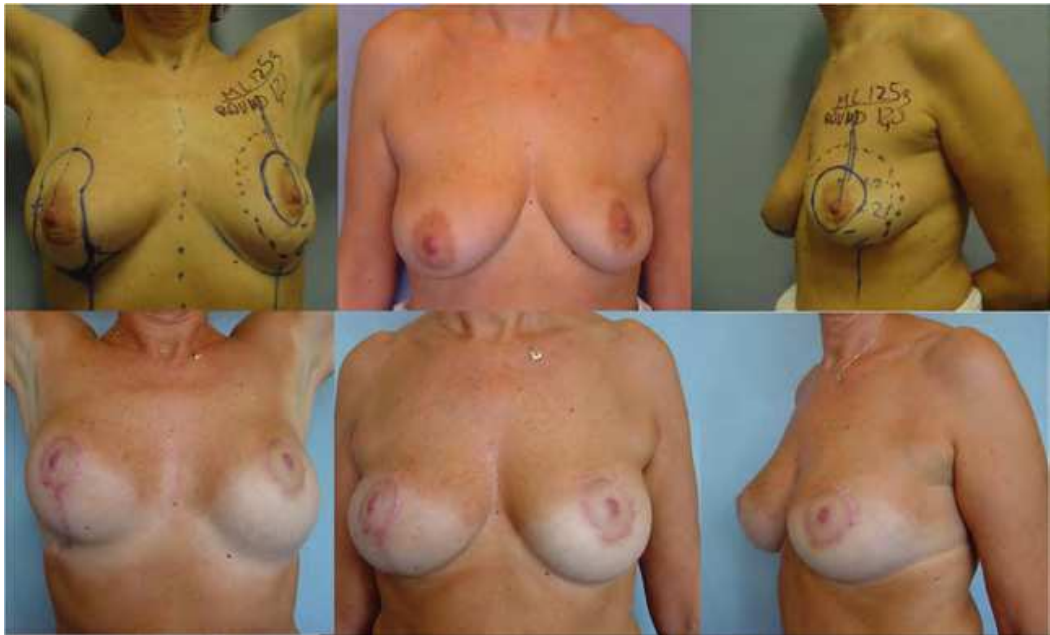

Fig. 39. Delayed left breast reconstruction after upper quadrantectomy, by anatomical implant (Allergan 410ML 125g) and round-block pexy. The previous scar was included in the deepithelialised area. The contralateral breast was corrected by a reshaping by upper pedicle flap. Above Left: Frontal view at lifted arms, preop marks. Center: Frontal view. Right: Lateral left view, preop marks. Below: corresponding postoperative views.

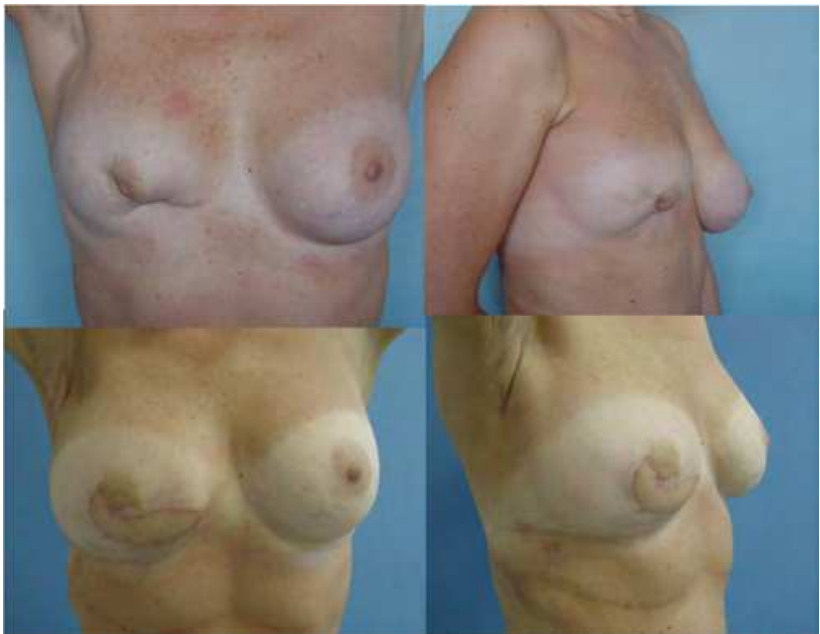

Fig. 40. Delayed reconstruction of the right breast after QUART using a latissimus dorsi myocutaneous flap. Above, Preoperative views, Left: frontal view at lifted arms. Right: lateral view. Below, Postoperative views, Left: frontal view at lifted arms. Right: lateral view.

The preop analysis of the deformity after BCT must evaluate the balance between cutaneous and subcutaneous/glandular resection, that is the main factor which determines the type of deformity. The second consideration regards individual characteristics: a) size and shape of the operated breast; b) scar retraction; c) size and shape of the opposite healthy breast; d) patient body structure. Last of all, the donor area of the flap will be detected: a) distance from the recipient breast deformity; b) presence of scar; c) tissue thickness; d) skin elasticity/stiffness, texture, and pigmentation; e) the donor area sequels. Then, the fasciocutaneous or myocutaneous can be chosen. Our preference is towards the myocutaneous pedicled flaps for two reasons: 1) major mobilization and rotation grade to be accustomed into the defect; 2) no problem compared with free flap which needs for vascular dissection deeply to an irradiated breast tissue that cannot be easily cut or removed. According to our past experience, latissimus dorsi and TRAM flaps were respectively used in 10% and 2% of total reconstructive cases. Two latissimus dorsi flaps were augmented by implant. Nowadays, TRAM has been discontinued excepting the decision for a mastectomy. Different solutions have been taken into account as the perforator flaps (Tseng, 2010). The best of them is the parascapular flap as it regards BCT (Hamdi, 2004).

The latissimus dorsi flap requires correct preparation of the recipient site and planning of the skin island on the back, as first (Fig.41). The location of the skin island must suit the breast shape and perfectly harmonize the skin and parenchyma defects (Fig. 42).

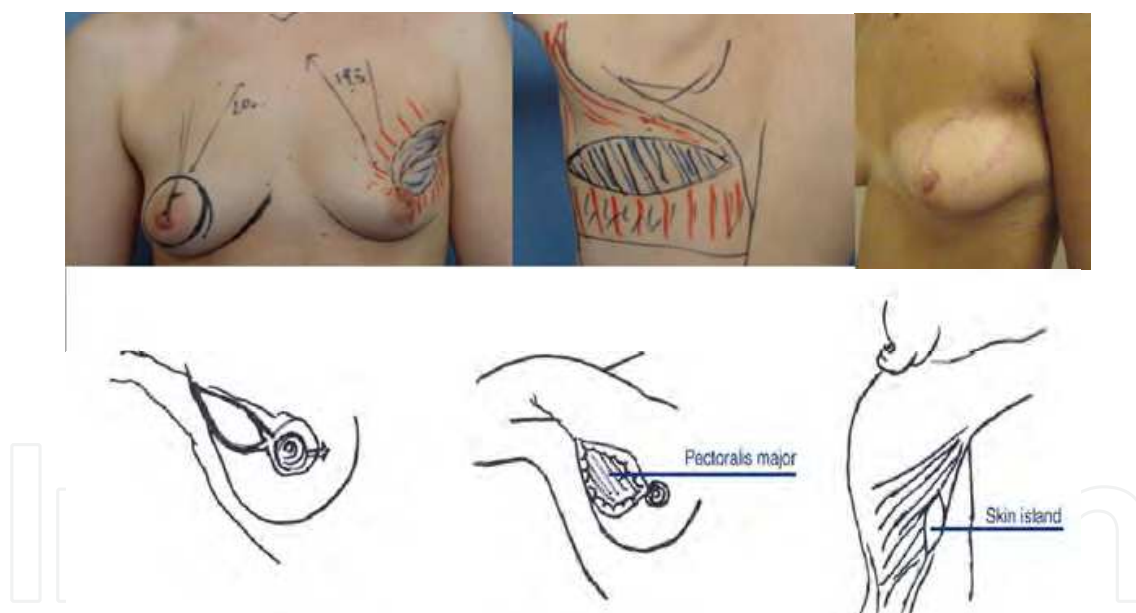


Fig. 41. Drawing of the latissimus dorsi flap for upper-external deformity. From left to right: dissection above the pectoralis maior muscle and removal of scar tissue, debridement and advancement of the nipple-areola complex, harvesting of skin island along with the muscular pedicle, result.

The TRAM flap must be limited to larger reconstruction (Fig.43). It was rarely used, and now indicated only for breast really amputated of the patients that decline the idea of a total mastectomy before the full-size reconstruction. Skin texture and subcutaneous thickness are less forgeable compared with latissimus dorsi flap, and hence the recipient site must be prepared with larger dissection and excision of fibrotic tissue.

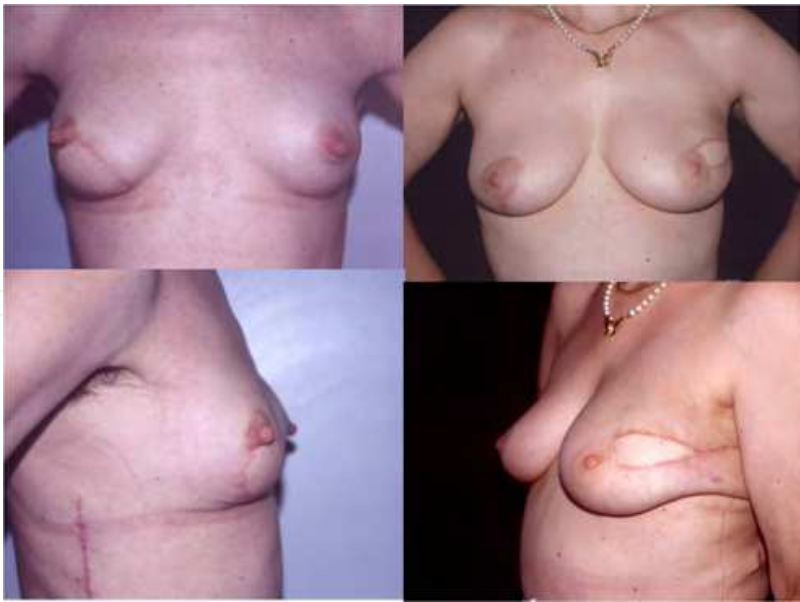

Fig. 42. Delayed breast reconstruction after QUART using latissimus dorsi myocutaneous flap. Left: Result after inferior resection, frontal and lateral views. Right: Result after lateral resection, frontal and lateral views.

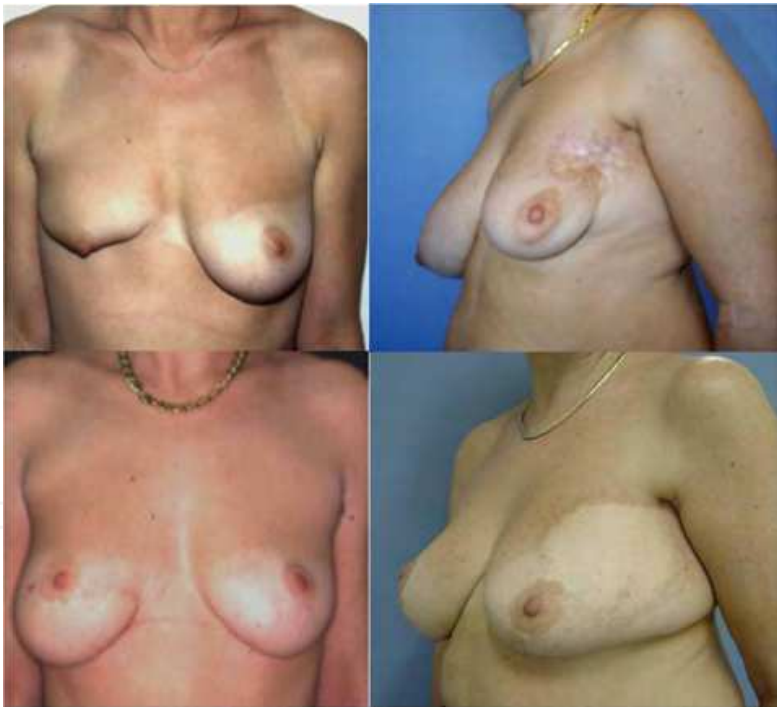

Fig. 43. Delayed breast reconstruction after QUART using TRAM flap. Left: Result after inferior resection, frontal view; above: preop, below: postop. Right: Result after lateral resection, lateral view; above: preop, below: postop.

4. Oncoplastic results

Reconstruction procedures must be considered as an integral part of the breast conservative treatment. Breast surgeon still thinks to manage many partial mastectomies without the aid

of some plastic aesthetic surgeon. Many authors were interested of this item in the past as well as recently, and we have reported a series of up-to-date references.

Immediate reshaping specifically needs for skill in cosmetic mastopexy and reduction to be successful in addition to the reconstructive and oncological expertise. Cosmetic results without reconstruction show low rates of appraisal, nearly 35% of them is poor. In the institutional series (Fig. 44), the results of BCT with immediate reconstruction were satisfactory in almost the 70% after 13.5 years of follow-up. Shape satisfaction reached the 75% of appraisals. On the other hand, symmetry was a little more satisfactory in the delayed group of reconstructions (>60%). However immediate reshaping remains the primary option for the best result. Also the contralateral mammoplasty improves symmetry even if contemporary. According to the patient wishes, mirror mammoplasty is better to be carried out immediately. Only 37% of cases underwent contralateral aesthetic surgery. Half of them consisted of breast reduction with upper dermaglandular flap, secondarily reduction with inferior flap; all mastopexis overcame the 20%.

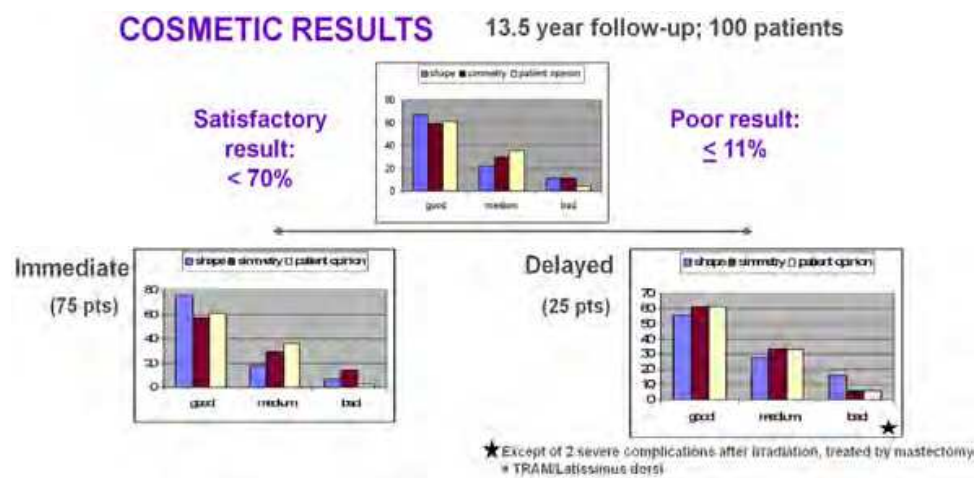


Fig. 44. Diagram of cosmetic results after BCT reconstruction in a pilot-study of 100 patients.

The oncological follow-up was 15 years in our pilot-study (Table 3):	
Time free of disease	2-11 yrs
Local recurrences	12/89
- Recurrences treated by further BCT	7
- Recurrences treated by salvage mastectomy (4 TRAM)	5
Contralateral cancer incidence	11
- Breast conservative treatment and dermaglandular reshape	5
- Patey mastectomy and breast reconstruction: 4 implants and 1 TRAM	6
Sporadic finding of controlateral cancer during surgery	0
Metastatic cancer	8
Patient survival after 15 years	95/100

Table 3. Oncological results (T<2.5cm; N0 out of N1 in 10 pts.; M0)

Above all, 13.5% of local recurrences, 9% of distant metastases, and 95% of survival rate reflect the literature data positively, and moreover demonstrate the comprehensive efficacy of the historical experience of our Cancer Institute.

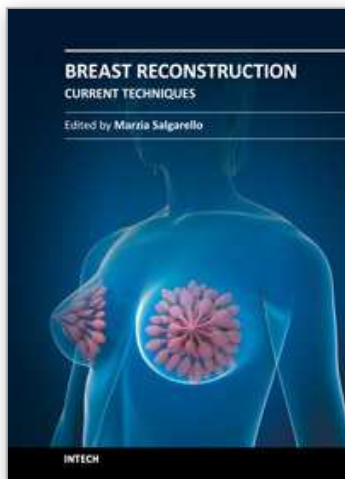
5. References

- Viani, GA., Stefano, EG., Afonso SL., De Fendi, LI., Soares, FV., Leon, PG., Guimaraes, FS., (2007) Breast-conserving surgery with or without radiotherapy in women with ductal carcinoma in situ: a meta-analysis of randomized trials. *Radiat Oncol.*, Vol. 2, (Aug 2007), pp. 2-28.
- Silverstein, MJ. (2006). Ductal carcinoma in situ: basics, treatment controversies, and an oncoplastic approach, In: *Surgery of the Breast: Principles and Art*. Vol. 1, Spear SL (ed.), 2nd ed., pp. 512-534, Lippincott Williams and Wilkins, Philadelphia.
- Fisher, ER., Costantino, J., Fisher, B., Palekar, AS., Redmond, C., Mamounas, E., (1995) Pathologic findings from the National Surgical Adjuvant Breast Project (NSABP) Protocol B-17. Intraductal carcinoma (ductal carcinoma in situ). The National Surgical Adjuvant Breast and Bowel Project Collaborating Investigators. *Cancer*, Vol. 15, No.75, 6, (Mar 1995), pp. 1310-9.
- Silverstein, MJ., Lagios MD., Craig, PH., &al., (1996) A prognostic index for ductal carcinoma of the breast in situ. *Cancer*, Vol.77, (1996), pp.2267-2274
- Veronesi, U., Bonadonna, G., Zurrida, S., Galimberti, V., Greco, M., Brambilla, C., Luini, A., Andreola, S., Rilke, F., Raselli, R. &al., (1995) Conservation surgery after primary chemotherapy in large carcinomas of the breast. *Ann Surg.*, Vol.222, No.5, (Nov 1995), pp.612-8.
- Veronesi, U., Saccozzi, F., Del Vecchio, M., &al., (1981) Comparing radical mastectomy with quadrantectomy, axillary dissection, and radiotherapy in patients with small cancers of the breast. *N Engl J Med*, Vol.305, (1981), pp.6-11
- Veronesi, U., Banfi, A., Del Vecchio M., Saccozzi, R., Clemente, C., Greco, M., Luini, A., Marubini, E., Muscolino, G., Rilke, F., & al., (1986) Comparison of Halsted mastectomy with quadrantectomy, axillary dissection, and radiotherapy in early breast cancer: long-term results. *Eur J Cancer Clin Oncol.*, Vol.22, No.9, (Sept 1986), pp. 1085-1089.
- Veronesi, U., Volterrani, F., Luini, A., &al. (1990) Quadrantectomy versus lumpectomy for small size breast cancer. *Eur J Cancer*, Vol.26, (1990), pp. 671-673
- Veronesi, U., Cascinelli, N., Mariani, L., Greco, M., Saccozzi, R., Luini, A., Aguilar, M., (2001) Radiotherapy after breast-conserving surgery in small breast carcinoma: long-term results of a randomized trial. *Ann Oncol.*, Vol.12, No.7, (Jul 2001), pp.997-1003.
- Veronesi, U., Cascinelli, N., Mariani, L., Greco, M., Saccozzi, R., Luini, A., Aguilar, M., Marubini, E., (2002) Twenty-year follow-up of a randomized study comparing breast-conserving surgery with radical mastectomy for early breast cancer. *N Engl J Med.*, Vol.17, No.347(16) pp.1227-32.
- Fisher, B., Bauer, M., Margolese, R., Piosson, R., Pilch, Y., Redmond, C., Fisher, E., Wolmark, N., Deutsh, M., Montague, E., &al. (1985) Five-year results of a randomized clinical trial comparing total mastectomy and segmental mastectomy with or without radiation in the treatment of breast cancer. *N Engl J Med.*, Vol.14, No.312(11), (1985), pp.665-73

- Fisher, B., Anderson, S., Bryant, J., Margolese, RG., Deutsch, M., Fisher, ER., Jeong, JH., Wolmark, N., (2002) Twenty-year follow-up of a randomized trial comparing total mastectomy, lumpectomy, and lumpectomy plus irradiation for the treatment of invasive breast cancer. *N Engl J Med.* Vol.17, No.347(16)(Oct 2002), pp.1233-41.
- Joop, A. van Dongen, Adri, C.Voodg, Ian, S. Fentiman, Catherine Legrand, Richard J.Sylvester, David Tong, Emmanuel, van der Shueren, Peter A., Helle, Kobus van Zijl and Harry Bartelink, (2000) Long-Term Results of a Randomized Trial Comparing Breast-Conserving Therapy With Mastectomy: European Organization for Research and Treatment of Cancer 10801 Trial. *J Natl Cancer Inst.*, Vol.92, No.14, (2000)pp. 1143-1150.
- Arriagada, R., Le, MG., Contesso, G., Guinebrètiere, JM, Rochard, F., Spielmann, M., (2002) Predictive factors for local recurrence in 2006 patients with surgically resected small breast cancer. *Ann Oncol.* Vol.13, No.9(2002)pp.1404-13.
- Yang, SH., Yang, KH., Li, YP., Zhang YC, He XD., Song, AL., Tian JH., Jiang, L., Bai ZG., He, LF., Liu, YL., Ma, B., (2008). Breast conservation therapy for stage I or stage II breast cancer: a meta-analysis of randomized controlled trials. *Ann Oncol.*, Vol.19 (2008)pp.1039-1044.
- Grisotti, A., (1994) Immediate reconstruction after partial mastectomy. *Oper. Techn. Plast Reconstr. Surg.*, Vol.1, No.1, (1994)pp.1-12.
- Tseng, CY., Lipa, JE., (2010) Perforator flaps in breast reconstruction. *Clin Plast Surg.*, Vol.37, No.4(Oct 2010), pp.641-54 vi-ii.
- Hamdi, M. Van Landuyt, K., Monstrey, S., Blondeel, P., (2004) Pedicled perforator flaps in breast reconstruction: a new concept. *Br J Plast Surg.* Vol.57, No.6, (Sept 2004)pp.531-9
- De Lorenzi, F.(2010) Oncoplastic surgery : the evolution of breast cancer treatment. *Breast J.*, Vol.16, Suppl 1, (Sept-Oct 2010), pp.S 20-1.
- Perez, CA.(2010) Breast conservation therapy in patients with stage T1-T2 breast: current challenges and opportunities. *Am J ClinOncol.*, Vol.33, No.5, (Oct 2010), pp.500-10.
- Fitoussi, AD., Berry MG., Famà, F., Falcou, MC., Curnier, A., Couturaud, B., Reyat, F., Salmon, RJ., (2010) Oncoplastic breast surgery for cancer: analysis of 540 consecutive cases. *Plast Reconstr Surg.*, Vol.125, No.2, (Feb 2010), pp.454-62.
- Hernanz, F. Regaño, S., Vega, A., Gómez Fleitas, M., (2010) Reduction mammoplasty: an advantageous option for breast conserving surgery for large breasted patients. *Surg.Oncol.*, Vol.19, No.4, (Dec 2010), pp. e95-e102. Epub 2009 Aug 27. Review
- Berry, MG., Fitoussi, AD., Curnier, A., Couturaud, B., Salmon, RJ., (2010) Oncoplastic breast surgery: a review and systematic approach. *J Plast Reconstr Aesthet Surg.*, Vol.63, No.8, (Aug 2010), pp.1233-43 Epub 2009 Jun 25. Review
- Hoffmann, J. Wallwiener, D., (2009) Classifying breast cancer surgery: a novel, complexity-based system for oncological, oncoplastic and reconstructive procedure, and proof of principle by analysis of 1225 operations in 1166 patients. *BMC Cancer*, Vol.8, No.9, (Apr 2009), p.108.
- Franceschini, G., Terribile, D., Fabbri, C., Magno, S., D'Alba, P., Chiesa, F., Di Leone, A., Masetti, R., (2008) Progress in treatment of early breast cancer. A mini- review *Ann Ital Chir*, Vol.79, No.1, (Jan-Feb 2008), pp.17-22.
- Franceschini, G. Magno, S., Fabbri, C., Chiesa, F., Di Leone, A., Moschella, F., Scafetta, I., Scaldaferrì, A., Fragomeni, S., Adesi Barone, L., Terribile, D., Salgarello M, Masetti,

- R., (2008) Conservative and radical oncoplastic approaches in the surgical treatment of breast cancer. *Eur Rev Med Pharmacol Sci.*, Vol.12, No.6, (Nov– Dec 2008), pp.387-96.Review
- Rietjens, M., Urban, CA., Rey, PC., Mazzarol, G., Maisonneuve, P., Garusi, C., Intra, M., Yamaguchi, S., Kaur, N., De Lorenzi, F., Matthes, AG., Zurrida, S., Petit, JY., (2007) Long term oncological results of breast conservative treatment with oncoplastic surgery. *Breast*, Vol.16, No.4(Aug 2007), pp. 387-95.Epub 2007 Mar 26.
- Vallejo da Silva, A., Destro, C., Torres, W., (2007)Oncoplastic surgery of the breast: rationale and experience of 30 cases. *Breast*, Vol.16, No.4(Aug2007), pp.411-9.Epub 207 Mar 19
- Luini, A. Gatti, G., Galimberti, V., Zurrida, S., Intra, M., Gentilini, O., Paganelli, G., Viale, G., Orecchia, R., Veronesi, P, Veronesi, U., (2005) Conservative treatment of breast cancer: its evolution. *Breast Cancer Res Treat.*, Vol.94, No.3, (Dec2005)pp.195-8 Review

IntechOpen



Breast Reconstruction - Current Techniques

Edited by Prof. Marzia Salgarello

ISBN 978-953-307-982-0

Hard cover, 276 pages

Publisher InTech

Published online 03, February, 2012

Published in print edition February, 2012

Breast reconstruction is a fascinating and complex field which combines reconstructive and aesthetic principles in the search for the best results possible. The goal of breast reconstruction is to restore the appearance of the breast and to improve a woman's psychological health after cancer treatment. Successful breast reconstruction requires a clear understanding of reconstructive operative techniques and a thorough knowledge of breast aesthetic principles. Edited by Marzia Salgarello, and including contributions from respected reconstructive breast plastic surgeons from around the world, this book focuses on the main current techniques in breast reconstruction and also gives some insight into specific topics. The text consists of five sections, of which the first focuses on the oncologic aspect of breast reconstruction. Section two covers prosthetic breast reconstruction, section three is dedicated to autogenous breast reconstruction, and section four analyzes breast reconstruction with a fat graft. Finally, section five covers the current approaches to breast reshaping after conservative treatment.

How to reference

In order to correctly reference this scholarly work, feel free to copy and paste the following:

Egidio Riggio and Valentina Visintini Cividin (2012). Breast Reconstruction Approach to Conservative Surgery, Breast Reconstruction - Current Techniques, Prof. Marzia Salgarello (Ed.), ISBN: 978-953-307-982-0, InTech, Available from: <http://www.intechopen.com/books/breast-reconstruction-current-techniques/breast-reconstruction-approach-to-conservative-surgery>

INTech
open science | open minds

InTech Europe

University Campus STeP Ri
Slavka Krautzeka 83/A
51000 Rijeka, Croatia
Phone: +385 (51) 770 447
Fax: +385 (51) 686 166
www.intechopen.com

InTech China

Unit 405, Office Block, Hotel Equatorial Shanghai
No.65, Yan An Road (West), Shanghai, 200040, China
中国上海市延安西路65号上海国际贵都大饭店办公楼405单元
Phone: +86-21-62489820
Fax: +86-21-62489821

© 2012 The Author(s). Licensee IntechOpen. This is an open access article distributed under the terms of the [Creative Commons Attribution 3.0 License](https://creativecommons.org/licenses/by/3.0/), which permits unrestricted use, distribution, and reproduction in any medium, provided the original work is properly cited.

IntechOpen

IntechOpen