

We are IntechOpen, the world's leading publisher of Open Access books Built by scientists, for scientists

6,900

Open access books available

186,000

International authors and editors

200M

Downloads

Our authors are among the

154

Countries delivered to

TOP 1%

most cited scientists

12.2%

Contributors from top 500 universities



WEB OF SCIENCE™

Selection of our books indexed in the Book Citation Index
in Web of Science™ Core Collection (BKCI)

Interested in publishing with us?
Contact book.department@intechopen.com

Numbers displayed above are based on latest data collected.
For more information visit www.intechopen.com



Double-Pedicle DIEP and SIEA Flaps and Their Application in Breast Reconstruction

Marzia Salgarello, Liliana Barone-Adesi and Giuseppe Visconti
*University Hospital "Agostino Gemelli",
 Catholic University of "Sacro Cuore", Rome,
 Italy*

1. Introduction

Autologous breast reconstruction with deep inferior epigastric artery perforator (DIEP) and superficial inferior epigastric artery (SIEA) flaps is nowadays considered the gold standard in post-mastectomy reconstruction. Excellent results could be achieved in term of softness and natural appealing breast, making these lower abdominal flaps very popular.

Nevertheless, large breast reconstruction still remains a challenge for the surgeons because the amount of fat that could be safely transferred with the DIEP and SIEA flaps in the conventional way could be insufficient to achieve a good symmetry with the contralateral breast. A contralateral reduction mammoplasty may solve some of these cases, but in other clinical situations a flap larger than standard is needed. This fact gains importance especially in patients with scant abdominal tissue or infraumbilical vertical scars, and in delayed reconstructions after previous modified radical mastectomy (MRM) where there is a severe lack of skin and subcutaneous tissue. Moreover, patients who previously had mastectomy plus expander breast reconstruction often show a depression of the cartilage rib cage which could need larger flap to be corrected.

2. Relevant applied microvascular anatomy of the DIEP and SIEA flaps

DIEP and SIEA flap relevant anatomy has been extensively explained in the relative chapters. In this paragraph we will focus on the microvascular anatomy of the abdominal flaps as its comprehension is key-point when choosing a double-pedicle instead of an unipedicle flap. A three- and four-dimensional computed tomographic angiography (CTA) study by Wong C. et al. on injected medial and lateral row DIE perforators demonstrates that the area of perfusion of a medial row DIE perforator is larger (around 300 cm²) and more centralized when compared to the lateral row DIE perforator ones, that results smaller (around 200 cm²) and more lateralized, encompassing almost only the ipsilateral hemiabdomen.

2.1 Arterial microvascular anatomy

When selecting a perforator for DIEP flap reconstruction, the largest perforator should be selected (i.e. the dominant perforator). The medial row perforators have been shown to often have dominance over the lateral row perforators. Furthermore, the "clinical"

angiosome sustained by a medial row perforator is normally larger than the one sustained by a lateral row perforator.

The perfusion of the transverse lower abdominal flap was first described by Scheflan and Dinner on the unipedicle transverse rectus abdominis musculocutaneous (TRAM) flap. These authors divided the lower abdominal ellipse into four equal parts and named them with numbers according to their clinical impression of perfusion. However, the zoning system became known after Hartrampf's paper on the TRAM flap for breast reconstruction and took his name (Hartrampf zone of perfusion). As already described by Scheflan and Dinner, the flap is ideally divided in four zones, as follows. The abdomen midline divides the lower abdominal flap in two hemiabdominal flaps. These are ideally divided in two halves, thus resulting four zones, which are numbered from I to IV based on their perfusion and viability. Zone I is the most perfused zone being the one corresponding to the selected perforator. Zone IV is the most distant one and usually bad perfused and not viable. (figure 1)

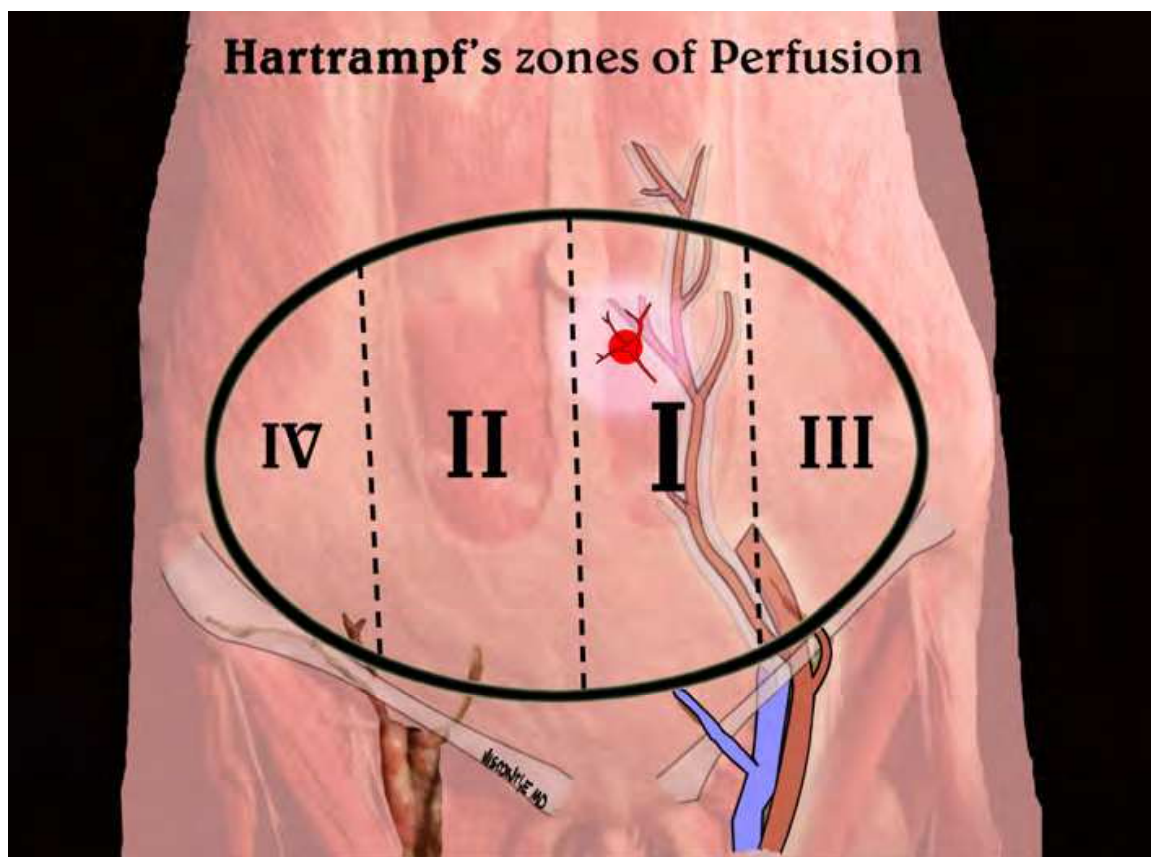


Fig. 1. The figure shows the dominant medial perforator and the corresponding zoning system. This follows the Hartrampf's classification.

One year later Hartrampf's paper, Dinner's further investigation casted a shadow on the strictness of this zoning system as zone II and III should have to be switched. Twenty-three years later, Holm et al. confirmed Dinner's observation by decreeing that Hartrampf zone of perfusion II and III are reversed according to their fluorescent perfusion techniques. (figure 2).

It was only after the 3D and 4D CTA studies by Saint-Cyr et al., that the DIEP flap zones of perfusion were clarified. According to this study, zones of perfusion depend on the row position of the perforator harvested, as follows:

- Flap based on a single *medial row perforator* shows a more centralized perfusion thus following the Hartrampf's classification of perfusion zones. (figure 1)
- Flap based on a single *lateral row perforator* shows a more lateralized perfusion thus following the Holm's classification of perfusion zones. (figure 2)

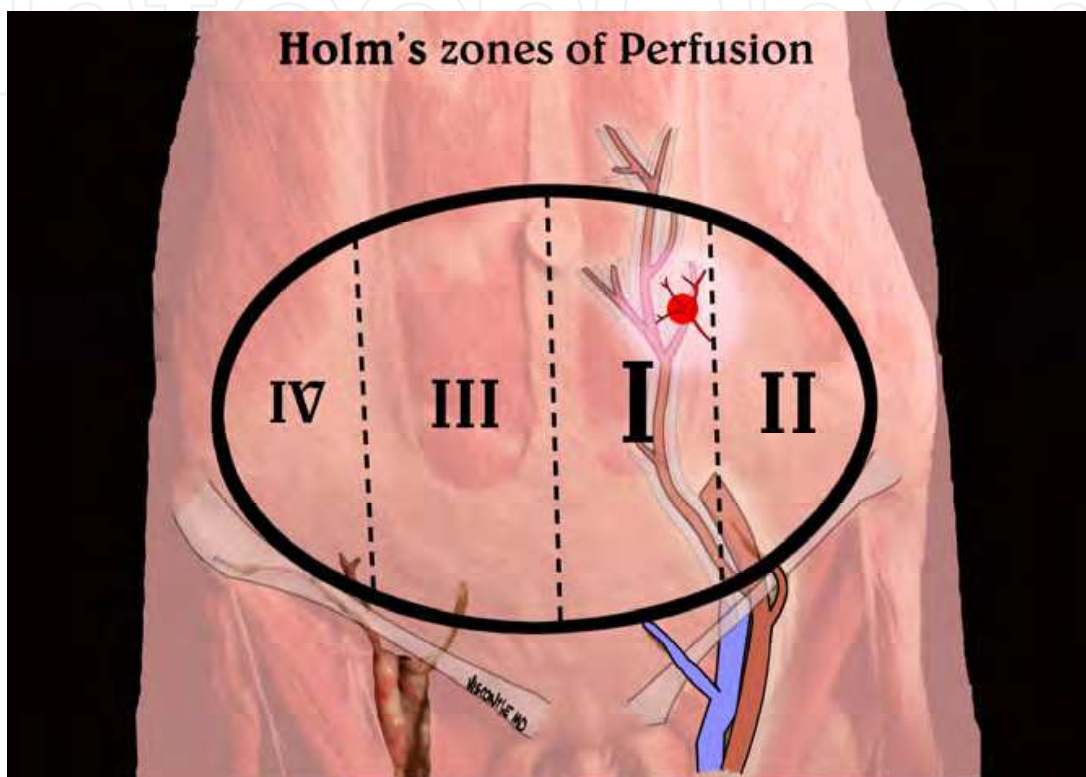


Fig. 2. The figure shows the dominant lateral perforator and the corresponding zoning system. This follows the Holm's classification.

However, both these theories are applied for a single dominant perforator. Depending on the perforator size and location, it is not uncommon that more than 1 perforator is harvested to improve DIEP flap perfusion.

Since Saint-Cyr et al. introduced the perforasome concept, nowadays the perforasome zone of perfusion (ZoP) theory is applied to the DIEP flap surgery (figures 3,4), as follows:

- *ZoP I*: it corresponds to the selected perforator, both medial or lateral row perforator;
- *ZoP II*: perforasomes just adjacent to the selected perforasome.
- *ZoP III*: next group of perforasomes, further distal to the selected perforasome.
- *ZoP IV and so on*: further distal perforasomes.

The perforasome concept is based on the fact that each perforator has its own vascular territory. It represents the "perforator" evolution of the Taylor's "anatomic angiosome".

Each perforasome is able to capture a variable number of adjacent perforasomes via direct and indirect linking vessels. This is what Taylor defines "clinical angiosome". Direct linking

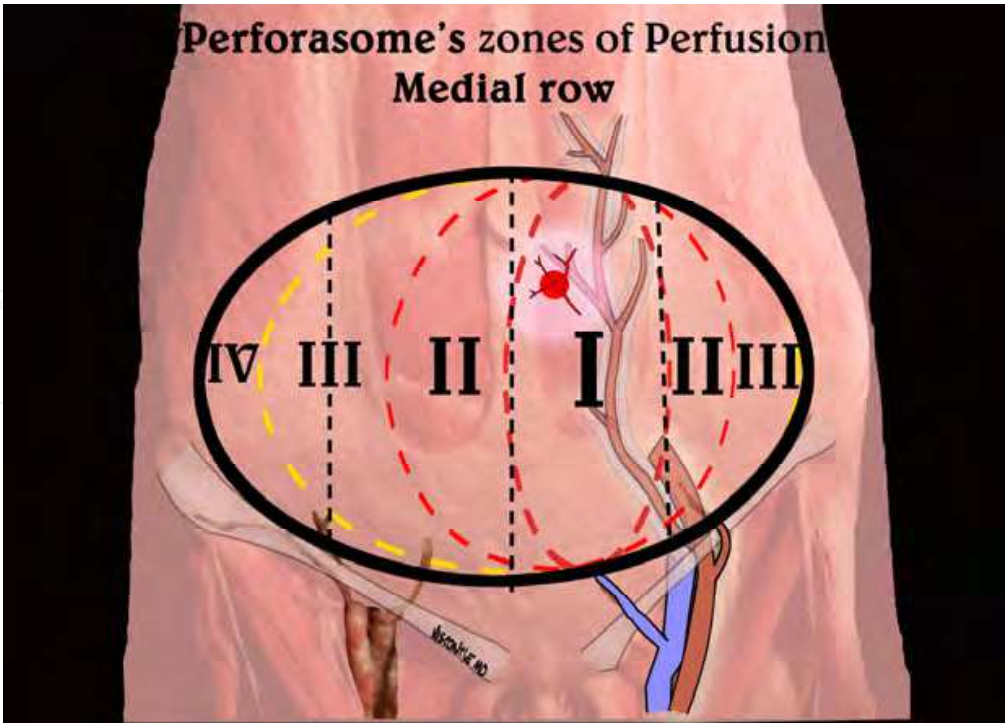


Fig. 3. The perforasome’s zone of perfusion when selecting a medial row dominant perforator. The viable flap is more centralized and have a larger surface when compared to a lateral row perforator.

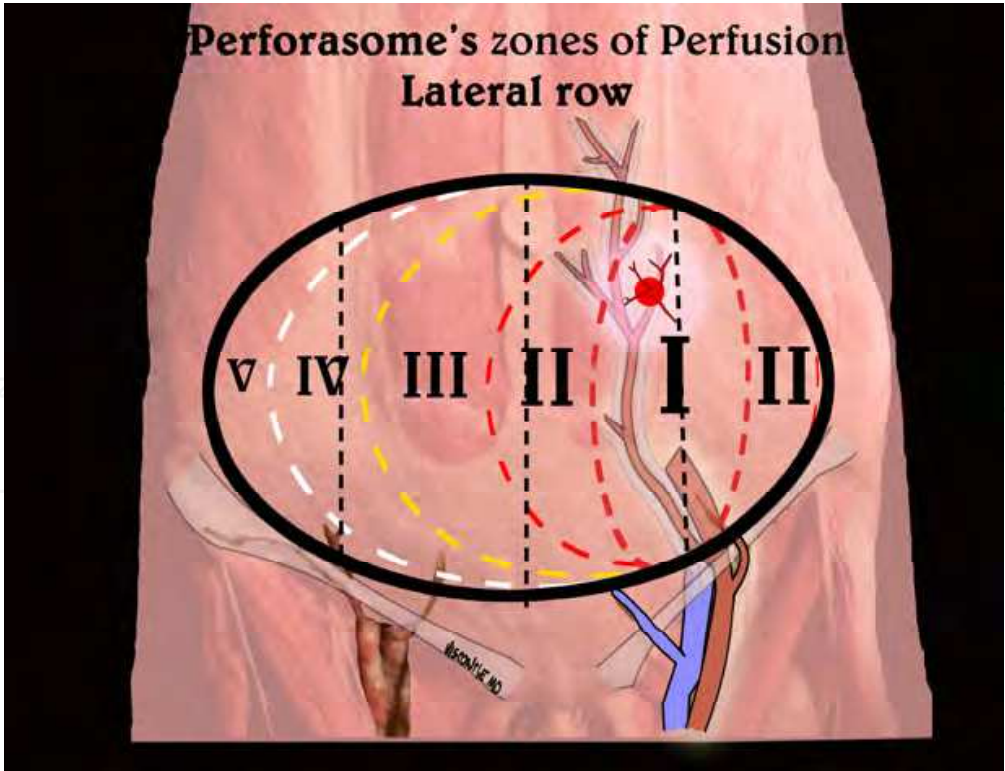


Fig. 4. The perforasome’s zone of perfusion when selecting a lateral row dominant perforator. The viable flap is more lateralized and have a smaller surface when compared to a medial row perforator.

vessels have large calibre and allow to capture adjacent perforasomes through an interperforasome flow mechanism. Indirect linking vessels are small calibre vessels, similar to the Taylor's choke vessels, allowing to capture adjacent perforasome through a recurrent flow mechanism. This normally takes place in the subdermal plexus.

In DIEP flap, Saint Cyr et al. observed that:

- perforators of the same row of the selected perforator are connected via direct linking vessels.
- perforators of the other row than the selected perforator are connected via direct and indirect linking vessels.
- Perforators of the opposite hemiabdomen than the selected perforators are connected only via indirect linking vessels because the vascular connections at linea alba between the two hemiabdomens take place only via indirect vessels.

So far, in DIEP flap surgery, the dimension of the viable flap based on a selected perforator relies on the clinical angiosome of the selected perforator. In other word, it depends on the number of perforasomes that are perfused by the selected perforator.

What Hartrampf, Holm and the perforasome zones of perfusion have in common is:

- the distal contralateral area then the selected perforator hemiabdomen (zone IV) is usually not viable and reliable. However, Wong C. et al reported that around 20% of the medial row perforators DIEP flap vascular territories encroach zone IV, whereas none of the lateral row perforators do.
- the clinical angiosome of an unipedicle DIEP flap extends within the same perforator hemiabdomen and partially in the contralateral hemiabdomen.
- the unipedicle DIEAP flap based on a medial row perforators is more centralized thus extending more its viable area in the contralateral hemiabdomen.
- the unipedicle DIEAP flap based on a lateral row perforators is more lateralized and the viable area on the contralateral hemiabdomen is minimal.

Regarding the SIEA microvascular anatomy, Schaverien et al. demonstrated that the perfusion pattern mostly overlaps the lateral row DIEP perforator pattern being the contralateral hemiabdomen never interested. However, in literature larger SIEA pattern has been described. (figure 5)

The vascular connection between the superficial vessels and both the medial and lateral row perforators of the same hemiabdomen are via indirect linking vessels in the subdermal plexus (recurrent flow).

In conclusion, when facing with the need of a large DIEP flap, a medial row perforator DIEP flap should be the choice. However, if the need is to transfer the whole lower abdominal skin and soft tissues (four zone DIEP flap) a double-pedicle (i.e perforator of the contralateral DIE or the SIEA/SIEV pedicle) is usually needed to increase the flap viable area.

2.2 Venous microvascular anatomy

The arterial anatomy of the lower abdominal skin and soft tissue has been widely described, and advances have been made with the modern concept of perforasome zones of perfusion. On the other side, the venous microanatomy of the abdominal wall did not receive the same

appraisal. In modern era of DIEP flap, the main vascular issues encountered are the venous drainage problems that can drive the flap from partial to complete necrosis.

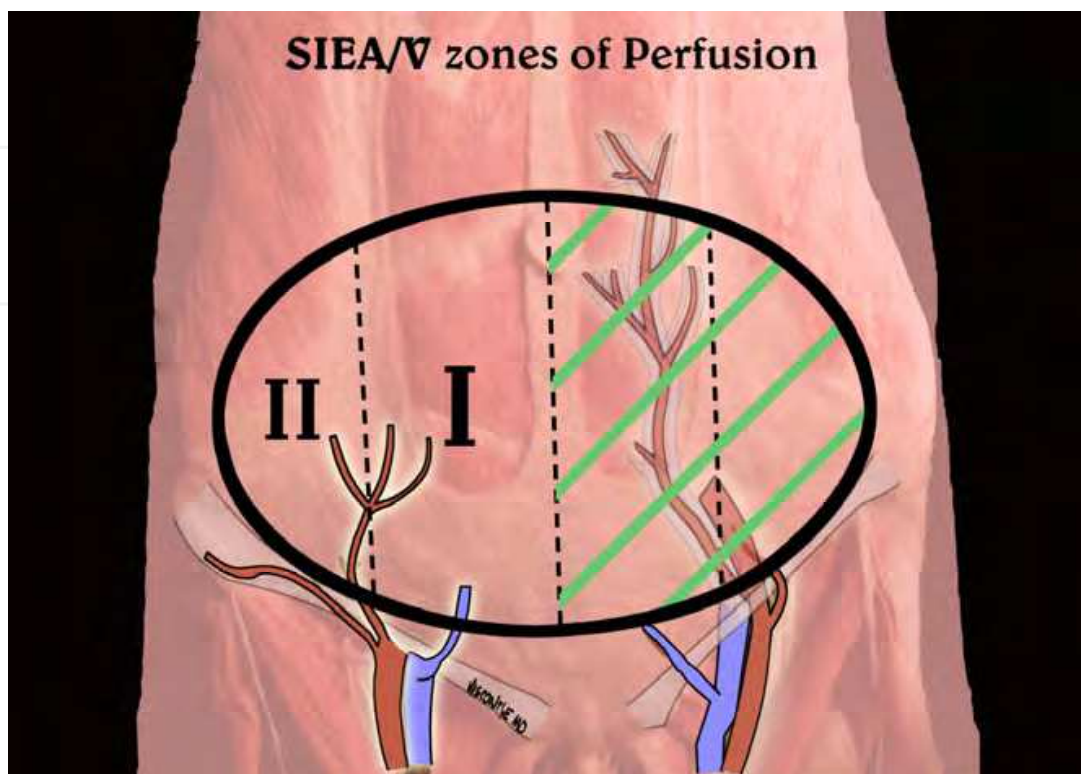


Fig. 5. The perfusion pattern of a SIEA/V flap. It is generally described as a hemiabdominal flap or I-II zones flap, being the contralateral hemiabdomen not perfused.

The venous drainage of the lower abdomen is provided by the superficial system belonging to SIEVs and the deep venous system belonging to DIEVs. Cadaver and in-vivo studies by Shaverien M et al. and Rozen WM et al. demonstrated the presence of small connecting veins (also called oscillating veins) between the superficial and the deep venous systems that usually diverts the subcutaneous venous flow from the superficial (SIEVs) to the deep veins (DIEVs) through the DIE perforator comitantes veins. In this case, the dominant perforator comitantes veins are often 1mm or bigger. On the other side, there could be also cases with prevalent venous drainage towards the superficial venous system, via SIEVs. A SIEV bigger than 1.5 mm at the inferior skin incision can be a pointer of this situation.

So far, the calibre of the selected perforator vein can be a limiting factor in DIEP flap drainage.

However, additional factors may be responsible for the lower abdomen soft tissue venous congestion:

- *The degree of communications between the superficial and deep system.* The links between the superficial and the perforating system are not uniform and frequently via small calibre vessels, also called *oscillating veins*. These may limit the efficiency of the venous drainage.
- *Midline cross-over connections by the SIEVs.* Each SIEV has been found to be a single trunk in the majority of the cases but sometimes can show a bifurcating or very rarely a trifurcating trunk below the umbilicus.

SIEV often supplies a medial branch that crosses the midline routinely at the arcuate line. Sometimes, there are additional cross-over just above and below the umbilicus. However, these midline cross-over connections can also be weak or even absent. These factors may also contribute to venous congestion.

In our centre, we usually study and evaluate the mid-line cross-over SIEV connections according to a grading scale where Grade I stands for absent connections at the midline, Grade II for weak connections, Grade III for good midline connection and Grade IV for good connections with at least one big size midline connection. (figure 6)

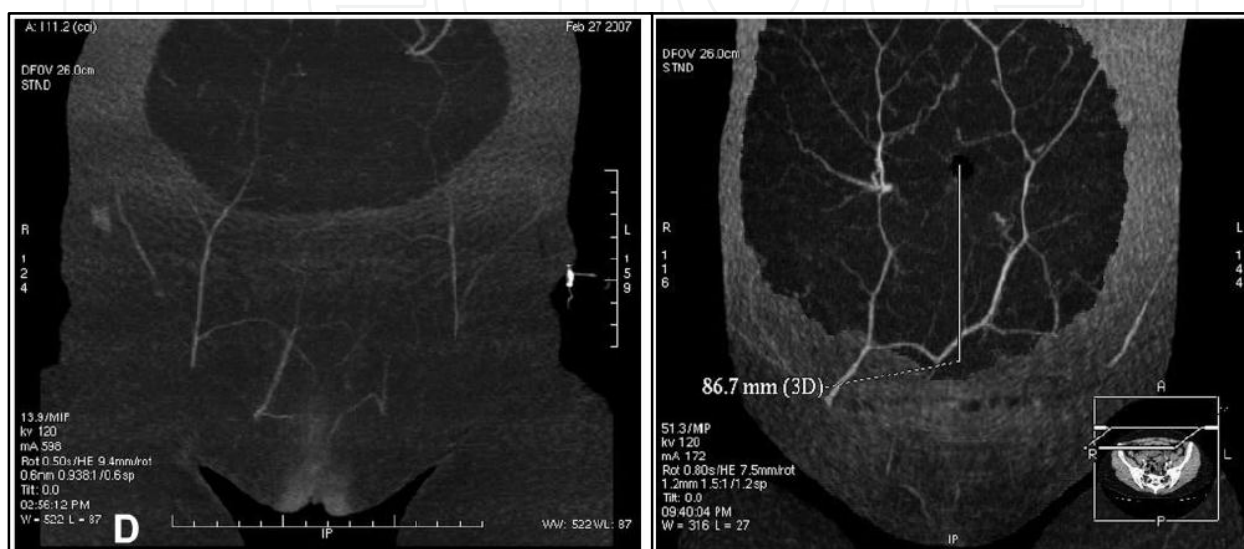

Fig. 6. (left) C-T coronal subvolume MIP (Maximum Intensity Projection) reconstruction of the subcutaneous fat of the lower abdomen shows multiple small connections among the superficial venous systems of both sides. Grade II connections.
(right) C-T coronal subvolume MIP (Maximum Intensity Projection) reconstruction of the subcutaneous fat of the lower abdomen shows a large venous connection between the superficial epigastric veins of both sides. Grade IV connections.

In conclusion, when planning a four zone DIEP flap is paramount to predict and to evaluate that the flap has adequate arterial input and venous discharge. In four zone DIEP flap, a double-pedicle flap is what is normally needed to assure both good perfusion to all the four zones as well as efficient venous discharge. With reliable SIEA/SIEV, it is possible to raise a four zone lower abdominal flap on DIEP on one side and contralateral SIEA/SIEV or even based on bilateral SIEA/SIEV. In the latter, it is more appropriate to talk about a double I-II zone flap as each SIEA/SIEV flap sustains the corresponding hemiabdomen only.

There are few situations where an unipedicle DIEP flap with an additional venous anastomosis (one of the SIEVs) can be enough.

All this will be better explained in the next paragraphs.

3. Relevant applied vascular anatomy of the internal mammary vessels

The internal mammary vessels are widely used as recipient vessels in autologous tissue breast reconstruction. Their central location, reliability in terms of size and constancy,

freedom of flap inseting and the relatively resistance to atherosclerosis, preservation following radiation therapy and axillary surgery make them a natural choice as recipient vessel in breast reconstruction. Moreover, avoiding the use of thoracodorsal vessels as recipients, the latissimus dorsi (LD) flap is preserved as salvage option.

The internal mammary vessels are bilateral. On each side we can distinguish the internal mammary artery (IMA) and at least one internal mammary vein (IMV).

3.1 IMA

The internal mammary artery originates from the subclavian artery. Occasionally, it can have a common origin with the thyrocervical trunk, scapular artery, dorsal scapular artery, thyroid artery or costocervical trunk. It courses downward and medially joining the posterior surface of the first cartilaginous rib. It continues downward, ventral to the parietal pleura and on the posterior surfaces of the first six cartilaginous ribs being at the lateral sternal border. The distances between the IMA and the lateral sternal border is on average 15 mm, ranging from 6 to 24 mm. Starting from the third intercostal space, the IMA is found superficial to the transversus thoracis muscle which separates the artery from the parietal pleura, making the dissection safer.

The IMA diameter varies at each intercostal space, being normally bigger proximally. Arnez et al. measures the IMA at the third, fourth and fifth intercostal spaces finding out an average diameter of 2.8, 2.6 and 2.6 mm, respectively. IMA tends to be larger on the right than the left side.

At the sixth intercostal space IMA normally splits in two trunks: the musculo-phrenic artery and the superior epigastric artery.

A combined radiologic and clinical study on 120 patients by Murray ACA et al. pointed out that in all patients both left and right IMA were always present and detectable both at ultrasound (US) and CTA. This study found out that in 99 % of the cases the IMA is a single trunk and in 1% of the case two trunks can be found. At the third intercostal space, where the IMV is normally split in two venous trunks, the IMA was found medial to the vein(s) in 22.5% of the cases, lateral to vein(s) in 6% of the cases and central positioned in 71.5% of the cases.

IMA shows anastomosis with the intercostal arteries of each space and gives off perforating branches at each intercostal space. However, a great variability has been described about IMA perforator calibre. The biggest IMA perforator is usually the one located at the second intercostal space followed by the ones at the third and first intercostal spaces with an average diameter of 1 mm, ranging from 0.5 to 2 mm. This makes the IMA perforator potential recipient vessels instead of the IMA itself, when the perforator has an acceptable calibre (more than 1 mm).

Besides all the positive aspects that makes the IMA the most favourite recipient vessel in breast reconstruction, there are rare cases where congenital anatomical variations, pathologic and iatrogenic phenomena can make the IMA not suitable as recipient vessel. This makes useful a preoperative radiologic assessment of IMA features by US or CTA. In our centre, we normally study the IMA preoperatively with color-doppler ultrasound (CDS).

3.2 IMV

Internal mammary veins originated from the confluence of the superior epigastric veins and the musculophrenic veins. This normally takes place at the sixth intercostal space. These veins are comitantes of the homonymous artery.

Generally, two IMVs accompany the IMA till the second/third intercostal spaces where the two venous trunks converge in an unique IMV. An anatomic study from Clark CP III et al showed that in 90 % of the cases, the IMV bifurcation takes place at the third rib on the left side and in 40% on the right side (in 60% of cases bifurcate downwards). This means that at the second intercostal spaces almost always a unique venous trunk is found on both right and left side. This place is the one we now prefer for the preparation of recipient vessels.

In literature, many authors choose the third intercostal space for recipient vessel preparation.

The IMV calibre varies at each intercostal space as the IMA calibre does. At the second intercostal space a vein about 3 mm is generally found. The same calibre is found only in 50 % of the cases at the third intercostal space, being generally not less than 2 mm till the fourth intercostal space. However, by progressing lower than the fourth intercostal space the vein calibre diminishes progressively till 1 mm or less, making the veins not consistent for a reliable anastomosis.

The physiologic IMV venous flow is toward the anonymous vein. The IMV is connected with intercostal and sternal veins at each intercostal space and gives off perforating vein at each intercostal space. A recent anatomic study by Mackey SP et al showed that IMV can contain a variable number of valves, mostly one and sometimes more (till 3). According to their cadaveric study on 32 human bodies, they found valves in 42% of male specimens and in 44% of female specimens. The valves has been found to be caudal to the second intercostal space in about 22 % of the cadavers and caudal to the third space in about 11 %. From a rheologic point of view, this means that once the IMV is divided to be anastomosed to the flap pedicle, the proximal vein should be use because an anterograde flow is present but the distal vein may be not reliable because of valves that would limit the establishment of a retrograde flow.

The successful use of the distal limb of IMV as recipient vein in autologous breast reconstruction makes this logic assertion incorrect. Despite the presence of valve in the IMV, clinical experiences show that a retrograde flow takes place in the IMV distal limb, making it an important further recipient vein in breast reconstruction. This is especially useful when a second venous anastomosis is needed in autologous tissue reconstruction. Many theories has been advanced to explain the presence of a retrograde flow in the IMV despite the valves. Essentially, valves may be:

- Not present at all.
- Not present caudal to the venous anastomotic site.
- *incompetent*: the venous pressure proximal to the valve is higher than distally. This can force the valves making them incompetent.
- *bypassed by collaterals*: the rich connections between IMV and intercostals and sternal veins as well as the perforating branches of the IMV at each intercostal space can allow a bypass of the valvular system by these collaterals.

- Both incompetent and bypassed by collaterals.

The retrograde flow in the distal limb of the IMV can be explained as follows:

- The IMV flow has been interrupted by the venous split and the corresponding decreased venous pressure gradient through the anonymous vein does not directly exist anymore for the IMV distal limb.
- the corresponding deep superior epigastric vein has been ligated if a double-pedicle DIEP flap has been harvested, because the DIE has been harvested. This reduces the venous flow and pressure through the IMV distal limb.
- The arterial input into the flap is responsible for the flap venous outflow and pressure.
- The higher venous pressure gradient of the flap output on the remaining IMV distal limb venous afferents makes the direction of the venous flow reversed, thus a retrograde flow takes place.

4. Indications

Lower abdominal tissue nowadays represents the gold standard in breast autologous tissue reconstruction.

The four zones DIEAP flap identifies the case when the whole lower abdominal skin and soft tissue is harvested.

Regarding the recipient site in single breast reconstruction, the four zone DIEP flap has these general indications:

- Need to *reconstruct a large breast* in patients with large contralateral breast that does not wish to reduce their breast size.
- Need to *reconstruct the breast mound and extramammary skin*, as in patients undergoing radical mastectomy or MRM with added skin resection. (figure 7)
- Patients with *rib cage congenital or acquired depressions* (i.e. Radiated mastectomy patients with expander). In these cases there is the need to fill the depression besides the breast mound reconstruction. (figure 8)

Regarding the donor site, the four zone lower abdominal tissue is required in single breast reconstruction in:

- Patients with scant abdominal tissue;
- Patients with *infraumbilical vertical scar* (in this case a double-pedicle flap is mandatory if more than a hemiabdominal flap is required).

Contraindications applied for standard DIEP and SIEA flaps are applied also to the four zone lower abdominal flap.

5. Flap markings

In the preoperative setting, abdominal multidetector row computer tomography (MDCT) is very helpful to study the vascular architecture of the lower abdominal soft tissues in order to plan a reliable flap.

At our institution, all patients scheduled for lower abdominal flap breast reconstruction, undergo abdominal MDCT to investigate, localize and select “dominant” perforators. Care

is taken on: diameters of perforators and their branching into the subcutaneous layer, perforator's localization, intramuscular course, connection to the superficial epigastric veins (SIEV), DIEA branching pattern and superficial venous architecture.

Indications for the four zone lower abdominal flap

Relative to the recipient site features:

- Patient with large native breasts who does not wish to reduce the contralateral breast.
- Patient with wide skin resection besides the mastectomy
- Patients with rib cage constitutional or acquired deformities.
- Patients with both the needing of reconstruct large breast and rib cage deformities.

Relative to the donor site features:

- Patients with scant abdominal tissue.

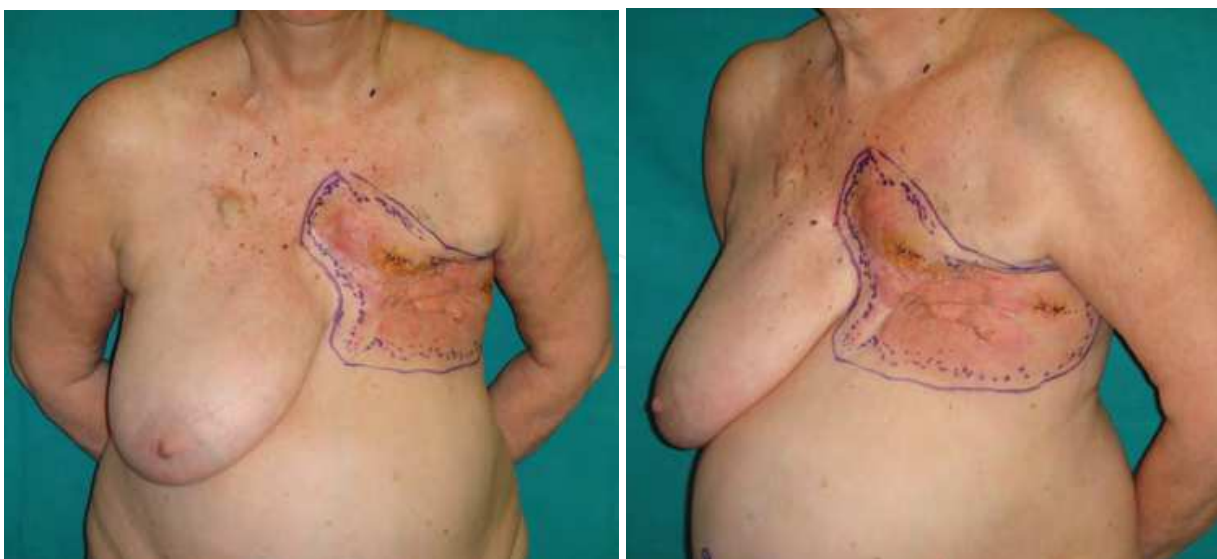


Fig. 7. Patient with a history of modified radical mastectomy, left axillary clearance and adjuvant radiation therapy. The patient developed a chest wall angiosarcoma. The skin resection needed is wider than the classic mastectomy pattern.

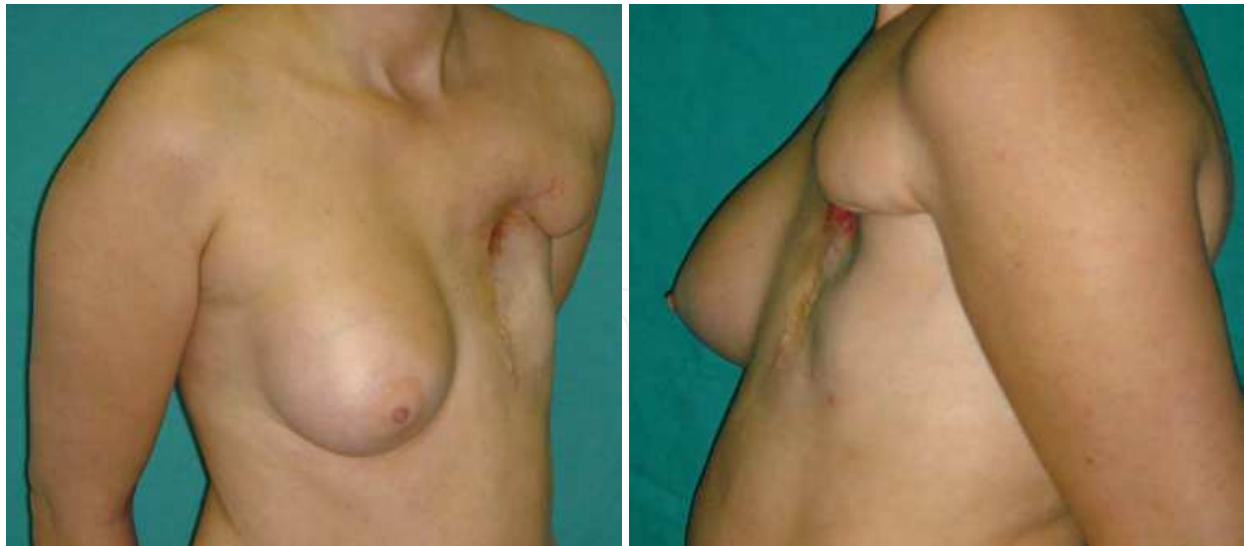

Fig. 8. Patient with a history of modified radical mastectomy, immediate tissue-expander placement and adjuvant radiation therapy. She developed a breast carcinoma recurrence. Note the left side chest wall depression as sequelae of the tissue-expander contracture.

When a four zone DIEP flap is needed for unilateral breast reconstruction, a double-pedicle DIEP flap is usually planned, as follows:

- when “true dominant” perforators are found on each hemiabdomen, the four zone flap will be raised based on these two perforators. The presence of a “dominant” lateral row perforator would be preferable in the double-pedicle four zone DIEP flap as better perfusion of the lateralmost part of the flap is expected. Moreover, dissection will be easier and faster than with the medial row perforators.
- when one or multiple medium caliber perforators are found without the presence of a “true dominant” perforator, the best perforators are selected on each hemiabdomen. In this cases, more than one perforator for each hemiabdomen can be included in the flap, preferring to include perforators of the same row.

A four zone lower abdominal flap can be also raised on one DIE pedicle and one SIE pedicle. As a premise of the followings, it has to be remarked that we prefer to inset the flap after 180 degree rotation, in order to place the fattiest portion of the flap (i.e. the periumbelical one) to reconstruct the inferior quadrants. In the case of a flap raised on one DIE pedicle and one SIE pedicle, due to short pedicle of the superficial system (range 5 to 8 cm), it would be preferable to have the superficial pedicle on the ipsilateral side of the breast to reconstruct in order to avoid the need of further recipient vessel dissection than the internal mammary vessels (i.e. thoracodorsal vessels) and/or to use an artery and vein graft to allow anastomosis to the internal mammary vessels. Another option is to use the contralateral SIE pedicle anastomosed to the ipsilateral DIE pedicle (distal DIE stump or other row stump) with an intraflap anastomosis.

There are rare cases, when a four zone DIEP flap can be safely raised based on only one pedicle with additional SIEV supercharging in patients without mid-line abdominal scar. This is possible when a “true dominant” medial row perforator is present, a large caliber SIEV (more than 1.5 mm) is found along with good midline cross-over SIEV connections (grade III to IV).

The perforators identified by MDCT are then reported on the abdominal site, possibly with aid of CDS that further analyzes the caliber of perforators and flow velocity.

Markings begin on the abdominal area while the patient is in a supine position. The markings follows those of the standard abdominoplasty.

6. Surgical technique

6.1 Double-pedicle DIEP flap harvest

The patient is placed in supine position with the arm of the side of affected breast elevated in order to expose the axilla (in immediate reconstruction) or the arms lying along the sides (in delayed reconstruction). The harvest of the flap begins by the dissection of the SIEV bilaterally. If a suitable SIEA is encountered on the ipsilateral side of the affected breast with a diameter of 1,5 mm at the level of the inferior skin incision, it can be dissected as well. The decision if the ipsilateral flap has to be raised on the SIE pedicle or on the DIEP pedicle depends on the characteristics of the dominant perforator/s. In case the dominant perforator/s caliber is bigger than 1,5mm at the preoperative MDCT, the choice shift toward the DIEP flap.

Harvesting the flap is done in standardized approach using perforators from both sides (or SIEA on one side). The DIE pedicle has to be dissected up to its entry into external iliac vessels to keep it as long as possible. The distal extent of DIE pedicle and the stump of the second row, when present, have to be dissected 1-2 centimeters further to be ready for possible additional anastomoses.

6.2 Vascular construct

After dissection of both vascular systems on each side, consideration has to be given to the location and the dissection of the recipient vessels. Recipient vessels selection is highly influenced by the configuration that could provide the best orientation for flap positioning and inset.

Over the last thirty years the internal mammary vessels has become the gold-standard as recipients in autologous tissue breast reconstruction. Moreover, their diameter is favorable as it normally matches the one of the deep inferior epigastric artery and veins allowing an easier end-to-end anastomosis. However, other recipients site can be used. The most frequent alternative recipients to the internal mammary vessels are the thoracodorsal vessels. However, these vessels are laterally located and more prone to damage from previous axillary surgery and from radiation therapy. Furthermore, their use may preclude the possibility to rely on the LD flap as salvage option.

When raising the double-pedicle lower abdominal flap entails the need of simultaneous restoration of the blood supply of both pedicles. Various methods of reconstructing the blood supply of double-pedicle flaps have been reported.

The most common technique is to combine two different recipient vessels. Many anatomical solutions exist, the most popular one being internal mammary vessels, or its perforators when possible, and thoracodorsal vessels. In case they could not be both available, such as in some delayed reconstruction, other options are still possible:

- Circumflex scapular vessels.

- Serratus branches
- Thoracoacromial vessels.
- Contralateral internal mammary vessels, with the drawback of an additional visible scar.

However, the split internal mammary vessels can be used to reconstruct both the arterial and venous flow of the double-pedicle flap. Since its first description almost ten years ago, we routinely use the inferior limb of the internal mammary artery and vein when an arterial and/or venous supercharging is needed.

Thus, there are two possibilities to reconstruct the vascular connection of the double-pedicle flap by using a single set of internal mammary vessels, as follows:

- *Double anastomoses to a single set of internal mammary vessels.* DIE double anastomoses to both the superior and inferior limbs of the split internal mammary vessels, being with antegrade flow the superior limb anastomosis and with retrograde flow the inferior limb one (figure 9), as already described by Li S et al. and Xu H et al. This is also our preferred choice.

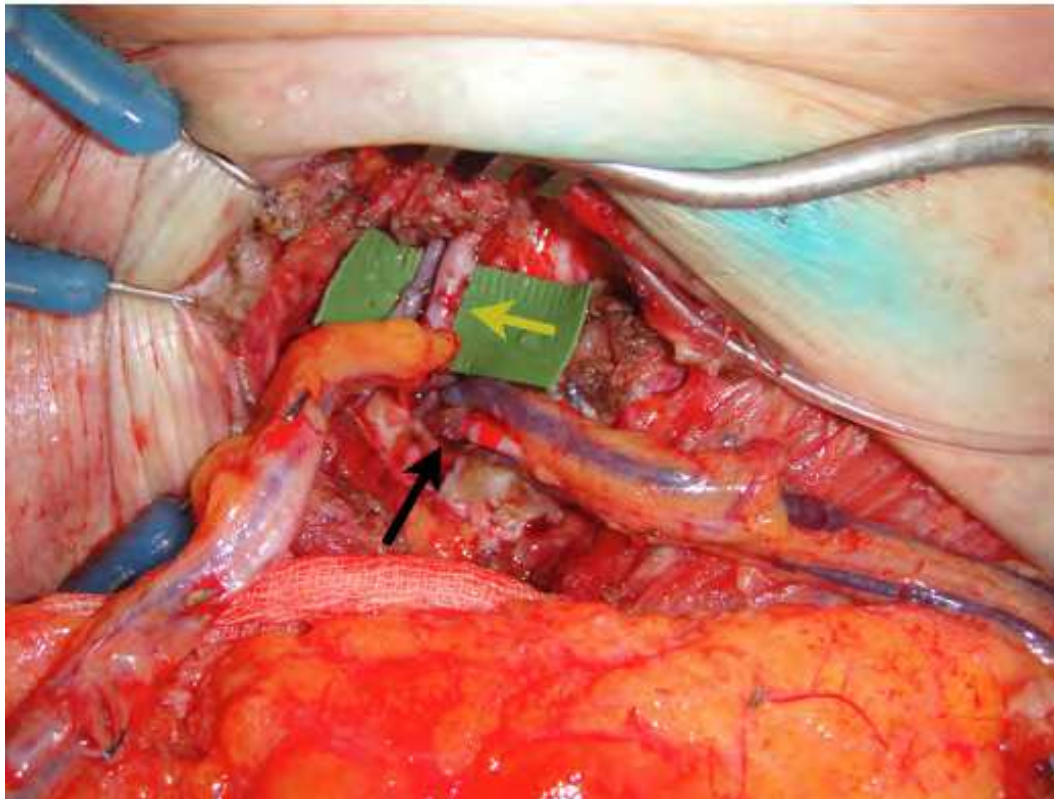


Fig. 9. The two DIEP pedicle are anastomosed to a single set of internal mammary vessels. The black arrow points the contralateral DIEP pedicle anastomosed to the inferior limb of the internal mammary vessel. The blood flow is retrograde. The yellow arrow points the homolateral DIEP pedicle anastomosed to the superior limb of the internal mammary vessel. The blood flow is antegrade.

- *The “serial” intraflap anastomosis.* Premising that the flap is 180 degree rotated, the contralateral DIE pedicle is anastomosed to the ipsilateral pedicle. The intraflap anastomosis may be performed on the abdomen while the flap is still perfused by the

ipsilateral DIE pedicle, in order to reduce the ischaemia time. Moreover, this allows to check the patency of the intraflap anastomosis before completely dividing the DIE pedicle from the abdomen. This can be accomplished in an end-to-end fashion to the distal end of the ipsilateral DIE pedicle or to the other row stump of the DIE (if present).

One key point in harvesting double pedicle lower abdominal flaps is keeping the pedicles as long as possible to easily perform the additional anastomoses and to accommodate the pedicles according to these spatial configurations, thus avoiding subsequent stretching of the pedicles.

6.3 Cases images

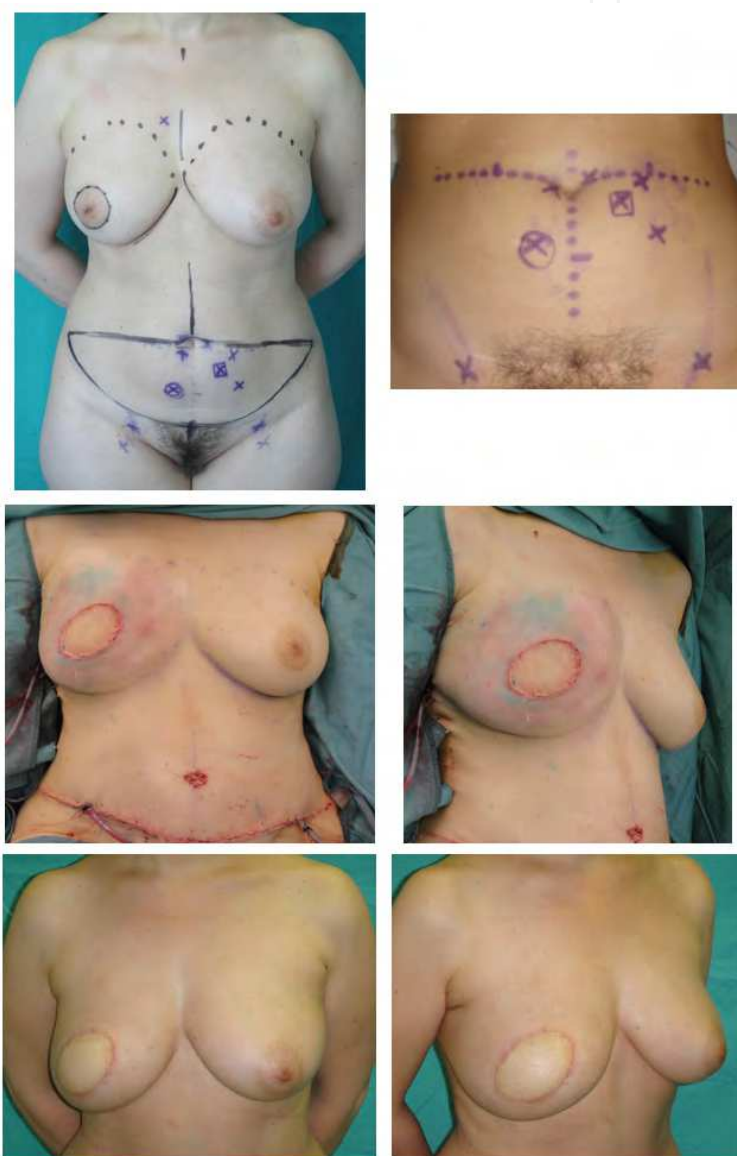


Fig. 10. (Above, left and right) Preoperative planning of a double pedicle DIEP flap. The patient was planned for a Type I skin-sparing mastectomy. She did opt for the autologous tissue reconstruction and did not wish to reduce contralateral breast size. A four zone flap is needed to reconstruct a similar size right breast. The abdominal wall perforators have been

marked after the MDCT scan and CDS. The dominant perforators have been circled. (center, left and right) Intraoperative pictures after flap inset. (Below, left and right) Six month postoperative pictures.

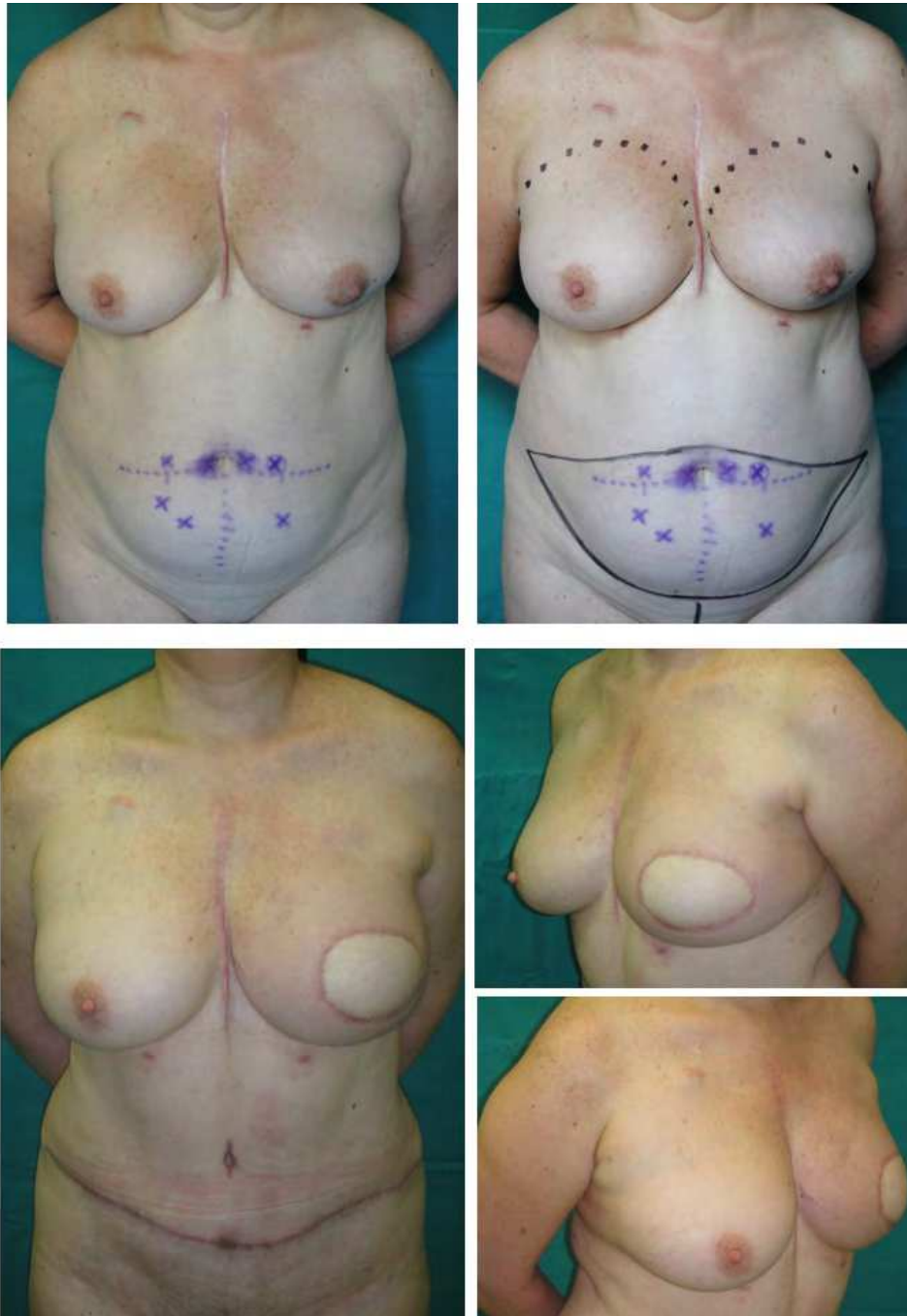


Fig. 11. (Above, left and right) Preoperative planning of a double pedicle DIEP flap. The patient had history of timoma extirpation and mantle irradiation. She was planned for a Type I skin-sparing mastectomy and autologous tissue reconstruction. She did not wish to reduce contralateral breast size. A four zone flap is needed to reconstruct a similar size left breast. The abdominal wall perforators have been marked after the MDCT scan and CDS. The dominant perforators have been circled. (Below, left and right) Three month postoperative pictures

6.4 Flap inset

The flap is usually *folded* on one or both ends to create the most projecting point of the breast mound according with the contra lateral volume and shape of the breast.

Special attention has to be paid before the anastomoses to the spatial configuration of the pedicles in order to avoid kinking, twisting or their stretching. This is particularly true when the double DIE pedicle is anastomosed to both the superior and inferior limb of the internal mammary vessels.

DellaCroce FJ et al. extensively described another option for a full lower abdominal flap inset in single breast reconstruction with “stacked” DIEP flap. This is a layered combination in the recipient site of a two hemiabdominal free DIEP/SIEA flaps. Firstly, one hemiabdominal DIEP flap is deepithelialized and inset into the breast pocket, orienting its vascular pedicle for the anastomosis with the internal mammary vessels. Then, the second flap is inserted after performing the intraflap to the distal stump or other row stump of the first flap pedicle (DIEP or SIEA flaps).

7. Postoperative care and complications

Postoperative management of a four zone DIEP/SIEA flap are identical to that of a standard DIEP flap as well as the complications that could be experienced. Compared to a unipedicle DIEP flap, the likelihood of venous congestion are rarely experienced as we should think to double-pedicle flap as two I-II zones flaps. Consequentially, the rate of liponecrosis experienced in double-pedicle flaps is also faraway smaller than a unipedicle flap.

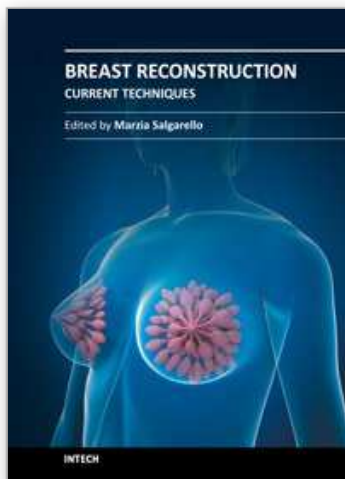
8. Acknowledgment

Thanks to Emiliano Visconti, M.D., Resident in-training, Department of Bioimages and Radiologic Sciences, University Hospital “A. Gemelli”, Rome - Italy for its contribution in digital artworks.

9. References

- Arnez ZM, Valdatta L, Tyler MP et al (1995) Anatomy of the IM veins and their use in free TRAM flap breast reconstruction. *Br J Plast Surg* 48:540.
- Bailey SH, Saint-Cyr M, Wong C, Mojallal A, Zhang K, Ouyang D, Arbique G, Trussler A, Rohrich RJ. The single dominant medial row perforator DIEP flap in breast reconstruction: three-dimensional perforasome and clinical results. *Plast Reconstr Surg*. 2010 Sep;126(3):739-51.
- Beahm EK, Walton RL. The efficacy of bilateral lower abdominal free flaps for unilateral breast reconstruction. *Plast Reconstr Surg*. 2007 Jul;120(1):41-54
- Clark CP 3rd, Rohrich RJ, Copit S, Pittman CE, Robinson J. An anatomic study of the internal mammary veins: clinical implications for free-tissue-transfer breast reconstruction. *Plast Reconstr Surg*. 1997 Feb;99(2):400-4.
- DellaCroce F J, Sullivan SK, Trahan C. Stacked deep inferior epigastric perforator flap breast reconstruction: a review of 110 flaps in 55 cases over 3 years. *Plast Reconstr Surg* 2011 Mar;127(3):1093-9
- Dinner MI, Dowden RV, Schefflan M. Refinements in the use of the transverse abdominal island flap for postmastectomy reconstruction. *Ann Plast Surg*. 1983 Nov;11(5):362-72.

- Hartrampf CR. Breast reconstruction with living tissue. Norfolk: Raven Press Ltd. Hampton Press Publishing Company; 1991
- Holm C, Mayer M, Hoffer E, Ninkovic M. Perfusion zones of the DIEP flap revisited: a clinical study. *Plast Reconstr Surg* 2006; 117:37-43.
- Kerr-Valentic MA, Gottlieb LJ, Agarwal JP. The retrograde limb of the internal mammary vein: an additional outflow option in DIEP flap breast reconstruction. *Plast Reconstr Surg*. 2009 Sep;124(3):717-21.
- Li S, Mu L, Li Y, xu J, Yang M, Zhao Z, Liu Y, Li J, Ling Y. Breast reconstruction with the free bipedicle inferior TRAM flap by anastomosis to the proximal and distal ends of internal mammary vessels. *J Reconstr Microsurg* 2002;18:161-168
- Li S, Mu L, Li Y, xu J, Yang M, Zhao Z, Liu Y, Li J, Ling Y. Clinical study of the hemodynamics of both ends (proximal and distal) of the internal mammary artery and its following-up. *Chin J Plast Surg* 2002;18:140-142
- Mackey SP, Ramsey KW. Exploring the myth of the valveless internal mammary vein--a cadaveric study. *J Plast Reconstr Aesthet Surg*. 2011 Sep;64(9):1174-9.
- Murray AC, Rozen WM, Alonso-Burgos A, Ashton MW, Garcia-Tutor E, Whitaker IS. The anatomy and variations of the internal thoracic (internal mammary) artery and implications in autologous breast reconstruction: clinical anatomical study and literature review. *Surg Radiol Anat*. 2011 Oct 11. [Epub ahead of print]
- Rahmanian-Schwarz A, Rothenberger J, Hirt B, Luz O, Schaller HE. A combined anatomical and clinical study for quantitative analysis of the microcirculation in the classic perfusion zones of the deep inferior epigastric artery perforator flap. *Plast Reconstr Surg*. 2011 Feb;127(2):505-13.
- Rozen WM, Pan WR, Le Roux CM, Taylor GI, Ashton MW. The venous anatomy of the anterior abdominal wall: an anatomical and clinical study. *Plast Reconstr Surg*. 2009 Sep;124(3):848-53.
- Saint-Cyr M. Assessing perforator architecture. *Clin Plast Surg*. 2011 Apr;38(2):175-202.
- Salgarello M, Barone-Adesi L, Sturla M, Masetti R, Mu L. Needing a large DIEAP flap for unilateral breast reconstruction: double-pedicle flap and unipedicle flap with additional venous discharge. *Microsurgery* 2010;30(2):111-7
- Salgarello M, Cervelli D, Barone-Adesi L, Finocchi V. Anterograde and retrograde flow anastomoses to the internal mammary vessels in the third intercostal space. *J Reconstr Microsurg*. 2010 Nov;26(9):637-8
- Schaverien M, Saint-Cyr M, Arbique G, Brown SA. Arterial and venous anatomy of the deep inferior epigastric perforator and superficial inferior epigastric artery flaps. *Plast Reconstr Surg*. 2008 Jun;121(6):1909-19.
- Schefflan M, Dinner MI. The transverse abdominal island flap: part I. Indications, contraindications, results, and complications. *Ann Plast Surg*. 1983 Jan;10(1):24-35.
- Schefflan M, Dinner MI. The transverse abdominal island flap: Part II. Surgical technique. *Ann Plast Surg*. 1983 Feb;10(2):120-9.
- Wong C, Saint-Cyr M, Mojallal A, Schaub T, Bailey SH, Myers S, Brown S, Rohrich RJ. Perforasome of the DIEP flap: vascular anatomy of the lateral versus medial row perforators and clinical implications. *Plast Reconstr Surg*. 2010 Mar;125(3):772-82.
- Xu H, Dong J, Wang T. Bipedicle deep inferior epigastric perforator flap for unilateral breast reconstruction: seven years' experience. *Plast Reconstr Surg* 2009 Dec;124(6):1797-807
- Zeltzer AA, Andrades P, Hamdi M, Blondeel PN, Van Landuyt K. The use of a single set of internal mammary recipient vessels in bilateral free flap breast reconstruction. *Plast Reconstr Surg*. 2011 Jun;127(6):153e-4e. No abstract available.



Breast Reconstruction - Current Techniques

Edited by Prof. Marzia Salgarello

ISBN 978-953-307-982-0

Hard cover, 276 pages

Publisher InTech

Published online 03, February, 2012

Published in print edition February, 2012

Breast reconstruction is a fascinating and complex field which combines reconstructive and aesthetic principles in the search for the best results possible. The goal of breast reconstruction is to restore the appearance of the breast and to improve a woman's psychological health after cancer treatment. Successful breast reconstruction requires a clear understanding of reconstructive operative techniques and a thorough knowledge of breast aesthetic principles. Edited by Marzia Salgarello, and including contributions from respected reconstructive breast plastic surgeons from around the world, this book focuses on the main current techniques in breast reconstruction and also gives some insight into specific topics. The text consists of five sections, of which the first focuses on the oncologic aspect of breast reconstruction. Section two covers prosthetic breast reconstruction, section three is dedicated to autogenous breast reconstruction, and section four analyzes breast reconstruction with a fat graft. Finally, section five covers the current approaches to breast reshaping after conservative treatment.

How to reference

In order to correctly reference this scholarly work, feel free to copy and paste the following:

Marzia Salgarello, Liliana Barone-Adesi and Giuseppe Visconti (2012). Double-Pedicle DIEP and SIEA Flaps and Their Application in Breast Reconstruction, *Breast Reconstruction - Current Techniques*, Prof. Marzia Salgarello (Ed.), ISBN: 978-953-307-982-0, InTech, Available from: <http://www.intechopen.com/books/breast-reconstruction-current-techniques/double-pedicle-diep-and-siea-flaps-and-their-application-in-breast-reconstruction>

INTech
open science | open minds

InTech Europe

University Campus STeP Ri
Slavka Krautzeka 83/A
51000 Rijeka, Croatia
Phone: +385 (51) 770 447
Fax: +385 (51) 686 166
www.intechopen.com

InTech China

Unit 405, Office Block, Hotel Equatorial Shanghai
No.65, Yan An Road (West), Shanghai, 200040, China
中国上海市延安西路65号上海国际贵都大饭店办公楼405单元
Phone: +86-21-62489820
Fax: +86-21-62489821

© 2012 The Author(s). Licensee IntechOpen. This is an open access article distributed under the terms of the [Creative Commons Attribution 3.0 License](https://creativecommons.org/licenses/by/3.0/), which permits unrestricted use, distribution, and reproduction in any medium, provided the original work is properly cited.

IntechOpen

IntechOpen