

We are IntechOpen, the world's leading publisher of Open Access books Built by scientists, for scientists

6,900

Open access books available

186,000

International authors and editors

200M

Downloads

Our authors are among the

154

Countries delivered to

TOP 1%

most cited scientists

12.2%

Contributors from top 500 universities



WEB OF SCIENCE™

Selection of our books indexed in the Book Citation Index
in Web of Science™ Core Collection (BKCI)

Interested in publishing with us?
Contact book.department@intechopen.com

Numbers displayed above are based on latest data collected.
For more information visit www.intechopen.com



Preoperative Computed Tomographic Angiogram for Deep Inferior Epigastric Artery Perforator Flap for Breast Reconstruction: The Imaging Mapping Era

Jaume Masia^{1,*}, Carmen Navarro¹, Juan A. Clavero² and Xavier Alomar²

¹*Plastic Surgery Department,*

Hospital de la Santa Creu i Sant Pau (Universitat Autònoma de Barcelona),

²*Radiology Department, Clínica Creu Blanca, Barcelona, Spain*

1. Introduction

Surgical techniques for breast reconstruction have been greatly refined in last decades and important landmarks have been achieved. Autologous reconstruction with microsurgical flaps marked a before and after in breast reconstruction because the aesthetic outcome is improved, a prosthesis is not needed and long-term results are good. Different types of flaps have been used to create a new breast with similar characteristics in shape, size, contour and position to the contralateral one. The preferred donor site for this purpose is the abdominal wall. The deep inferior epigastric artery perforator flap (DIEP) provides fat and skin with characteristics that are very similar to those of the normal breast and spares the rectus abdominis muscle or fascia, thereby minimizing donor site morbidity (1-3). In function of these advantages the DIEP flap has become the gold standard for breast reconstruction in many hospitals (4).

A key point in breast reconstruction with DIEP flap is choosing the best supplying perforator and several factors should be kept in mind when doing so (5). The ideal perforator vessel should have a large right calibre, a short intramuscular course, the easiest dissection, a suitable location within the flap and subcutaneous branching with intraflap axially. In some cases of DIEP, we can find paramuscular vessels that initially follow a retromuscular plane before piercing the muscular fascia in the exact abdominal mid-line. Many of these perforators have a good caliber and good arborization in the subcutaneous tissue and could be considered to be the ideal perforators because their course facilitates the surgical dissection (6).

After working with perforator flaps for more than 10 years, we can attest that perforator vessels arising from the deep inferior epigastric system are anatomically highly variable regarding their number, location, caliber and relationships with surrounding structures. In

* Corresponding Author

view of this variability, we need a reliable method that will accurately identify and locate the dominant perforator before surgery. This can be achieved through preoperative anatomic images that provide information about the vascularization of the abdomen. Precise imaging can help us to select the best hemiabdomen to raise, to differentiate between superficial and deep epigastric vessels and to combine two or more perforator vessels when there is no dominant vessel. With a precise image we can plan the operative technique, reduce operating time and improve operative outcomes (7). Without a pre-operative investigation, the surgeon may not be aware of previous surgical damage, scar formation or anatomical variants. Using preoperative imaging techniques to study the epigastric vessels we have decreased the number of postoperative complications. An accurate preoperative evaluation by means of imaging of the vascular anatomy of the abdominal wall is extremely valuable for the plastic surgeon as the images provided are easy to interpret and they facilitate safer and faster procedures.

2. Conventional methods for preoperative study of abdominal perforating vessels

Before imaging techniques were described for the study of abdominal perforators, the two most widely used approaches were handheld Doppler ultrasound and color Doppler imaging.

Handheld Doppler ultrasound was the first method described for the study of perforators (8). It is still the most widely used method to locate a perforator, due to its low cost and simplicity of use. However the information it offers is limited. Correlation between the acoustic signal and the diameter of the vessel is unreliable and often imprecise. Furthermore, this technique cannot distinguish perforator vessels from main axial vessels. Besides, this technique has shown an unacceptable number of false positives and tiny vessels can be confused acoustically with a good perforator (9,10). But despite these drawbacks, handheld Doppler ultrasound remains useful in our daily practice and can still be useful for specific indications, such as to assess the location and the course of the superficial epigastric vessels.

Color Doppler imaging provides much more reliable information than Doppler sonography (11). It provides a good evaluation of the main axial vessels and their perforator vessels. It is a highly reliable technique to identify and locate the dominant abdominal perforator vessel. Besides, it provides information about blood flow direction, pattern and velocity. Moreover, the caliber and hemodynamic characteristics of the perforator vessels can be observed directly on color Doppler imaging. The high sensitivity and the 100% predictive value of this technique have made it a good diagnostic tool in the planning of abdominal flaps. However, color Doppler imaging also has some limitations; It is a long test, possibly lasting up to an hour, and this can be uncomfortable for patients as they have to remain in the same position during the procedure. Furthermore, it requires the presence of highly skilled sonographers with knowledge of perforator flap surgery and its results are technician-dependent. In addition, color Doppler imaging does not provide anatomic images that show the surgeon the anatomic relationship between the deep inferior epigastric artery and its perforator branches and other structures along its route. These important limitations have contributed to its relative disuse in microsurgical units.

3. Multidetector-row computed tomography

In 2003 we began to work with CT scan and in 2006 we published the first results where for the first time an imaging technique was used for the visualization and study of abdominal perforator vessels (7). Since then, the multidetector-row computed tomography (MDCT) scan has proved to be highly reliable in preoperative planning of abdominal free flap breast reconstruction and has demonstrated excellent results, significantly reducing operative time and complications (12-16). With the incorporation of the MDCT for mapping the abdominal vascularization, we are not only able to locate the dominant perforators but we also receive extra information about the vessels and the donor area thanks to the anatomical images that these methods provide. Anatomical images inform us about the number of perforators, their location, their intramuscular course and their distribution inside the subcutaneous tissue (figures 1,2: axial MDCT image of an abdominal perforator). They have 100% sensitivity and specificity at the time of locating the dominant perforator, and they are also technically reproducible. This last characteristic is especially handy as it means we can record the information on a CD or pen-drive and have it at our disposition at the moment of surgery. Besides, the increased spatial resolution offered by MDCT allows highly accurate multiplanar and 3D reconstructed images, creating a 3-dimensional map of the perforating vessels. Another advantage is the fact that they provide an anatomical reference of the area. It should also be mentioned that MDCT is very fast to perform and a considerable number of thin sliced CT images are obtained in a short time.

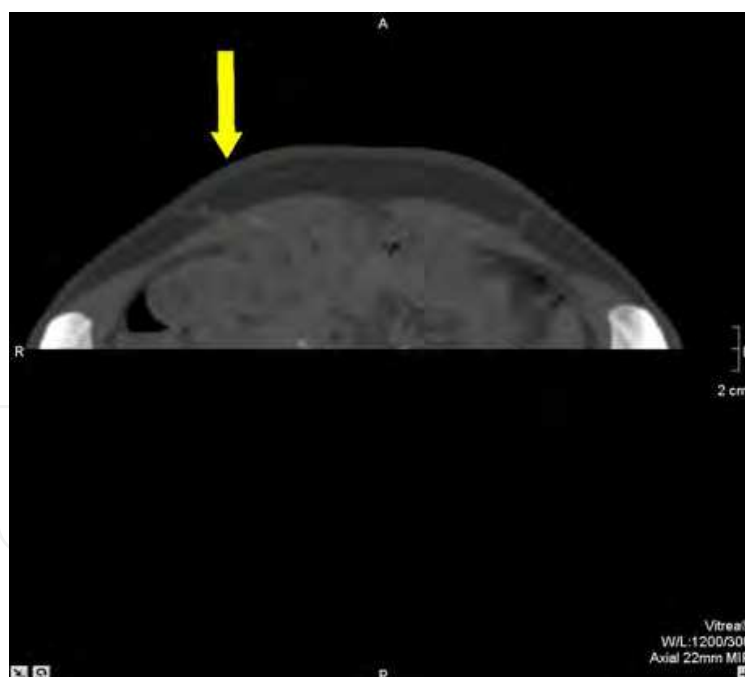


Fig. 1. Axial MCDT image of an intramuscular perforator of the deep epigastric vessels with its branching. Yellow arrow indicates the point in which the perforator pierces the fascia.

In spite of all its advantages, the MDCT has 2 clear drawbacks. The first is the radiation the patient receives when the test is performed (effective dose is 5.6 mSv). However, the effective dose of radiation used with this technique is 5.6mSv which is less than that used for an opaque enema or a conventional abdominal CT scan. The second drawback of the MDCT

is the need to administer an intravenous medium; this is uncomfortable for the patient and can cause allergic reactions.

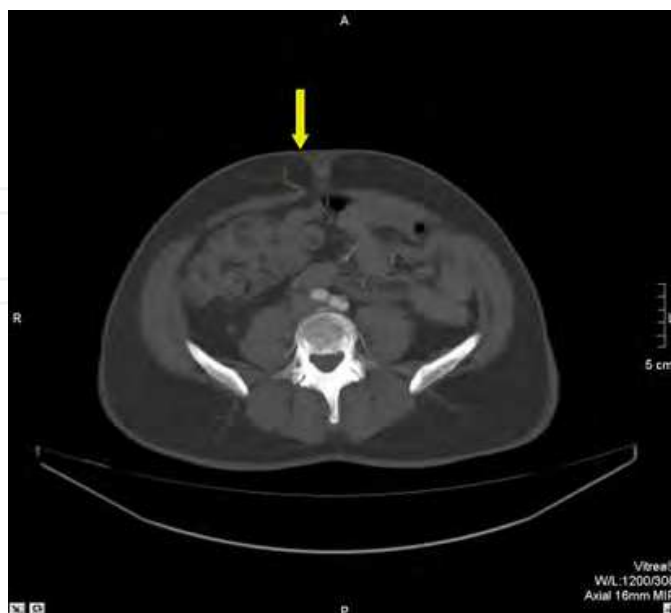


Fig. 2. Axial MCDT image of a paramuscular perforator of the deep epigastric vessels with its branching in the subcutaneous tissue. Yellow arrow indicates the point in which the perforator arises from the fascia.

3.1 MDCT protocol

Nowadays our multidetector computed tomography studies are performed using a 64 or 320-detector-row CT scanner with the following parameters: 120 kVp, 80-120 mAs (0.4 sec gantry rotation period), detector configuration 64 x 0.5mm, 54-mm table travel per rotation, 512 x 512 matrix, and a 180 to 240 field of view. All scanning was performed during IV administration of 100 ml of non-ionic iodinated contrast medium with a concentration of 300 mg I/ml (Xenetix 300 [Iobitridol]; laboratories Guerbet, Paris, France). The contrast material was mechanically injected (injector TC missori XD 2001); Ulrich GmbH & Co. K, Ulm, Germany) at a rate of 4 ml/sec. through an 18-gauge IV catheter inserted into an antecubital vein.

An important concept to note is that the patient is placed in a supine position on a CT table in the exact manner that will be used on the day of surgery. Sections are obtained from 5 cm above the umbilicus to the lesser trochanter of the hip during a single breath-hold while the patient holds his breath for approximately 10 to 12 seconds. The approximate time of acquisition is 3-4 seconds. The entire procedure takes less than 10 minutes and is therefore very well tolerated by the patient. The volumetric data acquired are then used to reconstruct images with a slice width of 1-millimetre and a reconstruction interval of 0.8-millimetres. The resulting complete set of reconstructed images is automatically transferred to a computer workstation (Vitrea version 4.0.1, Vital Images, Plymouth, MN) which generates the reformatted images in multiple planes (coronal, axial, sagittal and oblique) and in three-dimensional volume rendered images. This system allows measurements to be taken so that different planes of space can be automatically correlated. Data can be stored on a pen drive

(e-Film Medical Inc., Toronto, Canada) which can easily be used and managed using a standard computer (17).

4. Non-contrast magnetic resonance imaging

To overcome the limitation of radiation with MDCT-technique, many began to investigate the possibility of using magnetic resonance imaging (MRI) for abdominal perforator mapping (18). For several years, we worked with different kinds of MRI technologies, until we get good results with 1.5T non-contrast magnetic resonance imaging FBI technique (19). In 2010 we published the first results demonstrating that non-contrast magnetic resonance imaging provides reliable information on the vascular anatomy of the abdominal wall. Preoperative magnetic resonance imaging without the contrast showed no false positive or false negative results. This technique provided accurate location of the dominant perforator, good definition of its intramuscular course and excellent evaluation of the superficial inferior epigastric system (figure 3: axial non contrast-MRI image of abdominal perforators). We are also able to define the perforator branching within the subcutaneous abdominal tissue and evaluate the vascular connections between the superficial and the deep inferior epigastric vessels (20).

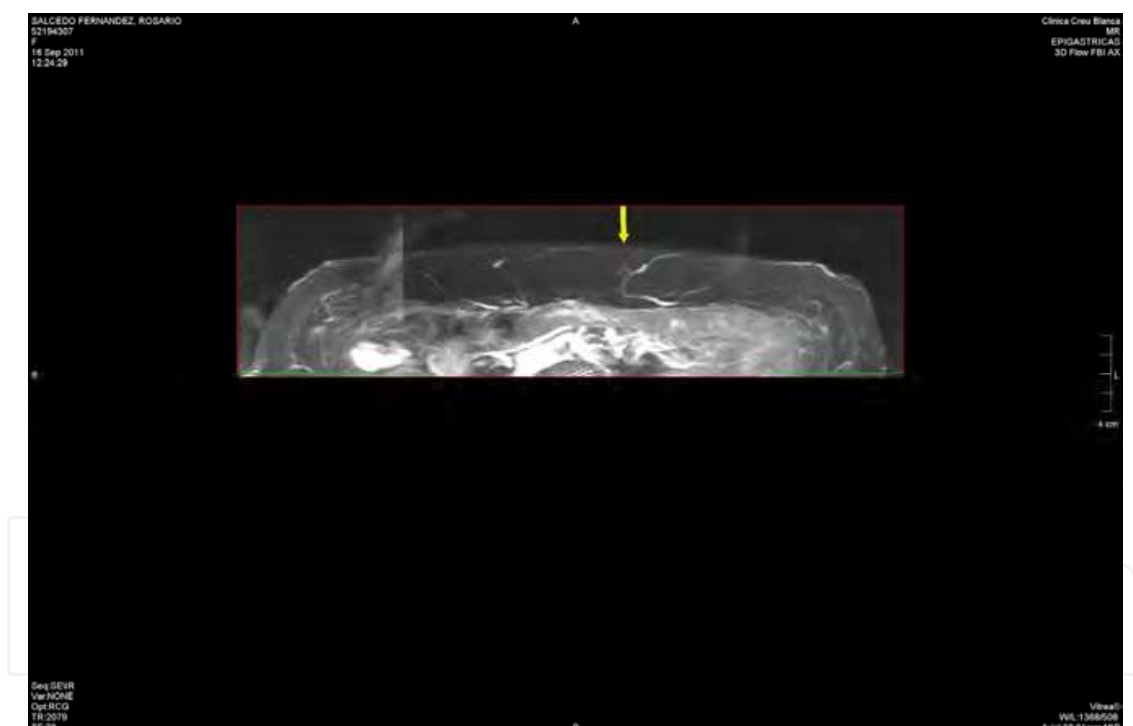


Fig. 3. Axial non contrast-MRI image of abdominal perforators. Yellow arrow indicates the point in which the dominant perforator pierces the fascia.

4.1 Non-contrast MRI protocol

As with MDCT, the first step with this technique is to acquire multiplanar images with the patients in supine in the same position as they will be placed at surgery. In contrast with MDCT, however, no prior patient preparation is needed and nor is contrast medium required, so the patient does not require the 6 hours of fasting before acquisition of images.

We use high speed parallel imaging (speeder technology) to achieve accelerated scan times. Initially, sagittal scouts are acquired to locate the inferior abdominal wall and to delimit the study zone. A sequence phase 3D+5_FSfbi is used in the anterior coronal plane with the following parameters: TR:2694, TE:80, slice thickness 1.5 mm, number of slices: 50, number of acquisition: one, 512x512 matrix, field of view 380x380 mm, TI:160 and resp + ECG gate. A sequence phase 3D+5_FSfbi is then performed in the axial plane with the following parameters: TR:2900, TE:78, slice thickness 3 mm, number of slices: 56, number of acquisition: one, 704x704 matrix, field of view 380x380 mm, TI:160 and resp + ECG gate. The anterior coronal plane phase only includes the anterior abdominal wall, from a plane immediately below the pubis to the xiphoid process of the sternum. The axial plane phase includes the area from the infrapubic zone to 3cm above the umbilicus. The acquisition time ranges from 10 to 20 minutes. Multiplanar formatted images and 3D volume rendered images are regenerated on a Vitrea computer workstation (Vitrea version 3.0.1. Vital Images, Plymouth, MN) (20).

5. Image analysis to select the most suitable perforator

The images obtained are usually interpreted by both the radiologist and the plastic surgeon who is going to harvest the DIEP flap. The team chooses the perforator considered the most suitable according to the following criteria: largest calibre, best location, shortest intramuscular course and also intraflap axiility. The perforator selected gives a pair of x/y coordinates based on an axial system centred on the umbilicus and the flap can be raised based on the dominant perforator. The surgeon is provided with three types of image: axial, sagittal and coronal. The axial views and sagittal reconstructions are of great help in the assessment of the perforator vessel to evaluate its dependence on the main trunk or any direct branch of the deep inferior epigastric artery and to delimit its origin on the fascia and its distribution through subcutaneous fat and skin. Rendered reconstructions allow us to mark on the patient's skin the exact point where the perforator vessel emerges through the fascia of the rectus abdominis muscle.

The image is assessed using the following protocol:

Step 1. In the axial view we study the deep inferior epigastric artery course from its origin, through the muscle, to five centimetres cranial to the umbilicus. We normally identify the two or three best perforators on each side of the abdomen, marking them with an arrow, and classify them according to their external calibre into three categories (small, medium, large). At the suprafascial level we assess the perforator branching in the subcutaneous tissue. We assess the intramuscular course of the deep inferior epigastric artery, defining its relationship to the tendinous intersections and the number of branches. We also study the superficial epigastric system, defining the calibre of the artery at its origin. In our experience vessel size greater than 0.6 mm can potentially be used for raising a SIEA flap if it has a medial distribution on the abdomen. When we choose the best perforator in the imaging technique, we look for the point where it pierces the fascia in the axial view and we mark an arrow on the skin at this level. From there on the arrow will appear in all views. We draw a coordinate x/y axis on the umbilicus and we make measurements to locate the exit of the perforating vessel in relation to the

umbilicus. First, we measure the distance from the midline to the perforator in the axial view, and this is given the value “x”.

- Step 2.** We review the sagittal view to double check the quality of the chosen perforators and to place them in three planes. The second measure is done in the sagittal view measuring from the umbilicus level to the exit of the perforator. This will be the “y” value. In the sagittal view we can also assess the interconnections between the superficial and deep systems (figure 4: axial and sagittal views of a dominant perforator).

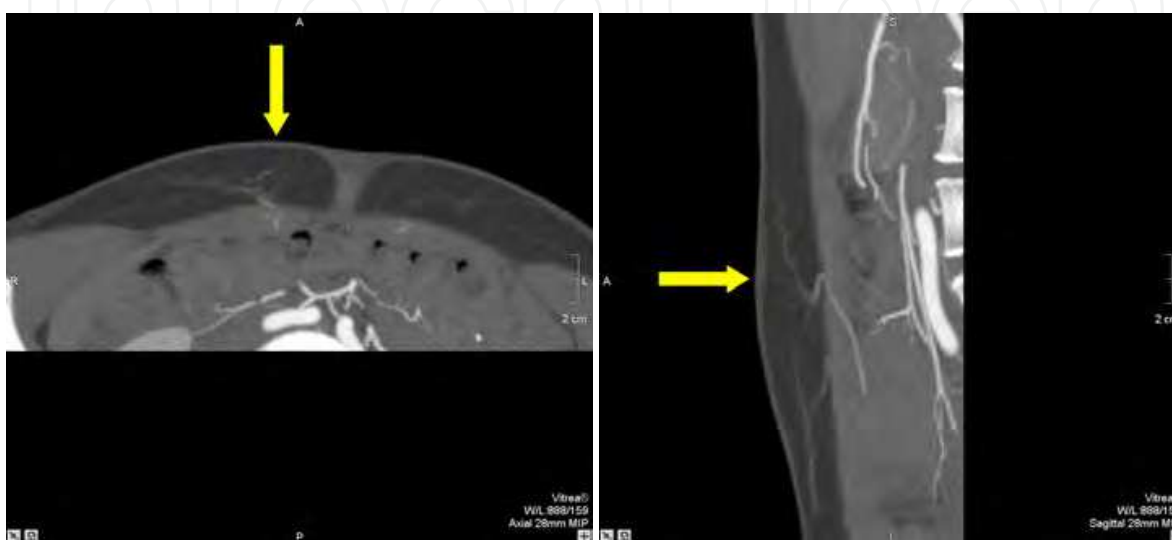
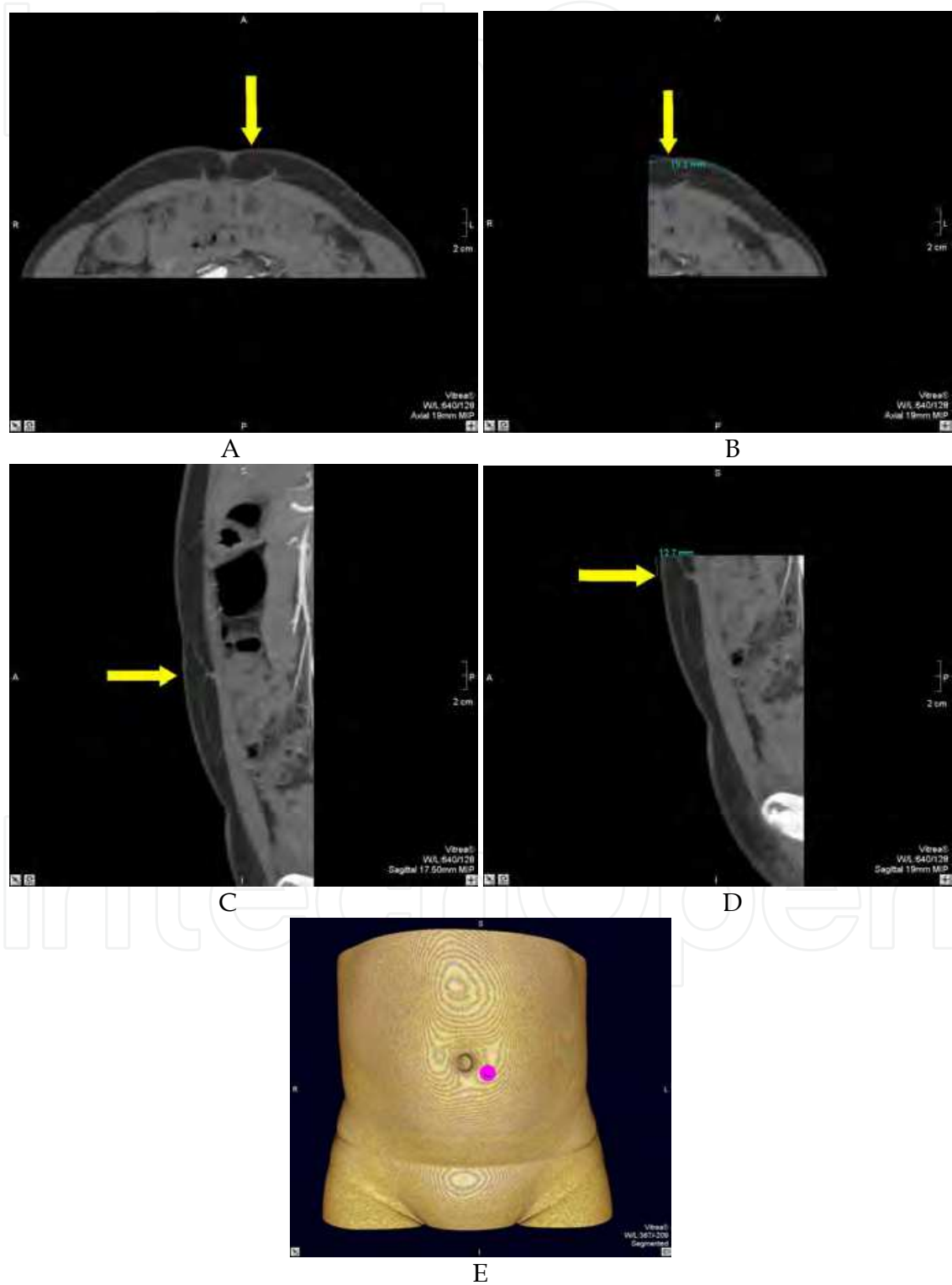


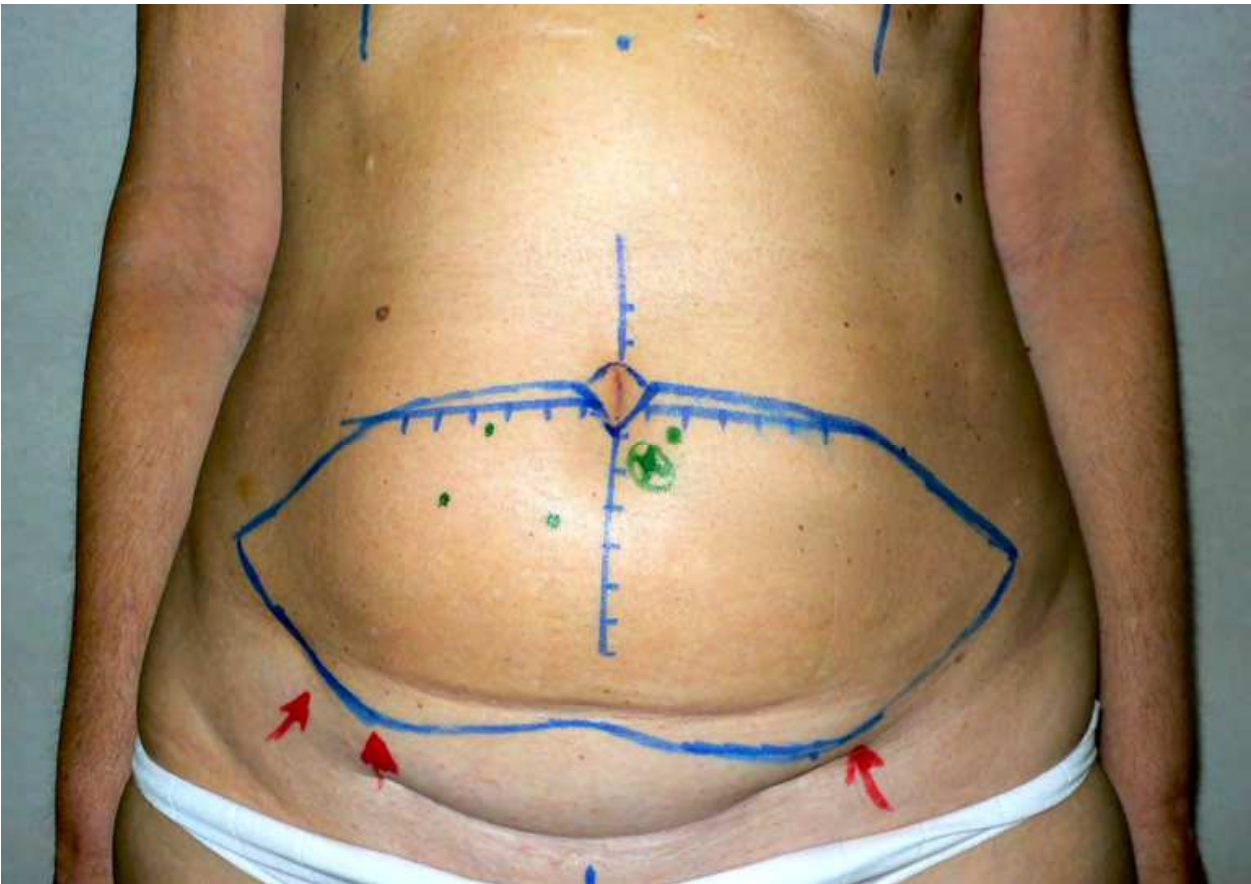
Fig. 4. 4A) Axial MCDT image of an intramuscular perforator of the deep epigastric vessels with its intramuscular course and its branching. 4B) Sagittal view MDCT image of the same patient showing the same perforator with its intramuscular course. Yellow arrow indicates the point in which the perforator pierces the fascia.

- Step 3.** Then we perform a 3D reconstruction of the abdomen to precisely locate the points on the skin surface where the best perforators emerge from the fascia of the rectus abdominis muscle. Using a virtual coordinate system with the umbilicus at the centre, all information is transferred to a data form sheet so that the perforators are mapped in a format that allows us to transpose their position preoperatively onto the abdominal skin of the patient. If we transfer these values from the computer to paper, we locate the exact point where we will find the perforator when we raise the flap (figures 5a,b,c,d,e,f: protocol for images assesment).
- Step 4.** Before we complete the study with the radiologist we like to look at the coronal cuts to visualize the subcutaneous and distribution pattern of the superficial inferior epigastric arterial system and assess the connections between the superficial and deep systems (figures 6a,b,c: Coronal images showing the abdominal vascular network).

So therefore, depending on the findings of the images provided by the MDCT or the MRI, we will decide which vessel is going to nourish the flap. The first point to check is the superficial system. If the superficial vessels have a good caliber -that is, more than 0.6mm- and a medial distribution in the abdomen, a SIEA flap could be performed. When there is not a good superficial system, we will consider the deep epigastric system. The second aspect is to search for a good paramuscular perforator. If we find a good one, we will center the flap on it, as its dissection is easier and faster. If we do not find a good paramuscular

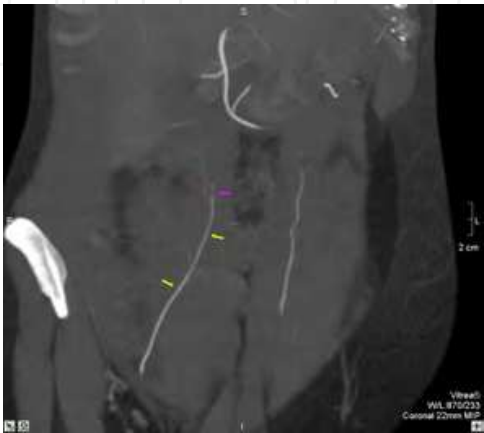
perforator, we will choose an intramuscular one. Several factors must be taken into account when we are selecting the perforator that is going to nourish the flap. Whenever possible a direct branch from the deep inferior epigastric artery and the one with the shortest intramuscular course will be selected as our perforator. The location of the perforator should be as central as possible within the flap and it should have a good intraflap axially and subcutaneous branching.



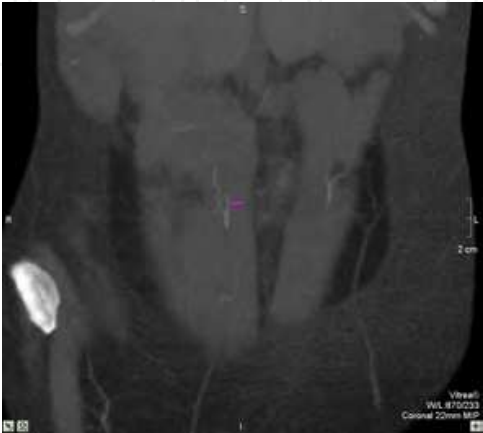


F

Fig. 5. Protocol for images assesment. A) Axial MDCT image showing the most suitable abdominal perforator in this patient. The yellow arrow indicates the point where the paramuscular perforator pierces the fascia. B) We measure the distance from the midline to the perforator in the axial view, and this is given the value of "x". C) Sagittal DMCT image showing the perforator. The yellow arrow indicates the point where the perforator pierces the fascia. D) The second measure is done in the sagittal view measuring from the umbilicus level to the exit of the perforator. This will be the "y" value. E) MDTC 3-D reconstruction for the same patient. The magneta arrow indicates the exactly point where the perforator pierces the fascia. F) Preoperative markings in the patient with the dominant perforator located.



A



B

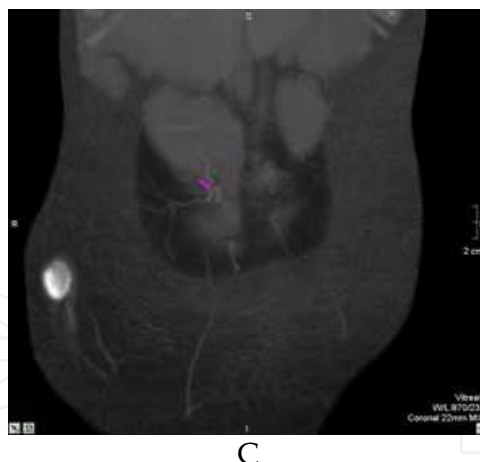

Fig. 6. Coronal images showing the abdominal vascular network. A) Deep level: Coronal image showing the course of the deep epigastric vessels (yellow arrows) and the origin of the main perforator (magneta arrow). 6B) Intermediate level. 7B) Superficial level: Coronal image showing the perforator connecting with the superficial vascular network. Magneta arrow marks the same perforator.

6. Discussion

Raising a perforator flap requires meticulous dissection of the perforator vessels, sparing the muscle structure with its segmentary motor nerves. Special skill is needed for such surgical dissection, and the intraoperative time is considerable. Because the vascular anatomy of the abdominal wall varies greatly among individuals and even between one hemi-abdomen and the other in the same individual, establishing a vascular map of each patient before surgery facilitates dissection.

The ability to detect the dominant perforating artery preoperatively saves considerable time for the surgeon. The benefits thus extend to the patient and also to reducing costs and conserving resources. Many techniques have been used to preoperatively map abdominal perforating vessels. The ideal technique should possess low cost, high availability and reproducibility, and high reliability in selecting the dominant perforator. In addition, it should be fast to perform, easy to interpret and free of morbidity.

Since the first reports on MDCT appeared many centers have focused on developing and improving this technique. MDCT today is considered the technique of choice in the preoperative evaluation of patients who are candidates for autologous breast reconstruction (13). In the continuing search for the ideal technique and to minimize the disadvantages of MDCT, many eyes are presently on MRI and results to date seem promising (19,20).

By using imaging techniques to decide preoperatively which perforators are most suitable, we can reduce the amount of stress for the surgeon who can now go straight to the chosen perforator with confidence and can ligate the other perforators safely without wasting time. The amount of time saved in the operating room can be balanced against the extra cost of the investigation. These techniques (MRI and CT) also allow us to plan an optimal design for the flap size the best vascularized tissue supplied by the dominant perforator. As a result, fat necrosis and partial flap loss has been shown to be reduced in our studies when we validated the MDCT that we published in 2006 because it allows the surgeon to choose the best

vascularised region of abdominal tissue supplied by the dominant perforator. This information is also extremely valuable if a patient has had previous surgery, such as liposuction or a hysterectomy, in the abdominal area. The high sensitivity, specificity and the 100% positive predictive value of this non-invasive and easy-to-interpret preoperative mapping technique have made it a highly-promising diagnostic tool in the planning of DIEP flaps.

Considerable discussion remains concerning whether MDCT or non-contrast-MRI is the more ideal method for the preoperative study. The answer depends on the facilities of the center, but if we know that we can achieve the same information with both techniques, we should use the one which has less morbidity for the patient. We use MDCT in two main situations: 1) when we can take advantage of the extension study requested by the oncologist in cases of delayed reconstruction and 2) in cases when we need to study a large extension of the body to rule out anatomical abnormalities.

With MDCT and MRI we have achieved a breakthrough in the preoperative evaluation of the perforator surgery. Compared with the handheld Doppler and color Doppler imaging, the advantages are multiple:

- High sensitivity and high specificity
- Good three-dimensional evaluation of quality, course and location of perforators
- Easy interpretation by the radiologist and plastic surgeon
- Easy storage of data on a pendrive, simplifying reproducibility
- Reduction of operating time and complications
- Good patient tolerance
- Reduction of surgeon stress

Day to day progress is being made in the quality of images and radiological equipment. The ideal preoperative method will be that which offers the best quality images with minimal inconvenience to the patient. MDCT and MRI are clearly the best tools available as yet to make a complete preoperative study prior to breast reconstruction. With the application of increasingly sophisticated, faster and less invasive methods, we are getting closer to a virtual dissection of the perforator before surgery. There is still a long road ahead but we have undoubtedly come a long way.

7. Abbreviations

DIEP: Deep Inferior Epigastric Perforator

MDCT: Multidetector Row Computed Tomography

MRI: Magnetic Resonance Imaging

SSFP: steady-state free-precession

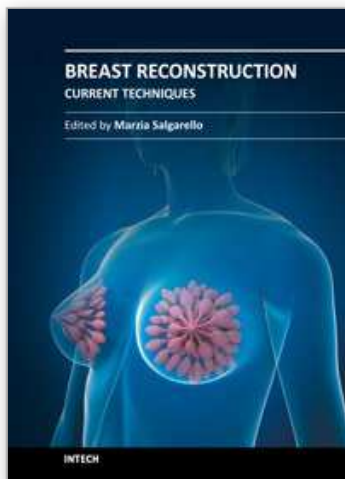
T-SLIP: time spatial inversion pulse

FBI: Fresh Blood Imaging

8. References

- [1] Allen RJ, Treece P. Deep inferior epigastric perforator flap for breast reconstruction. *Ann Plast Surg* 1994;32:32-8.
- [2] Blondeel PN, Boeckx WD. Refinements in free flap breast reconstruction: The free bilateral deep inferior epigastric perforator flap anastomosed to internal mammary artery. *Br J Plast Surg* 1994;47:495-501.

- [3] Craigie JE, Allen RJ. Autogenous breast reconstruction with the deep inferior epigastric perforator flap. *Clin Plast Surg* 2003;30:359-69.
- [4] Granzow JW, Levine JL. Breast reconstruction with the deep inferior epigastric perforator flap: history and an update on current technique. *J Plast Reconstr Aesthet Surg* 2006;59:571-9.
- [5] Blondeel PN, Neligan PC. Perforator Flaps. *Anatomy Technique and Clinical Applications*. Vol I Chapter 7: Complications: Avoidance and Treatment. 118-9. Quality Medical Publishing Inc., 2006.
- [6] Masia J, Larrañaga J, Clavero JA, Vives L, Pons G, Pons JM. The value of the multidetector row computed tomography for the preoperative planning of deep inferior epigastric artery perforator flap: our experience in 162 cases. *Ann Plast Surg* 2008; 60:29-36.
- [7] Masia J, Clavero JA, Larrañaga JR, Alomar X, Pons G, Serret P. Multidetector-row computed tomography in the planning of abdominal perforator flaps. *J Plast Reconstr Aesthet Surg*. 2006; 59:594-9.
- [8] Taylor, G. I., Doyle, M., and McCarten, G. The Doppler probe for planning flaps: Anatomical study and clinical applications. *Br. J. Plast. Surg.* 43: 1, 1990.
- [9] Blondeel PN, Beyens G, Verhaeghe R, Van Landuyt K, Tonnard P, Monstrey SJ, Matton G. Doppler flowmetry in the planning of perforator flaps. *Br J Plast Surg* 51:202-209, 1998
- [10] Giunta RE, Geisweid A, Feller AM. The value of preoperative Doppler sonography for planning free perforator flaps. *Plast Reconstr Surg*. 2000 Jun; 105(7):2381-6.
- [11] Hallock GG. Doppler sonography and color duplex imaging for planning a perforator flap. *Clin Plast Surg* 2003 Jul;30(3):347-57, v-vi.
- [12] Rajan S, Uppal, Bob Casaer, Koenraad Van Landuyt, Phillip Blondeel. The efficacy of preoperative mapping of perforators in reducing operative times and complications in perforator flap breast reconstruction. *J Plast Reconstr Aesthet Surg*. 2009 Jul;62(7):859-64.
- [13] Mathes DW, Neligan PC. Preoperative imaging techniques for perforator selection in abdomen-based microsurgical breast reconstruction. *Clin Plast Surg*. 2010 Oct; 37(4):581-91.
- [14] Hijawi JB, Blondeel PN. Advancing deep inferior epigastric artery perforator flap breast reconstruction through multidetector row computed tomography: an evolution in preoperative imaging. *J Reconstr Microsurg*. 2010 Jan;26(1):11-20.
- [15] Hamdi M, Van Landuyt K, Hedent EV, Duyck P. Advances in autogenous breast reconstruction. The role of preoperative perforator mapping. *Ann Plast Surg* 2007;58:18-26.
- [16] Rozen WM, Ashton MW, Grinsell D, Stella DL, Phillips TJ, Taylor GI. Establishing the case for CT angiography in the preoperative imaging of abdominal wall perforators. *Microsurgery*. 2008;28(5):306-13.
- [17] Clavero JA, Masia J, Larrañaga J, Monill JM, Pons G, Siurana S, Alomar X. MDCT in the preoperative planning of abdominal perforator surgery for postmastectomy breast reconstruction. *AJR Am J Roentgenol* 2008; 191:670-6
- [18] Rozen WM, Stella DL, Bowden J, et al. Advances in the pre-operative planning of deep inferior epigastric artery perforator flaps: magnetic resonance angiography. *Microsurgery* 2009;29:119-23.
- [19] Masia J, Kosuotić D, Cervelli D, Clavero JA, Monill JM, Pons G. In search of the ideal method in perforator mapping: noncontrast magnetic resonance imaging. *J Reconstr Microsurg*. 2010 Jan;26(1):29-35.
- [20] Masia J, Navarro C, Clavero JA, Alomar X. Noncontrast magnetic resonance imaging for preoperative perforator mapping. *Clin Plast Surg*. 2011 Apr; 38(2):253-61.



Breast Reconstruction - Current Techniques

Edited by Prof. Marzia Salgarello

ISBN 978-953-307-982-0

Hard cover, 276 pages

Publisher InTech

Published online 03, February, 2012

Published in print edition February, 2012

Breast reconstruction is a fascinating and complex field which combines reconstructive and aesthetic principles in the search for the best results possible. The goal of breast reconstruction is to restore the appearance of the breast and to improve a woman's psychological health after cancer treatment. Successful breast reconstruction requires a clear understanding of reconstructive operative techniques and a thorough knowledge of breast aesthetic principles. Edited by Marzia Salgarello, and including contributions from respected reconstructive breast plastic surgeons from around the world, this book focuses on the main current techniques in breast reconstruction and also gives some insight into specific topics. The text consists of five sections, of which the first focuses on the oncologic aspect of breast reconstruction. Section two covers prosthetic breast reconstruction, section three is dedicated to autogenous breast reconstruction, and section four analyzes breast reconstruction with a fat graft. Finally, section five covers the current approaches to breast reshaping after conservative treatment.

How to reference

In order to correctly reference this scholarly work, feel free to copy and paste the following:

Jaume Masia, Carmen Navarro, Juan A. Clavero and Xavier Alomar (2012). Preoperative Computed Tomographic Angiogram for Deep Inferior Epigastric Artery Perforator Flap for Breast Reconstruction: The Imaging Mapping Era, *Breast Reconstruction - Current Techniques*, Prof. Marzia Salgarello (Ed.), ISBN: 978-953-307-982-0, InTech, Available from: <http://www.intechopen.com/books/breast-reconstruction-current-techniques/preoperative-computed-tomographic-angiogram-for-deep-inferior-epigastric-artery-perforator-flap-brea>

INTeCH
open science | open minds

InTech Europe

University Campus STeP Ri
Slavka Krautzeka 83/A
51000 Rijeka, Croatia
Phone: +385 (51) 770 447
Fax: +385 (51) 686 166
www.intechopen.com

InTech China

Unit 405, Office Block, Hotel Equatorial Shanghai
No.65, Yan An Road (West), Shanghai, 200040, China
中国上海市延安西路65号上海国际贵都大饭店办公楼405单元
Phone: +86-21-62489820
Fax: +86-21-62489821

© 2012 The Author(s). Licensee IntechOpen. This is an open access article distributed under the terms of the [Creative Commons Attribution 3.0 License](https://creativecommons.org/licenses/by/3.0/), which permits unrestricted use, distribution, and reproduction in any medium, provided the original work is properly cited.

IntechOpen

IntechOpen