

We are IntechOpen, the world's leading publisher of Open Access books Built by scientists, for scientists

6,900

Open access books available

186,000

International authors and editors

200M

Downloads

Our authors are among the

154

Countries delivered to

TOP 1%

most cited scientists

12.2%

Contributors from top 500 universities



WEB OF SCIENCE™

Selection of our books indexed in the Book Citation Index
in Web of Science™ Core Collection (BKCI)

Interested in publishing with us?
Contact book.department@intechopen.com

Numbers displayed above are based on latest data collected.
For more information visit www.intechopen.com



Implant and Implant Assisted Breast Reconstructions

Sarah S.K. Tang and Gerald P.H. Gui
Royal Marsden NHS Trust,
United Kingdom

1. Introduction

The number of women in the USA with breast implants is now estimated at over 6 million based on national surveys. This is numerically in excess of 5% of the female adult population. The majority of these women had cosmetic augmentations but 20-30% had implant based post-mastectomy breast reconstructions or correction of congenital abnormalities. In 2010, 296203 breast augmentations were performed in the USA and silicone implants were used in 60% of cases (American Society of Plastic Surgeons [ASPS], 2010). 93083 breast reconstructions were performed for congenital or postmastectomy defects. Of these 67% were performed using tissue expander and implant techniques. The significant majority of implants used in breast reconstruction were silicone (73%). Reconstructions using autologous tissue formed a small percentage of overall reconstructions (transverse rectus abdominus myocutaneous flaps (TRAM) 7%, latissimus dorsi (LD) flaps 7% and deep inferior epigastric perforator flaps (DIEP) 5%).

RECONSTRUCTIVE PROCEDURES	TOTAL PROCEDURES	13-19	20-29	30-39	40-54	55 AND OVER
Breast reconstruction	93,083	555	2,466	11,203	47,155	31,704
Saline Implants	18,334	-	-	-	-	-
Silicone Implants	50,559	-	-	-	-	-
Implant alone	9,452	-	-	-	-	-
Tissue expander and implant	62,081	-	-	-	-	-
TRAM flap	6,758	-	-	-	-	-
DIEP flap	5,118	-	-	-	-	-
Latissimus Dorsi Flap	6,335	-	-	-	-	-
Breast reduction	83,241	4,645	13,464	19,950	30,251	14,931
Breast implant removals (Reconstructive patients only)	14,991	134	1,031	2,870	6,779	4,177

Table 1. Breakdown of breast reconstruction procedures performed in 2010 according to procedure type and age range (ASPS, Report of the 2010 Plastic Surgery Statistics)

The history of implant based breast reconstruction spans five decades when the first silicone breast implants became available. The last 20 years have seen rapid advances in expander and implant technology such that the era in which implant reconstructions aimed at simply producing the appearance of a breast mound in clothing has transitioned into the current era in which in appropriately selected patients an implant based reconstruction has the potential to resemble a natural breast in contour, projection and a well-defined inframammary crease.

A common misconception is that breast reconstructions with autologous tissue are necessarily superior in quality compared to reconstructions with implants. Patient selection and a full discussion on rewards versus risks enable patient choice in making an informed decision about the reconstructive options available. The longer complex procedures to harvest autologous donor material, often involving microvascular surgery, are associated with donor site healing and scars with a longer period of recovery compared with implant based breast reconstruction. Excellent outcomes can be achieved with implant based reconstruction, optimising the implant pocket where necessary with staged surgery, acellular dermal matrices, fat transfer techniques but with the more likely need for maintenance surgery in the longer term. Breast reconstruction surgery is a process and often involves secondary procedures, whether the primary reconstruction is autologous or implant based.

Implant based breast reconstruction is technically challenging and great care and attention to detail is necessary to achieve the best results. With autologous breast reconstruction, if sufficient amounts of skin and fat can be brought to the site of the mastectomy, it is relatively simple to shape this tissue to achieve an attractive result with the breast reconstruction. Implant based breast reconstruction requires careful assessment to determine suitability for one-stage or two-stage surgery; fixed volume, expandable implants or tissue expanders; shaped or round devices; pocket enhancement techniques or the incorporation of implant plus autologous tissue flaps. The process can be a complex algorithm based on multifactorial parameters that may be patient and surgeon dependent.

The backbone of two-stage implant based reconstructions is tissue expansion. The placement of an expander can be performed in either an immediate or delayed setting following mastectomy for breast cancer. Tissue expansion is often a pre-requisite in the delayed setting while a choice of tissue expansion, the insertion of a permanent fixed volume or expandable implant is available in the immediate setting. Immediate reconstructions have the advantage that patients wake up from surgery with a reconstructed breast, limiting some of the psychological sequelae experienced by patients following mastectomy. This is of particular relevance in patients undergoing risk reducing surgery who are usually young women undergoing bilateral procedures who should not require adjuvant therapy and would desire a rapid return to normal life. However, there are some advantages to delaying reconstruction in an oncologic setting. The delayed insertion of a tissue expander is less technically challenging. As the post-mastectomy skin-flaps have been allowed time to heal, there is a reduced risk of skin flap ischaemia and wound healing complications. Delaying reconstruction also eliminates the uncertainty of postoperative chest wall radiotherapy and allows more flexibility with operating theatre scheduling. Returning to surgery for the implant exchange allows pocket revision to optimise the reconstructed breast form.

Initial expander and implant devices were rudimentary and cosmetic outcomes were limited. These early devices had smooth elastomer surfaces and were associated with high rates of capsular contracture and device displacement. Aesthetic outcome was less predictable and in many cases, it was necessary to perform multiple adjustments to improve implant position, projection, or inframammary fold definition. In other cases, patients were expected to live with reconstructions that simply produced the impression of a breast mound in clothing. The unpredictability and inconsistency of expander-implant

reconstructions drove the development of alternative strategies to reconstruct the breast, namely autologous tissue options (initially the TRAM and LD flaps, and later the DIEP flaps), initially as replacements or salvage techniques and later as the primary approach to breast reconstruction. Autologous tissue reconstructions have become popular with some surgeons as a satisfactory breast mound can usually be achieved in a single operative procedure with more predictable long-term results and lower complication rates when compared with tissue expansion and implant techniques (Beasley & Ballard, 1990; Rosen et al., 1990). It is possible to combine tissue expansion with autologous tissue flap procedures, although an often cited advantage of autologous reconstruction is to avoid the disadvantages associated with the use of an implant. The main advantages that expander-implant reconstructions have over autologous muscle flap techniques include the shorter surgical time and quicker recovery, avoiding the use of donor tissue and associated donor site morbidity with relatively short scars to complement the minimal access approach of skin-sparing mastectomy. The need for secondary procedures to refine the reconstructed breast, the contralateral breast or the trunk is common to all reconstruction types. Several generations of silicone implants have been developed since 1963, with a gradual progression to improved surface texturing, gel consistencies, range of sizes and shapes. The availability of these newer and improved devices has enabled surgeons to obtain more consistent and aesthetically pleasing results. Within the limitations of each individual's chest wall anatomy, soft tissue characteristics and opposite breast contour, a realistic implant based breast reconstruction is now achievable.

2. Types of implants

2.1 Silicone

Silicone refers to a group of polymers, based on the element silicon. Silicon dioxide (sand) is one of the most abundant compounds on Earth. The silicone polymer polydimethylsiloxane (PDMS) is abundantly used in medical applications from indwelling catheters, extended wear contact lenses, pacemakers, syringes and pharmaceuticals to name but a few. Silicone is ideally suited for medical use because of its thermal and oxidative stability, chemical and biological inertness, hydrophobic nature and sterilization capability. Silicone polymers may be produced in a variety of forms, including oil, gels or elastomers (rubber). The physical state is determined by the degree of chemical cross-linking. Cross-linking occurs between vinyl and hydrogen groups on silicon atoms. Silicone oils are straight chains of PDMS without cross-linking and are insoluble in water. Silicon gels consist of cross-linked PDMS chains, together with variable amounts of PDMS liquid. Elastomers of silicone have high degrees of cross-linking and almost no PDMS oil. Common to all implants is the outer shell made out of silicone elastomer reinforced with silica. The shell can be single or double layered, smooth or textured, barrier coated and/or covered with polyurethane foam.

2.1.1 A short history of silicone implants

The modern silicone breast implant as we know it was released to the open market in 1963. It has gone through intense phases of development which have improved the initially primitive and limited devices to current day devices which exhibit a tremendous range of surface textures, sizes, gel consistencies and anatomical shapes.

2.1.2 First generation (1960s)

The original silicone gel implant was developed by Cronin and Gerow and was named the Silastic 0. These implants had envelopes of thick smooth walled silicone elastomer made in 2 sections and filled with viscous silicone gel material. The shell halves were then glued together. By the end of the 1960s the shell was cast as a single unit and sealed with a small patch. Fixation patches were introduced in the early part of this period because it was felt that scar and tissue ingrowth was necessary to fix the implant and prevent migration. These fixation patches were made out of Dacron mesh, perforated silicone or polyurethane foam. Not only were the patches found to be generally unnecessary, they also increased the rupture rate by creating stress points in the envelope.

2.1.3 Second generation (1970s)

A new generation of thinner shells and less viscous gels were released in the mid-1970s as attempts to reduce capsular contractures. Unfortunately not only were capsular contracture rates unchanged, these fragile devices were more prone to rupture.

2.1.4 Third generation (1980s)

This period saw significant advances in silicone technology and the implants produced during this era form the backbone of our current devices. Stronger shells reduced the amount of silicone oil “bleed” into adjacent tissues. The gel content was made more viscous and cohesive. Expandable implants with subcutaneous ports were also developed. In 1989 textured-surface envelopes became available. These were felt to reduce capsular contracture rates. Polyurethane coating of implants was first introduced in the 1960s but did not gain popularity until the 1980s. The reduction in capsular contracture seen with polyurethane coated devices was attributed to its open cell structure which allowed tissue in-growth and prevented a regular circumferential deposition of collagen.

In the early 1990s the modern silicone implant was affected by a substantial negative media publicity campaign over the apparent danger of breast implants resulting in a marked drop in the use of silicone implants for all indications. Safety issues centred around silicone oil leakage locally and systemically and the use of polyurethane coating that had become popular towards the end of 1980s. Polyurethane was shown to undergo a degradation process in vivo that produced toluenediamine (TDA). This chemical was a known carcinogen in rats. At that time, the risk to humans was unknown but has been since shown to be extremely low. Further, the polyurethane coating was found to completely delaminate from the underlying silicone shell after several years in vivo. This resulted in loss of implant form. The devices were voluntarily removed from the market in the early 1990s. There has since been extensive research proving the safety of silicone and breast implants. Evidence is widely available disproving any correlation between implants (or silicone) and carcinogenesis, delayed cancer detection, autoimmune disease, neurological disease, teratogenicity and TDA toxicity.

2.1.5 Fourth and fifth generation implants

The adverse publicity seen in the 1990s resulted in stricter manufacturing standards. Current implants of the fourth and fifth generations are essentially refined 3rd generation devices. These devices include cohesive gel products in which, instead of cross linkage of

only 20% of gel contents (and therefore the remaining 80% being oil), the cross linking is 40% of the contents. The resulting gel is much stiffer and maintains its shape even when cut therefore controlling spread of gel contents in the event of shell rupture. Larger incisions are however required to accommodate these less flexible implants. In an effort to reduce gel bleed from silicone-filled devices, phenyl or trifluoropropyl groups are bonded to the shell to decrease the shell permeability to PDMS oil. These low bleed implant shells with barrier coating are characteristic of current third, fourth and fifth generation implants.

2.2 Saline

These devices are inserted empty and are filled with saline at surgery. Each size has a recommended fill range provided by the manufacturer. Overfilling produces a firm device and under filling risks early rupture from a process called “fold flaw” which results in increased rubbing of the membrane at that point. Any breach of the shell results in instant deflation and harmless absorption of the saline over the next day or two.

2.3 Textured versus smooth surfacing

There are several commercially manufactured varieties of textured silicone elastomer shells. Mentor have developed the Siltex pattern which results as a negative contact imprint of a texturing foam. This process produces many fine nodules on the surface of the shell in a regular distribution. Allergan’s Biocell surface is produced through a lost salt technique. The implant shell is coated with finely graded salt under light pressure. The salt crystals are subsequently lost through the manufacturing process, leaving many fine depressions on the surface of the shell. True tissue in-growth with textured surfaces only occurs reliably when the implant is placed in a snug pocket or in the tissue expansion environment. These textured surfaces may reduce the rate of capsular contracture but this effect has only been seen in silicone implants and not in saline filled devices. Texturing to provide adhesion of the implant to the surrounding tissue is an important consideration with shaped devices to prevent rotation but may impact negatively on implant scalloping of the overlying skin.

2.4 Expandable implants

Permanent expandable implants combine an outer chamber of factory prefilled silicone with an inner chamber that allows post-operative filling with saline. In current practice the 2 relevant implant valve types are the Becker self-sealing valve which closes on removal of the filling tube and port and the Allergan 150 valve which is plugged when the fill tube is removed. These implants permit gradual and temporary over inflation to create an ample pocket and then can be left in as a permanent implant after the size has been adjusted satisfactorily.

2.5 Shaped versus round implants

Implants can be either shaped or round. Shaped implants can also be referred to as tear dropped, contoured or anatomical. Shaped implants have greater fullness in the lower half and less fullness in the upper half. Some surgeons feel that these implants provide a more natural breast shape particularly in women with extremely little or no breast tissue as these women would appear too full in the upper pole if a round implant was inserted. Others feel

that the shaped implant makes no difference to the final result and compensate for upper pole fullness in small breasted women by lowering the position of the implant. Further, because the silicone gel or saline component of the round implant gravitates to the lower pole of the implant when a woman stands, the lower pole naturally becomes fuller, and some argue that this negates the need for a shaped implant. The disadvantage of shaped implants is that post-surgery rotation would result in an obvious sideways appearance to the breast requiring revisional surgery, a problem that does not arise with a round implant. In order to reduce the risk of rotation, shaped implants are textured to reduce the risk of rotation. Shaped implants are generally more expensive than rounded implants.

3. Patient selection

Important factors that should be considered during the patient selection process include patient features (breast volume, breast shape, the contralateral breast, chest wall, body mass index, lifestyle including work and sport, and co-morbid factors), patient understanding (of the procedure, complications, implications and of the device), and the oncologic features (skin sparing mastectomy versus traditional mastectomy, systemic therapy needs and adjuvant radiotherapy). Conventional teaching stipulates that the ideal woman for an implant based reconstruction has small to moderate sized breasts without significant ptosis. Bilateral breast reconstructions for cancer or risk reduction may also be ideal because it provides an optimum scenario for achieving symmetry. Patients undergoing unilateral mastectomies may require a contralateral procedure for symmetrisation by augmentation, mastopexy or breast reduction. Women who rely on upper limb strength for work or sport may be directed towards an implant reconstruction or muscle sparing autologous abdominal option as this would avoid the potential functional morbidity experienced that may follow an LD flap reconstruction.

Women with large or ptotic breasts may still be suitable for implant reconstruction by utilization of a skin-sparing volume reducing approach. A Wise pattern approach allows reduction of the skin envelope. The de-epithelialized lower flap facilitates lower pole implant cover and often allows for pseudo-ptosis with careful positioning of the inframammary crease. The nipple may be preserved on the superior mastectomy skin flap. Caution may need to be exercised in women with a generous subcutaneous adipose covering as implant projection may be compromised by the depth of the rib cage below the fat layer.

There are relative contraindications which would make some patients less suited to an implant based reconstruction. Aside from the usual medical conditions that would increase the risk of anaesthesia or infection, a significant contraindication is unrealistic expectation. Patients with large or advanced breast cancers and clinically involved axillary lymph nodes are likely to require adjuvant radiotherapy. Radiotherapy either prior to implant insertion or following implant insertion can result in hardened and thickened soft tissues and initiate or exacerbate capsular contraction.

4. Preparing a patient for an implant breast reconstruction

4.1 Biodimensional planning

Biodimensional planning involves taking a few detailed chest measurements, including the sternal-notch nipple, inframammary crease nipple and midline nipple distances. The attributes of the existing breast form should be measured, namely the transverse breast

width, vertical breast height and projection. These measurements along with pre-operative photographs form an essential part of the medical records of the pre-operative state on which post-operative evaluation can be compared. Careful assessment should be made of the patient’s chest wall, general predisposition and soft tissue properties.

	Implant reconstruction	Autologous reconstruction
Anatomy and patient physique	Small to moderate sized breasts with minimal ptosis are best suited for implant reconstruction Implant reconstruction for large, ptotic breasts can still be achieved by performing a Wise-pattern skin-sparing volume reducing mastectomy Body habitus/ BMI: excessive subcutaneous adiposity risks compromising implant projection	Larger, ptotic breasts may be better reconstructed using autologous tissue
Attitude and anxieties	Patient wants a shorter procedure with a more rapid post-operative recovery period Does not mind the presence of a device	Patient is willing to invest time and effort in a longer and more complex operation Can accept the additional potential complications associated with the donor site Does not want reconstruction using a device
Stage of disease	Earlier disease with a lesser chance of adjuvant chest wall radiotherapy with its associated increased risk of capsulation A temporizing implant can be used to maintain the skin envelope. This can be deflated if radiotherapy is required to optimize delivery of external beam therapy. If radiotherapy is not required, prompt implant exchange can be performed to avoid delay to other adjuvant therapies	More advanced disease with a higher chance to chest wall radiotherapy becoming necessary. Radiotherapy will still affect autologous tissues but capsulation is avoided
General health	A patient who would benefit from a shorter operation and more rapid post-operative recovery period i.e. a person with a greater number of comorbidities and is at higher anaesthetic risk	Low anaesthetic risk
Muscle function	Relies on upper limb function for work or sport and therefore should avoid a latissimus dorsi flap. Increased use of abdominal wall in sport or work, may be at higher risk of abdominal wall herniation if TRAM is performed	Loss of muscle function or effect of long scars should not have profound effect on work, activities of daily living or sport
Bilateral procedures	Ideally suited to implant reconstructions as provides the greatest opportunity to achieve symmetry	Increases the complication and anaesthetic risks associated with these longer and more complex procedures

Table 2. Description of patient characteristics that may influence the type of breast reconstruction chosen

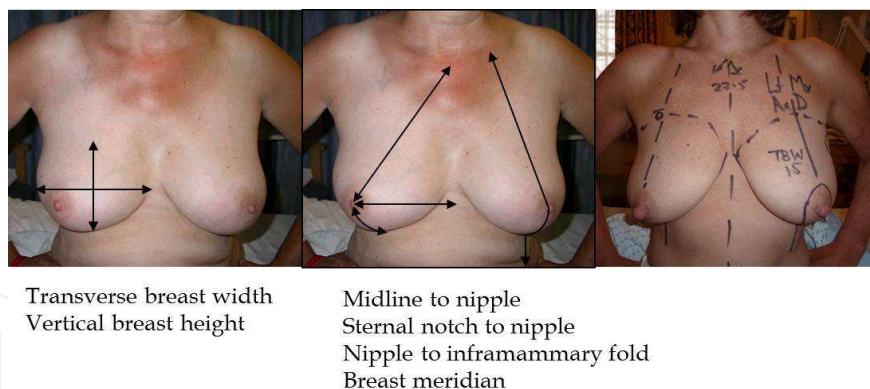


Fig. 1. Measurement of the existing breast form are taken as part of biodimensional planning

These factors contribute to the choice of surgical technique and aid implant selection so that the optimum breast reconstruction is achieved for that individual. Both round and shaped implants are available in a range of base widths, heights and profiles. The main determinant of implant selection is breast width. This takes account of the patient's chest wall characteristics and is an essential consideration in order to avoid placing a narrow implant on a wide chest wall or conversely a wide implant on a narrow chest wall. Once the base width is established the appropriate height can be selected. Patients who have less ptosis will have a fuller upper pole and would therefore benefit from a rounded implant or taller height implant whereas a more ptotic breast would be better reconstructed using a shaped implant with a shorter height. The profile refers to the amount of forward projection of the implant from the chest wall and range from low to ultra-high projections. Profile selection can be guided by comparison to the contralateral breast or by patient's desire for projection, adjusting the contralateral breast as appropriate. In patients with extremely wide chest walls and excessive subcutaneous tissue, achieving adequate projection is a challenge and these patients are therefore less suited to an implant only reconstruction.

4.2 Marking up

With the patient sitting or standing up, the midline, the breast meridian, inframammary folds, lateral border and upper extents of both breasts should be marked. The breast meridian can be taken from a point 5cm lateral to the medial end of the clavicle to the centre of the nipple and the line extended to the inframammary crease. Mark the meridian beyond the inframammary crease as the marking often washes out during the surgery. The skin incision should also be indicated. In many cases of immediate breast reconstruction, a skin-sparing approach is suitable but may sometimes need to be modified to take into account pre-existing scars. The choice of skin incision is extremely variable and dependent on each individual case and the surgeon's preference. Common skin incisions include the circumareolar incision, circumareolar incision with a lateral or vertical extension and the inframammary fold incision. It is best to avoid extending the incision into the superior and medial sectors of the breast. The incision should be planned to allow preservation of the most favourable blood supply to the mastectomy skin flaps.

If skin excision is to form part of the mastectomy, commonly used patterns include the circumareolar to excise the nipple areolar complex with a range of extensions, most commonly lateral or vertical. The nipple areolar complex could also be incorporated into a number of skin

excision patterns including the oblique ellipse, transverse ellipse, vertical ellipse, inverted T shape, mastopexy and Wise pattern excisions. This wide variation could also be modified for nipple preservation in suitable cases. Ultimately the goal is to leave sufficient amounts of well-vascularized skin while excising the maximum amount of breast tissue.

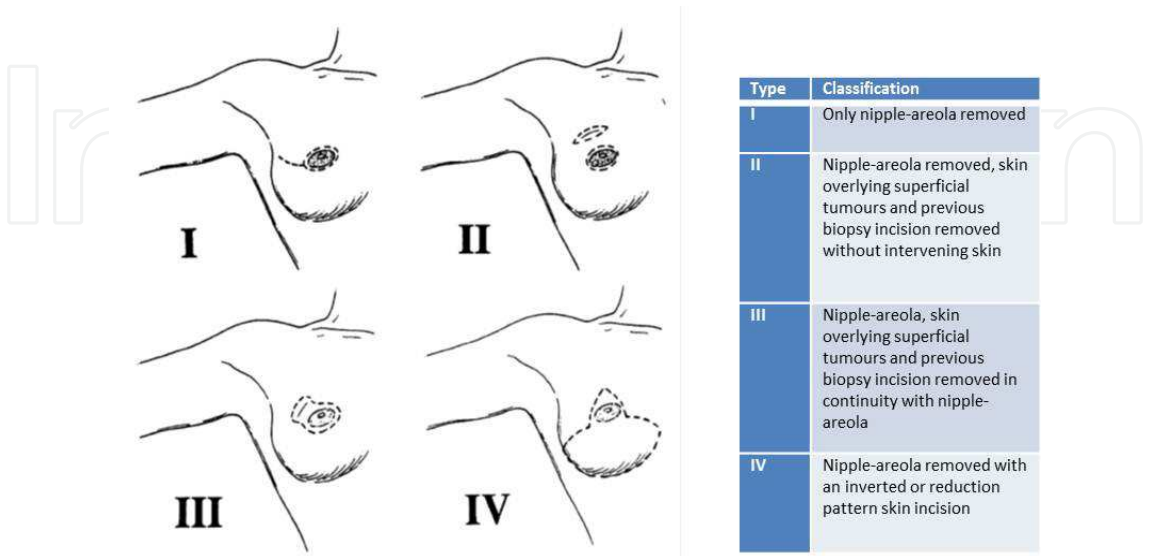


Fig. 2. Classification of skin sparing mastectomy (Carlson, 1997)

Good cover of the implant or the tissue expander should be obtained such that the desired breast shape is created without undue laxity or tension and without skin necrosis from ischaemic flaps. When the plan for reconstruction includes the addition of a flap, the surgical excision can be designed such that the planned skin paddle of the transposed myocutaneous flap accurately replaces the area of removed native breast skin.

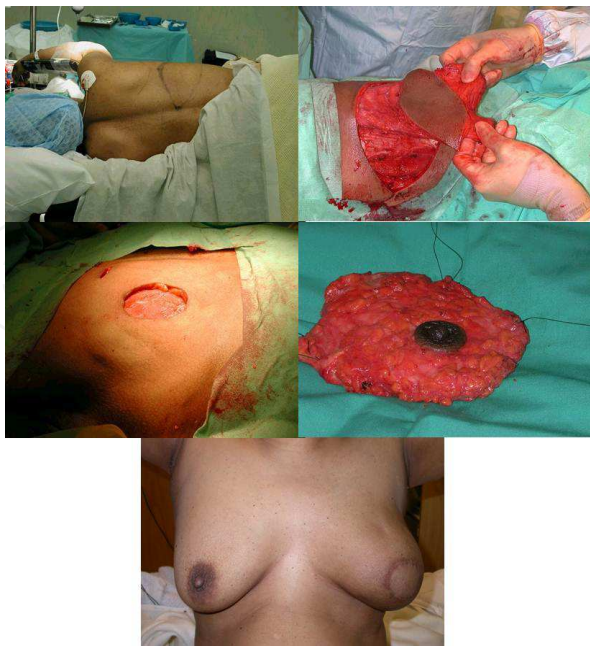


Fig. 3. An implant assisted LD breast reconstruction following a skin sparing mastectomy. The planned skin paddle of the LD flap accurately replaces the removed nipple-areolar complex

4.3 Positioning

Most surgeons would perform the mastectomy on a supine patient with both arms out on a board to add access to the lateral extent of the breast incision, to allow access to the axillary nodes and to enable comparison with the contralateral breast. Adequate exposure should be provided when draping the patient to view the collar bones, lateral extents of both breasts and the lower chest. Creation of the submuscular pocket, reshaping of the mastectomy space and device insertion can be done with the patient supine initially, and the patient can be moved into a sitting position intra-operatively to allow for positional variation. Further adjustments to the pocket can then be performed. These stages of the breast reconstruction can be performed on patients at 45 degrees or in a complete upright sitting position. Appropriate operating table choice and positioning is essential prior to draping.

5. Reconstruction options

5.1 Immediate reconstruction

The options for immediate implant based reconstruction are as follows:

- One stage using a permanent implant
- One stage using an expandable implant
- Two stage using a tissue expander and subsequent implant exchange

The replacement of mammary tissue with an implant immediately after a mastectomy has been refined over the years and usually implies the use of an expandable implant as a planned one stage procedure or the insertion of a tissue expander prior to the subsequent placement of a permanent fixed volume implant. Occasionally an adequate submuscular pocket can be created for a fixed volume implant at the primary procedure. Unless oncologic criteria determine otherwise, a skin-sparing mastectomy is commonly performed in association with an immediate breast reconstruction.

5.1.1 Implant reconstruction in small breasts with minimal ptosis

This forms the classic group of patients in whom implant based breast reconstruction is often described. Tissue expansion can usually be avoided in patients with small breasts who require reconstruction of a non-ptotic breast of similar or slightly larger size. In such patients, an increase in the desired reconstructed breast size usually requires the use of an expandable implant as a planned one stage procedure in the presence of an adequate pocket. A significant increase in size is best addressed as a two stage procedure. If nipple preservation is being considered, this can usually be maintained attached to the mastectomy flap via the periareolar extension, with or without extensions for access.

5.1.2 Implant reconstruction in moderate sized breasts

The place of implant breast reconstruction in this patient is also established. For women with moderate sized breasts and no or minimal ptosis, total submusculo-fascial cover may not be achieved and it is not the authors' preference to have incomplete implant cover. Such cases may be best addressed as a two stage tissue expansion procedure, inserting a tissue expander into the submusculo-fascial pocket and expanding over an interval in outpatients, before a two stage implant exchange.

The use of acellular dermal matrices (vide infra) has extended the role of one stage implant reconstruction in this group of patients. An implant assisted latissimus flap also provides for excellent long term implant cover in this patient group. The acceptance of nipple preservation in some patient subgroups in conjunction with use of an acellular dermal matrix has renewed interest in the inframammary crease approach, preserving the nipple in its normal anatomical position and draping the lower pole of the retained skin envelope over the acellular dermal matrix sheet interpositioned between the lower freed border of pectoralis major and the surgically created inframammary crease. Nipple preservation if appropriate can also be maintained via the periareolar incision with or without extension for access. The larger the increase in size from the original breast envelope the more unpredictable the final nipple position on the reconstructed breast. Great care needs to be taken in surgical planning to maintain the nipple position at the appropriate height in the breast meridian that needs to coincide with the projected new midline nipple distance, that requires to match the contralateral side.

5.1.3 Implant reconstruction in women with larger breasts

In women with larger and ptotic breasts, the use of a Wise pattern approach provides excellent access to perform a mastectomy despite the breast size. The lower mastectomy-skin flap is de-epithelialized and used to provide lower pole implant cover. This approach usually results in a smaller breast mound that corrects for ptosis and is considered a skin-sparing volume reducing technique. The implant reconstruction can usually be performed with a fixed volume device or expandable implant as a one stage procedure. Planning a two stage procedure has some advantages of returning to optimize the pocket but may not be an essential second step as excellent pocket control can be achieved with this surgery. The procedure is well suited to bilateral cases and in unilateral cases, the contralateral breast will require a reduction mammoplasty for symmetry. Nipple preservation is possible with this technique if oncologic parameters allow, usually based on the superior skin flap. The ability to use the de-epithelialized lower flap often negates the requirement for an acellular dermal matrix in this type of operation.

5.2 Skin sparing mastectomy

Many access incisions for skin-sparing mastectomy have been described. Fiberoptic lighting or headlamps are very useful to visualize dissection through minimal access incisions. Great care must be taken to avoid trauma by distension and diathermy injury to the skin flaps. Insulated instruments are helpful when diathermy dissection is used. After mastectomy, careful haemostasis is essential.

If the nipple is to be preserved, intra-operative frozen sections of the nipple base or nipple core to confirm a clear nipple margin of resection can be helpful. Histologically proven cancer extension into the nipple zone at the time of surgery is best treated by primary nipple resection. Preservation of the areola at nipple resection may be one option (Simmons, 2003). Delayed identification of nipple involvement when standard histological assessment is back may pose a dilemma on further management. The option of targeted radiotherapy may have a role and may be an alternative to the more common recommendation of secondary nipple excision.

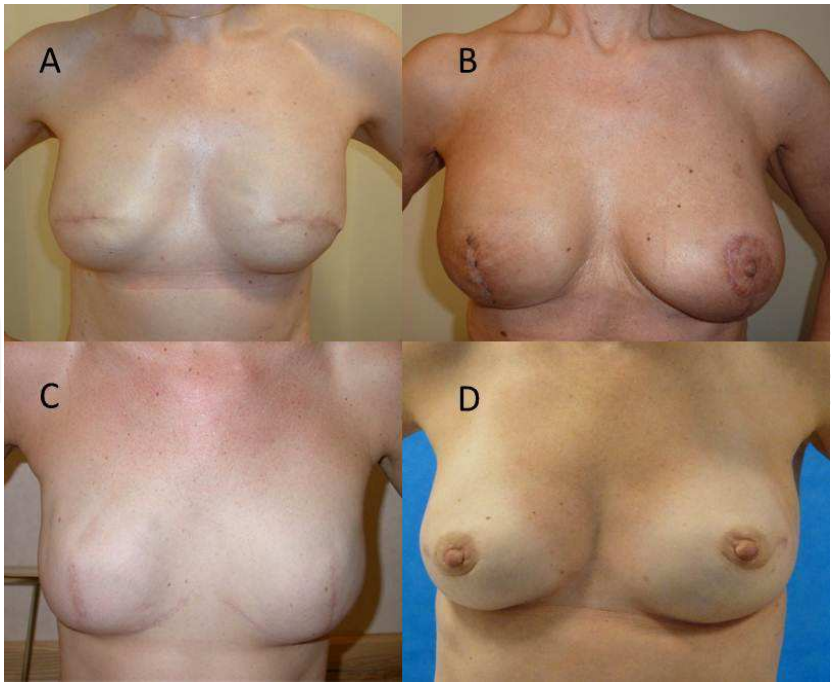


Fig. 4. Examples of skin incisions. A, transverse incisions. B, verticle incision. C, wise pattern excision without nipple preservation. D, peri-areolar incisions with lateral extension

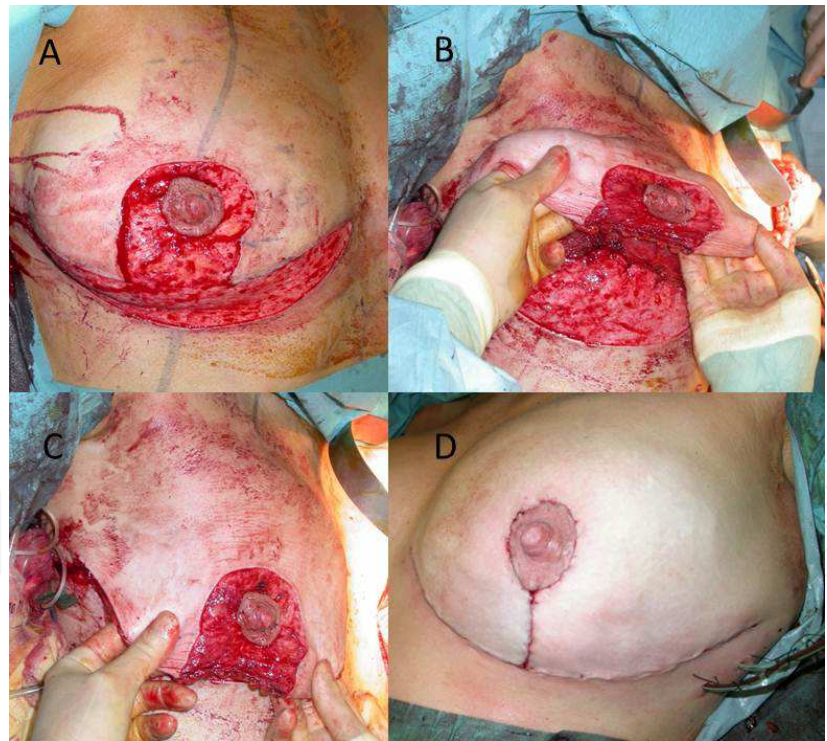


Fig. 5. Wise pattern skin excision for nipple sparing mastectomy. A, skin excision is performed and the marked areas are de-epithelialised. B, The de-epithelialised lower flap is disconnected and sutured to the inferior edge of pectoralis. C, The upper flap is drapped over the implant and the de-epithelialized lower flap. A butterfly needle has been inserted into the laterally sited injection port to allow adjustments to final inflation volume of the permanent expandable implant during pocket and skin closure. D, The incisions are closed

5.3 Creating the submuscular pocket

5.3.1 Raising pectoralis major

Following completion of the mastectomy, attention is turned to creation of a submuscular or submusculo-fascial pocket to house the implant or expander. To create a space in the submuscular plane, the fibres of pectoralis major are split 1cm lateral to the free lateral border. The inferior surface of pectoralis major is raised off the rib cage and the dissection taken medially taking care to preserve the anterior intercostal perforators as they emerge through the intercostal spaces close to the lateral sternal edge. The pectoralis major muscle should not be detached from the sternum. The upper border is taken to 1cm beyond the marked upper pole of the projected breast mound to ensure a gentle take off of the superior reconstructed breast. The inferior musculo-fascial border is created by disconnecting the attachment of pectoralis major to the ribcage from within the pocket. This takes the dissection on to a plane in continuity with the anterior rectus sheath, allowing the lower pole of the breast reconstruction to rise on the inferior implant surface. This dissection needs to be limited by the marking of the existing or new inframammary crease. Sparing the contents of the inframammary fold facilitates this dissection and avoids buttonholing of the thin fascia that can exist below the fibres of the pectoralis attachment.

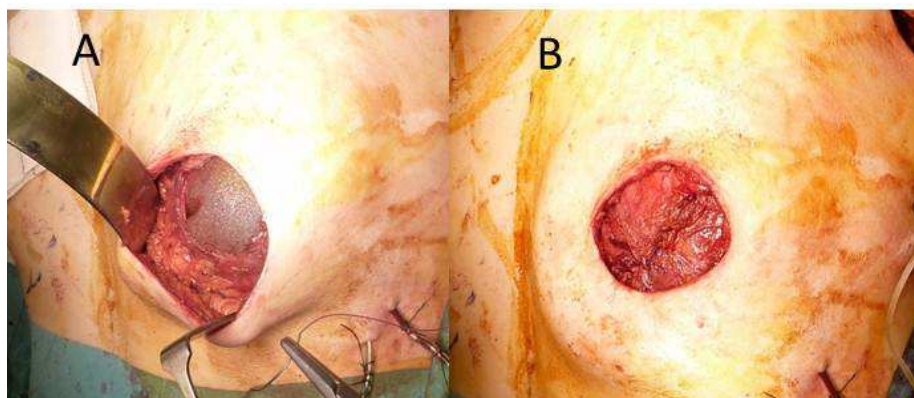


Fig. 6. Skin sparing mastectomy through a transverse incision. A, open pocket with implant visible. A butterfly needle has been inserted into the subcutaneous injection port laterally to allow adjustments to final inflation volume of the permanent expandable implant during pocket closure. B. Closed muscular pocket with the sutured edge of pectoralis major visible, the lateral border attached to serratus anterior

5.3.2 Providing cover for the inferior mammary space

When the inferior mammary musculo-fascial space does not provide adequate cover, the disconnected inferior border of pectoralis major may either be attached to the lower mastectomy flap by a series of interrupted sutures or alternatively holding sutures to the tough fascia of the inframammary crease like guide ropes, allowing the anterior surface of the muscle to adhere to the mastectomy skin flaps. In this situation, a two staged planned implant exchange is usually the preferred option enabling a return to optimise the implant pocket at a subsequent procedure. The development of acellular dermal matrices has made cover of the lower implant pole in this circumstance much simpler and interposition of a matrix sheet cut to size to interposition the required space between the free muscle border and the inframammary crease feasible as a one stage procedure.

5.3.3 The lateral pocket

The lateral musculo-fascial pocket is created by dissecting down from the lateral edge of the split pectoralis major fibres on to the lateral chest wall to find the anterior fibres of serratus anterior as they attach to the rib cage. Often this involves dividing some of the fibres at the lateral edge of pectoralis minor. The serratus anterior fibres can be freed to a varying extent to house the expander or implant. In general, in a planned two stage expansion, this dissection laterally can be limited to fit the footprint of the device, the true expansion process occurring post-surgery as an outpatient. In a planned one stage reconstruction, the dissection may need to be taken far back enough to free the anterior rib cage attachment of the serratus anterior to allow the lateral pocket to be raised fully to cover the fixed volume or expandable implant. Anatomically this extended lateral pocket consists of the lateral fibres of pectoralis major, the intervening fascia between pectoralis major and serratus anterior, and the anterior fibres of serratus anterior. The surgical dissection of the extended lateral pocket creation needs to be carefully undertaken as the fascial layer between the two muscles can be very thin.

5.3.4 Partial musculo-facial cover

Partial musculo-facial cover of the implant pocket is described, and is a simpler dissection. Advocates argue that placing the expander or implant in the subpectoral space alone allows for quicker operative time, less painful surgery, less discomfort after surgery (including during expansion) and better definition of the inframammary fold. The pectoralis major muscle is dissected free at its lateral border. The muscle is elevated and detached inferiorly at its insertion. Medially the dissection is carried to the parasternal region, but the muscle should not be detached from sternum. In particular, it is important not to detach the muscle along the sternal border superiorly, which would result in substantial dislocation of the muscle. The free inferior pectoralis major muscle should be tacked down to the lower mastectomy skin flap or to the inferior mammary crease as guide ropes as the muscle would otherwise retract resulting in poor implant cover. Spear et al. have found that placement of the implant partially under the mastectomy flap delivers predictable and cosmetically pleasing outcomes (Spear, 2004). This approach creates a breast that may be more easily placed on the chest wall and is unrestricted by the lower attachment of the pectoralis major to the rib cage. By avoiding disruption of the serratus anterior and rectus fascia, there is less postoperative pain as well as less pain during expansion. Because implant cover inferiorly is simply by the lower mastectomy flap, lower pole rippling can be more evident. It is important to minimize undermining of the inframammary fold and preserve adequate thickness of the lower mastectomy flap when possible.

5.3.5 Acellular dermal matrix

If an acellular dermal matrix sheet is to be used in the reconstruction, the dissection and creation of the submuscular pocket is simplified. The pectoralis major is freed at its lateral and inferior border, maintaining the attachment at the lower sternum. The selected acellular dermal matrix sheet is cut to size and the sheet sutured to interposition the area required to bridge the gap between the lower free muscle border and the inframammary crease. When placed in contact with viable tissue, the acellular matrix can become repopulated with circulating stem cells that differentiate into normal stromal components (endothelial cells,

fibroblasts etc), resulting in the turnover of matrix components and the integration of the matrix into host beds (Buinewicz, 2003; Menon, 2003). It is available in a range of sizes and thickness (1-16cm length, 1-6cm width and 0.18 to more than 1.8mm in thickness). The matrix is fairly pliable while maintaining good tensile strength. In the short term, the matrix acts as a barrier, adding a layer of protection under compromised skin flaps.

Examples of acellular dermal matrices available include AlloDerm (Lifecell, Branchburg, NJ) and Strattice (Lifecell, Branchburg, NJ). AlloDerm is an acellular dermal matrix derived from human cadaver skin that has been processed and sterilized to remove all cells and antigenic components leaving an extracellular matrix of collagen, elastin, hyaluronic acid, fibronectin, proteoglycans and vascular channels. AlloDerm requires to be rehydrated before use for 5 minutes in sterile normal saline or Ringer's lactate. Strattice is derived from pig skin and is maintained in a rehydrated state in the packaging. The Strattice sheet needs to be washed thoroughly in sterile saline before use to minimise patient contact with the preservation fluid. The combined arc length of the IMF and lateral fold is measured to determine the length of matrix needed. A fixed volume implant can often be used to create a planned one stage breast reconstruction. Expandable implants can also be used but it is unlikely that the acellular matrix itself enables post-operative expansion. Early expansion as an outpatient, however, facilitates expansion of the pocket as a whole and has been successfully used by the authors.

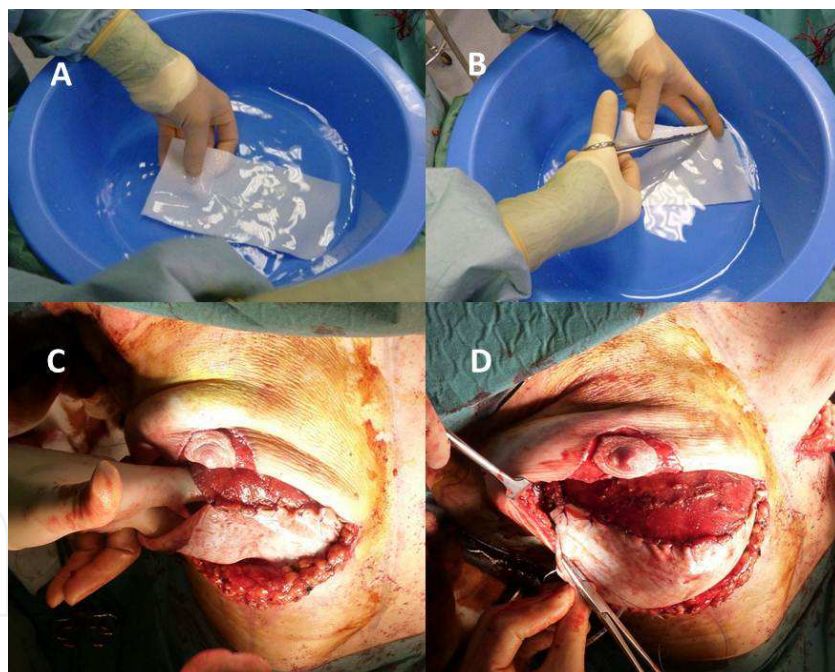

Fig. 7. (clockwise from top left): A, Strattice wash. B, Strattice cut to size. C, The superior pocket is being closed. D, Strattice sewn in with implant in pocket

5.3.6 Recreating the inframammary fold

The inframammary fold may need to be recreated by suturing the dermis or superficial fascia back down to the chest wall. A similar manoeuvre may be required to create the lateral breast fold by reattaching the advanced lateral skin flaps to the chest wall, which will prevent the tissue expander from sliding laterally or into the axilla.

5.4 Device placement and intraoperative filling

The key to successful implant reconstruction is the creation of a well-placed and adequate pocket. When a definitive fixed volume implant is planned in the immediate or delayed setting, sizers may be used intra-operatively to guide the final implant choice and position.

Expandable implants such as the Becker series (Mentor) and the Style 150 (Allergan) are designed to allow post-operative inflation. Inflation of the device creates projection on the footprint of the implant and allows correction of small volume discrepancies and projection compared with the contralateral breast. Expandable implants should not be used as tissue expanders as the tension they exert if expected to perform as expanders often are inadequate or result in implant distortion, filling at sites where expansion is easier, such as the upper pole. Expandable implants can be placed through minimal access incisions partly inflated with sterile saline and inflation completed when the device is secured in its final position within the pocket. Optimum fill is often 75% of the saline fill or more at the time of surgery and only a few post-operative inflations are generally required to achieve the desired final size (Gui, 2003). If expandable implants with remote ports are being used, the ports need to be sited and secured in an accessible subcutaneous position that does not interfere with underclothes. The lateral chest wall near the inframammary crease enables port removal with a well hidden scar, or alternatively placement adjacent to a scar that can be used for port removal such as an axillary incision avoids exposed scars when the ports are subsequently removed.

If a tissue expander is being used, accurate placement of the footprint creates the desired projection with subsequent inflation and therefore optimises the stretching of the overlying pocket tissue and skin in the expansion process. The expander is usually under filled with the intention of post-operative expansion in outpatients. The access ports can be integral or remote. Some of the integral ports with larger metallic components may not be MRI compatible or be perceived to interfere with radiotherapy planning and delivery. Choice of such expanders needs to be taken with the multidisciplinary approach to breast cancer management in mind.

Choice of sutures vary with surgeon preference. Absorbable sutures are commonly used to close the implant pocket and include PDS, Biosyn and Vicryl. Sutures to recreate the inframammary crease are more controversial as to whether a non-absorbable suture such as nylon or prolene is necessary. The important feature of recreation of the inframammary crease is well placed sutures to define the inframammary crease at the correct position on the chest wall. Even if absorbable sutures are used the healing process and the formation of a soft capsule often defines the final implant position including the inframammary crease.

5.5 Post-operative expansion

Expansion is started once pain has settled and viability of the skin flaps is assured. There are generally two schools of thought for tissue expansion. Those in favour of early expansion commence the inflation process a few days after surgery while others wait for several weeks. The quality of the overlying soft tissue and patient comfort are the primary determining factors. A 23g needle is inserted into the injection port under aseptic conditions in outpatients and 50 to 100 ml are injected once or twice weekly to reach the desired volume. Depending on the devices used, overexpansion and maintenance of this for several

weeks prior to volume reduction to the desired fill may help create pseudo-ptosis, remove skin folds and may decrease the incidence of capsular contracture. In women who require post-operative radiotherapy, some surgeons prefer to fully expand these patients prior to commencing radiation. A massaging protocol may be initiated and continued during the radiotherapy to minimize fibrosis.

The expander is exchanged for a permanent implant when radiotherapy changes have subsided and is often at least 6 months following the completion of radiation. In women not requiring radiotherapy, implant exchange can be performed a short interval after final expansion, commonly after one month. The inflation ports for expandable implants can be removed when the inflation process is complete and the ports are no longer required. Different implant manufacturers have their own methods described for easy and effective port removal.

5.6 Implant exchange (second stage)

The time period during which expansion occurs is a useful interval for patients to reflect on the effect the breast cancer diagnosis has had, be proactive in the reconstruction process and to be prepared for the final appearance of their breast reconstruction. Patients have the choice in decision making on breast size and position, shape and texture.

Tissue expansion is a two-stage process where the expander is exchanged for a definitive implant. The range of definitive fixed volume devices and the ability to return to optimise the implant pocket, breast form and scars at the secondary procedure has many advantages for better long term results. Other secondary procedures such as nipple reconstruction and attention to the contralateral breast for symmetry may need to be considered at the second or sometimes subsequent stages of the reconstruction process. Even when an expandable implant is placed with the intention of using it as a permanent device, secondary implant exchange may become necessary in a proportion of patients because of limitations in symmetry. This is often due to poor or differential expansion and capsule formation. One-stage surgery is a misnomer as secondary procedures are often required that are unrelated to implant exchange. In the context of expandable implants, this includes removal of the inflation port, nipple reconstruction and attention to the contralateral breast. Implant based surgery is also associated with a requirement for maintenance surgery over time.

Skin-sparing volume reducing surgery with use of the lower de-epithelialized mastectomy skin flap for lower pole implant cover has made planned one-stage surgery with reference to obviating the need to return to the implant pocket more common. The evolution of the role of acellular dermal matrices may influence the place of two stage surgery where planned implant exchange surgery has been the recommendation.

5.7 Delayed-immediate reconstruction

A two staged approach that bridges the immediate and delayed settings can be employed with the use of a temporizing implant and is suitable for a patient who desires an immediate breast reconstruction but is at a higher risk of requiring chest wall radiotherapy (Kronowitz, 2010). Following skin sparing mastectomy, a saline-filled tissue expander is inserted and serves as an adjustable scaffold to preserve the 3-dimensional shape of the skin envelope. If postmastectomy radiotherapy is not necessary, the expander is exchanged for a permanent

implant, either early to avoid delaying adjuvant therapy or upon completion of chemotherapy, to preserve the ptosis in the skin envelope. If radiotherapy is required, the expander is usually maintained at a constant volume to facilitate radiotherapy planning and delivery. Some surgeons and radiation oncologists recommend deflation of the expander before radiotherapy is commenced. The resultant flat chest wall facilitates delivery of 3-beam radiotherapy. When the breast skin has recovered from the radiotherapy, a period of at least three if not six months, a skin preserving delayed reconstruction is performed by removal of the expander and transfer of an autologous tissue flap. Sometimes, the quality of the skin may have recovered adequately post-radiotherapy to consider further implant based options. The pocket may need to be optimized by fat transfer procedures prior to the implant exchange.

5.8 Delayed reconstruction

A delayed reconstruction usually requires the placement of a tissue expander to stretch the pre-existing mastectomy flaps. Delayed insertion of a tissue expander is usually a safe procedure when good quality soft tissue is available, with a reduced risk of mastectomy skin flap ischaemia, and wound healing complications. Delayed reconstruction also eliminates the uncertainty of unplanned postoperative adjuvant radiotherapy affecting a definitive reconstruction and allows more flexibility with scheduling. Delayed reconstruction however leaves patients temporarily at least without a breast mound, is usually associated with longer scars that may not be optimal and loss of skin. Tissue expansion to create a pocket must take into account whether the expansion will create sufficient skin stretch to match the contralateral side and what adjustments if necessary to both sides may become necessary to achieve symmetry.

Preoperative markings are performed with the patient in an upright position. The contralateral breast inframammary crease is outlined and the transverse base diameter and vertical base height is measured. A template may be used to transfer these measurements in the mastectomy side.

Intraoperatively, a varying length of the existing mastectomy incision is reopened for adequate access. The inferior lateral border of the pectoralis major muscle is identified and a subpectoral dissection initiated. Meticulous haemostasis is performed. Dissection beneath the pectoralis major muscle continues superiorly to the extent of the preoperative markings but not beyond to limit unwanted superior expansion and to direct expansion inferiorly. The submuscular dissection continues medially and inferiorly partially dividing the origin of the pectoralis major muscle along the parasternal border from the second rib to the fourth rib. This partial release of the muscle improves anterior projection and cleavage definition during expansion. Inferiorly the pocket dissection switches to the subcutaneous plane just above the serratus anterior, external oblique and rectus abdominis fascia. This dissection continues to the level of the marked inframammary crease. Complete release of any restricting scar or fascia extending nearly to the dermis at the desired IMF location will aid in the passive creation of a distinct fold during the expansion process. The subcutaneous positioning of the inferior portion of the expander is reliably safe in a delayed reconstruction because flap ischemia is not usually a concern. This subcutaneous placement allows easy expansion with improved projection in the inferior pole.

An appropriate expander is selected and any air within the device removed. Precise placement of the expander stretches the required soft tissue without unnecessary overexpansion. The expander is then partially filled with some saline so that the inferior border of the device rests at the level of the desired inframammary crease height. A drain is then placed in the pocket before closure of the mastectomy incision in layers. The expander may then be further filled to the maximum volume the soft tissues will allow.



Fig. 8. Postoperative appearances followed delayed breast reconstruction following tissue expansion and implant exchange. Radiotherapy related skin changes are still visible.

Expansion can commence early, and often within a few weeks if there are no concerns with wound healing or skin flap health. Saline is added to the expander to reach the end point of moderate soft tissue tension. This should result in minimal patient discomfort if any. Expansion continues every 2 to 4 weeks until the desired maximum point of lower pole projection is obtained. The final volume within the expander should closely match the size of the opposite breast, limiting overexpansion to 10-15%. Once full expansion has been achieved, the expander should remain in place for at least one month. This allows time to achieve a mature, pliable capsule. This period of maximum expansion also prevents any recoil of the soft tissue envelop once the expander is removed. The second stage involves exchanging the expander for a permanent implant using techniques previously described for the second stage of immediate reconstructions.

6. Implant reconstruction in the irradiated breast

Radiation has significant negative effects on all types of breast reconstruction but this effect is most marked in implant based reconstructions. Irradiated tissues fibrose and contract with time, causing an apparent increasing hardness (capsular contracture) of the implant based reconstruction. Patients who present with advanced diseases or with heavily involved axillary nodes may require chest wall radiotherapy following mastectomy so are therefore less favourable candidates for implant reconstructions. Several studies have shown capsular formation rates of between 11 to 68% with varying lengths of follow-up.

Previous chest wall radiation is a relative contraindication to tissue expansion as a delayed procedure. Depending on the timing technique and quantity of radiation administered, the soft tissues can be unyielding. Expansion under these circumstances is therefore difficult with an increased risk of complications.

Study	n	n RT	% capsule formation	
			No RT	RT
Tallet 2003	77	55	0	16
Cordeiro 2004	143	68	40	68
Clough 2004	334	28		11 (2y) 15 (5y)
Collis 2000	197	32		12
Behranwala2006	136	44	14	39

Table 3. Studies evaluating capsule formation after radiotherapy in implant IBR

A study from the Royal Marsden Hospital found capsule formation in 38.6% of reconstructed breasts using a permanent expander implant followed by radiotherapy compared to 14.1% of reconstructed breasts not needing post mastectomy radiotherapy at a median follow-up of 4 years (Behranwala, 2006). At univariate analysis, radiotherapy emerged as the only variable related to capsule formation ($p<0.001$) with significantly shorter time to capsule formation in immediate breast reconstructions that received post mastectomy radiotherapy. These results clearly demonstrate the relationship between radiotherapy post immediate implant breast reconstruction and capsular formation. However, as more than 60% of patients do not get capsules despite radiotherapy at 4 years, the use of implant assisted tissue expansion techniques still presents a viable reconstructive option in selected cases.

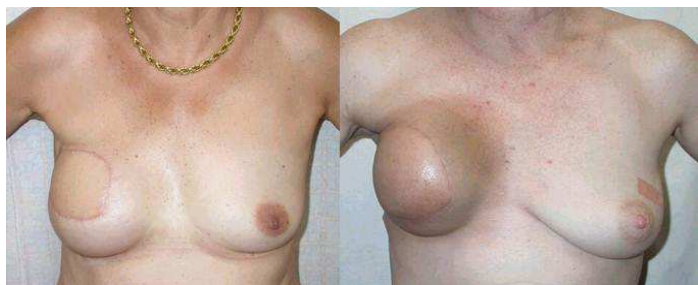

Fig. 9. Implant assisted LD reconstruction A. before post mastectomy chest wall radiotherapy. B, after post mastectomy chest wall radiotherapy.

7. Potential complications of implant based reconstructions

7.1 Rupture

Rupture of silicone filled implants presents two main areas of concern: release of silicone gel into the body and failure of the device. While there is no correlation between connective tissue disease and breast implants, a local inflammatory response to a silicone leak can result in the formation of silicone granulomas. These present as discrete breast or axillary node masses and can be mistaken for recurrence.

The rates of implant rupture range from 11 to 77% depending on the study design, generation of implant used and the age of the implant at time of study. Grouping of all devices to provide a single rupture rate is also not an accurate estimation of rupture rates which depend on type of implant where variables include shell thickness, elastomer type, surface texture and shape. True implant rupture rates are associated with time from implantation, particularly in the case of earlier generation devices which are associated with

a higher rupture rate. Almost all studies have a self-selection bias of patients who present with signs consistent with implant rupture. Devices were subsequently examined for rupture and we would therefore expect a higher rate of rupture when compared to the general implant population. Most studies have used radiologic imaging to determine device integrity where overall accuracy may be limited by sensitivity or specificity. MRI imaging for instance has a high false positive rate of rupture. Allergan is conducting a 10 year Core study to assess the safety and effectiveness of their rounded implants in 715 patients. The rate of rupture is compared between patients undergoing scheduled MRIs at years 1,3,5,7 and 9 years (to screen for silent ruptures) and those not scheduled for routine MRI assessments. The 4 year results have now been reported and show an implant rupture rate of 2.7% in the MRI cohort group compared to a 0.4% rupture rate in augmented patients in the non-MRI cohort. No ruptures were reported in the 98 patients who had undergone primary implant breast reconstruction in the 4 year time period (Inamed, 2005).

Author	Infection (%)	Haematoma (%)	Seroma around implant (%)	Native skin necrosis (%)	Implant loss or extrusion (%)	Difficulty expansion (%)	Valve failure (%)	Deflation (%)
Mansel 1986	7.9 8.3			2.6	16.7 23.7			
Schuster 1990	5.4	3.6	7.1	12.5	7.1			
Hunter-Smith 1995	3.7	0	1.9	3.7	1.9		1.9	1.9
Ramon 1997	9.6	5.8		1.9	5.8	11.5	3.8	3.8
Spear 1998	3.5	1.2		5.3	10.5			4.0
Slavin 1998	2.0	0		21.6	3.9			
Peyser 2000	4.2	1.4		9.9			1.4	
Gui 2003	6.2	1.6	0	3	3.9	0	0	0

Table 4. Complications from implant reconstructions, comparison of published reports (modified from Gui, 2003)

7.2 Infection

The most serious threat to an implant based breast reconstruction is infection. The reported incidence is between 2% and 9.6%(see table 4). The first signs and symptoms may appear as early as 5 days or as late as 5 weeks after surgery. Commonly infections with staphylococcus aureus, staphylococcus epidermidis or pseudomonas appear within 5 to 7 days with dramatic symptoms suggestive of abscess formation. Diffuse redness, swelling, tenderness and systemic symptoms of fever and malaise are common. Attainment of culture material is helpful and intravenous antibiotics with hospital surveillance is recommended. If no improvement or worsening symptoms, immediate exploration is indicated in an attempt to downstage or control the process. In the presence of gross pus and inflammation at exploration, it is probably best to remove the implant, debride clearly infected tissues, thoroughly lavage the pocket, place a drain, and close the wound and cover with antibiotics. If the operative findings are favourable, it may be possible to salvage or exchange the implant after adequate cleaning of the pocket. Adequate soft tissue cover is essential with

close surveillance and appropriate antibiotic cover, guided by microbiology culture and sensitivity. If salvage strategies fail, the device needs to be removed and further reconstructive attempts delayed for a reasonable period for tissue to recover, usually at least 6 months. Mycobacterium infection may present differently and may be suspected following repeated negative cultures. Signs and symptoms may be delayed for 3-5 weeks after surgery and are mostly local and minor, often consisting of a clear discharge from the incision with no systemic symptoms.

7.3 Capsular contracture

Symptomatic capsular contracture occurs in 3 to 5% of patients (Mandrekas 1995). Retaining the filling port permanently allows some surgeons to treat early signs by over inflation of the implant at the onset of symptoms and maintaining the over expanded state for 2 to 3 months, followed by a return to the recommended fill range. As capsular contracture progresses, pocket revision may become necessary. Modest capsule formation may be treated by capsulotomy but often the implant capsule is thick and may need to be excised by capsulectomy. If soft tissue coverage is inadequate, consideration needs to be made as to whether this could be improved by increasing the subcutaneous adiposity by fat transfer, implant cover by incorporation of an acellular dermal matrix or autologous tissue such as using a latissimus flap. In cases of recurrent capsule formation, especially early or after radiotherapy, an autologous component for implant cover may become necessary or an elective strategic change to autologous reconstruction without implant would avoid further capsule related complications.

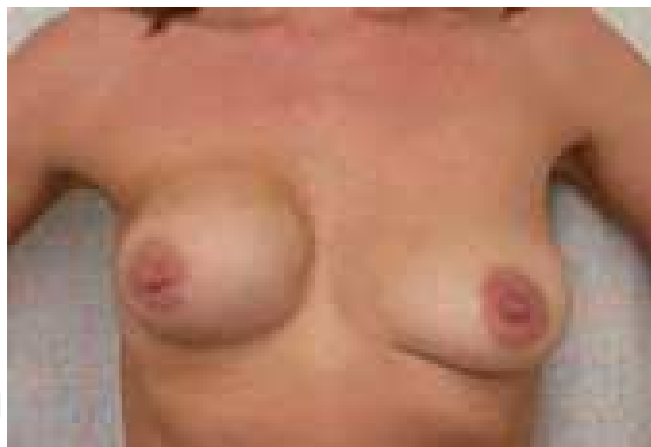

Fig. 10. Grade 4 capsule contracture

7.4 Scalloping and rippling

Over or under filling of the device may cause visible and palpable wrinkling of the outer envelope. This becomes even more obvious when thin, loose or irradiated soft tissue fail to provide adequate padding. Irregular visible or palpable implant edges mostly in the upper inner quadrant of the reconstructed breast may be avoided by conforming to the saline fill range recommended by the manufacturer. Another site at which rippling may be more prominent is the inferior pole of the reconstructed breast in a dual plane approach where the pectoralis major covers the upper pole of the implant while the lower pole lies in the subcutaneous plane.

Textured surfaces that provide tissue ingrowth also result in tissue adhesion to the anterior implant pocket. The resultant tethering may contribute to visible and palpable wrinkling of the tissue overlying the implant. A loose pocket or a smooth surface on the other hand does not eliminate this problem as elasticity of the overlying skin may similarly result in a wrinkled appearance. Other solutions that could be considered include skin tightening, fat transfer, internal capsulorrhaphy, incorporation of an acellular dermal matrix or the addition of a latissimus dorsi muscle flap.

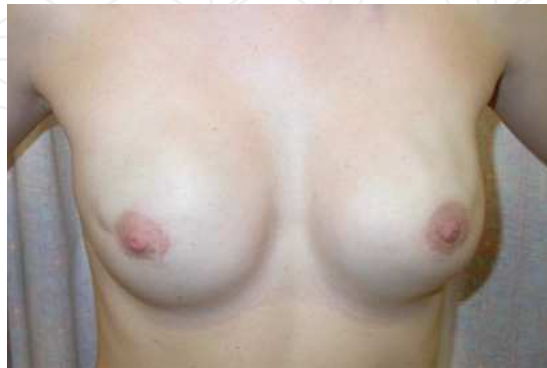

Fig. 11. Left upper pole rippling following nipple sparing mastectomy

7.5 Skin and nipple ischaemia and necrosis

Compromise to the blood supply of the mastectomy skin flaps or to a preserved nipple can result in tissue ischaemia and necrosis. The risk of skin and nipple ischaemia is elevated when skin sparing techniques have been used because of the increased length of the mastectomy flaps from the perforating blood vessels supplying the skin. Care must be taken to ensure that the flaps are not compromised. Supportive measures in the immediate post-operative period such as warming (with a warming blanket and warmed intravenous fluids), nursing in a supine position, correction of profound anaemia and avoidance of hypotension may reduce the incidence of skin and nipple ischaemia. Superficial necrosis may be managed conservatively with supportive measures in the first instance and then with appropriate dressing and wound care. Infection, inflammation and skin necrosis should be aggressively treated either with antibiotics or excision of the necrotic skin with primary closure. It is particularly important to excise and repair any necrotic skin early as if necrotic tissue is left for longer, the risk of a wound infection increases significantly.

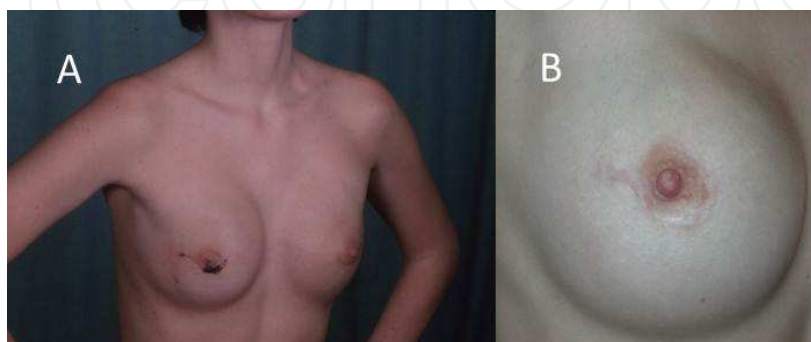


Fig. 12. A, partial nipple necrosis following nipple sparing mastectomy. B, Close-up view of nipple-areolar complex showing recovery of necrotic areas

8. Conclusion

Implant based breast reconstruction remains the most common method utilized to reconstruct a breast after mastectomy for cancer. Implant reconstruction has advanced through the years with better devices and improved surgical techniques. Skin-sparing volume reducing procedures that utilize de-epithelialized skin for implant cover have broadened the scope of patients suitable for implant based breast reconstruction beyond the traditional concept of slim to moderately built women with modest breast size and minimal ptosis. The further development of acellular dermal matrices and fat transfer techniques will see further evolution of patients suitable for implant based techniques.

Autologous breast reconstruction is an option for many women. The choice of breast reconstruction depends on multiple factors when selecting the best reconstruction option for a patient. One consideration is the level of patient motivation and the patient's willingness to undergo complex or extensive procedures, including the risk of failure or comorbidities associated with those procedures. The magnitude of surgery, the length of recovery, potential complications, resultant extensive scarring, and potential functional loss associated with some forms of autologous breast reconstruction may be a valid reason why patients opt for implant based surgery, recognising that maintenance surgery is more likely. Breast reconstruction using expanders and implants offers an excellent opportunity to achieve high quality results in breast reconstruction.

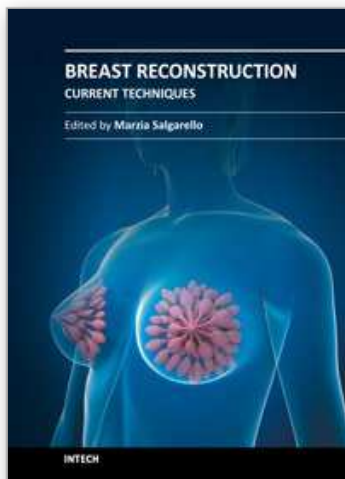
Breast reconstruction should be tailored to meet the individual needs of patients. The options available and the decision making process should be fully discussed and a balance of benefits and risks used in the final analysis of patient choice. Units that offer breast reconstruction should have access to the range of options in current practice to meet these needs.

9. References

- American Society of Plastic Surgeons. (2010). Report of the 2010 Plastic Surgery Statistics, In: ASPS website, Accessed 24th July 2011:
<http://www.plasticsurgery.org/Documents/news-resources/statistics/2010-statisticss/Top-Level/2010-US-cosmetic-reconstructive-plastic-surgery-minimally-invasive-statistics2.pdf>
- Beasley, M.E. & Ballard, A.R. (1990). Immediate breast reconstruction: a comparison of techniques utilizing the pedicled TRAM and tissue expanders. *Proceedings of the annual meeting of the American Association of Plastic Surgeons*, Hot Springs, Va, May, 1990
- Behranwala, K.A., Dua, R.S., Ross, G.M., et al. (2006). The influence of radiotherapy on capsule formation and aesthetic outcome after immediate breast reconstruction using bi-dimensional anatomical expander implants. *British Journal Plast Surg*, 59, pp. 1043-51
- Buinevicz, B. & Rosen, B. (2004). Acellular cadaveric dermis (AlloDerm): a new alternative for abdominal hernia repair. *Ann Plas Surg*, 52, pp.188
- Carlson, G.W., Bostwick, J.B., Toncred, M.S., et al. (1997). Skin-Sparing Mastectomy: Oncologic and Reconstructive Considerations. *Annals of Surgery*, 225, pp.570-578

- Clough K.B., Thomas S.S., Fitoussi A.D., et al. (2004). Reconstruction after conservative treatment for breast cancer: cosmetic sequelae classification revisited. *Plast Reconstr Surg*, 114, pp.1743-53.
- Collis N. & Sharpe D.T. (2000). Breast reconstruction by tissue expansion. A retrospective technical review of 197 two-stage delayed reconstructions following mastectomy for malignant breast disease in 189 patients. *Br J Plast Surg*, 53, pp. 37-41
- Cordeiro P.G., Pusic A.L., Disa J.J., et al. (2004). Radiation after immediate tissue expander/implant breast reconstruction: outcomes, complications, aesthetic results, and satisfaction among 156 patients. *Plast Reconstr Surg*, 113, pp 877-81
- Gui, G.P.H., Tan, S-M., Faliakou, E.C., et al. (2003). Immediate breast reconstruction using biodimensional anatomical permanent expander implants: a prospective analysis of outcome and patient satisfaction. *Plast Reconstr Surg*, 111, pp.125-138
- Hunter-Smith D.J. & Laurie S.W. (1995). Breast reconstruction using permanent tissue expanders. *Aust N Z J Surg*. 65, pp. 492-5
- Inamed (2005) Summary of safety and effectiveness data, silicone gel filled breast implants, FDA website, accessed on 24th July 2011, available http://www.accessdata.fda.gov/cdrh_docs/pdf2/P020056b.pdf
- Kronowitz, S.J. (2010). Delayed-immediate breast reconstruction: technical and timing considerations. *Plast Reconstr Surg*, 125, pp 463-74
- Mandrekas, A.D., Zambacos, G.J. & Katsantoni, P.N. (1995). Immediate and delayed reconstruction with permanent expanders. *Br J Plast Surg*, 48, 572
- Mansel R.E., Horgan K., Webster D.J., et al. (1986). Cosmetic results of immediate breast reconstruction post-mastectomy: a follow-up study. *Br J Surg.*, 73, pp. 813-6.
- Menon, N.G., Rodriguez, E.D., Byrnes, C.K., et al. (2003). Revascularization of human acellular dermis in full-thickness abdominal wall reconstruction in the rabbit model. *Ann Plast Surg*, 50, pp. 523
- Peyser P.M., Abel J.A., Straker V.F., et al. (2000). Ultra-conservative skin-sparing 'keyhole' mastectomy and immediate breast and areola reconstruction. *Ann R Coll Surg Engl*. 82, pp. 227-35
- Ramon Y., Ullmann Y., Moscona R., et al. (1997). Aesthetic results and patient satisfaction with immediate breast reconstruction using tissue expansion: a follow-up study. *Plast Reconstr Surg*. 99, pp. 686-91
- Rosen, P.B, Jabs, A.D., Kister, S.J., et al. (1990). Clinical experience with immediate breast reconstruction using tissue expansion or transverse rectus abdominis musculocutaneous flaps. *Ann Plast Surg*, 25, pp. 249
- Schuster RH, Rotter S, Boonn W., et al. (1990). The use of tissue expanders in immediate breast reconstruction following mastectomy for cancer. *Br J Plast Surg.*, 43, pp. 413-8.
- Simmons, R..M., Hollenbeck, S.T. & Latrenta, G.S. (2003). Areola-sparing mastectomy with immediate breast reconstruction. *Ann Plast Surg*, 51, pp 547-51
- Slavin S.A., Schnitt S.J., Duda R.B., et al. (1998). Skin-sparing mastectomy and immediate reconstruction: oncologic risks and aesthetic results in patients with early-stage breast cancer. *Plast Reconstr Surg*. 102, pp. 49-62
- Spear S.L. & Majidian A. (1998). Immediate breast reconstruction in two stages using textured, integrated-valve tissue expanders and breast implants: a retrospective

- review of 171 consecutive breast reconstructions from 1989 to 1996. *Plast Reconstr Surg.* 101, pp. 53-63
- Spear, S.L. & Pelletiere, C.V. (2004). Immediate breast reconstruction in two stages using textured, integrated-valve tissue expanders and breast implants. *Plast Recons Surg*, 113, pp. 2098
- Tallet A.V., Salem N., Moutardier V., et al. (2003) Radiotherapy and immediate two-stage breast reconstruction with a tissue expander and implant: complications and esthetic results. *Int J Radiat Oncol Biol Phys*, 57, pp. 136-142



Breast Reconstruction - Current Techniques

Edited by Prof. Marzia Salgarello

ISBN 978-953-307-982-0

Hard cover, 276 pages

Publisher InTech

Published online 03, February, 2012

Published in print edition February, 2012

Breast reconstruction is a fascinating and complex field which combines reconstructive and aesthetic principles in the search for the best results possible. The goal of breast reconstruction is to restore the appearance of the breast and to improve a woman's psychological health after cancer treatment. Successful breast reconstruction requires a clear understanding of reconstructive operative techniques and a thorough knowledge of breast aesthetic principles. Edited by Marzia Salgarello, and including contributions from respected reconstructive breast plastic surgeons from around the world, this book focuses on the main current techniques in breast reconstruction and also gives some insight into specific topics. The text consists of five sections, of which the first focuses on the oncologic aspect of breast reconstruction. Section two covers prosthetic breast reconstruction, section three is dedicated to autogenous breast reconstruction, and section four analyzes breast reconstruction with a fat graft. Finally, section five covers the current approaches to breast reshaping after conservative treatment.

How to reference

In order to correctly reference this scholarly work, feel free to copy and paste the following:

Sarah S.K. Tang and Gerald P.H. Gui (2012). Implant and Implant Assisted Breast Reconstructions, *Breast Reconstruction - Current Techniques*, Prof. Marzia Salgarello (Ed.), ISBN: 978-953-307-982-0, InTech, Available from: <http://www.intechopen.com/books/breast-reconstruction-current-techniques/implant-and-implant-assisted-breast-reconstruction>

INTech
open science | open minds

InTech Europe

University Campus STeP Ri
Slavka Krautzeka 83/A
51000 Rijeka, Croatia
Phone: +385 (51) 770 447
Fax: +385 (51) 686 166
www.intechopen.com

InTech China

Unit 405, Office Block, Hotel Equatorial Shanghai
No.65, Yan An Road (West), Shanghai, 200040, China
中国上海市延安西路65号上海国际贵都大饭店办公楼405单元
Phone: +86-21-62489820
Fax: +86-21-62489821

© 2012 The Author(s). Licensee IntechOpen. This is an open access article distributed under the terms of the [Creative Commons Attribution 3.0 License](https://creativecommons.org/licenses/by/3.0/), which permits unrestricted use, distribution, and reproduction in any medium, provided the original work is properly cited.

IntechOpen

IntechOpen