

# We are IntechOpen, the world's leading publisher of Open Access books Built by scientists, for scientists

6,900

Open access books available

185,000

International authors and editors

200M

Downloads

Our authors are among the

154

Countries delivered to

TOP 1%

most cited scientists

12.2%

Contributors from top 500 universities



WEB OF SCIENCE™

Selection of our books indexed in the Book Citation Index  
in Web of Science™ Core Collection (BKCI)

Interested in publishing with us?  
Contact [book.department@intechopen.com](mailto:book.department@intechopen.com)

Numbers displayed above are based on latest data collected.  
For more information visit [www.intechopen.com](http://www.intechopen.com)



# The Accuracy of Ultrasound in the Pre-Operative Localisation of Parathyroid Lesions in Primary Hyperparathyroidism: A Review of the Literature

S. Alford<sup>1</sup>, W. Barber<sup>1</sup>, G. Cheung<sup>2</sup> and K. Thoires<sup>1</sup>

<sup>1</sup>*School of Health Sciences, University of South Australia*

<sup>2</sup>*Flinders Medical Centre, Bedford Park, South Australia  
Australia*

## 1. Introduction

Primary hyperparathyroidism (PHPT) is caused by excessive autonomous secretion of parathormone (PTH), usually as a result of a parathyroid adenoma (80-85%), and less frequently due to parathyroid gland hyperplasia (15%-20%) or carcinoma (1%) (Kaplan et al. 1991). Patients often suffer from mild subjective symptoms such as weakness and tiredness, but if untreated, symptoms progress to include dementia, depression, peptic ulcer disease, pancreatitis, constipation, renal calculi, and diffuse bone and joint pain (Clark 2003).

PHPT can be diagnosed by detecting elevated PTH and blood calcium levels (Carlier et al. 2008). The most effective treatment or cure for PHPT is parathyroidectomy, the surgical removal of the affected parathyroid glands. Surgery has traditionally been performed using a traditional bilateral neck exploration (BNE), but in recent times, minimally invasive parathyroidectomy (MIP) has replaced this approach as a first line surgical choice in the United States, Australia, and mainland Europe (Palazzo 2004). MIP compared to BNE neck exploration has comparable clinical outcomes and complications, but can reduce length of hospital stays and operating times by 50% (Udelsman 1999). Successful cure for PHPT using MIP depends on consistently reliable methods for localizing parathyroid lesions, so the surgeon can direct the dissection to the site of the abnormal parathyroid gland (Johnson et al. 2007). The success of the resection can be assessed by means of intraoperative intact parathyroid hormone (IOPTH) assay (Quiros et al. 2004). Surgeons experienced in MIP can explore both the upper and lower glands on the same side of the neck from a slightly enlarged incision if the localization study has not identified the lesion correctly, and in cases where preoperative localization has failed to identify a gland on the contralateral side, the surgeon may proceed to BNE.

The Nuclear Medicine (NM) Technetium 99m (Tc<sup>99m</sup>) sestamibi examination is a common imaging choice to preoperatively localize diseased parathyroid glands (Levy et al. 2011). The Tc<sup>99m</sup> sestamibi examination involves the injection of a radiopharmaceutical, made up of a radioisotope (Tc<sup>99m</sup>) and a pharmaceutical tracing agent (sestamibi). A dual phased technique is used, where a gamma camera detects the radiation emitted from within the

patient in an early phase at 15–30 minutes (Figure 1) and in a late phase at 2–4 hours (Figure 2) after intravenous administration of the radioisotope. Diseased parathyroid glands are detected based on the time-related differential washout of radioactivity between the thyroid gland and a parathyroid lesion. In diseased parathyroids there is a retention of Tc-99m sestamibi within the parathyroid in the second phase (Nguyen 1999). The disadvantages of NM localization examinations include that they use ionizing radiation, require an injection to the patient of a radiopharmaceutical (Levy et al. 2011) which carries a slight risk of adverse reactions (Mujtaba et al. 2007). NM studies also require a high level of patient cooperation to remain still for extended periods, which may be difficult in elderly, ill or confused patients. This is particularly important when integrated single-photon-emission computed tomography and computed tomography (SPECT/CT) systems (Figure 3), which are prone to misregistration errors due to patient movement (Bybel et al. 2008) are used to improve sensitivity.

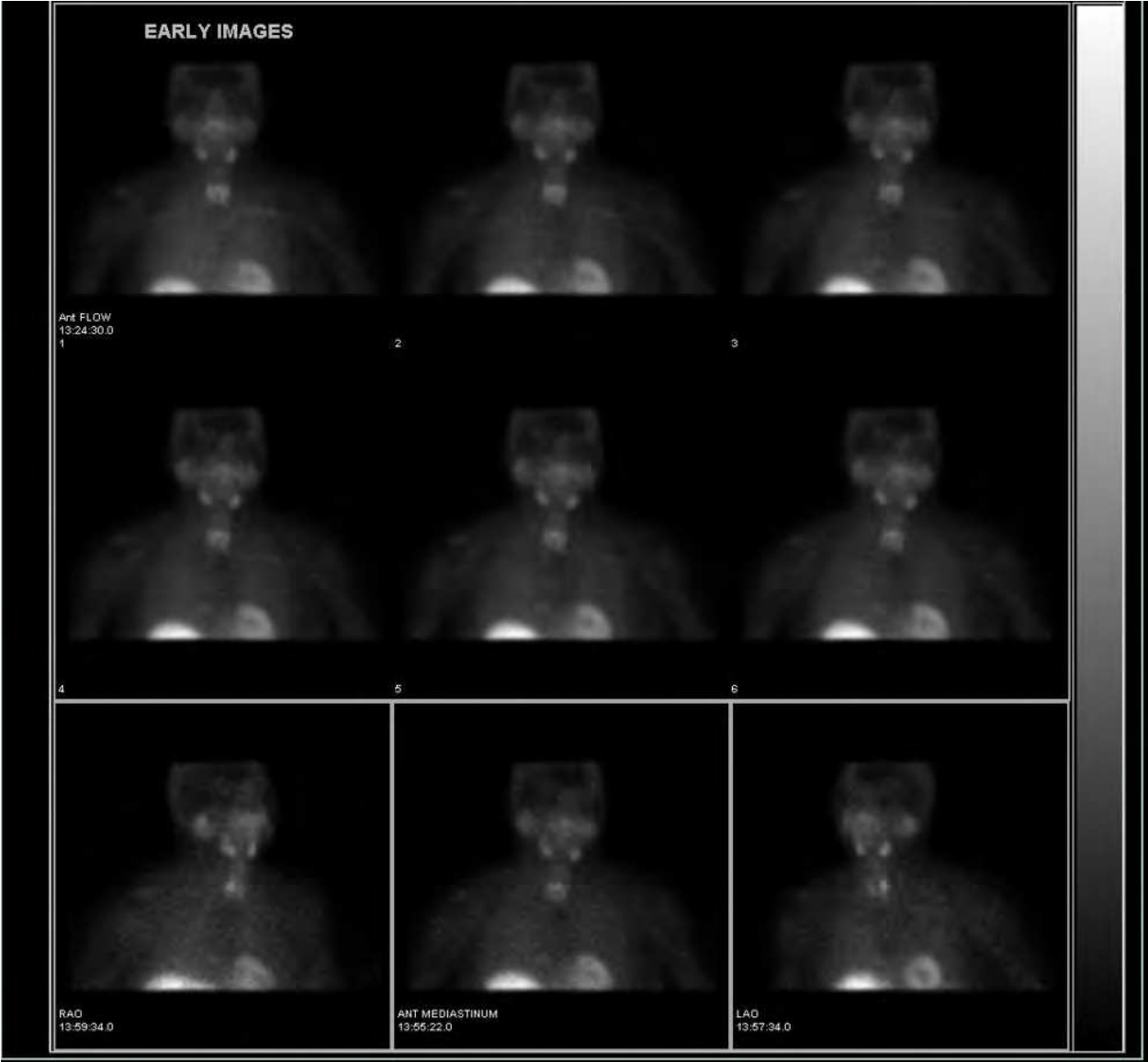


Fig. 1. Early phase parathyroid Nuclear Medicine scan. Image courtesy of Royal Adelaide Hospital, Department of Nuclear Medicine, PET & Bone Densitometry

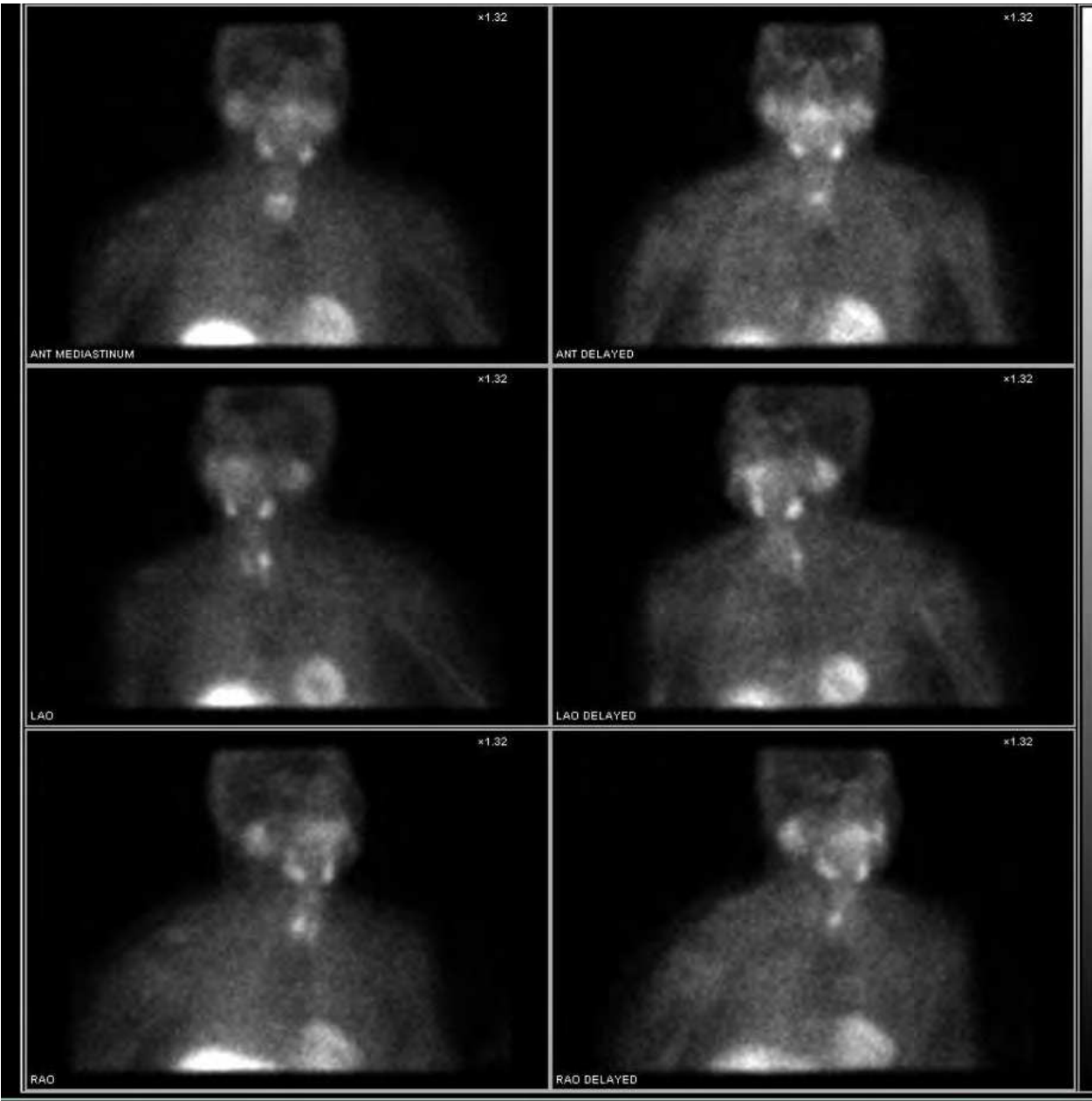


Fig. 2. Late phase parathyroid Nuclear Medicine scan demonstrating parathyroid lesion in superior mediastinum. Image courtesy of Royal Adelaide Hospital, Department of Nuclear Medicine, PET & Bone Densitometry

Parathyroid ultrasound (US) has emerged as an alternative or complementary localization procedure to NM techniques because it does not use ionizing radiation or an injection to the patient (Levy et al. 2011), and has greater tolerance for patient movement. US is considered to be one of the most cost-effective, quick and easy imaging modalities, but it has demonstrated variable performance over time and between varying clinical environments (Whiting et al. 2003; Mihai et al. 2009) when localizing parathyroid lesions. Older studies, such as those by Liou et al. (1996) have shown US to have sensitivities and specificities up to 75 per cent and 95 per cent respectively, compared to Tc<sup>99m</sup> sestamibi which showed 87.5 per cent sensitivity and 100 per cent specificity.

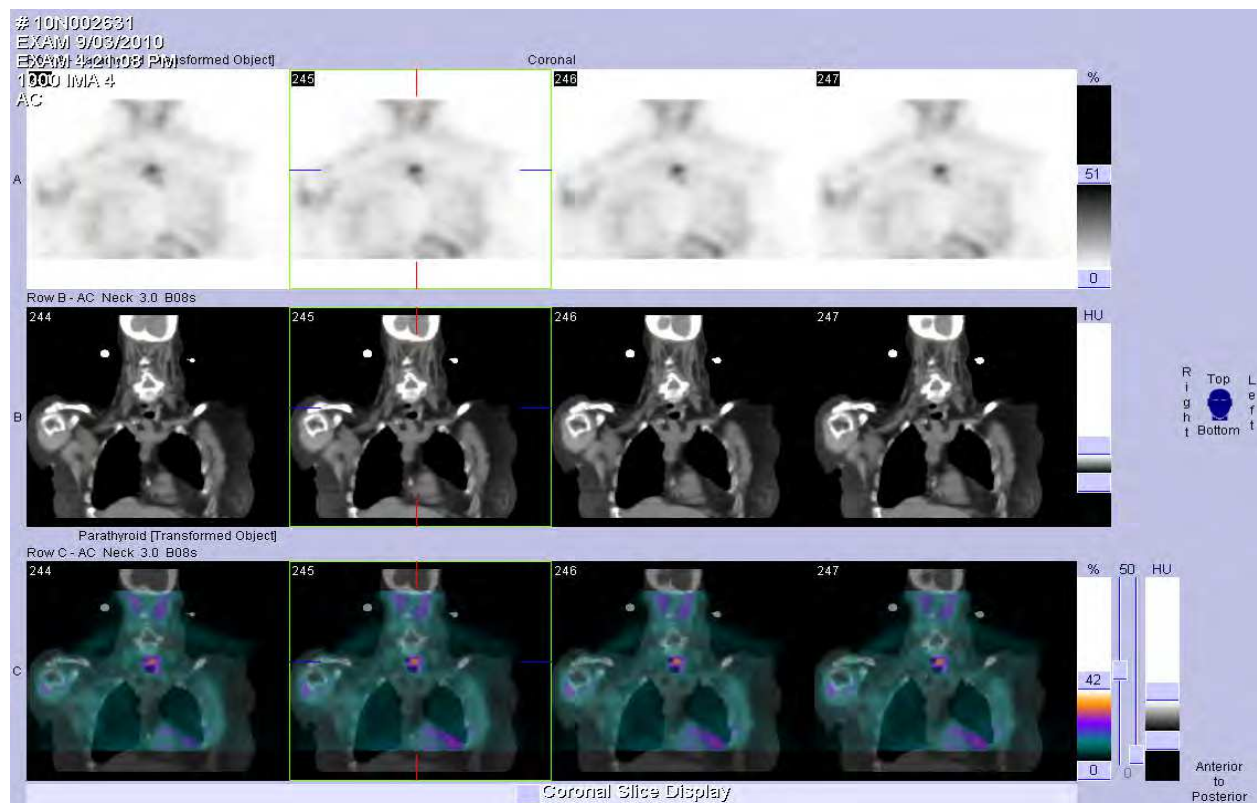


Fig. 3. SPECT/CT parathyroid Nuclear Medicine scan demonstrating parathyroid lesion in superior mediastinum. Image courtesy of Royal Adelaide Hospital, Department of Nuclear Medicine, PET & Bone Densitometry

Variability in the performance of US to localize parathyroid lesion may be due to the variability of the anatomical location of the glands themselves. The possibility of ectopic glands and variation in the number of glands presents challenges for US (Yeh et al. 2006), as the field of view in each image is small and requires a careful and thorough scanning technique. Ectopic glands may be obscured in US examinations by bony and air filled structures that impede US penetration. For example, retro-sternal, retro-oesophageal and retro-tracheal glands are difficult to localize with US. Intra-thyroid lesions (Figure 4), which are rare, may also be difficult to localize because they are difficult to differentiate from thyroid nodules (Kobayashi et al. 1999).

The US equipment and sonographer expertise and protocols also have the potential to influence the accuracy of the ultrasound examination (Mihai et al. 2009). US requires comprehensive and reproducible protocols as it is very operator-dependent, and localization accuracy may vary according to the level of experience of the sonographer (Yeh et al. 2006). The size of diseased glands may be very small and therefore the successful localization of very small structures with US may be constrained by the resolution of the ultrasound system (Lo et al. 2007). Older US units can be compromised by image quality compared to modern equipment, and this may have contributed to the lower rates of accuracy reported in older studies (Levy et al. 2011). The use of colour Doppler (Figure 6) to identify enlarged feeding arteries to parathyroid adenomas has also been reported to increase detection rates (Reeder et al. 2002).

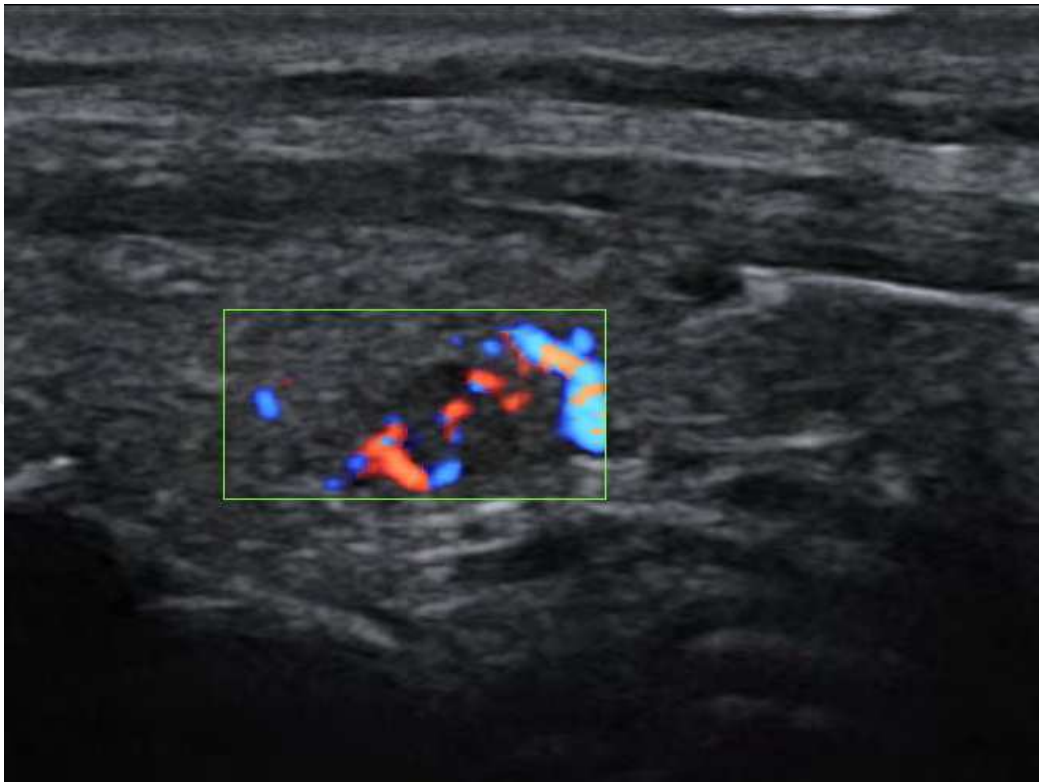


Fig. 4. Intra-thyroid parathyroid adenoma demonstrated on ultrasound image. Image courtesy of Division of Medical Imaging, Flinders Medical Centre

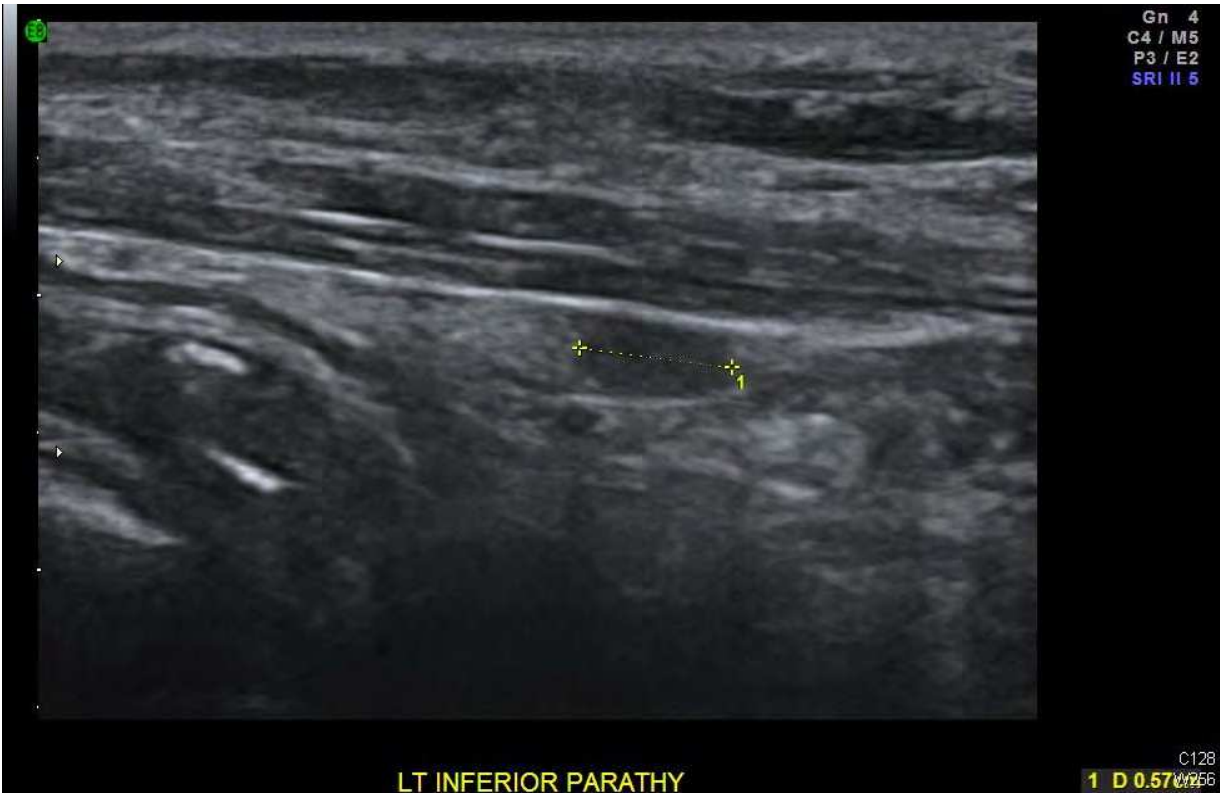


Fig. 5. Small inferior parathyroid adenoma demonstrated on ultrasound image. Image courtesy of Division of Medical Imaging, Flinders Medical Centre

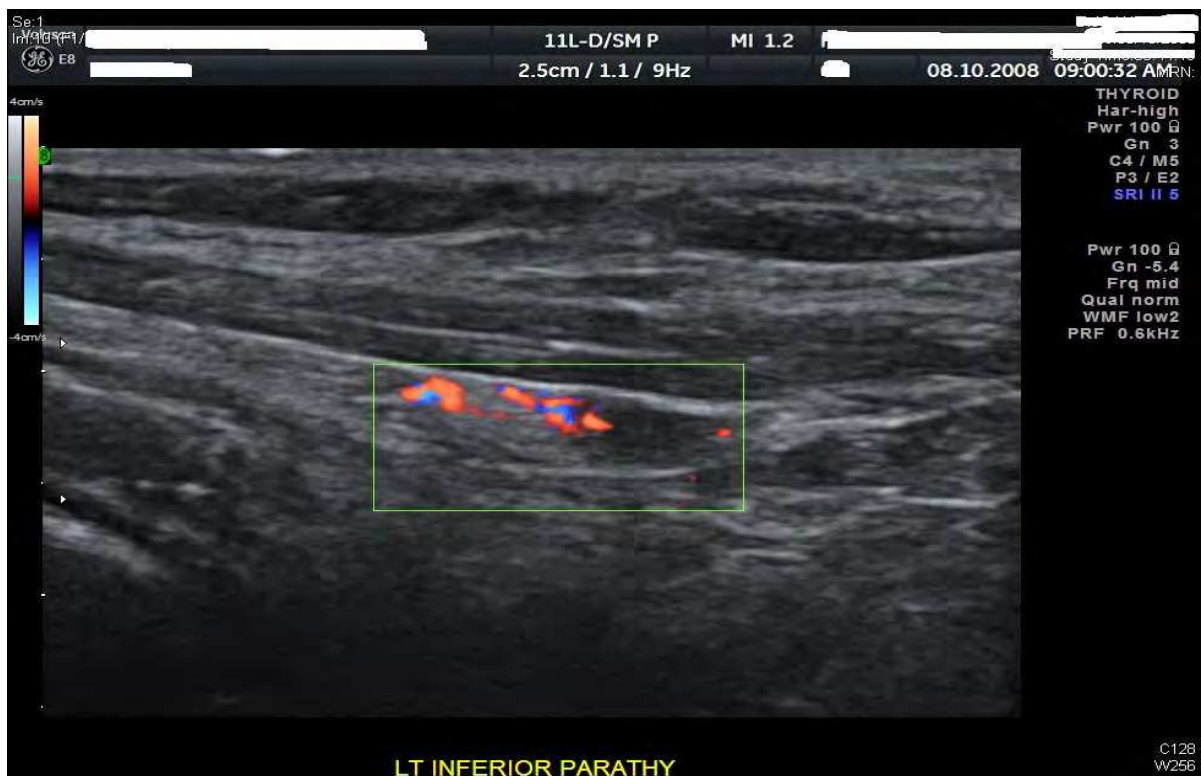

Fig. 6. Small inferior parathyroid adenoma demonstrated on ultrasound image. A feeding artery is demonstrated with the application of Colour Doppler. Image courtesy of Division of Medical Imaging, Flinders Medical Centre

Many medical imaging/radiology departments offer both NM and US studies to localize parathyroid lesions preoperatively. Imaging departments should periodically assess their performance through audits for quality assurance purposes. Benchmark performance levels can be identified through critical review and synthesis of the literature. With this in mind we performed a systematic review of the recent literature to determine the current performance of preoperative parathyroid US localizing parathyroid lesions in PHPT. We included an assessment of NM localization studies as a comparison.

2. Systematic review

2.1 Search strategy

A search of the literature was performed on 25 May, 2011 using Medline via Ovid, EMBASE via Ovid, ScienceDirect and Scopus databases (Table 1). Five groups of terms were searched using the Boolean-pharse methodology.

Category	Search terms
Population	parathyroid* or hyperparathyroid*
Intervention	ultraso* or sonograph*
Intervention	efficacy or effective* or accura* or precis* or sensitiv* or specific*
Outcome	localis* or localis* or locat* or identif*
Population/ Assessment	preoperative or pre-operative or pre operative

Table 1. Search strategy

2.2 Inclusion and exclusion criteria

We included prospective studies published after 2003 in English, which focused on the performance of preoperative US and NM localization of parathyroid lesions in PHPT. In order to be included the studies must have described a randomized or consecutive sampling strategy, cases must have been selected based on suspicion or diagnosis of PHPT and all cases must have undergone US, NM and parathyroidectomy. The results of both US and NM must have been compared to surgical findings, with or without postoperative hormone assays. Studies were excluded if they were not available in English. The review excluded all articles reporting on case studies, literature reviews, paediatric focused studies, animals and retrospective study designs. Studies which focused on intra-operative or endoscopic ultrasound were also excluded.

2.3 Search results

The search returned a total of 1205 articles (Table 2), of which 313 duplicates were removed. Twenty-seven articles in languages other than English were excluded. Based on titles alone, 798 studies were excluded after application of the selection criteria. Two authors both reviewed the abstracts of the remaining 67 articles and analyzed them using the inclusion and exclusion criteria. Seven articles were selected to be included in the review (Figure 7).

Database	Limitations applied	Results
Medline via OvidSP	English language, journal article, 2002 to 25 May 2011, human subjects	150
EMBASE via OvidSP	English language, article, 2002 to 25 May 2011, human subjects	155
ScienceDirect	Journal article, 2002 to 25 May 2011	556
Scopus	English language, article, 2002 to 25 May 2011, human or humans	344

Table 2. Search results

All the studies identified from the search were well-designed non-experimental descriptive studies, with no identified randomized clinical trials. The methodological quality of the articles was assessed using an adapted QUADAS checklist (Whiting et al. 2003) (Table 3) by two independent reviewers, with discrepancies between reviewers resolved by consensus. The articles were all of similar methodological quality.

All seven studies examined populations of patients who had a diagnosis of PHPT which was established by elevated PTH and calcium levels in the blood. In all studies, diagnosis was confirmed by successful surgical removal of parathyroid pathology with or without post surgical follow up histology and blood assays. Five studies additionally confirmed surgical success with follow up assays (Bhansali et al. 2006; Carlier et al. 2008; Lo et al. 2007; Prasannan et al. 2007; Shaheen et al. 2008), and three studies confirmed the nature of the excised lesion(s) with histology (Mihai et al. 2006; Lo et al. 2007; Carlier et al. 2008).

The US and NM localization examinations were always performed prior to surgery, therefore bias was minimized due to blinding to the surgical results. All studies, except two,

(Mihai et al. 2009, Prasannan et al. 2007) stated that the US was interpreted without knowledge of the results of the NM scan. While, this approach limits risk of contamination between the two localization studies and provides an independent assessment of the localization study’s performance, it does not mirror usual clinical practice. In clinical practice each test is often treated as complementary to the other, and is not interpreted in isolation with the alternate test. The combination of the findings from both US and NM has been proven to increase the overall sensitivity in identifying and localizing parathyroid lesions (Bhansali et al. 2006; Lo et al. 2007; Sugg et al. 2004).

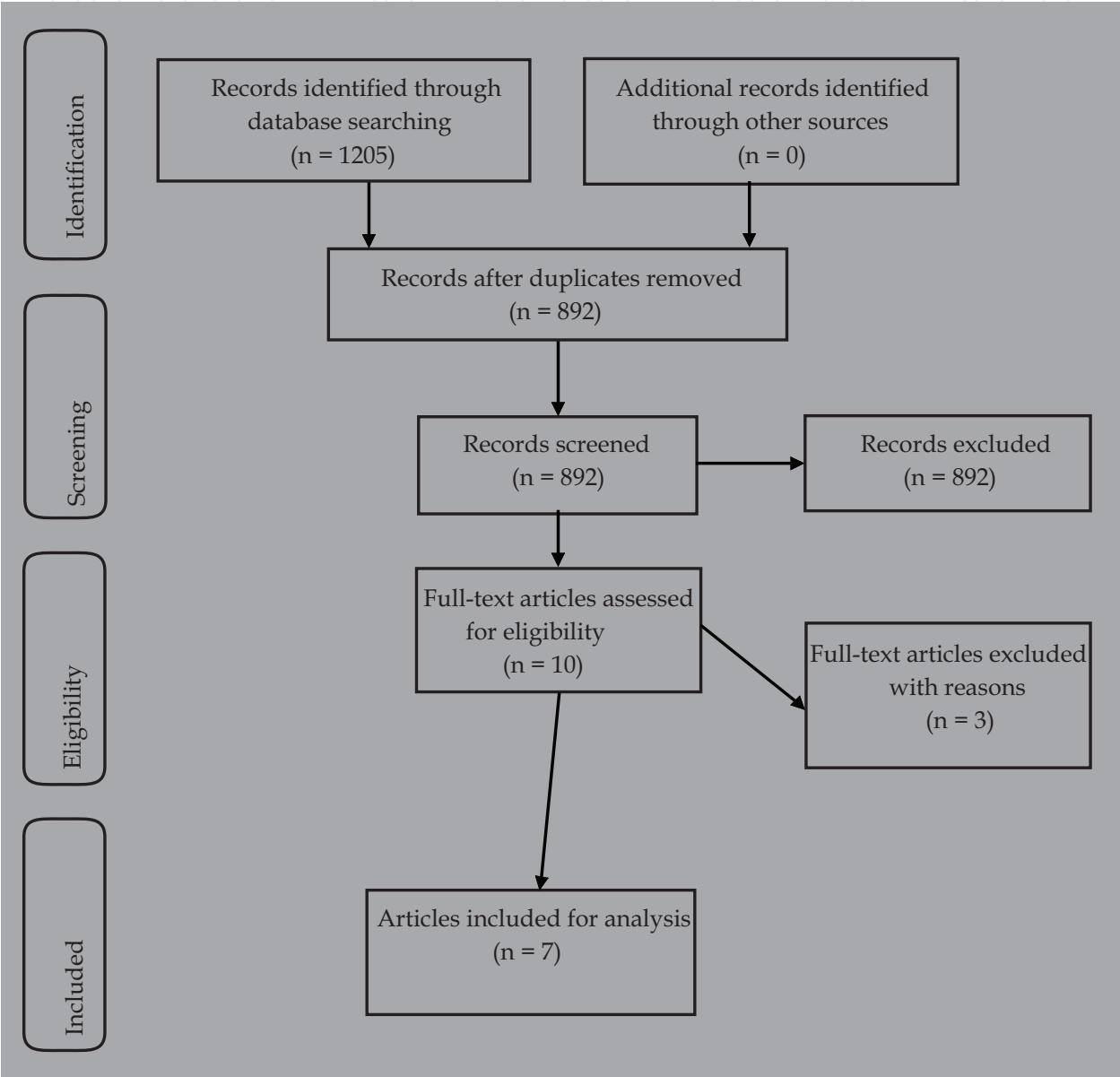


Fig. 7. Flow chart of article selection process

All studies, excepting two, described the ultrasound equipment and the experience or credentials of the operator, the type of NM technique used, the type of surgical technique and cut off values of normal for post- and pre-operative blood assays. This information is important when interpreting and transferring the findings to other settings, especially when

Legend: Cells shaded white = Yes; Cells shaded grey = Unclear; Cells shaded black = No.

Table 3. Methodologic quality of articles

Item	Bhansali et al. (2006)	Carlier et al. (2008)	Lo et al. (2007)	Mihai et al. (2006)	P et
1 Was the spectrum of patients representative of the patients who will receive the test in practice?					
2 Were selection criteria clearly described?					
3 Is the reference standard likely to correctly classify the target condition?					
4 Is the time period between reference standard and index test short enough to be reasonably sure that the target condition did not change between the two tests?					
5 Did the whole sample or a random selection of the sample, receive verification using a reference standard of diagnosis?					
6 Did patients receive the same reference standard regardless of the index test result?					
7 Was the reference standard independent of the index test (i.e. the index test did not form part of the reference standard?)					
8 Was the execution of the index test described in sufficient detail to permit replication of the test?					
9 Was the execution of the reference standard described in sufficient detail to permit its replication?					
10 Were the index test results interpreted without knowledge of the results of the reference standard?					
11 Were the reference standard results interpreted without knowledge of the results of the index test?					
12 Were the same clinical data available when test results were interpreted as would be available when the test is used in practice?					
13 Were uninterpretable/ intermediate test results reported?					
14 Were withdrawals from the study explained?					

tests and procedures are complex and variable. The exceptions were Prasannan et al. (2007) who provided no information on the execution of the  $Tc^{99m}$  sestamibi scan, and Shaheen et al. (2008) who provided no information on the experience or credentials of the operator(s). Whilst most studies used pre-operative or post-operative hormone assays, only three studies (Bhansali et al. 2006; Prasannan et al. 2007; Sugg et al. 2004) provided clear cut-off values for normal or abnormal assays.

Only two studies in this review, applied a standardized surgical approach for all patients (Bhansali et al. 2006; Shaheen et al. 2008), with a trend in the studies to mirror current clinical practice, and adjust the surgical approach (MIP or BNE), based on the results of the localization studies (Quiros et al. 2004). Common surgical practice is to still to use BNE in cases of suspected multiglandular disease and those with equivocal pre-operative localization (Johnson et al. 2007). The potential bias arising from using more than one approach to confirm the presence and location of lesions is probably minimal because there were few cases reported across the studies where parathyroid lesions were not found at surgery.

All studies appeared to be undertaken under clinical conditions where patients were undergoing diagnosis and treatment in healthcare settings. There was some lack of clarity in areas of reporting which impact on the ability to transfer results to other clinical settings, and also may be sources of bias. For example, there was lack of clarity around the selection criteria used, the time period between the localization studies and the surgery, and no study reported uninterpretable, indeterminate or intermediate results. Only one study (Lo et al. 2007) accounted for withdrawals from the study.

## 2.4 Study and subject characteristics

A summary of the subject and study characteristics of the articles is demonstrated in Table 4.

Six studies compared US and NM to surgical findings (Bhansali et al. 2006; Carlier et al. 2008; Lo et al. 2007; Prasannan et al. 2007; Shaheen et al. 2008; Sugg et al. 2004). Mihai et al. (2006) differed by not directly comparing US to surgical findings, instead comparing it to NM only, then comparing NM to surgical findings.

Across the studies a total of 740 patients were examined, comprising 534 females (72 per cent) and 206 males (28 per cent), a distribution which closely reflects the epidemiology of PHPT (Ljunghall et al. 1991). The 740 patients had 798 pathologic parathyroid glands, comprising mostly of single adenomas (86 per cent), with a lower prevalence of double adenomas (3 per cent), hyperplasia (10 per cent), carcinoma ( $n=0.5$  per cent) and one paraganglioma ( $n=0.5$  per cent).

US was performed by experienced radiologists in two studies (Carlier et al. 200; Lo et al. 2007), experienced sonographers in two studies (Bhansali et al. 2006; Sugg et al. 2004), a parathyroid surgeon in one study (Prasannan et al. 2007) and the operator was not specified by Mihai et al. (2006) or Shaheen et al. (2008). Two studies (Lo et al. 2007; Shaheen et al. 2008) indicated that multiple operators were involved in performing the ultrasound examinations in their studies. US examinations were performed using linear array, small

footprint or unspecified shaped transducers with frequencies of 5-12 MHz, all of which would be found to be used in current clinical practice.

		Bhansali et al. (2006)	Carlier et al. (2008)	Lo et al. (2007)	Mihai et al. (2006)	Prasannan et al. (2007)	Shaheen et al. (2008)	Sugg et al. (2004)
n		46 (33 female, 13 male)	51 (38 female, 13 male)	100 (70 female, 30 male)	155 (115 female, 40 male)	130 (97 female, 33 male)	25 (8 female, 17 male)	233 (173 female, 60 male)
Age	Mean	37.1	56	55.5 MEDIAN	62.1	59.1	18-25 RANGE	56

Table 4. Summary of patients

The most common NM tests were planar Tc<sup>99m</sup> sestamibi, dual radionuclide subtraction (Tc<sup>99m</sup>/Tl<sup>201</sup>), and dual phase Tc<sup>99m</sup> sestamibi. Patients underwent a range of NM techniques including conventional single photon emission computed tomography (C-SPECT) and pinhole SPECT (P-SPECT).

BNE was performed on 310 patients, and the remaining 430 underwent MIP. Two studies (Bhansali et al. 2006; Shaheen et al. 2008) performed BNE on all subjects. In the other studies the decision to perform MIP rather than BNE was made when the results of the US and NM localization examinations were concordant (Carlier et al. 2008), when suspected lesions were Tc<sup>99m</sup> sestamibi positive (Lo et al. 2007), or on surgeon’s preference (Carlier et al. 2008). It was common procedure in the studies to assess the success of the surgery in removing the parathyroid lesion(s) by performing a post-operative or intra-operative PTH assay, with or without corresponding serum calcium assays. A return of normal assay values was confirmatory for surgical success. Some studies reported that assays were undertaken intra-operatively (Lo et al. 2007; Shaheen et al. 2008; Sugg et al. 2004), and others reported the hormone assays to be taken postoperatively, with follow up which varied between 1 week and 3 years duration (Carlier et al. 2008; Bhansali et al. 2006; Mihai et al. 2006; Prasannan et al. 2007).

2.5 Results

Table 5 provides a summary of the results. Overall, US demonstrated lower sensitivities (51 to 86 per cent), to correctly localize parathyroid lesions compared to NM (64 to 98 per cent). Four studies reported the sensitivities of US to be comparable or slightly less than NM (Bhansali et al. 2006; Lo et al. 2007; Mihai et al. 2006; Shaheen et al. 2008). Two studies reported US to have higher detection rates than NM (Prasannan et al. 2007, Sugg et al. 2004). One study reported US to have significantly lower sensitivity (51 per cent) compared with planar Tc<sup>99m</sup> sestamibi (75 per cent), conventional SPECT (82 per cent), and planar SPECT (87 per cent) (Carlier et al. 2008). Three studies analyzed data specifically for single gland disease (SGD) and multi-gland disease (MGD) and found US to have higher sensitivity (73-82 per cent) compared to NM (45 to 64 per cent) in identifying MGD (Bhansali et al. 2006; Shaheen et al. 2008; Sugg et al. 2004). There were no apparent trends to suggest that one NM imaging localization technique was better than any other.

## 2.6 Discussion

Our initial search revealed 892 articles, demonstrating a wide breadth of research into the pre-operative localization of parathyroid lesions. We restricted the review to include only prospective studies with consecutive or randomized sampling. Prospective studies are more easily controlled, and allow more rigorous methodologies including the use of blinding (Euser et al. 2009). The exclusion of retrospective studies significantly reduced the number of studies included in this review, as retrospective studies are more widely reported (Mihai, Simon & Hellman 2009) and prospective studies are less frequently reported due to long data collection periods when this study design is used. Articles prior to 2003 were excluded to capture the most advanced imaging technologies. Older studies using less sensitive equipment have demonstrated lower sensitivities for both US and NM (Ruda et al. 2005). However, the descriptions of US techniques were mostly limited to the operator and basic specifications of the transducer, rather than the make and model of the equipment, and it was not possible to assess if the differences in results were influenced by the capabilities of the technology used in each study.

Despite the limitations of our selection criteria, and resulting narrow range of studies included, we found wide variations in sensitivity rates for both US and NM localization examinations. Sensitivity rates for the detection of parathyroid lesions for preoperative US localization examinations ranged from 51 to 85.7 per cent and ranged from 64 to 98 per cent for NM localization examinations. In most cases successful localization was defined when the lesion(s) was correctly identified on the correct side of the neck. This is an important consideration for surgical planning. The sensitivities rates were similar to what was reported in a similar review (Mihai et al. 2009) which reported ultrasound sensitivity rates of 51 to 96 per cent, and NM sensitivity rates from 34 to 100 per cent. The wider variation reported by Mihai et al. (2009) is likely due to their inclusion of retrospective studies, short case series and older studies which were excluded from our review.

There are a number of factors that may impact on the performance of US in detecting parathyroid lesions including the expertise of the operator, the small size of some lesions, ectopic gland positions, multinodular thyroid goiter and parathyroid hyperplasia (Levy et al. 2011; Mihai et al. 2009; Ruda et al. 2005). Two studies in this review referred to the impact of lesion size on sensitivity rates; Prasannan et al. (2007) stated that US was more sensitive when detecting lesions over 1270 milligrams and Bhansali et al. (2006) stated that sensitivity reached 92.3 per cent sensitivity for glands weighing over five grams. While the sensitivity of US was shown to be lower in smaller glands (Bhansali et al. 2006; Prasannan et al. 2007), US still demonstrates the capability to detect lesions as small as 1.2 grams in weight (Bhansali et al. 2006). Colour Doppler US can be important in the differential diagnosis of a suspected lesion, demonstrating superior feeding vessels in parathyroid glands, as opposed to hilar flow in lymph nodes. However, the use of Doppler US in the differential diagnosis of parathyroid lesions was only reported in one study in this review (Prasannan et al. 2007).

The position of parathyroid lesions also influenced detection rates. The sensitivity of US to detect and localize ectopic parathyroid lesions was notably lower than the sensitivity when localizing those lesions in normal anatomical positions and appeared to be unrelated to the sizes of the ectopic lesions (Bhansali et al. 2006, Carlier et al. 2008). Across the seven studies,

twenty ectopic glands were established at surgery. The overall detection rate of retro-sternal glands was low, regardless of their size. The study with the highest number of ectopic glands gave the lowest sensitivity (51 per cent) (Carlier 2008), and the highest sensitivity was recorded in studies with no or few ectopic glands in their series (Prasannan et al. 2007; Shaheen et al. 2008).

Bhansali et al. (2006) reported that US missed several ectopic glands which were located in retro-oesophageal and mediastinal positions. Both US and NM were more likely to identify ectopic lesions in the neck than those in retro-sternal positions (Carlier et al. 2008). For US, this is likely due to the difficulty in scanning through the narrow sternal notch, to avoid surrounding bony structures. NM is less affected by bone and gas than US, but despite this Bhansali et al. (2006) reported that NM missed the same retro-sternal lesions that were undetected using US.

It is not clear if the expertise of the US operator influences results. In studies which were clear in reporting the expertise of operators, radiologists appeared to be less successful in US localization compared to sonographers. Only one study (Prasannan et al. 2007) reported on surgeon performance of US localization, with good results (sensitivity 82%). Surgeons may have an advantage over other operators by receiving direct feedback on their performance when they perform surgery on the cases they examined with US.

Bhansali et al. (2006), Prasannan et al. (2007) and Sugg et al. (2004) assessed cases with single gland disease (SGD) separately to those with multi gland disease (MGD). US localization studies were better than NM in identifying MGD and also found that US was more effective in detection of MGD than SGD (Bhansali et al. 2006; Sugg et al. 2004). Caution should however be exercised when interpreting this finding due to the low prevalence of MGD compared to SGD.

The presence of thyroid nodules or multinodular goiter was also noted to reduce the sensitivity of US in the detection and localization of parathyroid lesions (Lo et al. 2007).

The variations in the reported performance of US and NM may also be influenced by other factors such as differences in selection criteria, and differences in cut off values of hormone assays both to diagnose PHPT in patients, and to confirm surgical success. These factors may have not had a large effect, but should not be discounted.

Differences in detection rates between US and NM may be due to the nature of the imaging in these techniques. Nuclear medicine scanning relies on a physiological process, and this is reflected in observations by Mihai et al. (2006) that there were lower detection rates for adenomas with predominantly chief cells, and higher detection rates for adenomas with oxyphil cells and mixed cells in NM scanning. Additionally, false positives may occur in NM scanning when non-parathyroid tissue uptakes Tc<sup>99m</sup> sestamibi (Carlier et al. 2008). US instead relies on structural changes, and false negatives may result when sound reflective tissues such as bone and gas limits the identification of retro-sternal, retro-tracheal and retro-oesophageal lesions (Mihai et al. 2009). False positives may occur in US localization studies, when other structures such as lymph nodes are mistaken for parathyroid glands.

It has been suggested that both US and NM localization examinations should be performed for preoperative localization of parathyroid lesions (Mihai et al. 2009), to determine whether

		Bhansali et al. (2006)	Carlier et al. (2008)	Lo et al. (2007)	Mihai et al. (2006)	
Surgery Type	BNE	46	28	34	63	
	MIP	0	23	66	92	
Ectopic glands		N=1 (retro-oesophageal)	N=11, (6 posterior, 3 thyrothymic ligament, 1 mediastinal, 1 intra-thyroid)	N=1 (carotid sheath)	N=7 (retrosternal)	
Conditions	US Operator	Experienced Sonographer	Experienced Radiologist	Radiologist	Single Experienced Operator	
	US Transducer	Linear array 7.5-10 MHz	7-12 MHz	10 MHz	Linear Array Small Footprint 15 MHz	
	NM Scan Type	Dual Phase Tc99m Sestamibi, Dual Radionuclide Subtraction Tc99m/Tl201, C-T SPECT	Dual Phase Subtraction Tc99mO4/Tc99m sestamibi, C-SPECT, P-SPECT	Tc99m sestamibi, C-SPECT	Tc99m sestamibi	
Reference Standard	Surgical Findings	√	√	√	√	
	Histopathology	√	√	√	√	
	Post/intra operative Assay	Post Ca and iPTH	Six Month	Quick PTH		C i
NM results known		no	no	no	Not stated	
Results	Total number of Lesions	53	55	100	155	
	Lesions detected on US (n)	31/42 SGD 9/11 MGD	28/55	56/100	104/155	
	US Sensitivity	73% (for correct side)	51%	57% (for correct side)	57% (for correct side)	
	Lesions Detected on NM (n)	41/42 SGD 5/11 MGD	Planar Scintigraphy 42/55, C-SPECT 45/55, P-SPECT 48/55	85/100	103/155	
	NM sensitivity	98%	76%, 82%, 87%	89%	93%	

Key: BNE = Bilateral Neck Exploration;Ca=serum calcium level; MIP = Minimally Invasive Parathyroidectomy; n.s. = Not Stated; % = per cent, MHz = megahertz; PTH = Parathyroid Hormone; iPTH = Intact Parathyroid Hormone; IOPTH = Intraoperative Parathyroid Hormone Assay; SGD = Single Gland Disease; MGD = Multi Gland Disease; C-SPECT = Conventional Single Photon Emission Computed Tomography; P-SPECT = Pinhole Single Photon Emission Computed Tomography; SPECT = Single Photon Emission Computed Tomography; Tc99m = Technetium 99m; Tl201 = Thallium 201; O4 = Oxygen 4

Table 5. Key findings

the patient is a viable candidate for MIP. The dependence of NM on physiologic changes, and the dependence of US on anatomic changes supports the argument to use the two techniques as complementary localization techniques. This approach was further supported in our review, with five studies demonstrating improvement in sensitivity when a combination of two localization examinations were employed (Bhansali et al. 2006; Lo et al. 2007; Prasannan et al. 2007; Shaheen et al. 2008; Sugg et al. 2004).

Most studies reported sensitivity (Bhansali et al. 2006, Carlier et al. 2008, Lo et al. 2007, Prasannan et al. 2007, Shaheen et al. 2008) as an outcome measure of the performance of the localization studies. Approximately half of the studies also reported positive predictive value (PPV) (Bhansali et al. 2006; Lo et al. 2007; Prasannan et al. 2007; Shaheen et al. 2008). PPV is influenced by the prevalence of the target condition, with high prevalence rates resulting in artificially elevated PPV rates. The sample populations in this review consisted of patients with recognized and confirmed parathyroid disease (i.e. 100 per cent prevalence), therefore limiting the relevance of the PPV. Other measurements of localization performance included detection rates (Mihai et al 2006; Shaheen et al. 2008; Sugg et al. 2004), accuracy (Lo et al. 2007) and specificity (Carlier et al. 2008). Specificity of US and NM in identifying and localizing parathyroid lesions is not widely reported. Patients are usually conclusively diagnosed using clinical examinations and blood tests prior to undergoing imaging, which is primarily for localization rather than diagnosis. In addition to this, most prospective studies using surgical findings as a reference standard only include patients that have at least one lesion as it is unethical to operate on an unaffected patient, and as such there should be no true-negative results from which to calculate specificity.

## 2.7 Conclusion

The aim of this review was to investigate the effectiveness of US as a localization technique for pre-operatively detecting and localizing parathyroid lesions. The rationale behind this was to establish benchmark sensitivity rates in order to set best practice goals for departmental audits. Audits are valuable not only as an assessment of performance, but also can be used to improve professional practice (Ridder et al. 2008). The results of the review determined that there was wide variability of US sensitivity in detecting parathyroid lesions, despite the studies being of similar quality and at the same level of evidence. Benchmarking is therefore difficult, without having a clear understanding of the reasons for the wide variability. Patient presentation, including the presence of pathologic ectopic parathyroid glands, are likely to have an impact on the sensitive rates for gland localization. Therefore benchmarking of detection rates will depend on the prevalence of ectopic glands in each setting. This review demonstrates that high detection rates using US can be achieved if there is low prevalence of pathologic ectopic glands.

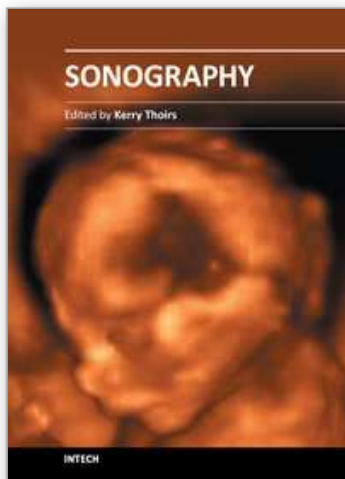
## 3. References

- Bhansali, A, Masoodi, S, Bhadada, S, Mittal, B, Behra, A & Singh, P (2006). Ultrasonography in detection of single and multiple abnormal parathyroid glands in primary hyperparathyroidism: Comparison with radionuclide scintigraphy and surgery. *Clinical Endocrinology*, vol. 65, no. 3, (September 2006), pp. 340-345, ISSN 1365-2265.

- Byel, B, Brunken, R, DiFilippo, F, Neumnn, D, Wu, G, Cerqueira, M. (2008), SPECT /CT Imaging: Clinical Utility of an Emerging Technology, *Radiographics*, vo.28, no.4, (July-August 2008), pp.1097-1113, ISSN 0271-5333.
- Carlier, T, Oudoux, A, Mirallie, E, Seret, A, Daumy, I, Leux, C, Bodet-Milin, C, Kraeber-Bodere, F & Ansquer, C (2008), 99mTc-MIBI pinhole SPECT in primary hyperparathyroidism: comparison with conventional SPECT, planar scintigraphy and ultrasonography, *European journal of nuclear medicine and molecular imaging*, vol. 35, no. 3, (March 2008), pp. 637-643, ISSN 1619-7070.
- Clark O. (2003), How should patients with primary hyperparathyroidism be treated?[editorial], *Journal of Clinical Endocrinology and Metabolism*, vol.88, no. 7, (July 2003), pp. 3011-3014, ISSN 0021-972X.
- Euser, AM, Zoccali, C, Jager, K & Dekker, F (2009), Cohort Studies: Prospective versus Retrospective, *Nephron Clinical Practice*, vol. 113, no. 3, (August 2009), pp. 214-217, ISSN 1660-8151.
- Johnson, N, Tublin, M, Ogilvie, J. (2007), Review: Parathyroid Imaging: Technique and Role in the Preoperative Evaluation of Primary Hyperparathyroidism, *American Journal of Roentgenology*, vol. 188, no. 6, (June 2007), pp. 1706-1715, ISSN 1546-3141.
- Kaplan, E, Yashiro, T, Salti, G. (1992), Primary hyperparathyroidism in the 1990s: choice of surgical procedures for this disease. *Annals of Surgery*, vol.215, no.215, no.4, (April 1992), pp. 300-316, 1528-1140.
- Kobayashi, T, Man-I,M, Shin, E, Kikkawa, N, Kawahara, K, Kurata, A, Fukuda, H, Asakawa, H. (1999), Hyperfunctioning intrathyroid parathyroid adenoma: Report of two cases, *Surgery Today*, vol.29, no.8, (August 1999), pp.766-768, ISSN 0941-1291
- Levy, J, Kandil, E, Yau, L, Cuda, J, Sheth, S & Tufano, R. ( 2011), Can ultrasound be used as the primary screening modality for the localization of parathyroid disease prior to surgery for primary hyperparathyroidism? A review of 440 cases, *Journal for oto-rhino-laryngology and its related specialties*, vol. 73, no. 2, (March 2011) pp. 116-120, ISSN 1423-0275.
- Liou M, Huang H, Lin J, Huang BY, Hsueh C, Jeng L, Tzen KY. (1996), The accuracy of ultrasonography and 201Tl-99mTc subtraction scan in localization of parathyroid lesions, *Chang Gung Medical Journal*, vol. 19, no. 2, (June 1996) pp. 121-128.
- Ljunghall S, Hellman P, Rastad J, Akerström G. (1991), Primary hyperparathyroidism: epidemiology, diagnosis and clinical picture, *World Journal Surgery*, vol. 15, no.6, (November-December 1991), pp.681-687, ISSN 0364-2313.
- Lo, C, Lang, B, Chan, W, Kung, A & Lam, K. (2007), A prospective evaluation of preoperative localization by technetium-99m sestamibi scintigraphy and ultrasonography in primary hyperparathyroidism, *The American Journal of Surgery*, vol. 193, no. 2 February 2007), pp. 155-159, ISSN 0002-9610.
- Mihai, R, Gleeson, F, Buley, I, Roskell, D & Sadler, G. (2006), Negative imaging studies for primary hyperparathyroidism are unavoidable: Correlation of sestamibi and high-resolution ultrasound scanning with histological analysis in 150

- patients, *World Journal of Surgery*, vol. 30, no. 5, (May 2006) pp. 697-704, ISSN 0364-2313.
- Mihai, R, Simon, D & Hellman, P. (2009), Imaging for primary hyperparathyroidism-an evidence-based analysis, *Langenbeck's Archives of Surgery*, vol. 394, no. 5, (September 2009) pp. 765-784, ISSN 1435-2443.
- Mujtaba, B, Adenaike, M, Yaganti, V, Mujtaba, N & Jain, D. (2007), Anaphylactic reaction to Tc-99m sestamibi (Cardiolite) during pharmacologic myocardial perfusion imaging, *Journal of Nuclear Cardiology*, vol. 14, no. 2, (April 2007), pp. 256-258, ISSN 1071-3581.
- Nguyen B. (1999), Parathyroid imaging with Tc-99m sestamibi, planar and SPECT scintigraphy, *Radiographics*, vol.19, no.3, (May-June 1999), pp. 601-614, ISSN 0271-5333.
- Palazzo F. (2004), Minimally invasive parathyroidectomy [editorial], *British Medical Journal*, vol. 328, (April 2004), pp.849-850, ISSN 0959-8138.
- Prasannan, S, Davies, G, Bochner, M, Kollias, J & Malycha, P. (2007), Minimally invasive parathyroidectomy using surgeon-performed ultrasound and sestamibi, *ANZ Journal of Surgery*, vol. 77, no. 9, (September 2007), pp. 774-777, ISSN 1445-1433.
- Quiros, R, Alioto, J, Wilhelm, A, Prinz, R. (2004) An Algorithm to Maximize Use of Minimally Invasive Parathyroidectomy, *Archives of Surgery*, vol. 139, no. 5, (May 2004), pp. 506-507, ISSN 0272-5533
- Reeder, S, Desser, T, Weigel, R, Jeffrey R. (2002), Sonography in Primary Hyperparathyroidism: Review With Emphasis on Scanning Technique, *Journal of Ultrasound in Medicine*, vol.21, no. 5, (May 2002), pp. 539-552, ISSN 0278-4297.
- Ruda, J, Hollenbeak, C & Stack, B. (2005), A systematic review of the diagnosis and treatment of primary hyperparathyroidism from 1995 to 2003, *Otolaryngology - Head and Neck Surgery*, vol. 132, no. 3, (March 2005), pp. 359-372, ISSN 0194-5998.
- Shaheen, F, Chowdry, N, Gojwari, T, Wani, A & Khan, S. (2008), Role of cervical ultrasonography in primary hyperparathyroidism, *Indian Journal of Radiology and Imaging*, vol. 18, no. 4, (November 2008), pp. 302-305, ISSN 0971-3026.
- Sugg, S, Krzywda, E, Demeure, M & Wilson, S. (2004), Detection of multiple gland primary hyperparathyroidism in the era of minimally invasive parathyroidectomy, *Surgery*, vol. 136, no. 6, (December 2004), pp. 1303-1309, ISSN 0039-6060.
- Udelsman R. (2002), Six hundred fifty-six consecutive explorations for primary hyperparathyroidism, *Annals of Surgery*, vol. 235, no. 5, (May 2002), pp.665-672, ISSN 0003-4932.
- Udelsman, R, Donovan, P & Sokoll, L. (2000), One Hundred Consecutive Minimally Invasive Parathyroid Explorations, *Annals of Surgery*, vol. 232, no. 3, (September 2000), pp. 331-339, ISSN 0003-4932.
- Van de Ridder, J, Stokking, K, mCGaghie, W, ten Cate, O. (2008), What is feedback in Medical Education?, *Medical Education*, vo. 42, no. 2, (February 2008), pp. 189-197, ISSN 0308-0110.

- Whiting, P, Rutjes, A, Reitsma, J, Bossuyt, P & Kleijnen, J. (2003), The development of QUADAS: a tool for the quality assessment of studies of diagnostic accuracy included in systematic reviews, *BMC Medical Research Methodology*, vol. 3, no. 25, (November 2003), pp. 25-37, ISSN 1471-2288.
- Yeh, M, Barraclough, B, Sidhu, S, Sywak, M, Barraclough, B & Delbridge, L. (2006), Two hundred consecutive parathyroid ultrasound studies by a single clinician: The impact of experience, *Endocrine Practice*, vol. 12, no. 3, (May-June 2006), pp. 257-263, ISSN 1530-891X.



## **Sonography**

Edited by Dr. Kerry Thoirs

ISBN 978-953-307-947-9

Hard cover, 346 pages

**Publisher** InTech

**Published online** 03, February, 2012

**Published in print edition** February, 2012

Medical sonography is a medical imaging modality used across many medical disciplines. Its use is growing, probably due to its relative low cost and easy accessibility. There are now many high quality ultrasound imaging systems available that are easily transportable, making it a diagnostic tool amenable for bedside and office scanning. This book includes applications of sonography that can be used across a number of medical disciplines including radiology, thoracic medicine, urology, rheumatology, obstetrics and fetal medicine and neurology. The book revisits established applications in medical sonography such as biliary, testicular and breast sonography and sonography in early pregnancy, and also outlines some interesting new and advanced applications of sonography.

### **How to reference**

In order to correctly reference this scholarly work, feel free to copy and paste the following:

S. Alford, W. Barber, G. Cheung and K. Thoirs (2012). The Accuracy of Ultrasound in the Pre-Operative Localisation of Parathyroid Lesions in Primary Hyperparathyroidism: A Review of the Literature, Sonography, Dr. Kerry Thoirs (Ed.), ISBN: 978-953-307-947-9, InTech, Available from:  
<http://www.intechopen.com/books/sonography/the-accuracy-of-ultrasound-in-the-pre-operative-localisation-of-parathyroid-lesions-in-primary-hyper>

**INTECH**  
open science | open minds

### **InTech Europe**

University Campus STeP Ri  
Slavka Krautzeka 83/A  
51000 Rijeka, Croatia  
Phone: +385 (51) 770 447  
Fax: +385 (51) 686 166  
[www.intechopen.com](http://www.intechopen.com)

### **InTech China**

Unit 405, Office Block, Hotel Equatorial Shanghai  
No.65, Yan An Road (West), Shanghai, 200040, China  
中国上海市延安西路65号上海国际贵都大饭店办公楼405单元  
Phone: +86-21-62489820  
Fax: +86-21-62489821

© 2012 The Author(s). Licensee IntechOpen. This is an open access article distributed under the terms of the [Creative Commons Attribution 3.0 License](https://creativecommons.org/licenses/by/3.0/), which permits unrestricted use, distribution, and reproduction in any medium, provided the original work is properly cited.

IntechOpen

IntechOpen