

We are IntechOpen, the world's leading publisher of Open Access books Built by scientists, for scientists

6,900

Open access books available

186,000

International authors and editors

200M

Downloads

Our authors are among the

154

Countries delivered to

TOP 1%

most cited scientists

12.2%

Contributors from top 500 universities



WEB OF SCIENCE™

Selection of our books indexed in the Book Citation Index
in Web of Science™ Core Collection (BKCI)

Interested in publishing with us?
Contact book.department@intechopen.com

Numbers displayed above are based on latest data collected.
For more information visit www.intechopen.com



Clinical Perspectives of Scrotal Ultrasound in Urology

Shou-Hung Tang, Tai-Lung Cha and Guang-Huan Sun
*Tri-Service General Hospital, National Defense Medical Center, Taiwan,
R.O.C.*

1. Introduction

Scrotal ultrasound is widely used in modern hospitals as the first-line evaluation of almost all scrotal abnormalities. It provides useful and timely information for physicians to make management decisions without delay. This chapter is written in accordance with the clinical perspectives of urologists, as opposed to the technical interpretation of radiologists, in order to provide practical assistance to practicing physicians. An assessment of the commonest scrotal disorders will be discussed in this chapter.

Quick guide to ultrasound equipment and common imaging techniques
Normal ultrasound anatomy of the testis and epididymus
Identify scrotal and testicular emergencies that require surgical attention
Testicular torsion
Acute epididymitis, orchitis, and epididymo-orchitis
Testicular trauma
Fournier’s gangrene
Neoplasm of the testis
Malignant neoplasms of the testis
Benign neoplasms of the testis
Non-neoplastic disease of the scrotum and testis
Varicocele
Hydrocele
Spermatocele
Testicular microlithiasis
Scrotal wall abscess

Table 1. Chapter highlights

2. Quick guide to ultrasound equipment and common imaging techniques

It is generally recommended that a high frequency (7 to 12 MHz) ultrasound transducer should be used whenever possible, set to the “small parts” setting, in order to examine

scrotal contents (Bluth et al., 2001). Transducers with higher frequencies (e.g., >17 MHz) may help to obtain greater resolutions of fine anatomical details and are therefore particularly useful in pediatric patients. A machine that has the ability to perform color Doppler scans is always included as a standard setting. Color Doppler scans are required to diagnose vascular abnormalities, such as varicoceles, or more importantly, testicular torsion. Combined high-frequency scans and color Doppler images are sufficient for the diagnosis of most cases (Sandor et al., 2011). Advanced ultrasound techniques include contrast-enhanced studies, power Doppler scanning, and down-shifted Doppler frequencies in specific clinical situations. However, we do not recommend their use in routine daily practice.

Prior to the ultrasound examination, it is crucial that the patient should be calmed and that the procedure has been fully explained to them. The examiner should obtain a clear clinical history of the patient and any major past medical history should be known about before the study begins. It is recommended that the patient should be placed in the supine position with their thighs slightly abducted, described as the “frog-legs” posture. We have found that putting a rolled towel underneath the scrotum is helpful, but this maneuver should be individualized and only performed when the findings will not be affected by any compressive force.

Routine scanning procedures include the following scans as a minimum: long-axis (longitudinal), short-axis (transverse), and color-Doppler scans of both testicles, the epididymis and the spermatic cords. Care must be taken not to overlook lesions underneath or within the scrotal wall. In most cases, the content of the contralateral scrotum is a good reference guide to assessing the side with the lesion, and it is convenient to use the split-screen function for a contemporaneous comparison of both sides.

3. Normal ultrasound anatomy of the testis and epididymis

Normal testes are responsible for both reproductive and endocrine functions. In the adult human, the testes are ovoid in shape, with a size of approximately 4 x 3 x 2.5 cm (30 ml volume). Each testis is composed of approximately 250-300 lobules that contain seminiferous tubules. The lobules are separated by septa that cannot be visualized under sonography. These septa attach to the inner side of the tunica albuginea and connect to the mediastinum of the testis. At the mediastinum, the convoluted seminiferous tubules become straightened (the so-called “rete testis”) and form 10-15 ductules that drain into the epididymis (Campbell et al., 2007).

The epididymis tightly attaches to the posterior lateral aspect of each testis. Grossly, this organ resembles an earthworm with an overall length of 4 to 5 cm. The epididymis contains a head (upper pole), body (mid-part), and a tail which connects to the vas deferens.

4. Identify scrotal and testicular emergencies that require surgical attention

4.1 Testicular torsion

Testicular torsion, or more precisely, torsion of the spermatic cord, is a true urological emergency. It affects approximately 1 in 4,000 young males before the age of 25 years (Datta et al., 2011). Almost all patients with testicular torsion present with excruciating pain, which usually wakes them up during sleep. The pain occurs as a result of testicular ischemia, and in some cases, the pain might have resolved as a result of spontaneous detorsion.

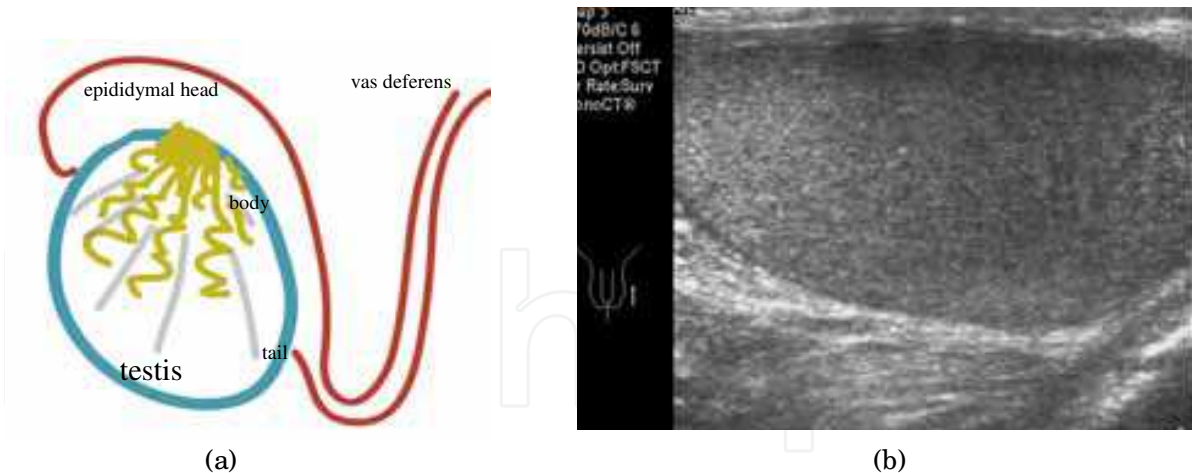


Fig. 1. (a) Simplified anatomy of the testis and epididymis; (b) normal appearance of the left-sided testis on a longitudinal scan

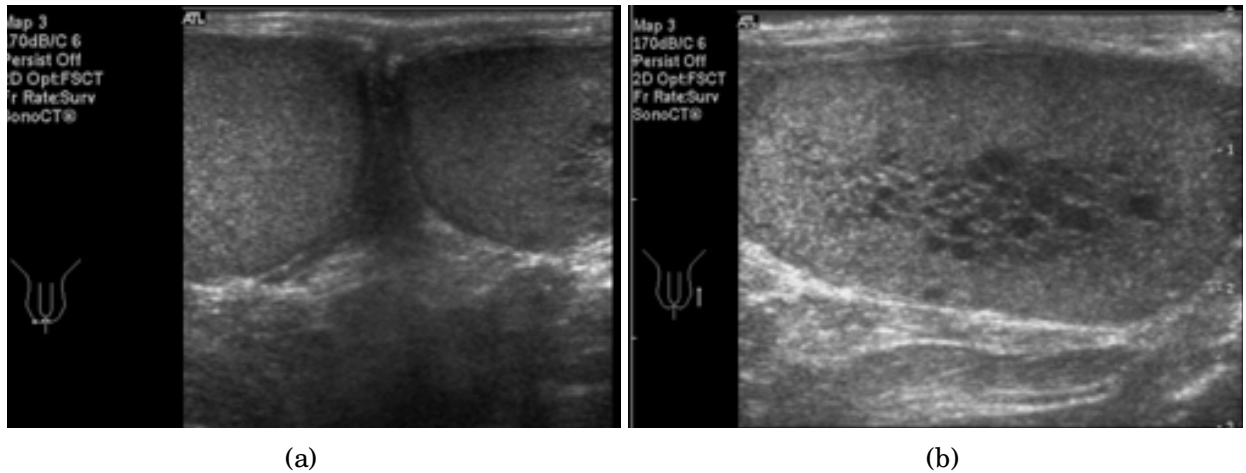


Fig. 2. The rete testis: (a) hypoechoic foci in the left testis were found on a transverse midline scan; (b) multiple tubule-like hypoechoic areas in the area of testicular mediastinum

The etiology of this condition is attributed to an abnormally high or thin attachment of the tunica vaginalis to the spermatic cord, which makes twisting of the cord more likely. This is known as a bell-clapper deformity. Testicular torsion can be intravaginal, which is seen in all age groups, or extravaginal, which is seen exclusively in neonates.

Torsion of the epididymal appendix should also be included in the differential diagnosis of testicular pain, but is seldom treated as a surgical emergency. Physical examination of the affected testis may reveal that its long axis is altered, and it lies more horizontally. Mildly swelling of the scrotum can be expected, and the testis moves in a cephalad direction towards the external inguinal ring. In up to 99% of patients, there is no cremasteric reflex on the affected side (Schmitz, 2009).

Although manual detorsion has been suggested by some authors, this is not considered to be the definite treatment. All patients in which testicular torsion is suspected should undergo surgical detorsion within 6 hours of the symptoms developing, and a concurrent prophylactic orchiopexy should be performed on the contralateral testis.

Ultrasound with color Doppler flow imaging provides the most useful information to urologists within a very short time. Typically, lower or no vascular flow to the affected testis is compatible with the diagnosis, and a detectable blood flow to the peripheral tunica albuginea may be seen. The echogenicity of the testis may vary from normal to hypoechoic, or even heterogeneous, which reflects the severity of injury.

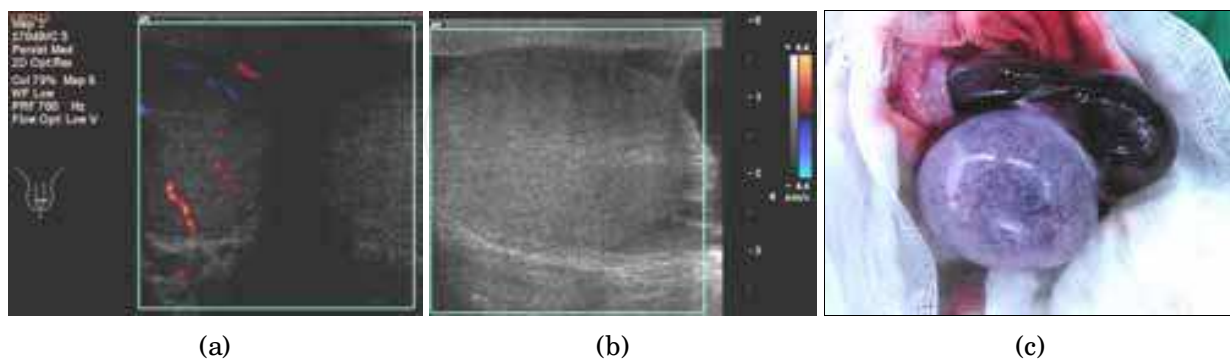


Fig. 3. Testicular torsion. A 50-year-old male presented to the ER and complained of a sudden painful enlargement of his left testis over 1 day: (a, b) ultrasonography showed absent vascularity with a cystic lesion in the left testis. Testicular echogenicity had not changes; (c) emergent exploration confirmed a 360° torsion and necrotic change of the affected organ. A left-sided orchiectomy was performed

4.2 Acute epididymitis, orchitis, and epididymo-orchitis

Acute epididymitis or epididymo-orchitis is one of the most common urological disorders in males. It primarily occurs in men aged between 18 and 60 years old, but can affect males of any age. This type of inflammatory change is often caused by bacteria (e.g., *E. coli* and *Pseudomonas* species), sexually-transmitted pathogens (e.g., *Neisseria gonorrhea*), or *Mycobacterium tuberculosis*. Ascending infections of pathogens from the urethra is the most common etiology; however, the hematogenous spread of pathogens to the epididymus can occur.

Patients tend to present with unilateral scrotal swelling and pain. Fever and leukocytosis may accompany the pain. If the inflammatory process cannot be controlled during its early phase, the affected epididymis/ testis may undergo infarction and necrotic change, which eventually lead to abscess formation. It is not uncommon to see those abscesses ruptured through the scrotal skin.

Scrotal ultrasound with color Doppler imaging offers a clue to making this diagnosis, if present in conjunction with relevant clinical symptoms. During the early phase of inflammation, focal swelling (most commonly, the epididymal tail is the first to become enlarged) and increased focal blood flow can be detected. Later, the testis becomes tense and enlarged, and its blood flow is therefore compromised in certain areas, which results in a heterogeneous sonographic appearance (de Cassio Saito et al., 2004). The formation of a large abscess is usually an indication for surgery.

Chronic inflammatory changes of the epididymis and testes are not uncommon. Diagnosing chronic epididymitis requires the combination of a relevant clinical history for over 3 months, positive urine cultures, and an inflammatory process that observed with sonography.

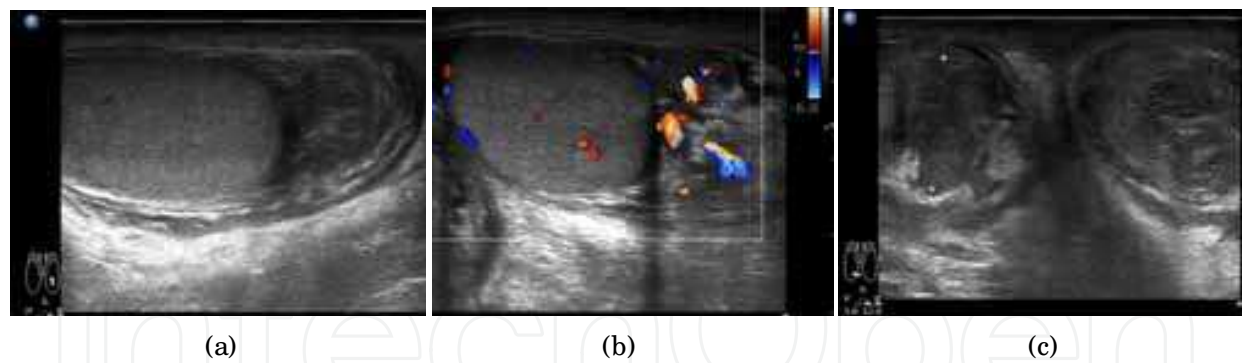


Fig. 4. Bilateral epididymitis. A 21-year-old with a gonococcal urethritis later developed fever and bilateral painful swelling of testicles. The sonography showed (a, b) swelling and hypervascularity of the left epididymal tail. (c) A short-axis scan at the level of the lower scrotum demonstrated bilateral involvement of the inflammatory process

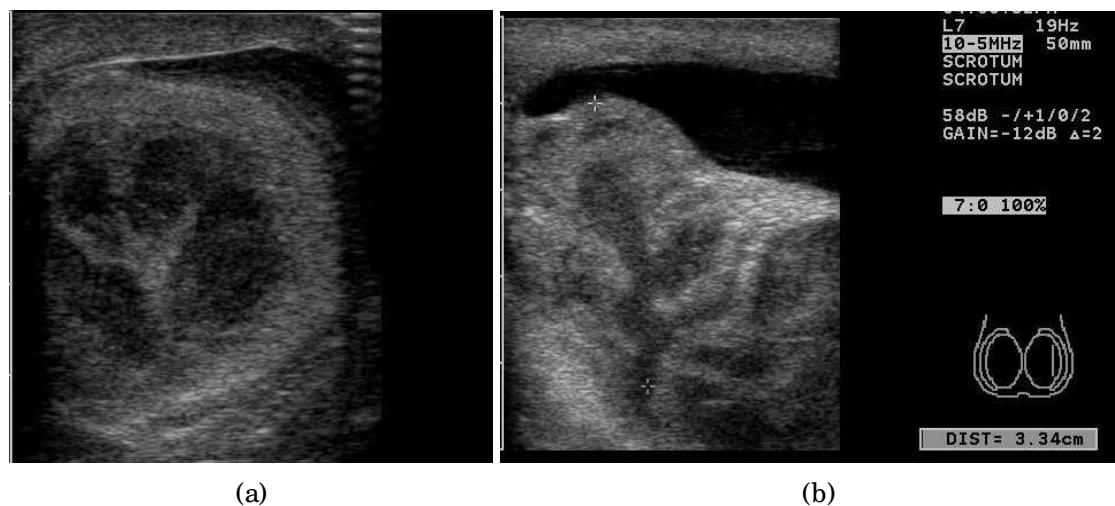


Fig. 5. A case of chronic epididymo-orchitis with an abscess. An 86-year-old male presented with a low grade fever and painful swelling of his left testicle. (a) A short-axis scan and (b) long-axis scan both revealed a heterogeneous irregularly enlarged epididymis and testis. A hydrocele was also noted. The patient underwent a left-sided orchiectomy and the histopathological findings confirmed a chronic inflammation. It was not sonographically evident to differentiate a neoplasm from the inflammatory changes in this case

4.3 Testicular trauma

4.3.1 Testicular rupture

Testicular trauma is a common presentation to the emergency department. Blunt trauma to the genitalia accounts for more than 80% of these patients, and testicular injury should be considered in any patient with a pelvic fracture.

Patients universally present with a definite mechanism and with pain. At physical examination, the affected testicle is usually enlarged and tender. As only a ruptured tunica albuginea should be surgically corrected, this should be diagnosed as quickly as possible.

Diagnosing testicular rupture with ultrasound has a specificity of over 80% (Cokkinos et al., 2011). The sonography should be focused on the presence of hematocele (fluid between the

layers of the tunica vaginalis), a discontinued line of the tunica albuginea, and unequal testicular sizes. It is important to consider that testicular torsion can occur after a minor trauma, and this should not be overlooked.

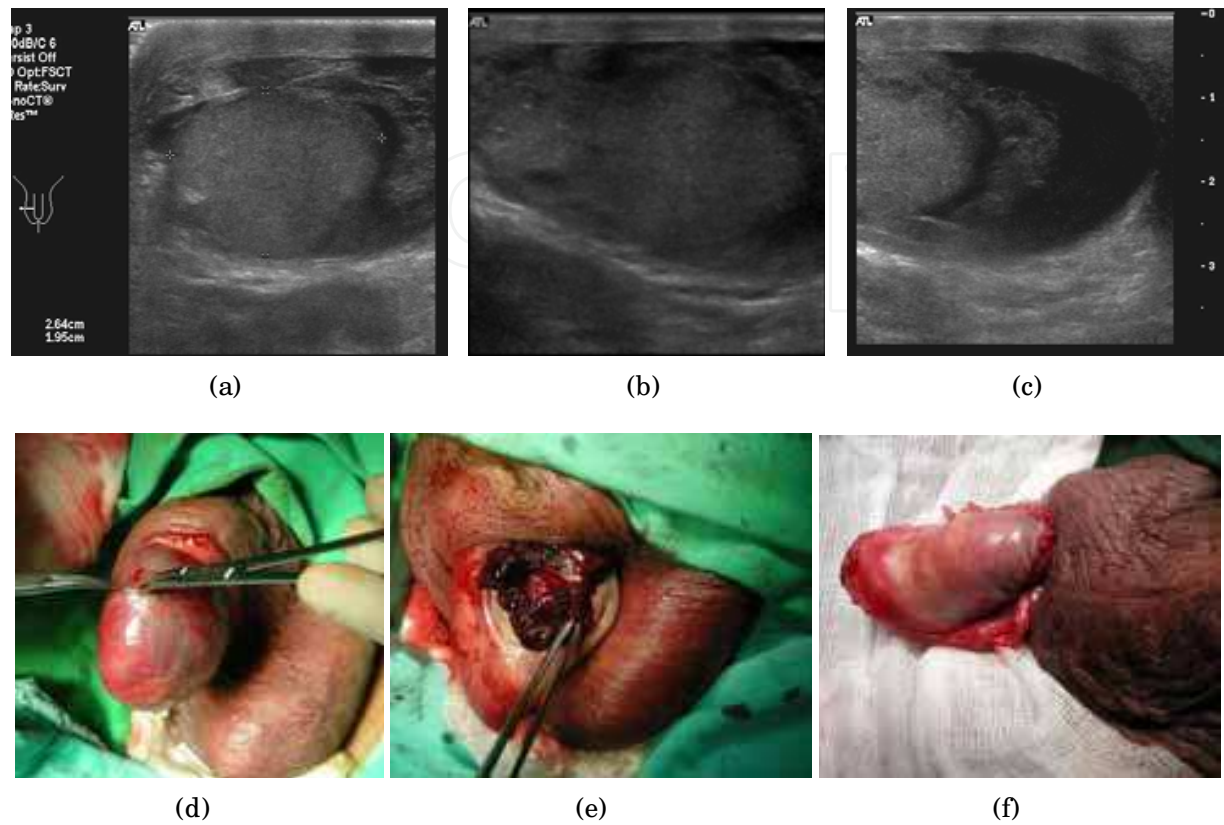


Fig. 6. Testicular rupture. A 46-year-old male sustained a blunt force to the genitalia and scrotal painful swelling developed. (a-c) Ultrasonography showed an ill-defined testicular margin, deformity, heterogeneous echogenicity and swelling of the right testis. A hydrocele or hematocoele was also noted. (d) On surgical exploration, the tunica vaginalis was intact and a hematocoele was found inside. (e) Testicular rupture through the disrupted tunica albuginea. (f) The tunica albuginea was repaired, and swollen testicular tissues were trimmed away

4.3.2 Intratesticular hematoma

After blunt contusion of the testis, testicular hematoma may occur, rather than a true rupture. The patient may complain of a gradually enlarging testis if he is seen few weeks after the injury. The typical sonographic findings reveal various degrees of heterogeneous echogenicity with a focally decreased pattern of blood flow. It is difficult to diagnose an intratesticular hematoma purely based on image findings.

4.3.3 Testicular contusion

Testicular contusion occurs frequently in active males. Contusion can be accidental, related to sports or as a result of violence. It is therefore important to obtain a clear history in order to estimate the force of injury accurately. Scrotal ultrasound is helpful in diagnosing testicular rupture, but making the diagnosis of a contusion by ultrasound is sometimes difficult.

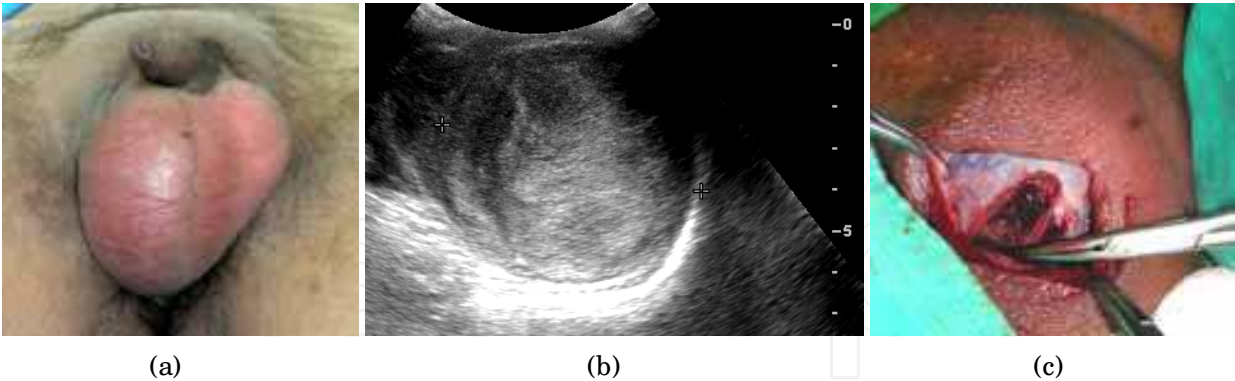


Fig. 7. Intratesticular hematoma. A 25-year-old male suffered a contused right hemiscrotum while lifting a box 2 weeks before. (a) Gross appearances showed an enlarged right testicle but no scrotal ecchymosis. (b) The right testis was enlarged with a heterogeneous echopattern, diminished blood flow, and an irregular contour that was suspicious of a testicular rupture. (c) Surgical exploration found a tense intratesticular hematoma; decompression was performed

The sonographic pictures may change over the first 72 hours from injury. After a blunt force to the testis, the testis may undergo inflammatory changes and become swollen. Since the tunica albuginea itself is strong and maintains the shape and volume of the testis, blood flow to a tense testis decreases as a result of swelling. Such a mechanism therefore makes the pattern seen on sonography very similar to that of a testicular torsion.

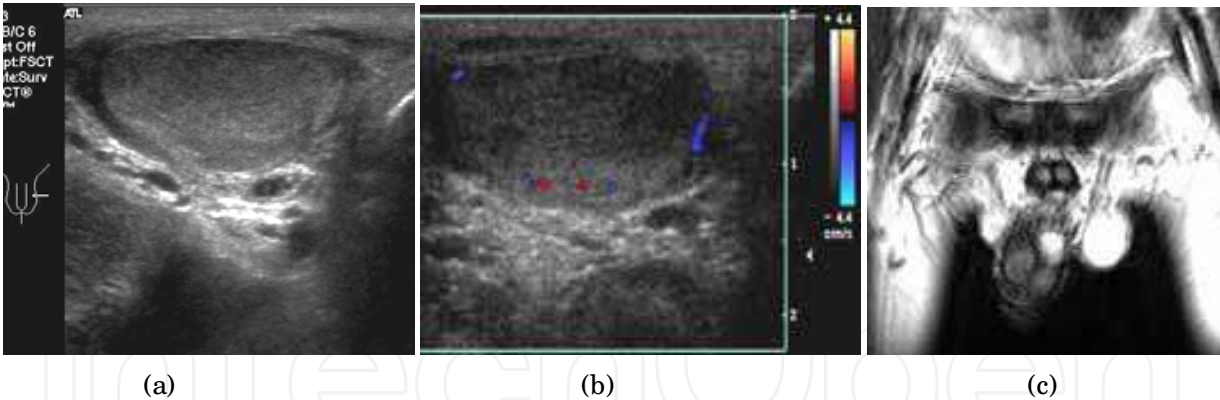


Fig. 8. A 26-year-old male sustained blunt scrotal injury and presented with left scrotal pain. (a) A transverse sonographic scan showed mild heterogeneous change of the left-sided testis. (b) There was a marked decrease in blood flow to the affected testis. (c) Magnetic resonance imaging: normal testicular perfusion and shape 1 day after the initial sonographic study

4.4 Fournier’s gangrene

Fournier’s gangrene is the most lethal necrotizing fasciitis that involves the genital and the perianal region. Most of the cases occur in patients between the ages of 20 and 50 years, with a male predominance. The mortality rate remains high at approximately 50% of cases even after aggressive debridement and other modern interventions.

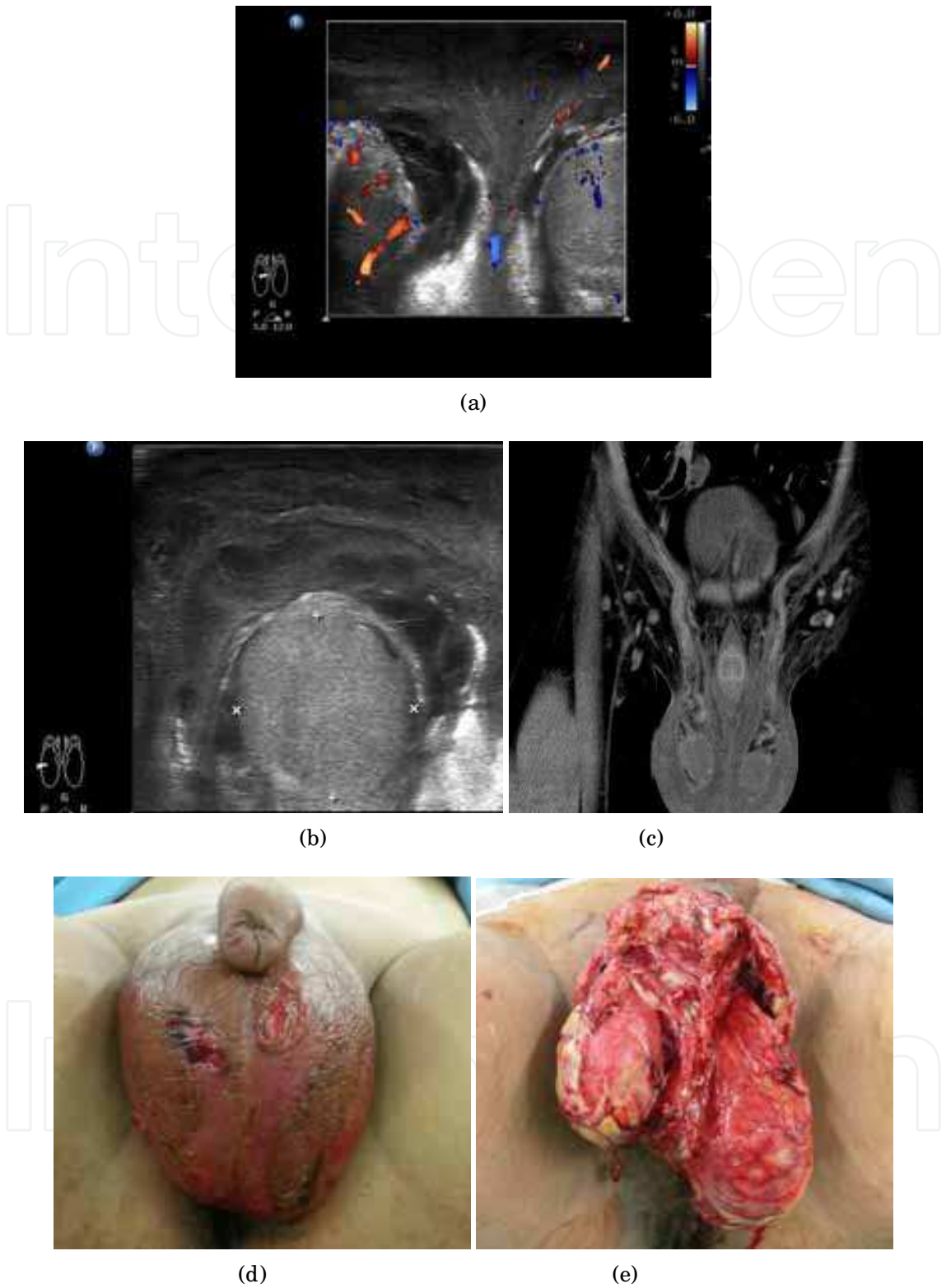


Fig. 9. A 27-year-old male presented with scrotal pain. (a,b) Enlargement, heterogeneous echogenicity, and increased vascularity of the bilateral epididymis with bilateral scrotal wall thickening on sonography. (c) Edematous scrotal wall on CT scanning. (d) Gross appearance of the scrotum. (e) Intraoperative view, showing that large amount of necrotic tissue should be removed

Urinary tract infection is recognized as the most common etiology, and it is commonly seen in cases that have undergone urethral catheterization; colorectal disease may also progress to Fournier's gangrene. Cases of Fournier's gangrene are associated with mixed flora on bacterial culture and some gas-forming organisms. The diagnosis depends on careful physical examinations, and with the aid of imaging studies to assess the extent of the infection. During physical examination, any abnormally red or black skin coloration of the affected area should be observed to indicate ischemia; all examinations should include a test for skin crepitus to assess the presence of subcutaneous air.

Additional imaging study should never delay the timing of surgical intervention, since the infection is characterized by its rapid progression. Scrotal ultrasonography and CT scans of the lower abdomen to pelvic area are usually indicated.

Ultrasound imaging reveals heterogeneous echogenicity and increased vascularity in the affected testis. Thickening of the scrotal wall and areas of fluid-gas accumulation may be observed (Bartolotta et al., 2000). Without additional clear clinical information, a Fournier's gangrene can be mistaken ultrasonographically for acute epididymitis.

5. Neoplasm of the testis

5.1 Malignant neoplasms of the testis

The incidence of malignant neoplasms of the testis is rare compared with the aforementioned disorders. Overall, 90-95% of primary testicular cancers are germ cell tumors. Germ cell tumors can be divided into two major groups: seminomas (35%) and non-seminomatous germ cell tumors (65%). Subgroups that include embryonal cell carcinoma, teratoma, choriocarcinoma, and mixed type tumors are termed as non-seminomatous germ cell tumors (NSGCTs). A small portion of testicular cancers are metastatic lesions of leukemias and lymphomas (Tanagho et al., 2008).

Testicular cancers are more common on the right side, but this is not always the rule. Thirty to fifty percent of primary testicular cancers are seen in patients with a history of cryptorchidism. Approximately 90% of patients have painless enlargement of the testis, while others may present with pain or without symptoms at all. The combination of a sonographic diagnosis and serum tumor markers play an important role in the diagnosis of testicular cancers.

The major role of ultrasonography is to differentiate between malignant and benign testicular enlargement. In difficult cases, testicular cancers may mimic the signs of an infection; both of these share a pattern of increased blood flow of the affected region. However, characteristic sonographic features of malignancy are associated with specific cancer types.

Seminomas are intratesticular lesions, where the size of the lesion ranges from small nodules to the replacement of a whole testis. Seminomas typically appear as homogeneously hypoechoic on ultrasonography. NSGCTs are more aggressive tumors that can distort the contour of the ovoid tunica albuginea. They appear as heterogeneous lesions with irregular margins on ultrasonography. Teratomas consist of all three layers of embryonic tissues; they appear as mixed cysts, heterogeneous masses, and foci of calcification.

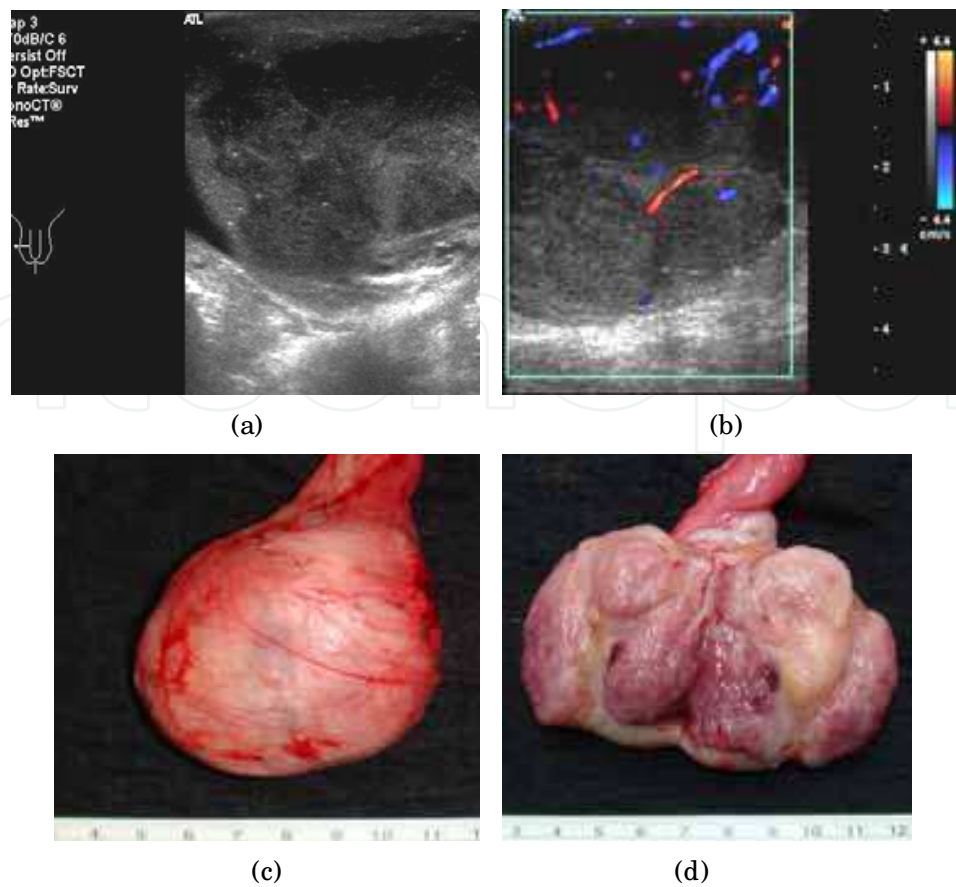


Fig. 10. Seminoma of the testis. A 31-year-old male presented with a gradual enlargement of the right testicle over several months. Vague pain was also mentioned. (a,b) Transverse ultrasound images showed multiple well-defined homogeneously hypoechoic lesions (the largest one was approximately 2.1 cm in size) in the right testis with increased vascularity in the peripheral region. (c) Radical orchiectomy was performed: the tumor was grossly confined within the tunica vaginalis. (d) The bivalve specimen showed the typical histological pattern of a seminoma

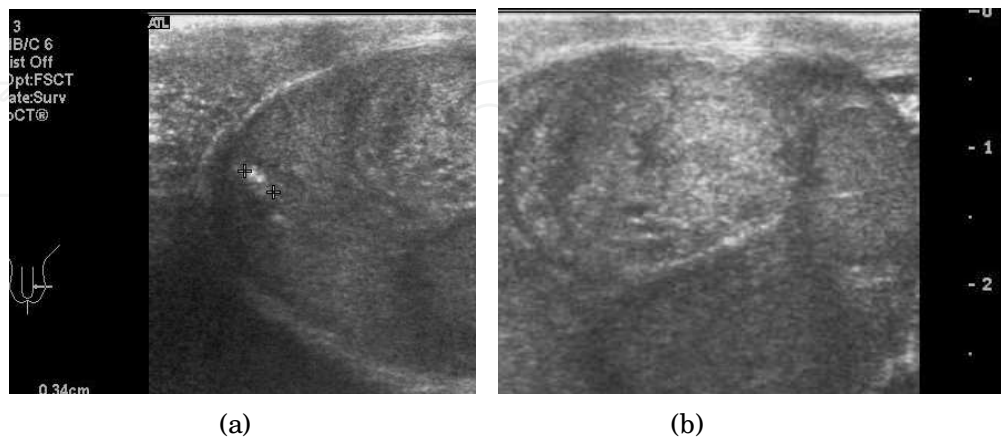


Fig. 11. A non-seminomatous germ cell tumor of the testis. A 25-year-old male presented with pain over his lower abdomen. (a,b) A heterogenous mass (size: 3.2 x 2.9 cm) was shown to be located in the left testis with a few peripheral calcified spots. Pathology later confirmed that the lesion was a mixed germ cell tumor with embryonal carcinoma and yolk sac tumor components

If a primary testicular cancer is suspected, a biopsy should not be performed before definitive surgery (radical orchiectomy), in order to avoid iatrogenic seeding.

Testicular involvements from leukemia/ lymphoma are usually seen in elderly patients. They appear as homogeneous, hypoechoic lesions within the testes, and are usually bilateral. A biopsy is required to make a definite diagnosis. Lung cancer and prostatic cancer can rarely metastasize to the testes, and sonographic findings may vary according to the nature of the cell of origin.

5.2 Benign neoplasms of the testis

Benign tumors of the testis are rare. Among these, epidermoid cysts are the most common disorder. Epidermoid cysts can be diagnosed with ultrasonography, which avoids an orchiectomy. They occur in men aged between 20 and 40 years and are often found during a routine physical check-up or self-examination. Epidermoid cysts usually grow slowly and seldom cause pain. The characteristics of ultrasonography of an epidermoid cyst are a well-circumscribed lesion with a solid central core surrounded by an echogenic rim(s), which sometimes resemble a hollow target or layers of an onion (Meng et al., 2004). Recently magnetic resonance imaging has also played a role in this diagnosis of epidermoid cysts.

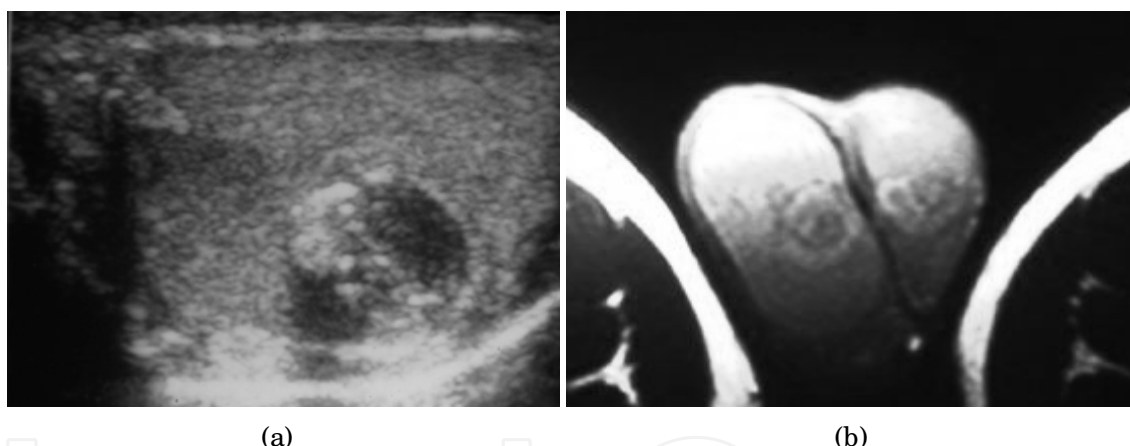


Fig. 12. Testicular epidermoid cysts. (a) Typical sonographic pattern showing cystic lesion with an echogenic ring and some internal echogenic spots. (b) Magnetic resonance imaging was compatible with the diagnosis. This patient then underwent conservative surgery

6. Non-neoplastic disease of the scrotum and testis

6.1 Varicocele (scrotal varices)

Varicocele is a common cause of scrotal mass, and is estimated to affect 15% of males. It frequently causes symptoms in young males. Symptoms of varicoceles may include dull ache of the affected testis especially after prolonged standing or exercise. Varicoceles have also frequently been diagnosed during studies for male infertility (Tsao et al., 2009).

Varicoceles are more common in left-sided testicles (90%), and can occur bilaterally. By definition, a varicocele is the dilatation of the pampiniform plexus, which are the veins that

drain the testis. The testicular vein (internal spermatic vein) drains to the renal vein on the left side and to the inferior vena cava on the right side. The anatomical characteristics of these drainage routes means that there is a steeper insertion of the internal spermatic vein on the left side, which makes it prone to vascular reflux as a result of gravity. It is also believed that incompetent venous valves will cause reflux within the spermatic veins, which can be responsible for venous reflux back into the testis.

Diagnosing varicoceles is straightforward with physical examination. Varicoceles can be classified as mild, moderate or severe. With severe varicocele, one can easily observe “a bag-of-worms” appearance while the patient is standing. When in doubt, or there is a need to evaluate the underlying testes, ultrasonography with color flow imaging can offer clear information. Most authors agree that dilated veins greater than 2-3 mm in diameter with a change in the direction of flow during the Valsalva maneuver are compatible with the diagnosis of a varicocele.

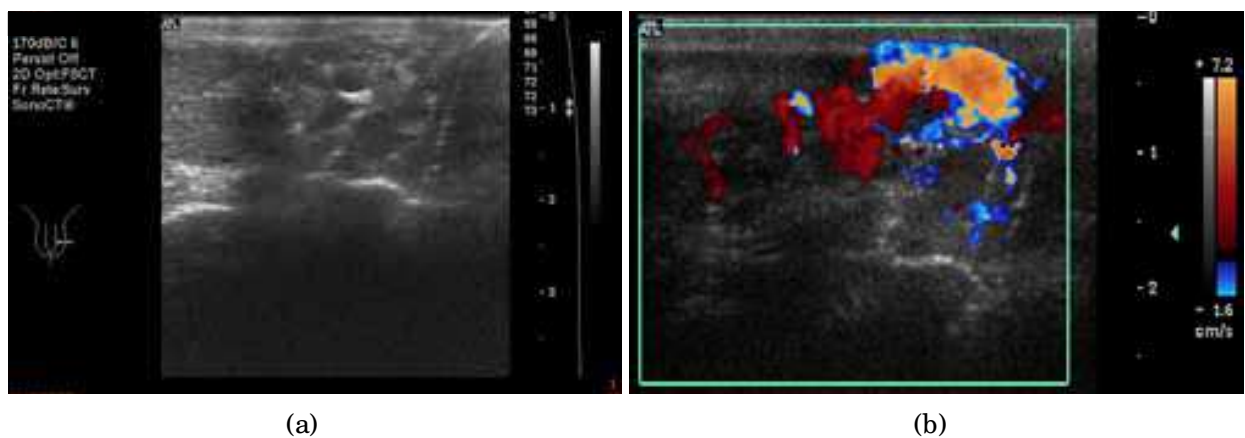


Fig. 13. Scrotal varices. A 15-year-old male presented with dull ache and a left upper scrotal mass. (a) Upper scrotal transverse scan showed multiple hypoechoic vascular channels. (b) The Valsalva maneuver confirmed the reversed venous flow within the varicocele

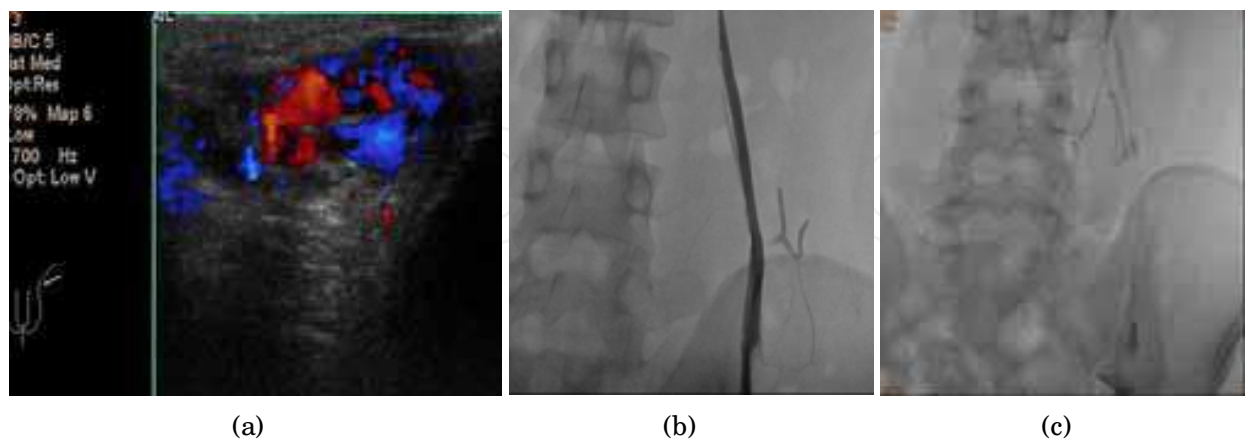


Fig. 14. Recurrent varicoceles. A 21-year-old male presented with a recurrent scrotal mass after a high ligation of internal spermatic vein (ISV) 2 years previously. (a) Sonographic diagnosis of reflux flow in the dilated left pampiniform plexus; (b) trans-jugular venography demonstrated patency of the left ISV; (c) embolization with coils successfully treated the recurrence

6.2 Hydrocele (hydrocele of the tunica vaginalis)

A hydrocele of the testis indicated fluid accumulation between the two layers of the tunica vaginalis. The tunica vaginalis is a remnant of peritoneum, which should close before birth. In children, a hydrocele is usually congenital and can present with an inguinal hernia. In the adult population, the hydrocele is usually secondary to infections (e.g., epididymitis), renal transplantation, peritoneal dialysis, testicular cancers, or torsion. Hydrocele affects 1% of adult men and is bilateral in 10% of all cases. Bilateral hydroceles should raise the suspicion of other underlying systemic diseases.

A hydrocele typically presents as a gradually enlarged testicle with no obvious pain. Severe and abrupt pain can indicate that the underlying condition should be investigated. During physical examination, good transillumination indicates a fluid content within the scrotum. Definite diagnosis can be made by ultrasonography. Scrotal ultrasound plays an important role not only for the diagnosis of hydrocele, but also to seek other possible etiologies, such as torsion, inflammation or malignancy.

Ultrasonographic findings of hydrocele are of typically pure anechoic fluid collection outside the tunica albuginea (Akin et al., 2004), but the fluid can be mixed with internal echoes in chronic cases. Some complex cases may demonstrate septations and loculations.

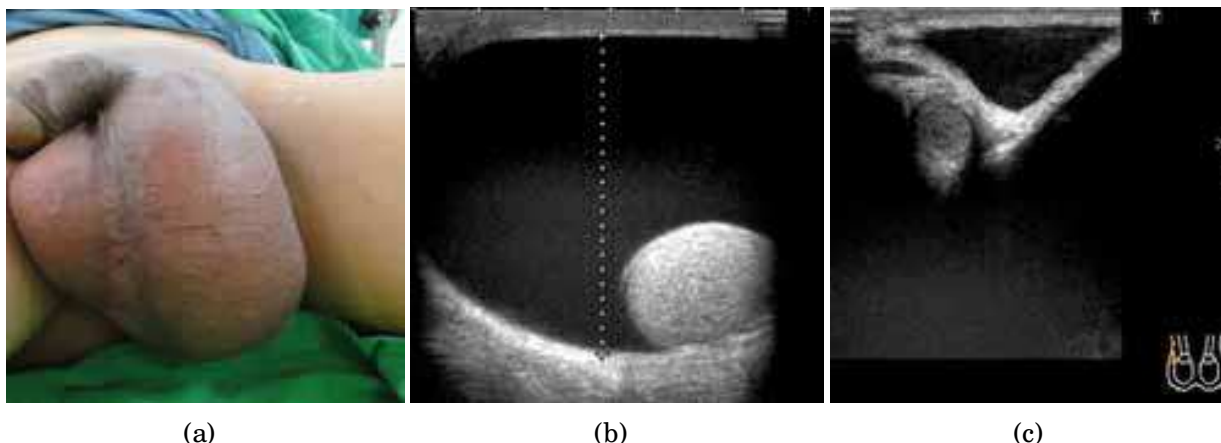


Fig. 15. A 58-year-old male presented with a feeling of heaviness and a gradually enlarged left scrotum. (a) A grossly enlarged left scrotum that was not tender; (b) transverse scan showed a marked accumulation of anechoic fluid and the testis was pushed aside; and (c) the hydrocele extends to the level of the external inguinal ring

6.3 Spermatocoele

A spermatocoele is a benign cystic lesion that contains sperm. It is commonly found in the epididymal head. Many spermatocoeles are incidental, and are found during ultrasound screening in middle- to old-aged patients. The size of a spermatocoele may vary from a few millimeters to several centimeters. Most spermatocoeles do not cause symptoms, and the patient may present with a soft palpable mass inside the scrotum. In some cases, discomfort secondary to the mass effect may be present.

The etiology of spermatocoele remains unclear. Most authors suggest that an obstruction in the efferent ductules is the origin of the disease. It is expected to grow slowly. Therefore,

aspiration of the cystic lesion will not solve the problem, and surgical excision offers the only curative approach for this disorder.

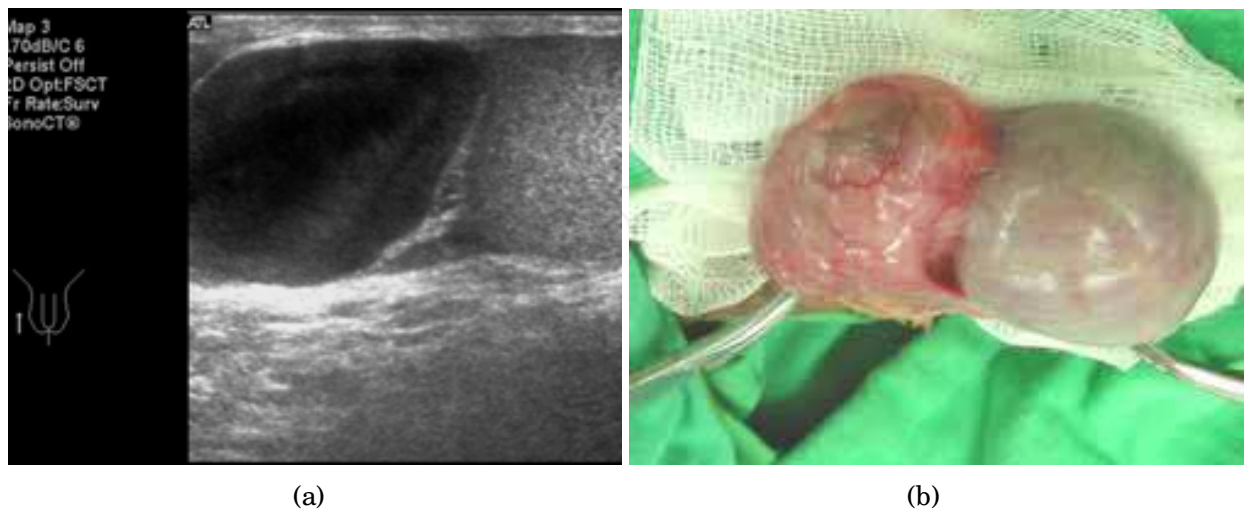


Fig. 16. Epididymal spermatocele. A 56-year-old male presented with a slow-growing right scrotal mass that developed over several years. (a) Longitudinal scan showed a well-defined, 3-cm cystic lesion at right epididymal head with faint internal echogenicity; (b) scrotal exploration revealed findings that were compatible with the diagnosis of spermatocele

6.4 Testicular microlithiasis

Testicular microlithiasis (TM) is usually incidentally diagnosed by ultrasonography. TM may be correlated with testicular cancer and carcinoma in situ, although this issue remains controversial. In addition, TM is reported to be associated with various conditions, including male infertility, testicular atrophy, cryptorchidism, gonadal dysgenesis, Klinefelter syndrome, male pseudohermaphroditism, testicular torsion and varicocele. By definition, TM consists of small hyperechoic spots that less than 3 mm in size in the testis; the spots are usually multiple. A classic TM was defined as five or more microliths found on an

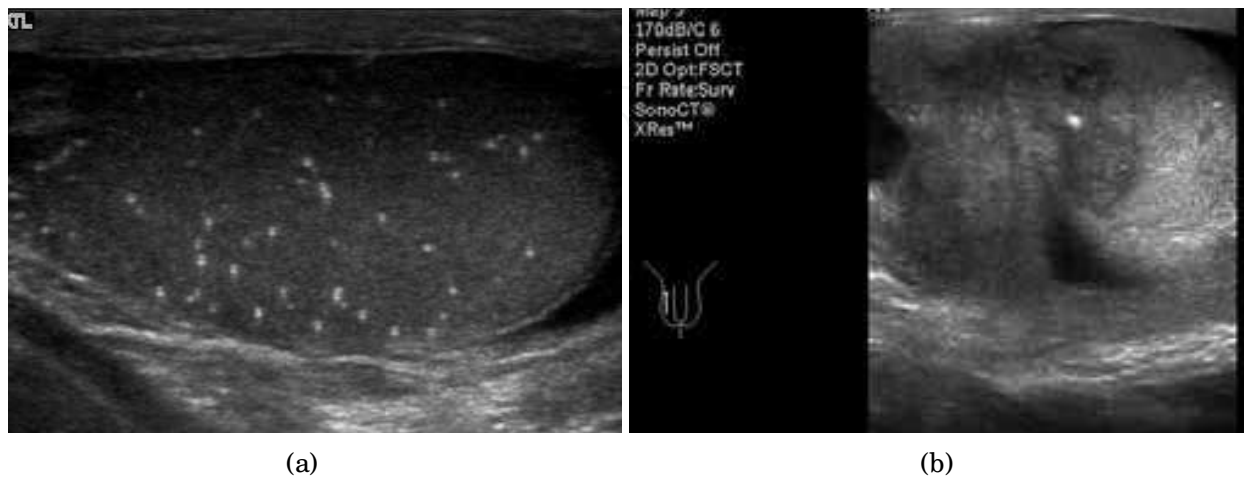

Fig. 17. Two cases of TM associated with germ cell neoplasms. (a) Classic TM associated with a testicular cancer in the contralateral testis; (b) limited TM associated with an ipsilateral testicular germ cell tumor

ultrasound scan, and fewer the five microliths would be recognized as a form of limited TM. Hyperechoic spots on sonography are usually found without acoustic shadows. The incidence of TM ranges from 0.6%-9% in various retrospective studies (Chen et al., 2010). We also noted that patients with a malignant testicular neoplasm have a higher prevalence of TM (Ou et al., 2007).

6.5 Scrotal wall abscess

Abnormal scrotal conditions can be missed on routine ultrasonography if the clinical information is ignored. Detecting common scrotal disorders, such as an abscess, sebaceous cysts, lipomas, and edematous skin, should be the final step of the sonographic evaluation. The examiner is suggested to ask relevant questions to the patient in order to locate scrotal abnormalities accurately.

The sonographic patterns of scrotal abscesses range from anechoic to irregularly hyperechoic, with areas of internal echoes, septae, or even gas. Manually compressing with the ultrasound probe upon the abscess may induce motion within the abscess material.

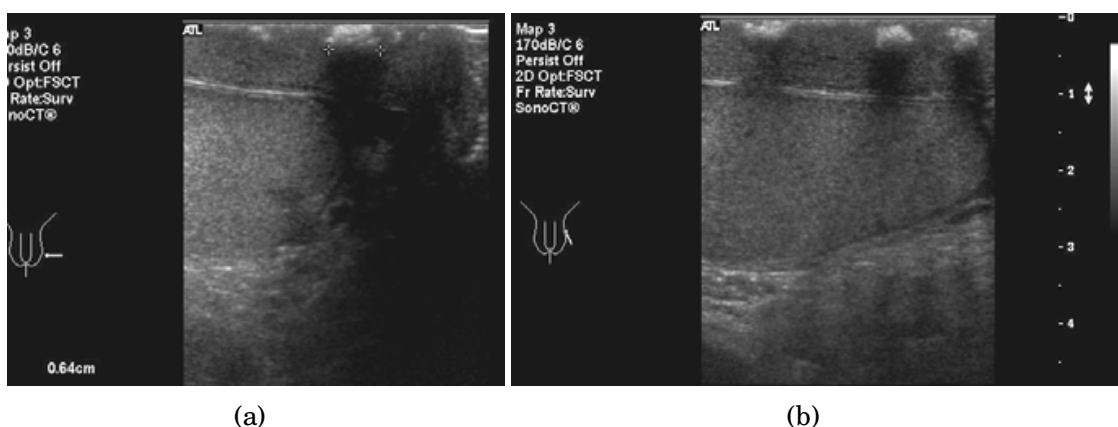

Fig. 18. A 52-year-old suffered a perineal contusion 3 months previously. He presented with pain and induration over the left lower scrotum. (a) Transverse scan showed scrotal wall edematous changes, with hypoechoic areas and calcified lesions within the skin; (b) a longitudinal scan revealed similar findings that were compatible with chronic inflammatory changes

7. Conclusion

Ultrasound is convenient and important for the diagnosis of various scrotal abnormalities in clinical practice. Most notably, it is a time-saving procedure that requires only a very short time to train personnel to recognize urological emergencies. Nonetheless, a detailed medical history and physical examination should always precede the ultrasound study. Scrotal ultrasound offers clear information on whether a mass is intra- or extra-testicular, is cystic or solid, has increased or decreased focal flow, and whether the normal testicular ovoid shape is intact after a direct trauma.

A physician that performs scrotal ultrasound studies should be able to identify testicular torsion and testicular rupture in the emergency room setting, as both of these conditions require immediate surgical intervention. Lastly, although ultrasonography offers many

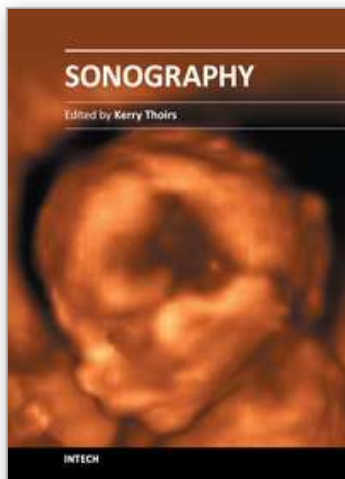
important diagnostic clues, it is not a perfect diagnostic tool. Adjunctive diagnostic tools, such as CT or MRI scanning or surgical exploration, may be needed to make a definitive diagnosis in difficult cases.

8. Acknowledgment

We thank Dr. Sheng-Tang Wu, Dr. Feng-Ping Chuang, Dr. Chi-Wei Tsao and Dr. En-Meng (TSGH-urology) for contributing cases to this chapter. We also thank Dr. Dah-Shyong Yu (urology), Dr. Sun-Yran Chang (urology) and Dr. Ching-Junn Wu (radiology) for their long-term education and support with our imaging studies.

9. References

- Akin, EA., Khati, NJ, Hill, MC., et al. (2004). Ultrasound of the scrotum. *Ultrasound Q*, Vol. 20, No.4, (December 2004), pp.181-200, ISSN 0894-8771
- Bartolotta, TV., Midiri, M., Caruso, G. et al. (2000). Necrotizing fasciitis of the scrotum (Fournier's gangrene): ultrasound findings. *Radiol Med*, Vol. 100, No.6, (April 2001), pp. 510-512, ISSN 0033-8362
- Bluth, EL., Arger, PH., Benson, CB., et al. (2001). *Ultrasonography in urology* (1st edition), Thieme, ISBN 1588900517, New York
- Campbell, MF., Wein, AJ, Kavoussi, LR. (2007). *Campbell-Walsh urology* (9th edition), W.B. Saunders, ISBN 1416029664, Philadelphia
- Chen, JL., Chou, YH., Tiu, CM., et al. (2010). Testicular microlithiasis: analysis of prevalence and associated testicular cancer in Taiwanese men. *J Clin Ultrasound*, Vol. 38, No.6, (July 2010), pp. 309-313. ISSN 1097-0096
- Cokkinos, DD., Antypa, E., Tserotas, P., et al. (2011). Emergency ultrasound of the scrotum: a review of the commonest pathologic conditions. *Curr Probl Diagn Radiol*, Vol. 40, No.1, (January 2011), pp. 1-14, ISSN 1535-6302
- Datta, V., Dhillon, G., Voci, S. (2011). Testicular torsion/ detorsion. *Ultrasound Q*, Vol. 27, No.2, (June 2011), pp. 127-128, ISSN 1536-0253
- de Cassio Saito, O., de Barros, N., Chammas, MC. et al. (2004). Ultrasound of tropical and infectious diseases that affect the scrotum. *Ultrasound Q*, Vol. 20, No.1, (March 2004), pp. 12-18, ISSN 0894-8771
- Meng, E., Sun, GH., Wu, CJ, et al. (2004). Epidermoid cysts of the testes in Taiwanese men. *Arch Androl*, Vol. 50, No.3, (May 2004), pp. 201-205, ISSN 0148-5016
- Ou, SM., Lee, SS., Tang, SH., et al. (2007). Testicular microlithiasis in Taiwanese men. *Arch Androl*, Vol. 53, No.6, (November 2007), pp. 339-344, ISSN 0148-5016
- Schmitz, D., Safranek, S. (2009). Clinical inquiries. How useful is a physical exam in diagnosing testicular torsion? *J Fam Pract*, Vol. 58, No.8, (August 2009), pp.433-434, ISSN 1533-7294



Sonography

Edited by Dr. Kerry Thoirs

ISBN 978-953-307-947-9

Hard cover, 346 pages

Publisher InTech

Published online 03, February, 2012

Published in print edition February, 2012

Medical sonography is a medical imaging modality used across many medical disciplines. Its use is growing, probably due to its relative low cost and easy accessibility. There are now many high quality ultrasound imaging systems available that are easily transportable, making it a diagnostic tool amenable for bedside and office scanning. This book includes applications of sonography that can be used across a number of medical disciplines including radiology, thoracic medicine, urology, rheumatology, obstetrics and fetal medicine and neurology. The book revisits established applications in medical sonography such as biliary, testicular and breast sonography and sonography in early pregnancy, and also outlines some interesting new and advanced applications of sonography.

How to reference

In order to correctly reference this scholarly work, feel free to copy and paste the following:

Shou-Hung Tang, Tai-Lung Cha and Guang-Huan Sun (2012). Clinical Perspectives of Scrotal Ultrasound in Urology, Sonography, Dr. Kerry Thoirs (Ed.), ISBN: 978-953-307-947-9, InTech, Available from: <http://www.intechopen.com/books/sonography/clinical-perspectives-of-scrotal-ultrasound-in-urology>

INTech
open science | open minds

InTech Europe

University Campus STeP Ri
Slavka Krautzeka 83/A
51000 Rijeka, Croatia
Phone: +385 (51) 770 447
Fax: +385 (51) 686 166
www.intechopen.com

InTech China

Unit 405, Office Block, Hotel Equatorial Shanghai
No.65, Yan An Road (West), Shanghai, 200040, China
中国上海市延安西路65号上海国际贵都大饭店办公楼405单元
Phone: +86-21-62489820
Fax: +86-21-62489821

© 2012 The Author(s). Licensee IntechOpen. This is an open access article distributed under the terms of the [Creative Commons Attribution 3.0 License](https://creativecommons.org/licenses/by/3.0/), which permits unrestricted use, distribution, and reproduction in any medium, provided the original work is properly cited.

IntechOpen

IntechOpen