

# We are IntechOpen, the world's leading publisher of Open Access books Built by scientists, for scientists

6,900

Open access books available

185,000

International authors and editors

200M

Downloads

Our authors are among the

154

Countries delivered to

TOP 1%

most cited scientists

12.2%

Contributors from top 500 universities



WEB OF SCIENCE™

Selection of our books indexed in the Book Citation Index  
in Web of Science™ Core Collection (BKCI)

Interested in publishing with us?  
Contact [book.department@intechopen.com](mailto:book.department@intechopen.com)

Numbers displayed above are based on latest data collected.  
For more information visit [www.intechopen.com](http://www.intechopen.com)



# Sonography of the Scrotum

Chee-Wai Mak and Wen-Sheng Tzeng

*Department of Medical Imaging, Chi Mei Medical Center, Tainan, Taiwan*

*Central Taiwan University of Science and Technology, Taichung, Taiwan*

*Chung Hua University of Medical Technology, Tainan, Taiwan*

*Republic of China*

## 1. Introduction

Although the development of new imaging modality such as computerized tomography and magnetic resonance imaging have open a new era for medical imaging, high resolution sonography remains as the initial imaging modality of choice for evaluation of scrotal disease. Many of the disease processes, such as testicular torsion, epididymo-orchitis, and intratesticular tumor, produce the common symptom of pain at presentation, and differentiation of these conditions and disorders is important for determining the appropriate treatment. High resolution ultrasound helps in better characterize some of the intrascrotal lesions, and suggest a more specific diagnosis, resulting in more appropriate treatments and avoiding unnecessary operation for some of the diseases.

## 2. Imaging technique

For any scrotal examination, thorough palpation of the scrotal contents and history taking should precede the sonographic examination. Patients are usually examined in the supine position with a towel draped over his thighs to support the scrotum. Warm gel should always be used because cold gel can elicit a cremasteric response resulting in thickening of the scrotal wall; hence a thorough examination is difficult to be performed. A high resolution, near-focused, linear array transducer with a frequency of 7.5 MHz or greater is often used because it provides increased resolutions of the scrotal contents. Images of both scrotum and bilateral inguinal regions are obtained in both transverse and longitudinal planes. Color Doppler and pulsed Doppler examination is subsequently performed, optimized to display low-flow velocities, to demonstrate blood flow in the testes and surrounding scrotal structures. In evaluation of acute scrotum, the asymptomatic side should be scanned first to ensure that the flow parameters are set appropriately. A transverse image including all or a portion of both testicles in the field of view is obtained to allow side-to-side comparison of their sizes, echogenicity, and vascularity. Additional views may also be obtained with the patient performing Valsalva maneuver.

## 3. Anatomy

The normal adult testis is an ovoid structure measuring 3 cm in anterior-posterior dimension, 2–4 cm in width, and 3–5 cm in length. The weight of each testis normally ranges

from 12.5 to 19 g. Both the sizes and weights of the testes normally decrease with age. At ultrasound, the normal testis has a homogeneous, medium-level, granular echotexture. The testicle is surrounded by a dense white fibrous capsule, the tunica albuginea, which is often not visualized in the absence of intrascrotal fluid. However, the tunica is often seen as an echogenic structure where it invaginates into the testis to form the mediastinum testis [Fig. 1]. In the testis, the seminiferous tubules converge to form the rete testes, which is located in the mediastinum testis. The rete testis connects to the epididymal head via the efferent ductules. The epididymis is located posterolateral to the testis and measures 6–7 cm in length. At sonography, the epididymis is normally iso- or slightly hyperechoic to the normal testis and its echo texture may be coarser. The head is the largest and most easily identified portion of the epididymis. It is located superior-lateral to the upper pole of the testicle and is often seen on paramedian views of the testis [Fig. 2]. The normal epididymal body and tail are smaller and more variable in position.

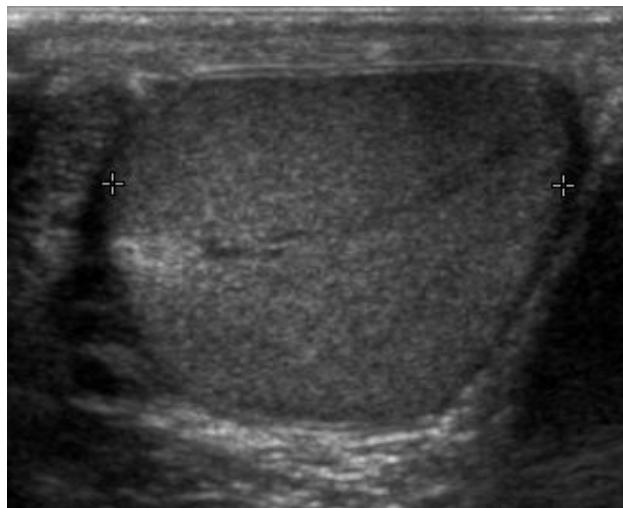


Fig. 1. Sonography of a normal testis. The normal testis presents as a structure having homogeneous, medium level, granular echotexture. The mediastinum testis appears as the hyperechoic region located at the periphery of the testis as seen in this figure

The testis obtains its blood supply from the deferential, cremasteric and testicular arteries. The right and left testicular arteries, branches of the abdominal aorta, arise just distal to the renal arteries, provide the primary vascular supply to the testes. They course through the inguinal canal with the spermatic cord to the posterior superior aspect of the testis. Upon reaching the testis, the testicular artery divides into branches, which penetrate the tunica albuginea and arborize over the surface of the testis in a layer known as tunica vasculosa. Centripetal branches arising from the capsular arteries carry blood toward the mediastinum, where they divide to form the recurrent rami that carry blood away from the mediastinum into the testis. The deferential artery, a branch of the superior vesicle artery and the cremasteric artery, a branch of the inferior epigastric artery, supply the epididymis, vas deferens, and peritesticular tissue.

Four testicular appendages have been described: the appendix testis, the appendix epididymis, the vas aberrans, and the paradidymis. They are all remnants of embryonic ducts (Dogra et al 2003, as cited in Cook and Dewbury, 2000). Among them, the appendix testis and the appendix epididymis are usually seen at scrotal US. The appendix testis is a

mullerian duct remnant and consists of fibrous tissue and blood vessels within an envelope of columnar epithelium. The appendix testis is attached to the upper pole of the testis and found in the groove between the testis and the epididymis. The appendix epididymis is attached to the head of the epididymis. The spermatic cord, which begins at the deep inguinal ring and descends vertically into the scrotum is consists of vas deferens, testicular artery, cremasteric artery, deferential artery, pampiniform plexuses, genitofemoral nerve, and lymphatic vessel.

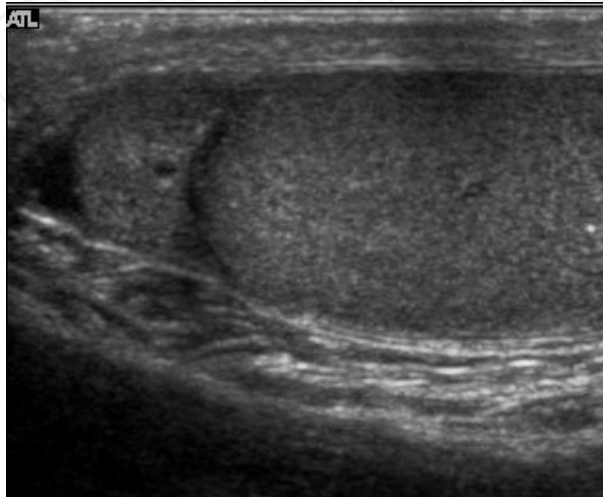


Fig. 2. Normal epididymal head. The epididymal head, usually iso- or slightly hyperechoic than the testis is seen located cephalad to the testis

## 4. Intratesticular tumors

One of the primary indications for scrotal sonography is to evaluate for the presence of intratesticular tumor in the setting of scrotal enlargement or a palpable abnormality at physical examination. It is well known that the presence of a solitary intratesticular solid mass is highly suspicious for malignancy. Conversely, the vast majority of extratesticular lesions are benign.

### 4.1 Germ cell tumors

Primary intratesticular malignancy can be divided into germ cell tumors and non-germ cell tumors. Germ cell tumors are further categorized as either seminomas or nonseminomatous tumors. Other malignant testicular tumors include those of gonadal stromal origin, lymphoma, leukemia, and metastases.

#### 4.1.1 Seminoma

Approximately 95% of malignant testicular tumors are germ cell tumors, of which seminoma is the most common. It accounts for 35%–50% of all germ cell tumors (Woodward et al, 2002). Seminomas occur in a slightly older age group when compared with other nonseminomatous tumor, with a peak incidence in the fourth and fifth decades. They are less aggressive than other testicular tumors and usually confined within the tunica albuginea at presentation. Seminomas are associated with the best prognosis of the germ cell tumors because of their high sensitivity to radiation and chemotherapy (Kim et al, 2007).

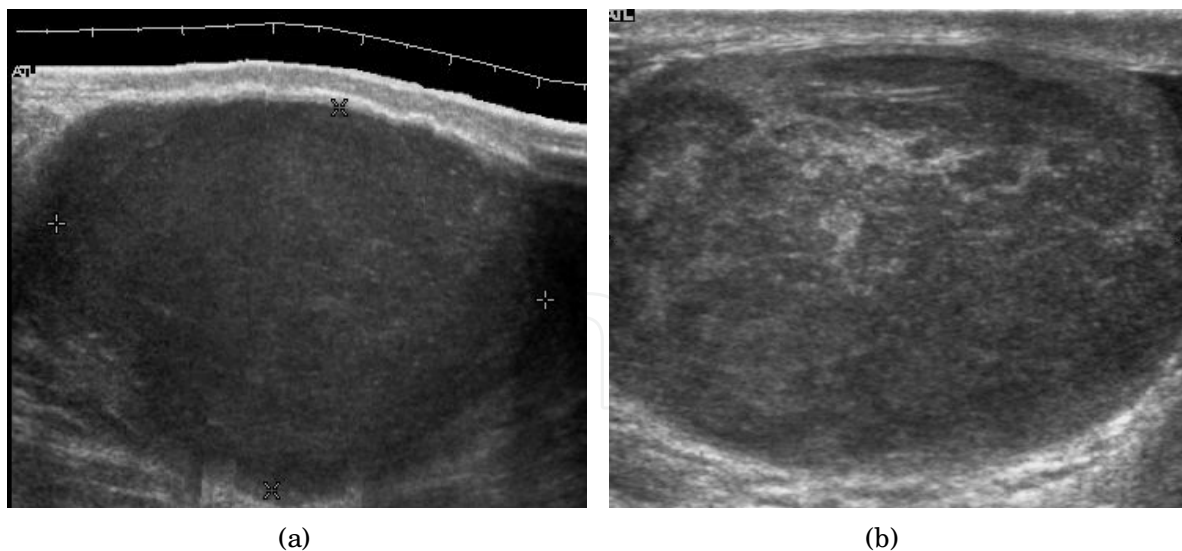


Fig. 3. Seminoma. (a) Seminoma usually presents as a homogeneous hypoechoic nodule confined within the tunica albuginea. (b) Sonography shows a large heterogeneous mass is seen occupying nearly the whole testis but still confined within the tunica albuginea, it is rare for seminoma to invade to peritesticular structures

Seminoma is the most common tumor type in cryptorchid testes. The risk of developing a seminoma is increased in patients with cryptorchidism, even after orchiopexy. There is an increased incidence of malignancy developing in the contralateral testis too, hence sonography is sometimes used to screen for an occult tumor in the remaining testis.

On US images, seminomas are generally uniformly hypoechoic, larger tumors may be more heterogeneous [Fig. 3]. Seminomas are usually confined by the tunica albuginea and rarely extend to peritesticular structures. Lymphatic spread to retroperitoneal lymph nodes and hematogenous metastases to lung, brain, or both are evident in about 25% of patients at the time of presentation (Dogra et al 2003, as cited in Guthrie & Fowler, 1992)

#### 4.1.2 Nonseminomatous germ cell tumors

Nonseminomatous germ cell tumors most often affect men in their third decades of life. Histologically, the presence of any nonseminomatous cell types in a testicular germ cell tumor classifies it as a nonseminomatous tumor, even if most of the tumor cells belong to seminoma. These subtypes include yolk sac tumor, embryonal cell carcinoma, teratocarcinoma, teratoma, and choriocarcinoma. Clinically nonseminomatous tumors usually present as mixed germ cell tumors with variety cell types and in different proportions.

**Embryonal cell carcinoma** --- Embryonal cell carcinomas, a more aggressive tumor than seminoma usually occurs in men in their 30s. Although it is the second most common testicular tumor after seminoma, pure embryonal cell carcinoma is rare and constitutes only about 3 percent of the nonseminomatous germ cell tumors. Most of the cases occur in combination with other cell types.

At ultrasound, embryonal cell carcinomas are predominantly hypoechoic lesions with ill defined margins and an inhomogeneous echotexture. Echogenic foci due to hemorrhage, calcification, or fibrosis are commonly seen. Twenty percent of embryonal cell carcinomas



have cystic components (Dogra et al, 2003). The tumor may invade into the tunica albuginea resulting in contour distortion of the testis [Fig. 4].

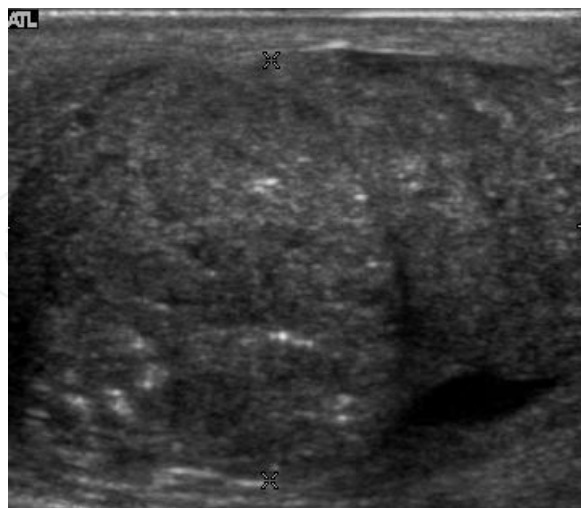

Fig. 4. Embryonal cell carcinoma. Longitudinal ultrasound image of the testis shows an irregular heterogeneous mass that forms an irregular margin with the tunica albuginea

**Yolk sac tumor** --- Yolk sac tumors also known as endodermal sinus tumors account for 80% of childhood testicular tumors, with most cases occurring before the age of 2 years (Woodward et al, 2002, as cited in Frush & Sheldon 1998). Alpha-fetoprotein is normally elevated in greater than 90% of patients with yolk sac tumor (Woodward et al, 2002, as cited in Ulbright et al, 1999). In its pure form, yolk sac tumor is rare in adults; however yolk sac elements are frequently seen in tumors with mixed histologic features in adults and thus indicate poor prognosis. The US appearance of yolk sac tumor is usually nonspecific and consists of inhomogeneous mass that may contain echogenic foci secondary to hemorrhage.

**Choriocarcinoma** --- Choriocarcinoma is a highly malignant testicular tumor that usually develops in the 2<sup>nd</sup> and 3<sup>rd</sup> decades of life. Pure choriocarcinomas are rare and represent only less than 1 percent of all testicular tumors (Woodward et al, 2002). Choriocarcinomas are composed of both cytotrophoblasts and syncytiotrophoblasts, with the latter responsible for the clinical elevation of human chorionic gonadotrophic hormone level. As microscopic vascular invasion is common in choriocarcinoma, hematogeneous metastasis, especially to the lungs is common (Dogra et al, 2003, as cited in Geraghty et al, 1998). Many choriocarcinomas show extensive hemorrhagic necrosis in the central portion of the tumor; this appears as mixed cystic and solid components (Dogra et al 2003, as cited in Hamm, 1997) at ultrasound.

**Teratoma** --- Although teratoma is the second most common testicular tumor in children, it affects all age groups. Mature teratoma in children is often benign, but teratoma in adults, regardless of age, should be considered as malignant. Teratomas are composed of all three germ cell layers, i.e. endoderm, mesoderm and ectoderm. At ultrasound, teratomas generally form well-circumscribed complex masses. Echogenic foci representing calcification, cartilage, immature bone and fibrosis are commonly seen [Fig. 5]. Cysts are also a common feature and depending on the contents of the cysts i.e. serous, mucoid or keratinous fluid, it may present as anechoic or complex structure [Fig. 6].

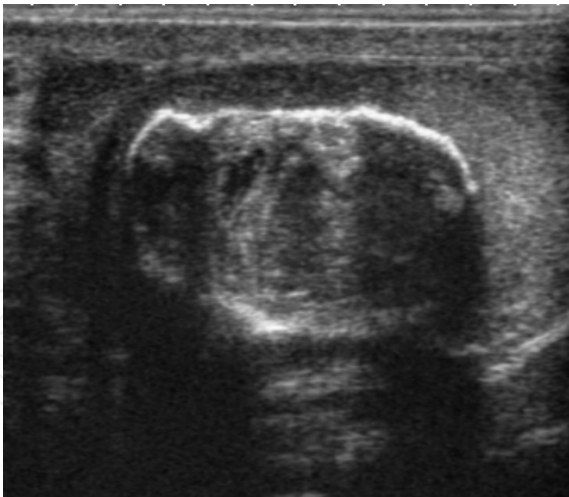

Fig. 5. Teratoma. A plaque like calcification with acoustic shadow is seen in the testis

4.2 Non-germ cell tumours

4.2.1 Sex cord-stromal tumours

Sex cord-stromal (gonadal stromal) tumors of the testis, account for 4 per cent of all testicular tumors (Dogra et al, 2003). The most common are Leydig and Sertoli cell tumors. Although the majority of these tumors are benign, these tumors can produce hormonal changes, for example, Leydig cell tumor in a child may produce isosexual virilization. In adult, it may have no endocrine manifestation or gynecomastia, and decrease in libido may result from production of estrogens. These tumors are typically small and are usually discovered incidentally. They do not have any specific ultrasound appearance but appear as well-defined hypoechoic lesions. These tumors are usually removed because they cannot be distinguished from malignant germ cell tumors.

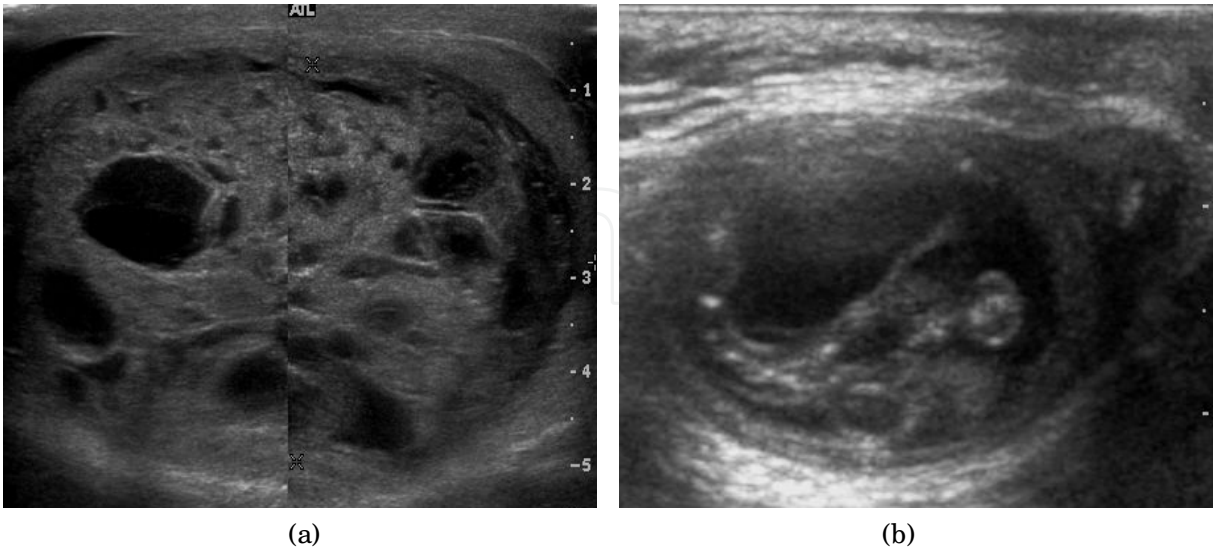


Fig. 6. Mature cystic teratoma. (a) Composite Image. Mature cystic teratoma in a 29 year-old man. Longitudinal sonography image of the right testis shows a multilocular cystic mass. (b) Mature cystic teratoma in a 6 year-old boy. Longitudinal sonography of the right testis shows a cystic mass contains calcification with no obvious acoustic shadow

Leydig cell tumors are the most common type of sex cord–stromal tumor of the testis, accounting for 1%–3% of all testicular tumors. They can be seen in any age group, they are generally small solid masses, but they may show cystic areas, hemorrhage, or necrosis (Woodward et al 2002, as cited in Ulbright et al, 1999). Their sonographic appearance is variable and is indistinguishable from that of germ cell tumors (Woodward et al 2002, as cited in Avery et al, 1991)

Sertoli cell tumors are less common, constituting less than 1% of testicular tumors. They are less likely than Leydig cell tumors to be hormonally active, but gynecomastia can occur (Woodward et al 2002, as cited in Ulbright et al, 1999). Sertoli cell tumors are typically well circumscribed, unilateral, round to lobulated masses.

#### 4.2.2 Lymphoma

Clinically lymphoma can manifest in one of three ways: as the primary site of involvement, or as a secondary tumor such as the initial manifestation of clinically occult disease or recurrent disease. Although lymphomas constitute 5% of testicular tumors and are almost exclusively diffuse non-Hodgkin B-cell tumors, only less than 1 % of non-Hodgkin lymphomas involve the testis (Doll and Weiss 1986).

Patients with testicular lymphoma are usually old aged around 60 years of age, present with painless testicular enlargement and less commonly with other systemic symptoms such as weight loss, anorexia, fever and weakness. Bilateral testicle involvements are common and occur in 8.5% to 18% of cases (Dogra et al, 2003, as cited in Horstman et al, 1992). At sonography, most lymphomas are homogeneous and diffusely replace the testis [Fig. 7]. However focal hypoechoic lesions can occur, hemorrhage and necrosis are rare. At times, the sonographic appearance of lymphoma is indistinguishable from that of the germ cell tumors [Fig. 8], then the patient's age at presentation, symptoms, and medical history, as well as multiplicity and bilaterality of the lesions, are all important factors in making the appropriate diagnosis.

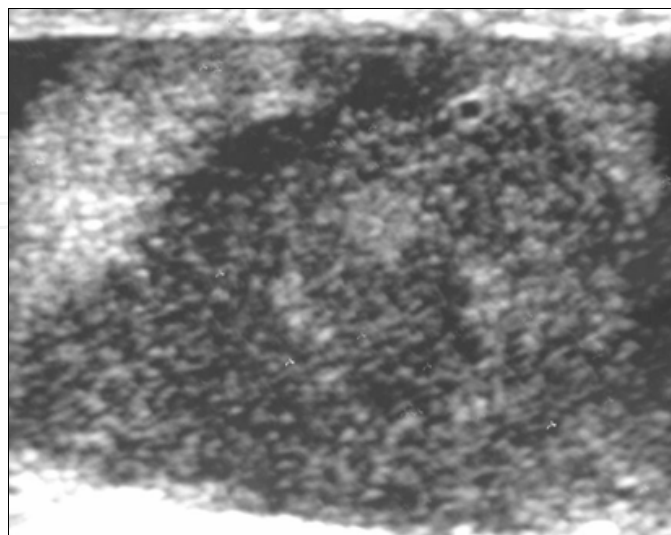


Fig. 7. Lymphoma. Lymphoma in a 61 year-old man. Longitudinal sonography shows an irregular hypoechoic lesion occupied nearly the whole testis



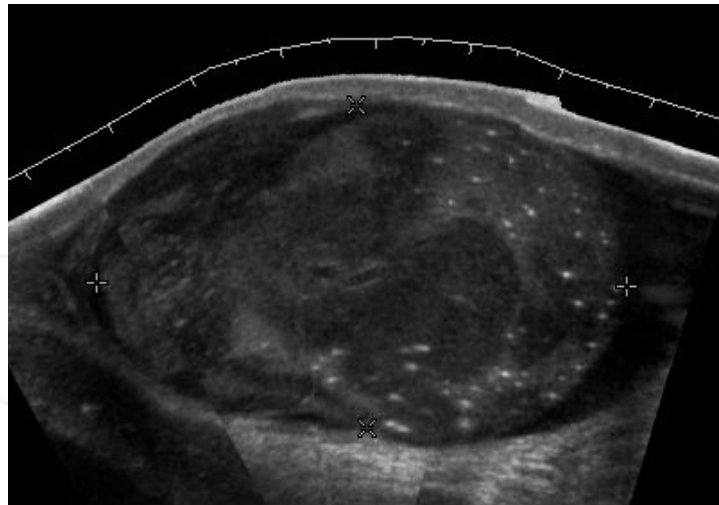


Fig. 8. Primary Lymphoma. Longitudinal sonography of a 64 year-old man shows a lymphoma mimicking a germ cell tumor

#### 4.2.3 Leukemia

Primary leukemia of the testis is rare. However due to the presence of blood-testis barrier, chemotherapeutic agents are unable to reach the testis, hence in boys with acute lymphoblastic leukemia, testicular involvement is reported in 5% to 10% of patients, with the majority found during clinical remission (Dogra et al, 2003). The sonographic appearance of leukemia of the testis can be quite varied, as the tumors may be unilateral or bilateral, diffuse or focal, hypoechoic or hyperechoic (Woodward et al, 2002). These findings are usually indistinguishable from that of the lymphoma [Fig. 9].

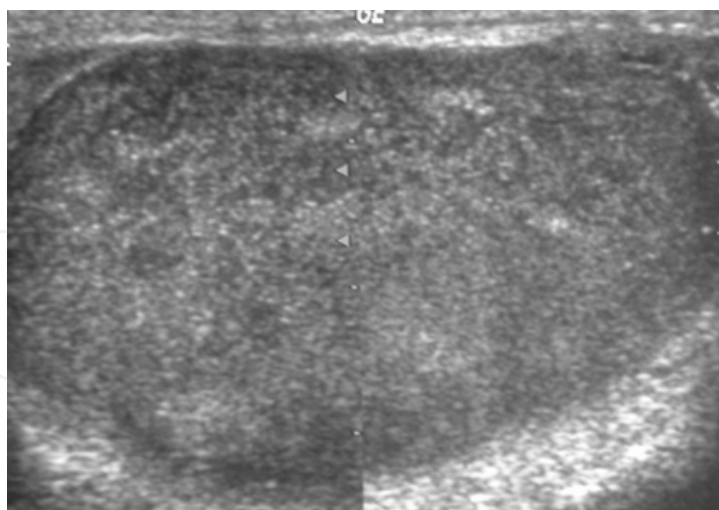


Fig. 9. Leukemia. Diffuse hypoechoic infiltrative lesions are seen involving the whole testis, indistinguishable from that of the lymphoma

#### 4.3 Epidermoid cyst

Epidermoid cysts, also known as keratocysts, are benign epithelial tumors which usually occur in the second to fourth decades and accounts for only 1–2% of all intratesticular

tumors. As these tumors have a benign biological behavior and with no malignant potential, preoperative recognition of this tumor is important as this will lead to testicle preserving surgery (enucleation) rather than unnecessary orchiectomy.

Clinically, epidermoid cyst cannot be differentiated from other testicular tumors, typically presenting as a non-tender, palpable, solitary intratesticular mass. Tumor markers such as serum beta-human chorionic gonadotropin and alpha-feto protein are negative.

The ultrasound patterns of epidermoid cysts are variable and include:

- i. A mass with a target appearance, i.e. a central hypoechoic area surrounded by an echolucent rim (Mak et al, 2007a, as cited in Maxwell & Mamtara, 1990);
- ii. An echogenic mass with dense acoustic shadowing due to calcification; (Mak et al, 2007a, as cited in Meiches & Nurenberg 1991);
- iii. A well-circumscribed mass with a hyperechoic rim (Mak et al, 2007a, as cited in Cohen 1984);
- iv. Mixed pattern having heterogeneous echotexture and poor-defined contour (Mak et al, 2007a, as cited in Atchley & Dewbury, 2000) and
- v. An onion peel appearance consisting of alternating rings of hyperechogenicities and hypoechogenicities (Mak et al, 2007a, as cited in Malvica, 1993).

However, these patterns, except the latter one, may be considered as non-specific as heterogeneous echotexture and shadowing calcification can also be detected in malignant testicular tumors (Mak et al, 2007a). The onion peel pattern of epidermoid cyst [Fig. 10] correlates well with the pathologic finding of multiple layers of keratin debris produced by the lining of the epidermoid cyst. This sonographic appearance should be considered characteristic of an epidermoid cyst and corresponds to the natural evolution of the cyst. Absence of vascular flow is another important feature that is helpful in differentiation of epidermoid cyst from other solid intratesticular lesions.

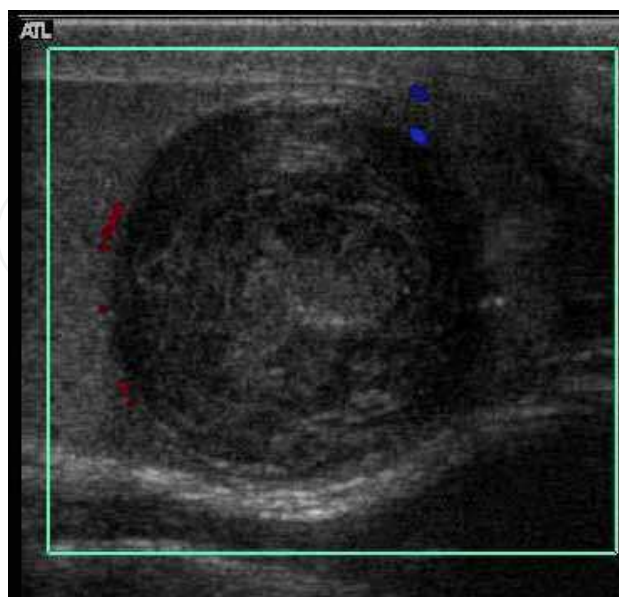


Fig. 10. Epidermoid cyst. Onion peel appearances of the tumor together with absence of vascular flow are typical findings of epidermoid cyst

## 5. Extratesticular tumors

Although most of the extratesticular lesions are benign, malignancy does occur; the most common malignant tumors in infants and children are rhabdomyosarcomas (Mak et al 2004, as cited in Green, 1986). Other malignant tumors include liposarcoma, leiomyosarcoma, malignant fibrous histiocytoma and mesothelioma.

### 5.1 Rhabdomyosarcoma

Rhabdomyosarcoma is the most common tumor of the lower genitourinary tract in children in the first two decades, it may develop anywhere in the body, and 4% occur in the paratesticular region (Mak et al 2004a, as cited in Hamilton et al, 1989) which carries a better outcome than lesions elsewhere in the genitourinary tract. Clinically, the patient usually presents with non-specific complaints of a unilateral, painless intrascrotal swelling not associated with fever. Transillumination test is positive when a hydrocele is present, often resulting in a misdiagnosis of epididymitis, which is more commonly associated with hydrocele.

The ultrasound findings of paratesticular rhabdomyosarcoma are variable. It usually presents as an echo-poor mass [Fig. 11a] with or without hydrocele (Mak et al 2004a, as cited in Solvietti et al, 1989). With color Doppler sonography [Fig. 11b] these tumors are generally hypervascular (Mak et al, 2004a).

### 5.2 Mesothelioma

Malignant mesothelioma is an uncommon tumor arising in body cavities lined by mesothelium. The majority of these tumors are found in the pleura, peritoneum and less frequently pericardium. As the tunica vaginalis is a layer of reflected peritoneum, mesothelioma can occur in the scrotal sac. Although trauma, herniorrhaphy and long term

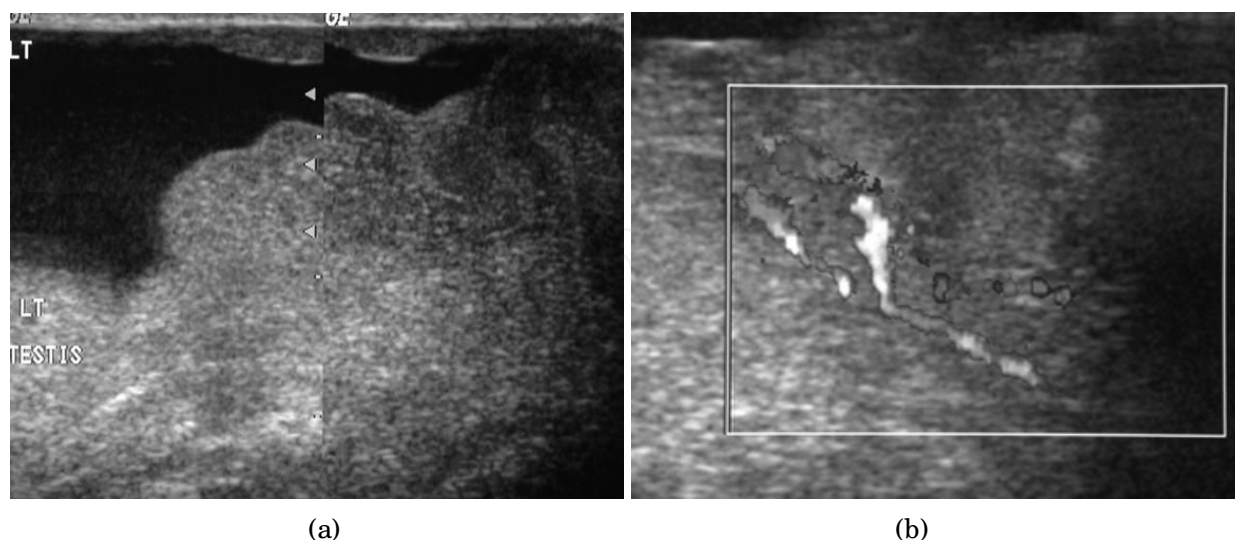


Fig. 11. Rhabdomyosarcoma (Reproduced with permission from British Institute of Radiology, British Journal of Radiology 2004; 77: 250–252). (a) Longitudinal section (composite image) of high resolution ultrasound of a 14 year-old boy shows a well defined hypoechoic extratesticular mass is found in the left scrotum, hydrocele is also present. (b) Color Doppler ultrasound shows that the mass is hypervascular

hydrocele (Mak et al, 2004b, as cited in Gurdal & Erol, 2001) have been considered as the predisposing factors for development of malignant mesothelioma, the only well established risk factor is asbestos exposure (Boyum & Wasserman, 2008). Patients with malignant mesothelioma of the tunica vaginalis frequently have a progressively enlarging hydrocele and less frequently a scrotal mass, rapid re-accumulation of fluid after aspiration raises the suggestion of malignancy (Mak et al, 2004b, as cited in Wolanske & Nino-Murcia, 2001).

The reported ultrasound features of mesothelioma of the tunica vaginalis testis are variable. Hydrocele, either simple or complex is present and may be associated with: (1) multiple extratesticular papillary projections of mixed echogenicity (Boyum & Wasserman 2008, as cited in Fields et al, 1992); (2) multiple extratesticular nodular masses of increased echogenicity (Boyum & Wasserman, 2008, as cited in Bruno et al, 2002 and Tyagi et al, 1989); (3) focal irregular thickening of the tunica vaginalis testis (Bruno et al, 2002); (4) a simple hydrocele as the only finding (Boyum & Wasserman, 2008, as cited in Jalon et al, 2003) and (5) A single hypoechoic mass located in the epididymal head (Boyum & Wasserman, 2008; Mak et al, 2004b). With color Doppler sonography, mesothelioma is hypovascular [Fig. 12] (Bruno et al, 2002; Mak et al, 2004b; Wang et al, 2005).

### 5.3 Leiomyoma

Leiomyomas are benign neoplasms that may arise from any structure or organ containing smooth muscle. The majority of genitourinary leiomyomas are found in the renal capsule, but this tumor has also been reported in the epididymis, spermatic cord, and tunica albuginea. Scrotal leiomyomas have been reported in patients from the fourth to ninth decades of life with most presenting during the fifth decade. These tumors are generally slow growth and asymptomatic. The sonographic features of leiomyomas have been reported as solid hypoechoic or heterogeneous masses that may or may not contain

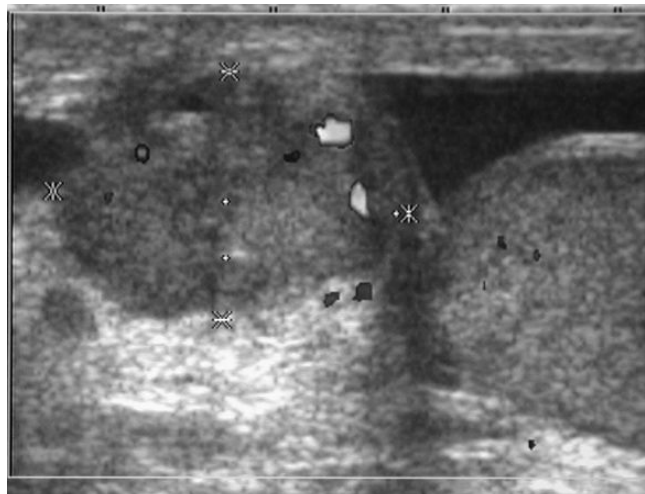


Fig. 12. Mesothelioma arising from the tunica vaginalis (Reproduced with permission from British Institute of Radiology, British Journal of Radiology 2004:77:780–781). Color Doppler ultrasound demonstrates a well-defined hypoechoic nodule occupying the left epididymal head, with a few areas of color flow demonstrated. The left testis is intact with no focal nodule detected. Hydrocele is also present



shadowing calcification (Mak et al, 2004c, as cited in Hricak & Filly, 1983 & Leonhardt, 1993). Other findings include whorl shaped configuration [Fig. 13a] of the nodule (Mak et al, 2004c) and multiple, narrow areas of shadowing not cast by calcifications [Fig. 13b], but corresponding to transition zones between the various tissue components of the mass (Mak et al, 2004c, as cited in Hertzberg et al, 1996) are characteristic of leiomyoma and may help differentiate it from other scrotal tumors.

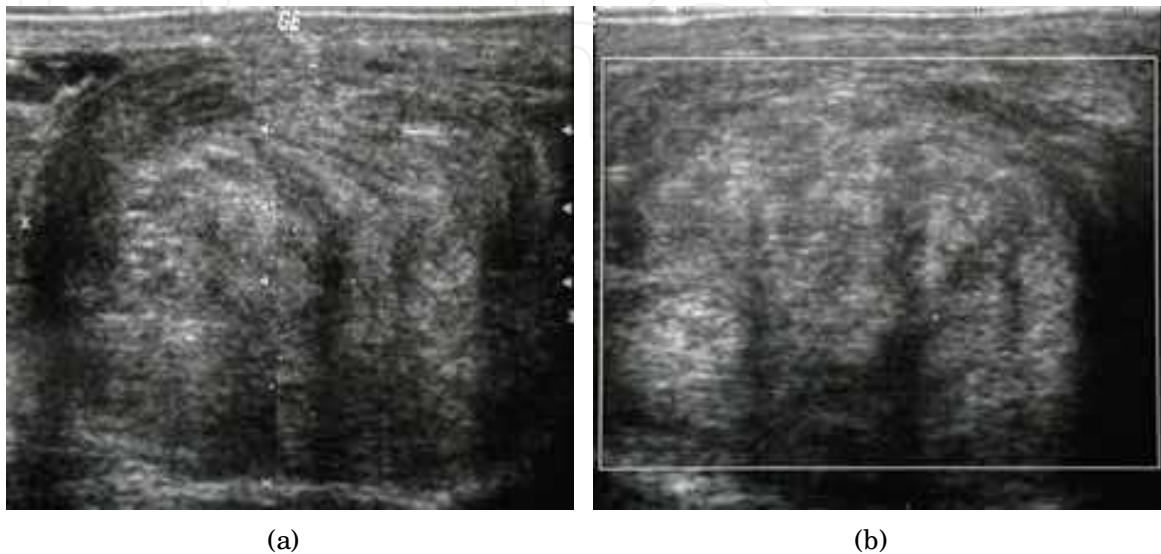


Fig. 13. Leiomyoma arising from tunica albuginea (Reproduced with permission from John Wiley and Sons publishing company License number 2643411100095, Journal of Clinical Ultrasound 2004; 32:309–311). (a) Montage of 2 contiguous sonograms of a 67 year-old man shows a well-defined extratesticular mass with a whorl-shaped echotexture. (b) Color Doppler sonogram shows no internal vascularity. Note the presence of multiple shadows not associated with echogenic foci in the mass

## 5.4 Fat containing tumors

### 5.4.1 Lipoma

Lipoma is the most common nontesticular intrascrotal tumor. It can be divided into 3 types depending upon the site of origination and spread:

1. Originate in the spermatic cord with spread to the scrotum;
2. Originate and develop within the cord (most common type) and
3. Originate and develop within the scrotum (Rosenberg & Williamson, 1989).

At ultrasound, lipoma is a well-defined, homogeneous, hyperechoic paratesticular lesion of varying size [Fig. 14]. The simple finding of an echogenic fatty mass within the inguinal canal, while suggestive of a lipoma, should also raise a question of fat from the omentum secondary to an inguinal hernia. However lipomas are well-defined masses, whereas herniated omentum appears to be more elongated and can be traced to the inguinal area, hence scanning along the inguinal canal as well as the scrotum is necessary to make the differential diagnosis. Magnetic resonance imaging and computerized tomography are helpful in doubtful cases.



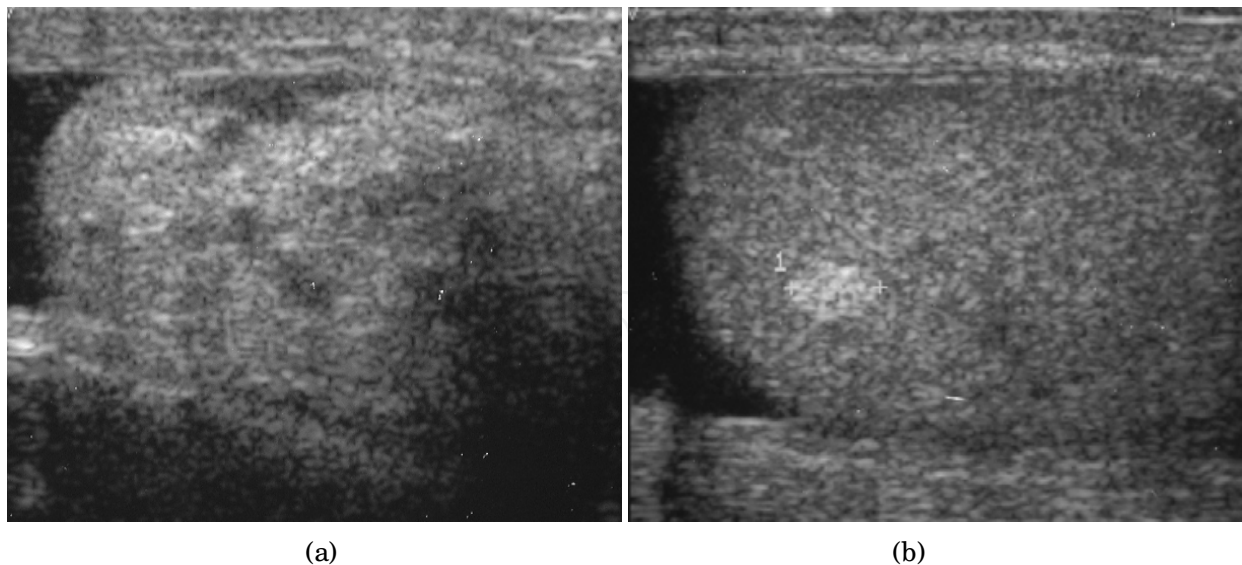


Fig. 14. Lipoma at spermatic cord and testicle. (a) Longitudinal scrotal sonography of a 61 year-old patient shows a well defined hyperechoic nodule is seen in the scrotum. (b) Scrotal sonography of the same patient shows a hyper echoic nodule in the left testis, pathology proved that this is a lipoma too

#### 5.4.2 Liposarcoma

Malignant extratesticular tumors are rare. Most of the malignant tumors are solid and have nonspecific features on ultrasonography. The majority of the malignant extratesticular tumors arise from spermatic cord with liposarcoma being the most common in adults (Woodward et al, 2003). On gross specimen, liposarcoma is a solid, bulky lipomatous tumor with heterogeneous architecture, often containing areas of calcification (Bostwick & Eble, 1997). Although the sonographic appearances of liposarcoma are variable and nonspecific, it still provides a clue about the presence of lipomatous matrix. Echogenic areas corresponding to fat often associated with poor sound transmission and areas of heterogeneous

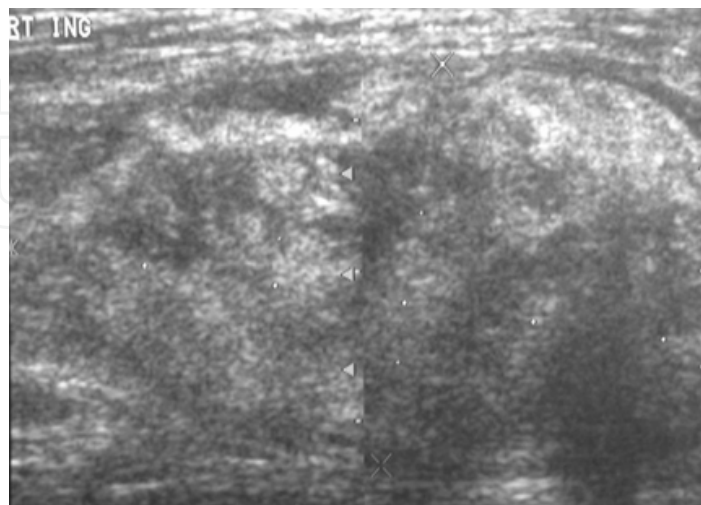


Fig. 15. Liposarcoma. A heterogeneous mass consists of an upper hyperechoic portion corresponds to lipomatous matrix and areas of hypoechogenicity corresponds to nonlipomatous component is seen

echogenicity corresponding to nonlipomatous component are present [Fig. 15]. Some liposarcomas may also mimic the sonographic appearance of lipomas [Fig. 16] and hernias that contain omentum, but lipomas are generally smaller and more homogeneous and hernias are elongated masses that can often be traced back to the inguinal canal. CT and MR imaging are more specific, as they can easily recognize fatty component along with other soft tissue component more clearly than ultrasound.

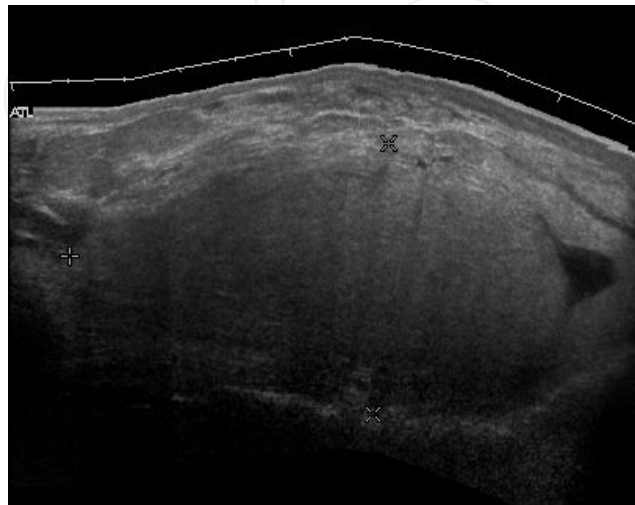


Fig. 16. Liposarcoma mimicking lipoma. A homogeneous hypoechoic mass presents with the same appearance of lipoma, rapid growth of this tumors grants surgical intervention with pathology proved to be well differentiated liposarcoma

### 5.5 Adenomatoid tumor

Adenomatoid tumors are the most common tumors of the epididymis and account for approximately 30% of all paratesticular neoplasms, second only to lipoma (Bostwick & Eble, 1997). They are usually unilateral, more common on the left side, and usually involve the epididymal tail. Adenomatoid tumor typically occurs in men during the third and fourth decades of life. Patients usually present with a painless scrotal mass that is smooth, round and well circumscribed on palpation. They are believed to be of mesothelial origin and are universally benign. Their sonographic appearance is that of a round shaped, well-defined, homogeneous mass with echogenicity ranging from hypo- to iso- to hyperechoic [Fig. 17] (Mak et al, 2001).

### 5.6 Fibrous pseudotumor

Fibrous pseudotumors, also known as fibromas are thought to be reactive, nonneoplastic lesions. They can occur at any age, about 50% of fibromas are associated with hydrocele, and 30% are associated with a history of trauma or inflammation (Akbar et al, 2003). Although the exact cause of this tumor is not completely understood, it is generally believed that these lesions represent a benign reactive proliferation of inflammatory and fibrous tissue, in response to chronic irritation (Garriga et al, 2009).

Sonographic evaluation generally shows one or more solid nodules arising from the tunica vaginalis, epididymis, spermatic cord and tunica albuginea [Fig. 18]. A hydrocele is frequently present too. The nodules may appear hypoechoic or hyperechoic, depending on the amount

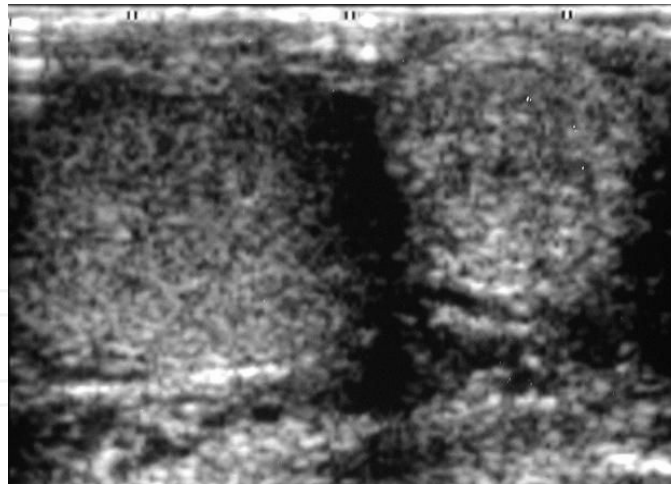


Fig. 17. Adenomatoid tumor at epididymis. A nodule that is isoechoic to the testis is seen occupying nearly the entire epididymal tail

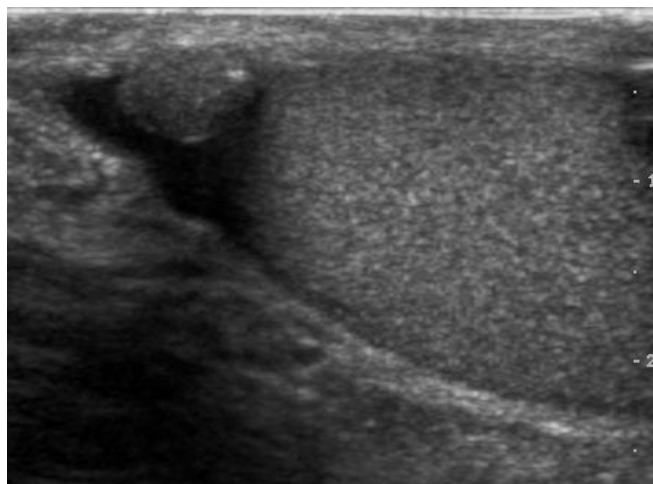


Fig. 18. Fibrous pseudotumor. A homogeneous hypoechoic nodular lesion is seen attached to the tunica associated with minimal amount of hydrocele

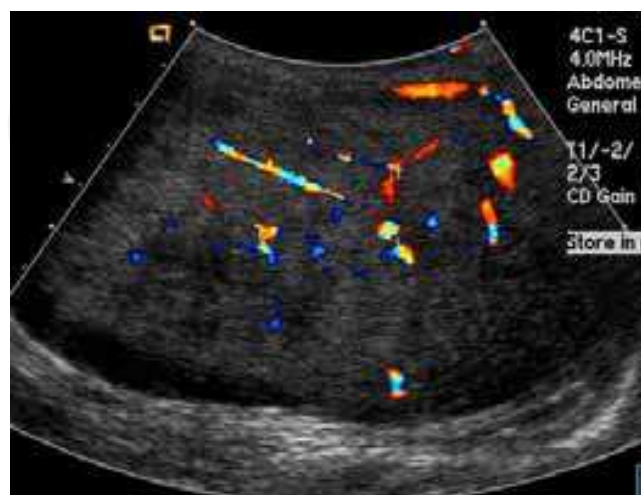

Fig. 19. Fibrous pseudotumor. With color Doppler, a little vascular flow is seen in this fibrous pseudotumor

of collagen or fibroblast present (Garriga et al, 2009, as cited in Tobias-Machado et al, 2000). Acoustic shadowing may occur in the absence of calcification due to the dense collagen component of this tumor. With color Doppler sonography, a small to moderate amount of vascularity may be seen (Garriga et al 2009, as cited in Germaine and Simerman, 2007) [Fig. 19].

## 6. Inflammation

### 6.1 Epididymitis and epididymo-orchitis

Epididymitis and epididymo-orchitis are common causes of acute scrotal pain in adolescent boys and adults. At physical examination, they usually are palpable as tender and enlarged structures. Clinically, this disease can be differentiated from torsion of the spermatic cord by elevation of the testes above the pubic symphysis. If scrotal pain decreases, it is more likely to be due to epididymitis rather than torsion (Prehn's sign). Most cases of epididymitis are secondary to sexually transmitted disease or retrograde bacteria infection from the urinary bladder. The infection usually begins in the epididymal tail and spreads to the epididymal body and head. Approximately 20% to 40 % of cases are associated with orchitis due to direct spread of infection into the testis (Kim et al, 2007, as cited in Horstman et al, 1991).

At ultrasound, the findings of acute epididymitis include an enlarged hypoechoic or hyperechoic (presumably secondary to hemorrhage) epididymis [Fig. 20a]. Other signs of inflammation such as increased vascularity, reactive hydrocele, pyocele and scrotal wall thickening may also be present. Testicular involvement is confirmed by the presence of testicular enlargement and an inhomogeneous echotexture. Hypervascularity on color Doppler images [Fig. 20b] is a well-established diagnostic criterion and may be the only imaging finding of epididymo-orchitis in some men (Kim et al, 2007, as cited in Horstman et al, 1991).

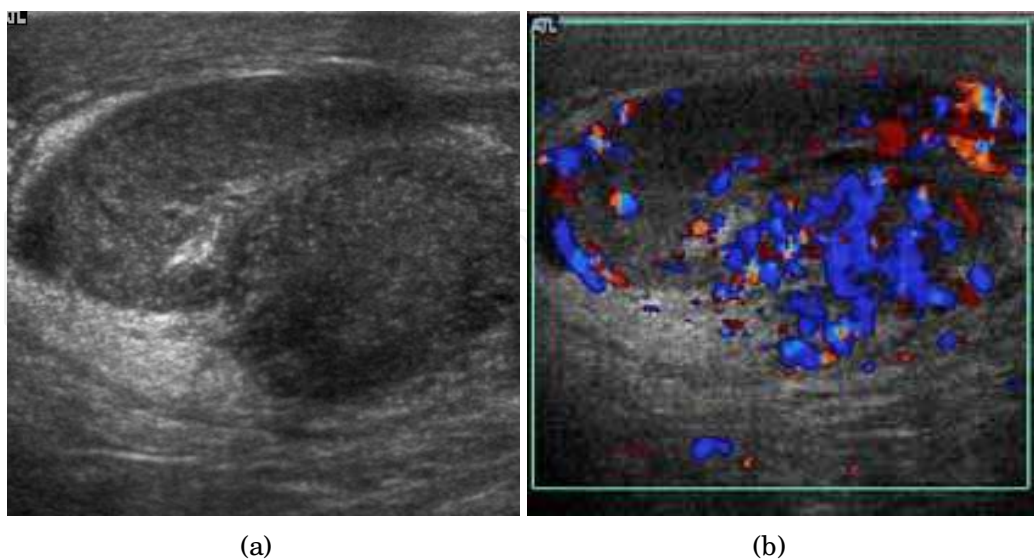


Fig. 20. Epididymo-orchitis in a 77 year-old man. (a) Transverse sonography shows enlargement of the epididymis with hypoechogenicity noted over the testis and epididymis associated with scrotal wall thickening. (b) Color Doppler sonography showed hyperemic change of the testis and epididymis, presenting as an “inferno” vascular flow pattern



## 6.2 Tuberculous epididymo-orchitis

Although the genitourinary tract is the most common site of extra-pulmonary involvement by tuberculosis, tuberculous infection of the scrotum is rare and occurs in approximately 7% of patients with tuberculosis (Muttarak and Peh, 2006, as cited in Drudi et al, 1997). At the initial stage of infection, the epididymis alone is involved. However if appropriate antituberculous treatment is not administered promptly, the infection will spread to the ipsilateral testis. The occurrence of isolated testicular tuberculosis is rare (Muttarak and Peh, 2006, as cited in Riehle & Jayaraman, 1982). Clinically patients with tuberculous epididymo-orchitis may present with painful or painless enlargement of the scrotum, hence they cannot be distinguished from lesions such as testicular tumor, testicular infarction and may mimic testicular torsion.

At ultrasound, tuberculous epididymitis is characterized by an enlarged epididymis with variable echogenicity. The presence of calcification, caseation necrosis, granulomas and fibrosis can result in heterogeneous echogenicity [Fig. 21a]. The ultrasound findings of tuberculous orchitis are as follow: (a) diffusely enlarged heterogeneously hypoechoic testis (b) diffusely enlarged homogeneously hypoechoic testis (c) nodular enlarged heterogeneously hypoechoic testis and (d) presence of multiple small hypoechoic nodules in an enlarged testis [Fig. 21b] (Muttarak and Peh, 2006).

Although both bacterial and tuberculous infections may involve both the epididymis and the testes, an enlarged epididymis with heterogeneously hypoechoic pattern favors a diagnosis of tuberculosis (Muttarak and Peh, 2006, as cited in Kim et al, 1993 and Chung et al, 1997). With color Doppler ultrasound, a diffuse increased blood flow pattern is seen in bacterial epididymitis, whereas focal linear or spotty blood flow signals are seen in the peripheral zone of the affected epididymis in patients with tuberculosis (Muttarak and Peh, 2006, as cited in Yang et al, 2000).

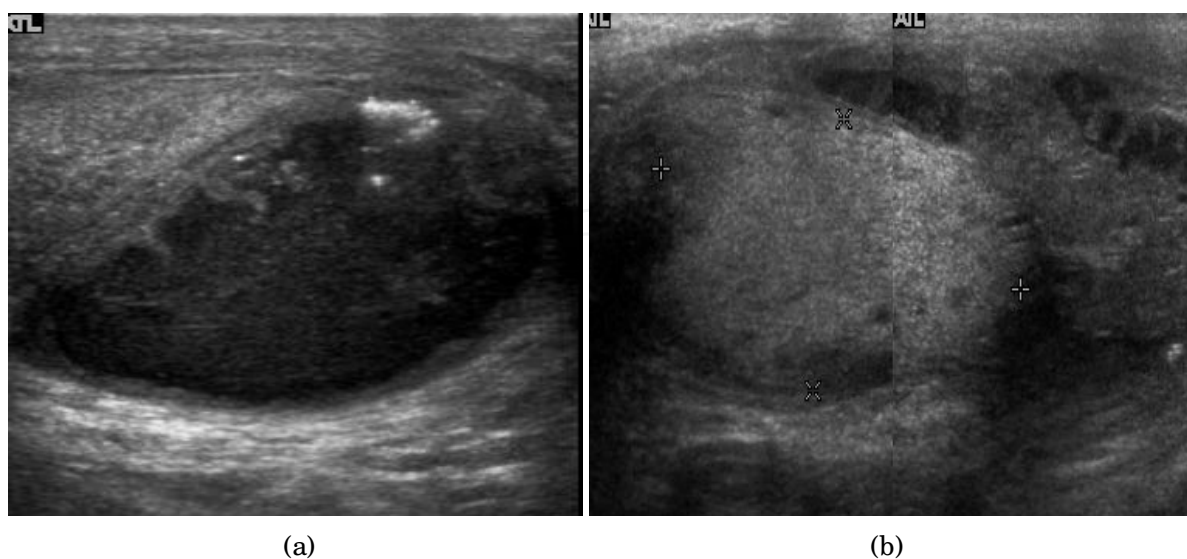


Fig. 21. Tuberculous epididymo-orchitis. (a) Transverse sonography of a surgically proved tuberculous epididymitis shows an enlarged epididymis containing calcification and necrosis. (b) Composite image: Transverse sonography of the same patient shows multiple hypoechoic nodules in the left testis associated with surrounding reactive hydrocele



### 6.3 Fournier gangrene

Fournier gangrene is a polymicrobial necrotizing fascitis involving the perineal, perianal, or genital regions and constitutes a true surgical emergency with a potentially high mortality rate. It usually develops from a perineal or genitourinary infection, but can arise following local trauma with secondary infection of the wound. 40–60% of patients are being diabetic. Although the diagnosis of Fournier gangrene is often made clinically, diagnostic imaging is useful in ambiguous cases.

The sonographic hallmark of Fournier gangrene is presence of subcutaneous gas within the thickened scrotal wall. At ultrasound, the gas appears as numerous, discrete, hyperechoic foci with reverberation artifacts [Fig. 22]. Evidence of gas within the scrotal wall may be seen prior to clinical crepitus. The only other condition manifesting with gas at sonographic examination is an inguinoscrotal hernia. This can be differentiated from Fournier gangrene by the presence of gas within the protruding bowel lumen and away from the scrotal wall. (Levenson et al, 2008).

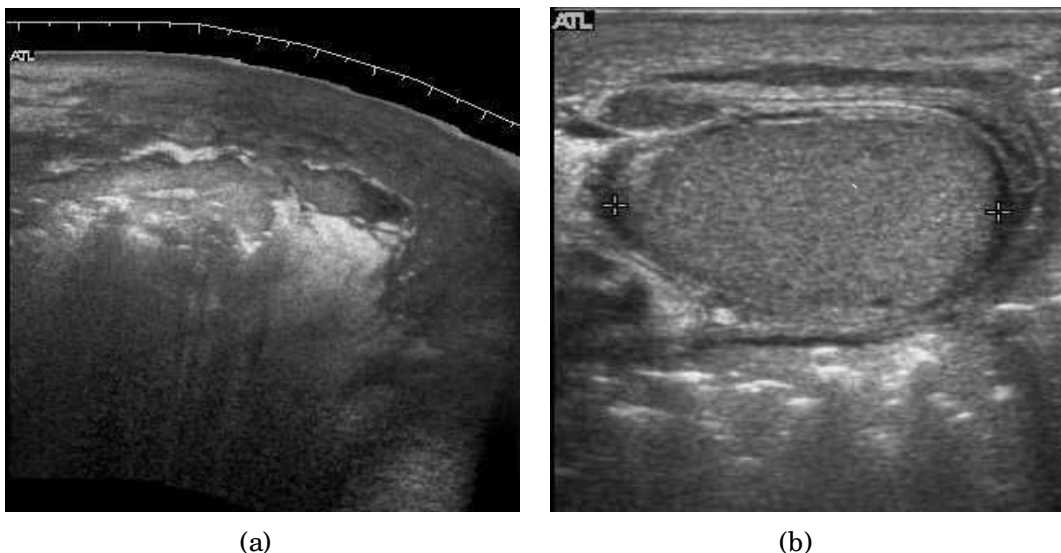


Fig. 22. Fournier gangrene. (a) Transverse sonography image shows echogenic areas with dirty shadowing representing air in the perineum. (b) Gas presented as numerous, discrete, hyperechoic foci with reverberation artifacts are seen at scrotal wall

## 7. Other benign lesions of the scrotum

### 7.1 Tubular ectasia

The normal testis consists of several hundred lobules, with each lobule containing several seminiferous tubules. The seminiferous tubules of each lobule merge to form the straight tubes, which in turn converge to form the rete testis. The rete testis tubules, which lie within the mediastinum testis, are an anastomosing network of irregular channels with a broad lumen, which then empties into the efferent ductules to give rise to the head of the epididymis. Obstruction in the epididymis or efferent ductules may lead to cystic dilatation of the efferent ductules, which usually presents as an epididymal cyst on ultrasound. However, in the more proximal portion this could lead to the formation of an intratesticular

cyst or dilatation of the tubules, so called tubular ectasia. Factors contributing to the development of tubular ectasia include epididymitis, testicular biopsy, vasectomy or an aging process (Mak et al 2007b). Clinically this lesion is usually asymptomatic. The ultrasound appearance of a microcystic or multiple tubular-like lesions located at the mediastinal testis [Fig. 23] and associated with an epididymal cyst in a middle-aged or elderly patient should alert the sonographer to the possibility of tubular ectasia.

The differential diagnosis of a multicystic lesion in testis should include a cystic tumor, especially a cystic teratoma. A cystic teratoma is usually a palpable lesion containing both solid and cystic components; and the cysts are normally larger than that of tubular ectasia, which appear microcystic [Fig. 24]. Furthermore, the location of tubular ectasia in the mediastinum testis is also helpful in making the differential diagnosis.

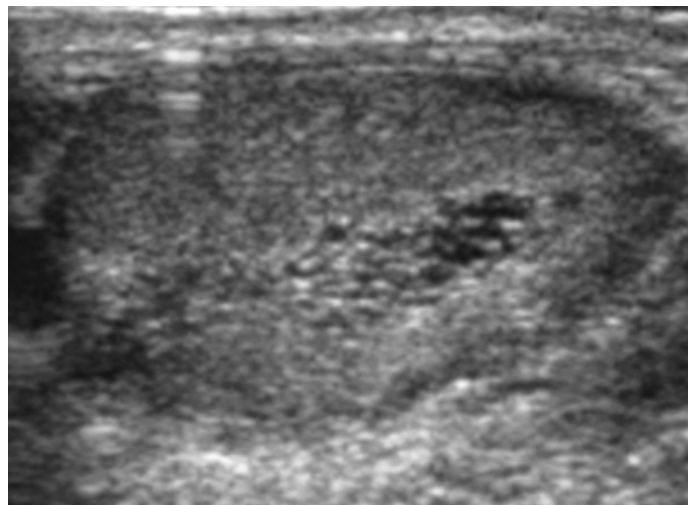


Fig. 23. Tubular ectasia of the testis. Honey-comb shaped cystic lesion at mediastinum testis

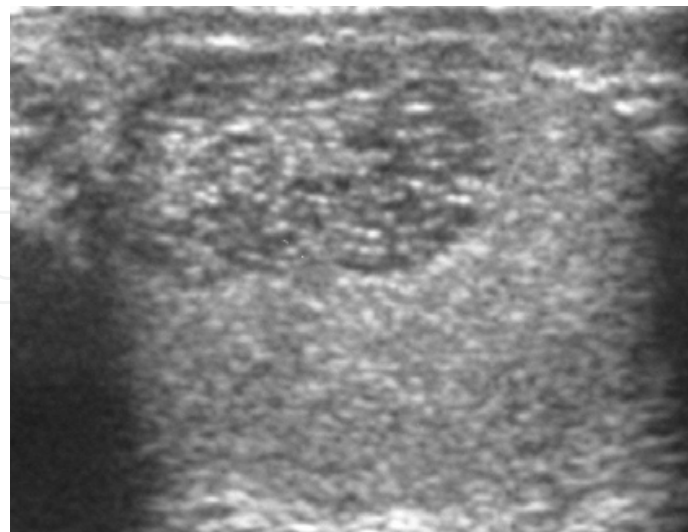


Fig. 24. Tubular ectasia of the testis (Reproduced with permission from British Institute of Radiology, British Journal of Radiology 2007; 80: 67-68). Lesion in the testis mimicking testicular tumor, but the microcystic appearance of this lesion is suggestive of tubular ectasia

## 7.2 Testicular microlithiasis

Histologically, testicular microlithiasis refers to the scattered laminated calcium deposits in the lumina of the seminiferous tubules. These calcifications arise from degeneration of the cells lining the seminiferous tubules. At ultrasonography, microliths appear as tiny punctate echogenic foci, which typically do not shadow. Although minor microcalcification within a testis is considered normal, the typical US appearance of testicular microlithiasis is of multiple nonshadowing echogenic foci measuring 2–3 mm and randomly scattered throughout the testicular parenchyma [Fig. 25] (Dogra et al, 2003, as cited in Janzen et al, 1992). The clinical significance of testicular microlithiasis is that it is associated with increased risk of testicular malignancy, thus follow up of affected individuals with scrotal sonography is necessary to ensure that a testicular tumor does not develop.

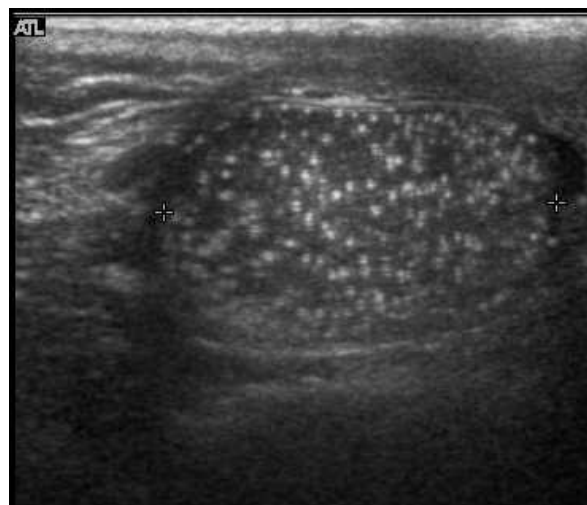


Fig. 25. Testicular microlithiasis. Multiple hyperechoic foci without acoustic shadow presenting as a starry sky appearance is seen in the testis

## 7.3 Testicular torsion

The normal testis and epididymis are anchored to the scrotal wall. If there is a lack of development of these attachments, the testis is free to twist on its vascular pedicle. This will result in torsion of the spermatic cord and interruption of testicular blood flow. Testicular torsion occurs most commonly at 12 to 18 years but can occur at any age. Torsion results in swelling and edema of the testis, and as the edema increases, testicular perfusion is further altered. The extent of testicular ischemia depends on the degree of torsion, which ranges from 180° to 720° or greater. The testicular salvage rate depends on the degree of torsion and the duration of ischemia. A nearly 100% salvage rate exists within the first 6 hours after the onset of symptoms; a 70% rate, within 6–12 hours; and a 20% rate, within 12–24 hours (Dogra et al, 2003, as cited in Patriquin et al, 1993). Therefore testicular torsion is a surgical emergency and the role of ultrasound is to differentiate it from epididymitis as both disease presents with acute testicular pain clinically.

There are two types of testicular torsion: extravaginal and intravaginal. Extravaginal torsion occurs exclusively in newborns. Ultrasound findings include an enlarged heterogeneous testis, ipsilateral hydrocele, thickened scrotal wall and absence of vascular flow in the testis and spermatic cord (Dogra et al 2003, as cited in Brown et al, 1990). The ultrasound findings

of intravaginal torsion vary with the duration and the degree of rotation of the spermatic cord. Gray scale ultrasound may appear normal if the torsion is just occurred. At 4-6 hours after onset of torsion, enlarged testis with decreased echogenicity is seen. At 24 hours after onset, the testis appears heterogeneous due to vascular congestion, hemorrhage and infarction (Dogra et al, 2003). As gray scale ultrasound is often normal during early onset of torsion, Doppler sonography is considered as essential in early diagnosis of testicular torsion. The absence of testicular flow at color and power Doppler ultrasound is considered diagnostic of ischemia [Fig. 26], provided that the scanner is set for detection of slow flow, the sampling box is small and the scanner is adjusted for the lowest repetition frequency and the lowest possible threshold setting.

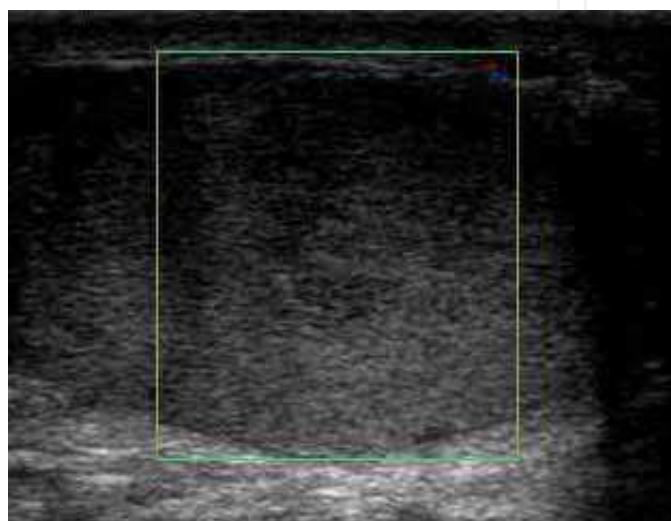


Fig. 26. Testicular torsion of the right testis. Absence of vascular flow and ill-defined hypoechoic lesions are seen in the testis

#### 7.4 Varicocele

Varicocele refers to an abnormal dilatation of the veins of the spermatic cord due to incompetence of valve in the spermatic vein. This results in impaired blood drainage into the spermatic vein when the patient assumes a standing position or during Valsalva's maneuver. Varicoceles are more common on the left side due to the following reasons (a) The left testicular vein is longer; (b) the left testicular vein enters the left renal vein at a right angle; (c) the left testicular artery in some men arches over the left renal vein, thereby compressing it; and (d) the descending colon distended with feces may compress the left testicular vein (Mehta and, Dogra, 1998).

The US appearance of varicocele consists of multiple, hypoechoic, serpiginous, tubular like structures of varying sizes larger than 2 mm in diameter that are usually best visualized superior or lateral to the testis [Fig. 27a]. Color flow and duplex Doppler US optimized for low-flow velocities help confirm the venous flow pattern, with phasic variation and retrograde filling during a Valsalva's maneuver [Fig. 27b]. Intratesticular varicocele may appear as a vague hypoechoic area in the testis or mimics tubular ectasia. With color Doppler, this intratesticular hypoechoic area also showed reflux of vascular flow during Valsalva's maneuver [Fig. 28]



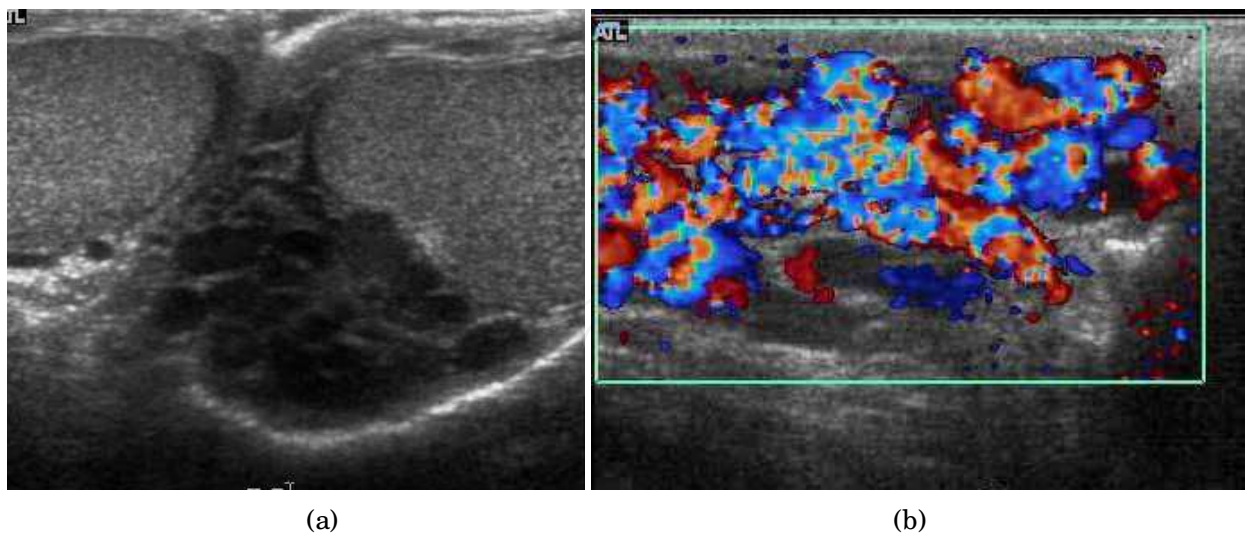


Fig. 27. Varicocele. (a) Multiple tortuous tubular like structure are seen in the left scrotum. (b) Color Doppler sonography shows vascular reflux during Valsalva's maneuver

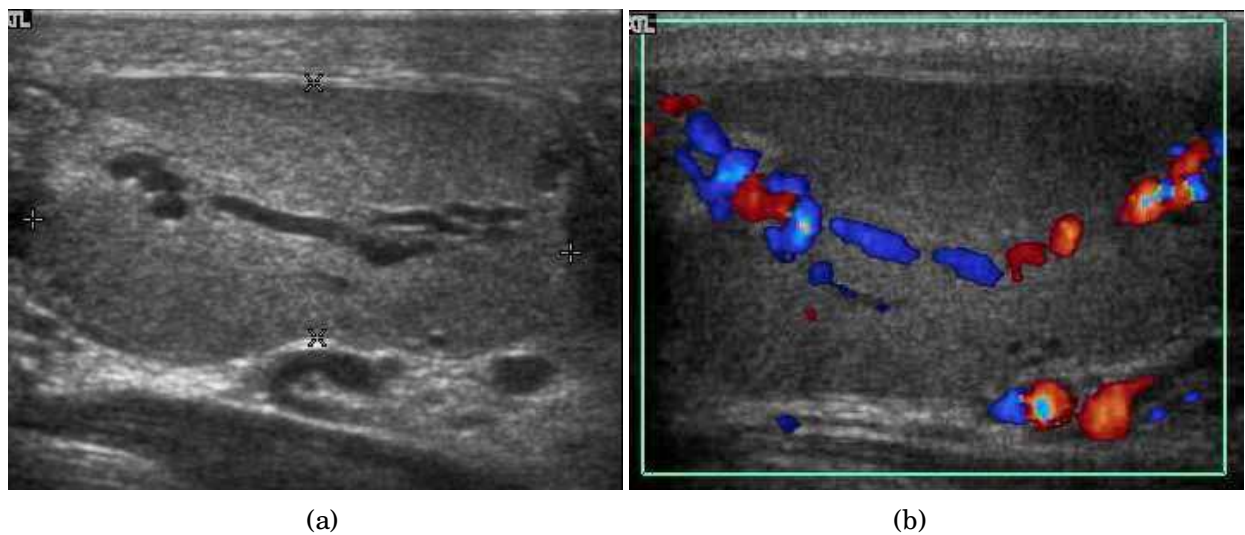


Fig. 28. Intratesticular varicocele. (a) Dilated tubular structures are seen within the testis. (b) Presence of vascular reflux is noted during Valsalva's maneuver

### 7.5 Undescended testis (Cryptorchidism)

Normally the testes begin its descent through the inguinal canal to the scrotum at 36 weeks' of gestation and completed at birth. Failure in the course of testes descent will result in undescended testes. Undescended testis is found in 4% of full-term infants and only 0.8% of males at the age of 1 year have true cryptorchidism. Although an undescended testis can be found anywhere along the pathway of descent from the retroperitoneum to the scrotum, the inguinal canal is the most common site for an undescended testis. Deviation of testis from the normal pathway of descent will result in ectopic testis that is commonly seen in pubopenile, femoral triangle and perineal regions.

Besides infertility, undescended testes carry an increased risk of malignancy even for the normally located contralateral testis. The risk of malignancy is estimated to be as high as 10



times the normal individual with seminoma being the most common malignancy. The incidence of infertility is decreased if surgical orchiopexy is carried out before the 1-3 years but the risk of malignancy does not change.

Because of the superficial location of the inguinal canal in children, sonography of undescended testes should be performed with a high frequency transducer. At ultrasound, the undescended testis usually appears small, less echogenic than the contralateral normal testis and usually located in the inguinal region [Fig. 29]. With color Doppler, the vascularity of the undescended testis is poor.

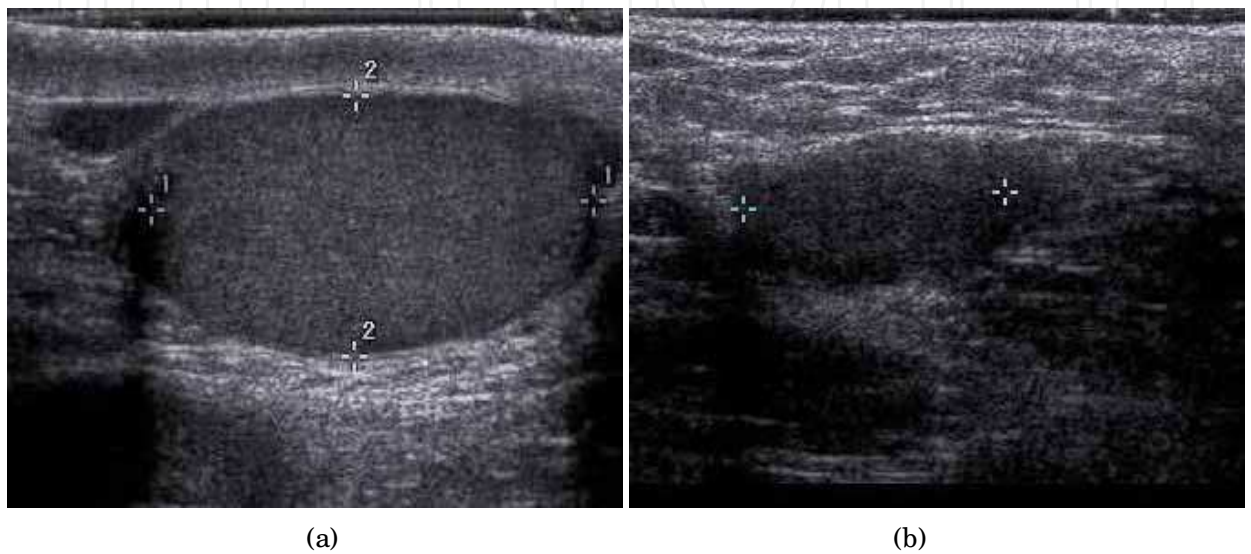


Fig. 29. Undescended testis. (a) Normal testis in the scrotum. (b) Atrophic and decreased echogenicity of the contralateral testis of the same patient seen in the inguinal region

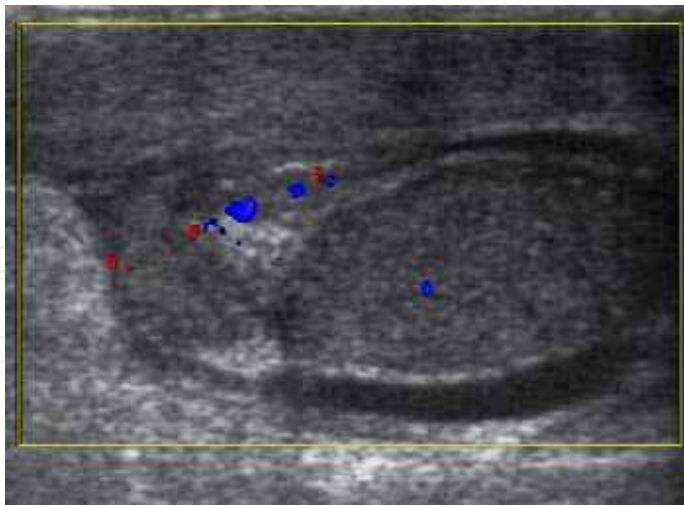


Fig. 30. Testicular appendiceal torsion. A hyperechoic lesion with surrounding vascularity is seen in the groove between the testis and epididymis

7.6 Testicular appendiceal torsion

At sonography, the appendix testis usually appears as a 5 mm ovoid structure located in the groove between the testis and the epididymis. Normally it is isoechoic to the testis but at

times it may be cystic. The appendix epididymis is of the same size as the appendix testis but is more often pedunculated. Clinically pain may occur with torsion of either appendage. Physical examination showed a small, firm nodule is palpable on the superior aspect of the testis and a bluish discoloration known as “blue dot” sign may be seen on the overlying skin (Dogra and Bhatt 2004, as cited in Skoglund et al 1970). Torsion of the appendiceal testis most frequently involved in boys aged 7-14 years (Dogra and Bhatt 2004).

The sonographic features of testicular appendiceal torsion includes a circular mass with variable echogenicity located adjacent to the testis or epididymis [Fig. 30], reactive hydrocele and skin thickening of the scrotum is common, increased peripheral vascular flow may be found around the testicular appendage on color Doppler ultrasound. Surgical intervention is unnecessary and pain usually resolves in 2 to 3 days with an atrophied or calcified appendages remaining.

## 8. Conclusion

Ultrasound remains as the mainstay in scrotal imaging not only because of its high accuracy, excellent depiction of scrotal anatomy, low cost and wide availability, it is also useful in determining whether a mass is intra- or extra-testicular, thus providing us useful and valuable information to decide whether a mass is benign or malignant even though malignancy do occur in extratesticular tumors and vice versa. Furthermore, ultrasound also provides information essential to reach a specific diagnosis in patients with testicular torsion, testicular appendiceal torsion and inflammation such as epididymo-orchitis, Fournier gangrene etc, thus enabling us to avoid unnecessary operation.

## 9. Acknowledgments

The authors acknowledge Miss Lee Ying-Fang for her expert technical support in preparation of this manuscript. We are also thankful to British Institute of Radiology and John Wiley and Sons publishing company in granting us permission to reuse some of the figures previously published in British Journal of Radiology and Journal of Clinical Ultrasound.

## 10. References

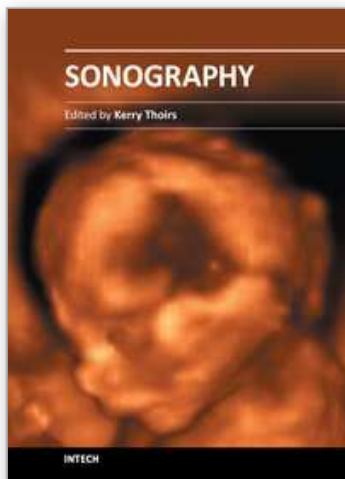
- Akbar SA (2003), Sayyed TA, Jafri SZ, Hasteh F & Neill JS. Multimodality Imaging of Paratesticular Neoplasms and Their Rare Mimics. *Radiographics*, Vol. 23, No. 6, (November-December 2003), pp. 1461-1476, ISSN 0271-5333
- Bostwick DG (1997). Spermatic Cord and Testicular Adnexa, In: *Urologic Surgical Pathology*, Bostwick DG, Eble JN, pp. 647-674 Mosby, ISBN 978080167 St Louis, Missouri.
- Boyum J(2008) & Wasserman NF. Malignant Mesothelioma of the Tunica Vaginalis Testis. *Journal of ultrasound in Medicine*, Vol. 27, No. 8, (August 2008), pp.1249-1255. ISSN 0278-4297
- Bruno C (2002), Minniti S & Procacci C. Diagnosis of Malignant Mesothelioma of the Tunica Vaginalis Testis by Ultrasound Guided Fine Needle Aspiration. *Journal of Clinical Ultrasound*, Vol. 30, No.3, (March-April 2002), pp.181-183. ISSN 0091-2751

- Dogra VS (2003), Gottlieb RH, Oka M & Rubens DJ Sonography of the Scrotum. *Radiology*, Vol.227, No.1, (April 2003), pp.18–36. ISSN 0033-8419
- Dogra V (2004) & Bhatt S. Acute Painful Scrotum. *Radiologic Clinics of North America*, Vol.42, (2004), pp. 349–363, ISSN 0033-8389
- Doll DC (1986) & Weiss RB Malignant Lymphoma of the Testis. *American Journal of Medicine*, Vol.81, No. 3, (September 1986), pp.515-524, ISSN 0002-9343
- Garriga V (2009), Serrano A, Marin A, Medrano S, Roson N & Pruna X. US of the Tunica Vaginalis Testis: anatomic relationships and pathologic conditions. *Radiographics*, Vol.29, No.7, pp.2017-2032, (November, 2009), ISSN0271-5333
- Kim W (2007), Rosen MA, Langer JE, Banner MP, Siegelman ES & Ramchandani P. US–MR Imaging Correlation in Pathologic Conditions of the Scrotum. *Radiographics*, Vol.27, No.5, (September 2007), pp.1239–1253, ISSN 0271-5333.
- Levenson RB (2008), Singh AK & Novelline RA. Fournier Gangrene: Role of Imaging. *Radiographics*, Vol.28, No.2, (March-April 2008), pp.519-528, ISSN0271-5333
- Mak CW (2001), Wu TC, Chou CK, Tzeng WS, Sia YL, Chang JM & Lin CN. Ultrasonographic Appearance of an Adenomatoid Tumor in the Epididymis: Report of a Case. *Journal of Medical Ultrasound*, Vol.9, No.4, (December 2001), pp. 202-205, ISSN 0929-6441
- Mak CW (2004a), Chou CK, Su CC, Huan SK & Chang JM. Ultrasound Diagnosis of Paratesticular Rhabdomyosarcoma. *British Journal of Radiology*, Vol.77, No. 915, (March 2004), pp.250–252, ISSN 0007-1285
- Mak CW (2004b), Cheng TC, Chuang SS, Wu RH, Chou CK & Chang JM. Malignant Mesothelioma of the Tunica Vaginalis Testis. *British Journal of Radiology*, Vol.77, No.921, (September2004), pp.780–781, ISSN 0007-1285
- Mak CW (2004c), Tzeng WS, Chou CK, Chen CY, Chang JM & Tzeng CC. Leiomyoma Arising from the Tunica Albuginea of the Testis: Sonographic Findings. *Journal of Clinical Ultrasound*, Vol.32, No.6, (July-August 2004), pp.309–311, ISSN 0091-2751
- Mak CW (2007a), Chen CY, Tzeng WS & Li CF. Epidermoid Cyst of the Testis. *Australasian Radiology*, Vol.51, No.Supplement S1, (October 2007), pp.B74–B76, ISSN 0004-8461
- Mak CW (2007b), Tzeng WS & Chou CK. Microcystic Lesion of the Testis. *British. Journal. Radiology*, Vol.80, No. 949, (January 2007) pp.67-68, ISSN 0007-1285.
- Mehta AL (1998) & Dogra VS. Intratesticular Varicocele. *Journal of Clinical Ultrasound*, Vol.26, No.1, pp.49-51, (January 1998), ISSN 0091-2751
- Muttarak M(2006) & Peh WC. Case 91: Tuberculous Epididymo-orchitis. *Radiology*, Vol.238, No.2, (February 2006), pp.748-751, ISSN 0033-8419
- Rosenberg R (1989) & Williamson MR. Lipomas of the Spermatic cord and Testis: Report of Two Cases. *Journal of Clinical Ultrasound*, Vol.17, No.9, (November-December 1989), pp.670-674, ISSN 0091-2751
- Wang MT (2005), Mak CW, Tzeng WS, Chen JC, Chang JM & Lin CN. Malignant Mesothelioma of the Tunica Vaginalis Testis: Unusual Sonographic Appearance. *Journal of Clinical Ultrasound*, Vol.33, No.8, (October, 2005), pp.418–420, ISSN 0091-2751
- Woodward PJ (2002), Sohaey, R, O'Donoghue MJ & Green DE. Tumors and Tumorlike Lesions of the Testis: Radiologic-Pathologic Correlation. *RadioGraphics*, Vol.22, No.1, (January-February 2002), pp.189–216, ISSN 0271-5333.

Woodward PJ (2003), Schwab CM & Sesterhenn IA. Extratesticular scrotal masses: Radiologic-pathologic correlation. *Radiographics*, Vol.23, No.1, (January-February 2003), pp. 215-40, ISSN 0271-5333.

IntechOpen

IntechOpen



## **Sonography**

Edited by Dr. Kerry Thoirs

ISBN 978-953-307-947-9

Hard cover, 346 pages

**Publisher** InTech

**Published online** 03, February, 2012

**Published in print edition** February, 2012

Medical sonography is a medical imaging modality used across many medical disciplines. Its use is growing, probably due to its relative low cost and easy accessibility. There are now many high quality ultrasound imaging systems available that are easily transportable, making it a diagnostic tool amenable for bedside and office scanning. This book includes applications of sonography that can be used across a number of medical disciplines including radiology, thoracic medicine, urology, rheumatology, obstetrics and fetal medicine and neurology. The book revisits established applications in medical sonography such as biliary, testicular and breast sonography and sonography in early pregnancy, and also outlines some interesting new and advanced applications of sonography.

### **How to reference**

In order to correctly reference this scholarly work, feel free to copy and paste the following:

Chee-Wai Mak and Wen-Sheng Tzeng (2012). Sonography of the Scrotum, Sonography, Dr. Kerry Thoirs (Ed.), ISBN: 978-953-307-947-9, InTech, Available from:

<http://www.intechopen.com/books/sonography/sonography-of-the-scrotum>

**INTECH**  
open science | open minds

### **InTech Europe**

University Campus STeP Ri  
Slavka Krautzeka 83/A  
51000 Rijeka, Croatia  
Phone: +385 (51) 770 447  
Fax: +385 (51) 686 166  
[www.intechopen.com](http://www.intechopen.com)

### **InTech China**

Unit 405, Office Block, Hotel Equatorial Shanghai  
No.65, Yan An Road (West), Shanghai, 200040, China  
中国上海市延安西路65号上海国际贵都大饭店办公楼405单元  
Phone: +86-21-62489820  
Fax: +86-21-62489821



© 2012 The Author(s). Licensee IntechOpen. This is an open access article distributed under the terms of the [Creative Commons Attribution 3.0 License](https://creativecommons.org/licenses/by/3.0/), which permits unrestricted use, distribution, and reproduction in any medium, provided the original work is properly cited.

IntechOpen

IntechOpen