

We are IntechOpen, the world's leading publisher of Open Access books Built by scientists, for scientists

6,900

Open access books available

186,000

International authors and editors

200M

Downloads

Our authors are among the

154

Countries delivered to

TOP 1%

most cited scientists

12.2%

Contributors from top 500 universities



WEB OF SCIENCE™

Selection of our books indexed in the Book Citation Index
in Web of Science™ Core Collection (BKCI)

Interested in publishing with us?
Contact book.department@intechopen.com

Numbers displayed above are based on latest data collected.
For more information visit www.intechopen.com



Novel Markers for Diagnosis and Prognosis of Oral Intraepithelial Neoplasia

Angela Celetti¹, Francesco Merolla^{1,2}, Chiara Luise¹,
Maria Siano² and Stefania Staibano²

¹*Istituto di Endocrinologia e Oncologia Sperimentale, CNR, c/o Dipartimento di
Biologia e Patologia Cellulare e Molecolare, Università Federico II, Napoli,*

²*Dipartimento di Scienze Biomorfologiche e Funzionali, Università Federico II, Napoli,
Italy*

1. Introduction

Squamous carcinoma of the oral cavity is a slow multi-steps process, based on progressive accumulation of genetic events leading to the selection of clonal populations of transformed epithelial cells (Ha&Califano, 2002). The spectrum of histological changes occurring in this process ranges from atypical squamous hyperplasia to carcinoma in situ (CIS), and is grouped under the designation of oral intraepithelial lesions (OILs) (Gale et al, 2005; Gale et al 2006). In their evolution, most cases of OILs are self-limiting and reversible, whereas some persist and may progress to SCC in spite of careful follow-up and treatment (Kambic~&Gale, 1986; Crissman et al, 1993).

As for the largest group of head and neck intraepithelial lesions, in the last years, various aspects of oral carcinogenesis have been investigated, including the aetiology, histological classification, treatment, frequency of malignant transformation and predictive factors. Particular attention has been directed to the analysis of the interrelationship between histological parameters and their biological behaviour (Gale et al 2005, Gale et al 2006; Kambic~&Gale, 1986; Putney&O'Keefe 1953; Kambic~ 1978; Crissman 1979; Henry 1979; Hellquist et al, 1982; Gillis et al, 1983; Grundmann 1983; Goodman 1984; Crissman&Fu 1986; Velasco et al 1987; Olde-Kalter et al 1987; Crissman&Zarbo 1989; Sllamniku et al 1989; Bouquot et al, 1991a; Kambic&Gale 1995; Hellquist et al 1999; Gale et al, 2000; Gallo et al 2001; Ricci et al 2003). These analyses have been recently further supplemented by molecular genetic investigations trying to include the molecular events involved in the pathogenesis of oral squamous cell carcinoma (OSCC) to improve the prognostic evaluation of OIN (Ha&Califano 2002; Somers et al 1992; Saglam et al 2007).

A precise and uniform terminology of squamous intraepithelia lesions is essential for successful collaboration among pathologists, as well as for proper communication with clinicians. The terminology used in clinical and pathological reports has changed significantly over the last six decades. Common agreement has recently been achieved for terms that are used only for the clinical appearance and do not have any histopathological and prognostic implications. The most frequently applied clinical diagnoses are oral

leukoplakia and erythroplakia (Kambic & Gale 1995; Gale et al 2000; Gallo et al 2001). In contrast, keratosis remains a controversial term, since it is often wrongly applied interchangeably to macroscopic and microscopic features, whereas it really represents a histological term denoting the appearance of a keratin layer on the surface of the squamous epithelium.

Unfortunately, inconsistent terminology still exists for the histological classification of OIN. The spectrum of epithelial changes has been variously described as keratosis, dysplasia, squamous intraepithelial neoplasia (SIN), oral intraepithelial neoplasia (OIN), etc, to list only the most commonly used terms. Because of our inability to harmonize different views and establish a single classification of squamous intraepithelial lesions, there are three classification schemes in the most recent edition of the World Health Organization (WHO) classification of tumours, pathology of the head and neck tumours, as follows: (i) dysplasia system, (ii) SIN system, and (iii) Ljubljana classification (Gale et al 2005). These classifications differ conceptually and terminologically, and analogy between them can only be approximate.

Chronic inflammation, leukoplakia or, occasionally, erythroplakia, appear mainly in the buccal mucosa, labial commissure, gingiva/alveolar ridge, tongue, floor of the mouth. Lesions can be either sharply circumscribed and grow exophytically, or be predominantly flat and diffuse, related in part to the amount of keratin layer. Their surface is rough, may be muddy brown to red (erythroplakia), perhaps with increasingly visible vascularity, or coated with diffuse or dispersed circumscribed whitish plaques. A circumscribed whitish thickening of the mucosa may be observed, covered by irregularly exophytic warty plaques. A speckled appearance of lesions can also be present, caused by an unequal thickness of the keratin layer (Gale et al 2005; Kambic & Gale 1995). Some leukoplakic lesions are ulcerated (6.5%) or combined with erythroplakia (15%) (Bouquot et al 1991a). In general, leukoplakic lesions are thought to have a low risk of malignant transformation, mixed white and red lesions, or speckled leukoplakia, an intermediate risk, and pure erythroplakia (red lesions) the highest risk of cancer development. However, none of these features can be used as an indicator of the overlying changes of the epithelium, and histological analysis of these lesions is mandatory to determine their biological potential.

Symptoms depend on the location and severity of the disease and usually last a few months before clinical notice.

2. Clinical classification of leukoplakia and epithelial dysplasia

Leukoplakia, erythroplakia and palatal keratosis, associated with reverse smoking, are categorized as precancerous lesions (Axell et al 1996; Pindborg et al 1997). Oral leukoplakia is the most common disease among precancerous lesions, whereas erythroplakia is relatively uncommon, and palatal keratosis associated with reverse smoking is rarely reported in Japan (Warnakulasuriya et al 2007). Pindborg et al (1963) confirmed that speckled leukoplakia, which is characterized by the presence of white nodular patches or white lesions interspersed with erythematous areas, was often associated with epithelial dysplasia or carcinoma. These findings were supported by subsequent reports showing the association of nonhomogeneous leukoplakia with epithelial dysplasia (Silverman et al 1976; Gupta et al 1980). The two-tiered clinical classification system, used to

divide oral leukoplakia into homogeneous and nonhomogeneous leukoplakia, was created by an international symposium (Axell et al 1996; Pindborg et al 1997). Under this system, homogeneous leukoplakia is further divided into four subtypes: flat, corrugated, wrinkled, or pumice; and similarly nonhomogeneous leukoplakia is subdivided into four types: verrucous, nodular (speckled), ulcerated, or erythroleukoplakia. The adjective “nonhomogeneous” refers to the color (i.e., a mixture of white and red changes for erythroleukoplakia) and texture (i.e., exophytic, papillary, or verrucous) of the lesion (van der Waal et al 1997). However, with regard to nonhomologous lesions, there are no reproducible criteria under this system for the clinical differentiation of proliferative verrucous leukoplakia from verrucous hyperplasia or verrucous carcinoma (van der Waal et al 1997; Shear&Pindborg 1980).

Sugar& Banoczy (1969) reported that leukoplakia erosiva and leukoplakia verrucosa were more often associated with epithelial dysplasia than leukoplakia simplex. Furthermore, because the clinical features of oral leukoplakia in Japan did not correlate with the two aforementioned systems, Amagasa et al (1977) developed a clinical classification system of oral leukoplakia in Japan, which was subsequently further developed in 2006 (Amagasa et al 2006). Under this system, oral leukoplakia is classified into four clinical types: type I, a flat white patch or plaque without red components; type II, a flat white patch or plaque with red components; type III, a slightly raised or elevated white plaque; and type IV, a markedly raised or elevated white plaque. Using this classification system, it was found that type II leukoplakia was significantly associated with epithelial dysplasia.

3. Histopathological features of Squamous Intraepithelial Lesions (SILs)

Traditional light microscopic examination, in spite of a certain subjectivity in interpretation, remains the most reliable method for determining an accurate diagnosis of SILs. Jackson first defined chronic laryngitis and keratosis as precancerous lesions (Jackson C, 1923); later, numerous studies and classifications have attempted to correlate phenotypic and genetic changes with the biological behaviour of the lesions (Michaels&Hellquist 2001). Regrettably, neither generally accepted criteria nor unified terminology have to date been provided for a histological grading system of oral SILs. Evidence of the inability of pathologists to set up a single, unified classification of SILs was manifest in the WHO Classification of head and neck tumours, published in 2005, where the dysplasia system is presented as the 2005 WHO classification simultaneously with the classification of SIN and the Ljubljana classification (Gale et al 2005). The majority of current classifications, such as the traditional dysplasia system (Hellquist et al 1982; Blackwell et al 1995), keratosis without (KWA) and with atypia/ in situ carcinoma (CIS) (Crissman 1979; Crissman 1982), Squamous Intraepithelial Neoplasia (SIN) (Crissman et al 1993; Crissman&Zarbo 1989) and Laryngeal Intraepithelial Neoplasia (LIN), (Friedmann&Ferlito 1993; Resta et al 1992) follow criteria similar to those commonly used for epithelial lesions of the uterine cervix. However, the different aetiology of oral lesions and their particular clinical and histological features require a grading system more appropriate to this region (Hellquist et al 1999). One can object that grading SILs, in spite of the clear histological criteria, is an attempt to impose arbitrary distinct categories of a continually progressing process without naturally and sharply defined borders (Bosman 2001; Kujan et al 2011). However, this continuous process, which is of long duration, may eventually stop, regress or progress, depending above all on the influence of various detri-

mental factors causing genetic and, consequently, phenotypic epithelial changes. When a biopsy is performed with a representative tissue sample, the established histological changes still serve at present as the main guidance for clinicians on how to treat the patient, as well as being the most reliable prognostic factor of the biological behaviour of the disease.

4. A lesson from premalignant lesions of the uterine cervix

One of the most significant advances in oncology has been the realization that cervical carcinoma arises from precursor lesions. There is probably more known about cervical neoplasia and its natural history than about any other human epithelial neoplasm. Most medical authorities now agree that cervical cancer is the end stage of a continuum of progressively more atypical changes in which one stage merges imperceptibly with the next. The first and apparently earliest change is the appearance of atypical cells in the basal layers of the squamous epithelium, but this occurs alongside normal differentiation toward the prickle and keratinizing cell layers. As the lesion evolves, there is progressive involvement of more and more layers of the epithelium, until it is totally replaced by atypical cells, exhibiting no surface differentiation (Robbins&Cortran 1979).

The most widely used term for the various stages in the evolution of these precursor lesions is “dysplasia” (Reagan&Hamonic 1956), which literally means bad molding or, in more scientific terms, disordered development. In WHO’s 1975 “Histological Typing of Female Genital Tract Tumours” (Poulsen et al 1975), dysplasia is subdivided into mild, moderate and severe, depending on the thickness of the squamous epithelium involved by atypical cells. When there is full-thickness involvement, we use the term “carcinoma in situ”, which was coined by Broders in 1932 in relation to head and neck lesions (Bouquot et al 2006; Broders 1932).

A newer terminology, “cervical intraepithelial neoplasia” (CIN), was subsequently proposed in an attempt to emphasize that these dysplastic changes represent a spectrum of the same basic changes (Richart 1966; 1973). CIN involves one or more clones of transformed cells slowly replacing normal keratinocytes, starting from the basal and parabasal layers to progressively invading the entire epithelial height. Richart subdivided CIN into three grades, CIN I, CIN II and CIN III, corresponding to mild, moderate and severe dysplasia, respectively, which then progresses to CIS.

The classifications and concepts of premalignant lesions of the uterine cervix have been extended to all other mucosal sites covered by squamous epithelial as oral mucosa.

5. WHO classification

In 1973, WHO defined an oral premalignant lesion as “a morphologically altered tissue in which oral cancer was more likely to occur than in its apparently normal counterpart”; more recently, researchers have recommended use of the term “potentially malignant disorder” (Warnakulasuriya et al 2007). Under the WHO classification, atypical epithelium is divided into two pathological entities, one with progression to SCC and the other without progression. Although the former is a true premalignant lesion and the latter is a reactive atypical epithelium, the concept of epithelial dysplasia (mild, moderate or severe) includes

both lesions and is a borderline category which can be placed in neither of the WHO's classifications.

As mentioned earlier, the dysplasia-carcinoma sequence theory as applied to the oral mucosa was adopted from the case of the uterine cervix, and the fundamental view of the WHO classification for oral cancer remained unchanged for more than three decades, from the first edition in 1971 (Wahi et al 1971, Napier&Speight 2008) to the latest version in 2005 (Gale et al 2005). WHO's "Histo-pathological Typing of Cancer and Precancer of the Oral Mucosa" (Pindborg et al 1997), is now used as a worldwide standard guide to diagnosis. The dysplastic features of oral mucosa are characterized by cellular atypia and loss of normal maturation and stratification, and the more severe the dysplasia, the greater the likelihood of malignant transformation. On the basis of the various criteria thought to be typical for the transformation of a dysplastic lesion to carcinoma, lesions are most frequently graded into one of four different groups: mild, moderate or severe dysplasia, or CIS, with the latter considered to be pre-invasive malignancy at the extreme end of epithelial dysplasia. Several histopathological changes may occur in epithelial dysplasia (Pindborg 1980). The criteria used for diagnosing dysplasia are provided in the form of a table in the WHO classification of tumours for the head and neck. Within the frame-work of the grading system of dysplasia, the more prominent or more numerous these factors are, the more severe the grade. These factors are limited to the lower third of the epithelium in mild dysplasia and extend to lower two-thirds of the epithelium in moderate dysplasia upward to the outer layer (Gale et al 2005). The use of the terms full thickness or almost full thickness architectural abnormalities is also recommended for the diagnosis of CIS.

This grading system of one-third, two-thirds and full thickness was described for the first time in the latest version of WHO's classification of head and neck tumours although it had been clearly referred to in the classification of uterine cervix since 1975 (Poulsen et al 1975). The large number of factors in this grading system would appear to be the basis of the many problems associated with the subjectivity of diagnosis (Pindborg 1980; Karabulut et al 1995; Holmstrup et al 2006). Accordingly, examination of the universality (inter-observer variability) and reproducibility (intra-observer variability) of this grading system for diagnosis has been carried out in recent years (Warnakulasuriya et al 2007; Kujan et al 2006; Kujan et al 2007; Ficher et al 2004; Tabor et al 2003; Abbey et al 1995; Brothwell et al 2003; Speight et al 1996) to sharply discriminate "indolent" low grade lesions, potentially reversible, from thoroughly preneoplastic high grade lesions. To this end, a novel binary grading system (low risk and high risk) designed to simplify the WHO classification and to raise the reproducibility of diagnosis has been advocated (Jares et al 1994; Califano et al 1996).

The histopathological criteria of dysplasia in the WHO classification are widely accepted among pathologists, and the concept of epithelial dysplasia outlined in the classification is considered to be correct in many cases (Crissman et al 1993; Putney&O'Keefe 1953; Ricci et al 2003; Franchi et al 2001). The notion that atypical cells progress from the basal layer to the surface is widely accepted in terms of the universality and reproducibility of diagnosis. However, it has become clear that there is a fatal flaw in this grading system as it does not, in practice, accurately reflect the clinical behaviour (Crissman&Zarbo 1989; Voravud et al 1993; Nadal&Cardesa 2003; Sanz-Ortega et al 2003; Chatrath et al 2003). The grades do not

offer clear therapeutic guidelines to clinicians for appropriate management. For CIS at least, the WHO grading system diagnoses CIS showing maturation and differentiation as lower risk lesions, and these lesions account for a large proportion of cases in the oral mucosa (Hellquist et al 1982; Gillis et al 1983; Yoo et al 2004; Kleist&Poetsh 2004; Jeannon et al 2004; Chi et al 2004).

6. SIN/dysplasia classification

In response to the concept of CIN in the uterine cervix, a similar view developed for the oral mucosa. In 2002, Kuffer&Lombardi stated that malignant transformation is a multistep process that should be approached from the histological—not merely clinical—standpoint. Intraepithelial neoplasia, a concept created in relation to the uterine cervix and already extended to other mucosae, should also be adapted for the case of the oral mucosa and used as diagnostic term: the use of the term oral intraepithelial neoplasia represents not only a change in terminology, but also progress in unifying the concept of the precursors of squamous cell carcinoma, while at the same time suppressing the futile debate about severe dysplasia and CIS. Furthermore, grading lesions as low- and high-grade OIN increases diagnostic consistency.

SIN/dysplasia in the oral cavity has been found to take two distinct morphological forms, at opposite ends of the SIN/ dysplasia spectrum: hyperplastic keratinizing SIN/dysplasia and atrophic SIN/dysplasia, which are clinically compatible with leukoplakia and erythroplakia, respectively. The former is keratinizing dysplasia and the latter is the classic (WHO type) form of dysplasia. As a complication, the features of these extremes overlap. Caution must be exercised as the admixture type of these two ends of the spectrum is commonly underdiagnosed and may not be recognized as high-grade SIN/dysplasia.

The SIN/dysplasia classification, a modification of the WHO grading system, proposes a category of keratinizing dysplasia to designate lesions showing superficial keratinization in association with high-grade cytological atypia in the lower epithelium (Crissman et al 1988; Blackwell et al 1995; Kambic~ et al 1992; Kambic~ 1997; Hellquist et al 1999; Crissman 1982). The authors suggesting this modification reported that these lesions have a high incidence of local relapse and a high progression rate to invasive SCC and, as such, they are included in the high-grade group as high-grade keratinizing SIN (Crissman&Sakr 2001; Sakr et al 2009). The authors further stressed that abnormal differentiation is present in these lesions in the form of aberrant keratinization (dyskeratosis), manifesting as single-cell keratinization and keratin pearls, occurring in the midst of the epithelium. The histopathological features used for grading OIN according to WHO are listed below:

1. Loss of polarity of the basal cells
2. Proliferation of the basal cells
3. Increased nucleus-to-cytoplasm ratio
4. Epithelial hyperplasia with drop-shaped submucosal rete extension
5. Irregular epithelial stratification and cellular pleomorphism
6. Premature keratinization of single cells (dyskeratosis) or keratin pearls in the rete pegs
7. Increased mitotic figures and abnormally superficial mitoses
8. Presence of abnormal mitotic figures
9. Variation in nucleus size, shape, and hyperchromatism; increased nucleus size

10. Increased number and size of nucleoli
11. Abnormal variation in cell shape and size.

The transition from normal epithelium to atypical epithelium and SCC is related to the progressive accumulation of genetic changes leading to a clonal population of transformed epithelial cells. Despite extensive research into these genetic changes in oral carcinogenesis, reliable genetic markers with diagnostic and prognostic value are still lacking (Gale et al 2009).

7. Ljubljana classification and SIL classification

The Ljubljana classification was devised by laryngeal pathologists Kambic and Lenart in 1971 (Hellquist et al 1999; Gale et al 2009; Kambic&Lenart 1971, Gale et al 2000). Based on clinical and histological observations, these authors adapted the classification to the specific demands of the oral cavity. The Ljubljana system nominally recognizes four grades: simple hyperplasia and basal/parabasal cell hyperplasia include mainly benign categories with a minimum risk of malignant alteration; atypical hyperplasia is potentially a malignant lesion; CIS is actually a malignant lesion (Kambic 1997; Gale et al 2000; Michaels 1997; Eversole 2009; Fleskens&Slootweg 2009; Koren et al, 2002). The main features that differentiate the Ljubljana grading system from other classifications are the distinction between mainly benign (squamous hyperplasia and basal-parabasal hyperplasia) and potentially malignant (atypical hyperplasia) lesions, and the positive separation of CIS from atypical hyperplasia. These two entities differ in morphology and progression to invasive carcinoma. In this classification, all histopathological change is included until it results in SCC (Crissman et al 1988; Sllamniku et al 1988; Crissman 1982). Although many studies have focused on the usefulness of this classification in relation to the larynx (Blackwell et al, 1995; Michaels 1997; Gale et al 2000; Kambic 1997; Frangez I et al, 1997), there is currently almost no verification of this in the oral mucosa (Mahajan&Hazarey 2004; Zerdoner 2003) so its usefulness cannot be discussed as yet.

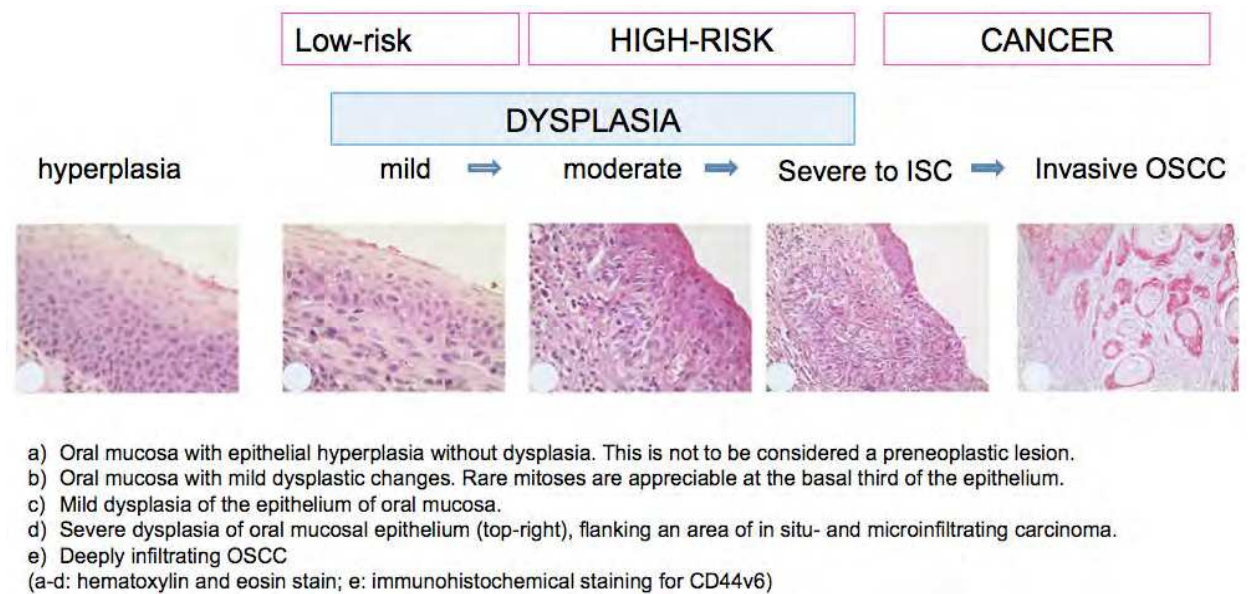


Fig. 1. Progression of Oral Cancer

The binary system which unites the SIN classification and the Ljubljana classification is advocated mainly by laryngeal pathologists. This system encompasses the Ljubljana classification into the SIN classification, with the concept of SILs being fundamentally the same (Gale et al 2009). The whole spectrum of histological changes, both reversible and irreversible, has recently been cumulatively designated as SIL, ranging from squamous hyperplasia to CIS. In terms of their evolution, some cases of SIL are self-limiting and reversible, some persist, and some progress to SCC despite careful follow-up and treatment. Although it would appear that both classifications can be unified, verification in the case of the oral mucosa remains to be determined.

8. Mechanisms of developing OIN

The genetic changes and the sequence of genetic events underlying the progression of normal mucosa to oral neoplastic tissue are still not entirely recognized. Between six and ten independent genetic events within a single cell have been estimated to be necessary for SCC development in the head and neck region. They are believed to be morphologically expressed as different grades of epithelial abnormality. The latency period between carcinogen exposure and appearance of malignancy may last up to 25 years.

The process of tumorigenesis of solid tumours, including oral neoplasia, involves both activation of proto-oncogene products that stimulate growth, and inactivation of tumour-suppressor genes (TSGs), the products of which normally inhibit cell proliferation (Califano et al 1996; Field 1996; Gallo et al 1997; Califano et al 2000). The identification and characterization of the comprehensive spectrum of genetic aberrations in SCC development may not only elucidate the process of carcinogenesis, but also provide promising diagnostic tools for early detection, prevention and assessment of cancer risk from precursor lesions.

9. Genetic progression model

Califano and co-workers have made two studies of cytogenetic alterations in head and neck carcinogenesis, which showed an increasing number of chromosomal alterations with the progression of Oral Intraepithelial Neoplasia (OILs), ranging from hyperplasia to CIS and invasive SCC. The areas of allelic loss, and less frequently allelic gain, are decisive elements in the progression model involving HNSCC. The results of Califano's studies have revealed that the spectrum of chromosomal loss progressively increases at each histopathological step of squamous intraepithelial lesions from benign hyperplasia to CIS and invasive SCC. The earliest alterations appear on chromosomes 9p21, where the p16 gene resides, at 3p with at least three putative tumour-suppressor loci, and at 17p13 where the p53 gene is located. Loss of chromosome region 9p21-22 appeared to be the most common of all genetic changes in HNSCC, with a frequency of 70% (van der Riet P et al 1994). Additional studies of microsatellite DNA allelic imbalance in oral carcinogenesis have confirmed that dysplasia correlates with loss of heterozygosity (LOH) at 3p21, 5q21, 9p21 and 17q13 (Sanz-Ortega J, 2003). Yoo et al. have suggested that 9p21 is the earliest event, already appearing in squamous metaplasia, as well as in invasive and metastatic SCC. LOH at 17p13, 3p35 and 3p14 was observed as an intermediate event, occurring from dysplasia to metastatic SCC (Yoo et al 2004). Micro-satellite instability (MSI), a novel marker of genetic instability, was also applied in a study to assess the risk of malignant progression in laryngeal preinvasive

lesions. The authors concluded that MSI is more common in preneoplastic oral lesions that have progressed to invasive SCC. They suggest that MSI assessment may be useful in determining the risk of malignant alteration in patients for whom chemopreventive and multiple endoscopic protocols can be attempted (Sardi et al 2006).

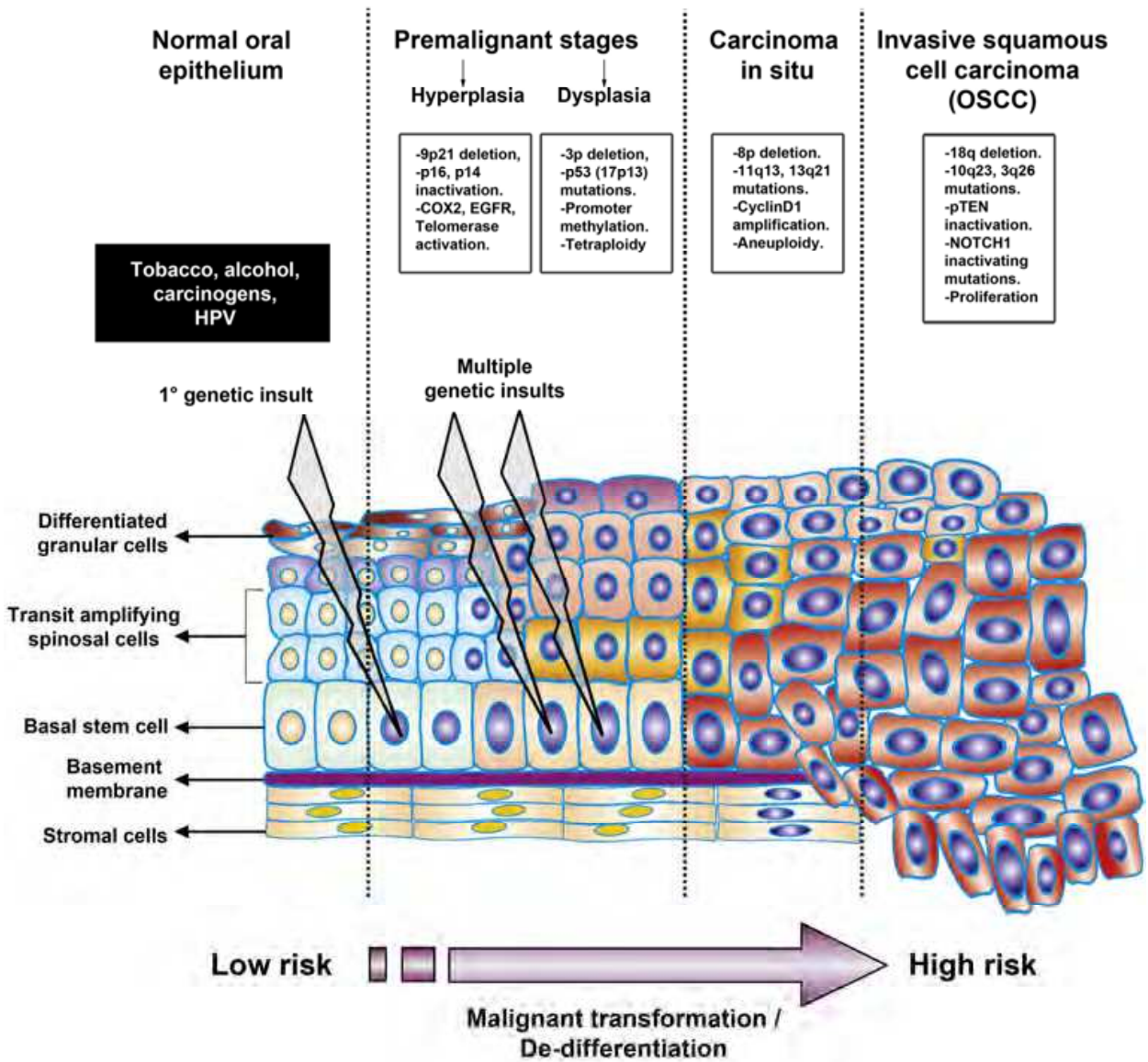


Fig. 2. Genetic Progression Model

10. Key tumour-suppressor genes in oral carcinogenesis

Gene p16 can be inactivated by a variety of mechanisms, such as mutation, homozygous deletion and promoter hypermethylation (Kamb et al 1994; Merlo et al 1995). The p16 gene functions as an inhibitor of cyclin-dependent kinase 4 and 6, with subsequent abrogation of retinoblastoma (Rb) phosphorylation and G1 cell cycle arrest (Serrano et al 1993; Kim et al 2004). Loss of chromosome region 9p21-22 occurs prior to the development of histological atypia, already at the level of hyperplastic mucosa, and is regarded as an early event in the development of HNSCC (Hasina&Lingen 2004).

Another important region identified by allelic loss is chromosome 17p, the site of the p53 gene. It is involved in several key cell functions such as gene transcription, DNA synthesis and repair, cell-cycle coordination and apoptosis. Mutation/inactivation of the p53 gene has been detected in approximately 50%, but may be present in as high as 80% of HNSCCs (Balz et al 2003). It remains unclear whether p53 gene inactivation is an early or late event of oral carcinogenesis. According to Boyle and co-workers, it occurs in the transition from the preinvasive to invasive form (Boyle et al 1993). Some others argue the opposite, presenting alterations of p53 among early steps of neoplastic transformation. Furthermore, gene p53 mutation has been hypothesized to be the earliest event in the development of a genetically altered field in oral mucosa, identifying an area of clonally related cells with malignant potential (Braakhuis et al 2003).

Although LOH frequently appears in head and neck carcinogenesis at chromosome 3p, the genes at this region have not been well defined (Ha&Califano 2002). The fragile histidine triad (FHIT) gene has been identified on chromosome 3p14 as one candidate for TSG, altered by deletions in human tumours. The expression of FHIT protein has recently been studied in HNSCC and premalignant lesions (Yuge et al 2005). Loss of FHIT protein was observed in 42% of SCCs and 23% of premalignant lesions. There was no significant difference among the three grades of dysplasia and FHIT expression. The results of this study indicate that FHIT alterations may play an important role in early events of carcinogenesis.

11. Key oncogenes in malignant alteration of SILs

Chromosome region 11q13 has been identified as the site of several putative oncogenes, such as Bcl-1, int-2, hst-1, EMS-1 and cyclin D1/PRAD1 (Kim&Califano 2004). Amplification of 11q13 is detected in approximately one-third of HNSCCs, but only cyclin D1 has shown consistent overexpression/amplification (Jares et al 1994, Callender et al 1994). The function of proto-oncogene cyclin D1 is to activate Rb via phosphorylation, thus facilitating progression from the G1 phase to the S phase (Kim&Califano 2004).

12. HPV-linked OSCC and OIN

Besides the evident epidemiological meaning, HPV infection linked to OSCC development shows clinical implications as these patients have about half the risk of death with respect to HPV-negative OSCC ones (Fakhry et al 2006). Moreover, the incidence of the subsets of OSCC more frequently found associated with HPV infection, i.e. tongue and tonsillar cancers, has been rising in young men and women 18 to 44 years old (67% of increase) for the past three decades, and the trend is actually most evident for young white women (Patel et al, 2011), whereas the OSCC incidence is declining for nonwhite men, for all age groups. These findings have been justified with the decrease of alcohol and smoke abuse, and the relative prevalence of infection with high-risk HPV strains, particularly in youngs.

This identifies then distinct risk factor profiles for HPV-positive and HPV-negative OIN patients, and justifies the designation of clinical trials to assess the optimal treatment for these groups. From a histopathological point-of-view, the HPV-linked OIN are mostly undifferentiated (Carpenter et al 2011).

This is particularly intriguing, considering that traditionally undifferentiated cancers have a very worse clinical outcome, being radio- and chemo-resistant, whereas HPV-linked undifferentiated OIN seems to have a better overall prognosis and a good response to post-surgical therapy.

For this reason, it seems fundamental to easily detect this subgroup of cancers and precancerous lesions, to preserve patients from overtreatment of their lesions.

Since high-risk HPVs lead to the intracellular accumulation of p16INK4a protein, due to the E7 block of pRb, it has been proposed to utilize the immunohistochemical evaluation of p16 for the screening of lesional tissue obtained from diagnostic biopsies. This has been shown to reliably predict the high-risk HPV infection in oral biopsies (Hoffmann et al 2010).

The screening with IHC for p16 INK4a protein, then, may be regarded as a precious tool for the proper evaluation of the outcome and responsiveness to therapy of oral cancer and precancerous lesions.

13. Key protein-based alterations in oral carcinogenesis

Protein overexpression can appear as a consequence of gene amplification, increased DNA transcription and translation. Several gene products can influence cancer progression in this manner (Ha&Califano 2002).

Epidermal growth factor receptor (EGFR), located on chromosome 7p12, codes for transmembrane growth-regulating receptor glycoprotein, which influences cell division, migration, adhesion, differentiation and apoptosis through a tyrosine kinase pathway (Pomerantz&Grandis 2004). The EGFR gene was found to be amplified in 25%, and its mRNA was overexpressed in 43% of oral SCCs. Half of the expressed cases occurred in the absence of detectable gene amplification. Both alterations appeared in advanced HNSCC (Irish&Bernstein 1993). Furthermore, overexpression of EGFR protein is an early event in carcinogenesis, rising with increasing degree of epithelial abnormalities, mainly in the progression of oral intraepithelial lesions to SCC (Shin et al 1994; Gale et al 1997).

Eucaryotic initiation factor 4E (eIF4E) is a 24-kDa protein, which binds to mRNA as the initial rate-limiting step in protein synthesis. Amplification and overexpression of the eIF4E gene, located at chromosome 4q21, has been associated with malignant transformation in breast cancer and HNSCC. The proto-oncogene eIF4E was found to be elevated in 100% of HNSCCs and is of prognostic value in predicting recurrence (Sorrells et al 1999).

14. Field cancerization

In early 1953, Slaughter et al. proposed the clinical concept of field cancerization to explain the development of multiple cancers and precursor lesions in the head and neck area, particularly in the oral cavity. Their concept is based on long-term carcinogenic exposure, which causes the independent transformation of multiple epithelial cells at separate sites. Polyclonal tumours may independently arise from these spots. The so called histologically-based field cancerization model has been gradually succeeded by a new one established on the basis of molecular changes of the affected mucosa. This hypothesis advocates a micrometastatic spread or a monoclonal theory, suggesting that a precancerous field of

mucosa may derive from an early genetic event that has undergone clonal expansion and lateral migration or expansion (Ha&Califano 2002, Califano et al 1996; 2000; Bedi et al 1996). Subsequent genetic alterations produce genetic divergence and various phenotypic alterations, resulting in a variety of histopathologically diverse regions in the local anatomical area and in the selection of various subclones. The theory, therefore, proposes a clonal origin of premalignant cells with successive lateral migration, and possible multiple primary tumours would not be monoclonal, but clonally related (Almadori et al 2004).

15. Telomerase reactivation in malignant alteration of OIN

The telomerase enzyme is a specialized multisubunit complex, with telomerase catalytic subunit (hTERT) functioning as a reverse transcriptase that can synthesize the telomeric ends at each cell division. Telomerase has been found to be re-activated in 90% of malignant neoplasms, including oral SCC (Meyerson et al 1996; Shay &Wright 1996, Luzar et al 2001). Recent studies have confirmed a close relationship between hTERT mRNA expression and telomerase activity, suggesting that quantification of hTERT gene expression can be used as an alternative to measurement of telomerase activity (De Kok et al 2000). These results suggest that telomerase re-activation is an early event in oral carcinogenesis, already detectable at the stage of precancerous oral epithelial changes.

16. Additional markers of malignant alterations of oral intraepithelial neoplasia

Several studies of OIN generally agree that the severity of epithelial abnormality reflects the degree of risk of SCC development (Jeannon et al 2004). No marker or group of markers has so far been identified as a reliable predictor of malignant progression of SILs. It is therefore under-standable that numerous studies have been devoted to the progression of OIN to invasive SCC. The role of cell-cycle proteins such as p16, p21, p27, p53, cyclin D1 and E have been extensively studied over the last two decades (Shin et al 1994; Fraczek et al 2007; Gorgoulis et al 1994; Gale et al 1997; Dolcetti et al 1992; Barbatis et al 1995; Nadal et al 1995; Poljak et al 1996; Uhlman et al 1996; Hirai et al 2003; Ioachim et al 2004; Wayne&Robinson 2006). However, none of these markers has been found to have reliable predictive value. In addition, detection of proliferative activity, mainly as immunohistochemical labelling for pCNA and Ki67 antigens, can be used only as adjuncts to light microscopy for more objective and reliable histological grading of OIN (Leopardi et al 2001; Peschos et al 2005). Recent study of the transforming growth factor-beta (TGF- β RII) has indicated that its down-regulation is an early event in oral carcinogenesis, which may occur in the loss of TGF- β -mediated inhibition, thereby facilitating progression of precancerous lesions to SCC (Franchi A, 2001). Promising biomarkers for improving cancer detection include minichromosome maintenance proteins (Mcm-2-7), which assemble in the prereplication complex and are essential for DNA replication in eucaryotic cells. All six proteins are abundant throughout the cell cycle, being broken down rapidly on differentiation and more slowly in quiescence. In 2003 Chatrath et al found that Mcm-2 is expressed within the most superficial surface layer in cases of oral CIS and SCC and with minimal expression in basal-parabasal (abnormal) and atypical hyperplasia. The authors suggest that Mcm-2 would be a good biomarker for distinguishing premalignant from malignant lesions. Quantification of cellular DNA by image or flow cytometry has achieved acceptance as an objective and

reproducible component in diagnostic pathology. Several studies of oral intraepithelial lesions have shown that a proportion of these lesions show abnormal DNA content and that the incidence of this finding correlates with the degree of oral intraepithelial lesions (Brac̣ko 1997; Munck-Wikland et al 1991; Crissman&Zarbo 1991). Brac̣ko has additionally noted that lack of abnormal DNA does not exclude malignant alteration, since malignant tumours exhibit minimal chromosomal abnormalities resulting in DNA changes, which are below the threshold of sensitivity of measurement with the use of image analysis or flow cytometry. In 2004, Kim and co-workers performed a study of quantitative PCR for genes specific to mitochondrial abundance in a spectrum of dysplastic head and neck lesions (Kim et al 2004b). Their study shows that mitochondrial DNA is directly proportional to histopathological grade.

17. Next-generation sequencing reveals NOTCH1 as an important tumor suppressor gene in head and neck cancer

Recently (Brakenhoff 2011; License Number 2756960749906), two papers came out on Science (Agrawal 2011; Stransky 2011). Their aim has been to provide new insight into the genetic changes of Head&Neck-SCC that may suggest the development of alternative treatment strategies. By using a high-throughput technique called massively parallel sequencing or next-generation sequencing to analyze the genomes of head and neck cancers in great detail. Both groups sequenced the exons of all known human genes in tumor DNA and compared the sequence to that of the corresponding normal DNA of the same patient. In total, the genomic landscapes of 32 (Agrawal 2011) and 74 (Stransky 2011) tumors were examined, including tumors that were positive or negative for the human papillomavirus. Agrawal et al. also provided genetic profiling data on chromosomal changes, verified the mutations by classical Sanger sequencing, and validated some mutations in an additional panel of tumor and normal tissues. Mutations were found in many of the genes already known to play a role in HNSCC, such as TP53, CDKN2A, PIK3CA, PTEN, and HRAS, but at least one new cancer gene previously not known to be involved in HNSCC, NOTCH1, was identified. In both studies, inactivating mutations of NOTCH1 were found in 10 to 15% of the head and neck tumors, and it was the second most frequently mutated gene after TP53 (which is mutated in 50 to 80% of the tumors). In several tumors, both alleles harbored mutations in NOTCH1.

Why was NOTCH1 not found before in this type of cancer or even in other malignancies (Klinakis et al 2011,) as an important tumor suppressor? Functional studies had identified a role for NOTCH1 in squamous cell carcinogenesis, at least in the skin (Dotto 2008), but robust mutational data in clinical samples were missing. NOTCH1 is a very large gene consisting of 34 coding exons, which hampers classical (Sanger) DNA sequencing, thus demonstrating the major improvement afforded by next-generation sequencing platforms.

The finding of numerous inactivating mutations in NOTCH1 in HNSCCs and the observation that mice with a disrupted NOTCH1 gene in the skin show a skin cancer phenotype (Nicolas et al 2003; Proweller et al 2006) provide strong evidence that NOTCH1 is an important tumor suppressor gene in HNSCC. NOTCH1 encodes a transmembrane receptor that functions in cell-to-cell communication (Ranganathan et al 2011) and is in the skin typically located in the cilia of the squamous cells, the dermal keratinocytes (Okuyama et al 2008; Ezratty et al 2011).

After ligand binding, the cytoplasmic tail of NOTCH is cleaved by a secretase enzyme, translocates to the nucleus, and functions as a transcription factor, driving the expression of numerous genes. All four NOTCH receptors encoded in the human genome are important for cell differentiation. Stransky et al. also found mutations in other cell differentiation-related genes, such as NOTCH2, NOTCH3, and TP63, suggesting that deregulation of the terminal differentiation program of mucosal keratinocytes is critical for squamous cancer development. This is not unexpected because terminal differentiation of normal keratinocytes in skin and mucosal epithelia is characterized by loss of cell organelles and even the nucleus during cornification—events that support the barrier function of squamous epithelia but which would inhibit malignant transformation.

However, some questions remain. A high-throughput sequencing approach can reveal many mutations in a large number of genes, but this does not necessarily imply that these are all “driver mutations” causally related to the malignant transformation process. Tumors are genetically unstable and acquire many mutations including so-called “passenger mutations” (Sjoblom et al 2006; Wood et al 2007) that are a result of malignant transformation and not the cause. Functional studies in animal models are required to elucidate the exact role of the NOTCH receptors and the other genes that are mutated in HNSCC. As an example, Agrawal et al. indicated that they also found mutations in FBXW7 in tumors that lack inactivating NOTCH1 mutations. The FBXW7 protein is a component of a ubiquitin ligase complex that targets NOTCH receptors for degradation by the proteasome, the protein degradation system of the cell, and this could be considered an inhibitory regulatory system of NOTCH1. Surprisingly, these FBXW7 mutations were also inactivating. One would have expected activating mutations in this inhibitory downstream pathway, assuming that NOTCH1 is the target. Hence, this requires more detailed investigation. Relating mutations to phenotypic consequences is a challenge for all potential cancer genes identified by these high-throughput methods. Even non-synonymous mutations in established cancer genes may not always be driving, unless supported by functional testing in relevant models.

An issue even more relevant to clinical application is that identification of a cancer gene does not mean that it is druggable. As Agrawal et al. note, proteins encoded by oncogenes (genes that, when activated, cause a normal cell to become cancerous) are most suited for treatments because inhibitory drugs will result in a reduction of cellular proliferation. However, in the case of inactivated or lost tumor suppressor proteins, inhibitors are of no use, and reactivation is complex or impossible. Instead, one has to make use of the principle of synthetic lethality—finding another pathway that compensates the effect of, for example, NOTCH pathway inactivation (Iglehart & Silver 2009). Cancer-associated signaling pathways are often so critical for cellular homeostasis that there are mechanisms of redundancy to compensate inactivation, and these take over in tumor cells. Blocking this compensating pathway is then lethal for tumor cells, whereas in normal cells this has less effect as both pathways are active. This principle of synthetic lethality is a highly successful strategy, as shown by the application of poly(ADP-ribose) polymerase inhibitors in BRCA1- and BRCA2-deficient breast cancers (Fong et al 2009). However, the presence of such compensating pathways and their synthetic lethal character need to be identified. Hence, there is more work to be done, but the studies by Agrawal et al and Stransky et al indicate that there are more candidate cancer genes to be identified and we should keep searching for them.

18. Cancer stem cells in oral cancer

The cancer stem cell hypothesis suggests that neoplastic clones are maintained exclusively by a rare fraction of cells with stem cell properties. Stem cells are defined as cells which are able to both extensively self-renew and differentiate into progenitors. Furthermore, stem cells are also attractive candidates as origin of cancers, as in their long lifespan they can acquire mutations and epigenetic changes that could favour the evolution toward malignancy. We discuss the evidences reported in literature on existence of cancer stem cells in oral cancer and mechanisms of the extrinsic and intrinsic circuitry controlling stem cell fate as well as their possible connections to cancer.

Oral cancer is a culmination of continued hyperplasia or uncontrolled proliferation of basal epithelial stem cells. In a well differentiated tumor tissue, the suprabasal cells exhibit basal stem-like phenotype and differ from the terminal highly keratinized cells. Many experiments have compared the expression patterns of epidermal and oral epithelial stem cells (Kaur&Li 2000; Evander et al 1997). Up to now, no true stem cell population could be identified from both normal and tumor tissue of oral epithelium purely based on sorting for stem cell specific surface markers reported from epidermal tissue (Prince&Ailles 2008). The stratified squamous epithelia of the oesophagus and epidermis have different functions and embryological origins. The pursuit for specific oral epithelial stem cell surface markers lead to the identification of CD markers such as CD44 (Prince et al 2007; Naor et al 2008), CD147 (Kose et al 2007; Toole et al 2008), integrins (Evander et al 1997), cytokeratins (Lindberg et al 1989, Presland et al 2002), EpCAM/ESA (Trzpis et al 2007; Munz et al 2004), E-cadherin (Kudo et al 2004), along with transcription factors Oct-4, Nanog (Chiou et al 2008) and Bmi-1 (Prince et al 2007). p75NGFR, a potential oral keratinocyte stem cell marker also co-localizes with BrdU incorporated stem cells and functions to mediate intercellular signaling in cell survival and apoptosis (Hatakeyama et al 2007; Nakamura et al 2007). An ideal cancer stem cell marker should impart all the acquired hallmarks of self-sufficiency in growth signals, anchorage-independent growth, apoptotic/drug resistance, invasiveness, metastatic potential in addition to primacy of high self-renewal conferred by cell of its origin, the normal stem cell. We discuss below several such stem cell markers representing the putative CSCs in oral squamous cell carcinoma and functional attributes bestowed by the expression pattern.

Methods for the identification of CSCs in solid malignancies mirror those strategies employed to differentiate normal stem cells from their differentiated progeny. These include the efflux of vital dyes by multidrug transporters, the enzymatic activity of aldehyde dehydrogenase, colony and sphere-forming assays utilizing specific culture conditions and the most widely used method—the expression of specific cell surface antigens known to enrich for stem cells. Once the subpopulation of tumor cells has been identified and isolated, functional characterization through quantitative xenotransplantation assays, the gold-standard for identification of CSCs, are used to assess the tumorigenicity and self-renewing potential of the putative CSC population in vivo

18.1 Surface antigens

By far the most common method of identifying CSCs has relied on the expression of specific cell-surface antigens that enrich for cells with CSC properties. Many of these antigens were

initially targeted because of their known expression on endogenous stem cells. While a multitude of studies have identified CSC markers across a variety of solid malignancies, relatively few of these markers have been studied in HNSCC. **CD133.** A pentaspan transmembrane glycoprotein localized on cell membrane protrusions (Costea et al 2006; Prince&Alley 2008), is a putative CSC marker for a number of epithelial malignancies including brain, prostate, colorectal, and lung (Chiou et al 2008; Kelly et al 2007). In HNSCC cell lines, CD133hi cells display increased clonogenicity, tumor sphere formation and tumorigenicity in xenograft models when compared to their CD133 low counterparts (Ramalho-Santos&Willenbring 2007; Singh et al 2004; Ricci-Vitiani et al 2007). **CD44.** A large cell surface glycoprotein involved in cell adhesion and migration. It is a known receptor for hyaluronic acid and interacts with other ligands such as matrix metalloproteases (Tan&Coussens 2007; Mimeault M, 2007). Initially identified as a solid malignancy CSC marker in breast cancer (Tabor et al 2002), Prince et al. demonstrated that CD44 expression could also be used to isolate a tumor subpopulation with increased tumorigenicity in HNSCC (Pillai&Nair 2000). Although CD44 expression enriches for cells with CSC properties, the relatively high number of cells required for tumor formation as compared with known CSC populations from other epithelial malignancies raises questions about whether CD44 expression alone is sufficient for isolation of a pure CSC population. Using primary human tumor samples as well as utilizing a more natural host microenvironment through an orthotopic xenograft model (Pheesse&Clarke 2009) might reduce the number of cells needed to generate tumors.

18.2 Aldehyde dehydrogenase activity

Aldehyde dehydrogenase (ALDH) is an intracellular enzyme normally present in the liver. Its known functions include the conversion of retinol to retinoic acids and the oxidation of toxic aldehyde metabolites, like those formed during alcohol metabolism and with certain chemotherapeutics such as cyclophosphamide and cisplatin (Bosron et al 1988; Thomasson et al 1991; Visus et al 2007). ALDH activity is known to enrich hematopoietic stem/progenitor cells (Chute et al 2006) and more recently has been shown to enrich cells with increased stem-like properties in solid malignancies (Carpentino et al 2009; Croker et al 2009; Deng et al 2010; Ma et al 2008). Chen et al. showed that ALDH activity correlated with disease staging in HNSCC and that higher enzymatic activity correlated with expression of epithelial-to-mesenchymal transition (EMT) genes as well as enriching cells with CSC properties (Chen et al 2009). **Side Population.** Hoechst 33342 is a fluorescent DNA- binding dye that preferentially binds to A-T rich regions. It is actively pumped out of cells by members of the ATP-binding cassette (ABC) transporter superfamily. Once stained with Hoechst dye, cells can be sorted by fluorescent-activated cell sorting (FACS) based upon the activity level of these multidrug transporters. Originally noted to enrich bone marrow for long-term hematopoietic stem cells (Clay et al 2010), this method has also been used to identify cells within solid tumors with increased tumorigenicity (Ho et al 2007; Szotek et al 2006; Wang et al 2007). Side population (SP) cells from oral squamous cell carcinoma have been shown to have increased clonogenicity and tumorigenicity in xenotransplantation assays (Loebinger et al 2008). Furthermore, HNSCC SP cells displayed higher expression of known stem cell related genes—Oct4, CK19, BMI-1 and CD44—and lower expression of involucrin and CK13, genes associated with a differentiated status (Zhang et al 2009).

18.3 Tumor sphere formation

Under serum-free culture conditions CSCs can be maintained in an undifferentiated state, and when driven toward proliferation by the addition of growth factors, form clonally derived aggregates of cells termed tumor spheres (Singh et al 2003). The ability of CSCs—but not the remaining tumor bulk—to form tumor spheres has been used extensively in neural tumors to identify populations enriched for CSCs. In HNSCC, these spheres have been shown to be enriched for stem markers, including CD44hi (Okamoto et al 2009), Oct-4, Nanog, Nestin, and CD133hi (Zhang et al 2009), as well as exhibiting increased tumorigenicity in orthotopic xenografts (Chiou et al 2008).

19. Cancer stem cells and disease progression

While there exists significant data defining the presence of CSCs within a variety of tumor types and many aspects of the cell and molecular biology of CSC have been elucidated, the manner in which this unique cell population influences clinical disease progression remains unclear. Given that metastases can be formed from implantation of a single tumor cell (Fidler&Talmadge 1986), it seems likely that CSCs, as the progenitor of all tumor cell types, would be responsible for metastatic spread. Central to the CSC hypothesis is the presence of a unique stem cell “niche” or environment necessary to support the growth of stem cells (Li&Xie 2005). It has been shown that a premetastatic niche is established by the attraction of bone marrow derived cells to the future site of metastases by the secretion of factors from cancer cells and that blocking the creation of this premetastatic niche prevents metastases (Kaplan et al 2005). What these secreted factors are and whether they are secreted by CSCs or one of their progeny remains an open question; however, creation of this niche, possibly for the arrival of CSCs to form a metastasis, appears to be a crucial step in metastatic spread.

Another stem cell marker, CD44, has also been implicated in metastatic spread and disease progression in HNSCC (Celetti et al 2005), although the CD44 story is more complex. Recently, three different isoforms, CD44 v3, v6, and v10, have been shown to be associated with progression and metastasis of HNSCC (Wang et al 2009). Increased CD44 v3 expression in primary tumors was associated with lymph node metastasis, while CD44 v10 expression was associated with distant metastasis and CD44 v6 expression was associated with perineural spread. In cell culture, blockade of these CD44 isoforms with isoform-specific antibodies inhibited cellular proliferation, with the greatest inhibition seen with blockade of CD44 v6. Finally, increased expression of CD44 v6 and v10 was associated with shortened disease-free survival (Staibano et al 2007). These studies suggest that alteration in CSC phenotype through variation in CD44 isoform expression may alter the interaction of CSCs with the surrounding microenvironment. This may allow CSCs to more readily invade surrounding tissues or metastasize, thereby promoting disease progression.

20. Treatment and evolution to malignancy

To date, many researchers have reported that the risk of developing cancer from oral leukoplakia could not be significantly reduced by surgical intervention (Holmstrup et al 2006; Vedtofte et al 1987; Schoelch et al 1999). Moreover, some review papers have stated that it is actually unclear whether removal of the lesion decreases malignant transformation

of oral leukoplakia because there is a lack of randomized controlled trials comparing the different treatment modalities (Lodi et al 2006, Lodi&Porter 2008).

Nevertheless, the research by Amagasa et al. (2006; 2011a; 2011b) showed that the malignant transformation rate of leukoplakia treated by surgery was significantly lower than that without any treatment or that without surgery, so we believe that surgical excision with an adequate safety margin, coupled with well-timed evaluation of oral leukoplakia on follow-up, is effective in preventing the malignant transformation of these lesions.

21. References

- Abbey L, Kaugars GE, Gunsolley JC et al (1995) Intraexaminer and interexaminer reliability in the diagnosis of oral epithelial dysplasia. *Oral Surg Oral Med Oral Pathol* 80:188–191
- Agrawal N, Frederick MJ, Pickering CR, Bettegowda C, Chang K, Li RJ, et al (2011) Exome Sequencing of Head and Neck Squamous Cell Carcinoma Reveals Inactivating Mutations in NOTCH1, *Science* 333, 1154.
- Almadori G, Bussu F, Cadoni G et al (2004) Multistep laryngeal carcinogenesis helps our understanding of the field cancerisation phenomenon: a review. *Eur. J. Cancer* 40; 2383– 2388.
- Amagasa T, Yamashiro M, Ishikawa H (2006) Oral leukoplakia related to malignant transformation. *Oral Sci Int* 3:45–55
- Amagasa T (2011a) Oral premalignant lesions *Int J Clin Oncol* 16:1–4
- Amagasa T, Yamashiro M, Uzawa N (2011b) “Oral premalignant lesions: from a clinical perspective” *Int J Clin Oncol* 16:5–14
- Axell T, Pindborg JJ, Smith CJ et al (1996) Oral white lesions with special reference to precancerous and tobacco-related lesions. *J Oral Pathol Med* 25:49–54
- Balz V, Scheckenbach K, Gotte K, Bockmuhl U, Petersen I, Bier H (2003) Is the p53 inactivation frequency in squamous cell carcinomas of the head and neck underestimated? Analysis of p53 exons 2-11 and human papillomavirus 16 / 18 E6 transcripts in 123 unselected tumor specimens. *Cancer Res* 63; 1188–1191.
- Barbatis C, Loukas L, Grigoriou M et al (1995) p53 overexpression in laryngeal squamous cell carcinoma and dysplasia. *Clin. Mol. Pathol* 48; M194–M197.
- Bedi GC, Westra WH, Gabrielson E, Koch W, Sidransky D. (1996) Multiple head and neck tumors: evidence for a common clonal origin. *Cancer Res.* 56; 2484–2487.
- Blackwell KB, Calcaterra TC, Fu YS (1995) Laryngeal dysplasia: epidemiology and treatment outcome. *Ann Otol Rhinol Laryngol* 104:596–602
- Blackwell KE, Fu YS, Calcaterra TC (1995) Laryngeal dysplasia. A clinicopathologic study. *Cancer* 75; 457–463.
- Bonneretal JA, *N.Engl.J.Med.*354,567(2006).
- Bosman FT (2001) Dysplasia classification: pathology in disgrace? *J. Pathol.* 194; 143–144.
- Bosron WF, Lumeng L, and Li TK (1988) “Genetic polymorphism of enzymes of alcohol metabolism and susceptibility to alcoholic liver disease,” *Molecular Aspects of Medicine*, vol. 10, no. 2, pp. 147–158
- Bouquot JE, Gnepp DR (1991) Laryngeal precancer: a review of the literature, commentary, and comparison with oral leukoplakia. *Head Neck* 13; 488–497.

- Bouquot JE, Speight PM, Farthing PM (2006) Epithelial dysplasia of the oral mucosa—diagnostic problems and prognostic features. *Curr Diagn Pathol* 12:11–21
- Boyle JO, Hakim J, Koch W et al (1993) The incidence of p53 mutations increases with progression of head and neck cancer. *Cancer Res* 53; 4477–4480.
- Braakhuis BJ, Tabor MP, Kummer JA, Leemans CR, Brakenhoff RH (2003) A genetic explanation of Slaughter's concept of field cancerization: evidence and clinical implications. *Cancer Res* 63; 1727–1730.
- Brac'ko M. Evaluation of DNA content in epithelial hyperplastic lesions of the larynx (1997) *Acta Otolaryngol* 527(Suppl.); 62–65.
- Brakenhoff RH (2011) Another NOTCH for Cancer, *Science* 333, 1102–1103
- Broders AC (1932) Carcinoma in situ contrasted with benign penetrating epithelium. *J Am Med Assoc* 99:1670–1674
- Brothwell DJ, Lewis DW, Bradley G et al (2003) Observer agreement in the grading of oral epithelial dysplasia. *Commun Dent Oral Epidemiol* 31:300–305
- Callender T, el-Naggar AK, Lee MS, Frankenthaler R, Luna MA, Batsakis JG (1994) PRAD-1 (CCND1)/cyclin D1 oncogene amplification in primary head and neck squamous cell carcinoma. *Cancer* 74; 152–158.
- Califano J, van der Riet P, Westra W et al (1996) Genetic progression model for head and neck cancer: implications for field cancerization. *Cancer Res* 56; 2488–2492.
- Califano J, Westra WH, Meininger G, Corio R, Koch WM, Sidransky D (2000) Genetic progression and clonal relationship of recurrent premalignant head and neck lesions. *Clin. Cancer Res* 6; 347–352.
- Carpenter DH, El-Mofty SK, Lewis JS Jr (2011) Undifferentiated carcinoma of the oropharynx: a human papillomavirus-associated tumor with a favorable prognosis. *Mod Pathol* 24(10):1306–12.
- Carpentino JE, Hynes MJ, Appelman HD et al (2009) Aldehyde dehydrogenase-expressing colon stem cells contribute to tumorigenesis in the transition from colitis to cancer *Cancer Research*, vol. 69, no. 20, pp. 8208–8215
- Celetti A, Testa D, Staibano S, Merolla F, Guarino V, Castellone MD, et al (2005) Overexpression of the cytokine osteopontin identifies aggressive laryngeal squamous cell carcinomas and enhances carcinoma cell proliferation and invasiveness. *Clin Cancer Res* 15;11(22):8019–27.
- Chatrath P, Scott IS, Morris LS et al (2003) Aberrant expression of minichromosome maintenance protein-2 and Ki67 in laryngeal squamous epithelial lesions. *Br. J. Cancer* 89; 1048– 1054.
- Chen Y-C, Chen Y-W, Hsu H-S et al (2009) Aldehyde dehydrogenase 1 is a putative marker for cancer stem cells in head and neck squamous cancer *Biochemical and Biophysical Research Communications*, vol. 385, no. 3, pp. 307–313.
- Chi FL, Yuan YS, Wang SY, Wang ZM (2004) Study on ceramide expression and DNA content in patients with healthy mucosa, leukoplakia, and carcinoma of the larynx. *Arch. Otolaryngol. Head Neck Surg* 130; 307–310.
- Chiou S-H, Yu C-C, Huang C-Y, Lin S-C, Liu C-J, Tsai T-H et al (2008) Positive correlations of Oct-4 and Nanog in oral cancer stem-like cells and high-grade oral squamous cell carcinoma, *Clinical Cancer Research* 14 4085–4095.

- Chute JP, Muramoto GG, Whitesides J et al (2006) Inhibition of aldehyde dehydrogenase and retinoid signaling induces the expansion of human hematopoietic stem cells," *Proceedings of the National Academy of Sciences of the United States of America*, vol. 103, no. 31, pp. 11707-11712.
- Clay MR, Tabor M, Owen JH et al (2010) Single-marker identification of head and neck squamous cell carcinoma cancer stem cells with aldehyde dehydrogenase *Head Neck*, vol. 32, no. 9, pp. 1195-1201.
- Costea D, Tsinkalovsky O, Vintermyr O, Johannessen A, Mackenzie I (2006) Cancer stem cells new and potentially important targets for the therapy of oral squamous cell carcinoma, *Oral Diseases* 12 443-454.
- Crissman JD (1979) Laryngeal keratosis and subsequent carcinoma. *Head Neck Surg* 1; 386-391.
- Crissman JD (1982) Laryngeal keratosis preceding laryngeal carcinoma. A report of four cases. *Arch Otolaryngol* 108:445-448
- Crissman JD, Fu YS (1986) Intraepithelial neoplasia of the larynx. *Arch. Otolaryngol. Head Neck Surg.* 112; 522-528.
- Crissman JD, Zarbo RJ, Drozdowicz S et al (1988) Carcinoma in situ and microinvasive squamous carcinoma of the laryngeal glottis. *Arch Otolaryngol Head Neck Surg* 114:299-307
- Crissman JD, Zarbo RJ (1989) Dysplasia, in situ carcinoma, and progression to invasive squamous cell carcinoma of the upper aerodigestive tract. *Am. J. Surg. Pathol.* 13(Suppl. I); 5- 16.
- Crissman JD, Zarbo RJ (1991) Quantitation of DNA ploidy in squamous intraepithelial neoplasia of the laryngeal glottis. *Arch. Otolaryngol. Head Neck Surg.* 117; 182-188.
- Crissman JD, Visscher DW, Sakr W (1993) Premalignant lesions of the upper aerodigestive tract: pathologic classification. *J. Cell. Biochem. Suppl.* 17F; 49-56.
- Crissman JD, Sakr WA (2001) Squamous intraepithelial neoplasia of upper aerodigestive tract. In: Gnepp DR (ed) *Diagnostic surgical pathology of the head and neck*. Saunders, Philadelphia, pp 1-17
- Crocker AK, Goodale D, Chu J et al (2009) High aldehyde dehydrogenase and expression of cancer stem cell markers selects for breast cancer cells with enhanced malignant and metastatic ability," *Journal of Cellular and Molecular Medicine*, vol. 13, no. 8 B, pp. 2236-2252 .
- De Kok JB, Schalken JA, Aalders TW, Reurs TJM, Willems HL, Swinkels DW (2000) Quantitative measurement of telomerase reverse transcriptase (hTERT) mRNA in urothelial cell carcinomas. *Int. J. Cancer* 87; 217-220.
- Deng S, Yang X, Lassus H et al (2010) Distinct expression levels and patterns of stem cell marker, aldehyde dehydrogenase isoform 1 (ALDH1), in human epithelial cancers," *PLoS ONE*, vol. 5, no. 4, Article ID e10277, pp. 1-11.
- Dolcetti R, Doglioni C, Maestro R et al (1992) p53 over-expression is an early event in the development of human squamous-cell carcinoma of the larynx: genetic and prognostic implications. *Int. J. Cancer* 52; 178-182.
- Dotto GP (2008) Notch tumor suppressor function *Oncogene* 27,5115.

- Ezratty EJ, Stokes N, Chai S, Shah AS, Williams SE, Fuchs E (2011) A role for the primary cilium in Notch signaling and epidermal differentiation during skin development *Cell* 145, 1129-41.
- Evander M, Frazer I, Payne E, Qi Y, Hengst K, McMillan N (1997) Identification of the alpha6 integrin as a candidate receptor for papillomaviruses *Journal of Virology* 71 2449-2456.
- Eversole LR (2009) Dysplasia of the upper aerodigestive tract squamous epithelium. *Head Neck Pathol* 3:63-68
- Fakhry C, D'souza G, Sugar E, Weber K, Goshu E, Minkoff H et al (2006) Relationship between prevalent oral and cervical human papillomavirus infections in human immunodeficiency virus-positive and -negative women. *J Clin Microbiol* 44(12):4479-85
- Field JK (1996) Genomic instability in squamous cell carcinoma of the head and neck. *Anticancer Res* 16; 2421-2431.
- Ficher DJ, Epstein JB, Morton TH et al (2004) Interobserver reliability in the histopathologic diagnosis of oral pre-malignant and malignant lesions. *J Oral Pathol Med* 33:65-70
- Fidler IJ and Talmadge JE (1986) Evidence that intravenously derived murine pulmonary melanoma metastases can originate from the expansion of a single tumor cell *Cancer Research*, vol. 46, no. 10, pp. 5167-5171
- Fong PC, Boss DS, Yap TA, Tutt A, Wu P, Mergui-Roelvink M et al (2009) *N.Engl.J.Med.* 361, 123-34.
- Fleskens S, Slootweg P (2009) Grading systems in head and neck dysplasia: their prognostic value, weakness and utility. *Head Neck Oncol* 1:1-8
- Fraczek M, Wozniak Z, Ramsey D, Krecicki T (2007) Expression patterns of cyclin E, cyclin A and CDC25 phosphatases in laryngeal carcinogenesis. *Eur. Arch. Otorhinolaryngol* 264; 923-928.
- Franchi A, Gallo O, Sardi I, Santucci M (2001) Downregulation of transforming growth factor beta type II receptor in laryngeal carcinogenesis. *J. Clin. Pathol* 54; 201-204.
- Frangé I, Gale N, Luzar B (1997) The interpretation of leukoplakia in laryngeal pathology. *Acta Otolaryngol* 527:142-144
- Friedmann I, Ferlito A (1993) Precursors of squamous cell carcinoma. In Ferlito A ed. *Neoplasms of the larynx*. Edinburgh: Churchill Livingstone 97-111.
- Gale N, Zidar N, Kambic V, Poljak M et al (1997) Epidermal growth factor receptor, c-erbB-2 and p53 overexpressions in epithelial hyperplastic lesions of the larynx. *Acta Otolaryngol.* 527(Suppl.); 105-110.
- Gale N, Kambic V, Michaels L et al (2000) The Ljubljana classification: a practical strategy for the diagnosis of laryngeal precancerous lesions. *Adv. Anat. Pathol* 7; 240-251.
- Gale N, Kambic V, Poljak M, Cor A, Velkavrh D, Mlacak B (2000) Chromosomes 7,17 polysomies and overexpression of epidermal growth factor receptor and p53 protein in epithelial hyperplastic laryngeal lesions. *Oncology* 58; 117-125.
- Gale N, Pilch BZ, Sidransky D, Westra WH, Califano J (2005) Epithelial precursor lesions. In Barnes L, Eveson JW, Reichart P, Sidransky D eds. *World Health Organization classification of tumour. Pathology and genetics of head and neck tumours*. Lyon: IARC, 140-143.

- Gale N, Michaels L, Luzar B et al (2009) Current review on squamous intraepithelial lesions of the larynx. *Histopathology* 54:639–656
- Gallo O, Santucci M, Franchi A (1997) Cumulative prognostic value of p16/CDKN2 and p53 oncoprotein expression in premalignant laryngeal lesions. *J. Natl Cancer Inst.* 89; 1161–1163.
- Gallo A, de Vincentiis M, Della Rocca C et al (2001) Evolution of precancerous laryngeal lesions: a clinicopathologic study with long-term follow-up on 259 patients. *Head Neck* 23; 42–47.
- Gillis TM, Incze J, Strong MS, Vaughan CW, Simpson GT (1983) Natural history and management of keratosis, atypia, carcinoma in situ, and microinvasive cancer of the larynx. *Am. J. Surg* 146; 512–516.
- Goodman ML. Keratosis (leukoplakia) of the larynx *Otolaryngol* (1984) *Clin. North Am.* 17; 179–183.
- Gorgoulis V, Rassidakis G, Karameris A, Giatromanolaki A, Barbatis C, Kittas C (1994) Expression of p53 protein in laryngeal squamous cell carcinoma and dysplasia: possible correlation with human papillomavirus infection and clinicopathological findings. *Virchows Arch* 425; 481–489.
- Grundmann E (1983) Classification and clinical consequences of precancerous lesions in the digestive and respiratory tracts. *Acta Pathol. Jpn.* 33; 195–217.
- Gupta PC, Mehta FS, Daftary DR et al (1980) Incidence rates of oral cancer and natural history of oral precancerous lesions in a 10 year follow-up study of Indian villagers. *Community Dent Oral Epidemiol* 8:287–333
- Ha PK, Califano J (2002) The molecular biology of laryngeal cancer. *Otolaryngol. Clin. North Am* 3; 993–1012.
- Hasina R, Lingen MW (2004) Head and neck cancer: the pursuit of molecular diagnostic markers. *Semin. Oncol* 31; 718–725.
- Hatakeyama S, Yaegashi T, Takeda Y, Kunimatsu K (2007) Localization of bromodeoxyuridine-incorporating, p63- and p75NGFR- expressing cells in the human gingival epithelium, *Journal of Oral Science* 49, 287–291.
- Hellquist H, Lundgren J, Olofsson J (1982) Hyperplasia, keratosis, dysplasia and carcinoma in situ of the vocal cords—a follow-up study. *Clin. Otolaryngol* 7; 11–27.
- Hellquist H, Cardesa A, Gale N, Kambic V, Michaels L (1999) Criteria for grading in the Ljubljana classification of epithelial hyperplastic laryngeal lesions. A study by members of the Working group on Epithelial Hyperplastic Laryngeal Lesions of the European Society of Pathology. *Histopathology* 34; 226–233.
- Henry RC (1979) The transformation of laryngeal leucoplakia to cancer. *J. Laryngol. Otol* 93; 447–459
- Hirai T, Hayashi K, Takumida M, Ueda T, Hirakawa K, Yajin K (2003) Reduced expression of p27 is correlated with progression in precancerous lesions of the larynx. *Auris Nasus Larynx* 30; 163–168.
- Ho M M, Ng AV, Lam S, and Hung JY (2007) Side population in human lung cancer cell lines and tumors is enriched with stem-like cancer cells *Cancer Research*, vol. 67, no. 10, pp. 4827–4833.

- Hoffmann M, Ihloff AS, Görögh T, Weise JB, Fazel A, Krams M et al (2010) p16(INK4a) overexpression predicts translational active human papillomavirus infection in tonsillar cancer. *Int J Cancer* Oct 1;127(7):1595-602.
- Holmstrup P, Vedtofte P, Reibel J et al (2006) Long-term treatment outcome of oral premalignant lesions. *Oral Oncol* 42:461-474
- Iglehart JD, Silver DP (2009) Synthetic lethality--a new direction in cancer-drug development. *N.Engl.J.Med.* 361, 189.
- Ioachim E, Peschos D, Goussia A et al (2004) Expression patterns of cyclins D1, E in laryngeal epithelial lesions: correlation with other cell cycle regulators (p53, pRb, Ki-67 and PCNA) and clinicopathological features. *J. Exp. Clin. Cancer Res* 23; 277-283.
- Irish JC, Bernstein A (1993) Oncogenes in head and neck cancer *Laryngoscope* 103; 42-52.
- Jackson C (1923) Cancer of the larynx: is it preceded by a recognizable precancerous condition? *Ann. Surg* 77; 1-14.
- Jares P, Fernandez PL, Campo E et al (1994) PRAD-1 / cyclin D1 gene amplification correlates with messenger RNA overexpression and tumor progression in human laryngeal carcinomas. *Cancer Res* 54; 4813-4817.
- Jeannon JP, Soames JV, Aston V, Stafford FW, Wilson JA (2004) Molecular markers in dysplasia of the larynx: expression of cyclin-dependent kinase inhibitors p21, p27 and p53 tumour suppressor gene in predicting cancer risk. *Clin. Otolaryngol. Allied Sci* 29; 698-704.
- Kamb A, Shattuck-Eidens D, Eeles R et al (1994) Analysis of the p16 gene (CDKN2) as a candidate for the chromosome 9p melanoma susceptibility locus. *Nat. Genet* 8; 23-26.
- Kambic V, Lenart I (1971) Notre classification des hyperplasies de l'épithélium du larynx au point de vue pronostic. *JFORL* 20:1145-1150
- Kambic V (1978) Difficulties in management of vocal cord precancerous lesions. *J. Laryngol. Otol* 92; 305
- Kambic V, Gale N, Ferluga D (1992) Laryngeal hyperplastic lesions, follow-up study and application of lectins and anticytokeratins for their evaluation. *Path. Res. Pract* 188; 1067-1077.
- Kambic V, Gale N (1995) Epithelial hyperplastic lesions of the larynx. Amsterdam: Elsevier 1-265.
- Kambic V (1997) Epithelial hyperplastic lesions - a challenging topic in laryngology. *Acta Otolaryngol. (Stockh)* 527(Suppl.); 7-11.
- Kaplan RN, Riba RD, Zacharoulis S et al (2005) VEGFR1- positive haematopoietic bone marrow progenitors initiate the pre-metastatic niche *Nature*, vol. 438, no. 7069, pp. 820-827.
- Karabulut A, Reibel J, Therkildsen MH et al (1995) Observer variability in the histologic assessment of oral premalignant lesions. *J Oral Pathol Med* 24:198-200
- Kaur P, Li A (2000) Adhesive properties of human basal epidermal cells: an analysis of keratinocyte stem cells, Transit amplifying cells and postmitotic differentiating cells 114 413-420.

- Kelly PN, Dakic A, Adams JM, Nutt SL, Strasser A (2007) Tumor growth need not be driven by rare cancer stem cells, *Science* 317, 337-.
- Kim MM, Califano JA (2004) Molecular pathology of head-and-neck cancer. *Int. J. Cancer* 112; 545-553.
- Kim MM, Clinger JD, Masayesva BG et al (2004) Mitochondrial DNA quantity increases with histopathologic grade in premalignant and malignant head and neck lesions. *Clin. Cancer Res* 10; 8512-8515.
- Klinakis A, Lobry C, Abdel-Wahab O, Oh P, Haeno H, Buonamici S, van De Walle I et al (2011) A novel tumour-suppressor function for the Notch pathway in myeloid leukaemia. *Nature* 473, 230-3.
- Kleist B, Poetsch M (2004) Divergent patterns of allelic alterations in premalignant laryngeal lesions indicate differences in the impact of morphological grading characteristics. *Oncology* 67; 420-427.
- Koren R, Kristt D, Shvero J et al (2002) The spectrum of laryngeal neoplasia: the pathologist's view. *Pathol Res Pract* 198:709-715
- Kose O, Lalli A, Kutulola AO, Odell EW, Waseem A (2007) Changes in the expression of stem cell markers in oral lichen planus and hyperkeratotic lesions, *Journal of Oral Science* 49 133-139.
- Kramer IRH, Lucas RB, Pindborg JJ et al (1978) Definition of leukoplakia and related lesions: an aid to studies on oral pre- cancer. *Oral Surg Oral Med Oral Pathol* 46:518-539
- Kudo Y, Kitajima S, Ogawa I, Hiraoka M, Sargolzaei S, Keikhaee MR et al (2004) Invasion and metastasis of oral cancer cells require methylation of E-cadherin and/or degradation of membranous a-catenin, *Clinical Cancer Research* 10 5455-5463.
- Kuffer R, Lombardi T (2002) Premalignant lesions of the oral mucosa. A discussion about the place of oral intraepithelial neoplasia (OIN). *Oral Oncol* 38:125-130
- Kujan O, Oliver RJ, Khattab A et al (2007) Why oral histopathology suffers inter-observer variability on grading oral epithelial dysplasia: an attempt to understand the sources of variation. *Oral Oncol* 43:224-231
- Kujan O, Oliver RJ, Khattab A, Roberts SA, Thakker N, Sloan P (2006) Evaluation of binary system of grading oral epithelial dysplasia for prediction of malignant transformation. *Oral Oncol* 42; 987-993.
- Leopardi G, Serafini G, Simoncelli C, Ludovini V, Pistola L, Altissimi G (2001) Ki67 and p53 in laryngeal epithelial lesions: correlations with risk factors. *Acta Otorhinolaryngol. Ital* 21; 243-247.
- Li L and Xie T (2005) Stem cell niche: structure and function *Annual Review of Cell and Developmental Biology*, vol. 21, pp. 605-631.
- Lindberg K, Rheinwald J (1989) Suprabasal 40 kd keratin (K19) expression as an immunohistologic marker of premalignancy in oral epithelium, *The American Journal of Pathology* 134, 89-98.
- Loebinger MR, Giangreco A, Groot KR et al (2008) Squamous cell cancers contain a side population of stem-like cells that are made chemosensitive by ABC transporter blockade," *British Journal of Cancer*, vol. 98, no. 2, pp. 380-387.
- Lodi G, Sardella A, Bez C et al (2006) Interventions for treating oral leukoplakia. *Cochrane Database Syst Rev*; CD001829

- Lodi G, Porter S (2008) Management of potentially malignant disorders: evidence and critique. *J Oral Pathol Med* 37(2):63–69
- Luzar B, Poljak M, Marin IJ, Fischinger J, Gale N (2001) Quantitative measurement of telomerase catalytic subunit (hTERT) mRNA in laryngeal squamous cell carcinomas. *Anticancer Res.* 21; 4011–4015.
- Ma S, Kwok W C, Lee T KW et al (2008) Aldehyde dehydrogenase discriminates the CD133 liver cancer stem cell populations *Molecular Cancer Research*, vol. 6, no. 7, pp. 1146–1153.
- Mahajan M, Hazarey VK (2004) An assessment of oral epithelial dysplasia using criteria of 'Smith & Pindborg grading system' & 'Ljubljana grading system' in oral precancerous lesions'. *J Oral Maxillofac Pathol* 8:73–81
- Merlo A, Herman JG, Mao L et al (1995) CpG island methylation is associated with transcriptional silencing of the tumour suppressor p16 / CDKN2 / MTS1 in human cancers. *Nat. Med* 1; 686–692.
- Meyerson M, Counter CM, Eaton EN et al (1996) Telomerase activity in human cancer. *Curr. Opin. Oncol* 8; 66–71.
- Michaels L (1997) The Kambic–Gale method of assessment of epithelial hyperplastic lesions of the larynx in comparison with the dysplasia grade method. *Acta Otolaryngol* 527:17–20
- Michaels L, Hellquist HB (2001) *Ear, nose and throat histopathology*, 2nd edn. London: Springer, 378–387.
- Mimeault M, Hauke R, Mehta PP, Batra SK (2007) Recent advances in cancer stem/progenitor cell research: therapeutic implications for overcoming resistance to the most aggressive cancers, *Journal of Cellular and Molecular Medicine* 11, 981–1011.
- Munck-Wikland E, Kuylensstierna R, Lindholm J, Auer G (1991) Image cytometry DNA analysis of dysplastic squamous epithelial lesions in the larynx. *Anticancer Res* 11; 597–600.
- Munz M, Kieu C, Mack B, Schmitt B, Zeidler R, Gires O (2004) The carcinoma-associated antigen EpCAM upregulates c-myc and induces cell proliferation, *Oncogene* 23, 5748–5758.
- Nadal A, Campo E, Pinto J et al (1995) p53 expression in normal, dysplastic, and neoplastic laryngeal epithelium. Absence of a correlation with prognostic factors. *J. Pathol* 175; 181–
- Nadal A, Cardesa A. Molecular biology of laryngeal squamous cell carcinoma. *Virchows Arch.* 2003; 442; 1–7.
- Nakamura T, Endo K.i, Kinoshita S (2007) Identification of human oral keratinocyte stem/progenitor cells by neurotrophin receptor p75 and the role of neurotrophin/p75 signaling, *Stem Cells* 25, 628–638.
- Naor D, Wallach-Dayana SB, Zahalka MA, Sionov RV (2008) Involvement of CD44, a molecule with a thousand faces, in cancer dissemination, *Seminars in Cancer Biology* 18, 260–267.
- Napier SS, Speight PM (2008) Natural history of potentially malignant oral lesions and conditions: an overview of the literature. *J Oral Pathol Med* 37:1–10

- Nicolas M, Wolfer A, Raj K, Kummer JA, Mill P, van Noort M, et al (2003) *Nat. Genet.* 33, 416-21.
- Olde Kalter P, Lubsen H, Delemarre JFM, Snow GB (1987) Squamous cell hyperplasia of the larynx. A clinical follow-up study. *J. Laryngol. Otol* 101; 579-588.
- Okamoto A, Chikamatsu K, Sakakura K, Hatsushika K, Takahashi G, and Masuyama K (2009) Expansion and characterization of cancer stem-like cells in squamous cell carcinoma of the head and neck *Oral Oncology*, vol. 45, no. 7, pp. 633-639.
- Patel SC, Carpenter WR, Tyree S, Couch ME, Weissler M, Hackman T et al (2011) Increasing incidence of oral tongue squamous cell carcinoma in young white women, age 18 to 44 years. *J Clin Oncol* 29(11):1488-94.
- Peschos D, Stefanou D, Vougiouklakis T, Assimakopoulos DA, Agnantis NJ (2005) Cell cycle proteins in laryngeal cancer: role in proliferation and prognosis. *J. Exp. Clin. Cancer Res.* 24; 431-437.
- Pesse TJ, Clarke AR (2009) Normal stem cells in cancer prone epithelial tissues, *British Journal of Cancer* 100 221-227.
- Pillai MR, Nair MK (2000) Development of a condemned mucosa syndrome and pathogenesis of human papillomavirus-associated upper aerodigestive tract and uterine cervical tumors, *Experimental and Molecular Pathology* 69, 233-241.
- Pindborg JJ, Renstrup G, Poulsen HE et al (1963) Studies in oral leukoplakias. V. Clinical and histologic signs of malignancy. *Acta Odont Scand* 21:407-414.
- Pindborg JJ (1980) *Oral cancer and precancer*. John Wright & Sons, Bristol
- Pindborg JJ, Reichart PA, Smith CJ et al (1997) *World Health Organization: Histological typing of cancer and precancer of the oral mucosa*, 2nd edn. Springer, Berlin
- Pomerantz RG, Grandis JR (2004) The epidermal growth factor receptor signaling network in head and neck carcinogenesis and implications for targeted therapy. *Semin. Oncol* 31; 734-443.
- Poljak M, Gale N, Kambic V, Ferluga D, Fischinger J (1996) Over- expression of p53 protein in benign and malignant laryngeal epithelial lesions. *Anticancer Res.* 16; 1947-1951.
- Poulsen HE, Taylor CW, Sobin LH (1975) Histological typing of female genital tract tumours, *International histological classification of tumours*, No. 13. World Health Organization, Geneva
- Proweller A, Tu L, Lepore JJ, Cheng L, Lu MM, Seykora J et al (2006) *Cancer Res.* 66, 7438-44.
- Presland R, Jurevic R (2002) Making sense of the epithelial barrier: what molecular biology and genetics tell us about the functions of oral mucosal and epidermal tissues, *Journal of Dental Education* 66, 564-574.
- Prince ME, Sivanandan R, Kaczorowski A, Wolf GT, Kaplan MJ, Dalerba P et al (2007) Identification of a subpopulation of cells with cancer stem cell properties in head and neck squamous cell carcinoma, *Proceedings of the National Academy of Science* 104, 973-978.
- Prince ME, Ailles LE (2008) Cancer stem cells in head and neck squamous cell cancer, *Journal of Clinical Oncology* 26 2871-2875.
- Putney FJ, O'Keefe JJ (1953) The clinical significance of keratosis of the larynx as a premalignant lesion. *Ann. Otol. Rhinol. Laryngol* 62; 348-357.

- Ramalho-Santos M, Willenbring H (2007) On the origin of the term "stem cell", *Cell Stem Cell* 1 35–38.
- Renan MJ (1993) How many mutations are required for tumorigenesis? Implications from human cancer data. *Mol. Carcinog* 7; 139–146.
- Ranganathan P, Weaver KL, Capobianco AJ (2011), *Nat.Rev. Cancer* 11, 338–51.
- Reagan JW, Hamonic MJ (1956) Dysplasia of the uterine cervix. *Ann N Y Acad Sci* 63:1236–1244
- Resta L, Colucci GA, Troia M, Russo S, Vacca E, Pesce Delfino V (1992) Laryngeal intraepithelial neoplasia (LIN). An analytical morphometric approach. *Path. Res. Pract.*; 188; 517–523.
- Ricci G, Molini E, Faralli M, Simoncelli C. (2003) Retrospective study on precancerous laryngeal lesions: long-term follow-up. *Acta Otorhinolaryngol. Ital* 23; 362–367.
- Ricci-Vitiani L, Lombardi DG, Pilozzi E, Biffoni M, Todaro M, Peschle C (2007) Identification and expansion of human colon-cancer-initiating cells, *Nature* 445 111–115.
- Richart RM (1966) Influence of diagnostic and therapeutic procedures on the distribution of cervical intraepithelial neoplasia. *Cancer* 19:1635–1638
- Richart RM (1973) Cervical intraepithelial neoplasia. *Pathol Ann* 8:301–328
- Robbins SL, Cortran RS (1979) *Pathologic basis of disease*, 2nd edn. Saunders, Philadelphia
- Saglam O, Shah V, Worsham MJ (2007) Molecular differentiation of early and late stage laryngeal squamous cell carcinoma: an exploratory analysis. *Diagn. Mol. Pathol* 16; 218–221.
- Sakr WA, Gale N, Gnepp DR et al (2009) Squamous intraepithelial neoplasia of the upper aerodigestive tract. In: Gnepp DR (ed) *Diagnostic surgical pathology of the head and neck*, 2nd edn. Saunders, Philadelphia, pp 1–44
- Sanz-Ortega J, Valor C, Saez MC et al (2003) 3p21, 5q21, 9p21 and 17p13 allelic deletions accumulate in the dysplastic spectrum of laryngeal carcinogenesis and precede malignant transformation. *Histol. Histopathol* 18; 1053–1057.
- Sardi I, Franchi A, De Campora L, Passali GC, Gallo O (2006) Microsatellite instability as an indicator of malignant progression in laryngeal premalignancy. *Head Neck* 28; 730–739.
- Shafer WG (1975) Oral carcinoma in situ. *Oral Surg* 39:227–238
- Shear M, Pindborg JJ (1980) Verrucous hyperplasia of the oral mucosa. *Cancer (Phila)* 46:1855–1962
- Schoelch ML, Sekandari N, Regezi JA et al (1999) Laser management of oral leukoplakias: a follow-up study of 70 patients. *Laryngoscope* 109:949–953
- Serrano M, Hannon GJ, Beach D (1993) A new regulatory motif in cell-cycle control causing specific inhibition of cyclin D/CDK4. *Nature* 366; 704–707.
- Shay JW, Wright WE (1996) Telomerase activity in human cancer. *Curr. Opin. Oncol* 8; 66–71.
- Shin DM, Kim J, Ro JY et al (1994) Activation of p53 gene expression in premalignant lesions during head and neck tumorigenesis. *Cancer Res* 54; 321–326.
- Silverman S Jr, Bhargava K, Mani NJ et al (1976) Malignant transformation and natural history of oral leukoplakia in 57518 industrial workers of Gujarat, India. *Cancer (Phila)* 38:1790–1795


- Singh SK, Clarke ID, Terasaki M et al (2003) Identification of a cancer stem cell in human brain tumors," *Cancer Research*, vol. 63, no. 18, pp. 5821–5828.
- Singh SK, Hawkins C, Clarke ID, Squire JA, Bayani J, Hide T et al (2004) Identification of human brain tumour initiating cells, *Nature* 432 396–401.
- Sjoblom T, Jones S, Wood LD, Parsons DW, Lin J, Barber TD, et al , *Science* 314, 268-74 (2006).
- Sllamniku B, Bauer W, Painter C, Sessions D (1989) The transformation of laryngeal keratosis into invasive carcinoma. *Am. J. Otolaryngol* 10; 42–54.
- Somers KD, Merrick MA, Lopez ME, Incognito LS, Schechter GL, Casey G (1992) Frequent p53 mutations in head and neck cancer *Cancer Res* 52; 5997–6000.
- Sorrells DL Jr, Ghali GE, De Benedetti A, Nathan CA, Li BD (1999) Progressive amplification and overexpression of the eukaryotic initiation factor 4E gene in different zones of head and neck cancers *J. Oral Maxillofac. Surg* 57; 294–299.
- Speight PM, Farthing PM, Bouquot JE (1996) The pathology of oral cancer and precancer. *Curr Diagn Pathol* 3:165–176
- Staibano S, Merolla F, Testa D, Iovine R, Mascolo M, Guarino V et al (2007) OPN/CD44v6 overexpression in laryngeal dysplasia and correlation with clinical outcome. *Br J Cancer* 97(11):1545-51
- Stransky N, Egloff AM, Tward AD, Kostic AD, Cibulskis K, Sivachenko A, et al (2011) The Mutational Landscape of Head and Neck Squamous Cell Carcinoma, *Science* 333, 1157 10.1126/ science.1208130.
- Szotek PP, Pieretti-Vanmarcke R, Masiakos PT et al (2006) Ovarian cancer side population defines cells with stem cell-like characteristics and Mullerian inhibiting substance respon- siveness *Proceedings of the National Academy of Sciences of the United States of America*, vol. 103, no. 30, pp. 11154–11159,.
- Tabor MP, Brakenhoff RH, Ruijter-Schippers HJ, Van Der Wal JE, Snow GB, Leemans CR, et al (2002) Multiple head and neck tumours frequently originate from a single preneoplastic lesion. *Am J Pathol* 161: 1051–1060
- Tabor MP, Braakhuis BJM, Van der Waal JE et al (2003) Comparative molecular and histological grading of epithelial dysplasia of the oral cavity and the oropharynx. *J Pathol* 199:354–360
- Tan T-T, Coussens LM (2007) Humoral immunity, inflammation and cancer, *Current Opinion in Immunology* 19 209–216.
- Thomasson HR, Edenberg HJ, Crabb DW et al (1991) Alcohol and aldehyde dehydrogenase genotypes and alcoholism in Chinese men *American Journal of Human Genetics*, vol. 48, no. 4, pp. 677–681.
- Toole BP, Wight TN, Tammi MI (2002) Hyaluronan-cell interactions in cancer and vascular disease, *The Journal of Biological Chemistry* 277 4593–4596.
- Trzpis M, McLaughlin PMJ, de Leij LMFH, Harmsen MC (2007) Epithelial cell adhesion molecule: more than a carcinoma marker and adhesion molecule, *The American Journal of Pathology* 171, 386–395.
- Uhlman DL, Adams G, Knapp D, Aeppli DM, Niehans G (1996) Immunohistochemical staining for markers of future neoplastic progression in the larynx. *Cancer Res* 56; 2199–2205.

- van der Riet P, Nawroz H, Hruban RH et al (1994) Frequent loss of chromosome 9p21-22 early in head and neck cancer progression. *Cancer Res* 54; 1156-1158.
- van der Waal I, Schepman KP, van der Meiji EH et al (1997) Oral leukoplakia: a clinicopathological review. *Oral Oncol* 33:291-301
- Vedtofte P, Holmstrup P, Hjorting-Hansen E et al (1987) Surgical treatment of premalignant lesions of the oral mucosa. *Int J Oral Maxillofac Surg* 16:656-664
- Velasco JRR, Nieto CS, de Bustos CP, Marcos CA (1987) Premalignant lesions of the larynx: pathological prognostic factors. *J. Otolaryngol* 16; 367-370.
- Vinitha Richard, M. Radhakrishna Pillai (2010) The stem cell code in oral epithelial tumorigenesis: "The cancer stem cell shift hypothesis" *Biochimica et Biophysica Acta* 1806 146-162
- Visus C, Ito D, Amoscato A et al (2007) Identification of human aldehyde dehydrogenase 1 family member a1 as a novel CD8+ T-cell-defined tumor antigen in squamous cell carcinoma of the head and neck *Cancer Research*, vol. 67, no. 21, pp. 10538-10545.
- Voravud N, Shin DM, Ro JY, Lee JS, Hong WK, Hittelman WN (1993) Increased polysomies of chromosomes 7 and 17 during head and neck multistage tumorigenesis. *Cancer Res* 53; 2874-2883.
- Wahi PN, Cohen B, Luthra UK et al (1971) Histological typing of oral and oropharyngeal tumours. International histological classification of tumours no. 4. World Health Organization, Geneva
- Wang SJ, Wong G, De Heer AM, Xia W, and Bourguignon LYW (2009) CD44 Variant isoforms in head and neck squamous cell carcinoma progression *Laryngoscope*, vol. 119, no. 8, pp. 1518-1530.
- Wang J, Guo LP, Chen LZ, Zeng YX, and Shih HL (2007) Identification of cancer stem cell-like side population cells in human nasopharyngeal carcinoma cell line *Cancer Research*, vol. 67, no. 8, pp. 3716-3724.
- Warnakulasuriya S (2001) Histological grading of oral epithelial dysplasia: revisited. *J Pathol* 194:294-297
- Warnakulasuriya S, Johnson NW, van der Wall I (2007) Nomenclature and classification of potentially malignant disorders of the oral mucosa. *J Oral Pathol Med* 36:575-580
- Warnakulasuriya S, Reibel J, Bouquot J et al (2008) Oral epithelial dysplasia classification system: predictive value, utility, weakness and scope for improvement. *J Oral Pathol Med* 37:127-133
- Wayne S, Robinson RA (2006) Upper aerodigestive tract squamous dysplasia: correlation with p16, p53, pRb, and Ki-67 expression. *Arch. Pathol. Lab. Med* 130; 1309-1314.
- Wood LD, Parsons DW, Jones S, Lin J, Sjöblom T, Leary RJ, et al (2007) *Science* 318, 1108-13.
- Yoo WJ, Cho SH, Lee YS et al (2004) Loss of heterozygosity on chromosomes 3p,8p,9p and 17p in the progression of squamous cell carcinoma of the larynx. *J. Korean Med. Sci* 19; 345-351.
- Yuge T, Nibu K, Kondo K, Shibahara J, Tayama N, Sugawara M (2005) Loss of FHIT expression in squamous cell carcinoma and premalignant lesions of the larynx. *Ann. Otol. Rhinol. Laryngol* 114; 127-131.
- Zerdoner D (2003) The Ljubljana classification: its application to grading oral epithelial hyperplasia. *J Craniomaxillofacial Surg* 31:75-79

- Zhang P, Zhang Y, Mao L, Zhang Z, and Chen W (2009) Side population in oral squamous cell carcinoma possesses tumor stem cell phenotypes *Cancer Letters*, vol. 277, no. 2, pp. 227– 234.
- Zhang Q, Shi S, Yen Y, Brown J, Ta JQ, and Le AD (2009) A subpopulation of CD133+ cancer stem-like cells characterized in human oral squamous cell carcinoma confer resistance to chemotherapy *Cancer Letters*, vol. 289, no. 2, pp. 151–160.

IntechOpen

IntechOpen



Intraepithelial Neoplasia

Edited by Dr. Supriya Srivastava

ISBN 978-953-307-987-5

Hard cover, 454 pages

Publisher InTech

Published online 08, February, 2012

Published in print edition February, 2012

The book "Intraepithelial neoplasia" is till date the most comprehensive book dedicated entirely to preinvasive lesions of the human body. Created and published with an aim of helping clinicians to not only diagnose but also understand the etiopathogenesis of the precursor lesions, the book also attempts to identify its molecular and genetic mechanisms. All of the chapters contain a considerable amount of new information, with an updated bibliographical list as well as the latest WHO classification of intraepithelial lesions that has been included wherever needed. The text has been updated according to the latest technical advances. This book can be described as concise, informative, logical and useful at all levels discussing thoroughly the invaluable role of molecular diagnostics and genetic mechanisms of the intraepithelial lesions. To make the materials easily digestible, the book is illustrated with colorful images.

How to reference

In order to correctly reference this scholarly work, feel free to copy and paste the following:

Angela Celetti, Francesco Merolla, Chiara Luise, Maria Siano and Stefania Staibano (2012). Novel Markers for Diagnosis and Prognosis of Oral Intraepithelial Neoplasia, Intraepithelial Neoplasia, Dr. Supriya Srivastava (Ed.), ISBN: 978-953-307-987-5, InTech, Available from: <http://www.intechopen.com/books/intraepithelial-neoplasia/novel-markers-for-diagnosis-and-prognosis-of-oral-intraepithelial-neoplasia>

INTECH
open science | open minds

InTech Europe

University Campus STeP Ri
Slavka Krautzeka 83/A
51000 Rijeka, Croatia
Phone: +385 (51) 770 447
Fax: +385 (51) 686 166
www.intechopen.com

InTech China

Unit 405, Office Block, Hotel Equatorial Shanghai
No.65, Yan An Road (West), Shanghai, 200040, China
中国上海市延安西路65号上海国际贵都大饭店办公楼405单元
Phone: +86-21-62489820
Fax: +86-21-62489821

© 2012 The Author(s). Licensee IntechOpen. This is an open access article distributed under the terms of the [Creative Commons Attribution 3.0 License](https://creativecommons.org/licenses/by/3.0/), which permits unrestricted use, distribution, and reproduction in any medium, provided the original work is properly cited.

IntechOpen

IntechOpen