

We are IntechOpen, the world's leading publisher of Open Access books Built by scientists, for scientists

6,900

Open access books available

185,000

International authors and editors

200M

Downloads

Our authors are among the

154

Countries delivered to

TOP 1%

most cited scientists

12.2%

Contributors from top 500 universities



WEB OF SCIENCE™

Selection of our books indexed in the Book Citation Index
in Web of Science™ Core Collection (BKCI)

Interested in publishing with us?
Contact book.department@intechopen.com

Numbers displayed above are based on latest data collected.
For more information visit www.intechopen.com



Gasless Single Port Surgery for Renal Cell Carcinoma: Minimum Incision Endoscopic Surgery

Kazunori Kihara, Yasuhisa Fujii, Satoru Kawakami,
Hitoshi Masuda, Fumitaka Koga, Kazutaka Saito,
Noboru Numao, Yoh Matsuoka and Yasuyuki Sakai
*Department of Urology, Graduate School,
Tokyo Medical and Dental University
Japan*

1. Introduction

Advances in minimally invasive urologic surgery have accumulated rapidly in recent years with the advent of laparoscopic and robot-assisted surgeries (Clayman, 1991; Guillonneau, 1999; Dasgupta, 2009; Lee, 2009). The procedures for renal cell carcinoma (RCC), radical nephrectomy and partial nephrectomy are among those that have benefited from such innovation. Both laparoscopic surgery and robot-assisted surgery have markedly reduced the invasiveness of surgeries compared to conventional open procedures; laparoscopic surgery is characterized by the use of endoscopy, insufflation with carbon dioxide (CO₂) gas, and insertion of instruments from several trocar ports, while robot-assisted surgery also incorporates stereovision and state-of-the-art movable instruments.

At present, both branches of surgery focus mainly on further minimizing postoperative scarring by performing surgery via a single site (Figure 1) (Ponsky, 2008; Raman, 2008; Kommu, 2009; Kaouk, 2009; Han, 2011). There are currently two major obstacles to achieving the goal of minimally invasive urologic surgery, namely, the necessity of CO₂ insufflation and the high cost of the equipment. The purpose of this chapter is to present a surgery for RCC which can be performed through single-port access, under gasless conditions, and using low-cost equipment (Fig. 1). This form of surgery, which we call minimum incision endoscopic surgery (MIES) or gasless laparoendoscopic single port surgery (GasLESS), has been under development in our department since 1998; techniques have been developed for almost all urological organs (Kihara, 2002, 2004, 2007, 2009a, 2009b, 2010a, 2010b; Kageyama, 2004; Koga, 2007; Saito, 2010). MIES was certified as advanced surgery by the Japanese government in 2006, and was first covered in the Japanese universal health insurance system in 2008 (Kihara et al., 2009a). Here, we will describe the methods and results of MIES-radical nephrectomy and MIES-partial nephrectomy for RCC and discuss its advantageous features that are not associated with other forms of laparoscopic or robot-assisted surgery.

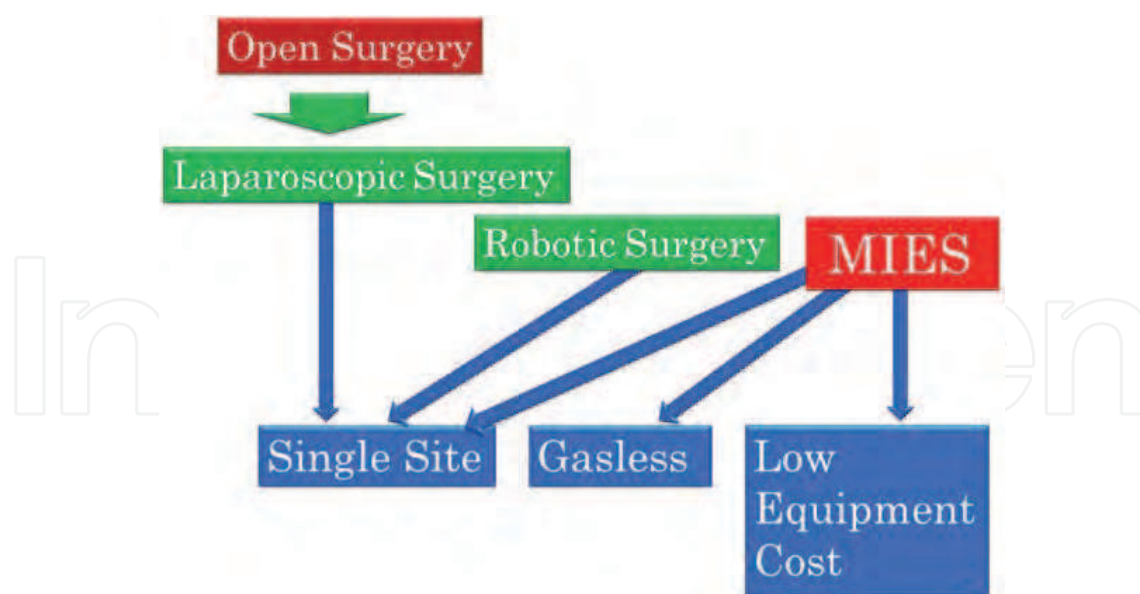


Fig. 1. Three characteristics which are currently important goals in minimally invasive urologic surgery: a single site, a gasless procedure and a low equipment cost. MIES: minimum incision endoscopic surgery.

2. Outline of procedures

2.1 Outline of minimum incision endoscopic surgery (MIES)

An outline of procedures is provided in Figure 2. 1) A minimal incision is made which will serve as a single port and permit extraction of the target specimen. 2) Through this port, a wide working space is made by separating the anatomical plane extraperitoneally; this opening is maintained with special retractors rather than gas insufflation. 3) An endoscope and all other instruments are inserted through the port. 4) Surgeons enjoy the benefits of endoscopy, especially the availability to all participants of magnified images from the beginning to the end of the operation, while the supplemental view with the naked eye remains visible through the port with stereovision and panoramic vision (Figure 3). Three dimensional high-vision endoscope is also being used at present. The size of the port can be tailored to the patient's situation before or during the operation for safety and proper practice, although this is rarely necessary. The multiple options for images and the possibility of modifying the size of the single port may mitigate technical demand and avoid patient selection. Patient position (lateral or supine) can be selected according to each patient's situation or tumour location. The operation is performed without CO₂ gas, without trocar ports, basically without antimicrobial prophylaxis, with an intact peritoneum and with minimal disposable instruments.

2.2 Representative specimen extractions

Representative extractions of various specimens are depicted. All operations were performed extraperitoneally: i) radical nephrectomy via a lumbar port in the lateral position (Figure 4), ii) radical nephrectomy through a paramedian port in the supine position (Figure 5), iii) partial nephrectomy of T1 RCC via a lumbar port (Figure 6) and iv) partial nephrectomy of T2 RCC via a lumbar port (Figure 7).

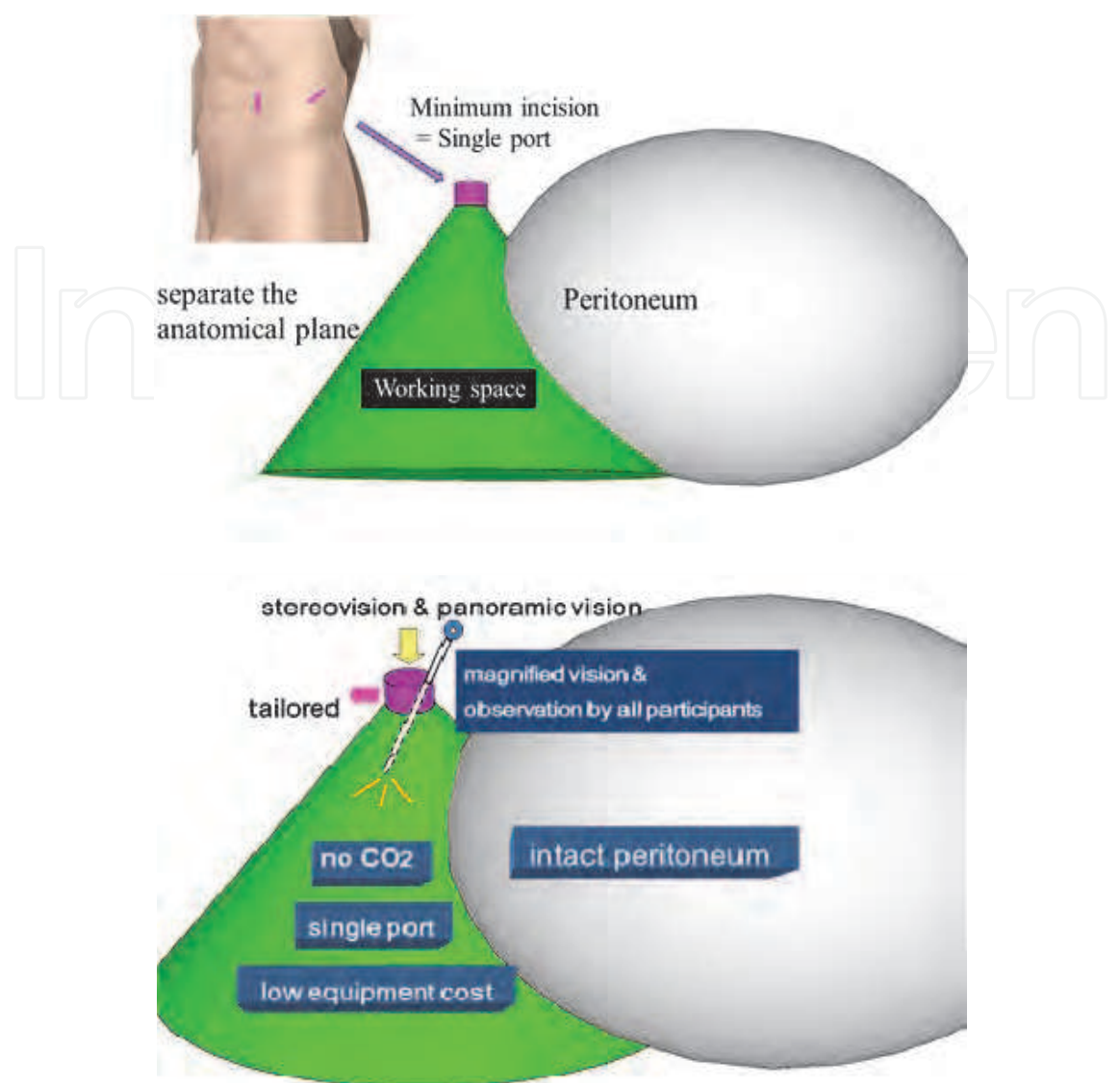


Fig. 2. Outline of the MIES procedures.

	Stereo-Vision	Magnified Vision	Panoramic Vision	General Vision*
Open surgery				
Laparoscopic surgery				
Robotic surgery				
MIES				

Fig. 3. Image availability in minimally invasive surgeries. *: images are available to all participants.

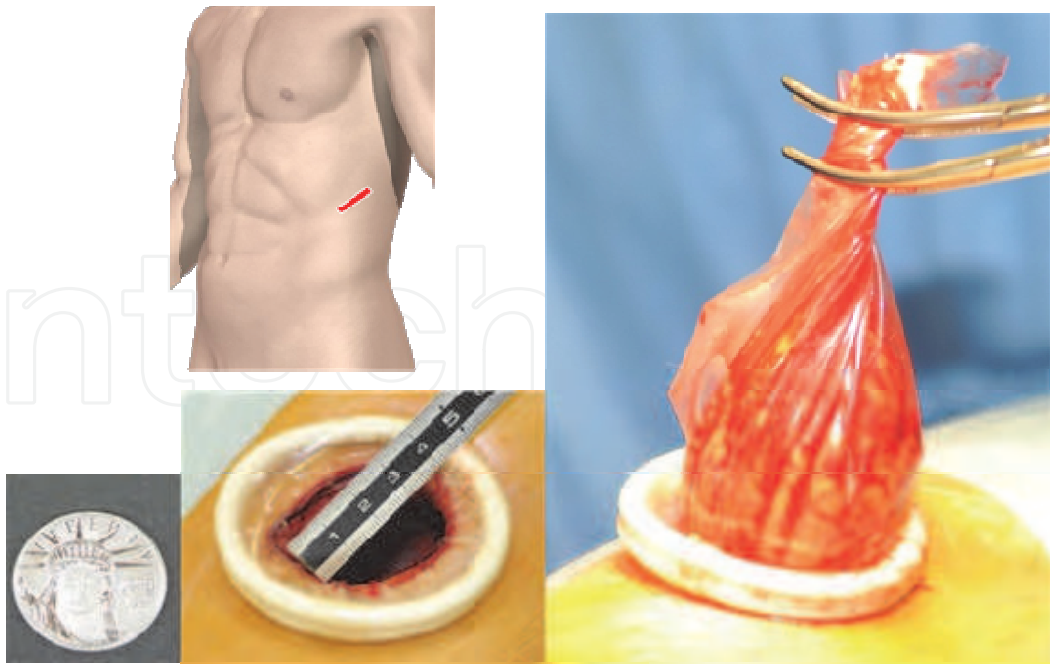


Fig. 4. Radical nephrectomy through a single lumbar port less than 4cm in diameter in the lateral position. To keep the wound open and protect it, an Alexis wound retractor® is typically used.

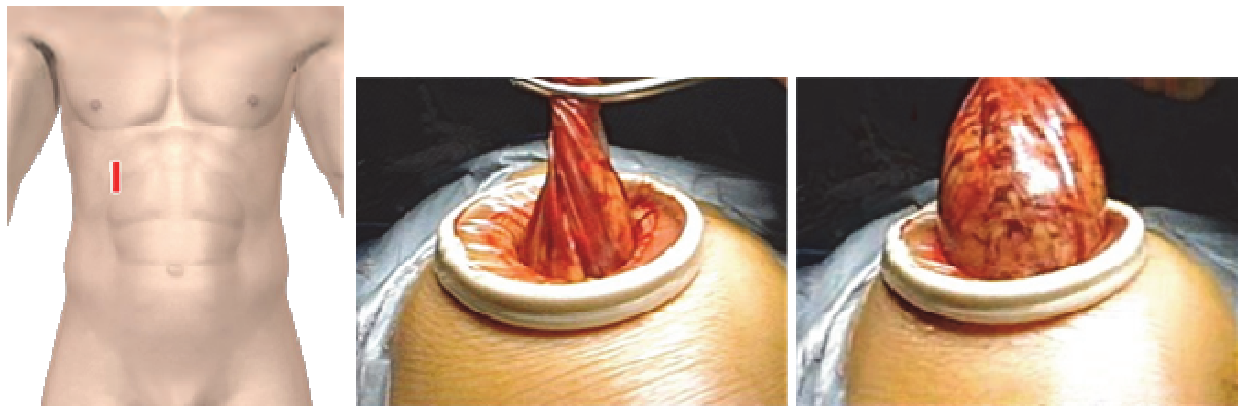


Fig. 5. Radical nephrectomy through a paramedian port in the supine position, performed extraperitoneally.

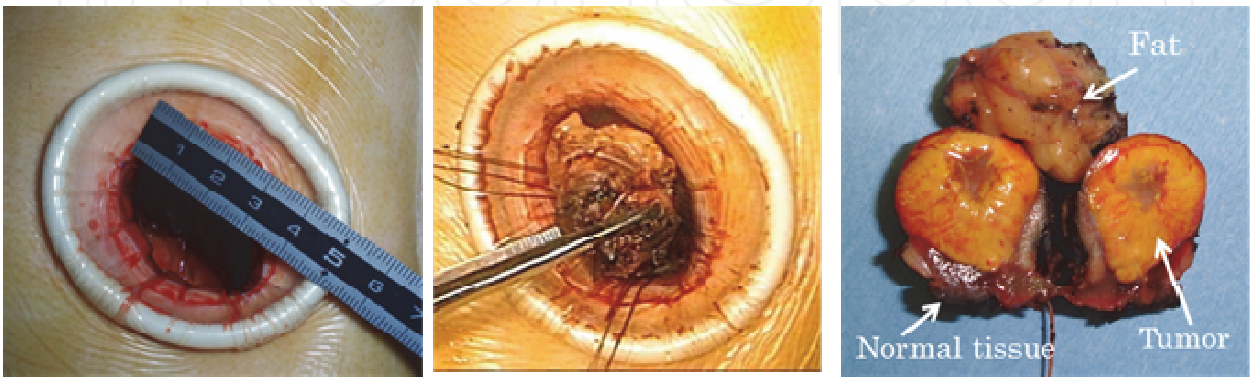


Fig. 6. Partial nephrectomy of T1 RCC via a lumbar port.

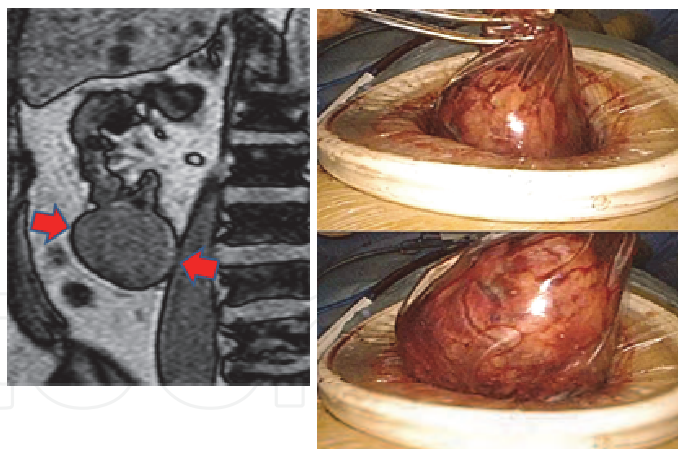


Fig. 7. Partial nephrectomy of T2 RCC through a lumbar port.

3. Methods

An outline of the technique, entitled “MIES-radical nephrectomy and MIES-partial nephrectomy”, has been previously reported (Kihara, 2009a, 2010a) and presented in the video library of the European Association of Urology (EAU) (Kihara, 2009b, 2010b). At our hospital, MIES-radical nephrectomy has been performed regularly over the last few years for large T1b-T3 RCC and for RCC in dialysis patients, while MIES-partial nephrectomy is performed for most (lately more than 85%) cases of T1a RCC. MIES-partial nephrectomy is typically performed without renal ischemia at our hospital to preserve renal function to as great a degree as possible.

3.1 MIES-radical nephrectomy

A lumbar or paramedian retroperitoneal approach is used. The latter approach is mainly selected when the patient has severe cardiovascular or respiratory disturbances or a large tumour adjacent to the renal pedicle. Antimicrobial prophylaxis is not used.

3.1.1 Lumbar retroperitoneal approach

After the induction of general anaesthesia, the patient is placed in the flank position over the break of the table. An incision just large enough to narrowly permit extraction of the kidney with perinephric fat, usually 3.5-6 cm, is made obliquely forward following the line of the 12th rib (Figure 4). After splitting the muscles, incising the transversalis fascia and moving the flank pad aside, the lateroconal fascia is exposed. During this procedure a small portion of the distal edge of the 12th rib may be removed if necessary. After opening the lateroconal fascia, separation is performed between the fascia of the psoas muscle posteriorly and Gerota's fascia anteriorly. During this separation procedure, the ureter can be readily identified medially. Next, an Alexis wound retractor® is set up and the single port is prepared (Figure 4). Separation along the posterior Gerota's fascia allows immediate access to the renal artery and vein. The renal artery is circumferentially mobilized, then doubly ligated and divided (Figure 8). Next, the renal vein is freed, doubly ligated and divided. The ureter, which was identified previously, is freed as low as possible and then ligated and divided.

After the wide separation along the posterior Gerota's fascia, a similar separation is performed along the anterior Gerota's fascia, allowing immediate access to the adrenal gland. Next, the perinephric fat is transversely divided at the level of transection of the ureter and subsequently between the adrenal gland and the kidney by retracting the kidney downward with a retractor. The adrenal gland is usually preserved, but when necessary it can be removed along with the kidney. After confirming the complete isolation of the kidney with perinephric fat by passing a tube around the perinephric fat, the specimen is extracted through the single port using a Flexible catcher®. Before the wound is closed, the operative field is washed thoroughly with saline, and the subcutaneous tissue is washed again with saline before epidermal suture to avoid the need for prophylactic antimicrobial agents.

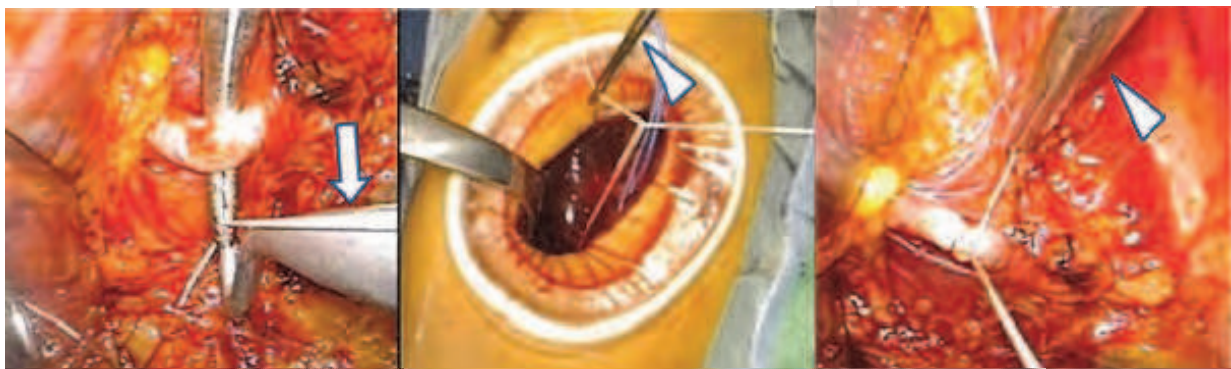


Fig. 8. Ligation of the renal artery using a Thread Pass® (arrow) and a Knot Slide® (arrowhead).

3.1.2 Paramedian retroperitoneal approach

This approach is the same as the lumbar retroperitoneal approach described above except in the following points. The patient is placed in the supine position under general anaesthesia. An incision just large enough to narrowly permit extraction of the kidney with perinephric fat is made downward on the pararectal line, 1-2 cm below the rib (Figure 5). By incising the anterior and posterior sheaths of the rectus muscle while preserving the muscle, the transversal fascia is exposed. The fascia is bluntly pushed downward off the transversal muscle to allow access to the flank pad on the lateroconal fascia. Next, the lateroconal fascia is opened and the anterior Gerota's fascia is separated medially to allow immediate access to the renal vein and artery.

After division of the renal artery and vein, wide separation along the anterior and posterior Gerota's fascia is performed. The kidney with the perinephric fat is freed from the surrounding tissue and extracted as described above, in the section on the translumbar retroperitoneal approach (Figure 5).

3.2 Partial nephrectomy

Partial nephrectomy using an MIES technique is typically performed without renal ischemia at our hospital. In some cases, such as when the tumour is adjacent to the renal pedicle, clamping of the renal vessels is performed as necessary. Either the lumbar retroperitoneal approach or the paramedian retroperitoneal approach is selected. Antimicrobial prophylaxis is not used unless the collecting system is opened.

Regardless of approach, the procedures are similar to those used in radical nephrectomy until the exposure of Gerota’s fascia. After setting up the single port, separating the posterior and anterior Gerota’s fascias from the surrounding tissue, and holding them back with an Alexis wound retractor®, the tumour is located within the perinephric fat by means of ultrasound (Figure 9). The surface of the kidney is exposed at some distance from the tumour, and the exposure is then extended to near the tumour.

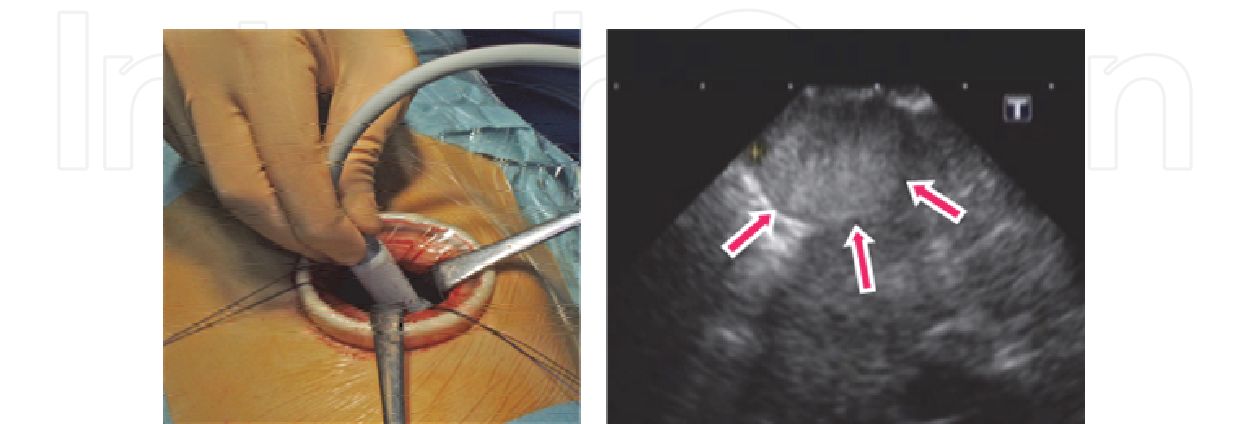


Fig. 9. Identification of the tumour using ultrasound.

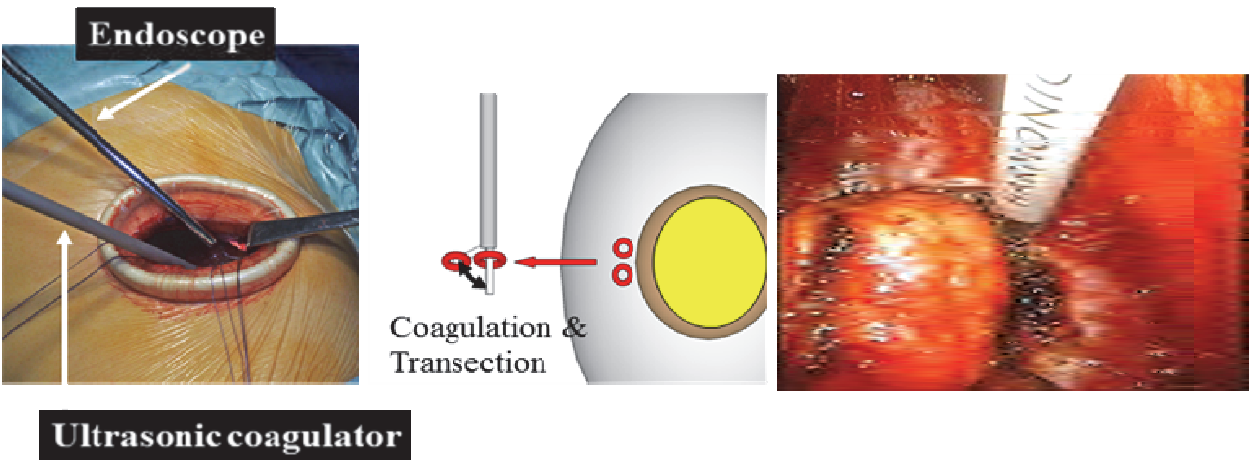


Fig. 10. Coagulation of the normal tissue around the tumour.

Using an ultrasonic coagulator, the normal tissue adjacent to the tumour is penetrated and coagulated (Figure 10). When coagulations around the tumour are completed, the tissue between coagulations is coagulated and transected. Using a suction tube, the coagulated normal tissue is shaped into the form of a pedicle connected to the tumour (Figure 11). The pedicle is tied with a rubber tape or a silk thread, with which the tumour is gently pulled up (Figure 11). After the operative field is filled with saline, the bottom of the tumour in the pedicle is identified with ultrasound. The tumour, its bottom and its transected region can be checked and the line to be transected is now identified (Figure 11).

According to the line identified, the normal tissue neighbouring the bottom of the tumour is transected using a coagulator as soon as the distance between the bottom and the collecting system is large enough. When the bottom is near the collecting system, the pedicle is transected little by little while the tissue is sutured on the calyx side. Finally, the target

specimen is freed and extracted through the single port (Figure 12). Immediately after the specimen is extracted, it is split in half and the margin of the tumour is evaluated (Figure 6). When the margin seems too small, a situation which arises very rarely, adjacent normal tissue can be additionally coagulated or resected. The remaining bed is coagulated by means of an argon laser or pasted with coagulating paste, if necessary, and is carefully confirmed to be bloodless (Figure 6). Then the perinephric fat is repaired to cover the kidney defect. Before the wound is closed, the operative field is washed with 2000 ml of saline so that prophylactic antibiotics are not required. Finally, the skin is closed with an epidermal suture (Figure 12).

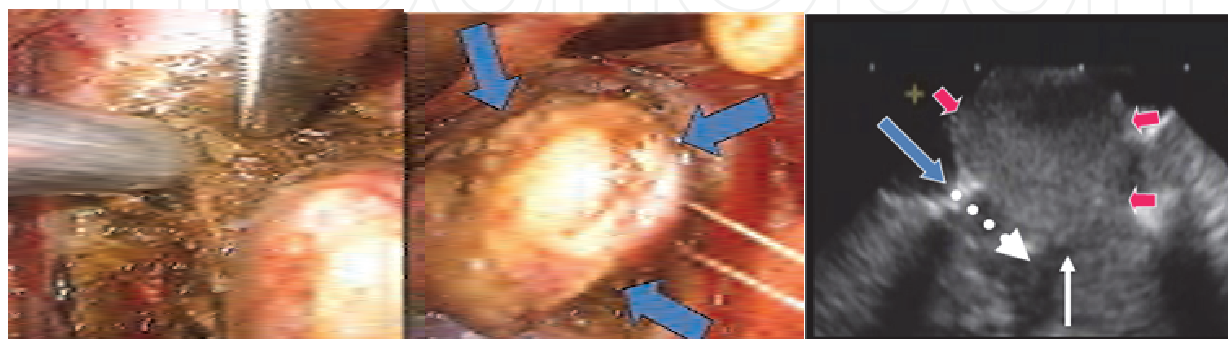


Fig. 11. Ensuring that the normal tissue beneath the tumour is clear. Transection of the normal tissue beneath the tumour is performed under ultrasound guidance. White dotted arrow, the line to be transected; blue arrow, transected normal tissue; red arrow, tumour; white arrow, bottom of the tumour.

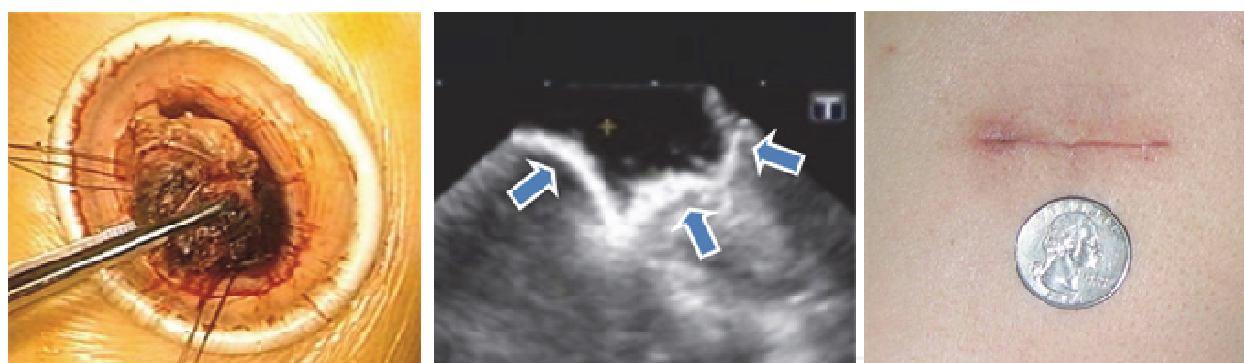


Fig. 12. Extraction of the tumour (left), remaining defect of the kidney (centre) and post-operative scar compared with a quarter (right).

3.3 Instruments

All instruments are inserted through a single port. Since this single port, usually 3-6 cm in diameter, is larger than the trocar ports typically used in laparoscopic surgery, larger instruments can be used which are not only less costly but also reusable. Representative instruments are cited. To keep the wound open as well as to protect it, an Alexis wound retractor® is usually used, but it is not always essential (Figure 4). To maintain the working space, original PLES retractors® are inserted (Figure 13). Haemostasis ligation is often achieved by means of two original devices, the Thread Pass® and the Knot Slide®, which allow easy ligation through the single port (Figure 14). A metal suction tube is useful both to

clean up the operative field and to separate the anatomical plane. Transection is often performed with a reusable ultrasonic coagulation device inserted through the port. To extract the kidney, an inexpensive original Flexible catcher® is used (Figure 15). All of the original devices mentioned here are commercially available and relatively inexpensive. For radical nephrectomy, only two of the required devices are disposable, the Flexible catcher® and the Alexis wound retractor®, and both of these are inexpensive, so that the overall cost of equipment is low. For partial nephrectomy, a Sonosurg® reusable ultrasonic coagulator can be used (Figure 16).




Fig. 13. Original PLES retractor®.




Fig. 14. Original devices for ligation: Thread Pass® and Knot Slide®. Ligation is often used for haemostasis and can be performed easily with these devices through the single port.

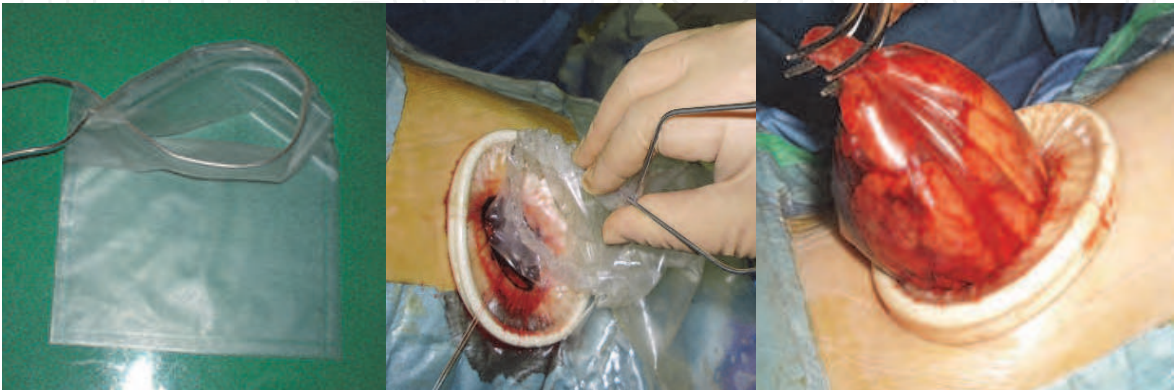

Fig. 15. The Flexible Catcher®, the original inexpensive catcher used to extract the specimen.

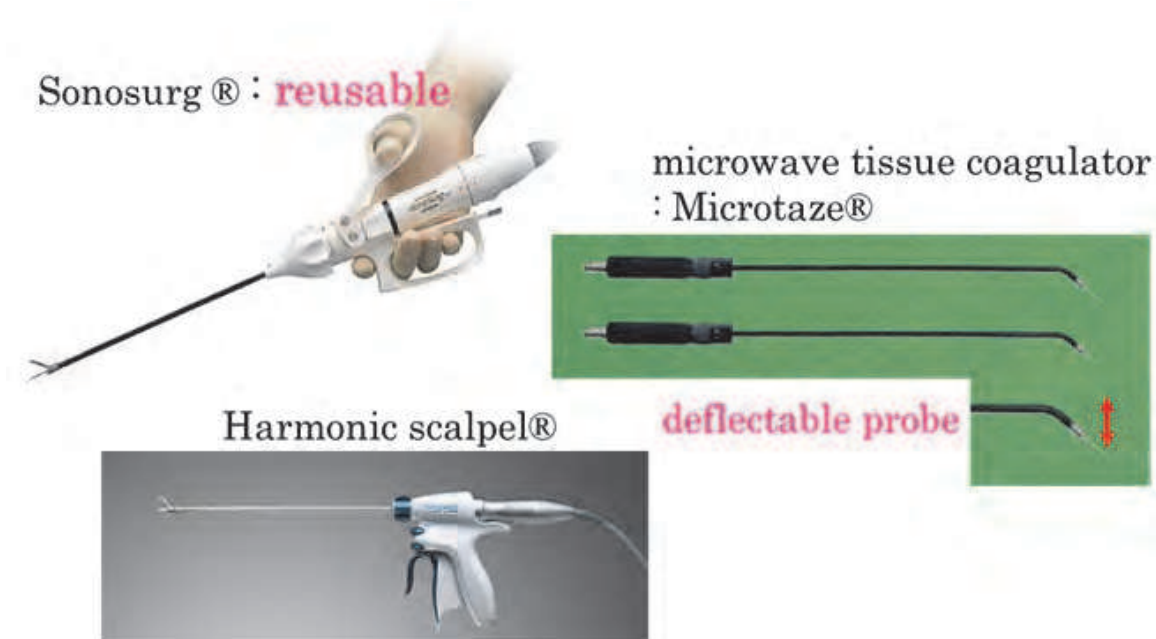


Fig. 16. For tissue coagulation and transection, especially in partial nephrectomy, a Sonosurg® reusable ultrasonic coagulator, a disposable Harmonic scalpel®, or a Microtaze® deflectable microwave tissue coagulator are used depending on the situation.

4. Results

4.1 Radical nephrectomy

The results of the initial 80 consecutive cases, performed by a small group of surgeons between August 1998 and June 2003, have been presented previously (Kihara et al., 2004). The results of 50 more recent consecutive cases, treated between 2009 and 2011, which were performed by a larger group of surgeons (including many inexperienced ones) are presented here. Patient age ranged from 35 to 85 years (mean 64). The duration of the operation was 186 min (range, 114 to 349). The median estimated blood loss was 229 ml (range, 2 to 1500). One patient subsequently received a blood transfusion. A complication arose during a single operation, namely, a small injury to the pleura which was repaired with a suture during the operation.

On the first postoperative day, oral feeding was possible in 90% of cases, and walking more than 100 m was possible in 92%. Within two postoperative days, discharge was possible for 86%. No complications \geq grade 3a according to the Clavien-Dindo classification were observed postoperatively. The rate of surgical site infection was 4% though no antimicrobial prophylactic agents were used. All infections were successfully treated by administering antibiotics.

Oncological outcomes of treatment for pT1-T2 RCC by means of this procedure at our hospital are as follows (Iimura et al., 2008): in 154 consecutive cases between 1998 and 2006, five-year overall survival, five-year recurrence-free survival and five-year cancer-specific survival were 95%, 91% and 96%. No local recurrence has been observed since 1998, when this procedure was introduced.

4.2 Partial nephrectomy

Between 2000 and 2011, over 150 cases of renal tumour underwent MIES-partial nephrectomy. In this chapter, we present the surgical outcomes of recent 50 consecutive cases treated between January 2009 and August 2010. Eight surgeons, including several who were inexperienced, performed these operations. The 50 cases consisted of 14 females and 36 males with a median age of 57 years (range, 36 to 79). Preoperative clinical T stage was T1a in 45 cases (90%), T1b in 3 (6%) and T2 in 1 (2%), and the median tumour size was 2.3 cm (range, 1.2 to 8.0). The location of tumour was peripheral in 37 cases (74%), central (a tumour contacting the renal sinus) in 12 (24%) and hilar (a tumour contacting the hilar vessels) in 1 (2%). The indication of partial nephrectomy was imperative in 2 cases (4%, chronic kidney disease and previous history of nephrectomy, respectively) and elective in the remaining 48 (96%).

In all cases but one, which was a central T1b tumour, partial nephrectomy was completed without clamping the hilar vessels. The median operation time was 234 min (range, 128 to 382). The median estimated blood loss was 210 ml (range, 0 to 2274). One case (2%) required allogeneic blood transfusion. No intraoperative complications were encountered.

On the first postoperative day, 47 patients (94%) resumed oral feeding. Patients were typically allowed to begin walking on the second postoperative day, when 43 patients (86%) were able to walk 100 m or farther. The median postoperative day on which the drainage tube was removed was 3 (range, 1 to 20). By postoperative day 3, 38 patients (76%) had recovered to such a degree that they no longer required inpatient care. Surgical site infection was observed in 2 cases (4%), both of which were successfully treated by administering antibiotics. Major postoperative complications of Clavien-Dindo grade 3 or greater were observed in 2 cases (4%); both cases required retroperitoneal drainage under local anaesthesia (Clavien grade 3a) for urine leakage and retroperitoneal abscess, respectively.

Pathological examination revealed that 41 tumours (82%) were RCC while the remaining 9 (18%) were benign. Although 5 (12%) of the 41 RCC patients had a positive surgical margin as determined microscopically, tumour tissues at the margin underwent thermal denaturation applied via an ultrasonic or a microwave coagulating device. To date, none of 150 cases including these 50 patients has experienced local disease recurrence. As for renal function of the 50 cases, the median % decrease in eGFR 3 months after the operation was 5.9%.

5. Advantageous features of MIES

CO₂ gas insufflation is associated with various risks, including hypertension, hypotension, hypercapnia, pulmonary embolism, decrease of pulmonary compliance and subcutaneous emphysema (See et al., 1993; Alberto et al., 2008); these arise mainly due to the effects of insufflation on the cardiovascular, respiratory and renal systems, although clinical problems rarely arise from careful anaesthesia. Gasless surgeries, such as this operation, can reduce the above risks and might prove especially helpful in operations on aged patients who often have concurrent cardiovascular, respiratory and renal disturbances. As the global population has aged, the number of aged patients has shown rapid increase lately. A high but fortunately subclinical rate of cardiac CO₂ embolism has been reported in laparoscopic radical prostatectomy for prostate cancer which usually occurs in aged men (Hong et al.,

2010); gasless surgery could reduce this rate. From the standpoint of global warming, furthermore, a reduction in the amount of CO₂ emitted from the hospital would be welcomed. In addition, MIES is associated with a low equipment cost similar to that associated with open surgery, because neither expensive disposable instruments nor robotic assistance is necessary, and with a low admission cost similar to that associated with laparoscopic surgery, because the procedure is minimally invasive which results in earlier discharge from the hospital. For cases of T4 RCC, advanced-stage RCC invading neighbouring organs, this surgery can be modified by extending the incision as necessary. Other common modifications are described below.

5.1 Radical nephrectomy for dialysis patients

It is well known that dialysis patients have high rates of RCC. Since dialysis patients usually have various concurrent conditions, especially of their cardiovascular or respiratory systems, and often undergo bilateral radical nephrectomy due to bilateral cancers (Sakura et al., 2007), the gasless nature of MIES is preferable for these patients as it reduces the risks of complications in the above systems. The retroperitoneal approach permitted by MIES is also helpful in that it reduces the likelihood of adhesion of the peritoneum, since some of these patients undergo peritoneal dialysis. The option to use the supine position in MIES is beneficial in that it reduces the risk of shunt obstruction. Finally, the low cost of MIES may also be helpful to the patients, given the high cost of dialysis.

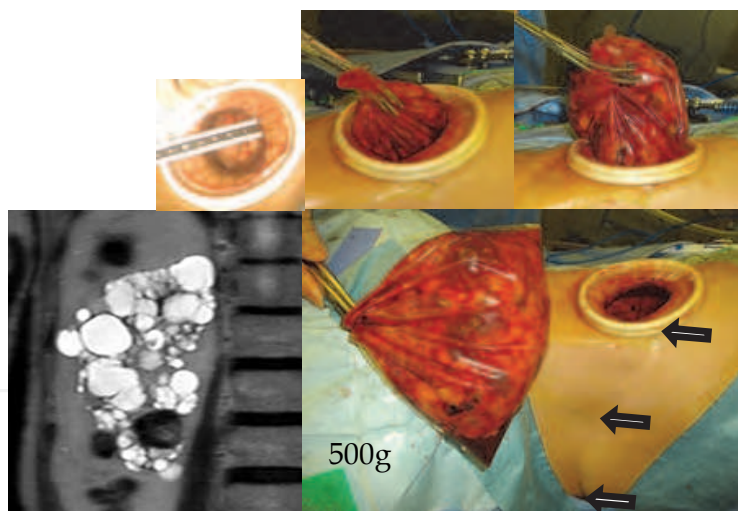


Fig. 18. Radical nephrectomy of a dialysis patient via a port 4 cm in diameter who had previously undergone partial resection of the liver. The arrows indicate the postoperative scar. The weight of the specimen extracted was 500g. CT scan shows ACDK, acquired cystic disease of the kidney, with RCC.

5.2 Modification of MIES for carcinoma of the renal pelvis

Carcinoma of the renal pelvis is considered a renal tumour and is sometimes difficult to distinguish from RCC. In other words, differential diagnosis between invasion of carcinoma of the renal pelvis into the renal parenchyma and RCC is occasionally not possible. In such cases, this procedure can be modified to allow two-port access for en-bloc extraction of the

kidney and ureter (Figure 19); this is described in the EAU video library (Saito et al., 2010). The kidney is isolated and extracted through a flank port while still connected with the ureter, as in MIES-radical nephrectomy, and is immediately analyzed to determine the presence of urothelial carcinoma or RCC. When urothelial carcinoma is highly suspected, the table is rotated from a lateral position to a semioblique position, and the distal ureter with the bladder cuff is isolated through a paramedian port about 3 cm in diameter in the lower abdomen. Thereafter, the specimen is extracted en bloc through the flank port and the paramedian port is used for drainage.

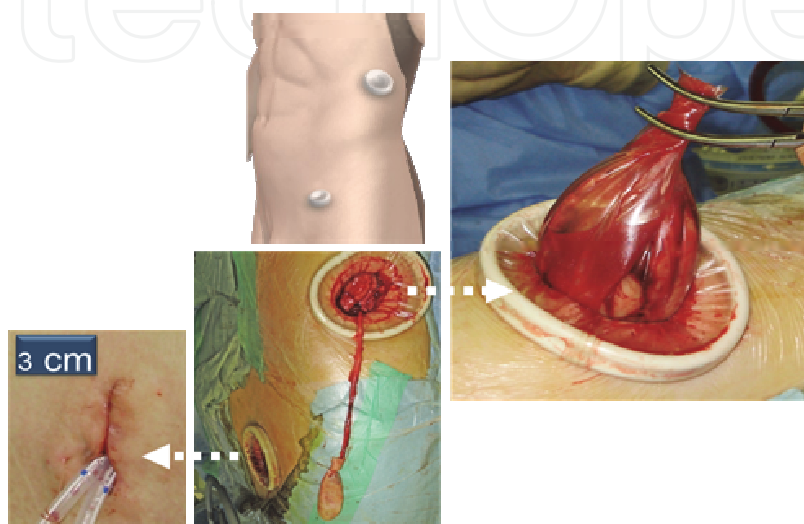


Fig. 19. MIES-total nephroureterectomy. See the text for details.

5.3 Preservation of renal function

It is essential in renal surgery to avoid the postoperative development of chronic kidney disease (Yokoyama et al., 2011a). In our analysis of 219 patients who underwent MIES-radical nephrectomy, 54 developed chronic kidney disease within 2 postoperative years. Univariate and multivariate analyses revealed that age, presence of diabetes mellitus, and preoperative estimated glomerular filtration rate were independent predictors of its development (Yokoyama et al., 2011b). Partial nephrectomy is recommended, if possible, for patients with the abovementioned risks. In order to preserve renal function insofar as it is possible during the operation, it is best to avoid clamping the renal vessels and using CO₂ insufflation which may cause compression of the renal vein. Recently, the rate of clampless MIES-partial nephrectomy at our hospital has been above 95%.

5.4 No usage of antimicrobial prophylaxis

Antimicrobial prophylaxis is associated with several negative effects, including drug-induced complications of major organs, possible introduction of drug-resistant bacteria and high cost. MIES has several features that may help reduce the incidence of infectious complications: a minimal incision, wound protection provided by the Alexis® wound retractor and completion of procedures without insertion of fingers. We prospectively evaluated the incidences of surgical site infection (SSI) after MIES for renal and adrenal tumours in the absence of antimicrobial prophylaxis (Yoshida et al., 2007; Kijima et al.,

2011). In 301 patients, the incidences of superficial SSI and deep SSI were very low, 1.3% and 0.7%, respectively. All perioperative infections were successfully treated by administering antimicrobial agents.

Antimicrobial prophylaxis is fundamentally not necessary in MIES-radical nephrectomy or MIES-partial nephrectomy in which the urinary tract is not opened during the operation. After stopping the routine usage of antimicrobial prophylaxis, the incidence of drug-resistant bacterial infection has markedly decreased at our ward (unpublished data).

5.5 Limitations of MIES

The limitations of MIES are due to the insertion of all instruments, including the endoscope, through a small single port. It is necessary to be familiar with the handling of the instruments used in the operation. Nevertheless, inexperienced surgeons become able to deliver results similar to those of high-volume surgeons within a short period (Kihara et al., 2010a). It may be attributed to the fact that this surgery offers four visions as described above (Figure 2), and can be modified to accommodate the operator's level of experience by extending the incision as necessary. More than 2000 MIES for urological cancers have been safely performed up to now in our hospital.

6. Spread of MIES

In Japan, several regulatory requirements must be met to perform MIES, but at present more than 70 major hospitals meet these requirements, and this number is increasing year by year. This surgery has been introduced worldwide, in such places as Europe, the US, China, Korea and Brazil. MIES-radical nephrectomy, MIES-partial nephrectomy and MIES-nephroureterectomy have been cited in the video library of EAU (Kihara, 2009b, 2010b; Saito et al., 2010), and textbooks on this technique have been published in China (Kihara, 2003, 2010c).

7. MIES in the near future

The two-dimensional endoscope is being replaced by a three-dimensional endoscope in our hospital, in which case direct supplemental visualization through the port for stereovision is unnecessary. As for the size of the port, it has already been reduced to just over 2 cm in diameter for a small specimen such as the adrenal gland. The console presently used for robotic surgery may become more compact to the point of being useable as a head mount. Depending on the economic situation involved, MIES could be modified into a gasless single-port (2 cm if necessary) and economical robotic (non-console) surgery.

8. Conclusion

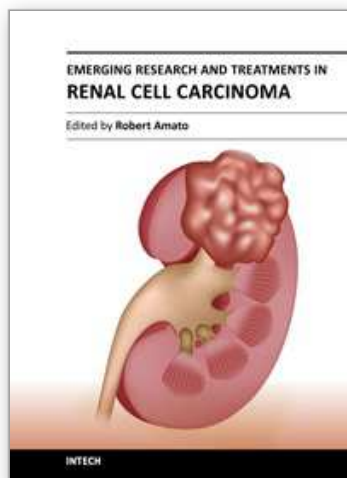
MIES for RCC has several unique characteristics including its gasless nature, single-port access, the use of the retroperitoneal approach, no usage of prophylactic agents, no clamping of the renal vessels and a relatively low equipment cost. MIES shows that low invasiveness similar to that in laparoscopic surgery can be achieved in surgery for RCC without gas insufflation and without expensive disposable instruments and expensive machines.

Future work will integrate the surgical techniques described here with new devices, and perhaps robots (non-console), to fulfil additional needs in the field of surgery for urological cancers.

9. References

- Alberto, R.; Bollens, R. & Cohen, B.E. (2008). Fundamentals of laparoscopic surgery. In: *Manual of laparoscopic urology*, Springer-Verlag, pp. 3-17, ISBN 978-3-540-74726-0, Berlin, Germany
- Clayman, R.V.; Kavoussi, L.R.; Soper, N.J.; Dierks, S.M.; Darcy, M.D.; Long, S.R.; Roemer, F.D.; Pingleton, F.D. & Thomson, P.G. (1991). Laparoscopic nephrectomy. *N. Engl. J. Med.*, Vol.324, No.19, pp. 1370-1371
- Dasgupta, P. & Kirby, R.S. (2009). Outcomes of robotic assisted radical prostatectomy. *Int. J. Urol.*, Vol.16, No.3, pp. 244-248
- Guillonnet, B. & Vallancien, G. (1999). Laparoscopic radical prostatectomy: initial experience and preliminary assessment after 65 operations. *Prostate*, Vol.39, No.1, pp. 71-75
- Han, W.K.; Kim, D.S.; Jeon, H.G.; Jeong, W.; Oh, C.K.; Choi, K.H.; Lorenzo, E.I. & Rha, K.H. (2011). Robot-assisted laparoendoscopic single-site surgery: partial nephrectomy for renal malignancy. *Urology*, Vol.77, No.3, pp. 612-616
- Hong, J.Y.; Kim, W.O. & Kil, H.K. (2010). Detection of subclinical CO2 embolism by transesophageal echocardiography during laparoscopic radical prostatectomy. *Urology*, Vol.75, No.3, pp. 581-584
- Iimura, Y.; Kihara, K.; Saito, K.; Masuda, H.; Kobayashi, T. & Kawakami, S. (2008). Oncological outcome of minimum incision endoscopic radical nephrectomy for pathologically organ confined renal cell carcinoma. *Int. J. Urol.*, Vol.15, No.1, pp.44-47
- Kageyama, Y.; Kihara, K.; Kobayashi, T.; Kawakami, S.; Fujii, Y.; Masuda, H.; Yano, M. & Hyochi, N. (2004). Portless endoscopic adrenalectomy via a single minimum incision by retroperitoneal approach: Experience with initial 30 cases. *Int. J. Urol.* Vol.11, No.9, pp. 693-699
- Kaouk, J.H. & Goel, R.K. (2009). Single-port laparoscopic and robotic partial nephrectomy. *Eur. Urol.*, Vol.55, No.5, pp. 1163-1169
- Kihara, K.; Kageyama, Y.; Kobayashi, T.; Okuno, T.; Kawakami, S.; Hayashi, T.; Masuda, H.; Suzuki, M.; Hyouchi, N. & Arai, G. (2002). *Portless endoscopic urological surgery*. Igaku-shoin, ISBN 4-260-13356-X, Tokyo, Japan (Japanese & English)
- Kihara, K.; Kageyama, Y.; Kobayashi, T.; Okuno, T.; Kawakami, S.; Hayashi, T.; Masuda, H.; Suzuki, M.; Hyouchi, N. & Arai, G. (2003). *Portless endoscopic urological surgery*. Liaoning Science and Technology Publishing House, pp. 10-185, ISBN 7-5381-3988-5, Liaoning, China (Chinese)
- Kihara, K.; Kageyama, Y.; Yano, M.; Kobayashi, T.; Kawakami, S.; Fujii, Y.; Masuda, H. & Hyochi, N. (2004). Portless endoscopic radical nephrectomy via a single minimum incision in 80 patients. *Int. J. Urol.*, Vol.11, No.9, pp.714-720
- Kihara, K. (2007). *Illustrated minimum incision endoscopic urological surgery*. Igaku-shoin, pp. 1-130, Japanese, ISBN 978-4-260-00481-7, Tokyo, Japan (Japanese)
- Kihara, K.; Kawakami, S.; Fujii, Y.; Masuda, H. & Koga, F. (2009a). Gasless single-port access endoscopic surgery in urology: minimum incision endoscopic surgery, MIES. *Int. J. Urol.*, Vol.16, No.10, pp.791-800

- Kihara, K.; Kawakami, S.; Fujii, Y.; Masuda H.; Koga F. & Saito F. (2009b). Gasless single port access radical nephrectomy. *Eur. Urol. Suppl.*, Vol.8, No.4, pp. 392
- Kihara, K.; Kobayashi. T.; Kawakami, S.; Fujii, Y.; Kageyama, H. & Masuda, H. (2010a). Minimum Incision Endoscopic Surgery (MIES) in Japanese Urology: Results of Adrenalectomy, radical nephrectomy and radical prostatectomy. *Aktuelle. Urol.*, Vol.41, Suppl.1, S15-S19
- Kihara, K.; Tushima, S.; Kawakami, Y.; Fujii, Y.; Masuda H.; Koga F. & Saito F. (2010b). Gasless single port access ultrasound-guided clampless partial nephrectomy: MIES partial nephrectomy. *Eur. Urol. Suppl.*, Vol.9, No.2, pp. 335-336
- Kihara, K. (2010c). *Illustrated minimum incision endoscopic urological surgery*. Guangxi Science and Technology Publishing House, pp. 1-130, ISBN 978-7-80763-578-9, Guangxi, China (Chinese)
- Kijima, T.; Masuda, H.; Yoshida, S.; Tatokoro, M.; Araki, S.; Yokoyama, M.; Numao, N.; Okada, Y.; Saito, K.; Koga, F.; Fujii, Y. & Kihara, K. (2011). Antibiotic prophylaxis is not necessary in minimally invasive surgery for renal and adrenal tumors: A prospective study of 301 consecutive patients. *J. Urol. Suppl.*, Vol.185, No.4, pp. 470-471
- Koga, F.; Kihara, K.; Masuda, H.; Kageyama, Y.; Kawakami, S. & Kobayashi. T. (2007). Minimum incision endoscopic Nephrectomy for giant hydronephrosis. *Int. J. Urol.*, Vol.14, No.8, pp.774-776
- Kommu, S.S.; Kaouk, J.H. & Rane, A. (2009). Laparo-endoscopic single-site surgery: preliminary advances in renal surgery. *BJU Int.*, Vol.103, No.8, pp.1034-1037
- Lee, R.S.; Sethi, A.S.; Passerotti, C.C.; Retik, A.B.; Borer, J.G.; Nguyen, H.T. & Peters, C.A. (2009). Robot assisted laparoscopic partial nephrectomy : a viable and safe option in children. *J. Urol.*, Vol.181, No.2, pp. 823-828
- Ponsky, L.E.; Cherullo, E.E.; Sawyer, M. & Hartke, D. (2008). Single access site laparoscopic radical nephrectomy: initial clinical experience. *J. Endourol.*, Vol.22, No.4, pp. 663-666
- Raman, J.D.; Cadeddu, J.A.; Rao, P. & Rane, A. (2008). Single-incision laparoscopic surgery: initial urological experience and comparison with natural-orifice transluminal endoscopic surgery. *BJU Int.*, Vol.101, No.12, pp. 1493-1496
- Saito, K.; Kihara, K.; Kawakami, Y.; Fujii, Y.; Masuda H. & Koga F. (2010). Gasless two port access total nephroureterectomy: MIES nephroureterectomy. *Eur. Urol. Suppl.*, Vol.9, No.2, pp. 335
- Sakura, M.; Kawakami, S.; Masuda, H.; Kobayashi, T.; Kageyama, Y. & Kihara, K. (2007). Sequential bilateral minimum incision endoscopic radical nephrectomy in dialysis patients with bilateral renal cell carcinomas. *Int. J. Urol.*, Vol.14, No.12, pp.1109-1112
- See, W.A.; Monk, T.G. & Weldon, B.C. (1993). Complications of laparoscopy. In: Clayman, R.V.; McDougall, E.M (eds). *Laparoscopic urology*. Quality Medical Publishing Inc., pp.183-206 ISBN 0-942219-41-4, St. Louis, MO, U.S.A.
- Yokoyama, M.; Fujii, Y.; Iimura, Y.; Saito, K.; Koga, F.; Masuda, H.; Kawakami, S. & Kihara, K. (2011a). Longitudinal change in renal function after radical nephrectomy in Japanese patients with renal cortical tumors. *J. Urol.*, Vol.185, No.6, pp. 2066-2071
- Yokoyama, M.; Fujii, Y.; Iimura, Y.; Saito, K.; Koga, F.; Masuda, H. & Kihara, K. (2011b). A nomogram for predicting the development of chronic kidney disease within 2 years after radical nephrectomy in patients with renal cortical tumor. *J. Urol. Suppl.*, Vol.185, No.4, pp. 436
- Yoshida, S.; Masuda, H.; Yokoyama, M.; Kobayashi, T.; Kawakami, S. & Kihara, K. (2007). Absence of prophylactic antibiotics in minimum incision endoscopic urological surgery (MEUS) of adrenal and renal tumors. *Int. J. Urol.*, Vol.14, No.5, pp. 384-387



Emerging Research and Treatments in Renal Cell Carcinoma

Edited by Dr. Robert Amato

ISBN 978-953-51-0022-5

Hard cover, 442 pages

Publisher InTech

Published online 03, February, 2012

Published in print edition February, 2012

The field of renal cell cancer has undergone a significant resurgence. This book summarizes up-to-date research and innovative ideas for the future in this rapidly changing field, which encompasses medicine, surgery, radiation oncology, basic science, pathology, radiology, and supportive care. This book is aimed at the clinician or scientist who has an interest in renal cell cancer, whether they are academic or nonacademic. The book covers tumor biology, molecular biology, surgery techniques, radiation therapy, personal testimonies, and present and future treatments of the disease that are on the horizon. The goal was to produce a textbook that would act as an authoritative source for scientists and clinicians and interpret the field for trainees in surgery, medicine, radiation oncology, and pathology.

How to reference

In order to correctly reference this scholarly work, feel free to copy and paste the following:

Kazunori Kihara, Yasuhisa Fujii, Satoru Kawakami, Hitoshi Masuda, Fumitaka Koga, Kazutaka Saito, Noboru Numao, Yoh Matsuoka and Yasuyuki Sakai (2012). Gasless Single Port Surgery for Renal Cell Carcinoma: Minimum Incision Endoscopic Surgery, *Emerging Research and Treatments in Renal Cell Carcinoma*, Dr. Robert Amato (Ed.), ISBN: 978-953-51-0022-5, InTech, Available from: <http://www.intechopen.com/books/emerging-research-and-treatments-in-renal-cell-carcinoma/gasless-single-port-surgery-for-renal-cell-carcinoma-minimum-incision-endoscopic-surgery-mies->

INTECH
open science | open minds

InTech Europe

University Campus STeP Ri
Slavka Krautzeka 83/A
51000 Rijeka, Croatia
Phone: +385 (51) 770 447
Fax: +385 (51) 686 166
www.intechopen.com

InTech China

Unit 405, Office Block, Hotel Equatorial Shanghai
No.65, Yan An Road (West), Shanghai, 200040, China
中国上海市延安西路65号上海国际贵都大饭店办公楼405单元
Phone: +86-21-62489820
Fax: +86-21-62489821

© 2012 The Author(s). Licensee IntechOpen. This is an open access article distributed under the terms of the [Creative Commons Attribution 3.0 License](https://creativecommons.org/licenses/by/3.0/), which permits unrestricted use, distribution, and reproduction in any medium, provided the original work is properly cited.

IntechOpen

IntechOpen