

We are IntechOpen, the world's leading publisher of Open Access books Built by scientists, for scientists

6,900

Open access books available

185,000

International authors and editors

200M

Downloads

Our authors are among the

154

Countries delivered to

TOP 1%

most cited scientists

12.2%

Contributors from top 500 universities



WEB OF SCIENCE™

Selection of our books indexed in the Book Citation Index
in Web of Science™ Core Collection (BKCI)

Interested in publishing with us?
Contact book.department@intechopen.com

Numbers displayed above are based on latest data collected.
For more information visit www.intechopen.com



Torsades de Pointes in Takotsubo Cardiomyopathy with QT Prolongation

Hiroaki Kawano

*Department of Cardiovascular Medicine, Nagasaki University
Japan*

1. Introduction

Takotsubo cardiomyopathy, or stress-induced cardiomyopathy, is characterized by reversible left ventricular apical ballooning associated with emotional or physiologic stress, mimicking acute myocardial infarction in the absence of significant coronary artery disease at angiography. Although the prognosis for patients with Takotsubo cardiomyopathy is relatively good, it is reported to be associated with long QT syndrome and torsades de pointes (TdP) which is a fatal polymorphic ventricular tachyarrhythmia.

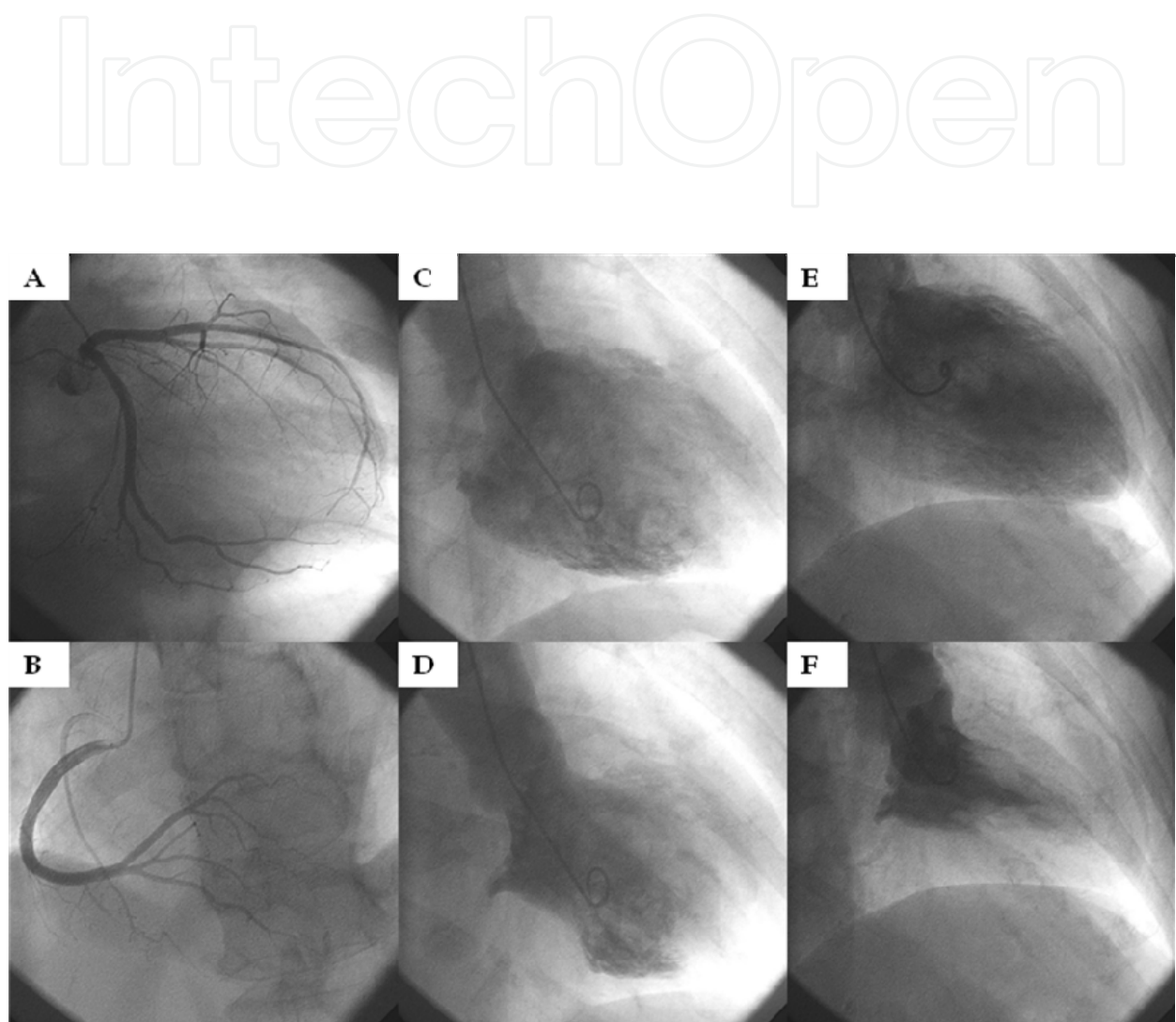
However, only QT prolongation abnormalities is not enough to induce TdP, and other factors associated with Takotsubo cardiomyopathy seem to be needed for the induction of TdP. In this chapter, the mechanism of TdP in Takotsubo cardiomyopathy with QT prolongation is discussed.

2. Takotsubo cardiomyopathy

Takotsubo cardiomyopathy, or stress-induced cardiomyopathy, is a disease exhibiting an acute left ventricular apical ballooning of unknown cause (Kawai et al., 2007). Many cases with takotsubo cardiomyopathy are associated with preceded emotional or physiologic stress. In this disease, the left ventricle takes on the appearance of a Japanese octopus fishing pot called a takotsubo. In takotsubo cardiomyopathy, left ventricular dysfunction is reversible, i.e., it recovers within a few weeks (Figure 1). Other signs include ECG changes, including ST-segment elevation, abnormal Q wave, and T-wave inversions (Figure 2), which mimicks acute myocardial infarction but there is no significant coronary artery disease at angiography (Kawai et al., 2007, Tsuchihashi et al., 2001, Kurisu et al., 2002).

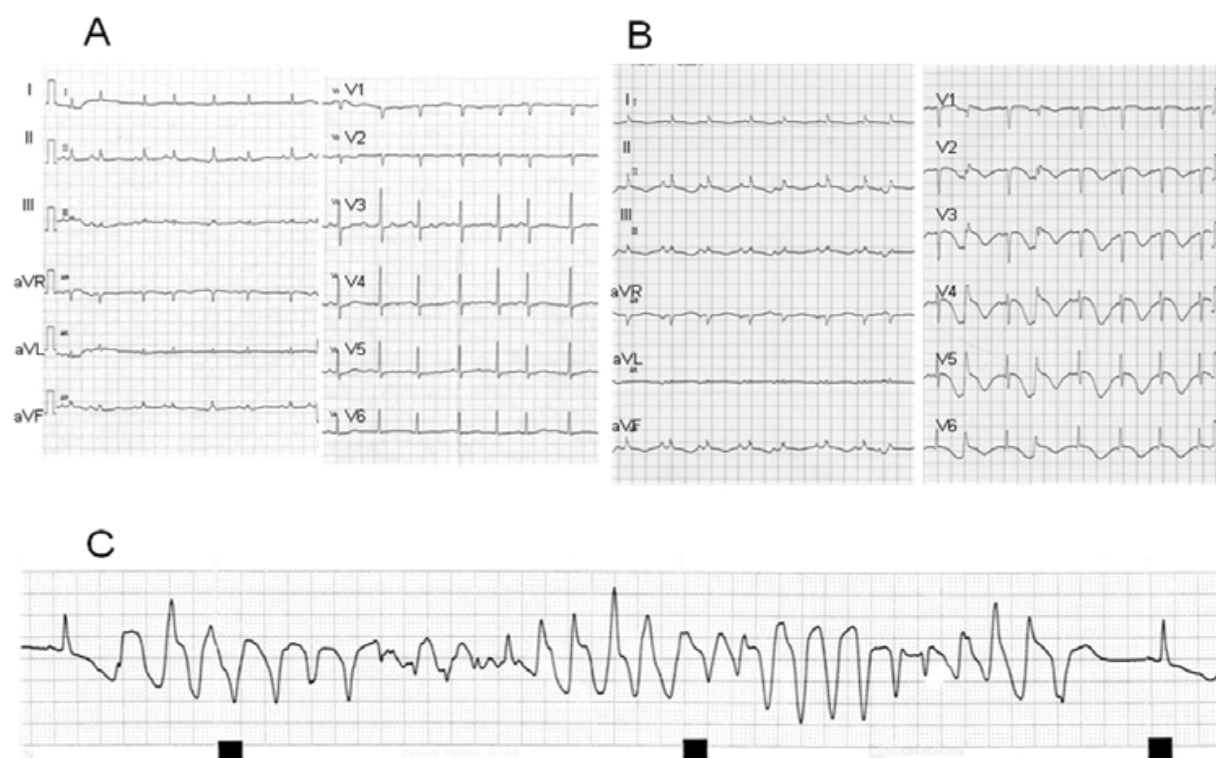
Several pathophysiological mechanisms have been proposed to explain the features of this syndrome, such as multivessel coronary vasospasm, abnormalities in coronary microvascular function, and catecholamine-mediated cardiotoxicity (Akashi et al, 2002, Kurisu et al, 2003, Sansen V & Holvoet G., 2007). Studies on ¹²³I-metaiodobenzylguanidine suggested the existence of cardiac autonomic damage and/or accelerated cardiac sympathetic nervous function in patients with Takotsubo cardiomyopathy (Akashi et al, 2004, Burgdorf et al, 2008). Nef, et al (Nef et al, 2007) reported that there were contraction bands, increase in fibrosis, and the regional accumulation of inflammatory cells in biopsied specimen of myocardium in acute phase of Takotsubo cardiomyopathy, and they suggested that these findings were similar to those associated with catecholamine cardiotoxicity. These

data suggest that catecholamine-mediated cardiotoxicity may be the most plausible cause of Takotsubo cardiomyopathy although the precise aetiology and pathophysiology of this syndrome remain unknown.



Coronary angiography showed no significant coronary stenosis of the left (A) and right (B) coronary arteries. Left ventriculography demonstrated akinesis of apex of the left ventricle on admission (C, end-diastolic phase; D, end-systolic phase) and showed recovered apical wall motion of the left ventricle about three weeks after admission (E, end-diastolic phase; F, end-systolic phase).

Fig. 1. Coronary angiography and left ventriculography on admission and about three weeks after the admission



A, ECG showed sinus rhythm, and flat T waves. B, ECG showed sinus rhythm, poor R wave progression in leads V1 to V3, and QT prolongation with a corrected QT interval of 800 msec. C, ECG monitor demonstrated torsades de pointes.

Fig. 2. Electrocardiography (ECG) before (A) and just after (B) the occurrence of Takotsubo Cardiomyopathy, and ECG monitor of torsades de pointes(C)

Takotsubo cardiomyopathy occurs most frequently in women over 50 years of age. The reason for the much more common occurrence in post-menopausal women is unclear. Several explanations have been proposed. Sex hormones may exert important influences on the sympathetic neurohormonal axis (Hinojosa-Laborde et al, 1999) and on coronary vasoreactivity (Sader & Celermajer, 2002). Women appear also to be more vulnerable to sympathetically mediated myocardial stunning (Lambert et al, 2002), and post-menopausal alteration of endothelial function in response to reduced estrogen levels has been advocated as a possible alternative explanation (Taddei et al, 1996).

3. Long QT syndrome (QT prolongation) and torsades de pointes

The Long QT syndrome (LQTS) is originally a hereditary disorder in which most affected family members have delayed ventricular repolarization manifest on the electrocardiogram (ECG) as QT prolongation (Moss et al, 1985). The disorder is associated with an increased propensity to arrhythmogenic syncope, polymorphic ventricular tachycardia (torsades de pointes), and sudden arrhythmic death. LQTS is due to mutations involving principally the myocyte ion-channels, and this monogenetic disorder has an autosomal-dominant inheritance pattern. Since the 3 genes were identified for the 3 major genotypes, a total of 13 forms of LQTS have been reported (Shimizu W & Horie M.).

Recently, mutations in the caveolin-3 gene (CAV3) have been linked with the congenital long QT syndrome (LQT9), and mutations in caveolar-localized ion channels may contribute

to other inherited arrhythmias. Caveolin-3 is the essential scaffolding protein of caveolae which are specialized membrane microdomains enriched in cholesterol and sphingolipids which are present in multiple cell types including cardiomyocytes. Along with the essential scaffolding protein caveolin-3, a number of different ion channels and transporters have been localized to caveolae in the heart. Mutations in caveolar-localized ion channels may contribute to other inherited arrhythmias, and changes in the caveolar microdomain in acquired heart disease may also lead to dysregulation and dysfunction of ion channels, altering the risk of arrhythmias in conditions such as heart failure (Balijepalli & Kamp, 2008). This indicate that abnormality or damage of structural elements of cardiomyocyte may also induce QT prolongation and arrhythmia.

Long QT syndrome can be also divided into idiopathic (congenital) and acquired forms. QT intervals vary according to age, sex, and heart rate, and acquired long QT syndrome describes pathologic QT interval prolongation. Acquired long QT syndrome can arise in response to various drugs, electrolyte abnormalities (e.g., hypokalemia, hypomagnesemia) and significant bradyarrhythmias. It also becomes a risk of arrhythmogenic syncope, polymorphic ventricular tachycardia (torsades de pointes), and sudden arrhythmic death.

Torsade de pointes (TdP) is a life-threatening arrhythmia that develops as a consequence of a reduction in the repolarization reserve of cardiac cells leading to amplification of electrical heterogeneities in the ventricular myocardium as well as to the development of early after depolarization-induced triggered activity.

Autonomic nervous system may have important role in the initiation of Tdp (Coumel, 1993). The level of adrenergic drive is required for the occurrence of Tdp, and it also produces a sinus tachycardia that would prevent QT prolongation. Autonomic tone influences the QT interval directly by affecting the action potential duration and indirectly by modulating the RR interval. These indicate that the interactions between heart rate and sympathetic nervous activity are complex. Fujiki et al (Fujiki et al, 2001) suggested that the sympathovagal imbalance may have an important role in the dynamic change in the QT interval and initiation of Tdp in patients with long QT syndrome. In patients with acquired long-QT syndrome, Locati et al (Locati et al, 1995) reported that both adrenergic- and pause-dependent mechanisms may have a synergistic role in the genesis of Tdp.

Women are more prone to develop TdP than men either congenital or acquired LQTS, and it is similar to the sex difference of occurrence of Takotsubo cardiomyopathy. Although the precise mechanism has not been clarified, female hormone may exert the influence on cardiac repolarization process (Kurokawa et al, 2009).

4. Torsades de pointes in takotsubo cardiomyopathy with QT prolongation

The presence of QT interval prolongation has been discussed in patients with Takotsubo cardiomyopathy (Abe et al., 2003, Desmet et al., 2003, Matsuoka et al., 2003), and there have been 17 reported cases of QT interval prolongation and torsades de pointes (TdP) associated with Takotsubo cardiomyopathy (Denney et al., 2005, Sasaki et al., 2006, Okada T, et al., 2007 [in Japanese], Nault et al., 2007, Boulouffe et al., 2007, Patel et al., 2007, Kurisu et al., 2008, Furushima et al., 2008, Hirose et al., 2008, Ghosh et al., 2009, Mahida et al., 2009, Inoue et al., 2009, Kawano et al., 2010, Purvis et al., 2009, Yamada et al., 2011) (Figure 2) (Table 1). Considering the 17 previous cases reported in the literature, QT prolongation in Takotsubo cardiomyopathy has been attributed to hypokalemia (n= 3), bradycardia associated with

atrioventricular (AV) block (n=4), idiopathic long QT syndrome (n=2), hypokalemia plus antiarrhythmic therapy (n=1), and hypokalemia plus idiopathic long QT syndrome (n=1), hypokalemia and hypomagnesemia (n=1), hyponagnesemia (n=1), and antibiotic (n=1) in 14 cases, and there was no specific factor associated with QT prolongation in 3 cases. The vasospasm provocation test was performed in only 3 cases, and vasospasm was not induced in any of these cases.

Hypokalemia or hypomagnesemia is one of the most important risk factor because it is present in 7 of 17 (41%) case. Bradycardia associated with AV block is also one of the important factor because its presence in 4 of 17 (24%) cases. These observations suggest that electrolyte imbalances and bradycardia are a risk factor for the development of torsades de pointes in patients with Takotsubo cardiomyopathy.

However, only QT prolongation is not enough to induce TdP. Oscillations of the RR interval or the short-long-short (or the long-short) sequence precede the initiation of TdP in patients with acquired prolongation of repolarization (Locati et al., 1995). In most cases of TdP, frequent premature ventricular contraction (PVC)s create long-short sequence, i.e., a VPC generates a post-extrasystolic pause, the following regular beat shows marked QT prolongation from which a subsequent PVC arise, and this beat initiates TdP. Triggered activity originating from early after-depolarization or phase 2 reentry has been suggested as the cause of the PVC which induces long-short initiating sequence and can be the first beat of TdP. However, there is another unique pattern of the initiating of TdP in Takotsubo cardiomyopathy (Kawano et al., 2010,). It seems that premature atrial contraction (PAC) followed by QRS on T wave can also induced reentrant ventricular tachycardia directly (Figure 3). The peak of T wave is known as the vulnerable period of the ventricle. Depolarization at this phase may easily induce unstable reentrant mechanism especially in the case with prominently increased dispersion of repolarization such as long QT syndrome. This mechanism of TdP is also very rare in long QT syndrome. Moreover, that case had already had mild QT prolongation with hypokalemia and PAC before the occurrence of Takotsubo cardiomyopathy. This suggests that other factors associated with Takotsubo cardiomyopathy is needed for the induction of TdP.

Prolongation of action potential duration (APD) due to abnormal ion channel current causes QT prolongation. Dispersion of APD or repolarization is thought to be one of the mechanisms of occurrence of TdP, and Furushima et al. (Furushima et al., 2008) reported abnormal LV repolarization gradient in a patient with Takotsubo cardiomyopathy. Taken together, dispersion of APD or repolarization in Takotsubo cardiomyopathy as well as QT prolongation may be important in the occurrence of TdP. Adrenergic stimulation may be also related to TdP in Takotsubo cardiomyopathy because catecholamine excess and neurogenic myocardial stunning are thought to be one of the the most plausible causes of Takotsubo cardiomyopathy.

On the other hands, TdP may be one of the trigger of Takotsubo cardiomyopathy in long QT syndrome. Although it occurs most frequently in women over 50 years of age, recent study demonstrated that men with Takotsubo cardiomyopathy-associated QT interval prolongation are at risk for TdP, and that most patients with Takotsubo cardiomyopathy-associated TdP have risk factors for TdP other than the female sex and systolic dysfunction (Samuelov-Kinori, 2009).

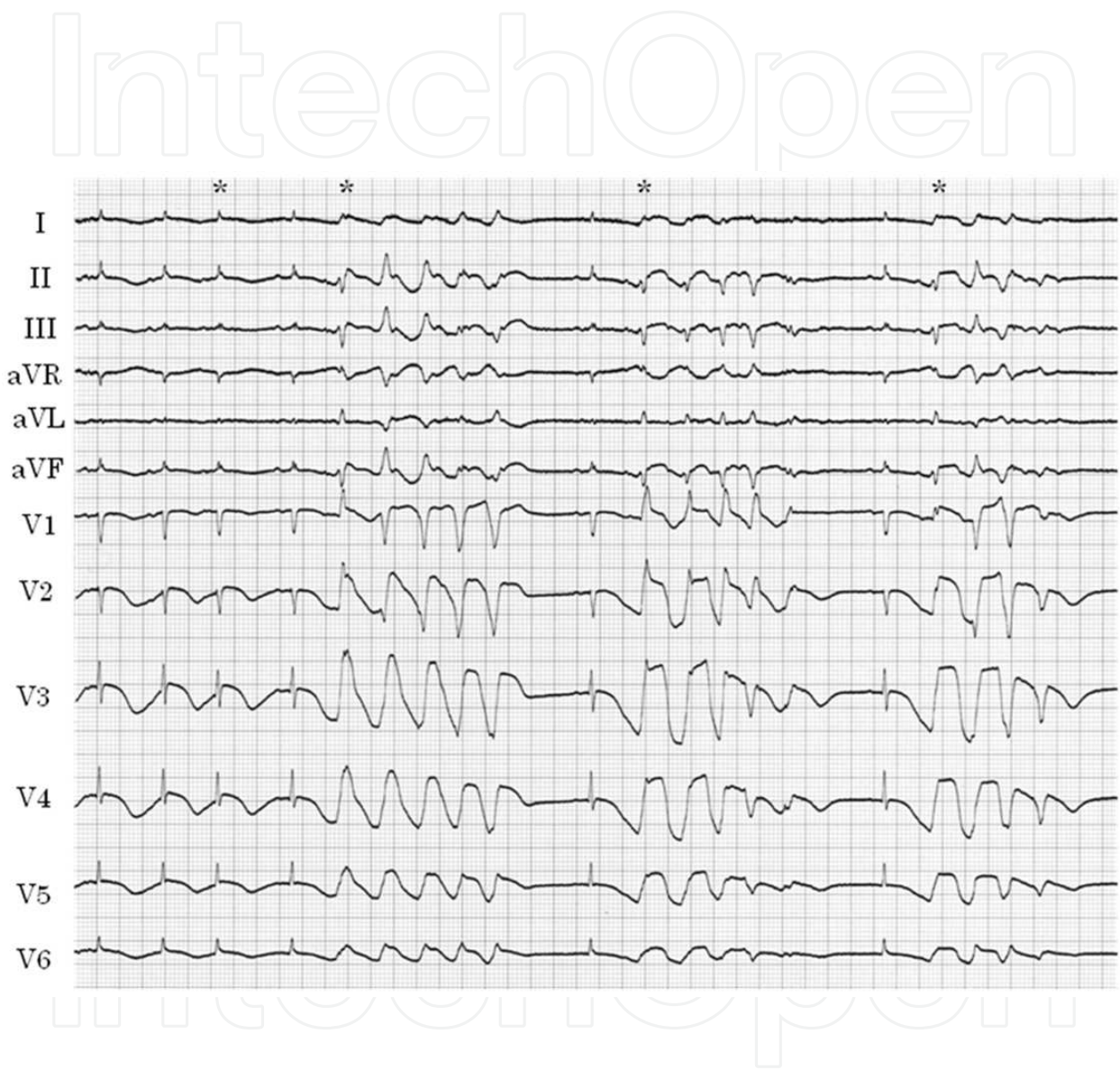


Fig. 3. ECG showed that PACs (*) induced long-short sequence and initiated TdP.

	Age	Sex	Diseases	serum K(mEq/L)	QTc (msec)
1	32	M	migrane, BA, allergic rhinitis	normal	467
2	22	F	LQTS	2.8	730
3	77	M	pneumonia	3.7	730
4	76	F	rhabdomyolysis	3.3	786
5	68	F	none	not determined	prolongation
6	72	F	HT, COPD	not determined	674
7	87	F	AV block	not determined	735
8	78	M	AV block	not determined	735
9	61	F	LQTS	not determined	590
10	63	F	Myasthenia gravis	2.8	549
11	59	F	HT, alcoholic	3.2	669
12	55	F	LQTS	normal	510
13	82	F	AV block	4	630
14	80	M	BA, HT, alcoholic	2.6	800
15	67	F	Depression	3.9	524
16	89	F	AV block	4.6	580
17	81	F	atrial fibrillation	4.3	620

M male, F female, BA bronchial asthma, LQTS idiopathic long QT syndrome, HT hypertension

Table 1. Reports of Takotsubo Cardiomyopathy with Torsades de Pointes

5. Conclusion

We usually pay attention to ventricular arrhythmia in other cardiomyopathy, i.e., hypertrophic cardiomyopathy and dilated cardiomyopathy. And we have to also consider the importance of PAC as well as VPC as the initiator of TdP, the life-threatening arrhythmia in Takotsubo cardiomyopathy .

6. Acknowledgment

I thank editors of Internal Medicine for their excellent advice to discuss the mechanisms of torsasede de pointes in Takotsubo cardiomyopathy.

7. References

Abe Y, Kondo M, Matsuoka R, Araki M, Dohyama K, Tanio H. Assessment of clinical features in transient left ventricular apical ballooning. J Am Coll Cardiol 41: 737-742, 2003

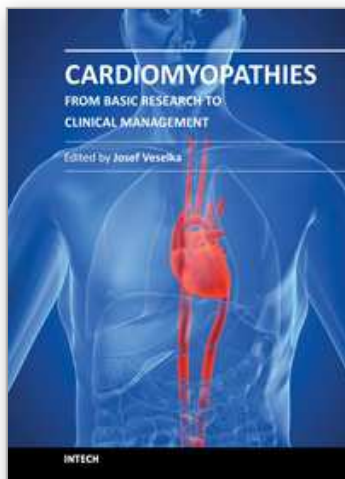
Akashi YJ, Nakazawa K, Sakakibara M, Miyake F, Sasaka K. Reversible left ventricular dysfunction "takotsubo" cardiomyopathy related to catecholamine cardiotoxicity. J Electrocardiol 35: 351-6, 2002

- Akashi YJ, Nakazawa K, Sakakibara M, Miyake F, Musha H, Sasaka K. 123I-MIBG myocardial scintigraphy in patients with "takotsubo" cardiomyopathy. *J Nucl Med* 45:1121-7, 2004
- Balijepalli RC& Kamp TJ.Caveolae, ion channels and cardiac arrhythmias. *Prog Biophys Mol Biol* 98:149-60, 2009
- Boulouffe C, Vanpee D, Gabriel L. Stress-induced cardiomyopathy: Takotsubo left ventricular dysfunction. *Am J Emerg Med* 25: 243-244, 2007
- Burgdorf C, von Hof K, Schunkert H, Kurowski V. Regional alterations in myocardial sympathetic innervation in patients with transient left-ventricular apical ballooning (Tako-Tsubo cardiomyopathy). *J Nucl Cardiol* 15 :65-72, 2008
- Coumel P. Cardiac arrhythmia and the autonomic nervous system. *J Cardiovasc Electrophysiol* 1993; 4: 338-355
- Denney SD, Lakkireddy DR, Khan IA. Long QT syndrome and torsade de pointes in transient left ventricular apical ballooning syndrome. *Int J Cardiol* 100:499-501, 2005
- Desmet WJ, Adriaenssens BF, Dens JA. Apical ballooning of the left ventricle: first series in white patients. *Heart* 89: 1027-1031, 2003
- Fujiki A, Nishida K, Mizumaki K, Nagasawa H, Shimono M, Inoue H. Spontaneous onset of torsade de pointes in long-QT syndrome and the role of sympathovagal imbalance. *Circ J* 65: 1087-1090, 2001
- Furushima H, Chinushi M, Sanada A, Aizawa Y. Ventricular repolarization gradients in a patient with takotsubo cardiomyopathy. *Europace* 10: 1112-1115, 2008
- Ghosh S, Apte P, Maroz N, Broor A, Zeineh N, Khan IA. Takotsubo cardiomyopathy as a potential cause of long QT syndrome and torsades de pointes. *Int J Cardiol* 136: 225-227, 2009
- Hinojosa-Laborde C, Chapa I, Lange D, Haywood JR. Gender differences in sympathetic nervous system regulation. *Clin Exp Pharmacol Physiol* 26:122-126, 1999
- Hirose K, Yamaguchi H, Oshima Y, Choraku M, Hirono A, Takamori N, Tamura K. Severe respiratory failure and torsades de pointes induced by disopyramide in a patient with myasthenia gravis. *Intern Med* 47: 1703-1708, 2008
- Inoue M, Kanaya H, Matsubara T, Uno Y, Yasuda T, Miwa K. Complete atrioventricular block associated with takotsubo cardiomyopathy. *Circ J* 73: 589-592, 2009
- Kawai S, Kitabatake A, Tomoike H; Takotsubo Cardiomyopathy Group. Guidelines for diagnosis of takotsubo (ampulla) cardiomyopathy. *Circ J*.71:990-2, 2007
- Kawano H, Matsumoto Y, Arakawa S, Satoh O, Hayano M. Premature atrial contraction induces torsades de pointes in a patient of Takotsubo cardiomyopathy with QT prolongation. *Intern Med*. 49:1767-73, 2010
- Kurisu S, Sato H, Kawagoe T, Ishihara M, Shimatani Y, Nishioka K, Kano Y, Umemura T, Nakamura S. Tako-tsubo-like left ventricular dysfunction with ST-segment elevation: a novel cardiac syndrome mimicking acute myocardial infarction. *Am Heart J* 143: 448-455, 2002
- Left ventricular apical thrombus formation in a patient with suspected tako-tsubo-like left ventricular dysfunction.
- Kurisu S, Inoue I, Kawagoe T, Ishihara M, Shimatani Y, Nishioka K, Umemura T, Nakamura S, Yoshida M, Sato H. *Circ J* 67: 556-558, 2003

- Kurisu S, Inoue I, Kawagoe T, Ishihara M, Shimatani Y, Nakama Y, Ohkawa K, Maruhashi T, Kagawa E, Dai K, Aoyagi T. Torsade de pointes associated with bradycardia and takotsubo cardiomyopathy. *Can J Cardiol* 24:640-642, 2008
- Kurokawa J, Suzuki T, Furukawa T. New aspects for the treatment of cardiac diseases based on the diversity of functional controls on cardiac muscles: acute effects of female hormones on cardiac ion channels and cardiac repolarization. *J Pharmacol Sci* 109:334-340, 2009
- Lambert G, Naredi S, Edén E, Rydenhag B, Friberg P. Monoamine metabolism and sympathetic nervous activation following subarachnoid haemorrhage: influence of gender and hydrocephalus. *Brain Res Bull* 58:77-82, 2002
- Locati EH, Maison-Blanche P, Dejode P, Cauchemez B, Coumel P. Spontaneous sequences of onset of torsade de pointes in patients with acquired prolonged repolarization: quantitative analysis of Holter recordings. *J Am Coll Cardiol* 25 :1564-75, 1995
- Mahida S, Dalageorgou C, Behr ER. Long-QT syndrome and torsades de pointes in a patient with Takotsubo cardiomyopathy: an unusual case. *Europace* 11: 376-378, 2009
- Matsuoka K, Okubo S, Fujii E, Uchida F, Kasai A, Aoki T, Makino K, Omichi C, Fujimoto N, Ohta S, Sawai T, Nakano T. Evaluation of the arrhythmogenicity of stress-induced "Takotsubo cardiomyopathy" from the time course of the 12-lead surface electrocardiogram. *Am J Cardiol* 92:230-233, 2003
- Moss AJ, Schwartz PJ, Crampton RS, Locati E, Carleen E. The long QT syndrome: a prospective international study, *Circulation* 71: 17-21, 1985
- Nault MA, Baranchuk A, Simpson CS, Redfearn DP. Takotsubo cardiomyopathy: a novel "proarrhythmic" disease-case report. *Anadolu Kardiyol Derg* 7(suppl 1): 101-103, 2007
- Nef HM, Möllmann H, Kostin S, Troidl C, Voss S, Weber M, Dill T, Rolf A, Brandt R, Hamm CW, Elsässer A. Tako-Tsubo cardiomyopathy: intraindividual structural analysis in the acute phase and after functional recovery. *Eur Heart J* 28: 2456-2464, 2007
- Okada T, Miyata S, Hashimoto K, Maie K, Mochizuki S. Takotsubo cardiomyopathy associated with torsades de pointes and long QT interval: a case report . *J Cardiol* 50 :83-88, 2007 [in Japanese]
- Patel HM, Kantharia BK, Morris DL, Yazdanfar S. Takotsubo syndrome in African-American women with atypical presentation: a single-center experience. *Clin Cardiol* 30: 14-18, 2007
- Purvis JA, Cunningham EL, McGlinchey PG, Barr SH. Drugs, electrolytes and tako-tsubo cardiomyopathy: triple aetiology of acquired long QT syndrome and torsades de pointes. *Ulster Med J*. 2009 Sep;78(3):188-9.
- Sader MA, Celermajer DS. Endothelial function, vascular reactivity and gender differences in the cardiovascular system. *Cardiovasc Res* 53:597-604, 2002
- Samuelov-Kinori L, Kinori M, Kogan Y, Swartzon M, Shalev H, Guy D, Ferenidou F, Mashav N, Sadeh B, Atzmony L, Kliuk-Ben-Basat O, Steinvil A, Justo D. Takotsubo cardiomyopathy and QT interval prolongation: who are the patients at risk for torsades de pointes? *J Electrocardiol*. 42:353-357, 2009
- Sansen V, Holvoet G. Takotsubo cardiomyopathy presenting as multivessel coronary spasm syndrome: case report and review of the literature. *Acta Cardiol* 62:507-11, 2007

- Sasaki O, Nishioka T, Akima T, Tabata H, Okamoto Y, Akanuma M, Uehata A, Takase B, Katsushika S, Isojima K, Ohtomi S, Yoshimoto N. Association of takotsubo cardiomyopathy and long QT syndrome. *Circ J* 70:1220-2, 2006
- Taddei S, Virdis A, Ghiadoni L, Mattei P, Sudano I, Bernini G, Pinto S, Salvetti A. Menopause is associated with endothelial dysfunction in women. *Hypertension* 28:576-582, 1996
- Tsuchihashi K, Ueshima K, Uchida T, Oh-mura N, Kimura K, Owa M, Yoshimura M, Miyazaki S, Haze K, Ogawa H, Honda T, Hase M, Kai R, Morii I; Angina Pectoris-Myocardial Infarction Investigation in Japan. Transient left ventricular apical ballooning without coronary artery stenosis: a novel heart syndrome mimicking acute myocardial infarction. *Angina Pectoris-Myocardial Infarction Investigations in Japan . J Am Coll Cardiol* 38: 11-18, 2001
- Yamada Y, Tani T, Homma M, Saito S. Two cases of torsades de pointes associated with takotsubo cardiomyopathy as the second insult. *J Electrocardiol.* 2011 [Epub ahead of print]

IntechOpen



Cardiomyopathies - From Basic Research to Clinical Management

Edited by Prof. Josef Veselka

ISBN 978-953-307-834-2

Hard cover, 800 pages

Publisher InTech

Published online 15, February, 2012

Published in print edition February, 2012

Cardiomyopathy means "heart (cardio) muscle (myo) disease (pathy)". Currently, cardiomyopathies are defined as myocardial disorders in which the heart muscle is structurally and/or functionally abnormal in the absence of a coronary artery disease, hypertension, valvular heart disease or congenital heart disease sufficient to cause the observed myocardial abnormalities. This book provides a comprehensive, state-of-the-art review of the current knowledge of cardiomyopathies. Instead of following the classic interdisciplinary division, the entire cardiovascular system is presented as a functional unity, and the contributors explore pathophysiological mechanisms from different perspectives, including genetics, molecular biology, electrophysiology, invasive and non-invasive cardiology, imaging methods and surgery. In order to provide a balanced medical view, this book was edited by a clinical cardiologist.

How to reference

In order to correctly reference this scholarly work, feel free to copy and paste the following:

Hiroaki Kawano (2012). Torsades de Pointes in Takotsubo Cardiomyopathy with QT Prolongation, *Cardiomyopathies - From Basic Research to Clinical Management*, Prof. Josef Veselka (Ed.), ISBN: 978-953-307-834-2, InTech, Available from: <http://www.intechopen.com/books/cardiomyopathies-from-basic-research-to-clinical-management/torsades-de-pointes-in-takotsubo-cardiomyopathy-with-qt-prolongation>

INTECH
open science | open minds

InTech Europe

University Campus STeP Ri
Slavka Krautzeka 83/A
51000 Rijeka, Croatia
Phone: +385 (51) 770 447
Fax: +385 (51) 686 166
www.intechopen.com

InTech China

Unit 405, Office Block, Hotel Equatorial Shanghai
No.65, Yan An Road (West), Shanghai, 200040, China
中国上海市延安西路65号上海国际贵都大饭店办公楼405单元
Phone: +86-21-62489820
Fax: +86-21-62489821

© 2012 The Author(s). Licensee IntechOpen. This is an open access article distributed under the terms of the [Creative Commons Attribution 3.0 License](https://creativecommons.org/licenses/by/3.0/), which permits unrestricted use, distribution, and reproduction in any medium, provided the original work is properly cited.

IntechOpen

IntechOpen