

We are IntechOpen, the world's leading publisher of Open Access books Built by scientists, for scientists

6,900

Open access books available

186,000

International authors and editors

200M

Downloads

Our authors are among the

154

Countries delivered to

TOP 1%

most cited scientists

12.2%

Contributors from top 500 universities



WEB OF SCIENCE™

Selection of our books indexed in the Book Citation Index
in Web of Science™ Core Collection (BKCI)

Interested in publishing with us?
Contact book.department@intechopen.com

Numbers displayed above are based on latest data collected.
For more information visit www.intechopen.com



Classification and Definitions of Cardiomyopathies

Bhulan Kumar Singh¹, Krishna Kolappa Pillai¹,
Kanchan Kohli² and Syed Ehtaishamul Haque¹

¹*Department of Pharmacology, Faculty of Pharmacy, Hamdard University, New Delhi*

²*Department of Pharmaceutics, Faculty of Pharmacy, Hamdard University, New Delhi, India*

1. Introduction

Cardiomyopathies are an important and heterogeneous group of diseases. The awareness and knowledge of these diseases in both the public and medical communities historically has been impaired by persistent confusion surrounding definitions and nomenclature. Classification schemes, of which there have been many, (Thiene et al., 2000, 2004; Richardson et al., 1996) are potentially useful in drawing relationships and distinctions between complex disease states for the purpose of promoting greater understanding; indeed, the precise language used to describe these diseases are profoundly important.

Cardiomyopathies are diseases of the heart muscle, characterized by abnormality in chamber size and wall thickness, or functional contractile dysfunctions mainly systolic or diastolic dysfunction in the absence of coronary artery disease, hypertension, valvular disease, or congenital heart disease (Elliott et al., 2008). These diseases are classified as either primary or secondary. Primary cardiomyopathies consist of disorders solely or predominantly confined to the heart muscle, which have genetic, non-genetic, or acquired causes. Secondary cardiomyopathies are disorders that have myocardial damage as a result of systemic or multiorgan disease (Maron et al., 2006). Cardiomyopathies are classified traditionally according to morphological and functional criteria into four categories: dilated cardiomyopathy (DCM), hypertrophic cardiomyopathy (HCM), restrictive cardiomyopathy (RCM) and arrhythmogenic right ventricular cardiomyopathy/dysplasia (ARVC/D). These cardiomyopathies can be primary myocardial disorders or develop as a secondary consequence of a variety of conditions, including myocardial ischemia, inflammation, infection, increased myocardial pressure or volume load and toxic agents.

The definitions of cardiomyopathies presented here are in concert with the molecular era of cardiovascular disease and have direct clinical applications and implications for cardiac diagnosis. However, the classification of cardiomyopathies presented herein is not intended to provide precise methodologies or strategies for clinical diagnosis. Rather, the classification of cardiomyopathies represents a scientific presentation that offers new perspectives to aid in understanding this complex and heterogeneous group of diseases and basic disease mechanisms.

2. Definition

The term cardiomyopathy was used for the first time in 1957. Over the next 25 years, a number of definitions for cardiomyopathies were advanced. Indeed, in the original 1980 WHO classification, cardiomyopathies were defined only as “heart muscle diseases of unknown cause,” reflecting a general lack of available information about basic disease mechanisms. In 1968, the WHO defined cardiomyopathies as “diseases of different and often unknown etiology in which the dominant feature is cardiomegaly and heart failure.” The final WHO classification published in 1995 proposed “diseases of myocardium associated with cardiac dysfunction” and included for the first time ARVC/D, as well as primary RCM.

The American Heart Association (AHA) expert consensus panel proposed definition of cardiomyopathies is as follows: “Cardiomyopathies are a heterogeneous group of diseases of the myocardium associated with mechanical and/or electrical dysfunction, which usually (but not invariably) exhibit inappropriate ventricular hypertrophy or dilatation, due to a variety of etiologies that frequently are genetic. Cardiomyopathies are either confined to the heart or are part of generalized systemic disorders, and often lead to cardiovascular death or progressive heart failure-related disability.” This definition of cardiomyopathies, similar to that reported by the European Society of Cardiology (ESC), under the auspices of the Working Group on Myocardial and Pericardial Diseases, excludes myocardial involvement secondary to coronary artery disease, systemic hypertension, and valvular and congenital heart disease.

3. Classifications of cardiomyopathies

Cardiac diseases can have an external cause, such as coronary artery disease, valve disease or hypertension, or may involve cardiomyopathies, in which the heart muscle itself is abnormal (i.e. an intrinsic cause of the disease is present in the heart muscle). The distinction between different classes of cardiac diseases are an important one to make, as cardiac diseases with similar phenotypes can have a diverse origin and may need different types of management. However, classification of cardiomyopathies is difficult, as the origin or pathophysiology is not always understood. Furthermore, at present there is no consensus on how to classify cardiomyopathies (e.g., based on origin, physiology or treatment) among clinicians.

In order to promote a uniform nomenclature and well-defined clinical patient groups, recent knowledge on underlying causes and pathophysiology of cardiomyopathies has been implemented in a cardiomyopathy classification system both on behalf of the American Heart Association (AHA) and of the European Society of Cardiology (ESC).

The AHA divided cardiomyopathies into 2 major groups based on predominant organ involvement. Primary cardiomyopathies (genetic, nongenetic, acquired) are those solely or predominantly confined to heart muscle and are relatively few in number (Fig. 1). Secondary cardiomyopathies show pathological myocardial involvement as part of a large number and variety of generalized systemic (multiorgan) disorders (Table 1). The frequency and degree of secondary myocardial involvement vary considerably among these diseases, some of which are exceedingly uncommon and for which the evidence of myocardial pathology may be sparse and reported in only a few patients. Because many cardiomyopathies may predominantly involve the heart but are not necessarily confined to that organ, some of the distinctions between primary and secondary cardiomyopathy are necessarily arbitrary and inevitably rely on judgment about the clinical importance and consequences of the myocardial process (Maron, 2008; Maron et al., 2006).

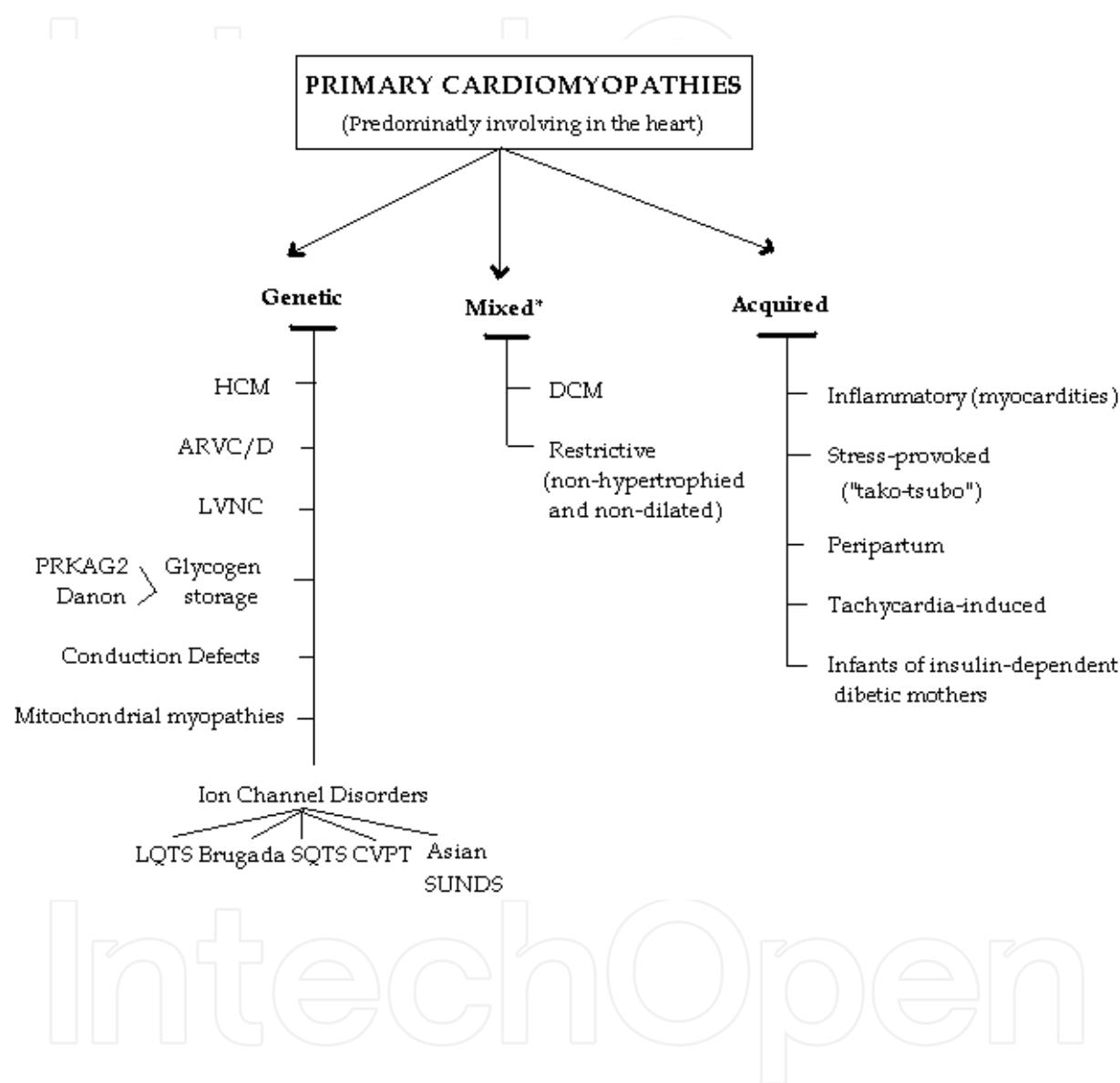


Fig. 1. Classification model for Primary cardiomyopathies (disease processes solely or predominantly involves the myocardium). The conditions have been segregated according to their genetic or nongenetic etiologies. *Predominantly nongenetic; familial disease with a genetic origin has been reported in a minority of cases. ARVC/D indicates arrhythmogenic right ventricular cardiomyopathy/ dysplasia; CPVT, catecholaminergic polymorphic ventricular tachycardia; DCM, dilated cardiomyopathy; HCM, hypertrophic cardiomyopathy; LQTS, long QT syndrome; LVNC, left ventricular noncompaction; SQTs, short QT syndrome; and SUNDS, sudden unexplained nocturnal death syndrome.

Infiltrative*	Amyloidosis (primary, familial autosomal dominant†, senile, secondary forms)
	Gaucher disease†
	Hurler’s disease†
	Hunter’s disease†
Storage‡	Hemochromatosis
	Fabry’s disease†
	Glycogen storage disease† (type II, Pompe)
	Niemann-Pick disease†
Toxicity	Drugs, heavy metals, chemical agents
Endomyocardial	Endomyocardial fibrosis
	Hypereosinophilic syndrome (Löeffler’s endocarditis)
Inflammatory (granulomatous)	Sarcoidosis
Endocrine	Diabetes mellitus†
	Hyperthyroidism
	Hypothyroidism
	Hyperparathyroidism
	Pheochromocytoma
	Acromegaly
Cardiofacial	Noonan syndromet
	Lentiginosist
Neuromuscular/neurological	Friedreich’s ataxiat
	Duchenne-Becker muscular dystrophy†
	Emery-Dreifuss muscular dystrophy†
	Myotonic dystrophy†
	Neurofibromatosis†
	Tuberous sclerosis†
Nutritional deficiencies	Beriberi (thiamine), pella, scurvy, selenium, carnitine, kwashiorkor
Autoimmune/collagen	Systemic lupus erythematosist
	Dermatomyositis
	Rheumatoid arthritis
	Scleroderma
	Polyarteritis nodosa
Electrolyte imbalance	
Consequence of cancer therapy	Anthracyclines: doxorubicin (adriamycin), daunorubicin
	Cyclophosphamide
	Radiation

*Accumulation of abnormal substances between myocytes (i.e., extracellular).

†Genetic (familial) origin.

‡Accumulation of abnormal substances within myocytes (i.e., intracellular).

Table 1. Important secondary cardiomyopathies

The ESC guidelines are more clinically orientated, which is appealing as this circumvents the complex pathophysiology of cardiomyopathies, which is not always comprehended upon presentation of the patient. According to the ESC guidelines cardiomyopathies are grouped into specific morphological and functional phenotypes; each phenotype is then sub-classified into familial and non-familial forms (Fig. 2). In this context, familial refers to the occurrence, in more than one family member, of either the same disorder or a phenotype that is (or could be) caused by the same genetic mutation and not to acquired cardiac or systemic diseases in which the clinical phenotype is influenced by genetic polymorphism. Most familial cardiomyopathies are monogenic disorders (i.e., the gene defect is sufficient by itself to cause the trait). A monogenic cardiomyopathy can be sporadic when the causative mutation is de novo, i.e. has occurred in an individual for the first time within the family (or at the germinal level in one of the parents). In this classification system, patients with identified de novo mutations are assigned to the familial category as their disorder can be subsequently transmitted to their offspring (Elliott et al., 2008). Non-familial cardiomyopathies are clinically defined by the presence of a cardiomyopathy in the index patient and the absence of disease in other family members (based on pedigree analysis and clinical evaluation). They are subdivided into idiopathic (no identifiable cause) and acquired cardiomyopathies in which ventricular dysfunction is a complication of the disorder rather than an intrinsic feature of the disease (Elliott et al., 2008).

Therefore, on the basis of all these considerations, cardiomyopathies can be most effectively classified as primary: genetic, mixed (genetic and nongenetic), acquired; and secondary.

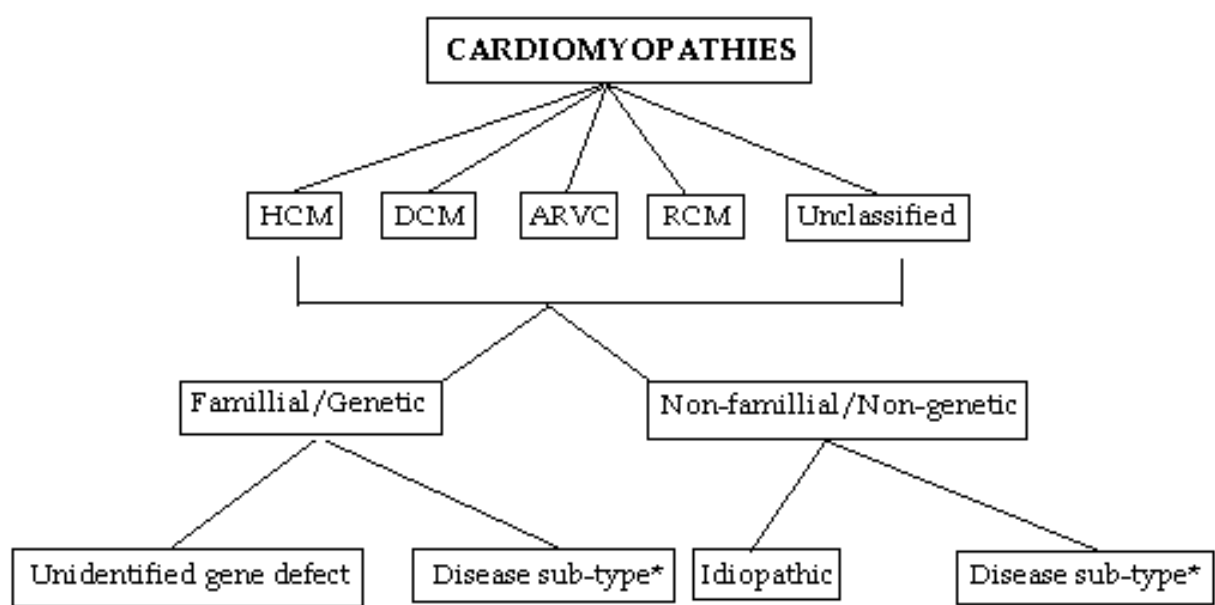


Fig. 2. Summery of proposed classification. HCM, hypertrophic cardiomyopathy; DCM, dilated cardiomyopathy; ARVC, arrhythmogenic right ventricular cardiomyopathy; RCM, restrictive cardiomyopathy (*see table 2).

	HCM	DCM	ARVC	RCM	Unclassified
Familial	Familial, unknown gene Sarcomeric protein mutations β-myosin heavy chain Cardiac myosin binding protein C Cardiac troponin I Troponin T α-tropomyosin Essential myosin light chain Regulatory myosin light chain Cardiac actin α-myosin heavy chain Titin Troponin C Muscle LIM protein Glycogen storage disease (e.g. Pompe; PKAG2, Forbes', Danon) Lysosomal storage diseases (e.g. Anderson–Fabry, Hurler's) Disorders of fatty acid metabolism Carnitine deficiency Phosphorylase B kinase deficiency Mitochondrial cytopathies Syndromic HCM Noonan's syndrome LEOPARD syndrome Friedreich's ataxia Beckwith–Wiedemann syndrome Swyer's syndrome Other Phospholamban promoter Familial amyloid	Familial, unknown gene Sarcomeric protein mutations (see HCM) Z-band Muscle LIM protein TCAP Cytoskeletal genes Dystrophin Desmin Metavinculin Sarcoglycan complex CRYAB Epicardin Nuclear membrane Lamin A/C Emerin Mildly dilated CM Intercalated disc protein mutations (see ARVC) Mitochondrial cytopathy	Familial, unknown gene Intercalated disc protein mutations Plakoglobin Desmoplakin Plakophilin 2 Desmoglein 2 Desmocollin 2 Cardiac ryanodine receptor (RyR2) Transforming growth factor-β3 (TGFβ3)	Familial, unknown gene Sarcomeric protein mutations Troponin I (RCM +/- HCM) Essential light chain of myosin Familial amyloidosis Transthyretin (RCM + neuropathy) Apolipoprotein (RCM + nephropathy) Desminopathy Pseudoxanthoma elasticum Haemochromatosis Anderson–Fabry disease Glycogen storage disease	Left ventricular non-compaction Barth syndrome Lamin A/C ZASP α-dystrobrevin
Non-familial	Obesity Infants of diabetic mothers Athletic training Amyloid (AL/prealbumin)	Myocarditis (infective/toxic/immune) Kawasaki disease Eosinophilic (Churg Strauss syndrome) Viral persistence Drugs Pregnancy Endocrine Nutritional – thiamine, carnitine, selenium, hypophosphataemia, hypocalcaemia Alcohol Tachycardiomyopathy	Inflammation	Amyloid (AL/prealbumin) Scleroderma Endomyocardial fibrosis Hypereosinophilic syndrome Idiopathic Chromosomal cause Drugs (serotonin, methysergide, ergotamine, mercurial agents, busulfan) Carcinoid heart disease Metastatic cancers Radiation Drugs (anthracyclines)	Tako Tsubo cardiomyopathy

ARVC, arrhythmogenic right ventricular cardiomyopathy; DCM, dilated cardiomyopathy; HCM, hypertrophic cardiomyopathy; RCM, restrictive cardiomyopathy.

Table 2. Examples of different diseases that cause cardiomyopathies

3.1. Primary cardiomyopathies

3.1.1 Genetic

3.1.1.1 Hypertrophic cardiomyopathy

HCM is a condition of the heart in which a part of the myocardium or the muscle of the heart is enlarged without any obvious reasons. It is very common and affects people of all ages. HCM is a clinically heterogeneous but relatively common autosomal dominant genetic heart disease (1:500 of the general population for the disease phenotype recognized by echocardiography) that probably is the most frequently occurring cardiomyopathy (Maron, 2002). It is the most common cause of sudden cardiac death in the young (including trained athletes) and is an important substrate for heart failure disability at any age.

HCM is characterized morphologically and defined by a hypertrophied, nondilated left ventricle (LV) in the absence of another systemic or cardiac disease that is capable of producing the magnitude of wall thickening evident (e.g., systemic hypertension, aortic valve stenosis). Clinical diagnosis is customarily made with 2 dimensional echocardiography (or alternatively with cardiac magnetic resonance imaging) by detection of otherwise unexplained LV wall thickening, usually in the presence of a small LV cavity, after suspicion is raised by the clinical profile or as part of family screening (Maron et al., 2006).

When LV wall thickness is mild, differential diagnosis with physiological athlete's heart may arise. Furthermore, individuals harboring a genetic defect for HCM do not necessarily express clinical markers of their disease such as LV hypertrophy on echocardiogram, ECG abnormalities, or symptoms at all times during life, and ECG alterations can precede the appearance of hypertrophy. Indeed, virtually any LV wall thickness, even when within normal limits, is consistent with the presence of an HCM-causing mutant gene, and diagnosis can be made by laboratory DNA analysis. Furthermore, recognition of LV hypertrophy may be age related with its initial appearance delayed well into adulthood (adult morphological conversion). Most HCM patients have the propensity to develop dynamic obstruction to LV outflow under resting or physiologically provokable conditions, produced by systolic anterior motion of the mitral valve with ventricular septal contact (Maron et al., 2006).

HCM is caused by a variety of mutations encoding contractile proteins of the cardiac sarcomere. Currently, 11 mutant genes are associated with HCM, most commonly β -myosin heavy chain (the first identified) and myosin binding protein C (Barry et al., 2008; Lowey, 2002). The other 9 genes appear to account for far fewer cases of HCM and include troponin T and I, regulatory and essential myosin light chains, titin, α -tropomyosin, α -actin, α -myosin heavy chain, and muscle LIM protein (Barry et al., 2008; Selvetella & Lembo, 2005). This genetic diversity is compounded by considerable intragenic heterogeneity, with >400 individual mutations now identified. These most commonly are missense mutations but include insertions, deletions, and splice (split-site) mutations encoding truncated sarcomeric proteins (Maron et al., 2006). The characteristic diversity of the HCM phenotype is attributable to the disease causing mutations and probably to the influence of modifier genes and environmental factors.

In addition, nonsarcomeric protein mutations in 2 genes involved in cardiac metabolism have recently been reported to be responsible for primary cardiac glycogen storage diseases in older children and adults with a clinical presentation mimicking (or indistinguishable

from) that of sarcomeric HCM. One of these conditions involves the gene encoding the γ -2-regulatory subunit of the AMP-activated protein kinase (PRKAG2), associated with variable degrees of LV hypertrophy and ventricular pre-excitation. The other involves the gene encoding lysosome-associated membrane protein-2 (LAMP-2), resulting in Danon-type storage disease (Maron et al., 2006). Clinical manifestations are limited largely to the heart, usually with massive degrees of LV hypertrophy and ventricular pre-excitation. These disorders are now part of a subgroup of previously described infiltrative forms of LV hypertrophy such as Pompe disease, a glycogen storage disease caused by α -1,4 glycosidase (acid maltase deficiency) in infants, and Fabry's disease, an X-linked recessive disorder of glycosphingolipid metabolism caused by a deficiency of the lysosomal enzyme α -galactosidase A, resulting in intracellular accumulation of glycosphingolipids. Undoubtedly, many other mutations causing cardiac hypertrophy by disrupting sarcomere, metabolic, and other genes remain to be identified (Elliott et al., 2008).

A number of other diseases associated with LV hypertrophy involve prominent thickening of the LV wall, occurring mostly in infants and children ≤ 4 years of age, which may resemble or mimic typical HCM caused by sarcomere protein mutations. These cardiomyopathies include secondary forms such as Noonan syndrome, an autosomal dominant cardiofacial condition associated with a variety of cardiac defects (most commonly, dysplastic pulmonary valve stenosis and atrial septal defect) resulting from mutations in PTPN11, a gene encoding the nonreceptor protein tyrosine phosphatase SHP-2 genes. At present, the causes of most cases of pediatric cardiomyopathies are unknown (Maron et al., 2006).

Other diseases in this category are mitochondrial myopathies resulting from mutations encoding mitochondrial DNA (including Kearns-Sayre syndrome) or mitochondrial proteins associated with ATP electron transport chain enzyme defects that alter mitochondrial morphology. Also included in these considerations are metabolic myopathies representing ATP production and utilization defects involving abnormalities of fatty acid oxidation (acyl CoA dehydrogenase deficiencies) and carnitine deficiency, as well as infiltrative myopathies, i.e., glycogen storage diseases (type II; autosomal recessive Pompe disease), Hunter's and Hurler's diseases, and the transient and nonfamilial cardiomyopathy as part of generalized organomegaly, recognized in infants of insulin-dependent diabetic mothers. In older patients, a number of systemic diseases have been associated with hypertrophic forms of cardiomyopathy; these include Friedreich's ataxia, pheochromocytoma, neurofibromatosis, lentiginosis, and tuberous sclerosis.

3.1.1.2 Arrhythmogenic right ventricular cardiomyopathy/dysplasia

ARVC/D is predominantly a genetically determined heart muscle disorder that is characterized pathologically by fibrofatty replacement of the right ventricular (RV) myocardium (Basso et al., 2009). In the early stage of the disease, structural changes may be absent or subtle and confined to a localized region of the RV, typically the inflow tract, outflow tract, or apex of the RV, the "triangle of dysplasia." Progression to more diffuse RV disease and left ventricular (LV) involvement, typically affecting the posterior lateral wall, is common (Marcus et al., 2010).

ARVC/D is a familial disease in at least 50% of cases and is typically transmitted as an autosomal dominant trait with variable penetrance. On the basis of clinical studies and data obtained from pre-participation screening for sport activity, the estimated prevalence of the disease in the general population ranges from 1 in 1000 to 1 in 5000 (Nava et al., 2000).

ARVC/D has a broad clinical spectrum, usually presenting clinically with ventricular tachyarrhythmias (e.g., monomorphic ventricular tachycardia). Noninvasive clinical diagnosis may be confounding, without an easily obtained single test or finding that is definitively diagnostic, and generally requires an integrated assessment of electrical, functional, and anatomic abnormalities. Diagnosis often requires a high index of suspicion, frequently triggered by presentation with arrhythmias, syncope, or cardiac arrest, as well as global or segmental chamber dilatation or wall motion abnormalities (Marcus et al., 2010).

Noninvasive tests used to diagnose ARVC/D, in addition to personal and family history, include 12-lead ECG, echocardiography, right ventricular angiography, cardiac magnetic resonance imaging, and computerized tomography. Endomyocardial biopsy from the right ventricular free wall is a sensitive diagnostic marker when fibrofatty infiltration is associated with surviving strands of myocytes. ECGs most commonly show abnormal repolarization with T-wave inversion in leads V_1 through V_3 and small-amplitude potentials at the end of the QRS complex (epsilon wave); Brugada syndrome-like right bundle-branch block and right precordial ST-segment elevation accompanied by polymorphic ventricular tachycardia also have been reported in a small subpopulation of ARVC/D patients (Basso et al., 2009; Protonotarios et al., 2011).

ARVC/D shows autosomal dominant inheritance, albeit often with incomplete penetrance. Autosomal dominant ARVC/D has been mapped to 8 chromosomal loci, with mutations identified thus far in 4 genes: the cardiac ryanodine receptor RyR2, which is also responsible for familial catecholaminergic polymorphic ventricular tachycardia (CPVT); desmoplakin; plakophilin-2; and mutations altering regulatory sequences of the transforming growth factor- β gene, which has a role in inflammation. Two recessive forms have been described in conjunction with palmoplantar keratoderma and woolly hair (Naxos disease) and with Carvajal syndrome, caused by mutations in junctional plakoglobin and desmoplakin, respectively. Although the function of desmosomal proteins to anchor intermediate filaments to desmosomes implicates ARVC/D as a primary structural abnormality, there is also a link to ion channel dysfunction (Maron et al., 2006).

3.1.1.3 Left ventricular noncompaction

Noncompaction of ventricular myocardium is a recently recognized congenital cardiomyopathy characterized by a distinctive (“spongy”) morphological appearance of the LV myocardium. Noncompaction involves predominantly the distal (apical) portion of the LV chamber with deep intertrabecular recesses (sinusoids) in communication with the ventricular cavity, resulting from an arrest in the normal embryogenesis (Freedom et al., 2005). LV noncompaction (LVNC) may be an isolated finding or may be associated with other congenital heart anomalies such as complex cyanotic congenital heart disease.

Diagnosis is made with 2-dimensional echocardiography, cardiac magnetic resonance imaging, or LV angiography (Chin et al., 1990). The natural history of LVNC is largely unresolved but includes LV systolic dysfunction and heart failure (and some cases of heart transplantation), thromboemboli, arrhythmias, sudden death, and diverse forms of remodeling. Both familial and nonfamilial cases have been described. In the isolated form of LVNC, ZASP (Z-line) and mitochondrial mutations, and X-linked inheritance resulting from mutations in the G4.5 gene encoding tafazzin (including association with Barth syndrome in

neonates) have been reported. Noncompaction associated with congenital heart disease has been shown to result from mutations in the α -dystrobrevin gene and transcription factor NKX2.5 (Monserrat Iglesias, 2008).

3.1.1.4 Conduction system disease

Lenegre disease, also called as progressive cardiac conduction defect. It is characterized by primary progressive development of cardiac conduction defects in the His-Purkinje system, leading to widening of the QRS complex, long pauses, and bradycardia that may trigger syncope. Phenotypically sick sinus syndrome is similar to progressive cardiac conduction defect. Familial occurrence of both syndromes has been reported with an autosomal dominant pattern of inheritance. An ion channelopathy, in the form of SCN5A mutations, is thought to contribute to these conduction system defects. Wolff-Parkinson-White syndrome is familial in some cases, but information about the genetic causes is unavailable.

3.1.1.5 Ion channelopathies

There is a growing list of uncommon inherited and congenital arrhythmia disorders caused by mutations in genes encoding defective ionic channel proteins, governing cell membrane transit of sodium and potassium ions (Aleong et al., 2007). These ion channel disorders include LQTS, short-QT syndrome (SQTS), Brugada syndrome, and CPVT. Nocturnal sudden unexplained death syndrome in young Southeast Asian males and Brugada syndrome are based on similar clinical and genetic profiles. A small proportion (5% to 10%) of sudden infant deaths also may be linked to ion channelopathies, including LQTS, SQTS, and Brugada syndrome (Modell & Lehmann, 2006). Clinical diagnosis of the ion channelopathies often can be made by identification of the disease phenotype on standard 12-lead ECG. Some of these cases had previously been classified as idiopathic ventricular fibrillation, a description that persists for a syndrome in which mechanistic understanding is lacking (Aleong et al., 2007; Kass, 2005).

3.1.1.5.1 Long-QT syndrome

This is the most common condition of the ion channelopathies. It is characterized by prolongation of ventricular repolarization and QT interval (corrected for heart rate) on the standard 12-lead ECG, a specific form of polymorphic ventricular tachycardia (torsade des pointes), and a risk for syncope and sudden cardiac death. Phenotypic expression (on the ECG) varies considerably, and ~25% to 50% of affected family members may show borderline or even normal QT intervals.

Two patterns of inheritance have been described in LQTS: a rare autosomal recessive disease associated with deafness (Jervell and Lange-Nielsen syndrome), which is caused by 2 genes that encode for the slowly activating delayed rectifier potassium channel (KCNQ1 and KCNE1 (minK)), and the much more common autosomal dominant disease unassociated with deafness (Romano-Ward syndrome), which is caused by mutations in 8 different genes. These include KCNQ1 (KvLQT1, LQT1), KCNH2 (HERG, LQT2), SCN5A (Na1.5, LQT3), ANKB (LQT4), KCNE1 (minK, LQT5), KCNE2 (MiRP1, LQT6), KCNJ2 (Kir2.1, LQT7, Andersen's syndrome), and CACNA1C (Ca1.2, LQT8, Timothy syndrome). Of the 8 genes, 6 encode for cardiac potassium channels, 1 for the sodium channel (SCN5A, LQT3), and 1 for the protein ankyrin, which is involved in anchoring ion channels to the cellular membrane (ANKB) (Maron et al., 2006).

3.1.1.5.2 Brugada syndrome

This syndrome is a relatively new clinical entity associated with sudden cardiac death in young people. First described in 1992, the syndrome is identified by a distinctive ECG pattern consisting of right bundle-branch block and coved ST-segment elevation in the anterior pre-cordial leads (V₁ through V₃). The characteristic ECG pattern is often concealed and may be unmasked with the administration of sodium channel blockers, including ajmaline, flecainide, procainamide, and pilsicainide. Familial autosomal dominant and sporadic forms have been linked to mutations in an α -subunit of the cardiac sodium channel gene SCN5A (the same gene responsible for LQT3) in 20% of patients. Another locus has been reported on the short arm of chromosome 3, but no gene has been identified. Sudden unexplained nocturnal death syndrome, found predominantly in young Southeast Asian males (i.e., those from Thailand, Japan, the Philippines, and Cambodia), is a disorder causing sudden death during sleep as a result of ventricular tachycardia/fibrillation. Some cases of sudden unexplained nocturnal death syndrome resulting from SCN5A gene mutations and Brugada syndrome have been shown to be phenotypically, genetically, and functionally the same disorder (Antzelevitch et al., 2005; Krittayaphong et al., 2003).

3.1.1.5.3 Catecholaminergic polymorphic ventricular tachycardia

CPVT is characterized by syncope, sudden death, polymorphic ventricular tachycardia triggered by vigorous physical exertion or acute emotion (usually in children and adolescents), a normal resting ECG, and the absence of structural cardiac disease. Family history of 1 or multiple sudden cardiac deaths are evident in 30% of cases. The resting ECG is unremarkable, except for sinus bradycardia and prominent U waves in some patients. The most typical arrhythmia of CPVT is bidirectional ventricular tachycardia presenting with an alternating QRS axis. The autosomal dominant form of the disease has been linked to the RyR2 gene encoding for the cardiac ryanodine receptor, a large protein that forms the Ca²⁺ release channel in the sarcoplasmic reticulum that is essential for regulation of excitation-contraction coupling and [Ca²⁺]_{li} levels. An autosomal recessive form has been linked to CASQ2, a gene that encodes for calsequestrin, a protein that serves as a major Ca²⁺-binding protein in the terminal cisternae of the sarcoplasmic reticulum. Calsequestrin is bound to the ryanodine receptor and participates in the control of excitation-contraction coupling (Wilde et al., 2008).

3.1.1.5.4 Short-QT syndrome

First described in 2000, the SQTS is characterized by a short QT interval (<330 ms) on an ECG and a high incidence of sudden cardiac death resulting from ventricular tachycardia/fibrillation. Another distinctive ECG feature of SQTS is the appearance of tall peaked T waves similar to those encountered with hyperkalemia. The syndrome has been linked to gain-of-function mutations in KCNH2 (HERG, SQT1), KCNQ1 (KvLQT1, SQT2), and KCNJ2 (Kir2.1, SQT3), causing an increase in the intensity of I_{kr}, I_{ks} and I_{kl}, respectively (Gaita et al., 2003; Schimpf et al., 2005).

3.1.1.5.5 Idiopathic ventricular fibrillation

A subgroup of patients with sudden death appears in the literature with the designation of idiopathic ventricular fibrillation. However, it is likely that idiopathic ventricular fibrillation is not an independent disease entity but rather a conglomeration of conditions with normal gross and microscopic findings in which arrhythmic risk undoubtedly derives from

molecular abnormalities, most likely ion channel mutations. At present, insufficient data are available to permit the classification of idiopathic ventricular fibrillation as a distinct cardiomyopathy (Chen et al., 1998).

3.1.2 Mixed (genetic and nongenetic)

3.1.2.1 Dilated cardiomyopathy

DCM is the most common cardiomyopathy worldwide and has many causes. It is a heart muscle disorder defined by the presence of a dilated and poorly functioning left or both ventricles. It can be primary (genetic, mixed or predominantly familial non-genetic, or acquired) or secondary (e.g., infiltrative or autoimmune). This disease can be diagnosed in association with recognized cardiovascular disease; however, to qualify as DCM, the extent of myocardial dysfunction cannot be explained exclusively by abnormal loading conditions (hypertension, valve disease) or ischaemic heart disease (Elliott et al., 2008; Jefferies & Towbin, 2010). A large number of cardiac and systemic diseases can cause systolic impairment and left ventricular dilatation, but in the majority of patients no identifiable cause is found hence the term “idiopathic” dilated cardiomyopathy (IDC). There are experimental and clinical data in animals and humans suggesting that genetic, viral, and immune factors contribute to the pathophysiology of IDC (Elliott, 2000). DCM is associated with sudden cardiac death and heart failure, resulting in a large cost burden because of the very high rate of hospital admission and the potential need for heart transplantation.

DCM is characterized mainly by left ventricular systolic (or diastolic in some case) dysfunction (abnormality of contraction), with an associated increase in mass and volume. Right ventricular dilation and dysfunction can also develop but are not needed for diagnosis. Prevalence in the general population remains undefined. This disorder develops at any age, in either sex, and in people of any ethnic origin (Rosamond et al., 2008; Towbin et al., 2006). In adults, DCM arises more commonly in men than in women. In children, the yearly incidence is 0.57 cases per 100000 per year overall, but is higher in boys than in girls (0.66 vs. 0.47 cases per 100000, $P < 0.006$), in black people than in white people (0.98 vs. 0.46 cases per 100000, $P < 0.001$), and in babies younger than 1 year than in children (4.40 vs. 0.34 cases per 100000, $P < 0.001$). Two thirds of children are thought to have idiopathic disease (Towbin et al., 2006). In adults, the prevalence is 1 in 2500 individuals, with an incidence of 7 per 100000 per year (but it could be underdiagnosed). In many cases, the disease is inherited, and is called familial dilated cardiomyopathy (FDC). The familial type might account for 20-48% of all cases (Taylor et al., 2006). To achieve improved care and outcomes in children and adults, a broadened understanding of the causes of these disorders are needed.

In this disease, the left ventricle is dilated, and more spherical than usual with raised wall stress and depressed systolic function. Mitral regurgitation, thromboembolic events and ventricular arrhythmias can also develop. Occasionally, other rhythm disturbances such as atrioventricular block, supraventricular tachycardia with or without pre-excitation including Wolf-Parkinson-White syndrome and atrial fibrillation develop. In the most severe cases, affected individuals present with signs and symptoms of HF-diaphoresis, breathlessness at rest or with exertion, orthopnoea, exercise intolerance, early onset fatigue, abdominal pain, and pallor. Cachexia and peripheral oedema typically arise late in the course of the disease. Young children often have poor appetite and cachexia, similar to adults. Sinus tachycardia,

gallop rhythm, jugular-venous distention, pallor, cool hands and feet, hepatomegaly, and a murmur that is consistent with mitral regurgitation are common findings at physical examination (Jefferies & Towbin, 2010; Luk et al., 2009). Additionally, peripheral oedema and ascites are late signs in children. DCM can occur in a number of X-linked diseases such as Becker's and Duchenne's muscular dystrophies. It may also occur in patients with mitochondrial DNA mutations and inherited metabolic disorders. Thus when taking a family history, specific attention should be given to a history of muscular dystrophy, features of mitochondrial disease (for example, familial diabetes, deafness, epilepsy, maternal inheritance), and signs and symptoms of other inherited metabolic diseases (Elliott, 2000)

About 20-48% of DCM have been reported as familial, although with incomplete and age-dependent penetrance, and linked to a diverse group of >20 loci and genes ((Taylor et al., 2006)). Although genetically heterogeneous, the predominant mode of inheritance for DCM is autosomal dominant, with X-linked autosomal recessive and mitochondrial inheritance less frequent. Several of the mutant genes linked to autosomal dominant DCM encode the same contractile sarcomeric proteins that are responsible for HCM, including α -cardiac actin; α -tropomyosin; cardiac troponin T, I, and C; β - and α -myosin heavy chain; and myosin binding protein C. Z-disc protein-encoding genes, including muscle LIM protein, α -actinin-2, ZASP, and titin, also have been identified.

DCM is also caused by a number of mutations in other genes encoding cytoskeletal/sarcolemmal, nuclear envelope, sarcomere, and transcriptional coactivator proteins. The most common of these probably is the lamin A/C gene, also associated with conduction system disease, which encodes a nuclear envelope intermediate filament protein. Mutations in this gene also cause Emery-Dreifuss muscular dystrophy. The X-linked gene responsible for Emery-Dreifuss muscular dystrophy, emerin (another nuclear lamin protein), also causes similar clinical features. Other DCM genes of this type include desmin, caveolin, and β - and α -sarcoglycan, as well as the mitochondrial respiratory chain gene. X-linked DCM is caused by the Duchenne muscular dystrophy (dystrophin) gene, whereas G4.5 (tafazzin), a mitochondrial protein of unknown function, causes Barth syndrome, which is an X-linked cardioskeletal myopathy in infants (Maron et al., 2006).

3.1.2.2 Restrictive cardiomyopathy

RCM is defined as heart-muscle disease that results in impaired ventricular filling, with normal or decreased diastolic volume of either or both ventricles. Systolic function usually remains normal, at least early in the disease, and wall thickness may be normal or increased, depending on the underlying cause (Kushwaha et al., 1997).

The exact prevalence of RCM is unknown but it is probably the least common type of cardiomyopathy. RCM may be idiopathic, familial, or result from various systemic disorders, in particular, amyloidosis, sarcoidosis, carcinoid heart disease, scleroderma and anthracycline toxicity. Familial RCM is often characterized by autosomal dominant inheritance, which in some families is caused by mutations in the troponin I gene; in others, familial RCM is associated with conduction defects, caused by mutations in the desmin gene (usually associated with skeletal myopathy) (Fitzpatrick et al., 1990). Rarely, familial disease can be associated with autosomal recessive inheritance (such as haemochromatosis caused by mutations in the HFE gene, or glycogen storage disease), or with X-linked inheritance (such as Anderson-Fabry disease) (Elliott et al., 2008).

RCM can also be caused by endocardial pathology (fibrosis, fibroelastosis, and thrombosis) that impairs diastolic function. These disorders can be sub-classified according to the presence of eosinophilia into endomyocardial diseases with hypereosinophilia (e.g., hypereosinophilic syndromes (HES)) and endomyocardial disease without hypereosinophilia (e.g., endomyocardial fibrosis (EMF)) (Fauci et al., 1982). Parasitic infections, drugs such as methysergide, and inflammatory and nutritional factors have been implicated in acquired forms of EMF. Fibrous endocardial lesions of the right and/or left ventricular inflow tract cause incompetence of the atrioventricular valves (Kushwaha et al., 1997). Isolated left ventricular involvement results in pulmonary congestion and predominant right ventricular involvement leads to right heart failure.

3.1.3 Acquired

3.1.3.1 Myocarditis (inflammatory cardiomyopathy)

Myocarditis is an acute or a chronic inflammatory process affecting the myocardium produced by a wide variety of toxins and drugs (e.g., cocaine, interleukin 2) or infectious agents, most commonly including viral (e.g., coxsackievirus, adenovirus, parvovirus, HIV), bacterial (e.g., diphtheria, meningococcus, psittacosis, streptococcus), rickettsial (e.g., typhus, Rocky Mountain spotted fever), fungal (e.g., aspergillosis, candidiasis), and parasitic (Chagas disease, toxoplasmosis), as well as Whipple disease (intestinal lipodystrophy), giant cell myocarditis, and hypersensitivity reactions to drugs such as antibiotics, sulfonamides, anticonvulsants, and anti-inflammatories. Endocardial fibroelastosis is a DCM in infants and children that is a consequence of viral myocarditis in utero (mumps) (Maron et al., 2006).

Myocarditis typically evolves through active, healing, and healed stages. It is characterized progressively by inflammatory cell infiltrates leading to interstitial edema and focal myocyte necrosis and ultimately replacement fibrosis (Calabrese & Thiene, 2003). These pathological processes create an electrically unstable substrate predisposing to the development of ventricular tachyarrhythmias. In some instances, an episode of viral myocarditis (frequently subclinical) can trigger an autoimmune reaction that causes immunologic damage to the myocardium or cytoskeletal disruption, culminating in DCM with LV dysfunction. Evidence for the evolution of myocarditis to DCM comes from several sources, including animal models, the finding of inflammatory infiltrates and persistence of viral RNA in endomyocardial biopsies from patients with DCM, and the natural history of patients with selected conditions such as Chagas disease. The list of agents responsible for inflammatory myocarditis overlaps with that of the infectious origin of DCM, thereby underscoring the potential interrelationship between the 2 conditions (Cooper, 2009).

Myocarditis can be diagnosed by established histopathological, histochemical, or molecular criteria, but it is challenging to identify clinically. Suspicion may be raised by chest pain, exertional dyspnea, fatigue, syncope, palpitations, ventricular tachyarrhythmias, and conduction abnormalities or by acute congestive heart failure or cardiogenic shock associated with LV dilatation and/or segmental wall motion abnormalities and ST-T changes on ECG. When myocarditis is suspected from the clinical profile, an endomyocardial biopsy may resolve an otherwise ambiguous situation by virtue of diagnostic inflammatory (leukocyte) infiltrate and necrosis (i.e., the Dallas criteria) but also

is limited by insensitivity and false-negative histological results. The diagnostic yield of myocardial biopsies can be enhanced substantially by molecular analysis with DNA-RNA extraction and polymerase chain reaction amplification of the viral genome. In addition to the inflammatory process, viral genome encoded proteases appear to disrupt the cytoskeletal sarcomeric linkages of cardiomyocytes (Calabrese & Thiene, 2003; Parrillo, 2001).

3.1.3.2 Stress ("Tako-Tsubo") cardiomyopathy

Stress cardiomyopathy, first reported in Japan as "takotsubo," is a recently described clinical entity characterized by acute but rapidly reversible LV systolic dysfunction in the absence of atherosclerotic coronary artery disease, triggered by profound psychological stress (Sealove et al., 2008; Sharkey et al., 2005). This distinctive form of ventricular stunning typically affects older women and preferentially involves the distal portion of the LV chamber ("apical ballooning"), with the basal LV hypercontractile. Although presentation often mimics ST-segment-elevation myocardial infarction, outcome is favorable with appropriate medical therapy.

3.2 Secondary cardiomyopathies

The most important secondary cardiomyopathies are provided in the Table 1. This list, however, is not intended to represent an exhaustive and complete tabulation of the vast number of systemic conditions reported to involve the myocardium. Rather, it is limited to the most common of these diseases most consistently associated with a cardiomyopathy.

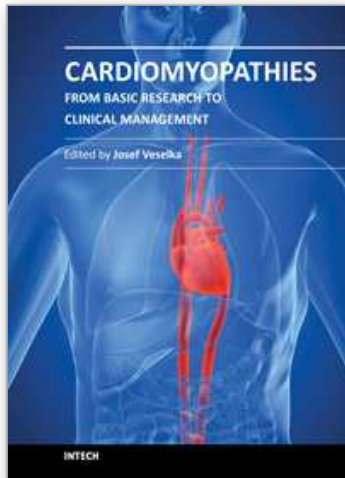
4. References

- Aleong, R.G., Milan, D.J. & Ellinor, P.T. (2007). The diagnosis and treatment of cardiac ion channelopathies: congenital long QT syndrome and Brugada syndrome. *Current Treatment Options in Cardiovascular Medicine*, Vol. 9, No. 5, (October 2007), pp. 364-371, ISSN 1092-8464
- Antzelevitch, C., Brugada, P., Borggrefe, M., Brugada, J., Brugada, R., Corrado, D., Gussak, I., LeMarec, H., Nademanee, K., Perez Riera, A.R., Shimizu, W., Schulze-Bahr, E., Tan, H. & Wilde, A. (2005). Brugada syndrome: report of the second consensus conference: endorsed by the Heart Rhythm Society and the European Heart Rhythm Association. *Circulation*, Vol. 111, No. 5, (January 17, 2005), pp. 659-670, ISSN 0009-7322
- Barry, S.P., Davidson, S.M. & Townsend, P.A. (2008). Molecular regulation of cardiac hypertrophy. *The International Journal of Biochemistry and Cell Biology*, Vol. 40, No. 10, (February 26, 2008), pp. 2023-2039, ISSN 1357-2725
- Basso, C., Corrado, D., Marcus, F.I., Nava, A. & Thiene G. (2009). Arrhythmogenic right ventricular cardiomyopathy. *Lancet*, Vol. 373, No. 9671, (April 11, 2009), pp. 1289-1300 ISSN 0140-6736
- Calabrese, F. & Thiene, G. (2003). Myocarditis and inflammatory cardiomyopathy: microbiological and molecular biological aspects. *Cardiovascular Research*, Vol. 60, No. 1, (October 2003), pp. 11-25, ISSN 0008-6363
- Chen, Q., Kirsch, G.E., Zhang, D., Brugada, R., Brugada, J., Brugada, P., Potenza, D., Moya, A., Borggrefe, M., Breithardt, G., Ortiz-Lopez, R., Wang, Z., Antzelevitch, C.,

- O'Brien, R.E., Schulze-Bahr, E., Keating, M.T., Towbin, J.A. & Wang, Q. (1998). Genetic basis and molecular mechanism for idiopathic ventricular fibrillation. *Nature*, Vol. 392, No. 6673, (March 19, 1998), pp. 293-296, ISSN 0028-0836
- Chin, T.K., Perloff, J.K., Williams, R.G., Jue, K. & Mohrmann, R. (1990). Isolated noncompaction of left ventricular myocardium. A study of eight cases. *Circulation*, Vol. 82, No. 2, (August 1990), pp. 507-513, ISSN 0009-7322
- Cooper, L.T. Jr. (2009). Myocarditis. *The New England Journal of Medicine*, Vol. 360, No. 15, (April 9, 2009), pp. 1526-1538, ISSN 0028-4793
- Elliott, P. (2000). Cardiomyopathy. Diagnosis and management of dilated cardiomyopathy. *Heart*, Vol. 84, No. 1, (July 2000), pp. 106-112, ISSN 1355-6037
- Elliott, P., Andersson, B., Arbustini, E., Bilinska, Z., Cecchi, F., Charron, P., Dubourg, O., Kühl, U., Maisch, B., McKenna, W.J., Monserrat, L., Pankuweit, S., Rapezzi, C., Seferovic, P., Tavazzi, L. & Keren, A. (2008). Classification of the cardiomyopathies: a position statement from the European Society Of Cardiology Working Group on Myocardial and Pericardial Diseases. *European Heart Journal*, Vol. 29, No. 2, (January 2008), pp. 270-276, ISSN 0195-668x
- Fauci, A.S., Harley, J.B., Roberts, W.C., Ferrans, V.J., Gralnick, H.R. & Bjornson, B.H. (1982). The idiopathic hypereosinophilic syndrome: clinical, pathophysiologic, and therapeutic considerations. *Annals of Internal Medicine*, Vol. 97, No. 1, (July 1982), pp. 78-92, ISSN 0003-4819
- Fitzpatrick, A.P., Shapiro, L.M., Rickards, A.F. & Poole-Wilson, P.A. (1990). Familial restrictive cardiomyopathy with atrioventricular block and skeletal myopathy. *British Heart Journal*, Vol. 63, No. 2, (February 1990), pp. 114-118, ISSN 0007-0769
- Freedom, R.M., Yoo, S.J., Perrin, D., Taylor, G., Petersen, S. & Anderson, R.H. (2005). The morphological spectrum of ventricular noncompaction. *Cardiology in the Young*, Vol. 15, No. 4, (August 2005), pp. 345-364, ISSN 1047-9511
- Jefferies, J.L. & Towbin, J.A. (2010). Dilated cardiomyopathy. *Lancet*, Vol. 375, No. 9716, (February 27, 2010), pp. 752-762, ISSN 0140-6736
- Gaita, F., Giustetto, C., Bianchi, F., Wolpert, C., Schimpf, R., Riccardi, R., Grossi, S., Richiardi, E. & Borggrefe, M. (2003). Short QT Syndrome: a familial cause of sudden death. *Circulation*, Vol. 108, No. 8, (August 18, 2003), pp. 965-970, ISSN 0009-7322
- Kass, R.S. (2005). The channelopathies: novel insights into molecular and genetic mechanisms of human disease. *The Journal of Clinical Investigation*, Vol. 115, No. 8, (August), pp. 1986-1989, ISSN 0021-9738
- Krittayaphong, R., Veerakul, G., Nademanee, K. & Kangkagate, C. (2003). Heart rate variability in patients with Brugada syndrome in Thailand. *European Heart Journal*, Vol. 24, No. 19, (October 2003), pp. 1771-1778, ISSN 0195-668x
- Kushwaha, S.S., Fallon, J.T. & Fuster, V. (1997). Restrictive cardiomyopathy. *The New England Journal of Medicine*, Vol. 336, No. 4, (January 23, 1997), pp. 267-276, ISSN 0028-4793
- Lowey, S. (2002). Functional consequences of mutations in the myosin heavy chain at sites implicated in familial hypertrophic cardiomyopathy. *Trends in Cardiovascular Medicine*, Vol. 12, No. 8, (November 2002), pp. 348-354, ISSN 1050-1738
- Marcus, F.I., McKenna, W.J., Sherrill, D., Basso, C., Bauce, B., Bluemke, D.A., Calkins, H., Corrado, D., Cox, M.G., Daubert, J.P., Fontaine, G., Gear, K., Hauer, R., Nava, A., Picard, M.H., Protonotarios, N., Saffitz, J.E., Sanborn, D.M., Steinberg, J.S., Tandri,

- H., Thiene, G., Towbin, J.A., Tsatsopoulou, A., Wichter, T. & Zareba, W. (2010). Diagnosis of arrhythmogenic right ventricular cardiomyopathy/dysplasia: proposed modification of the task force criteria. *Circulation*, Vol. 121, No. 13, (February 19, 2010), pp. 1533-1541, ISSN 0009-7322
- Maron, B.J. (2002). Cardiology patient pages. Hypertrophic cardiomyopathy. *Circulation*, Vol. 106, No. 19, (November 2002), pp. 2419-2421, ISSN 0009-7322
- Maron, B.J. (2008). The 2006 American Heart Association classification of cardiomyopathies is the gold standard. *Circulation Heart Failure*, Vol. 1, No. 1, (May 2008), pp. 72-75, ISSN 1941-3289
- Maron, B.J., Towbin, J.A., Thiene, G., Antzelevitch, C., Corrado, D., Arnett, D., Moss, A.J., Seidman, C.E. & Young, J.B. (2006). Contemporary definitions and classification of the cardiomyopathies: an American Heart Association Scientific Statement from the Council on Clinical Cardiology, Heart Failure and Transplantation Committee; Quality of Care and Outcomes Research and Functional Genomics and Translational Biology Interdisciplinary Working Groups; and Council on Epidemiology and Prevention. *Circulation*, Vol. 113, No. 14, (March 27, 2006), pp. 1807-1816. ISSN 0009-7322
- Modell, S.M. & Lehmann, M.H. (2006). The long QT syndrome family of cardiac ion channelopathies: a HuGE review. *Genetics in Medicine*, Vol. 8, No. 3, (March 2006), pp. 143-155, ISSN 1098-3600
- Monserat Iglesias, L. (2008). Left ventricular noncompaction: a disease in search of a definition. *Revista Espanola de Cardiologia*, Vol. 61, No. 2, (February 2008), pp. 112-115, ISSN 0300-8932
- Nava, A., Bauce, B., Basso, C., Muriago, M., Rampazzo, A., Villanova, C., Daliento, L., Buja, G., Corrado, D., Danieli, G.A. & Thiene, G. (2000). Clinical profile and long-term follow-up of 37 families with arrhythmogenic right ventricular cardiomyopathy. *Journal of the American College of Cardiology*, Vol. 36, No. 7, (December 2000), pp. 2226-2233, ISSN 0735-1097
- Parrillo, J.E. (2001). Inflammatory cardiomyopathy (myocarditis): which patients should be treated with anti-inflammatory therapy? *Circulation*, Vol. 104, No. 1, (July 3, 2001), pp. 4-6, ISSN 0009-7322
- Protonotarios, N., Anastasakis, A., Antoniadis, L., Chlouverakis, G., Syrris, P., Basso, C., Asimaki, A., Theopistou, A., Stefanadis, C., Thiene, G., McKenna, W.J. & Tsatsopoulou, A. (2011). Arrhythmogenic right ventricular cardiomyopathy/dysplasia on the basis of the revised diagnostic criteria in affected families with desmosomal mutations. *European Heart Journal*, Vol. 32, No. 9, (February 22, 2011), pp. 1097-1104, ISSN 0195-668x
- Richardson, P., McKenna, W., Bristow, M., Maisch, B., Mautner, B., O'Connell, J., Olsen, E., Thiene, G. & Goodwin, J. (1996). Report of the 1995 World Health Organization/International Society and Federation of Cardiology Task Force on the Definition and Classification of Cardiomyopathies. *Circulation*, Vol. 93, No. 5, (March 1, 1996), pp. 841-842, ISSN 0009-7322
- Rosamond, W., Flegal, K., Furie, K., Go, A., Greenlund, K., Haase, N., Hailpern, S.M., Ho, M., Howard, V., Kissela, B., Kittner, S., Lloyd-Jones, D., McDermott, M., Meigs, J., Moy, C., Nichol, G., O'Donnell, C., Roger, V., Sorlie, P., Steinberger, J., Thom, T., Wilson, M. & Hong, Y. (2008). Heart disease and stroke statistics-2008 update: a

- report from the American Heart Association Statistics Committee and Stroke Statistics Subcommittee. *Circulation*, Vol. 117, No. 4, (January 29, 2008), pp. e25-e146, ISSN0009-7322
- Schimpf, R., Wolpert, C., Gaita, F., Giustetto, C. & Borggrefe, M. (2005). Short QT syndrome. *Cardiovascular Research*, Vol. 67, No. 3, (August 15, 2005). pp. 357-366, ISSN 0008-6363
- Sealove, B.A., Tiyyagura, S. & Fuster, V. (2008). Takotsubo cardiomyopathy. *Journal of General Internal Medicine*, Vol. 23, No. 11, (August 2008), pp. 1904-1908, ISSN 0884-8734
- Selvetella, G. & Lembo, G. (2005). Mechanisms of cardiac hypertrophy. *Heart Failure Clinics*, Vol. 1, No. 2, (July 2005), pp. 263-273, ISSN 1551-7136
- Sharkey, S.W., Lesser, J.R., Zenovich, A.G., Maron, M.S., Lindberg, J., Longe, T.F. & Maron, B.J. (2005). Acute and reversible cardiomyopathy provoked by stress in women from the United States. *Circulation*, Vol. 111, No. 4, (February 1, 2005), pp. 472-479, ISSN 0009-7322
- Taylor, M.R., Carniel, E. & Mestroni, L. (2006). Cardiomyopathy, familial dilated. *Orphanet Journal of Rare Diseases*, Vol. 1, (July13, 2006), pp. 27, ISSN 1750-1172
- Thiene, G., Angelini, A., Basso, C., Calabrese, F. & Valente, M. (2000). The new definition and classification of cardiomyopathies. *Advances in Clinical Pathology*, Vol. 4, No. 2, (April, 2000), pp. 53-57, ISSN 1125-5552
- Thiene, G., Corrado, D. & Basso, C. (2004). Cardiomyopathies: is it time for a molecular classification? *European Heart Journal*, Vol. 25, No. 20, (October 2004), 1772-1775, ISSN 0195-668x
- Towbin, J.A., Lowe, A.M., Colan, S.D., Sleeper, L.A., Orav, E.J., Clunie, S., Messere, J., Cox, G.F., Lurie, P.R., Hsu, D., Canter, C., Wilkinson, J.D. & Lipshultz, S.E. (2006). Incidence, causes, and outcomes of dilated cardiomyopathy in children. *The Journal of the American Medical Association*, Vol. 296, No. 15, (October 18, 2006), pp. 1867-1876, ISSN 0098-7484
- Wilde, A.A., Bhuiyan, Z.A., Crotti, L., Facchini, M., De Ferrari, G.M., Paul, T., Ferrandi, C., Koolbergen, D.R., Odero, A. & Schwartz, P.J. (2008). Left cardiac sympathetic denervation for catecholaminergic polymorphic ventricular tachycardia. *The New England Journal of Medicine*, Vol. 358, No. 19, (May 8, 2008), pp. 2024-2029, ISSN 0028-4793



Cardiomyopathies - From Basic Research to Clinical Management

Edited by Prof. Josef Veselka

ISBN 978-953-307-834-2

Hard cover, 800 pages

Publisher InTech

Published online 15, February, 2012

Published in print edition February, 2012

Cardiomyopathy means "heart (cardio) muscle (myo) disease (pathy)". Currently, cardiomyopathies are defined as myocardial disorders in which the heart muscle is structurally and/or functionally abnormal in the absence of a coronary artery disease, hypertension, valvular heart disease or congenital heart disease sufficient to cause the observed myocardial abnormalities. This book provides a comprehensive, state-of-the-art review of the current knowledge of cardiomyopathies. Instead of following the classic interdisciplinary division, the entire cardiovascular system is presented as a functional unity, and the contributors explore pathophysiological mechanisms from different perspectives, including genetics, molecular biology, electrophysiology, invasive and non-invasive cardiology, imaging methods and surgery. In order to provide a balanced medical view, this book was edited by a clinical cardiologist.

How to reference

In order to correctly reference this scholarly work, feel free to copy and paste the following:

Bhulan Kumar Singh, Krishna Kolappa Pillai, Kanchan Kohli and Syed Ehtaishamul Haque (2012).
Classification and Definitions of Cardiomyopathies, *Cardiomyopathies - From Basic Research to Clinical Management*, Prof. Josef Veselka (Ed.), ISBN: 978-953-307-834-2, InTech, Available from:
<http://www.intechopen.com/books/cardiomyopathies-from-basic-research-to-clinical-management/classification-and-definitions-of-cardiomyopathies>

INTECH
open science | open minds

InTech Europe

University Campus STeP Ri
Slavka Krautzeka 83/A
51000 Rijeka, Croatia
Phone: +385 (51) 770 447
Fax: +385 (51) 686 166
www.intechopen.com

InTech China

Unit 405, Office Block, Hotel Equatorial Shanghai
No.65, Yan An Road (West), Shanghai, 200040, China
中国上海市延安西路65号上海国际贵都大饭店办公楼405单元
Phone: +86-21-62489820
Fax: +86-21-62489821

© 2012 The Author(s). Licensee IntechOpen. This is an open access article distributed under the terms of the [Creative Commons Attribution 3.0 License](https://creativecommons.org/licenses/by/3.0/), which permits unrestricted use, distribution, and reproduction in any medium, provided the original work is properly cited.

IntechOpen

IntechOpen