

We are IntechOpen, the world's leading publisher of Open Access books Built by scientists, for scientists

6,900

Open access books available

186,000

International authors and editors

200M

Downloads

Our authors are among the

154

Countries delivered to

TOP 1%

most cited scientists

12.2%

Contributors from top 500 universities



WEB OF SCIENCE™

Selection of our books indexed in the Book Citation Index
in Web of Science™ Core Collection (BKCI)

Interested in publishing with us?
Contact book.department@intechopen.com

Numbers displayed above are based on latest data collected.
For more information visit www.intechopen.com



Implantation Techniques of Leads for Left Ventricular Pacing in Cardiac Resynchronization Therapy and Electrocardiographic Consequences of the Stimulation Site

Michael Scheffer¹ and Berry M. van Gelder²

¹*Maasstad Hospital, Rotterdam*

²*Catharina Hospital, Eindhoven
The Netherlands*

1. Introduction

The first descriptions of beneficial effects of left ventricular (LV) or simultaneous LV and right ventricular (RV) pacing were published more than 35 years ago (Vagnini et al.,1967; Tyers et al.,1970; Gibson et al.,1971). In 1994 Cazeau published the first successful cases of biventricular pacing in patients with severe congestive heart failure (CHF) and no conventional indication for cardiac pacing (Cazeau et al.,1994). At the same time Bakker and colleagues reported their experiences (Bakker et al.,2000), with epicardial LV pacing by thoracotomy. The transvenous approach via the coronary sinus (CS) tributaries was first published by Daubert in 1998 and was an important contribution in the application of cardiac resynchronization therapy (Daubert et al.,1998) (Fig 1).

The transvenous approach has been more and more developed and has become the implantation technique of choice. CRT is recently categorized as class I level of evidence A in the European Society of Cardiology guidelines in patients with a dyssynchronous failing heart (Swedberg et al.,2005). In case of unsuccessful transvenous implantation, surgical LV lead placement can be achieved under direct visualization. Another approach for LV lead placement, when neither CS placement nor surgical options are available, is a trans-atrial septal puncture to pass the LV lead via the left atrium through the mitral valve and screw into the LV lateral wall (Leclercq et al.,1999; Jaïs et al.,1998; van Gelder et al.,2007), or by apical insertion of the LV lead (Kassai et al.,2009).

2. Venous access

Venous access can be obtained by subclavian or axillary vein puncture or by the cephalic vein cut down method.

The subclavian puncture is most frequently used for transvenous pacing leads. After the puncture is performed, a guide wire is passed into the subclavian vein and a dilator with a splitable sheath is advanced over the guide wire into the vein. The guide wire and the

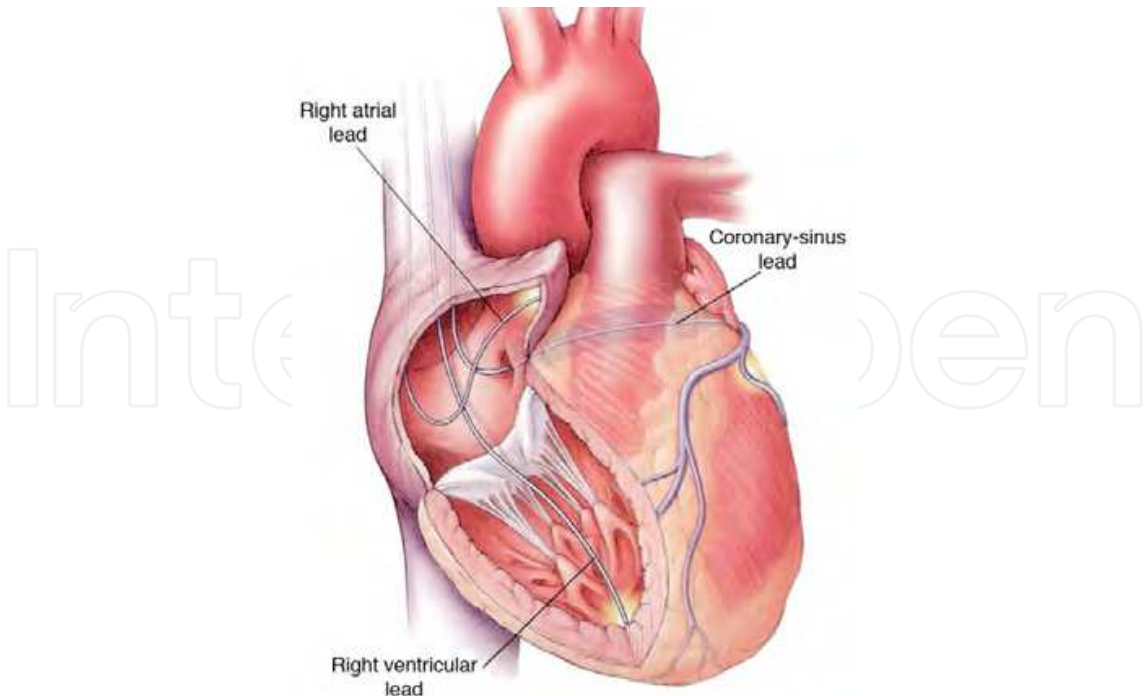


Fig. 1. The transvenous approach to CRT. Right atrial lead placed in the right atrial appendage. Right ventricular lead placed in the apex of the right ventricle. The left ventricular lead is advanced through the coronary sinus in one of the venous side branches running along the left postero-lateral wall of the left ventricle to allow synchronous activation of the left ventricle through continuous stimulation of left and right ventricular leads in a simultaneous or sequential way with an adjusted V-V interval.

dilator are removed and the sheath is left in the vein for passage of the pacing lead. This technique is referred to as the Seldinger technique. With a single puncture both RA and RV leads can be introduced. The RV lead is placed in the right ventricle leaving the guide wire alongside the lead. The sheath is withdrawn and the retained wire is used to introduce a second sheath for the RA lead. A separate puncture is advisable to introduce the LV lead.

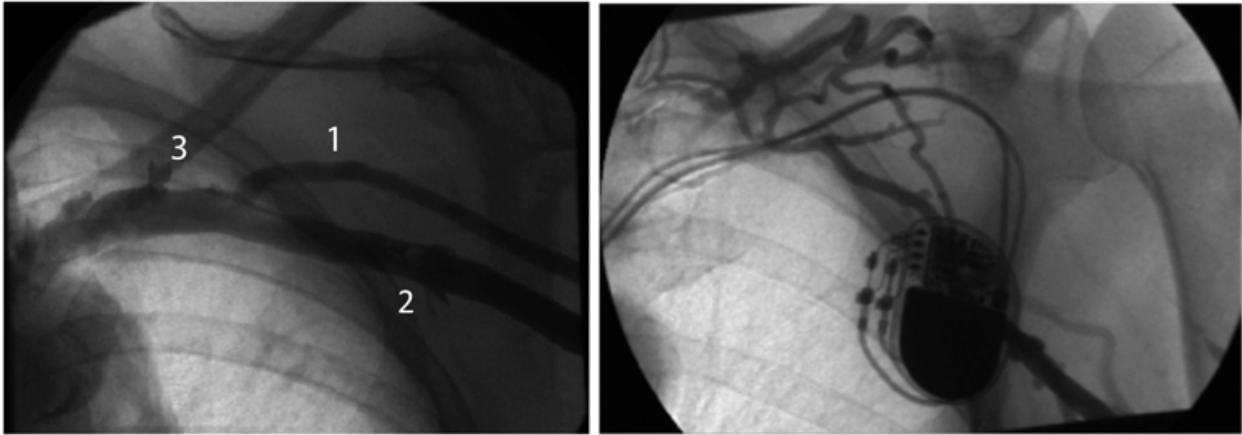


Fig. 2. Venous contrast injection showing the cephalic vein (1), axillary vein (2) and the subclavian vein (3) running under the clavicle. (left panel) Complete occlusion of the axillary and subclavian vein before an upgrading of a DDD pacemaker to a biventricular pacemaker (right panel).

As an alternative the cephalic vein can be located and cannulated in the deltopectoral groove to introduce one or more pacing leads. Usually this approach is combined with the puncture method, because the cephalic vein is often too small to insert three leads.

In our institution we prefer to start the implantation procedure with a contrast injection of 20 cc in the peripheral vein of the arm to visualize the cephalic, axillary and subclavian vein (Fig 2).

After the venography an image hold can help in case of a difficult puncture and RA and RV lead choice can be made depending on the size of the vessels and cardiac anatomy. If an upgrade to CRT is necessary subclavian thrombosis or severe stenosis is present in up to 15 % of the patients and with a planned venography needless effort can be prevented and a desirable strategy can be determined.

The left shoulder is the preferred implantation site, because it provides a more natural curve for the guiding catheter to enter the CS from the superior vena cava and right atrium. For implantation of a biventricular implantable cardioverter defibrillator (CRT-D) the left side is also preferable because of lower defibrillation threshold from this side. The cephalic vein cut down is used for both RA and RV leads and a separate puncture of the subclavian vein or axillary vein is used for the LV lead. This facilitates removal of the guiding delivery catheter for the LV lead with the slitting method.

In case of an absent cephalic vein double or triple puncture of the subclavian or axillary vein is used to introduce separate sheaths for the three leads. The RV lead is first implanted to provide backup pacing in case of traumatizing the right bundle in patients with preexisting left bundle branch block or due to traumatic atrioventricular block with introduction of the guiding catheter in the CS, which occur in 1-4% of cases (Abraham et al.,2002; Kautzner et al.,2004) (Fig 3).

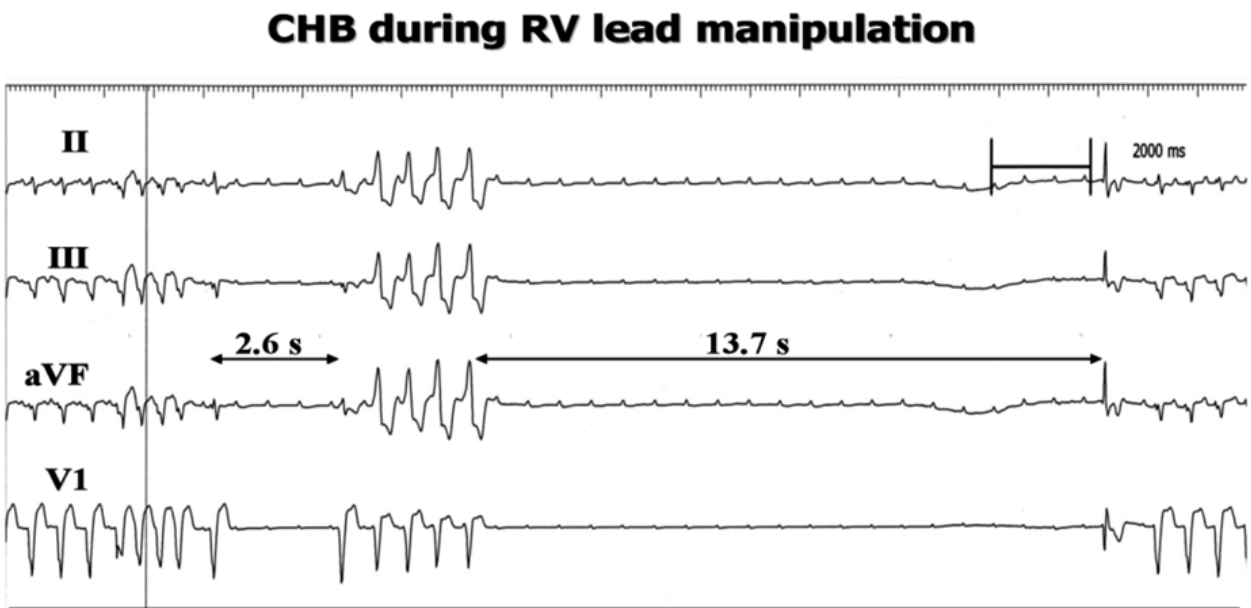


Fig. 3. During manipulation of the right ventricular lead complete heart block can occur due to traumatizing the right bundle as shown above. After a non sustained VT a pause of 2.6 seconds is followed by another non sustained VT and a second pause of 13.7 seconds in which only P waves are seen.

The RV lead can be screwed in the RV septum or placed in the RV apex. Although not proven is the mid septum position the best position to create an optimal separation between the RV and LV lead, which should be positioned in the postero-lateral wall.

The RA lead is positioned in the right atrial appendage or in case of interatrial conduction time delay of more than 120 ms in the interatrial septum to synchronize both atria. Interatrial conduction time delay can be measured beforehand with echocardiography using the Doppler signal from the tricuspid and mitral inflow and the p wave on the electrocardiogram, which gives the interatrial mechanical delay (Fig 4).

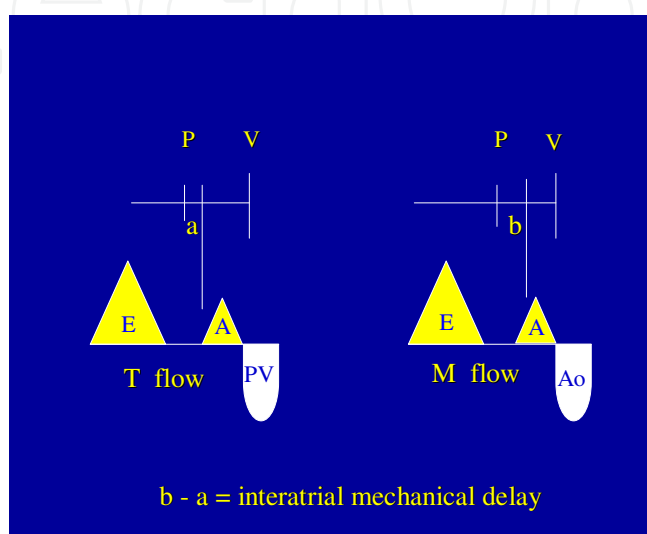


Fig. 4. Interatrial mechanical delay. With the use of echo-Doppler the inflow over the tricuspid and mitral valve can be obtained after which the difference between the electrical and mechanical activation of the right and left atrium can be measured. In the figure appointed as **a** for the right atrium and **b** for the left atrium. The difference between both gives the interatrial mechanical delay.

3. How to insert the left ventricular lead

3.1 Finding the coronary sinus

The key step in the implantation procedure for resynchronization therapy is finding the entrance to the CS. The CS ostium measures 5-15 mm in diameter and is located on the posterior interatrial septum anterior to the Eustachian ridge and valve and posterior to the tricuspid annulus (Fig 5).

Anatomy of the right atrium

The Thebesian valve frequently covers a part of the ostium, but can as a fenestrated valve completely occlude the ostium. Other valves found in the CS, like the Vieussens, sometimes seen at the ostium of the primary postero-lateral vein, opposite to the vein of Marshall and the non Vieussens valve at the ostium of the middle cardiac vein. Understanding the anatomy of the right atrium in the failing heart helps to successful access the CS. Non invasive imaging of the coronary venous anatomy has shown that the relationship between the RA and the CS in patients with congestive heart failure is quite different from that in patients with normal hearts (Chan et al.,2004). Due to the enlargement of the failing heart, the heart will rotate, causing the ostium of the CS to move to a low and posterior position in

the right atrium (León et al.,2005). Other landmarks seen with fluoroscopy can be used to identify the CS, such as calcifications of the right coronary artery, or the lucent adipose pad overlying the atrial-ventricular groove that marks the course of the CS.

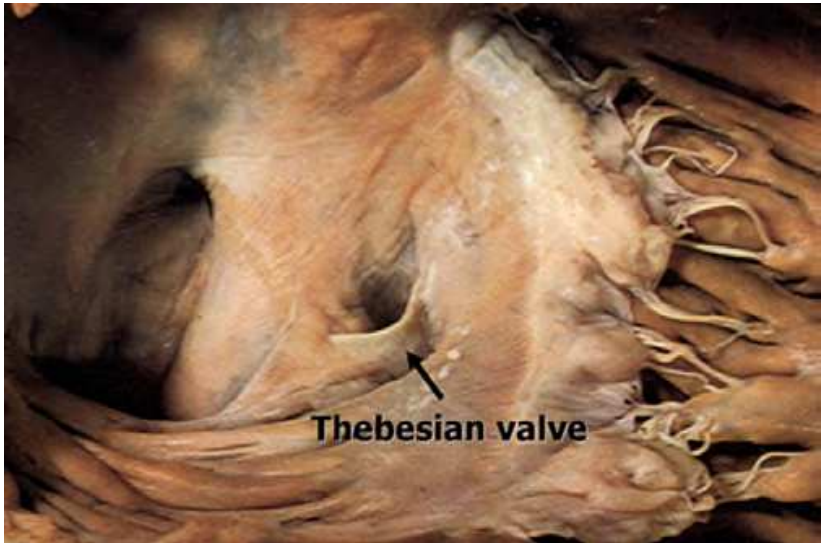


Fig. 5. The right atrium with the Thebesian valve partly covering the ostium of the coronary sinus.

Cannulation of the CS is done with preshaped guiding delivery sheaths, which are available in many different models (Fig 6). The main purpose of the guiding delivery sheath is to provide stability and pushability of the LV lead during cannulation of one of the tributaries of the CS and it also offers the possibility to make a venogram with the balloon catheter.




Fig. 6. Several types of guiding delivery sheaths used for cannulation of the coronary sinus. The type used depends on the side of implantation, enlargement of the right atrium and angulation of the CS and stability given by the provided guiding delivery sheath.

The guiding delivery sheath is brought into the subclavian vein through a 9 French sheath, so the guiding delivery catheter can move easily. The left anterior oblique (LAO) 30°-45° projection best guides CS access, because the CS runs toward the spine in a posterior direction to encircle the mitral annulus in that view.

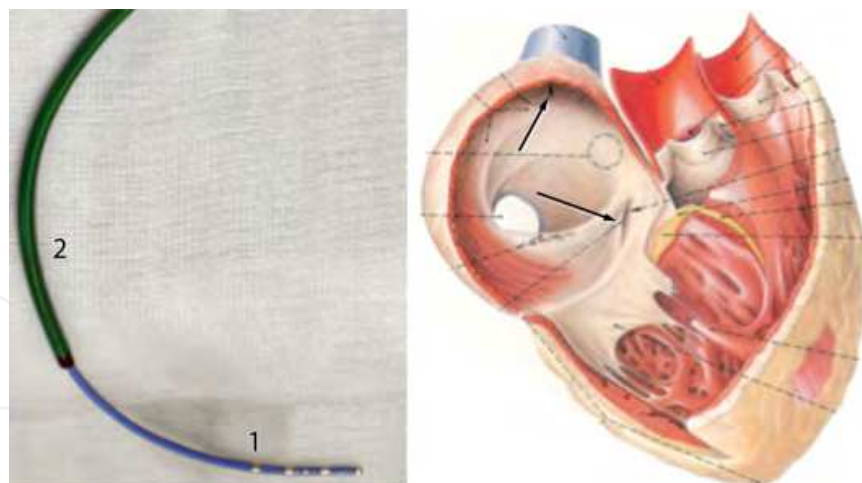


Fig. 7. The TORQR (1) is inside the guiding delivery sheath (2), left panel. Both catheters are brought into the roof of the right atrium (upper arrow), where the guiding delivery sheath is kept and the TORQR is advanced to cannulate the coronary sinus (lower arrow), right panel.

The guiding delivery sheath is brought in the roof of the right atrium after which the EP catheter is advanced in the floor of the right atrium and pulled up with counterclockwise torque to direct it posterior to the ostium of the CS. (Fig 7, right panel)

Another way is to maneuver the EP catheter into the right ventricle and then slowly withdrawn with counterclockwise torque towards the right atrium to engage the CS. Engagement of the CS ostium results in a characteristic rocking motion of the catheter due to systolic movement of the AV groove. The guiding delivery catheter is then pushed over the EP catheter as a railing system inside the CS to a distal position to prevent dislodgement.

When numerous attempts fail to locate the ostium of the CS, coronary angiography catheters like the Amplatz L2-L3 can be used for contrast injections near the ostium of the CS or a guidewire (0.035" J wire) is introduced to explore the lower right atrium for the ostium of the CS. If this also fails a selective coronary angiography of the left coronary artery in the LAO 30°-45° projection will disclose the CS if the venous passage of contrast is visualized. Otherwise visualization with intra cardiac echocardiography has been proposed, but this technique is relatively expensive and experience is limited.

After a learning curve the CS can be cannulated within several minutes, but even in experienced hands a failure rate to cannulate the CS is reported in the range of 1-3%.

A rare case of failure is an anatomical aberrancy in which the CS has no communication with the RA. In this situation the CS drains into the venous circulation through a persistent left superior caval vein. This aberrancy is encountered in 3 out of 500 CS implants (Gelder et al.,2003).

Once the CS is successfully cannulated the electrophysiology catheter can be exchanged for a balloon catheter to perform an occlusive CS venography in two projections LAO and RAO 30°-45°.

3.2 Retrograde coronary venography

The use of venography of the CS is necessary to facilitate LV lead implantation. The balloon catheter is loaded with a PCI wire and the balloon catheter is advanced to the end of the guiding delivery sheath under fluoroscopy. The 0.014 PCI wire is pushed out the balloon catheter and advanced into the CS. This will prevent dissection from the CS by the balloon catheter.

The PCI wire will be pulled back to allow a retrograde contrast injection after balloon occlusion of the CS (Fig 8). This is done with a 10 cc syringe hand injection of contrast diluted with saline 0,9 %.

Retrograde injection of contrast opacifies all potential target veins, valves, structures, collateral connections and specific anatomic details of the target veins that will help to make the right choice for the LV lead (Fig 9). It is desirable to make a long cine sequence to visualize collaterals or side branches occluded by the balloon. To avoid occlusion of side branches by the balloon catheter or if no side branches are visualized, contrast injections must be repeated at several levels in the CS.

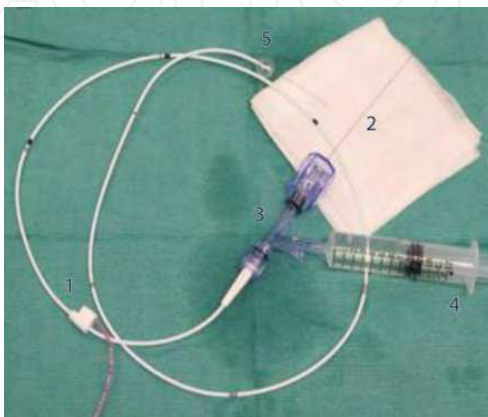


Fig. 8. Balloon catheter (1) with the PCI wire (2) and Y connector (3) together with a contrast syringe (4) to the side port. The balloon catheter is advanced in the CS with the PCI wire running before the balloon catheter to prevent dissection of the CS. After the PCI wire is pulled back a retrograde injection in the CS is made after balloon inflation (5).

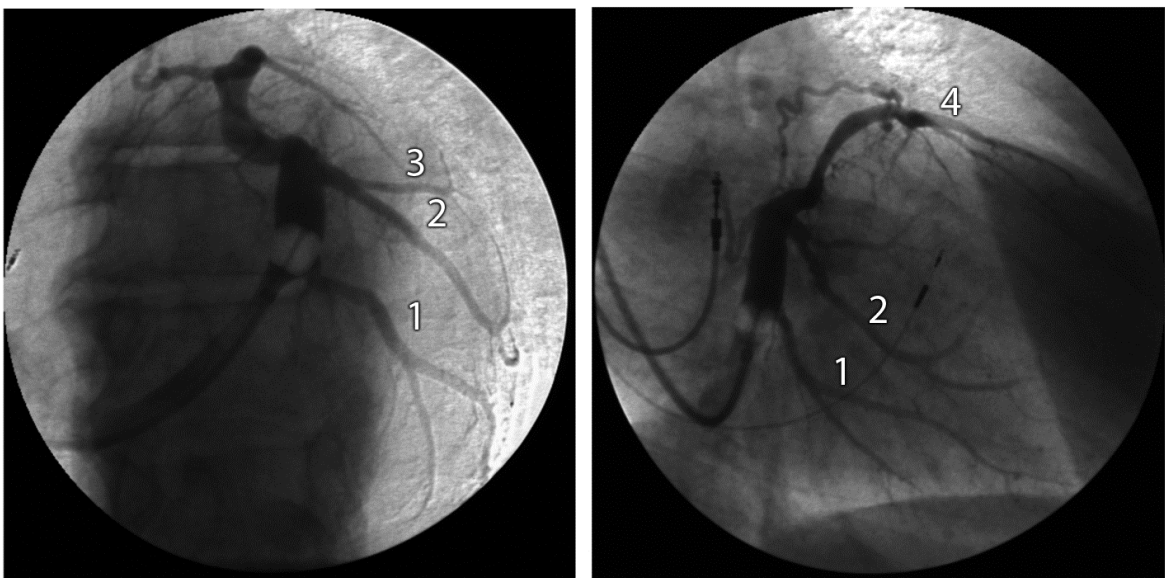


Fig. 9. Retrograde coronary venography of the coronary sinus. On the left panel the LAO projection shows the coronary sinus with two large postero-lateral branches (1 and 2) and a small lateral branch (3). The right side shows the RAO projection. In this projection we see again both postero-lateral branches (1 and 2) with second order branches and the great cardiac vein running over the anterior wall (4).

The PCI wire can be left in the balloon catheter to steer it into the selected vein. Position can be checked by contrast injection through the Y connector.

LV pacing from the lateral, postero-lateral or antero-lateral cardiac vein provides the optimal result of the CRT device (Butter et al.,2001). (Fig 10). Successful implantation also depends on the inclusion criteria, which should include mechanical dyssynchrony to provide responders to CRT (Scheffer et al.,2010; Yu et al.,2002; Bax et al.,2003). Stimulation at the LV site with the latest mechanical activation measured with TDI will provide the highest cardiac output (Ansalone et al.,2002).

Storing digitally acquired images in two radiographic views (RAO 30°and LAO 30-45°) offer a reference for advancing PCI wires and LV pacing leads in the target branch of the CS.

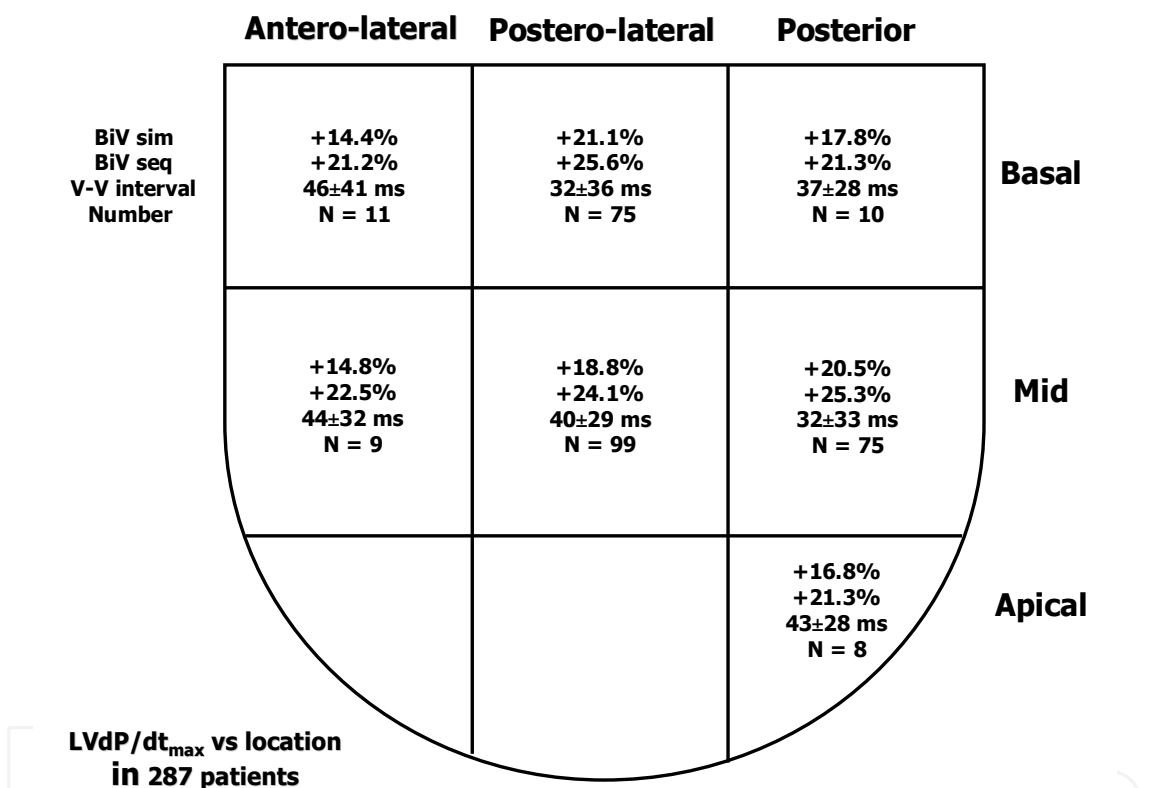


Fig. 10. Diagram of LV lead positions of 287 patients implanted with a CRT device combined figures from the Catharina Hospital, Eindhoven, The Netherlands and Maasstad Hospital Rotterdam in three years. Percentages indicate the rise in LV dp/dt compared to baseline. The preferred position is the basal lateral or mid lateral position measured with LV dp/dt immediately after implantation of a CRT device. These locations are also found by others to be the preferred position for optimal CRT.

3.3 Accessibility of side branches

Side branches too small for lead placement or complete absence of the side branches are a rare phenomenon, but can occasionally occur. Visualization of the middle cardiac vein can help to find a way to a lateral position for the LV lead. After coronary artery bypass surgery pericardial fibrosis or severe stenosis of the target vein may complicate the placement of the

LV lead. Coronary venoplasty or stenting is used in those patients to overcome these problems (Hansky et al.,2002; van Gelder et al.,2003) (fig 11).

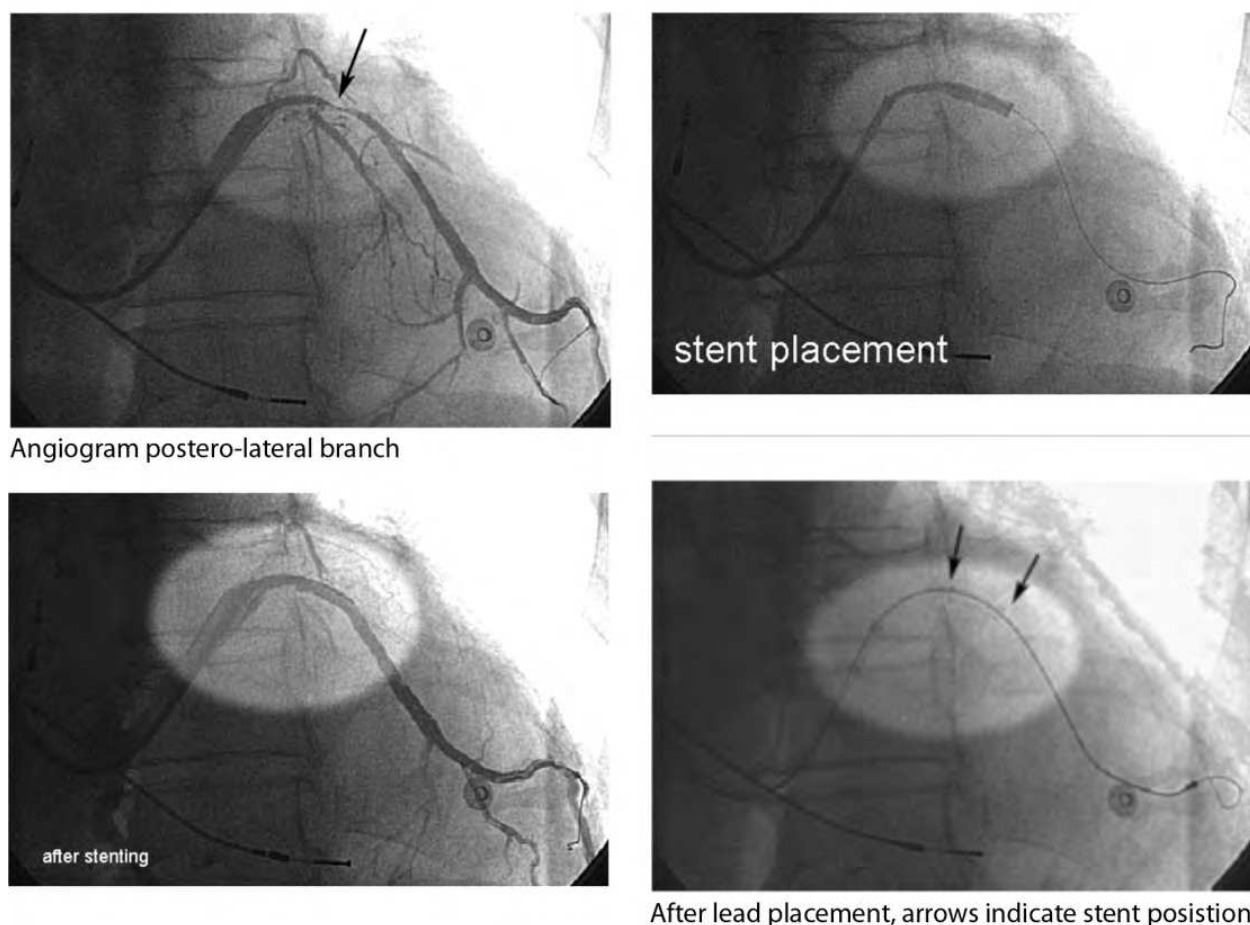


Fig. 11. Severe stenosis of a postero-lateral branch could be conquered with stenting after which the LV lead could be simply introduced.

Sometimes there are no tributes found in the CS and just a small part of the entry of the target vein is shown on the retrograde venography of the CS. Totally occluded target veins can be opened with the use of PCI wires and balloon dilatation (Fig 12).

With the knowledge of the retrograde venography of the CS the LV lead can be chosen, depending on the diameter and tortuosity of the target vein. Considerable advancements in LV lead design have led to numerous different unipolar, bipolar and multipolar LV leads. The LV leads can be used stylet driven or over the wire (OTW) similar to percutaneous coronary intervention.

In general the stylet driven LV leads are larger in diameter and used for larger veins, but some can also be used OTW and are called hybrids. Advancement of these stylet driven leads is performed by bending the distal 1-2 cm of the stylet at an angle corresponding to the angle of entry of the target vein into the CS. With the use of the bended stylet the LV lead can be steered into the target vein and exchanged for a soft, straight stylet to push the lead inside the vein. Lead advancement is often facilitated by clockwise rotation and repeated pushing of the lead with slight retraction of the stylet.

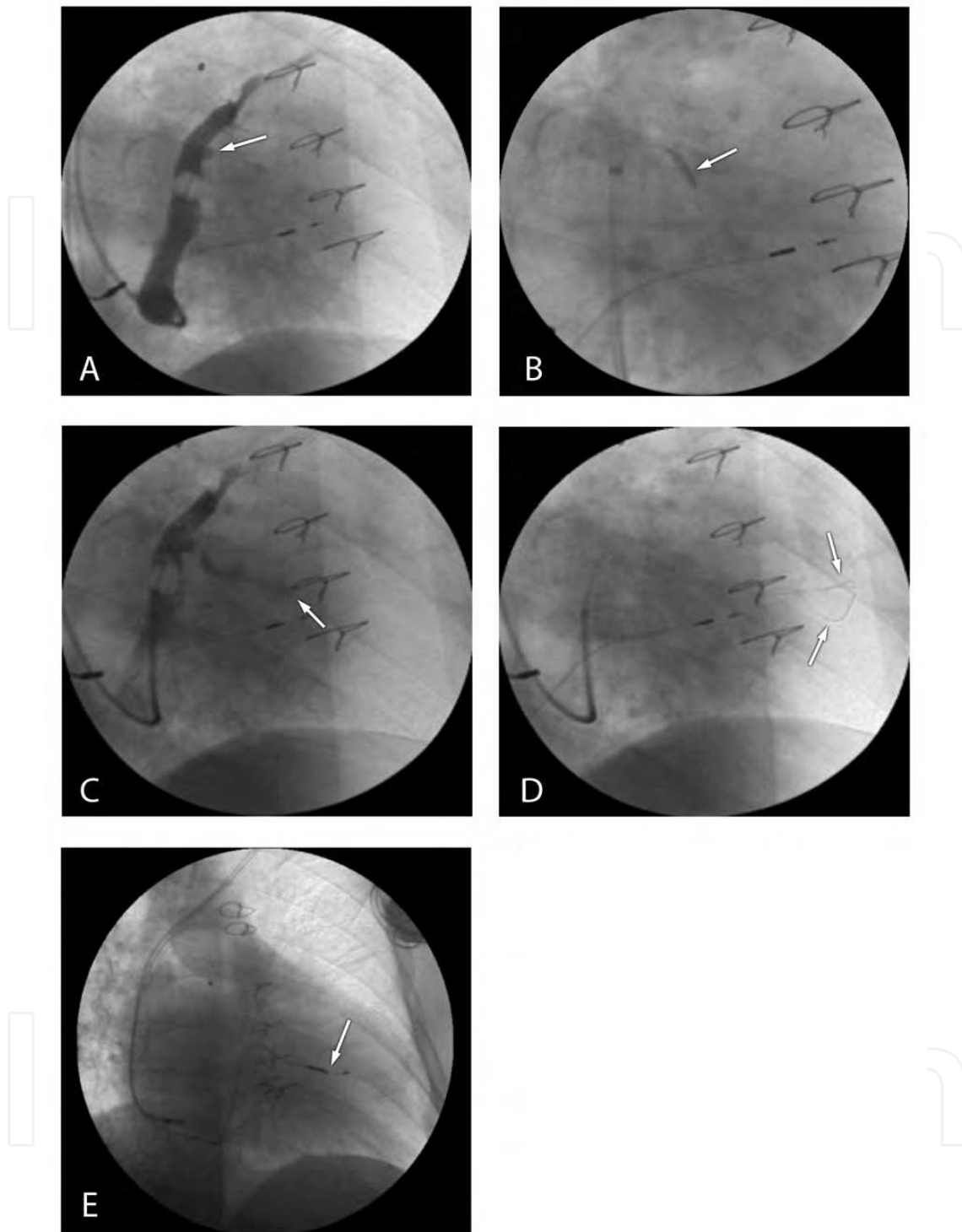


Fig. 12. a: coronary sinus projected in the RAO view with a total occluded posterolateral branch. (arrow pointing to occlusion)
 b: showing a balloon dilatation after a PCI wire crossed this total occlusion.
 c: slight filling of the postero-lateral branch.
 d: buddy wire technique to cross the difficulties in this narrowed vessel. (two arrows pointing to both PCI wires)
 e: Successful placements of the LV lead in the postero-lateral wall. (arrow)

3.4 The Over The Wire (OTW) technique

The OTW technique is different and provides access of the PCI wire to the target vein. First the LV lead is loaded with a PCI wire. The distal 5 mm of the PCI wire is slightly bended (Fig 13) and the LV lead combined with the PCI wire is brought into the CS through the guiding delivery sheath near the target vein.



Fig. 13. Over the wire technique showing the guiding delivery sheath (1) with the LV lead (2) pushed out of the guiding delivery catheter and the PCI wire going ahead to advance into the side branch of the CS. The slight bend in the PCI wire (arrow) makes it possible to steer the PCI wire in the desired direction.

The PCI wire is advanced out the LV lead and with the ease of a torque steered in the desired vein. The PCI wire is advanced as distally as possible into the vein to provide a track for the lead. Subsequently the LV lead is pushed over the PCI wire into the vein, while the PCI wire is fixed or slightly retracted until the tip of the LV lead wedges or has a stable position. The OTW technique enables the pacing lead to go into secondary veins or to maneuver the LV lead to the optimal position.

Several problems can come across why the PCI wire will not enter the target vein: valves at the entrance of the target vein, severe angulated proximal segments, very tortuous segments or a very small caliber of the vein. When the PCI wire cannot be advanced from the CS into the first branch, because there is an acute angle, a guide catheter is used. For this purpose special Attain catheters with different curves and soft tips are made (Fig 14 a, b) to cannulate the target vein. Instead standard coronary angiography catheters can be used.

Depending on the angle of the ostium of the target vein an Attain Select catheter or a coronary angiography catheter can be used. This catheter introduced into the guiding delivery sheath and used as a telescoping catheter to hook on to the target vein enabling to give selective contrast injections to facilitate cannulation. Once the catheter engages the target vein a PCI wire is passed through the catheter and the PCI wire is advanced as distally as possible into the vein. Under continuous fluoroscopy the catheter is withdrawn while keeping the PCI wire in place. Thereafter the LV lead is frontloaded (not all LV leads

can be frontloaded) with the PCI wire and the LV lead is advanced while retracting the PCI wire like a rail system to the desired site. Occasionally the LV lead cannot be advanced because the PCI wire has not straightened the acute angle or tortuous segment and a stiffer guidewire can be helpful. If this will not work the use of a buddy wire or telescopic sheaths may be the last resort to bring the lead transvenous to the desired place.



Fig. 14. Three Attain Select catheters (Medtronic) specially designed with a soft tip to cannulate side branches with sharp take off from the coronary sinus (left panel). The Attain Select catheters can be loaded with PCI wires to engage the target vessel or to give contrast injections in the tributary to visualize the peripheral part (right panel).

3.5 Special techniques or solutions for LV lead advancement

The buddy wire technique refers to the placement of one or more PCI wires alongside the first wire to optimal straighten the vein and allow passage of the LV lead. (Fig 12 d)

The telescoping sheath technique can only be used in larger diameter target veins, because the risk of perforation exists. The CS guiding delivery sheath must be at least 9 French and the target vein is cannulated with a heavy weight PCI wire. Over the PCI wire into the CS delivery guiding sheath is brought a smaller diameter straight CS sheath with a soft tip. On this CS catheter a Y connector is fastened to inject contrast if needed and allow visualization of the encroachment of the CS catheter into the target vein and dissection or perforation can be avoided. Sometimes even with the PCI wire in place the straightened CS sheath will not advance. The PCI wire is then replaced by an Attain Select catheter or coronary artery catheter that resembles the shape of the target vein and with manipulation of the tip the difficulties can be conquered.

The straightened soft CS sheath is advanced over the Attain Select or coronary artery catheter and the latest is withdrawn, so a stylet driven LV lead can pass through. In large diameter veins it is not always possible to obtain a stable LV lead position and new designed LV leads can solve this problem (Fig 15).

With the LV lead in place two new problems can be encountered, high left ventricular stimulation thresholds and phrenic nerve stimulation. Another more intriguing problem is ongoing mechanical dyssynchrony after implantation. This topic will be addressed in par.6.

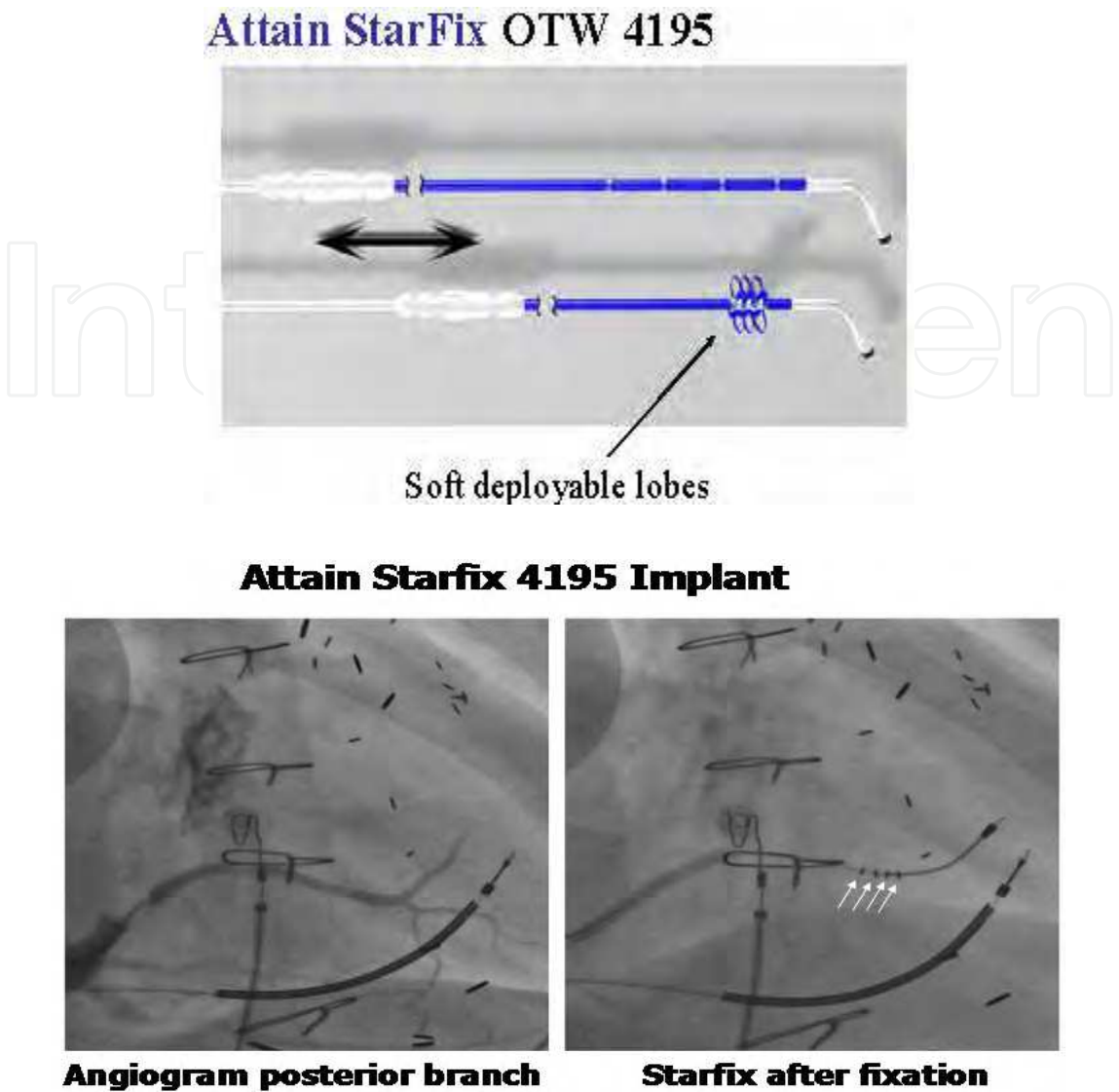


Fig. 15. The Starfix lead (Medtronic) with deployable lobes. By pushing up the redundant blue tube, which covers the lead at the proximal part of the lead, the distal part of the tube will show deployment of three lobes. In this way the lead will fix itself in the target vein. The two lower pictures shows the Starfix lead brought in position in a large postero-lateral vein under fluoroscopy.

4. The ECG in cardiac resynchronization therapy

4.1 Electrocardiographic consequences of different stimulation sites

Bi-ventricular pacing systems for ventricular resynchronization in the treatment of heart failure patients with a QRS complex > 120 ms and LBBB configuration have been employed for over 10 years. In these systems the ventricular stimulus is applied both to a left ventricular lead, positioned in one of the lateral, postero-lateral or posterior branches of the coronary sinus, and a right ventricular lead, positioned in an apical, septal or outflow tract position. Output on both leads can be programmed separately. In a normally functioning biventricular pacing system capture is obtained from both sites and the QRS morphology has a fusion pattern of right and left ventricular pacing.

The paced morphology of the QRS complex is dependent on the anatomical position of the right and left ventricular lead and a number of additional factors. Factors that determine the final morphology are

- 1. Location of the right and left ventricular lead.
- 2. Presence of anodal capture
- 3. The programmed AV interval
- 4. The programmed VV interval
- 5. Intrinsic AV conduction

An interaction between some of these factors also can contribute to the final morphology, like for instance the programmed AV interval and the intrinsic AV conduction, which may lead to fusion between paced and intrinsic ventricular activation.

4.2 The ECG in right ventricular pacing

The morphology for right ventricular pacing can be divided in pacing from the right ventricular apex, right ventricular septum and right ventricular outflow tract. In the following ECG stimulation from these sites in the same patient are demonstrated in figure 16.

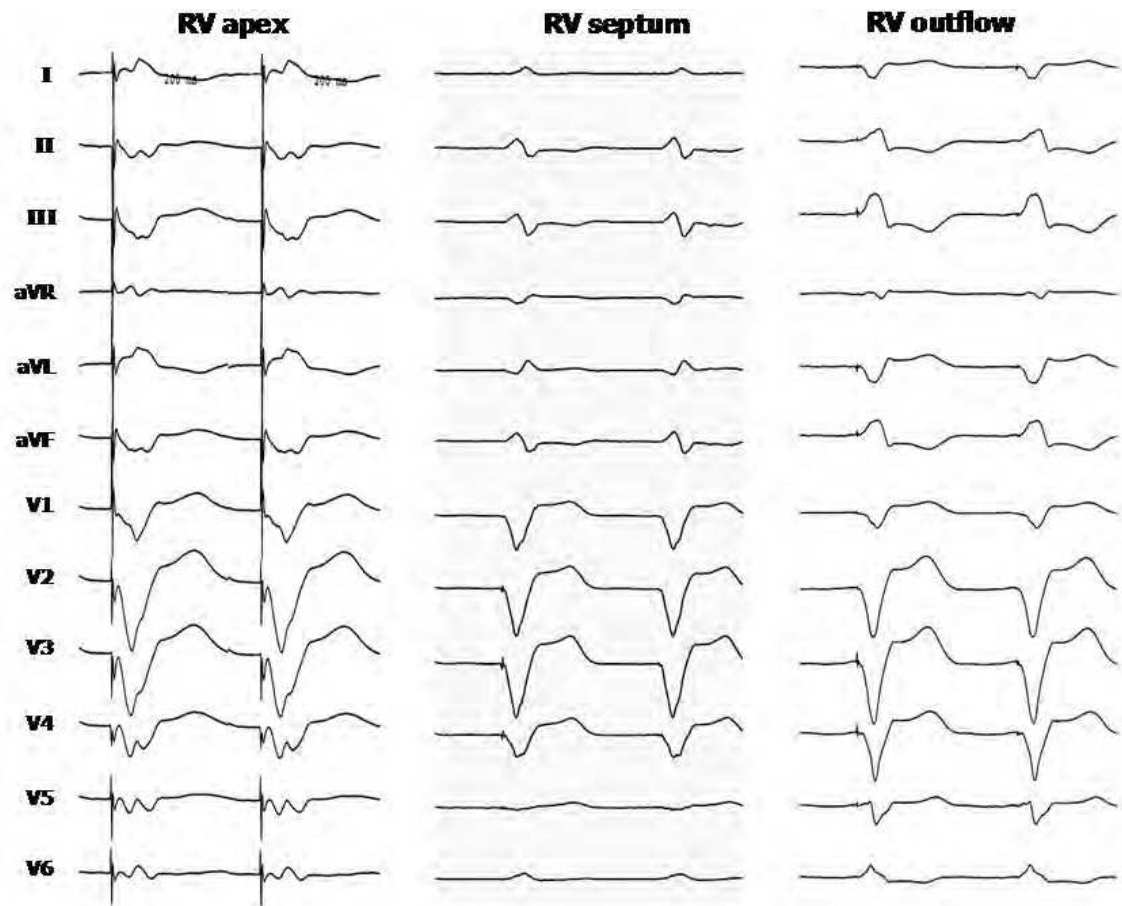


Fig. 16. ECG's from RV apex, RV septum and RV outflow tract.

The difference between the 3 locations is best appreciated from the frontal leads II and III that have a negative deflection during apex pacing (inferior to superior activation), a biphasic configuration during septum pacing indication interior to superior and superior to inferior activation, and a positive configuration during outflow tract pacing (superior to

inferior activation). The precordial leads show a LBBB pattern more or less similar for all locations.

Figure 17 illustrates the effect of location of the RV lead combined with left ventricular pacing from the postero-lateral area.

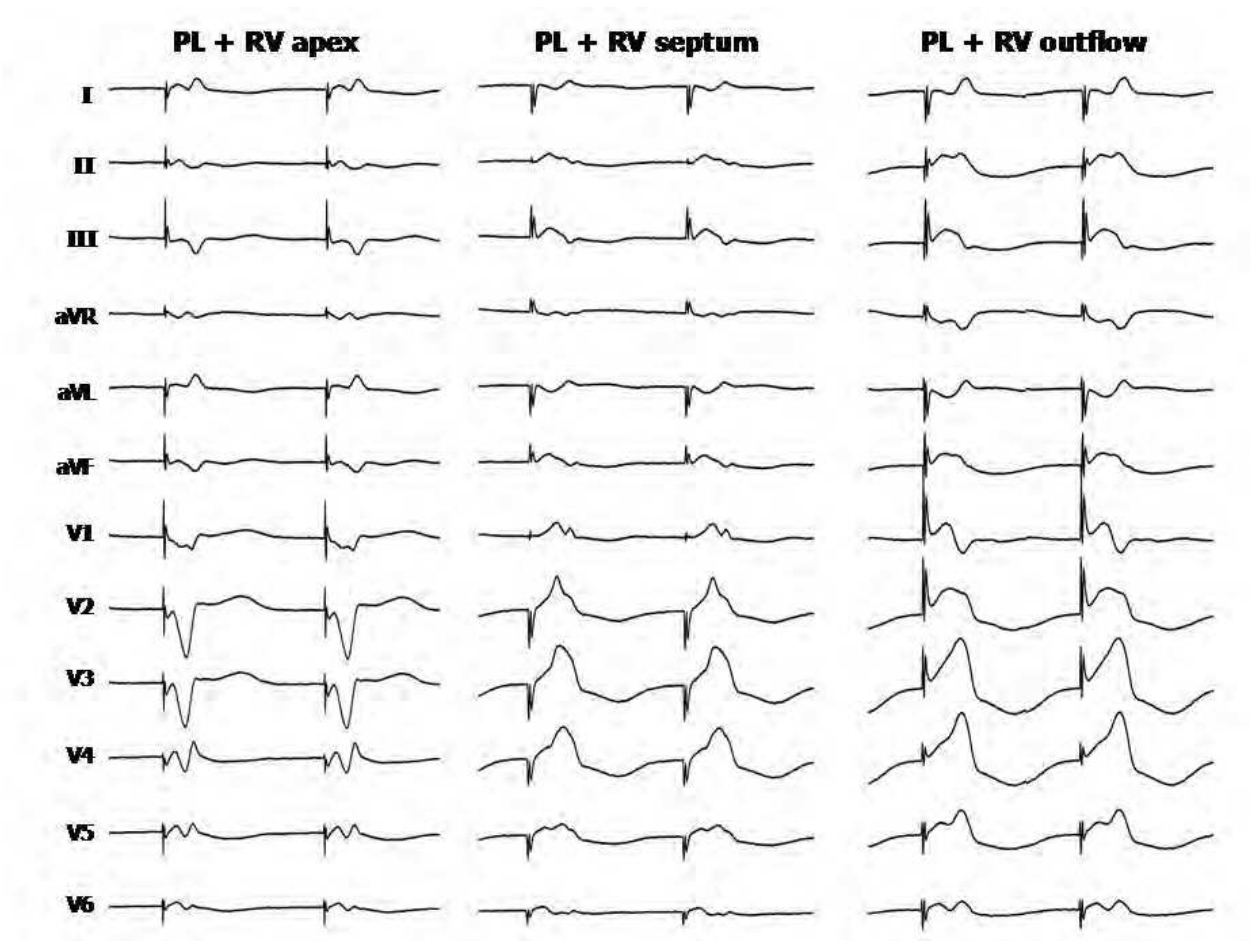


Fig. 17. Twelve lead ECG in biventricular pacing with LV pacing from a postero-lateral (PL) location in the coronary sinus combined with respectively RV apex, RV septum and RV outflow tract pacing.

4.3 The ECG in left ventricular pacing

The morphology of the stimulated QRS complex in left ventricular pacing has more variation than right ventricular pacing, due to the great variation of locations that can be obtained from the coronary venous anatomy. In a cross-section of the left ventricle, the segments can be divided in a posterior, postero-lateral, lateral, antero-lateral and anterior segment. In a longitudinal direction the left ventricle can be divided in 3 segments, the basal, the mid ventricular and apical segment.

Recognition of the longitudinal segment is relatively easy. The basal location will result in activation from superior to inferior, which is best reflected in the frontal plane of the ECG in the lead II and III. Similar an apical location will result in a negative QRS complex in the leads II and III, due to the activation travelling from inferior to superior. A mid segment location will result in a biphasic configuration in the leads II and III.

For the traverse segments during LV pacing the precordial leads are mandatory. For the postero-lateral area the QRS complex in the precordial leads will be positive from V1 to V4-5. For the posterior position the positive morphology will be limited to the leads V1-V3. In the lateral and antero-lateral positions there will a decrease in the positive amplitude in the pre-cordial leads which will gradually change to a negative deflection in the precordial leads. The closer the left ventricular stimulation electrode is located towards the intraventricular septum, the more resemblance there is with the morphology of right ventricular pacing characterized by a left bundle branch block pattern in the pre-cordial leads. The morphology during left ventricular pacing and the location of the stimulation electrode is illustrated in the ECG represented in figure 18.

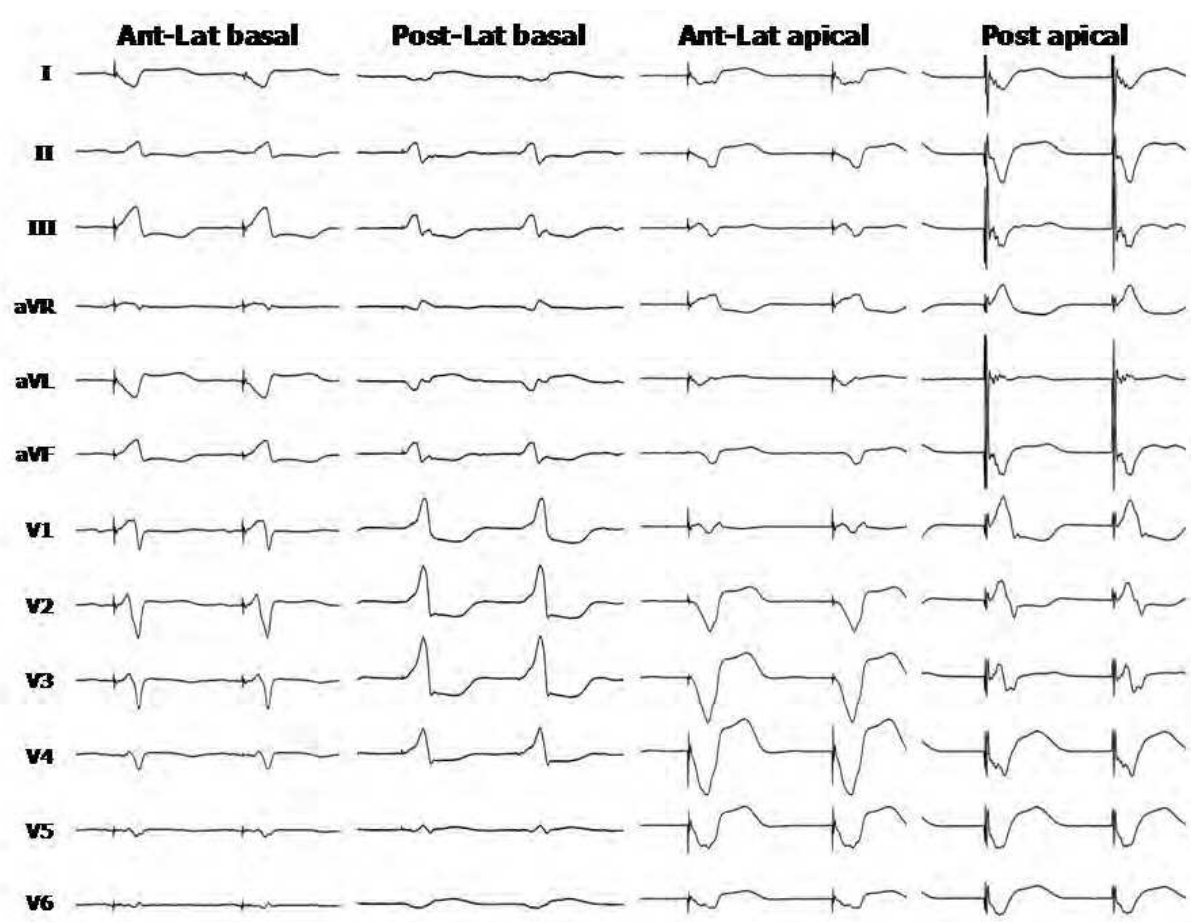


Fig. 18. Twelve lead ECG's from different LV epicardial locations (coronary sinus) illustrating the relationship between QRS morphology and stimulation site. See text for further explanation.

For the determination of the stimulation site with respect to the QRS morphology it is mandatory that left ventricular pacing is pure left ventricular pacing, not associated with any form of fusion with intrinsic activation. When pacing is performed in an atrial synchronous mode in patients with intrinsic AV conduction, the value of the programmed AV interval and the intrinsic AV conduction will determine the presence and degree of fusion (van Gelder et al. 2005). This is illustrated in figure 19.

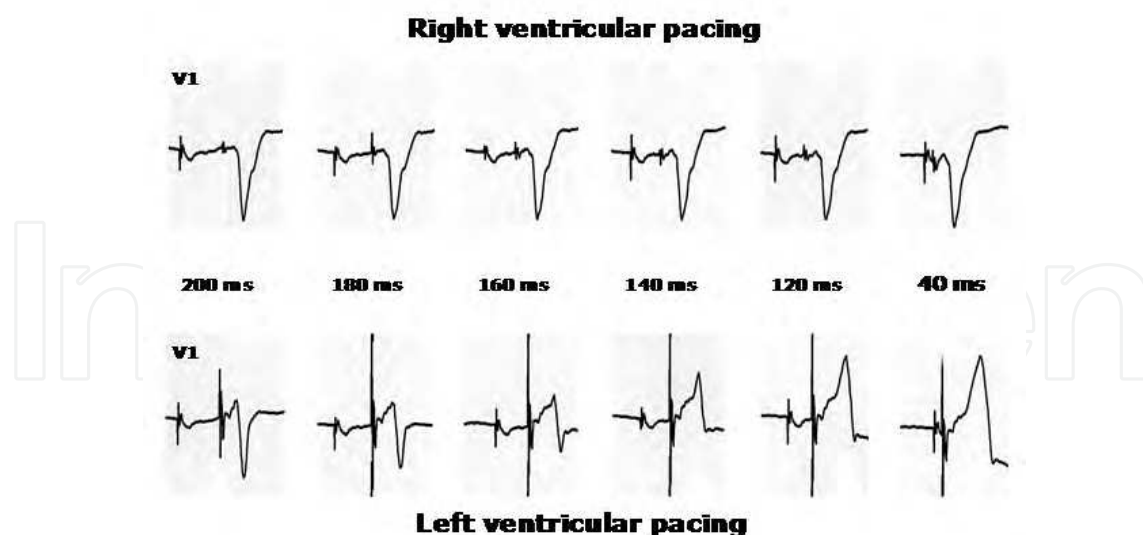


Fig. 19. Right and left ventricular pacing in the same patient with intrinsic AV conduction. Right and left ventricular pacing are performed with varying AV intervals. The RV pacing morphology is not affected by the AV interval. For LV pacing the degree of fusion determines the variation in the QRS morphology.

From this recording it is clearly demonstrated that for obtaining pure LV pacing, when pacing in an atrial synchronous mode, the AV interval should be programmed to the shortest paced AV interval. Pacing in an atrial asynchronous mode (VVI) is no guarantee that fusion is excluded. Fusion can still be present when coincidentally LV pacing occurs simultaneously with intrinsic activation.

4.4 Anodal stimulation in cardiac resynchronization therapy

Primarily LV coronary sinus leads had a unipolar configuration. Therefore the can of the device was used as the positive anodal electrode for LV pacing. In case of pectoral muscle stimulation the pacing configuration could be changed from the LV electrode to the ring electrode of the right ventricular lead. However, in this configuration RV anodal stimulation could be initiated by LV pacing, which resulted in simultaneous pacing from the left and right ventricle (van Gelder et al. 2001). This phenomenon is illustrated in figure 20.

An effective way of avoiding anodal stimulation is programming the device in the unipolar configuration using the can of the device as the anodal electrode (van Gelder et al., 2001). This is illustrated in figure 21, where changing the V-V interval is changing the morphology of the QRS for every value, so V-V programming is not hindered by anodal capture. When however, the LV configuration is changed from LVtip to RVring, in the presence of anodal capture the morphology doesn't change when changing the V-V interval from 80 to 60 and 40 ms. However, when the V-V interval was changed from 40 to 20 ms and subsequently 0 ms changes in the QRS morphology were observed.

This change in morphology is caused by triple site stimulation. When BiV pacing with a V-V interval of 40 ms or more is initiated, the LV stimulus captures LV (cathodal) as well as RV (anodal). This implies that the RV stimulus, which is delivered 40 to 80 ms later, is ineffective because the myocardial tissue is already refractory at the time of delivery of the RV stimulus. The myocardial tissue around the RV tip electrode is not immediately

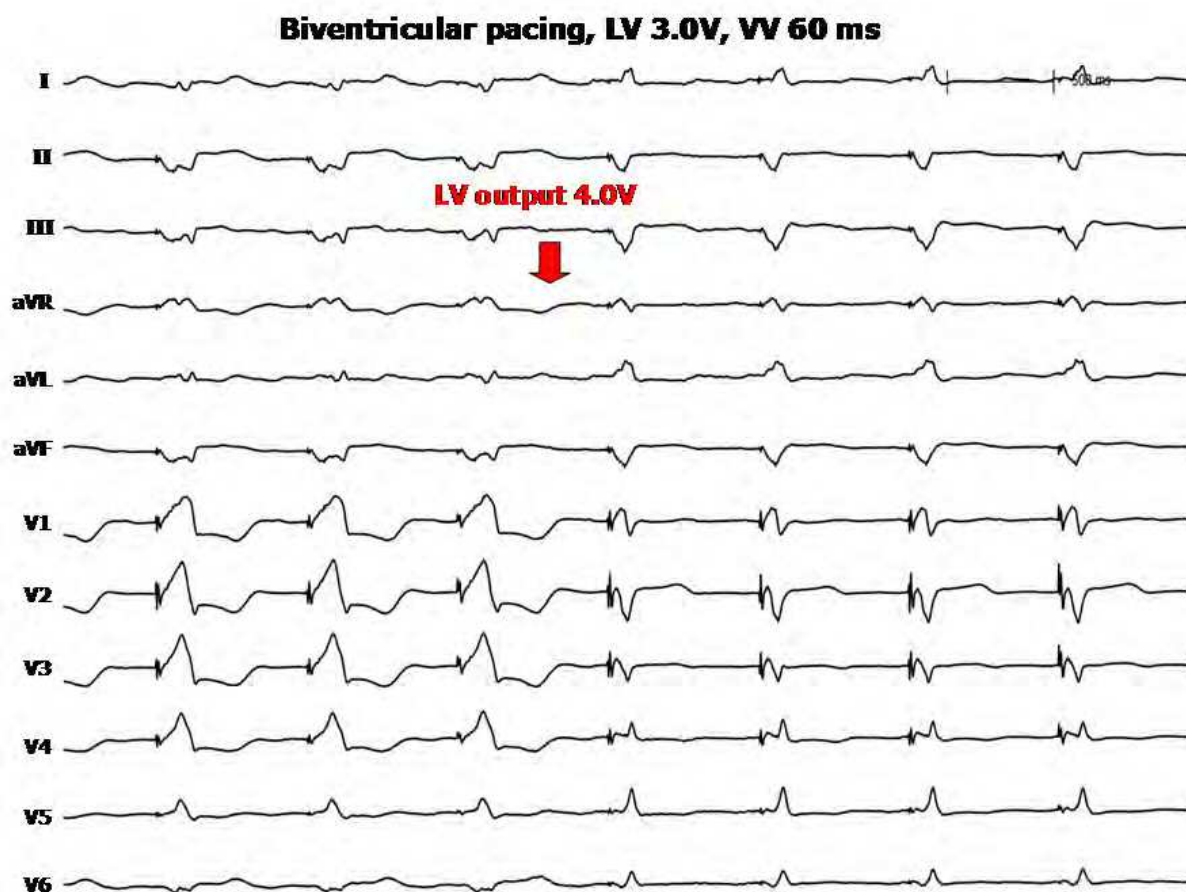


Fig. 20. Twelve lead ECG initially programmed in BiV pacing with LV pacing preceding RV pacing with 60 ms (V-V 60 ms). Because of this programmed value LV pacing dominates ventricular activation (R wave V1-5). But after programming LV output to 4.0V RV anodal capture occurs changing the QRS morphology due to simultaneous biventricular pacing.

refractory when anodal stimulation from the ring electrode occurs. It takes a short time for the anodal RV activation to reach the surrounding tissue of the RV tip electrode. Refractoriness of the myocardial tissue at the time of delivery of the RV stimulus depends on the distance between the ring and tip electrode of the RV lead, the time difference between LV and RV stimulation (V-V interval), and the conduction velocity of the myocardium (van Gelder et al., 2005, Fig. 22).

Anodal stimulation will not be present in configurations where the LV electrode is combined with the coil electrode of an ICD lead as anodal electrode, because of the surface area of this electrode which is around 500 mm². The current density is too low to evoke anodal capture. However, when a true bipolar ICD lead (e.g. Medtronic) is combined with a device of a company that standard uses integrated bipolar (e.g. BostonScientific), programming LVtip to RV coil leads to stimulation between LV tip and RV ring with the potential possibility of anodal capture (van Gelder et al., 2008).

4.5 The lead I paradox

Follow-up is often performed using ECG monitoring with the limb leads, implicating that lead I is the most important indicator for recognition of right or left ventricular activation. We reported on the paradoxical morphology of the QRS complex in lead I, showing a

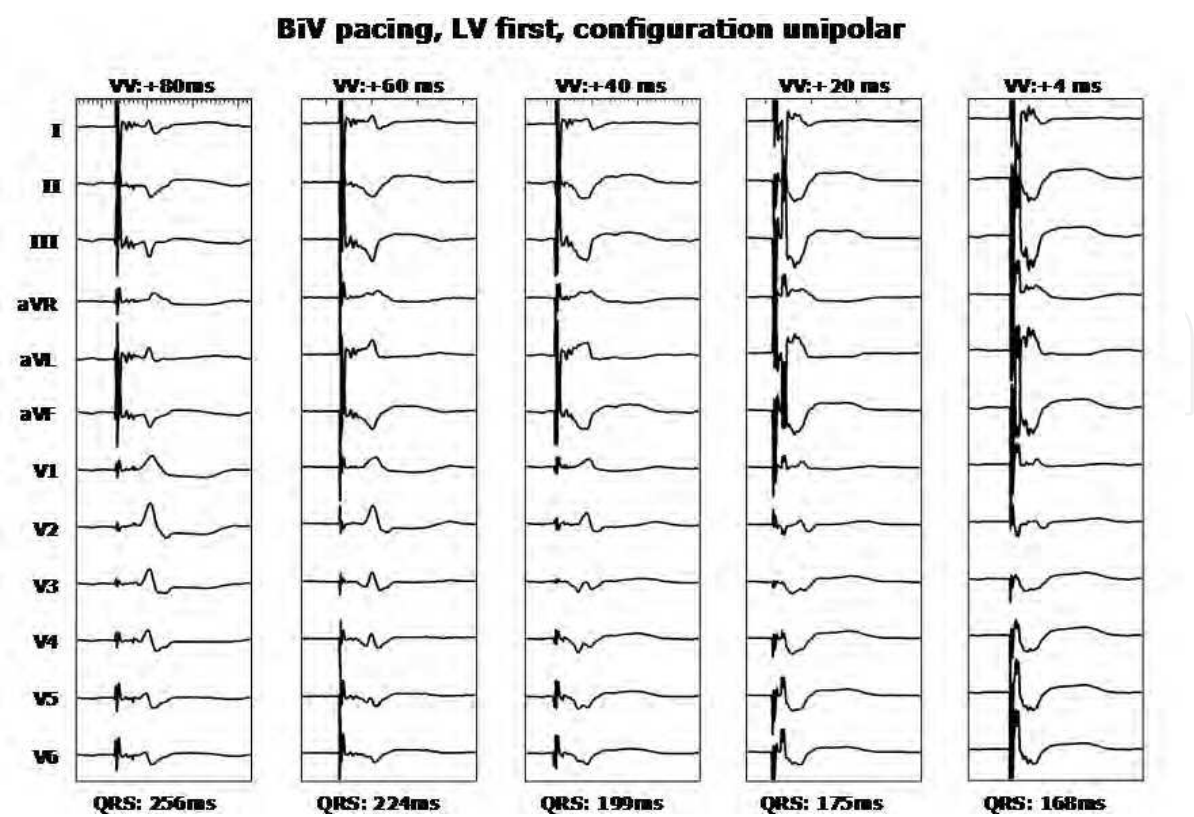


Fig. 21. Changing of V-V interval changes the QRS morphology. See text.

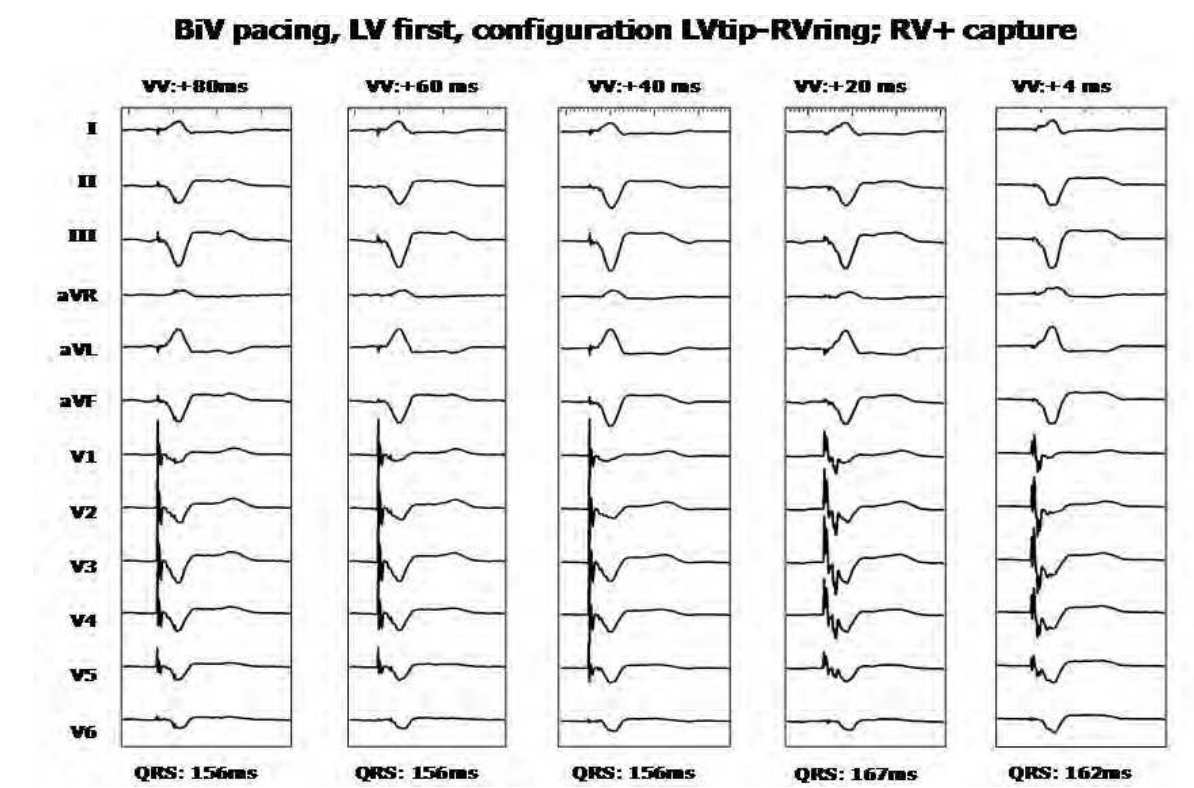


Fig. 22. No change in QRS morphology during anodal capture when programming V-V interval from 80 to 40, but changes are observed after programming V-V interval below 24 ms.

negative complex during right ventricular (RV) pacing and positive during left ventricular (LV) pacing in the same patient (van Gelder et al. 2008). During stimulation at the high septal site of the RV a negative QRS complex in lead I can be recorded. On the other hand a basal position of the LV lead in one of the posterior or postero-lateral veins may result in a positive deflection in lead I. When both phenomenon are present in the same patient, the configuration is in contradiction with the general finding of a positive QRS complex in lead I during RV pacing and negative during LV pacing and was called the lead I paradox. This paradoxical behavior might be an argument to record a precordial ECG lead (preferably V1) in the follow-up of patients with biventricular pacing systems (Fig. 23).

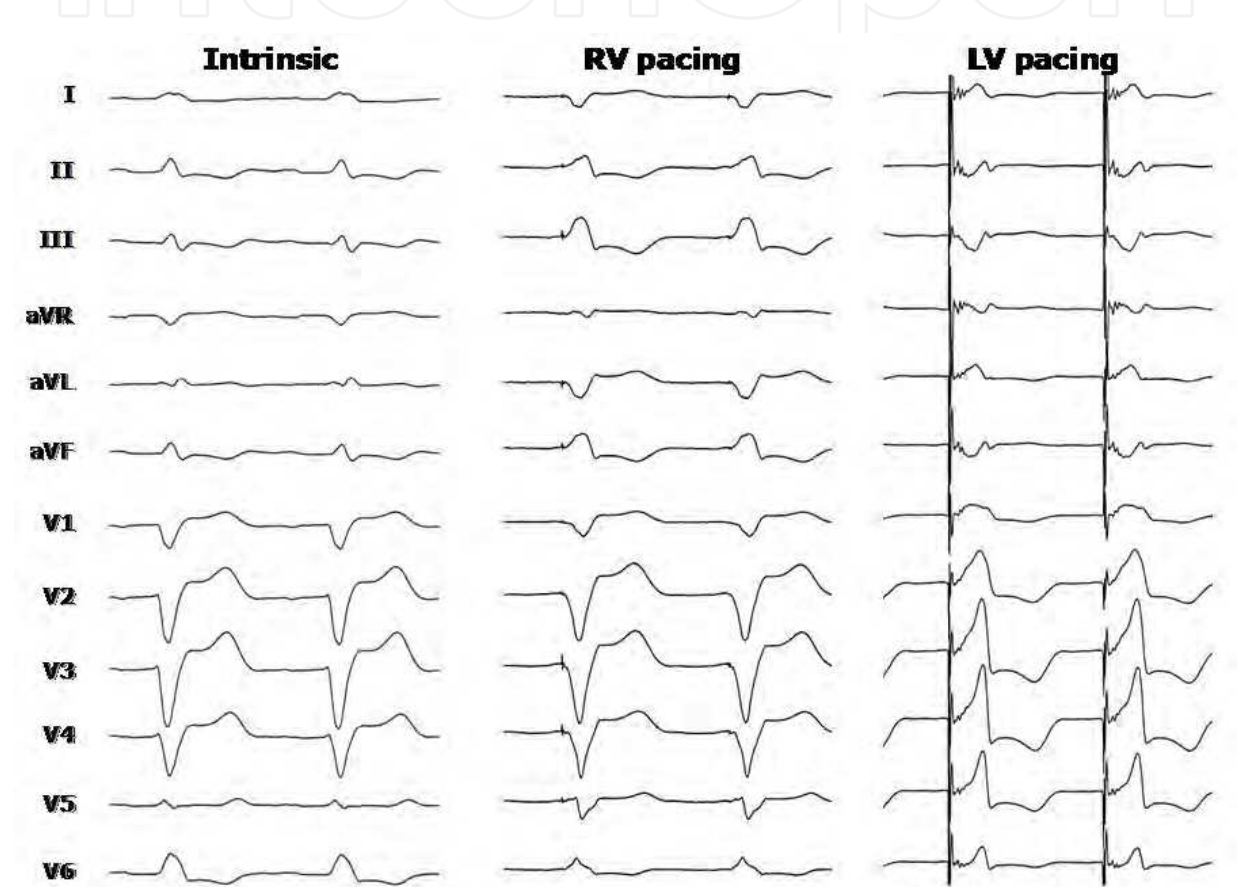


Fig. 23. Twelve-lead ECG of patient 2 showing the paradoxical presentation in lead I of RV and LV pacing. However,in the precordial leads a LBBB pattern is observed during RV pacing and a RBBB pattern during LV pacing.

The paradox in lead I has no relation to each other: a negative QRS complex in lead I during RV pacing has no effect on the positive QRS complex during LV pacing and vice versa. The negative QRS complex in lead I during RV high septal pacing is a known observation described during ventricular tachycardia arising from the RV outflow tract. A more anterior oriented position of the lead in the septum is more prone to this pattern due to the amount of ventricular myocardium depolarized from left to right, which is higher than with a posterior position of the lead. The presence of a preexisting right axis deviation with a negative QRS complex in lead I with fusion or pseudo fusion was ruled out as a cause by programming a short AV interval.

A positive QRS complex in lead I during LV pacing could be explained by the basal position of the LV lead combined with a more horizontal anatomical position of the long axis of the left ventricle or rotation of the left ventricle. Under these conditions, the ventricular myocardium is mainly depolarized in a right to left direction, thus giving rise to a negative QRS complex in lead I. Preexistence of an intrinsic positive QRS complex in lead I could be an explanation for the positive QRS complex during LV pacing due to fusion, which was ruled out as stated before. A positive QRS complex in lead I during LV pacing is also described by Kistler et al. (2003), but in their patient the LV lead was positioned in the great cardiac vein, close to the interventricular septum, whereas in all our patients CS leads were implanted in the postero-lateral area of the left ventricle (Fig. 24). A positive QRS complex during LV pacing can also be observed when anodal stimulation from the RV ring electrode occurs. This RV activation might dominate in the “biventricular” activation resulting in a positive QRS complex. In our patients RV anodal stimulation was ruled out during LV pacing. The presence of scar tissue affecting QRS morphology in these patients was unlikely because the indication was dilated cardiomyopathy in the majority.

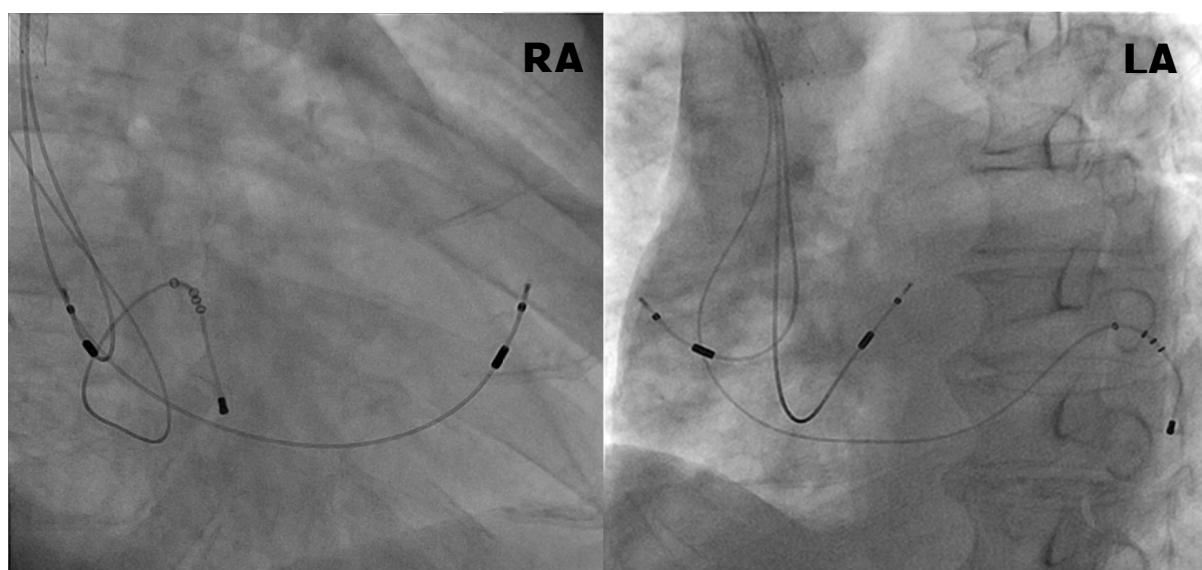


Fig. 24. X rays showing the lead positions in right anterior oblique (RAO) view and left anterior oblique view (LAO) of a patient showing the Lead I paradox, see also figure 23.

4.6 Electrode configuration in coronary sinus leads

The over the wire leads addressed in the previous paragraph all had a unipolar configuration. This implies that LV pacing is delivered between the distal electrode of the CS lead and the can of the device or the anodal electrode of the RV lead. In case of an ICD lead, the coil electrode will serve as the anodal electrode in the majority of cases. One of the drawbacks of this configuration is anodal capture that can occur when a RV ring electrode is used as the anodal electrode. Anodal capture results in simultaneous LV and RV activation, even when a V-V interval with LV pacing preceding RV pacing is programmed, so V-V timing can be deregulated by anodal capture.

Anodal RV capture can easily be prevented by the use of bipolar CS leads (e.g. Medtronic 4194). In this lead the ring electrode has an electrode surface area of 38 mm², but even in

spite of this large surface area stimulation threshold is lower when the coil electrode of an ICD lead, with a surface area of approximately 500 mm² is used as anodal electrode.

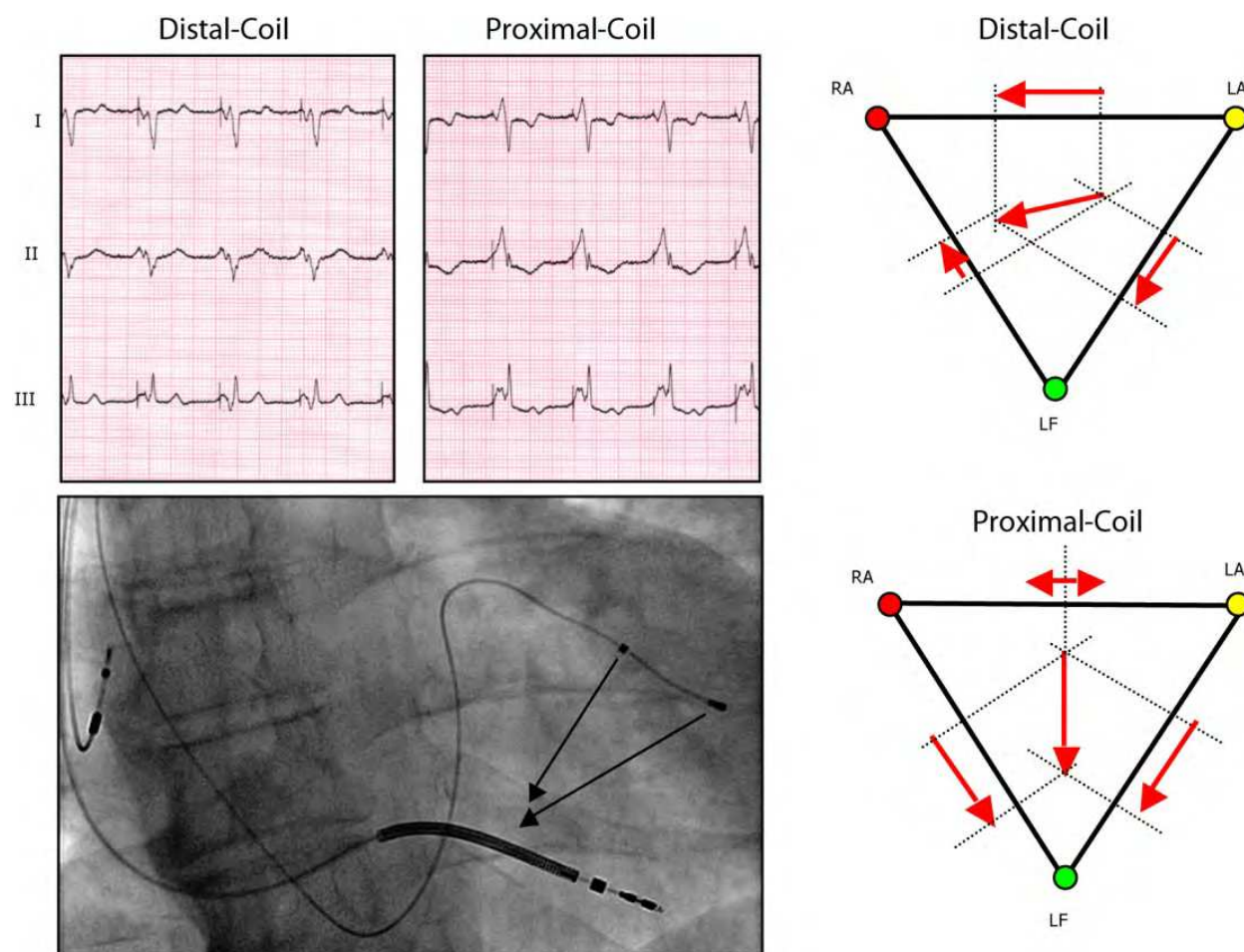


Fig. 25. Dual unipolar lead Medtronic 4196 implanted in a postero-lateral branch of the coronary sinus with the corresponding ECG's from pacing from proximal and distal electrode.

More recently bipolar CS leads are introduced, in which the proximal electrode has a surface area approximately equal to the surface area of the distal electrode (e.g. Guidant Easytrak 2, Medtronic 4196). These leads are far from ideal when used in a bipolar configuration, because the small surface area at the proximal electrode gives a rise in lead impedance without an increase of current efficiency. The idea behind the lead is that the stimulating electrode can be switched from distal to proximal in a unipolar configuration, in which the coil of the ICD lead is used as anodal electrode.

This option creates the possibility of changing non-invasively the pacing configuration, which can be useful in case of phrenic nerve stimulation or high stimulation threshold. The name "dual unipolar" or "dual cathodal lead" better covers the lead options than simply calling it a bipolar lead. In case of acceptable cathodal threshold from both electrodes a selection can be made based on the optimal hemodynamic effect. Figure 25 demonstrates the position of such a lead (Medtronic 4194) with corresponding ECG during LV pacing from the distal and proximal electrode.

Because of the difference in location of the pacing electrodes in the LVtip-can and LVring-can configuration the QRS complex during LV paving also differs and also the hemodynamic effect can be changed by the choice of the stimulation electrode. Since the tip and ring electrode has an equal surface area the bipolar pacing configuration (LVtip-ring) can easily result in dual site pacing due to anodal capture at the ring electrode. This is illustrated in figure 26.

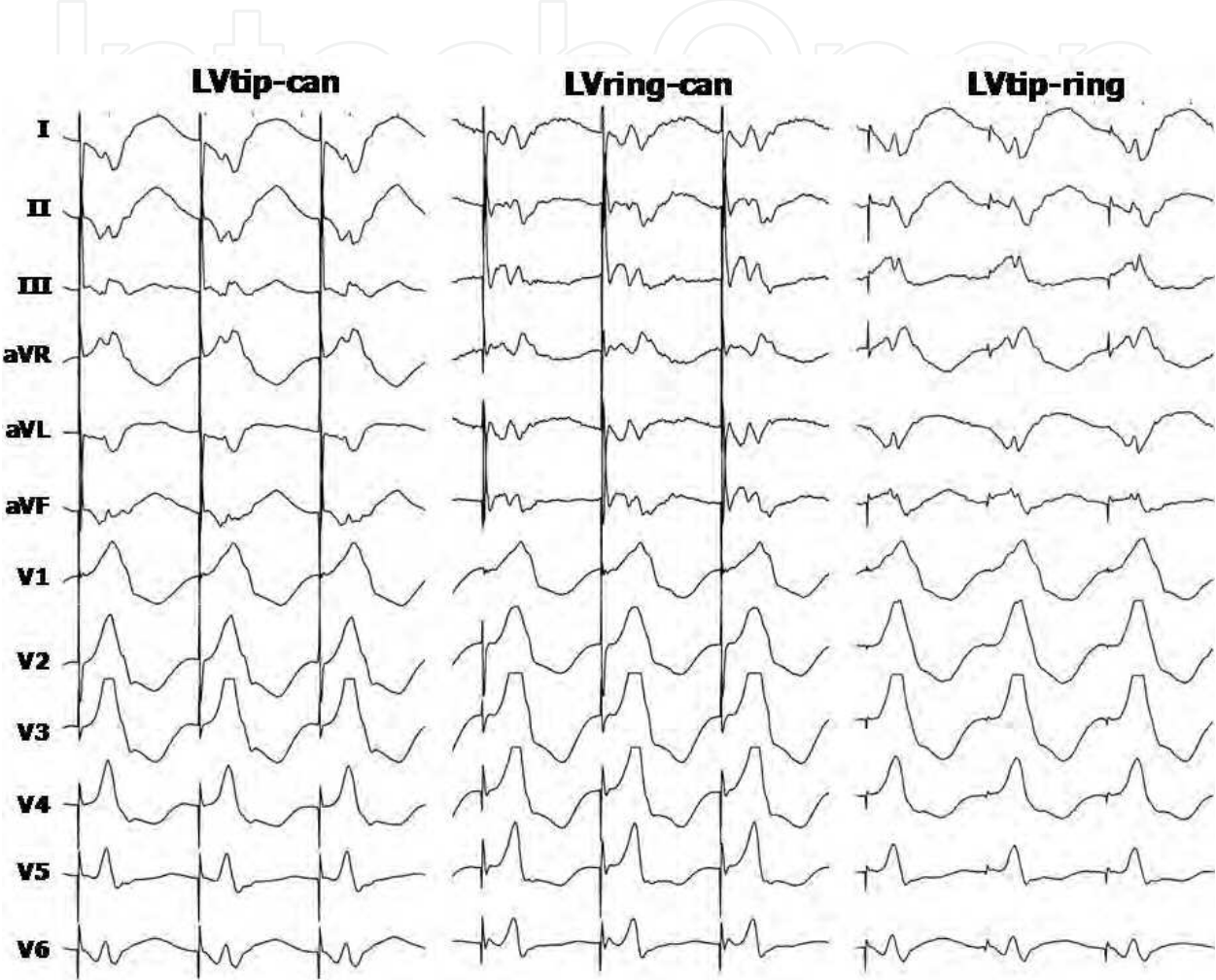


Fig. 26. Twelve lead ECG with unipolar stimulation from tip and ring electrode,(LVtip-can and LVring -can). The morphology of the QRS complex during LVtip-ring pacing has a different morphology from both other configuration indicating dual site LV pacing by anodal capture.

The hemodynamic effect of single and dual site LV paving is demonstrated in figure 27. From our initial experience it is clear that this example is representative for this lead with an inter-electrode distance of 21 mm. The single site best result does not become better by dual site pacing.

In future developments quadripolar CS leads will be employed, which increase the number of pacing vectors thus increasing the possibilities to handle phrenic nerve stimulation or elevated stimulation threshold. However, if this option has also hemodynamic consequences still has to be investigated.

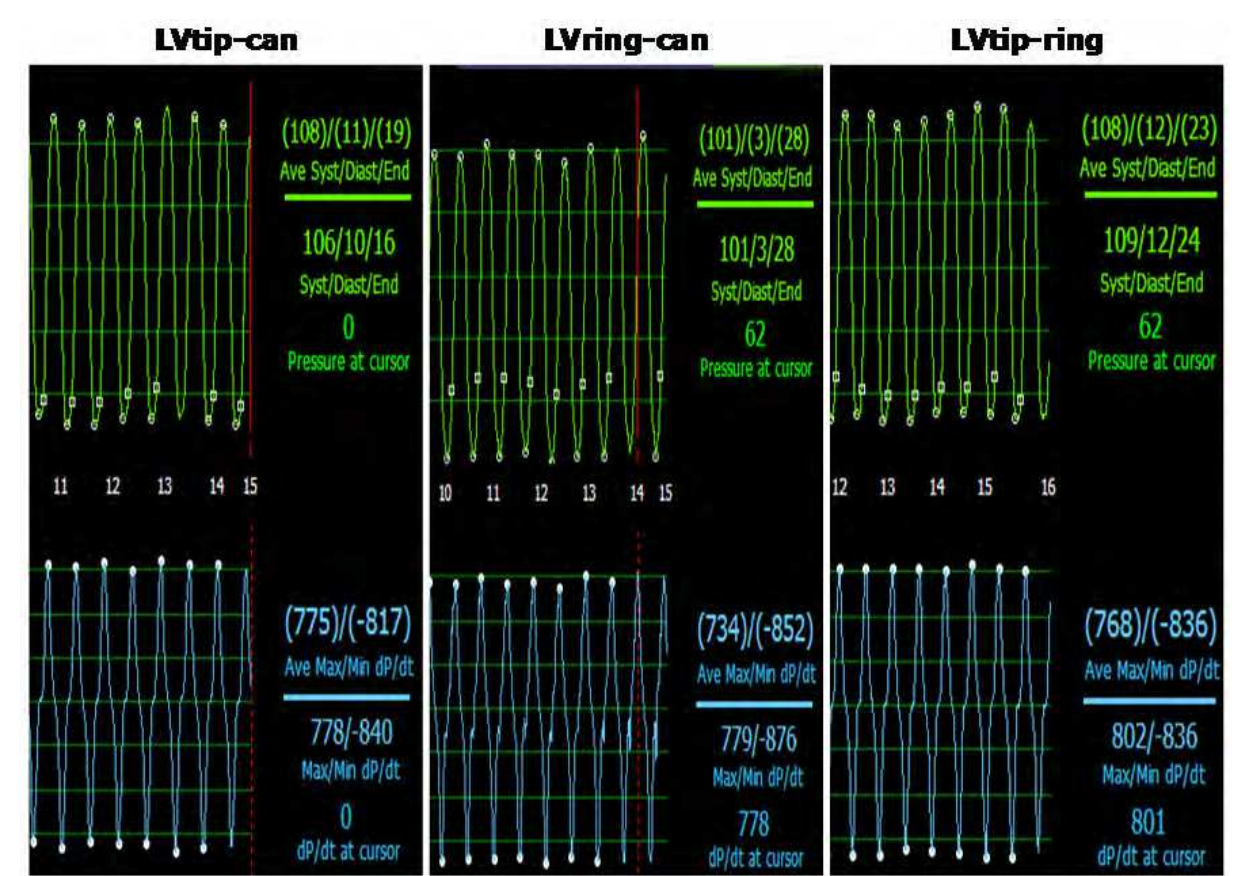


Fig. 27. Hemodynamic effect of single site (*LV tip and LV ring) and dual site LV pacing (LV tip-ring).

5. Slitting or cutting the guiding delivery catheter

The last step during the implantation procedure is the removal of the guiding delivery sheath. This is challenging because dislodgement of the LV lead is frustrating after a fatiguing implantation procedure.

The LV lead is kept in place with a finishing stylet provided with the LV lead. A special cutting device is attached to the lead and the guiding delivery catheter is removed by longitudinal slitting. The guiding delivery sheath is withdrawn in one continuous smooth motion under continuous fluoroscopic observation. Another technique is the use of long finishing stylet to keep the LV lead in place and use the traditional break and peel-away method.

With both techniques the long stylet or the cutting tool must be fixed in place, else redundancy of the LV lead introduces dislodgement, especially at the point the delivery sheath reaches the ostium of the CS. Advancing the finishing stylet or the LV lead at that point into the venous system paradoxically giving too much slack of the LV lead in the right atrium and the LV lead will drop out of the CS. Slight backward traction will prevent dislodgement by straightening the LV lead. Repositioning the LV lead without the back-up of the delivery sheath is occasionally achievable, but generally a new delivery sheath is needed to provide support for the renewed placement of the LV lead.

In case habitual dislodgement occurs the Star-fix LV lead (Medtronic) can be inserted and fixed in the target vein to ensure a supplementary steady position. The finishing wire is drawn back and the LV lead must be secured with tight sewing collars around the sleeve of

the LV lead. The same is done with RA and RV lead and all three leads are attached to the CRT device and the implantation procedure is finished.

6. Problems after LV lead placement

High left ventricular stimulation threshold can be due to the presence of scar tissue, however the place for the LV lead is dictated by the native coronary venous anatomy and sometimes thresholds up to 3.5 Volt at 0.5-msec pulse duration are accepted.

The other problem is left phrenic nerve stimulation causing diaphragmatic contraction. The left phrenic nerve is located anywhere along the lateral wall of the heart as multiple side branches of the phrenic nerve crosses broad areas of the pericardium. Phrenic nerve stimulation is not tolerated by the patient and repositioning of the LV lead is advisable even if pacing at outputs above 5 Volts with acceptable stimulation threshold stimulate the diaphragm. The patient is in a supine position during implantation and after the procedure the diaphragmatic threshold may drop and/or the LV lead threshold may rise with body changes and repositioning the LV lead to a tertiary branch or more proximal in the target vein can prevent a re-intervention with lead repositioning.

The use of bipolar leads does not prevent left phrenic nerve stimulation.

Special LV leads can be used with two electrodes that permit stimulation between one of the two electrodes and the anodal electrode of the RV lead, or coil electrode of the shock lead. Altering the LV-RV pacing vector may prevent left phrenic nerve stimulation. If left phrenic nerve stimulation persists one should go to surgical LV lead placement.

A third problem one can encounter after implantation is ongoing mechanical dyssynchrony despite optimization of the CRT device. This is mostly due to inappropriate LV lead placement and sometimes a second LV lead to recruit more of the left ventricular wall is needed to gain mechanical synchrony. In such a case both LV leads are coupled to a Y-splitter and attached in the LV port of the pacemaker (Fig 28)

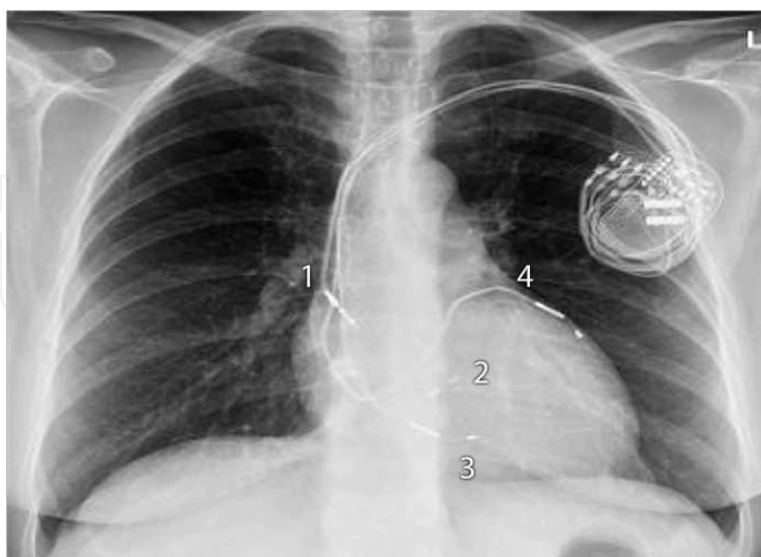


Fig. 28. X-ray of the chest showing a CRT device with a RA lead (1), RV lead (2), and two LV leads. The first LV lead (3) is positioned in a posterior branch. Because no mechanical resynchronization could be obtained a second lead (4) was placed afterwards in an antero-lateral branch, after which mechanical synchrony was achieved.

7. Concluding remarks

The implantation of a LV lead in patients with congestive heart failure is technically a rather complex procedure. Implantation training for CRT has a significant learning curve. Duration of implantation and fluoroscopic time will greatly reduce with experience (Kautzner et al., 2004). Implantation failure is due to inability to intubate the CS, unstable guiding delivery catheter, absence of suitable side branches in the postero-lateral region, coronary vein stenosis or occlusion, lead instability, high stimulation threshold, phrenic nerve stimulation or a combination of the above (Bentkover et al., 2003; Gras et al., 2002).

Success depends on multiple factors including operator's experience and technique, individual anatomy of the CS, threshold and phrenic nerve stimulation regions and available instrumentation and leads. With advanced materials and experienced operators up to 92 % of LV leads are successful via the transvenous approach (León et al., 2005). Complications inherent to LV lead implantation include CS dissection, intimal dissection of the target vein sometimes combined with acute thrombotic occlusion, hematoma in the wall of the target vessel, which can contribute to venous thrombosis and a life threatening complication due to wire exit is coronary venous perforation. Peri-implantation mortality risk is reported 0.4 % from ten pooled studies including 3,223 patients. Re-implantation occurs in 6-8% of patients within 6 months due to LV lead dislodgement, exit block or phrenic nerve stimulation (Greenberg et al., 2003). Further post-implantation risks are similar to conventional pacing. However if placement of a LV lead or the re-implantation fails one should consider surgical placement of an epicardial LV lead, which also can be performed with robotic assistance (DeRose et al., 2005) to provide the patient the benefit of CRT. In case surgery is contraindicated transseptal or transapical approaches with endocardial LV lead should be considered.


8. References

- Abraham WT, Fisher WG, Smith AL et al. For the MIRACLE Study Group. Cardiac resynchronization in chronic heart failure. *N Eng J Med* 2002; 346:1845-1853.
- Ansalone G, Giannantoni P, Ricci R et al. Doppler myocardial imaging to evaluate the effectiveness of pacing sites in patients receiving biventricular pacing. *J Am Coll Cardiol* 2002 106; 39:489-499.
- Bakker P, Meijburg H, De Vries JW et al. Biventricular pacing in end stage heart failure improves functional capacity and left ventricular function. *J Interv Card Electrophysiol* 2000; 4:395-404.
- Bax JJ, Molhoek SG, Erven van L, et al. Usefulness of myocardial tissue Doppler echocardiography to evaluate left ventricular dyssynchrony before and after biventricular pacing in patients with idiopathic dilated cardiomyopathy. *Am J Cardiol* 2003;91:94-97.
- Bentkover JD, Stewart EJ, Ignaszewski A et al. New technologies and potential cost savings related to morbidity and mortality reduction in class III/IV heart failure patients in Canada. *Int J Cardiol* 2003;88:33-41.
- Butter C, Auricchio A, Stellbrink et al. Effect of resynchronization therapy stimulation site on the systolic function of the heart failure patients. *Circulation* 2001;104:3026-3029.
- Cazeau S, Ritter P, Bakdach S et al. Four chamber pacing in dilated cardiomyopathy. *PACE* 1994; 17:1974-1979.

- Chan FP, Napoli A, Narayan G et al. Anatomy of the coronary venous system in patients with left heart failure. *Heart Rhythm* 2004; 1: S-29.
- Daubert JC, Ritter P, Le Breton H et al. Permanent left ventricular pacing with transvenous leads inserted into the coronary veins. *PACE* 1998; 21:239-245.
- DeRose JJ, Ashton RC, Balaram S et al. Robotically assisted left ventricular epicardial lead implantation for biventricular pacing. *J Am Coll Cardiol* 2005;46:2358-2359.
- Gelder B van, Bracke F, Meijer A. The effect of anodal stimulation on V-V timing at varying V-V intervals. *Pacing and Clin Electrophysiol* 2005;8:771 – 776.
- Gelder van B, Scheffer M, Meijer A et al. Transseptal endocardial left ventricular pacing : An alternative technique for coronary sinus lead placement in cardiac resynchronization therapy. *Heart Rhythm* 2007; 4:454-460.
- Gelder van BM, Elders J, Bracke FA, et al. Implantation of a biventricular pacing system in a patient with a coronary sinus not communicating with the right atrium. *PACE* 2003;26:1294-1296.
- Gelder van BM, Meijer A, Bastings P et al. Successful implantation of a coronary sinus leads after stenting of a coronary vein stenosis. *Pace* 2003;26:1904-1907.
- Gelder van BM, Bracke FA, Meijer A and Pijls NHJ The Hemodynamic Effect of Intrinsic Conduction During Left Ventricular Pacing as Compared to Biventricular Pacing *JACC* 2005; 46: 2305-2310
- Gelder van BM, Bracke, FA, Meijer A, Pilmeijer A. Triple-site ventricular pacing in a biventricular pacing system. *Pacing and Clin Electrophysiol* 2001;24:1165-1167
- Gelder van BM and Bracke FA. The ECG Lead I paradox in cardiac resynchronization therapy. *Pacing Clin Electrophysiol* 2008;31: 1519-1521
- Gibson DG, Chamberlain DA, Colart DJ et al. Effect of changes in ventricular activation on cardiac haemodynamics in man. Comparison of right ventricular, left ventricular and simultaneous pacing of both ventricles. *Br Heart J* 1971: 33:397-400.
- Gras D, Leclercq C, Tang AS et al. Cardiac resynchronization therapy in advanced heart failure : the multicenter inSync clinical study. *Eur J Heart Fail* 2002;4:311-320.
- Greenberg JM, Mera FV, Delurgio DB et al. Safety of implantation of cardiac resynchronization devices: A review of major biventricular pacing trials. *PACE* 2003;26:952.
- Hansky B, Lamp B, Minami K et al. Coronary vein balloon angioplasty for left ventricular pacemaker lead implantation. *J Am Coll Cardiol* 2002; 40:2144-2149.
- Jaïs P, Douard H, Shah DC et al. Endocardial biventricular pacing. *PACE* 1998 ; 21 :2128-2131.
- Kassai I, Foldesi C, Szekely A,, Szili-Torok T. Alternative method for cardiac resynchronization. Transapical lead implantation. *Ann Thoracic Surg* 2009;87(2):650-652.
- Kautzner J, Riedlbauchová L, Čihák R et al. Technical aspects of LV lead for cardiac resynchronization therapy in chronic heart failure. *PACE* 2004;27:783-790.
- Kistler PM, Mond HG, Corcoran SJM. Biventricular pacing: It isn't always as it seems. *Pacing Clin Electrophysiol* 2003; 26:2185-2187
- Leclercq F, Hager FX, Macia JC et al. Left ventricular lead insertion using a modified transseptal catheterization technique: a totally endocardial approach for permanent biventricular pacing in end-stage heart failure. *PACE* 1999; 22:1570-1575.

- León AR, Delurgio DB, Mera F. Practical approach to implanting left ventricular pacing leads for cardiac resynchronization. *J Cardiovasc Electrophysiol* 2005;16:100-105.
- Leon AR, Abraham WT, Curtis AB et al. Safety of transvenous cardiac resynchronization system implantation in patients with chronic heart failure: combined results of over 2000 patients from a multicenter study program. *J Am Coll Cardiol* 2005;46:2348-2356.
- Scheffer M, Dessel van PFHM, Gelder van B, et al. Peak longitudinal strain delay is superior to TDI in the selection of patients for resynchronization therapy. *Neth Heart J* 2010;18:574-582.
- Swedberg K, Cleland JG, Dargie H et al. Guidelines for the diagnosis and treatment of chronic heart failure: executive summary (update 2005). Task Force for the diagnosis and treatment of Chronic Heart Failure of the European Society of Cardiology. *Eur Heart J* 2005; 26:1115-1140.
- Tyers GF. Comparison of effect on cardiac function of single-site and simultaneous multiple-site ventricular stimulation after A-V block. *J Thorac Cardiovasc Surg* 1970; 59:211-217.
- Vagnini FJ, Gourin , Antell HI et al. Implantation sides of cardiac pacemaker electrodes and myocardial contractility. *Ann Thorac Surg* 1967; 4:431-439.
- Yu CM, Sanderson JE, Fan K, et al. Tissue Doppler echocardiographic evidence of reverse remodeling and improved synchronicity by simultaneously delaying regional contraction after biventricular pacing therapy in heart failure. *Circulation* 2002;105:438-445.

IntechOpen



Advances in Electrocardiograms - Methods and Analysis

Edited by PhD. Richard Millis

ISBN 978-953-307-923-3

Hard cover, 390 pages

Publisher InTech

Published online 25, January, 2012

Published in print edition January, 2012

Electrocardiograms are one of the most widely used methods for evaluating the structure-function relationships of the heart in health and disease. This book is the first of two volumes which reviews recent advancements in electrocardiography. This volume lays the groundwork for understanding the technical aspects of these advancements. The five sections of this volume, Cardiac Anatomy, ECG Technique, ECG Features, Heart Rate Variability and ECG Data Management, provide comprehensive reviews of advancements in the technical and analytical methods for interpreting and evaluating electrocardiograms. This volume is complemented with anatomical diagrams, electrocardiogram recordings, flow diagrams and algorithms which demonstrate the most modern principles of electrocardiography. The chapters which form this volume describe how the technical impediments inherent to instrument-patient interfacing, recording and interpreting variations in electrocardiogram time intervals and morphologies, as well as electrocardiogram data sharing have been effectively overcome. The advent of novel detection, filtering and testing devices are described. Foremost, among these devices are innovative algorithms for automating the evaluation of electrocardiograms.

How to reference

In order to correctly reference this scholarly work, feel free to copy and paste the following:

Michael Scheffer and Berry M. van Gelder (2012). Implantation Techniques of Leads for Left Ventricular Pacing in Cardiac Resynchronization Therapy and Electrocardiographic Consequences of the Stimulation Site, *Advances in Electrocardiograms - Methods and Analysis*, PhD. Richard Millis (Ed.), ISBN: 978-953-307-923-3, InTech, Available from: <http://www.intechopen.com/books/advances-in-electrocardiograms-methods-and-analysis/implantation-techniques-of-leads-for-left-ventricular-pacing-in-cardiac-resynchronization-therapy-an>

INTECH
open science | open minds

InTech Europe

University Campus STeP Ri
Slavka Krautzeka 83/A
51000 Rijeka, Croatia
Phone: +385 (51) 770 447
Fax: +385 (51) 686 166
www.intechopen.com

InTech China

Unit 405, Office Block, Hotel Equatorial Shanghai
No.65, Yan An Road (West), Shanghai, 200040, China
中国上海市延安西路65号上海国际贵都大饭店办公楼405单元
Phone: +86-21-62489820
Fax: +86-21-62489821

© 2012 The Author(s). Licensee IntechOpen. This is an open access article distributed under the terms of the [Creative Commons Attribution 3.0 License](https://creativecommons.org/licenses/by/3.0/), which permits unrestricted use, distribution, and reproduction in any medium, provided the original work is properly cited.

IntechOpen

IntechOpen