

# We are IntechOpen, the world's leading publisher of Open Access books Built by scientists, for scientists

6,900

Open access books available

186,000

International authors and editors

200M

Downloads

Our authors are among the

154

Countries delivered to

TOP 1%

most cited scientists

12.2%

Contributors from top 500 universities



WEB OF SCIENCE™

Selection of our books indexed in the Book Citation Index  
in Web of Science™ Core Collection (BKCI)

Interested in publishing with us?  
Contact [book.department@intechopen.com](mailto:book.department@intechopen.com)

Numbers displayed above are based on latest data collected.  
For more information visit [www.intechopen.com](http://www.intechopen.com)



# Computer Assisted Orthopedic Surgery in TKA

Eun Kyoo Song and Jong Keun Seon  
Chonnam National University Hwasun Hospital  
Korea

## 1. Introduction

Since Campbell and Boyd first developed a mold hemiarthroplasty in 1940, the procedure for a total knee arthroplasty has advanced greatly with the development of new materials and the increasing understanding of the knee joint biomechanics. And accurate alignment of the component and soft tissue balancing has been cited as the essential for the success of total knee arthroplasty. Although mechanical alignment guides have been designed to improve alignment accuracy, there are several fundamental limitations of this technology that will inhibit additional improvements. The long-term survival rate of a total knee arthroplasty after a 10-year follow up was reported to be 80% to 95% (Knutson et al., 1986; Ranawat et al., 1993; Scuderi et al., 1989). Various factors affect this long-term survival, the most closely related factor being the physiologic recovery of the leg alignment (Laskin, 1984; Ritter et al., 1994). Upon a follow-up study of more than 8 years, the loosening rate was only 3% in those patients with a correctly recovered leg alignment, but was 24% in those with an incomplete recovery of the leg alignment (Stulberg et al., 2002). There are limits on improving the alignment accuracy using a conventional total knee arthroplasty. Teter et al. (Teter et al., 1995) found that when a tibial extramedullary alignment guide was used, approximately 8% of the cuts were deviated 4 degrees of the ideal 90 degrees cut (perpendicular to the mechanical axis). However, this finding was based on coronal imaging, and the rate of malalignment may be considerably greater when the sagittal imaging is considered. Computer-assisted surgery (CAS) was introduced to overcome these difficulties and errors. Computer-assisted total knee arthroplasty has gained increasing acceptance among orthopedic surgeons as a technique to improve surgical precision and patient outcomes.

## 2. The history of computer assisted TKA

Computer-assisted surgery was first introduced in the neurosurgical field in 1980s to find surgical sites in the brain or spinal cord accurately. In orthopedic surgery, the American veterinarian Howard Paul and the orthopedic surgeon William Bargar first sought to improve femoral stem incorporation during total hip arthroplasty (THA), and devised a new drill to achieve a precise match for femoral prostheses. In fact, this concept was the basic idea that drove the development of medical robot. In 1986, Davis started a joint project between IBM (International Business Machine Corp.) and the University of California to

develop the ROBODOC®(Integrated Surgical Systems, Davis, CA) system. As a resultant, Integrated Surgical Systems (ISS) was founded by IBM in 1990, and subsequently, the first robot-assisted THA was performed on a human in 1992 in California using the ROBODOC system, which was later approved by the European Union in 1994. In 1997, Saragaglia developed a navigation system called Orthopilot®(Aesculap, Tuttlingen, Germany), which allows surgeons to perform surgery without any other imaging technique.

These Computer-assisted Orthopedic Surgery (CAOS) techniques were developed to minimize errors due to malalignment and inappropriate prosthesis insertion. The navigation system produced good results clinically and radiologically, but other factors, such as, the subtle movements of cutting blocks and the vibration of oscillating saws were then focused on as potential causes of inaccurate bone cutting, and these efforts resulted in the developments of robot systems. The ROBODOC and CASPAR systems were introduced almost simultaneously in Germany in 2000, and used to conduct the first robotic TKA in the same year. In 2007, ISS was purchased by the South Korean company Curexo, and in 2008 the FDA approved ROBODOC for THA. However, the FDA has not yet to approve ROBODOC for TKA. Nevertheless, 10 institutions in South Korea and 60 institutions worldwide use the ROBODOC system for TKA.

### **3. Navigation-assisted TKA**

#### **3.1 Classification**

Many manufacturers produce navigation-assisted surgery systems and it is difficult to classify. However they can be divided into two groups based on their dependence to imaging; image based systems and image free systems.

##### **3.1.1 Image based system**

Image based navigation systems use the data acquired from computed tomography or fluoroscopy to determine operating factors, such as, joint centers, the movement tracks of surgical tools, and the alignments of prostheses. These systems require the registration of a CT image acquired prior to surgery, or the registration of fluoroscopic data during surgery, where registration means not only inputting CT or fluoroscopic data, but also matching imaging data to joint kinematic information acquired during surgery and bone dimensional information acquired using indexes and calipers. By using kinematic and surface registration data, the system determines in real-time the location of the bone resection site, placement and alignment of the cutting block, and joint alignment for the prosthesis concerned. Surgery is then performed according to the data produced.

Accordingly, the registration process is perhaps the most critical for image based systems. The accuracy of registration can be detrimentally affected when border lines on CT images are blurred or segmented, cortical fixation screws are loose, or when computer hardware or software is defective. All image based systems can perform fluoroscopic registration automatically during surgery. However, this can be inconvenient because the fluoroscope is needed during operation.

##### **3.1.2 Image free system**

Although image based systems are useful during preoperative planning and postoperative evaluation, the image-acquiring process can be time-consuming and troublesome, and

consequently, image free systems are becoming more popular. These systems track the sizes, shapes, locations, and alignments of musculoskeletal structure based on a standard human frame in real-time during surgery, and then register and guide bone resection using navigation. Image free systems need tracking cameras and markers, the latter of which are referred to as rigid bodies, because they are fixed onto bones (at least four sites) with a pin or clamp. In addition, the tools and calipers used also have tracing markers that used by the system to guide the operative procedure. Optical systems use infrared lights and electromagnetic systems use electromagnets to detect markers. Systems based on the use of ultrasound are also under development, and have been reported to have errors of < 1mm or 1° of error range.

3.1.2.1 Optical systems

Both active and passive optical systems are available. Active systems have an LED (light-emitting diode) attached to each rigid body that emits infrared signals that are captured by a camera, whereas passive systems have a reflecting sphere attached to each rigid body, and the system senses the reflection of light emitted from an LED source mounted on the camera. It should be noted that signal interpretation depends on the amount of light detected, and thus, the active type requires a cable type or a battery type probe, and the passive type requires that the reflecting spheres are meticulously cleaned. For the active type, surgery starts with the attachment of a rigid body to the tibia and femur; the infrared LEDs are then attached using a cortical screw. When the hip, knee, and ankle joint are moved in sequence, LEDs emit infrared and the optical localizer monitors and calculates the joint centers and the movement ranges of the three joints 3-dimensionally to determine the location of the mechanical axis (kinematic registration). During surgery, the surgeon uses a pointer to mark the bony and articular landmarks and notes useful surgical information, such as, the locations and orientations of the femur and tibia. Using this information, the surgeon can promptly identify the optimal bone cutting line, and decide on its direction and position.

The ligament tensioner can be used to balance the ligament by tensioning the internal and external lateral ligament, and the internal and external knee joint gaps can then be measured in extension and flexion, which allows the external rotation range to be adjusted in accordance with flexion and extension intervals during distal femur anterior and posterior side dissections. In addition, It can assess implant size and location, which enables the surgeon to consider individual joint properties.

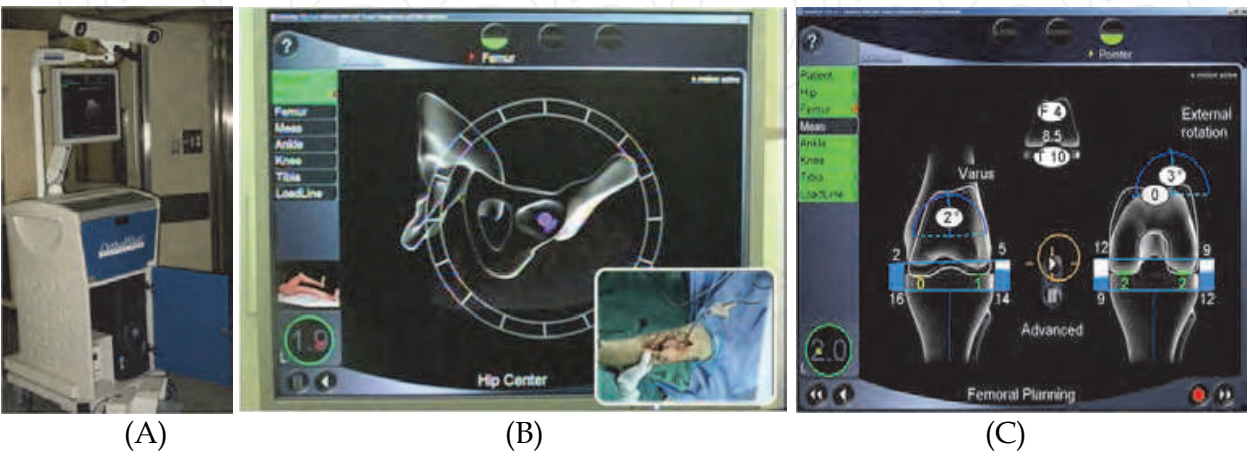


Fig. 1. Optical navigation system. (A) Appearance, (B) and (C) Different monitor views.

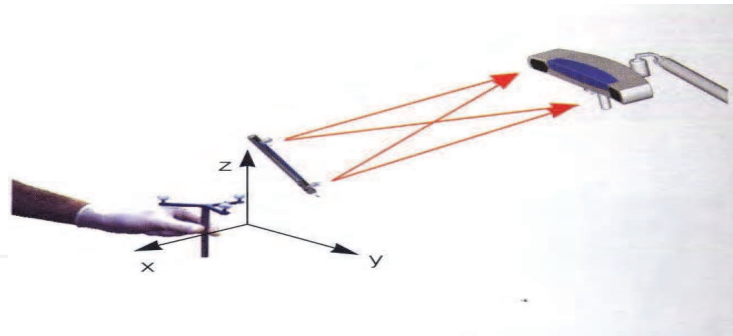


Fig. 2. Optical camera

The optical system of image free systems is fast and highly accurate, but operators should be careful about individual positioning to ensure visualization of the surgical field. The field can also be influenced by illumination intensity, and according to Tria (Tria et al, 2006), this system uses a large transmitter, which requires additional skin incision and a larger drill hole to hold the transmitter.

### 3.1.2.2 Electromagnetic Computer System (EMC)

As its name implies the EMC system is based on the detection of a weak magnetic field by sensors, transformed to digitalized voltage by receivers, and then transmitted to a computer. The magnetic field is produced by a localizer using direct or variable currents, although direct currents operation provides a more stable magnetic field. The localizer contains at least three generator coils and the coil numbers to a large extent dictate the performance of system because precision is dependent on the coil number. On the other hand, larger capacity computers are required for high coil numbers. EMC systems use dynamic reference frames (DRFs), which function as trackers, and resulting movement information can be used during surgery.

The early computer-based navigation systems had some disadvantages, such as, limited camera field of view, the requirement for sterilization, damage and tethering of soft tissue, and disruption of the surgical field by large surgical instruments. To avoid these disadvantages, researchers attempted to use non-line-of sight signals, which represented the beginning of EMC.

The EMC system was first applied in the pediatric neurologic surgical and ENT fields. In the orthopedic field, it was used secondary to conventional navigation due to signal instabilities, metallic interference, and its slower speed, which was caused by positional changes. However, after the coil number was increased and by enabling it to be attached to soft tissue, it has been more widely used.

The EMC system has the advantage of convenience during surgery, because it is not affected by the surgeon's position. Furthermore, gap balance is easily matched because the real shape of bone and dimensional data can be seen simultaneously. In addition, when a bone excision is incorrect, it can be corrected promptly, and because surgical instruments were small, it can easily be used during 'Minimal Invasive Surgery'. However, the EMC system suffers from distortion and low speed, and its safety has not been proven in humans. Furthermore, costs are high because the coil can only be used once.

Distortions can be classified as being due to conduction distortions and ferrous interference. When distortions are present, data may be incorrect or the monitor screen freezes or displays 'no reading'. Conduction distortions can be caused by most metals, including



aluminum, and carbon based materials, although titanium causes less distortion. Metal disturbances are more problematic when the ferrous content is high, and thus, efforts must be made to eliminate ferrous content from the proximity of the unit system, for example, a ‘fluoroscopy-possible’ operating table should be used and EMC instruments should be located near the surgical field. In addition, it should be added that surgeons require training and experience of the EMC system.

However, EMC represents advancement over other navigation systems because gap balance can be easily adjusted, incorrect bone dissection can be corrected promptly, and because its small size is useful for minimally invasive surgery.

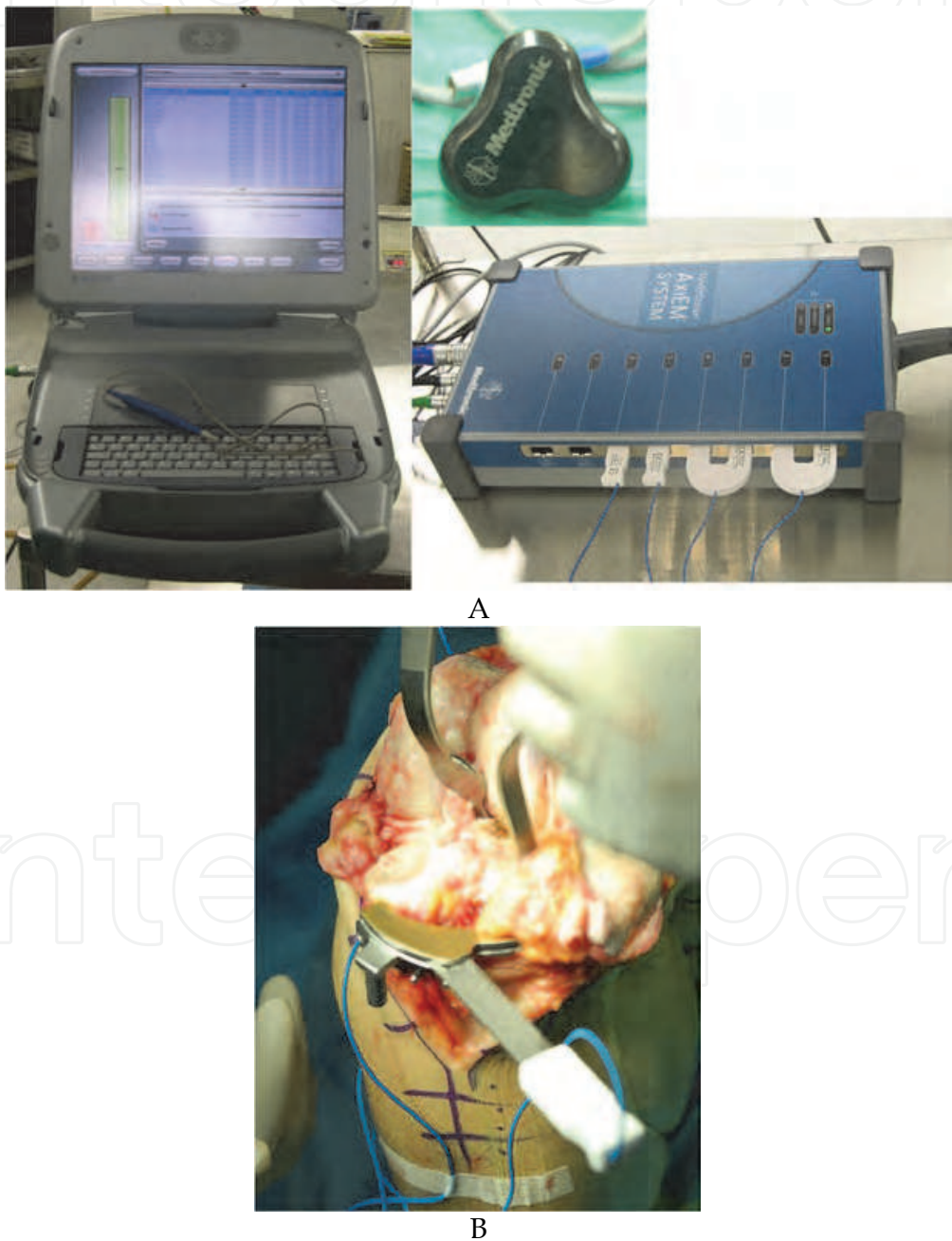


Fig. 3. Electromagnetic navigation system. (A) A structure; monitor, detector. (B) Intraoperative instrument.

According to Seon and Song(Seon and Song, 2004), the above two navigation systems showed more than a  $3^\circ$  malalignment in 15% of patients. It was suggested that this was caused by anatomical point ambiguity in real patients and registration failure. Furthermore, when registration failure occurs, EMS determined mechanical axis are more affected, and thus, these two authors concluded that EMS is more inaccurate than optical system.

### 3.2 Advantages and disadvantages navigation-assisted TKA

#### 3.2.1 Advantages

##### 3.2.1.1 Limb alignment

Many researchers have demonstrated the accuracy of lower leg alignment and the excellent implantation offered by navigation systems for TKA. Bathis et al.(Bathis et al., 2004) prospectively compared 80 TKAs performed using a navigation system with 80 TKAs performed using a conventional method, and found that varus and valgus angles of the mechanical axis and femur implantation in the coronal plane were more precise in the navigation group. Sterlbug et al. (Sterlbug et al., 2002) evaluated the precision of implantation and lower leg alignment after TKA using a conventional intramedullary guide. Their findings suggested that femoral implants tend to be varus, flex, internally rotate, and that tibia implants tend to be placed in varus position . There was no misalignment of more than  $3^\circ$ , and only 4 of 20 cases showed less than  $3^\circ$  alignment in the coronal or axial plane.

This result supports the previously reported argument that conventional TKA tends to cause varus, and that the margin of error between femur and tibia implantation could be less than  $1^\circ$ , which reduces the overall alignment error and can enhance surgical accuracy. According to comparative studies on navigation and conventional surgery groups, navigation systems showed statistically better results in terms of mechanical axis recovery, far fewer outliers, and more precise femur implantation in the coronal and axial planes.

The following features of navigation system can lead to precise lower leg alignment. The surgeon obtains thickness and angle of bone excision information in real time, and patients with an abnormal anatomical structure can be operated on correctly. During operation of total knee joint arthroplasty, matching flexion and extension intervals and ligament

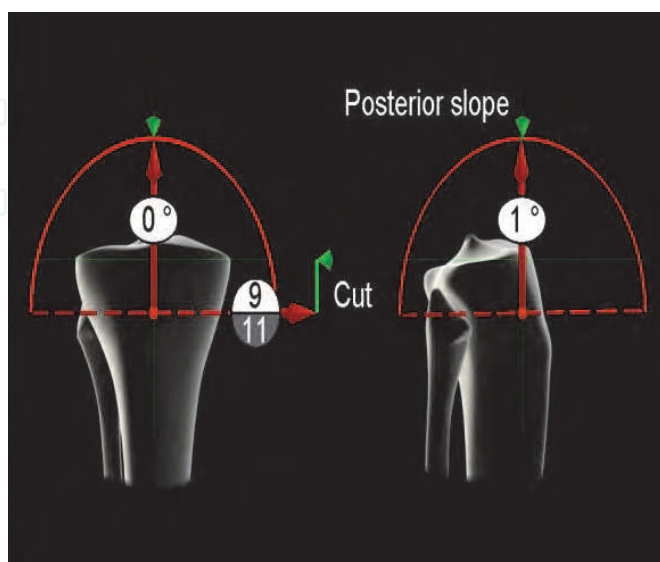


Fig. 4. Real-time monitoring

balancing are difficult due to damaged soft tissue, but navigation system can check flexion and extension intervals and ligament balancing instantly. Haaker et al.( Haaker et al., 2005) reported that real-time correction is possible after evaluating and collecting exact osteotomy data, implantation and soft tissue stability status promptly.

### **3.2.1.2 Functional results**

The use of navigation systems during TKA produces accurate limb alignment, but the effect of this accuracy on functional outcome is still under dispute. However, Choong et al.(Choong et al., 2009) reported patients that underwent navigation assisted surgery showed precise limb alignment ( $<3^\circ$ ), and concluded that accuracy improved new knee function and quality of life. Lehnert et al. (Lehnert et al., 2010) reported, in a 1-year follow up study, that Western Ontario and McMaster University (WOMAC) scores and Knee Society scores of 43 navigation assisted surgery patients were notably higher than those of 122 patients that underwent conventional surgery. Patient satisfaction was 91% in the navigation assisted group, but only 70% in the conventional surgery group.

### **3.2.1.3 Bleeding**

In navigation assisted total knee arthroplasty, the intramedullary jigs are not needed, and therefore, less bleeding can be expected as compared with conventional methods. Chauhan et al.(Chauhan et al., 2004) performed a randomized prospective study on 70 patients randomly allocated to computer-assisted surgery or conventional surgery. Mean amounts of bleeding were compared, and whereas the computer surgery group lost an average of 252mL (25-620), the conventional surgery group lost 446mL (100-1100). Furthermore, this low bleeding amount reduced the incidence of blood transfusions, and was useful when operating on patients in whom blood transfusion was problematic. Schnurr et al.(Schnurr et al., 2010) studied blood losses and transfusion amounts for 500 TKA operations. Average blood loss in their conventional and navigation groups were 1375mL and 1242mL, respectively. Furthermore, mean transfusion ratio was 0.23 in the conventional group and 0.12 in the navigation assisted group.

### **3.2.1.4 Embolisms**

Conventional TKA uses intramedullary jigs, which increase intramedullary pressure and increase the risk of fat embolism. Chauhan et al.(Chauhan et al., 2004) compared navigation guided TKA and conventional TKA and reported that acute confusional states caused by transient fat embolisms occurred more frequently in conventional TKA patients. On the other hand, the risk of fat embolism in TKA patients is remarkably reduced when navigation systems or extramedullary alignment guides are used. Kalairajah et al. (Kalairajah et al., 2006) reporting on a study based on noninvasive monitoring, navigation assisted surgery stated fewer embolisms in the systemic circulation during operation than during conventional surgery.

### **3.2.1.5 Miscellaneous**

Navigation assisted surgery, unlike conventional surgery, provides accurate records and comprehensive data on operations performed, which can be helpful during future investigations. Surgical wound healing characteristic are known to be similar for the two methods. Browne et al.(Browne et al., 2010) in a meta-analysis of 101,596 TKA patients, found that patients who underwent navigation guided surgery had a lower risk of cardiovascular complications than patient who underwent conventional surgery.



### **3.2.2 Disadvantages**

#### **3.2.2.1 Pin fixation**

In a navigation assisted surgery, pins are fixed on to the bones to acquire real-time information of the limb alignment. Potential complications involving the pin fixations have been reported. Some investigators reported that additional 4cm of incision was needed for the pin fixations during navigation surgery, and this could cause delayed soft tissue healing and increased risk of infection. The additional incision of the quadriceps femoris muscle were needed in order to install the femoral tracking array can cause delayed healing of the muscle during the early stage of rehabilitation. The fracture of the pin fixation site for the reference array could also occur. Sikorski et al.(Sikorski et al., 2004) reported that the accuracy of the navigation assisted surgery can be impaired in osteoporotic patients due to the loosening of the pinning site. Song et al.(Song et al., 2006) reported that inappropriately registered data in navigation assisted surgery can change the outcome of the operation creating an incorrect mechanical axis.

#### **3.2.2.2 Prolonged operation time**

Operation time differ between authors, but generally, navigation assisted TKA takes 15 to 30 minutes longer than conventional TKA. The type of prosthesis used and the skills of the operator can affect operation time, it has been reported that the learning curve requires 10~20 procedures. Bauwen et al(Bauwen et al., 2004) reviewed computer-assisted TKA related articles between 1990 and 2008, and reported that the accuracy of mechanical axis alignment was the same as that of conventional TKA and that operation times were 23% longer.

#### **3.2.2.3 Cost**

Newer techniques require new equipment, and thus, costs inevitably increases. However, several authors have concluded that navigation assisted surgery extends the life spans of prostheses and reduces the potential risk of revision surgery, and that it is less costly in the long term.

#### **3.2.2.4 Errors of the navigation system**

Many investigators have reported that navigation assisted TKA produces more accurate results. Seon et al.(Seon et al., 2004) reported that the accuracies of optical and electromagnetic navigation systems are affected by the registration of anatomical locations. Mullaji et al.(Mullaji et al., 2007) reported in a comparative study of navigation assisted TKA and conventional TKA that the accuracies of navigation systems depends on joint deformity, instability, computer hardware, computer software, and the surgical techniques used. In addition, they found that patients with 20~30° of varus deformity before TKA had more varus mechanical axes after surgery than patients with 10~20° of varus deformity before operation. Furthermore, the former patients showed significantly higher rates of varus locations of femoral and tibial prostheses. These findings indicate that radiographs should be used to determine the degree of varus deformity when placing sensors.

### **3.3 Operative procedure (Orthopilot® Version 4.0 or 4.2)**

The following text concerns that of the Orthopilot Version 4.0 or 4.2 (Aesculap, Tuttlingen, Germany) navigation system which is an image-free system.

Operation was performed using the gap technique with navigation. Using a medial parapatellar approach, the knee joint was exposed and the hip, knee, and ankle centers were navigated. Anatomical landmarks were registered by hand using a pointer to define the joint line and the mechanical axis of the leg. The mechanical axis was then restored to neutral ( $\pm 2^\circ$ ) at full extension by stepwise meticulous medial soft tissue release and osteophyte removal (Fig. 5). Proximal tibial bone cutting was performed under real-time navigation system control and the posterior cruciate ligament was preserved and confirmed to be functionally intact. Flexion and extension gaps were measured at full extension and at  $90^\circ$  of flexion using a tensioning device (V-STAT tensor, Zimmer) and a special torque wrench set at 200N before femoral bone cutting (precutting flexion and extension gaps) (Fig. 6). Gap differences were classified as; balanced, tight in flexion, or tight in extension. A balanced gap was defined as one having a flexion/extension gap difference of within 3mm, a tight flexion gap as a gap with an extension gap of at least 3mm more than the corresponding flexion gap, and a tight extension gap as one with a flexion gap of at least 3mm more than the corresponding extension gap. Levels of distal and posterior femoral cuts and amounts of femoral component rotations were determined based on extension-flexion and medial-lateral gap differences (Fig. 7). Following final bone cuts and soft tissue release completion, flexion, and extension gaps were reassessed (final flexion and extension gaps) (Fig. 8). And if soft tissue balance is adequate, the prosthesis are inserted.

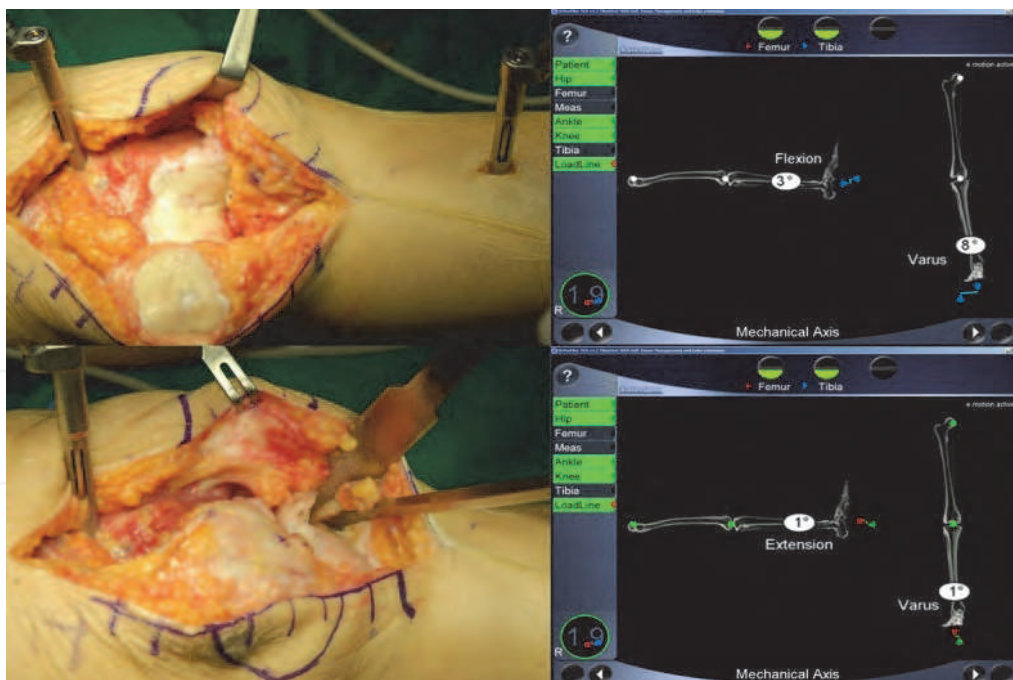


Fig. 5. After performing anatomical and kinematic registrations, the mechanical axis was restored to neutral ( $\pm 2^\circ$ ) at full extension by incremental meticulous medial soft tissue release and osteophyte removal.

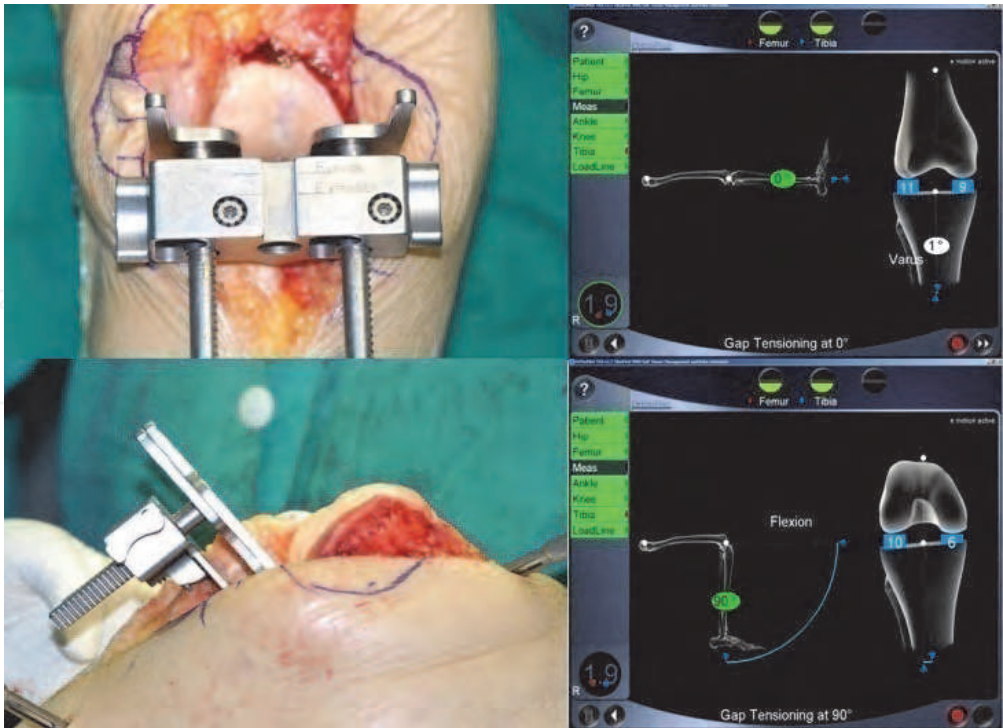


Fig. 6. After proximal tibial bone cutting while preserving the posterior cruciate ligament under navigation and before femoral bone cutting, flexion, and extension gaps were measured at full extension and at 90° of flexion using a tensioning device and a special torque wrench set at 50lb/inch (precutting flexion and extension gaps).

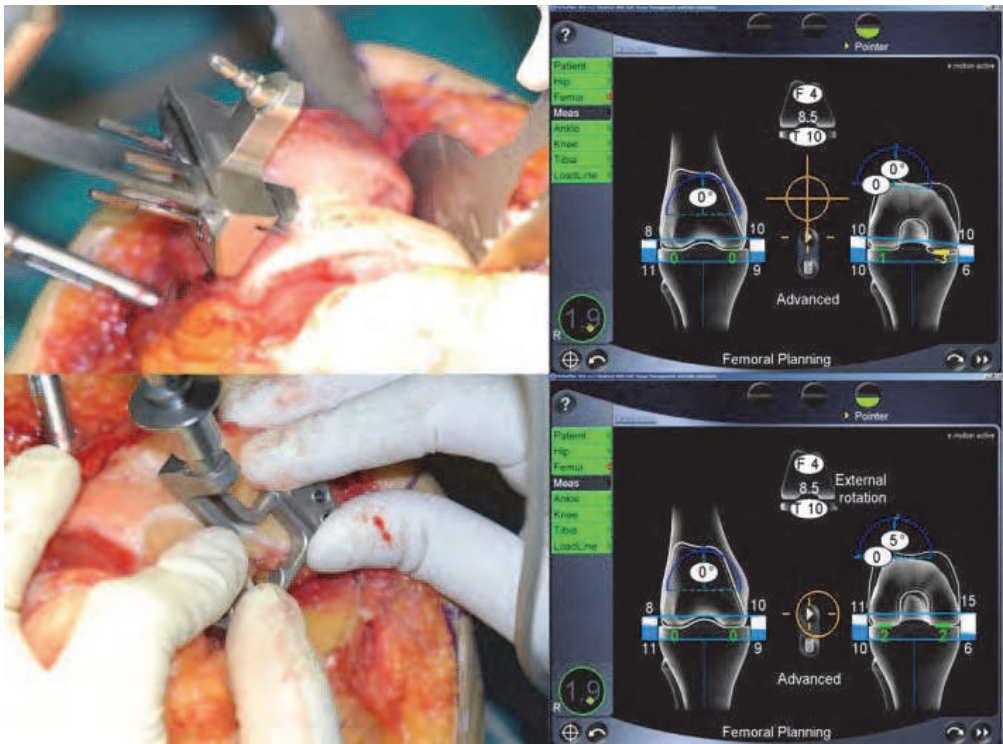


Fig. 7. Levels of distal and posterior femoral cuts and amounts of femoral component rotation were planned based on extension-flexion and medial-lateral gap differences.



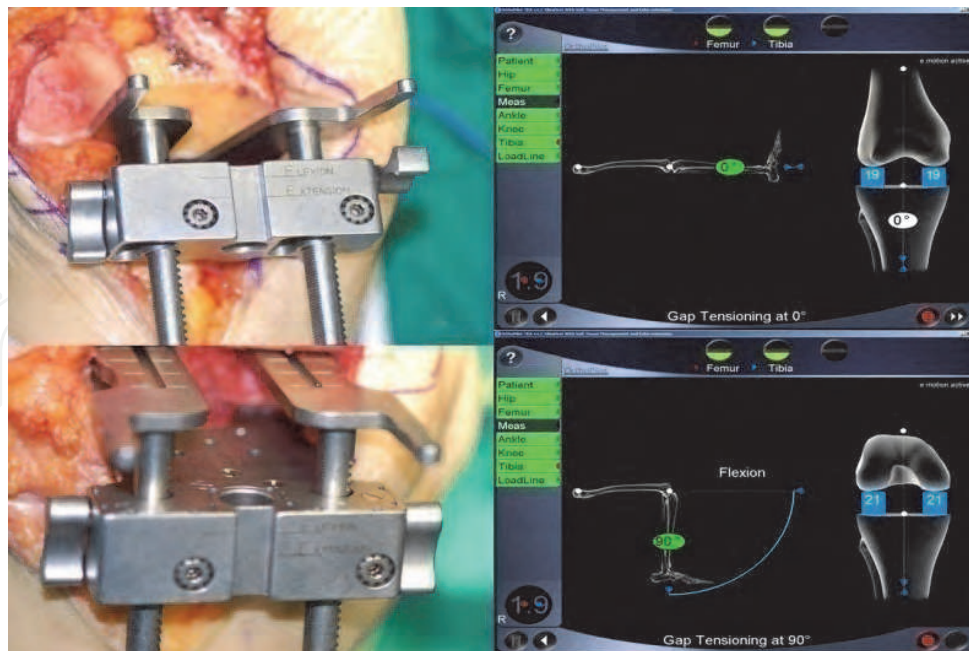


Fig. 8. Following final bone cuts and soft tissue release, flexion and extension gaps were reassessed (final flexion and extension gaps).

### 3.4 Clinical outcomes

Many reports have concluded that computer-assisted TKA produces consistent results, reduces malalignment and inappropriate prosthesis placement, and promotes rapid recovery and rehabilitation after surgery. Rosenberger et al. (Rosenberger et al., 2008) investigated 100 patients, and found that 50 patients who underwent navigation assisted TKA showed an average varus angle of  $0.28^\circ$ , whereas patients who underwent conventional TKA showed  $1.88^\circ$  in the coronal plane. The ideal prosthesis location was achieved in 16 cases (32%) in the conventional TKA group, and in 31 cases (62%) in the navigation assisted TKA group. These results show that navigation assisted surgery is a straightforward, stable, useful procedure for total knee arthroplasty.

Seon and Song et al. (Seon et al., 2009) investigated 43 cases in a 2-year follow up study, and found that Hospital for Special Surgery (HSS) and Western Ontario and McMaster University (WOMAC) scores were increased in both the navigation assisted and conventional groups, the scores were non-significantly different in both groups. Ranges of knee joint movement were also similar, but limb and prostheses alignments were better in the navigation assisted group.

However, others have reported that the conventional and navigational methods are no different with respect to pain, range of motion, ankylosis knee scores, and patient satisfaction. Spencer et al. (Spencer et al., 2007) reported that after a 2-year follow up of 71 patients with navigation assisted TKA group showed better alignment, but other factors such as functional assessments failed to reveal any significant difference.

## 4. Robotic-assisted TKA

### 4.1 Introduction to robot systems

Robotic surgery systems can be classified according to level of function, into three groups, that is, as passive types, active types, or semi-active types, and further divided into image

based or image free systems. Passive types guide the surgeon through the fixation and cutting block resection stages – the actual cutting and drilling processes are executed by the surgeon. Navigation systems are passive types. Whereas active robotic types prepare and execute the operation process entirely or in part, and perform the bone cutting. Initially, these robots were custom-made in small numbers, but many others originated from larger industrial robots.

The ROBODOC® (Integrated Surgical Systems, Davis, CA), and the CASPAR® (URS Ortho Rastatt, Germany) are typical commercial TKA robotic systems. ROBODOC was the first of its kind, and is the only system used in South Korea. The system is composed of two main parts; Orthodoc, a supercomputer which plans and executes surgery, and ROBODOC, which has robot arms and performs the surgery (Fig. 9). Orthodoc uses pre-operative CT images to analyze anatomy, to choose a prosthesis of the right size, a prosthesis location, to plan cutting, drilling, and finally to register the data in ROBODOC for execution.

The development of the CASPAR® system was inspired by the commercial success of ROBODOC in Germany, and was first developed by OrtoMaquet (a subsidiary of Maquet). This system uses infrared cameras and reflective trackers to track limb positions. The system is designed to stop if excessive limb movement is detected during surgery. Care is required during operation to ensure that bone debris or fluid spatter on reflective tracker is removed; splash-guards may be needed. However, the ROBODOC system uses bone motion detectors fixed about 5mm deep in bone, which are not compromised by debris or fluid.



Fig. 9. ROBODOC® system (Integrated Surgical Systems, Davis, CA) is composed of two primary components. (A) CT-based preoperative planning using ORTHODOC, and (B) Robot-assisted surgery using the ROBODOC surgical assistant (@ = robot base, b = robot arm, c = the control computer)



Semi-active systems are a combination of the passive and active types, whereby a robot guides the cutting tools within specific ranges, and the operator controls robot arms within these ranges to process bone. The Acrobot® system (Acrobot Co. Ltd., London) and the MAKO Tactile Guidance System (TGS) (MAKO Surgical Corp., Fort Lauderdale, Fla)(Fig. 10) are semi-active types, and are often used for conducting unicompartmental knee arthroplasty.



Fig. 10. MAKO Tactile Guidance System (TGS) (MAKO Surgical Corp., Fort Lauderdale, Fla)

The Acrobot system was developed at Imperial College (London) and was the first of its kind in the TKA field. According to this semi-active system, cutting tools are located within the dimensional range of bone to be cut. The tools are controlled by an Active Constraint Control™ system. At first Acrobot was used for TKA, but now it is more often

used for unicompartmental knee arthroplasty. The robot software limits the movements of cutting tools within a pre-set range, and the operator resects bone to the planned extent in this range. The developers of the Acrobot system believe that it will be more attractive to surgeons than active systems like ROBODOC or CASPAR. The Acrobot® system consists of two robots; a large robot which functions as a gross positioning device, and a smaller robot which controls the active constraint function; technically, Acrobot refers to the smaller robot. The Acrobot has a spherical kinematic design that contains two rotational axes (yaw and pitch) and one prismatic axis (extension). The handle is equipped with a sensor that measures the force applied by the operator and controls the power output of the robot arm. The gross positioning device holds the limb in a manner that enables positioning of Acrobot near the cut volume. A six-axis gross positioning device is used for TKA, and a three-axis device for UKA. Anatomical data is registered using pre-op CT images; the operator marks 20-30 dots on the bone surface, and matching of the 3D-CT image and actual bone is then performed.

#### **4.2 Surgical procedure (ROBODOC®)**

Robotic TKA is composed of two steps; pre-op preparation (during which operation plans are determined based on CT images) and robot-assisted surgery.

CT images are acquired with the knee joint flexed at 15~20°. A calibration rod is attached to the limb, and CT scans are acquired at five different levels (the foot joint, mid tibia, the knee joint, mid femur, and the femoral head). When acquiring images of the distal femur and proximal tibia, slice thickness is reduced to 0.625 mm to improve accuracy.

Orthodoc reconstructs sagittal images and 3D images (surface models of the tibia and the femur) from acquired coronal CT images. The mechanical axis of the virtual 3D bone models is then set using the centers of hip, knee, and ankle joints. The virtual femur and tibia are then set parallel to the mechanical axis. Subsequently, suitable femoral and tibial prostheses, in terms of extent of resection, prosthesis size, and degree of external rotation, are then placed. The tibial prosthesis is placed on the line between the center of the posterior cruciate ligament's origin and the medial 1/3 of the tibial tuberosity. Finally, Orthodoc performs virtual surgery to confirm prosthesis alignment (Fig. 11). A supercomputer then determines exact sites and the extent of bone resection, the information saved on a disc, is delivered to ROBODOC. This preparatory step takes about 15~30 minutes.

The operation begins by fixing the robot to the subject knee, and this is followed by a verification process, during which correspondences are determined between anatomical bone surfaces and virtual bone. Bone resection and prosthesis insertion are then executed (Fig. 12).

Before surgery, a calibration process is initiated to achieve a precision of less than 0.2 mm. Robotic surgery is conducted, like conventional surgery, using a medial parapatellar approach. The approach is conducted by the surgeon. The patella is then everted to expose the knee joint, and the joint is fixed at 90~120°. The robot then inserts a Schanz pin in the proximal tibia and in the distal femur, and two straight beams are used to connect the limb. Traction devices (two curved S pins) are then attached to pull soft tissue and achieve maximum exposure. These devices are placed so as not to interfere with movement of the cutting arm. Next, the recovery markers, a screw and a pin, are fixed to the femur and tibia

respectively. These markers enable the robot to sense unwanted limb movements (if movement exceeds 2 mm the robot will stop). This connecting step takes about 5-10 minutes (Fig. 13).

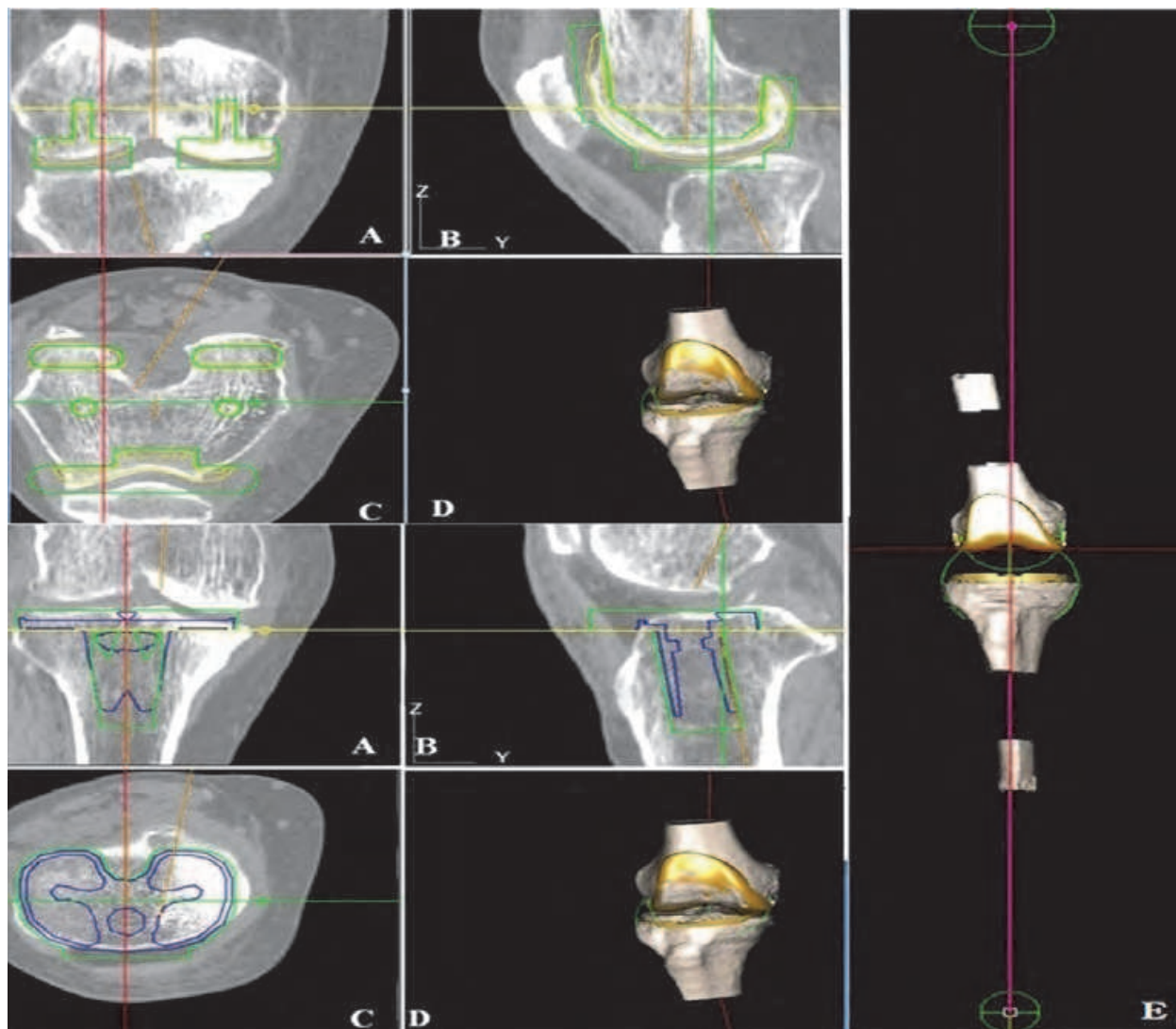


Fig. 11. Preoperative planning of the insertion of a femoral and tibial prosthesis using ORTHODOC. A= frontal plane; B= sagittal plane; C = transverse plane; and D= three-dimensional bone model of the femur and tibia; E= virtual surgery was conducted to verify femoral and tibial alignments and sizes with respect to the established femoral and tibial mechanical axes

Registration then performed. Actual knee joint bone surfaces are matched to the data saved in ROBODOC. This process involves making the ball probe of the robot contact each of 97 contact points in 28 different locations as indicated by the computer program. After this process has been completed, which takes 5-10 minutes, the robot can recognize anatomical landmarks and bone spatial details.



After verifying data, physiological saline is applied continuously for cooling and irrigation, and the robot begins milling the femur and the tibia. The milling sequence proceeds in the following order; distal femur, anterior femur, posterior medial condyle, and posterior lateral condyle. At the tibia, milling begins at the tibial plateau, and after milling, pilot holes are drilled. The saw is replaced with a smaller one to make the peg holes and tibial flanges. The whole milling process takes about 20 minutes. The robot's job ends here.

The surgeon proceeds with trimming of the resection margin. Soft tissue is then relaxed and balanced. The knee is flexed and extended, from 0° to 90° to check for soft tissue stretching, and if soft tissue balance is adequate, the prostheses are inserted.

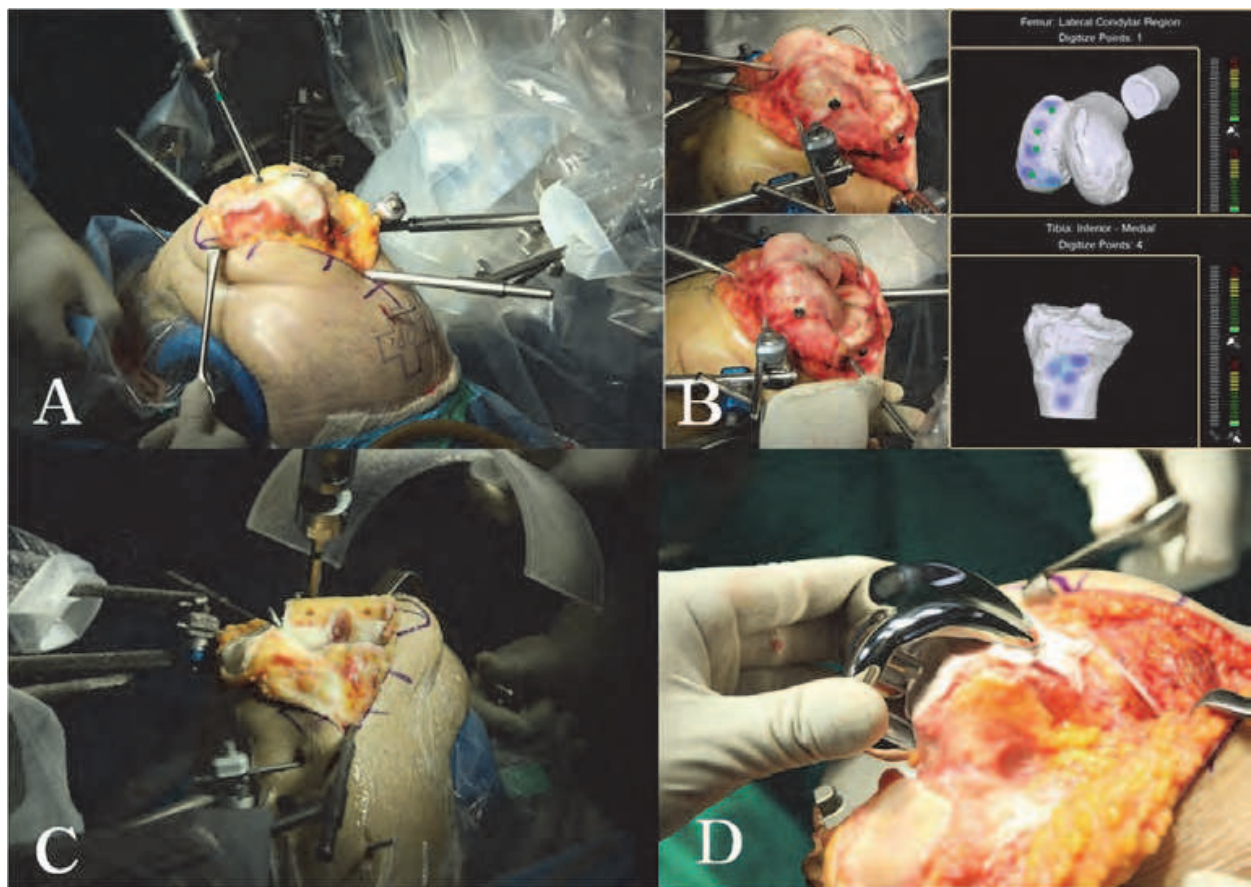


Fig. 12. Photographs showing the ROBODOC surgical procedure; Fixation between the patient's leg and surgical robot (A), Registration (B), Milling by the surgical robot (C), Implantation (D). During pinless registration (B), the digitizer arm is guided by the surgeon to certain points on the distal femur or proximal tibia. Digitized points are shown on the computer monitor. A correct hit is indicated when the point concerned turns green.

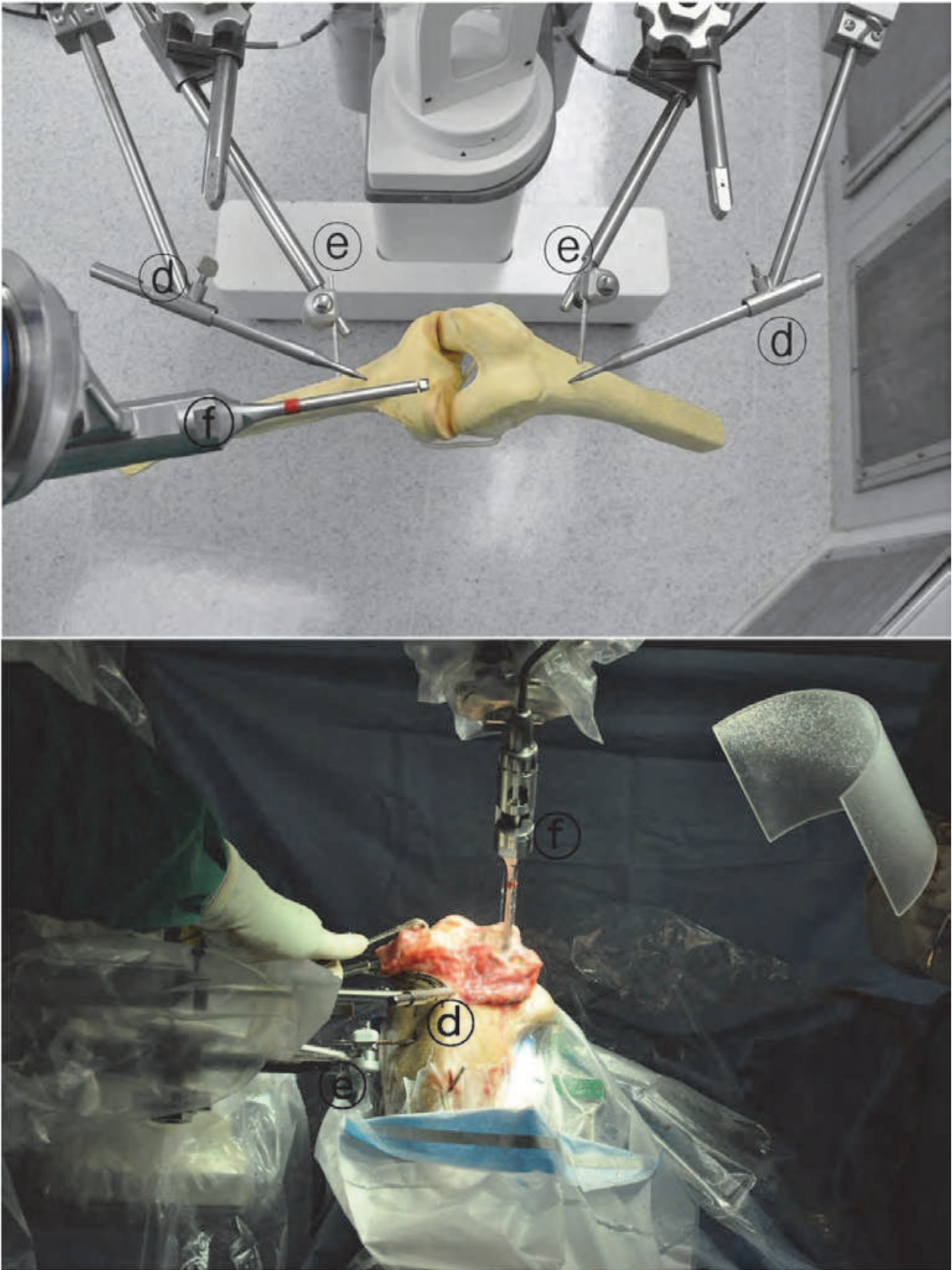


Fig. 13. The ROBODOC surgical robot. ①, ②, ③ (see Fig. 9), ④ = bone-motion detector, ⑤ = femoral and tibial fixators, ⑥ = the bone milling cutter.



### **4.3 Advantages and disadvantages of robotic-assisted TKA**

#### **4.3.1 Advantages**

The robot surgery can be planned with greater precision than conventional surgery. Drills are guided with pin-point accuracy and bone milling is performed without any shaking or vibration. Ideal prostheses alignments and mechanical axes can be achieved and verified on CT or weight-bearing x-ray images. Furthermore, results consistent with the operation plan are consistently achieved with almost no outliers.

Siebert et al. (Siebert et al., 2002) also mentioned that inadvertent injuries of ligaments, vessels, or nerves can be avoided, because movement of the cutting arm is precisely planned and calculated, as are the resections. For example, during robotic surgery, the insertion site of the posterior cruciate ligament always remains intact. In addition, milled surfaces almost perfectly fit prostheses, and the amount of resected bone is minimized, which makes potential revision surgery less complicated.

#### **4.3.2 Disadvantages**

Coon(Coon, 2009) remarked that bone registration, burr exchanging, and a long milling time limit the efficiency of workflow during robot-assisted surgery. In addition, the author criticized the robot's design, especially the unnecessarily long arms, which make it difficult to appropriately deploy, sterilize, and drape. Bellmans et al. (Bellmans et al., 2007) discontinued robot-assisted surgery due to longer surgery time (over 30 min.), the need for highly experienced personnel, and higher costs, and Borner et al.(Borner et al., 2010) reported of the first 100 cases of ROBODOC assisted surgery, about 5% were converted to conventional surgery due to technical problems, such as, digitization error, calibration error, or bone motion.

Park and Lee(Park & Lee, 2007) found that the large pins required and the wide radius of robot arm movements made robot surgery unsuitable for minimally invasive surgery. They reported that of the first 32 patients that underwent robot surgery, 6 experienced complications, such as, superficial infections, rupture of the patellar ligament, dislocation of the patella, supracondylar fracture, or peroneal nerve injury.

Decking et al. (Decking et al., 2004) commented that before it could be viewed as an integrated method for total arthroplasty, robot surgery should be quicker, cheaper, smaller, and include an integrated soft tissue balancing process without losing its integrity.

Currently, we lack evidence that superior accuracy improves clinical outcomes, and thus, more investigations are required.

#### **4.4 Clinical outcomes**

Little information is available on the clinical outcomes of robot-assisted TKA. In a cadaver-based study undertaken to evaluate the accuracy of a robot system, alignment errors of the mechanical axis averaged 1° and ranged up to 2°, and average prosthetic displacement was 1mm with a maximum of 2mm. 3D CT pre-operative planning and the precision of the robot made ideal prosthesis placement possible. Decking et al.(Decking et al., 2004) acquired similar results using the CASPAR system. In this study, 13 patients underwent TKA and CT images acquired preop and 10 days postop were compared. Average mechanical axis discrepancy, as compared with preop images, was 0.2°. The accuracies of prostheses alignments in the coronal, sagittal, and axial planes were  $\pm 1.2^\circ$ , whereas accuracies of linear alignments (anteroposterior, mediolateral, and craniocaudal) were  $\pm 1.1$  mm. The authors

concluded that robot-assisted TKA enables much more precise placement of prostheses. However, the authors added that the robotic procedure should include soft tissue balancing, and that robotic surgery should be quicker and less expensive to ensure its adoption.

Siebert et al. (Siebert et al., 2002) reported that in 70 cases of robot-assisted surgery, the average mechanical axis error was  $0.8^\circ$  and that the average operation time was 135 minutes. Furthermore, the conventional method had an average axis error of  $2.6^\circ$ , whereas robot surgery was more accurate. The authors mentioned that surgical precision (based on comparisons with pre-op CT images) was a strong point, but that the insertion and placement of markers, the longer operation time, and higher costs were weak points of the technique.

Borner et al. (Borner et al., 2004) reported 100 cases of ROBODOC assisted TKA. Mechanical axis errors were all within  $3^\circ$  and operations took only 90~100 minutes after sufficient experience. Precision beyond that achieved by the conventional technique has not been proven to be a requirement of TKAs, but it appears reasonable to believe that long term outcomes will surpass those of conventional surgery. Although most TKAs are viable for at least 15 years, robot-assisted surgery provides better axis alignment, and thus, minimizes prostheses wear and bone osteolysis, which should prolong the life spans of replaced knees.

Bellmans et al. (Bellmans et al., 2007) investigated 25 patients who underwent robotic TKA using the CASPER system. In this average 5-year follow up study, mechanical axis errors, alignments of prostheses in the coronal/sagittal planes, and rotation angles of femoral prosthesis were all  $< 1^\circ$ .

Park and Lee (Park & Lee, 2007) compared 30 cases treated using the conventional method with 32 cases of ROBODOC assisted surgery and concluded that the robotic system offers - accurate procedural planning, precise resection of bone, and accurate alignments and locations of prostheses and axes. They also mentioned that big pins and the robot's wide arm radius are not suitable for minimally invasive surgery.

Song et al. (Song et al., 2009) found in a minimum 3-year follow up study of 50 ROBODOC-surgery patients that mechanical axes were corrected  $0.49^\circ$  varus on average, and that they were within  $2^\circ$  in 46 patients and within  $3^\circ$  in the remaining four. Average angles of femoral and tibial prostheses in the coronal plane were  $89.5^\circ$  and  $90.1^\circ$ , respectively, and average gradients in the sagittal plane were  $1.06^\circ$  and  $85.56^\circ$  respectively. The accuracies of coronal and sagittal plane were within  $2^\circ$ .

In a later study, Song et al. (Song et al., 2011) investigated 30 cases of bilateral degenerative arthritis of the knee in a randomized, prospective, comparative trial of robot-assisted and conventional surgery. One knee was operated on using ROBODOC, and the other was treated conventionally. Patients were followed up for at least 2 years. Clinical scores and ranges of movement were not significantly different in the two groups. Moreover, when patients were surveyed for pain, joint stability, joint weakness, snapping, swelling, and unexplained discomfort, 11 preferred the ROBODOC operated knee, 13 expressed no preference, and 6 preferred the conventionally operated side. However, in terms of mechanical axis alignments, whereas as the conventional method had 7 outliers, ROBODOC had none, and in terms of tibial prosthesis alignments, there were six outliers in the conventional group, and none in the ROBODOC group. The authors concluded that robot-assisted surgery produces better clinical and radiologic outcomes.

#### 4.5 Future directions

Computer assisted orthopedic surgeries are being rapidly developed, and the future of navigation assisted surgery appears bright. In particular, if the physical sizes of these systems could be reduced they would be more useful for minimally invasive surgery. Furthermore, accuracies will undoubtedly be improved and errors will become infinitesimal.

The ROBODOC and CASPAR systems have achieved commercial success, and are now used in more than 100 European institutes. Furthermore, in South Korea, 10 institutions now routinely use the ROBODOC system. As was mentioned above, neither the ROBODOC nor the CASPAR system reduce operation costs, although robot supporters claim that by not using manual instrumentation the expenses of sterilization are saved, and that the superior clinical outcomes (lower revision operation rates, faster recovery, return to society, and others) offer across the board savings. However, there is insufficiency of the objective, and currently, it cannot be said that the superior accuracy provided by robot systems leads to better clinical outcomes.

### 5. Conclusion

In the orthopedic surgery field, navigation assisted surgery provides real-time alignment values, and allows the intra-operative evaluation and adjustment of prosthesis placement. Furthermore, computer-assisted surgery methods are expected to improve the qualities of surgical procedures. The majority of orthopedic surgeons believe that a computer system is needed during TKA to provide axis alignment, whereas others believe that computer-assisted surgery provides results that are effectively similar to those of conventional surgery. However, navigation assisted TKA provides precise information about femoral and tibial prostheses, enables optimal prosthesis sizes to be chosen for individual patients, and provides better range of knee movement after surgery. Furthermore, it improves the surgical experience for both the surgeon and patient.

In the operation room, robots have no limits regarding bone resection, which is why robot systems have been adopted in the orthopedic surgery field. In the TKA field, currently available robotic systems require more operative time and are more expensive than conventional surgery, but even at this stage of development they offer much more precise pre-operative planning.

### 6. Index

Knee joint, Osteoarthritis, Navigation, Kinematic registration, Surface registration, Infra-red, Optical system, Electromagnetic system, Light-emitting diodes, Ligament balancing, Tensioner, Real-time information, Robot, ROBODOC, ORTHODOC, Preoperative planning, Computer tomography, Passive system, Active system, Milling, Verification, Calibration, Bone motion, Mechanical alignment method, Anatomical alignment method

### 7. References

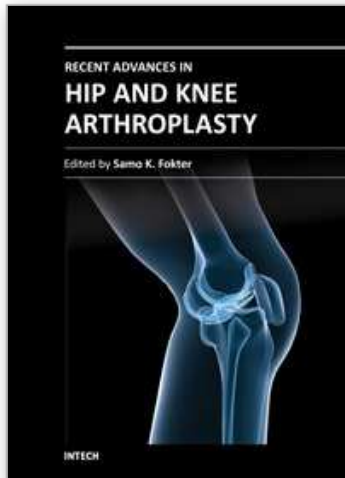
Bathis H, Perlick L, Tingart M, Luring C, Zurakowski D, Grifka J. Alignment in total knee arthroplasty. A comparison of computer-assisted surgery with the conventional technique. *J Bone Joint Surg Br.* 2004;86(5):682-687.

- Bellemans J, Vandenuecker H, Vanlauwe J. Robot-assisted total knee arthroplasty. *Clin Orthop Relat Res*. 2007;464:111-116.
- Borner M, Wiesel U, Ditzen W. Clinical experience with Robodoc and the Duracon Total Knee. In: Stiehl J, Konermann W, Haaker R(eds). *Navigation and Robotics in Total joint and Spine Surgery*. Berlin, Germany: Springer-Verlag. 2004:362-366.
- Browne JA, Cook C, Hofmann AA, Bolognesi MP. Postoperative morbidity and mortality following total knee arthroplasty with computer navigation. *Knee*. 2010;17(2):152-156.
- Chauhan SK, Scott RG, Breidahl W, Beaver RJ. Computer-assisted knee arthroplasty versus a conventional jig-based technique. A randomized, prospective trial. *J Bone Joint Surg Br*. 2004;86(3):372-377.
- Choong PF, Dowsey MM, Stoney JD. Does accurate anatomical alignment result in better function and quality of life? Comparing conventional and computer-assisted total knee arthroplasty. *J Arthroplasty*. 2009;24(4):560-569.
- Coon Thomas M. Integrating robotic technology into the operating room. *Am J Orthop*. 2009;38(2 Suppl):7-9.
- Decking J, Theis C, Achenbach T, Roth E, Nafe B, Eckardt A. Robotic total knee arthroplasty: the accuracy of CT-based component placement. *Acta Orthop Scand*. 2004;75(5):573-579.
- Ensini A, Catani F, Leardini A, Romagnoli M, Giannini S. Alignments and clinical results in conventional and navigated total knee arthroplasty. *Clin Orthop Relat Res*. 2007;457:156-162.
- Fadda M, Marcacci M, Toksvig-Larsen S, Wang T, Meneghello R. Improving accuracy of bone resections using robotics tool holder and a high speed milling cutting tool. *J Med Eng Technol*. 1998;22(6):280-284.
- Haaker RG, Stockheim M, Kamp M, Proff G, Breitenfelder J, Ottersbach A. Computer-assisted navigation increases precision of component placement in total knee arthroplasty. *Clin Orthop Relat Res*. 2005(433):152-159.
- Kalairajah Y, Cossey AJ, Verrall GM, Ludbrook G, Spriggins AJ. Are systemic emboli reduced in computer-assisted knee surgery?: A prospective, randomised, clinical trial. *J Bone Joint Surg Br*. 2006;88(2):198-202.
- Knutson K, Lindstrand A and Lidgren L. Survival of knee arthroplasties, a nation-wide multicenter investigation of 8,000 cases. *J Bone Joint Surg*. 1986; 68-B: 795-803.
- Laskin RS. Alignment of total knee components. *Orthopedics*. 1984; 7:62.
- Lehnen K, Giesinger K, Warschkow R, Porter M, Koch E, Kuster MS. Clinical outcome using a ligament referencing technique in CAS versus conventional technique. *Knee Surg Sports Traumatol Arthrosc*. 2010.
- Matziolis G, Kroker D, Weiss U, Tohtz S, Perka C. A prospective, randomized study of computer-assisted and conventional total knee arthroplasty. Three-dimensional evaluation of implant alignment and rotation. *J Bone Joint Surg Am*. 2007;89(2):236-243.
- Mullaji A, Kanna R, Marawar S, Kohli A, Sharma A. Comparison of limb and component alignment using computer-assisted navigation versus image intensifier-guided conventional total knee arthroplasty: a prospective, randomized, single-surgeon study of 467 knees. *J Arthroplasty*. 2007;22(7):953-959.
- Park SE, Lee CT. Comparison of robotic-assisted and conventional manual implantation of a primary total knee arthroplasty. *J Arthroplasty*. 2007;22(7):1054-1059.



- Plaskos C, Hodgson AJ, Inkpen K, McGraw RW. Bone cutting errors in total knee arthroplasty. *J Arthroplasty*. 2002;17(6):698-705.
- Ranawat CS, Flynn WF, Saddler S, Hansraj KH, Maynard MJ. Long-term results of total condylar knee arthroplasty. A 12-years survivorship study. *Clin Orthop*. 1993; 286: 94-102.
- Ritter MA, Faris PM, Keating EM, Meding JB. Postoperative alignment of total knee replacement its effect on survival. *Clin Orthop*. 1994;299: 153-156.
- Rosenberger RE, Hoser C, Quirbach S, Attal R, Hennerbichler A, Fink C. Improved accuracy of component alignment with the implementation of image-free navigation in total knee arthroplasty. *Knee Surg Sports Traumatol Arthrosc*. 2008;16(3):249-257.
- Schnurr C, Csecsei G, Eysel P, König DP. The effect of computer navigation on blood loss and transfusion rate in TKA. *Orthopedics*. 2010;33(7):474
- Scuderi GR, Insall JN, Windsor RE, Moran MC. Survivorship analysis of cemented knee replacement. *J Bone Joint Surg*. 1989;71-B:798-809
- Seon JK, Park SJ, Lee KB, Li G, Kozanek M, Song EK. Functional comparison of total knee arthroplasty performed with and without a navigation system. *Int Orthop*. 2009;33(4):987-990.
- Seon JK, Song EK. The Accuracy of Lower Extremity Alignment in a Total Knee Arthroplasty Using Computer-Assisted Navigation System. *J of Korean Orthop Assoc* 2004;39:566~571.
- Siebert W, Mai S, Kober R, Heeckt PF. Technique and first clinical results of robot-assisted total knee replacement. *Knee*. 2002;9(3):173-180.
- Sikorski JM. Computer-assisted revision total knee replacement. *J Bone Joint Surg Br*. 2004;86(4):510-514.
- Song EK, Seon JK, Park SJ, Jung WB, Park HW, Lee GW. Simultaneous bilateral total knee arthroplasty with robotic and conventional techniques: a prospective, randomized study. 1. *Knee Surg Sports Traumatol Arthrosc*. 2011 Feb 11. [Epub ahead of print]
- Song EK, Seon JK, Park SJ, Park JK, Park CH. Robotic Total Knee Arthroplasty - Minimal Follow-up of 3 Years - *J Korean Knee Soc* 2009;21:251~257.
- Song EK, Seon JK, Yoon TR, Park SJ, Bae BH, Cho SG. Functional results of navigated minimally invasive and conventional total knee arthroplasty: a comparison in bilateral cases. *Orthopedics*. 2006;29(10 Suppl):S145-147.
- Spencer JM, Chauhan SK, Sloan K, Taylor A, Beaver RJ. Computer navigation versus conventional total knee replacement: no difference in functional results at two years. *J Bone Joint Surg Br*. 2007;89(4):477-480.
- Stulberg SD, Loan P, Sarin V. Computer-assisted navigation in total knee replacement: results of an initial experience in thirty-five patients. *J Bone Joint Surg Am*. 2002;84-A Suppl 2:90-98.
- Teter KE, Bregman D, Colwell CW, Jr. Accuracy of intramedullary versus extramedullary tibial alignment cutting systems in total knee arthroplasty. *Clin Orthop Relat Res*. 1995(321):106-110.
- Tria AJ, Jr. The evolving role of navigation in minimally invasive total knee arthroplasty. *Am J Orthop (Belle Mead NJ)*. 2006;35(7 Suppl):18-22.
- Van Ham G, Denis K, Vander Sloten J, Van Audekercke R, Van der Perre G, De Schutter J, Aertbelien E, Demey S, Bellemans J. Machining and accuracy studies for a tibial knee implant using a force-controlled robot. *Comput Aided Surg*. 1998;3(3):123-133.





## **Recent Advances in Hip and Knee Arthroplasty**

Edited by Dr. Samo Fokter

ISBN 978-953-307-841-0

Hard cover, 452 pages

**Publisher** InTech

**Published online** 27, January, 2012

**Published in print edition** January, 2012

The purpose of this book is to offer an exhaustive overview of the recent insights into the state-of-the-art in most performed arthroplasties of large joints of lower extremities. The treatment options in degenerative joint disease have evolved very quickly. Many surgical procedures are quite different today than they were only five years ago. In an effort to be comprehensive, this book addresses hip arthroplasty with special emphasis on evolving minimally invasive surgical techniques. Some challenging topics in hip arthroplasty are covered in an additional section. Particular attention is given to different designs of knee endoprostheses and soft tissue balance. Special situations in knee arthroplasty are covered in a special section. Recent advances in computer technology created the possibility for the routine use of navigation in knee arthroplasty and this remarkable success is covered in depth as well. Each chapter includes current philosophies, techniques, and an extensive review of the literature.

### **How to reference**

In order to correctly reference this scholarly work, feel free to copy and paste the following:

Eun Kyoo Song and Jong Keun Seon (2012). Computer Assisted Orthopedic Surgery in TKA, Recent Advances in Hip and Knee Arthroplasty, Dr. Samo Fokter (Ed.), ISBN: 978-953-307-841-0, InTech, Available from: <http://www.intechopen.com/books/recent-advances-in-hip-and-knee-arthroplasty/computer-assisted-orthopedic-surgery-in-tka>

**INTech**  
open science | open minds

### **InTech Europe**

University Campus STeP Ri  
Slavka Krautzeka 83/A  
51000 Rijeka, Croatia  
Phone: +385 (51) 770 447  
Fax: +385 (51) 686 166  
[www.intechopen.com](http://www.intechopen.com)

### **InTech China**

Unit 405, Office Block, Hotel Equatorial Shanghai  
No.65, Yan An Road (West), Shanghai, 200040, China  
中国上海市延安西路65号上海国际贵都大饭店办公楼405单元  
Phone: +86-21-62489820  
Fax: +86-21-62489821

© 2012 The Author(s). Licensee IntechOpen. This is an open access article distributed under the terms of the [Creative Commons Attribution 3.0 License](#), which permits unrestricted use, distribution, and reproduction in any medium, provided the original work is properly cited.

IntechOpen

IntechOpen