

We are IntechOpen, the world's leading publisher of Open Access books Built by scientists, for scientists

6,900

Open access books available

186,000

International authors and editors

200M

Downloads

Our authors are among the

154

Countries delivered to

TOP 1%

most cited scientists

12.2%

Contributors from top 500 universities



WEB OF SCIENCE™

Selection of our books indexed in the Book Citation Index
in Web of Science™ Core Collection (BKCI)

Interested in publishing with us?
Contact book.department@intechopen.com

Numbers displayed above are based on latest data collected.
For more information visit www.intechopen.com



Concepts in Computer Assisted Total Knee Replacement Surgery

M. Fosco¹, R. Ben Ayad¹, R. Fantasia¹,
D. Dallari¹ and D. Tigani²

¹*From First Ward of Orthopaedic Surgery, University of Bologna, Rizzoli Orthopaedic Institute, Bologna*

²*From Department of Orthopaedic Surgery, Santa Maria alle Scotte Hospital, Siena Italy*

1. Introduction

Total knee arthroplasty (TKA) is commonly considered to be a reliable procedure, with implant survival rates higher than 90% at 10 to 15 years of follow-up. The goal of total knee replacement surgery is to relieve pain and obtain better knee function, those achieved by correct patient selection, pre-operative deformity, implant design, correct surgical technique and patient participation in the rehabilitation protocol (Nizard et al, 2002).

Several technical requirements during TKA are important to obtain good results:

- correction of deformities;
- achievement of functional joint motion and stability;
- optimal balancing of soft tissues;
- satisfactory alignment in the frontal, sagittal and horizontal planes.

From literature data alignment in frontal plane must be into 2° or 3° range around a neutral alignment; this thought is demonstrated by Ritter et al who observed that prostheses implanted in varus position had a lower survival rate than prostheses implanted in a neutral or valgus position (Ritter et al, 1994); moreover Jeffery et al observed that when mechanical axis was in 3° valgus-varus range, the loosening rate was 3%, whereas it's 24% when the alignment was out of this range (Jeffery et al, 1991). The alignment in the horizontal plane is of particular importance for extensor mechanism stability, patellar wear, tilted patella, prostheses dislocation or loosening. In a study of Berger et al it was observed that patients with extensor mechanism problems have internal rotation of the femoral and tibial components (Berger et al, 1998).

Technically, there is a definite relationship between the accuracy of implant positioning and long-term durability (Jeffery et al, 1991; Stulberg et al, 2002): the position of prosthetic components and, consequently the alignment of mechanical axis, could be the cause of polyethylene wear due to overload stresses, ending finally by prosthetic loosening. The postoperative mechanical axis of the lower limb should be a straight line passing through the center of the hip, the center of the knee, and the center of the ankle; so that satisfactory

position of a TKA prosthesis is commonly accepted to be an alignment within 3° from this neutral axis (Fig. 1).

To improve precision of implant positioning, various mechanical alignment guides are used, both intramedullary and extramedullary, but technical errors with these conventional surgical techniques still occur. Moreover, mechanical alignment and sizing devices presume a standardized bone geometry that may not be applied to all patients. Even the most elaborate mechanical instrumentation systems rely on visual inspection to confirm the accuracy of stability and of limb and implant alignment at the conclusion of the TKA procedure.

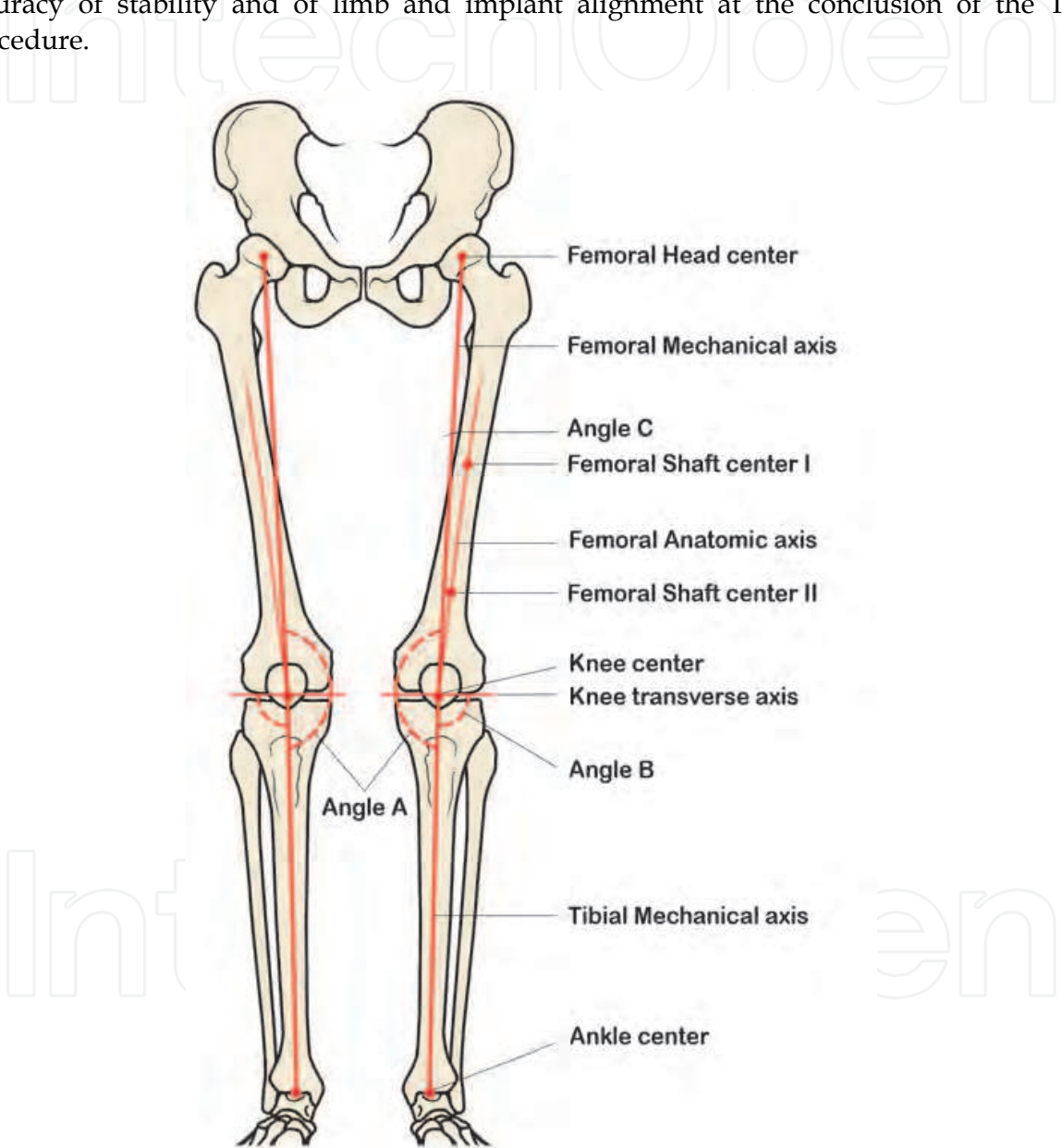


Fig. 1. Axes of the lower limb. Angle A represents knee mechanical physiologic valgus angle of 3°. Angle B represents tibia shaft angle, that is in 3° of varus from knee transverse axis. Angle C corresponds to angle between femoral anatomic and mechanical axis (6° of valgus). Femoral anatomic axis could be easily determined by two points located at the centre of the shaft. Mechanical axis of the lower limb passes near or through knee center and lies from femoral head center to ankle center.

Computer assisted surgery (CAS) for TKA was firstly introduced to improve the accuracy of alignment of the implanted prosthesis, thinking that it could make an inexperienced or occasional TKA surgeon performing more like an expert TKA surgeon, or to address the limitations inherent in mechanical instrumentation systems used for total knee replacement surgery (Jeffery et al, 1991; Stulberg et al, 2002).

During the last Decades CAS instrumentations have been improved in accuracy and various studies have been made to analyse results using this technique in TKA surgery. Advocates of this technique in total knee replacement claim benefits in terms of improving accuracy for alignment of the leg and orientation of the components, as well as a reduction in blood loss and a lower rate of intracranial micro emboli compared with traditional surgery.

The survival rate for modern total knee arthroplasty is reported between 80% to 95% after 10 years of follow up (Buechel et al, 2002; Robertsson et al, 2001), and the most important factor of failure is malalignment of mechanical axis (Jeffery et al, 1991; Rand et al, 1988). Recently the introduction of CAS have gained up improvement in post operative mechanical alignment (Bathis et al, 2004; Chauhan et al, 2004; Chin et al, 2005; Decking et al, 2005; Haaker et al, 2005). However, no clear published results associated with superior clinical and patients perceived functional results and consequently longer survival rate (Stulberg et al, 2006).

2. History of CAS and review of literature

The history of CAS for total knee replacement was dated back to the middle nineties (Picard et al, 1997). Intraoperative navigation in total joint replacement began in 1992, when W. Barger, in Sacramento (California) performed the first computer assisted surgery in orthopaedics for total hip replacement, while the first total knee replacement began in France, in January 1997, by F. Picard and D. Saragaglia after a study on cadavers (Picard et al, 1997; Saragaglia et al, 2001; Delp et al, 1998) and then started a prospective randomized study comparing the computer assisted technique to the conventional surgery in 50 patients. The postoperative mechanical axis was $181.2^{\circ} \pm 2.72^{\circ}$ in CAS group and $179.04^{\circ} \pm 2.53^{\circ}$ in conventional group, with a statistical significant value in favor of CAS group and reduction of outliers. The mechanical axis was in fact between 177° and 183° in 75% of patients in conventional group and in 84% in CAS group (Saragaglia et al, 2001). The Authors concluded their paper saying that computer-assisted surgery for total knee arthroplasty provides remarkably reliable results and that "once the growing pains of this new material have been mastered, all surgeons should be able to expect an improvement in the positioning of prosthetic implantations".

Bathis et al. in a prospective study compared an imageless navigation system to conventional methods using an intramedullary femoral guide and an extra-medullary tibia jig. They reported the postoperative mechanical axis to be within 3° of varus or valgus in 96% of the navigation cases versus 78% of the conventional cases (Bathis et al, 2004).

Other study by Chauman et al. in which they compared a computer-assisted knee arthroplasty with the current conventional jig-based technique in 70 patients randomly allocated to receive either of the methods. All the patients were evaluated postoperatively with computer tomography imaging observing a significant improvement in the alignment

of the components using computer-assisted surgery with regard to femoral varus/valgus (p=0.032), femoral rotation (p=0.001), tibial varus/valgus (p=0.047) tibial posterior slope (p=0.0001), tibial rotation (p=0.011) and femoral-tibial mismatch (p=0.037). The Authors reported that computer-assisted surgery took longer time with a mean increase of 13 minutes regarding the conventional technique, but the blood loss was significantly lower (Chauchan et al, 2004).

A significant number of recent randomized controlled trial studies compared the use of imageless CAS with conventional methods; the results of these studies are shown in Table 1.

Authors	Year of publication	M.A >3° (n/N)		M.A >2° (n/N)	
		CAS	Conv	CAS	Conv
Saragaglia	2001	4/25	6/25	10/25	11/25
Sparmann	2003	0/120	16/120	3/120	27/120
Chauhan	2004	5/34	10/30	11/34	11/30
Bathis	2004	3/80	18/80	15/80	32/80
Stulberg	2006	21/38	19/40	30/38	30/40
Pang	2009	2/35	9/35	7/35	17/35
Choong	2009	7/57	21/54	\	\

Table 1. Different RCTs studies comparing post-operative mechanical angle in conventional and imageless CAS knee arthroplasty. CAS=Computer Assisted Surgery, Conv= conventional surgery, M.A= Mechanical Angle, n= number of knees, N= total number of knees.

Most of those meta-analysis studies of the best available evidence indicate significant improvement in component orientation and a better restoration of the mechanical limb alignment when CAS is used (Mason et al, 2007). In review of the past literature, there were only few papers which have indicated that there was no significant difference between computer-assisted navigated TKA and conventional TKA (Mielke et al, 2001). In the report by Kim et al (Kim et al, 2007), bilateral sequential total knee replacements were carried out by one senior author in 160 patients (320 knees). One knee was replaced using a CT-free computer-assisted navigation system and the other side replaced conventionally without navigation. The Authors studied their cases with both standard radiological and CT imaging to determine the alignment of the components. The results of imaging and the number of outliers for all radiological parameters were not statistically different between the groups (p=0.109 to p=0.920). The post-operative limb alignment (femoral-tibial angle) exceeded 3° of varus/valgus deviation in only 18% (Sparman et al, 2003) of the patients operated by using the conventional technique, and in about 21%(Jenny et al, 2001) of the patients that were operated by navigation system.

3. Different computer navigation systems

Existing computer assisted surgery system must allow the accomplishment of the objectives above described: ensure optimal positioning of the prosthesis in the three planes (frontal, sagittal and horizontal); ensure optimization of the ligament balance; maintain joint stability (Nizard et al, 2002).

Firstly, computer-assisted navigation systems could be distinguished between active and passive computer systems as described by Picard et al. (Picard et al, 2001).

Active computer systems, also named robots, are able to realize the entire surgical procedure after the knee as been exposed through a conventional approach. The use of such complicated systems is viable only if the installation and functions during the surgical procedure can be performed within a reasonable time. The results of such systems have been presented in different studies (Tenbusch et al, 2001).

Passive computer systems do not perform any part of the surgical procedure which remains under direct control of the surgeon, that allowing him to apply and positioning the cutting guides.

Location systems for such CAS procedure crucially require a perfect and permanent fixation to the instrument. Two location systems are currently available, magnetic field detector and optical detector. Magnetic location systems are designed to generate a cylindrical field of about 80cm of diameter, received by collectors called dynamic reference frames (DRFs), which are fixed to the instruments or to the bone. This system does not require any particular position of the surgical team around the patient or between the system and the collectors, so no line of sight issues are present with EM tracking, but this system introduces the problem of metal influence. In fact, their failure is related to the use of ferromagnetic instrument in conventional technique like bone retractors, hammers and drill as well as mobile phones and hand watches. Lionberger (Lionberger et al, 2006) who studied the various problems of electromagnetic technology, pointed out the limited distortion of titanium, cobalt-chrome and some stainless steels. The software is furthermore designed with the possibility to induce an "off-signal" before the externally-generated source of instability or signal inaccuracy can be produced. Potentially, the collectors are linked to the computer system by wires, that could be troublesome during surgery.

Optical systems using infrared light are the most widely employed method of connection between the surgical field and the computer. These consist of two or three infrared camera sensors that detect the position of active or passive trackers implanted on the leg through rigid bodies or special shape instrument, which must all remain within the line of sight (Fig. 2).

The active leg trackers use systems that have light emitting diodes (LED) which sent out light pulsed to the optical localizer (Fig. 3). Opposite passive leg trackers use reflecting spheres mounted to the rigid body; recently new trackers are available consists of reflective discs connected together in angular arrangement (Fig. 4). Potential mistakes of data detection could be due to proximity of two localizers.

The advantage of optical systems is accurate detection without possible distorted information, while main disadvantages are usually due to reflecting spheres wear, the volume of infrared camera in the surgical room and also necessary adaptable positioning of surgical team personal to the system until the collectors have been located by the camera (Table 2).

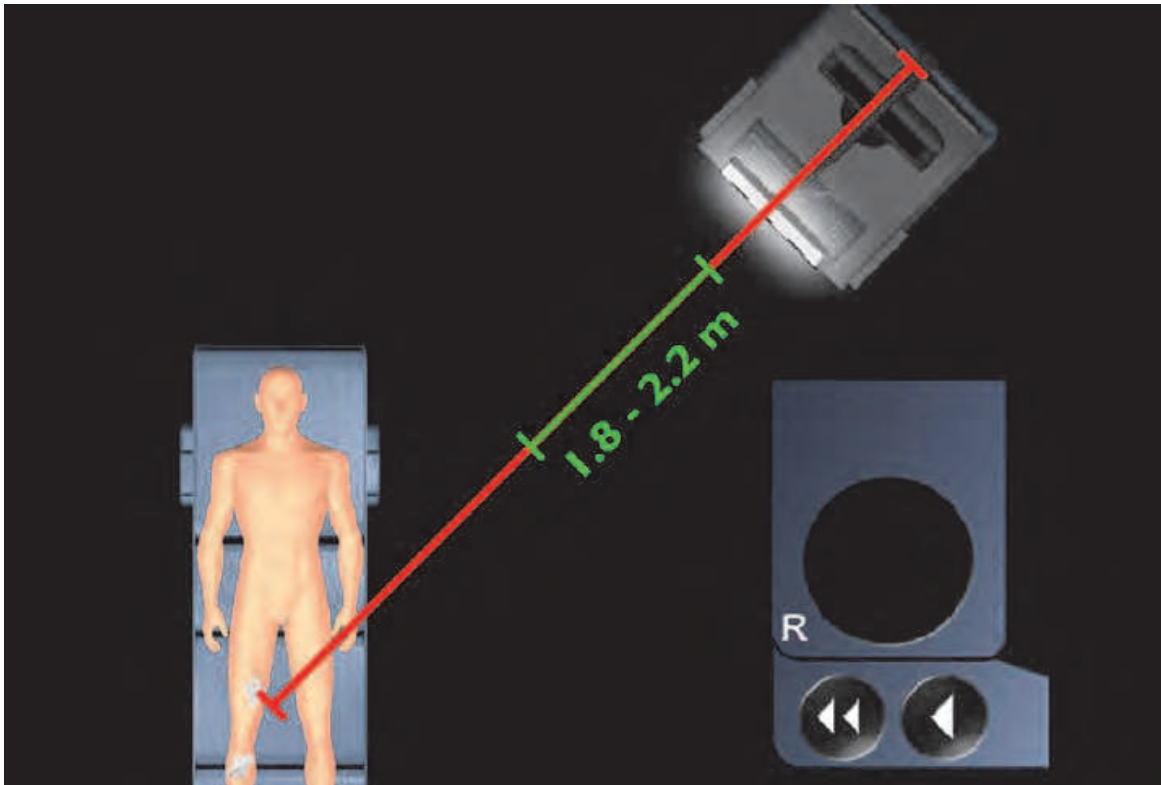


Fig. 2. Working station, consisting on display monitor and infra-red light camera sensors attached to stander, is positioned in a far position. Trackers have to be always within the line of sight with the camera. (Courtesy of B.Braun, Melsungen, D).

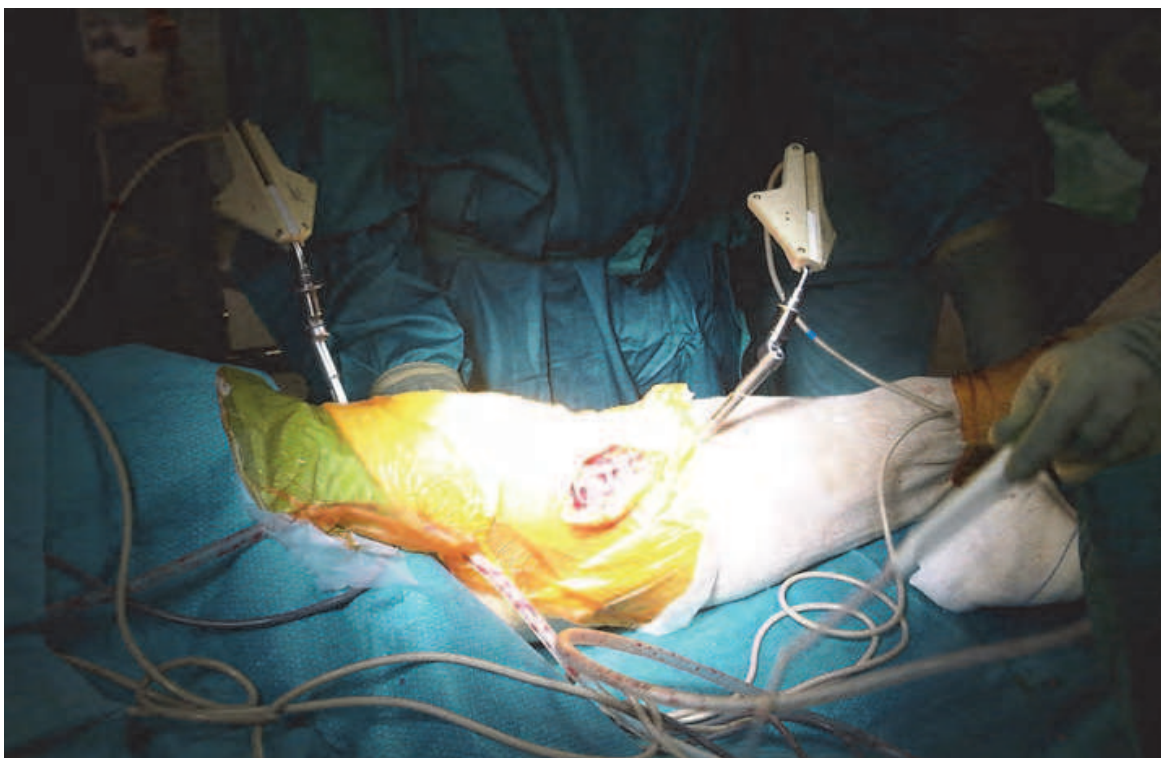


Fig. 3. Active optical trackers and intra-operative alignment of femoral and tibial parts

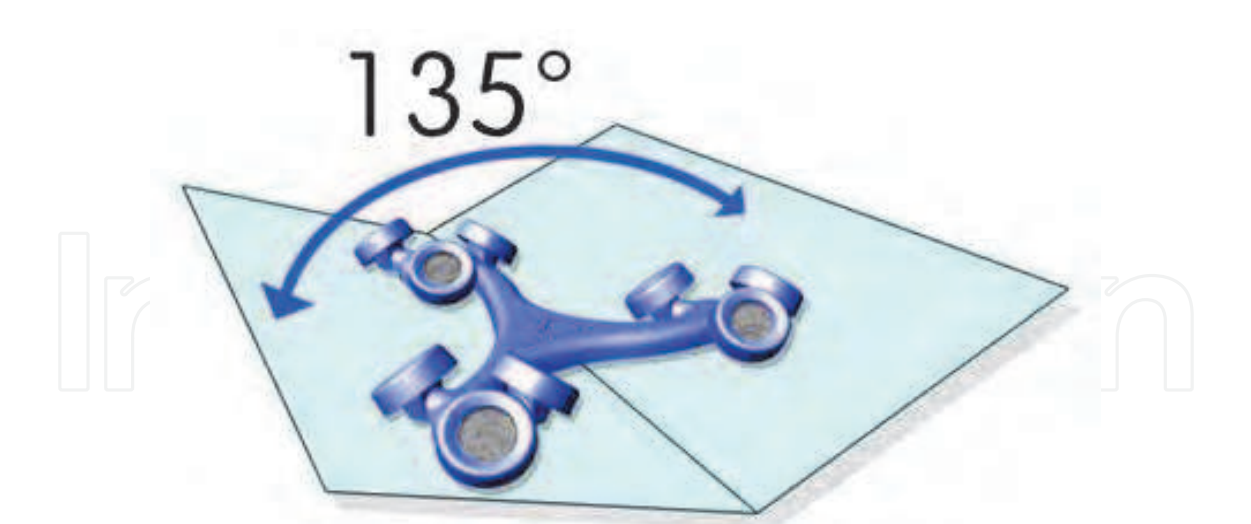


Fig. 4. Disc shape optical passive trackers connected in angular pattern (Courtesy of Zimmer, Warsaw, USA)

NAVIGATION SYSTEM		MAIN DISADVANTAGES
According to Picard et al, 2001	Active computer systems (robots)	Technically complicated and expensive system, very long surgical time
	Passive computer systems	Partially surgeon controlled-dependent results
According to Stulberg et al, 2002	Image-based (CT, MRI, fluoroscopic view)	Irradiation exposure of patient, adjunctive cost for peri-operative imaging procedure
	Image free	Additional surgical time, no clear information concerning the implants rotation
SIGNAL DETECTOR		MAIN DISADVANTAGES
Magnetic field detector		Metal influence needing specific-instrumentation, sometimes distorted information detected Mistakes of data due to proximity of localizers, bulky camera, adaptable positioning of surgical team personal
Optical detector		
TRACKER		MAIN DISADVANTAGES
Active optical trackers		Less detection accuracy due room light interference
Passive optical trackers		Needing instrument calibration as first step, frequent cleaning of reflecting spheres/ discs during surgery

Table 2. Different systems and components of navigation surgery.

3.1 Image-based navigation systems

According to Stulberg et al. CAS for joint replacement can be classified into two categories: image based and image-free navigation systems.

Using imaging devices the preoperative morphological data acquisition is necessary, which is gained by two different sources. The first one is preoperative imaging by a CT scan or MRI; second one is perioperative fluoroscopy imaging, performed in the operating room, during surgery. This imaging requires a specially modified fluoroscopy unit and entails the maneuvering of a relatively bulky and expensive apparatus during surgery.

CT-scan imaging modality which allow 3D reconstruction of bone morphology and bony landmarks, is probably the most time consuming step for the surgeon, while the MRI could be used in order to have information on soft tissue structure, but definition of bony landmarks is far inferior to that of CT-scan.

In such system, the registration and identification of special pointes process during the surgery is needed in order to match it with the image saved on the screen. Programmed software, using a mathematical algorithm, is able to help surgeon to identify these points during the matching process. Main advantage of image based systems is that it can be used in cases with extreme deformities, as seen in post fracture malunion and some bone disease, like Paget disease. It is possible to reconstruct 3D models when ipsilateral hip arthroplasty is present, and also in cases of revision of mono-compartmental knee prostheses or in two stage revision with temporary spacer in situ. However the main disadvantage is mandatory to obtain a preoperative CT-scan which is an additional hospital expense and a source of irradiation for the patients (Nizard et al, 2001).

Although potentially useful for knee reconstructive surgery imaging devices currently employed with CAS have been at present abandoned as requiring additional steps without providing significant benefits.

3.2 Image-free navigation systems

Image-free optical systems using infrared light are currently the most widely employed method of connection between the surgical field and the computer. These systems utilizes either optical (infra-red light), or electromagnetic devices that detect the position of active or passive markers implanted on the leg through rigid bodies or special shape instrument, which must all remain within the line of sight. The most important characteristic of this system is its ability to provide instant information regarding in vivo kinematics of the joint thus allowing the surgeon to quantify data, have dynamic intraoperative feedback or information and obtain more reproducible results..

First step is localization of important bony points: center of femoral head, knee center and ankle center are main points to identify (Fig. 5). Junction between these three points define the mechanical axis of lower limb. Several methods are available to define these points, which include:

- Center of femoral head localized by kinematic analysis of the hip joint; passive mobilization of the hip is needed to determine this center without reference point on the iliac crest.
- Knee center can be defined in two ways, one is based on kinematic analysis which requires passive mobilization of the knee, the other way is based on the definition of anatomic landmark (i.e. intercondylar trochlear notch, anterior tibial plateau eminence) (Yoshioka et al, 1989).

- Ankle center which is also determined by two methods, kinematic analysis of the ankle during passive motion, the other method is acquisition of anatomical points on the medial and lateral malleoli.

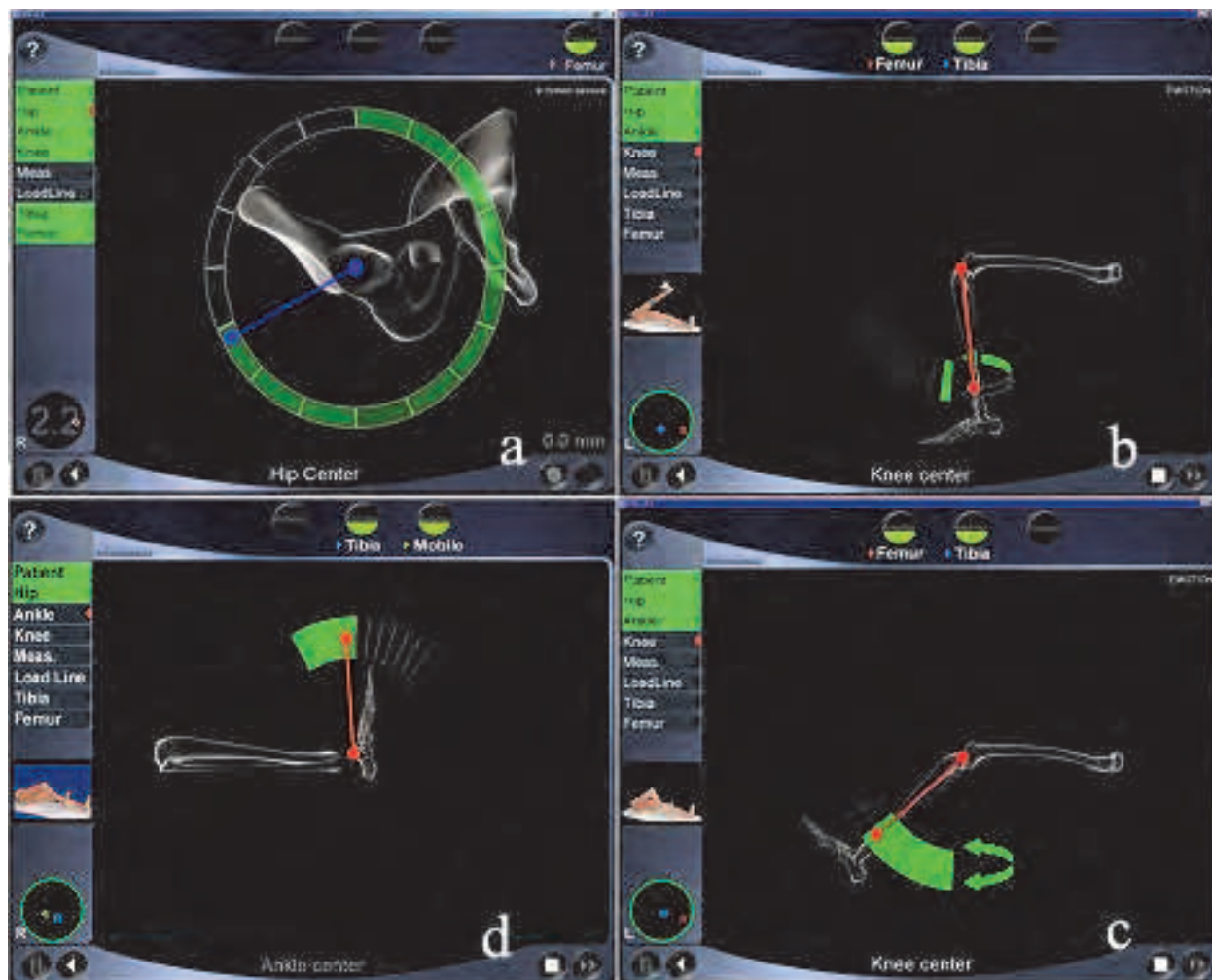


Fig. 5. Localization of hip (A), knee (B,C) and ankle (D) joint center.

Two types of information can be given by these image free systems, in two or three dimensions (3D). In two-dimensional systems, only the axes in frontal and sagittal planes are available. In 3D systems, digitization of anatomical structures allows reconstruction of an almost complete distal femur or proximal tibia using either statistically reshaped bony structures or completely redesigned bony structures from direct digitization.

The most important advantage of this system is avoidance of irradiation exposure, while their disadvantages are represented by additional time needed during the operation, and no clear information obtained concerning the rotational position of the implants (Arima et al, 1995; Kats et al, 2001; Saragaglia et al, 2001).

The first results reported with these systems are encouraging (Saragaglia et al, 2001; Clemens et al, 2001; Jenny et al, 2001; Kiefer et al, 2001). In a randomized study Saragaglia et al. have compared 25 knees operated with a conventional technique and 25 knees operated with the Orthopilot® navigation system; a satisfactory alignment in the frontal plane,

defined as a mechanical axis between 3° varus and 3° valgus alignment, was observed more often with the navigation system (84% versus 75% conventional technique). In a case-control study, Jenny et al. compared 60 prostheses implanted with the Orthopilot® system to 60 prostheses implanted using a conventional technique. With the navigation system 53 out of 60 prostheses were in the 3° valgus-3° varus range, whereas only 43 out of 60 were in this range with conventional system ($p < 0.05$). Tigani et al. analysing 123 patients who underwent TKA with CAS, have retrospectively compared two different techniques of total knee arthroplasty (gap balancing and measured resection) utilizing different computer navigation systems; using inter class correlation ICC and paired *t*-test, they reported that no difference regarding the joint line level, and significant improvement in the ability to create mechanical alignment at $180^\circ \pm 3^\circ$ in frontal plane in 95% of the operated patients (Tigani et al, 2010).

4. Indication for CAS in knee surgery

Computer-assisted navigation seems to be helpful in those difficult situations where accurate alignment remains crucial but traditional instrumentation is not applicable. Traditional cutting guides during knee arthroplasty relies on intramedullary (IM) femoral instruments and either intramedullary or extramedullary (EM) tibial instruments to obtain proper axial alignment.

Intramedullary instruments cannot be used in patients with:

- Retained hardware that would be difficult or inadvisable to remove (Fig. 6) or long-stemmed hip implants (Fig. 7) that could obstruct introduction of long IM instruments;
- Severe posttraumatic extrarticular femoral deformity when one is unable to pass an IM guide to accurately make a distal femoral cut (Fig. 8);
- IM guides may increase the infection risk in patients with history of focal diaphyseal osteomyelitis around the knee joint (Fehring et al, 2006);
- Patients with severe cardiopulmonary disease or a history of foramen ovale who may be at risk for embolic dissemination because of femoral IM instrumentation (Berman et al, 1998).

These problems can be avoided with extramedullary jigs on the tibial side, but EM instrumentation is cumbersome on the femoral side, which requires radiographically identifying the femoral head and a freehand technique of pinning the distal femoral resection guide. In cases with retained hardware or prosthesis, the distance from the articular surface is a topic question to take into consideration. The surgeon should be aware that in addition to the 9 to 11 mm of usual resection amount on distal femur a supplementary distance of at least 12 to 17 mm of femoral bone, according to the size and type of prosthesis, is necessary for the central box housing of posterior stabilized prosthesis (Haas et al, 2000).

In cases of extrarticular deformity, simultaneous or staged corrective osteotomy and total knee arthroplasty has been advocated to achieve normal alignment of the long bones and better ligament balancing. However, this technique may be associated with substantial complications, including nonunion at the osteotomy site and arthrofibrosis (Engh et al, 1990; Lonner et al, 2000).

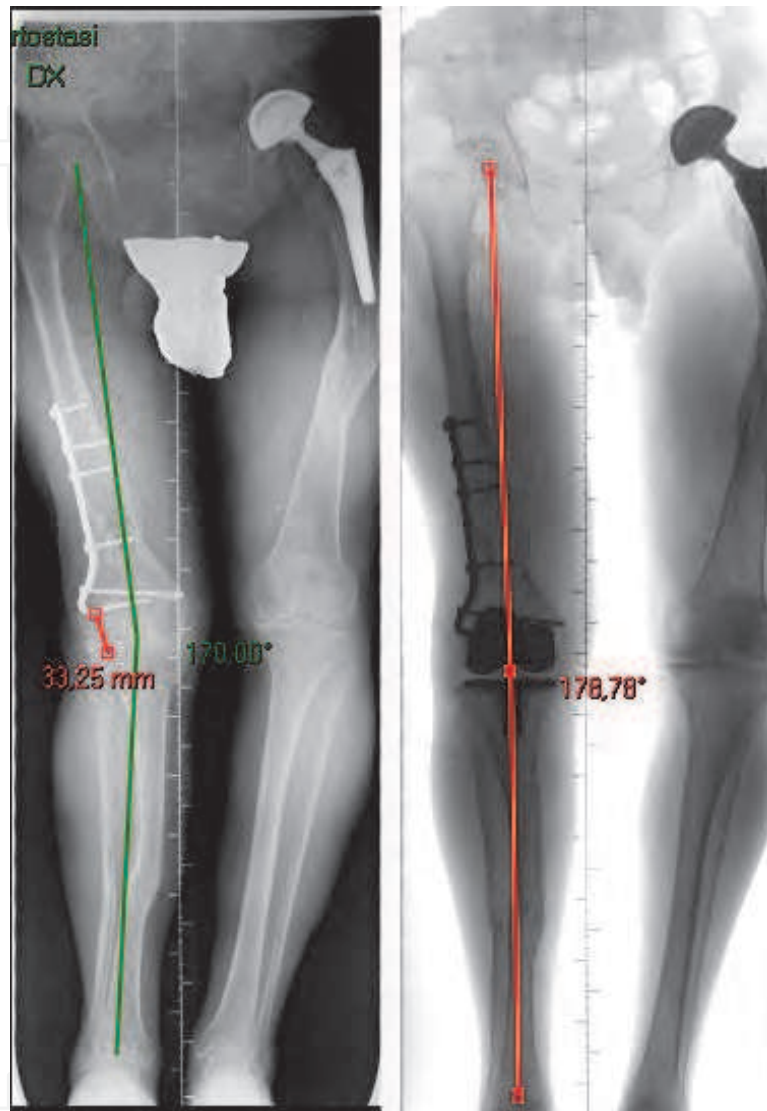


Fig. 6. Patient with blade-plate on distal right femur that prevent use of intramedullary guides. CAS during TKA surgery allow to correct mechanical axis and good positioning of prosthetic components.

An alternative to the combined osteotomy/TKA approach is to perform intraarticular bone resection and soft-tissue balancing. This procedure may be appropriate when the insertion of the collateral ligaments of the knee would not be jeopardized by the intra-articular bone resection (Wolff et al, 1991). The limits of intra-articular correction of an extrarticular deformity have been elucidated by Wang (Wang et al; 2001), who found that intraarticular resection without osteotomy was successful for patients with an average of 20° of coronal

plane deformity in the tibia and femur. So that CAS facilitates correction of the deformity and helps avoid massive intra-articular soft tissue release.

Obese patients are another challenging subgroup undergoing TKA. In these cases CAS helps to accurately estimate the center of the femoral head and the overall limb and component alignment, otherwise difficult to be clinically judged with conventional technique. Various authors (Berend et al, 2004; Choong et al, 2009) reported higher incidence of revision when body mass index was more than 30, with only 56% of knees having a final mechanical axis aligned within 3° of neutral using conventional technique, compared to 93% of knees in the navigated group.

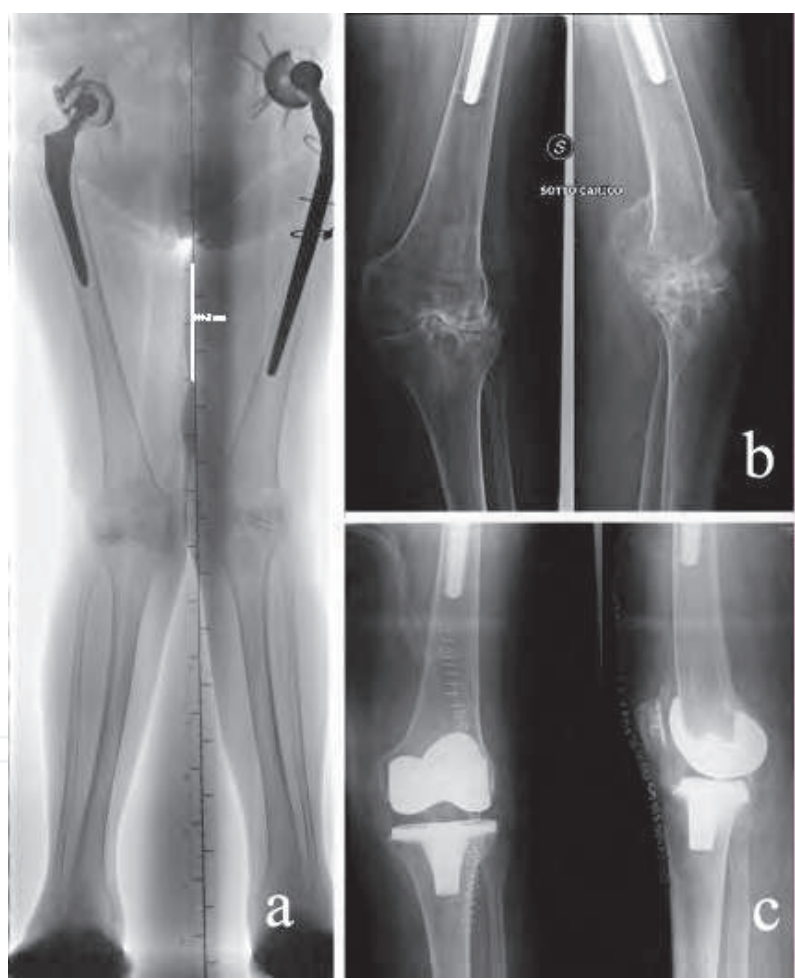


Fig. 7. Valgus osteoarthritic knees in patient with long stemmed arthroplasty at left hip. Computer-assisted surgery allow to implant knee prosthesis without use of intramedullary femoral guide.

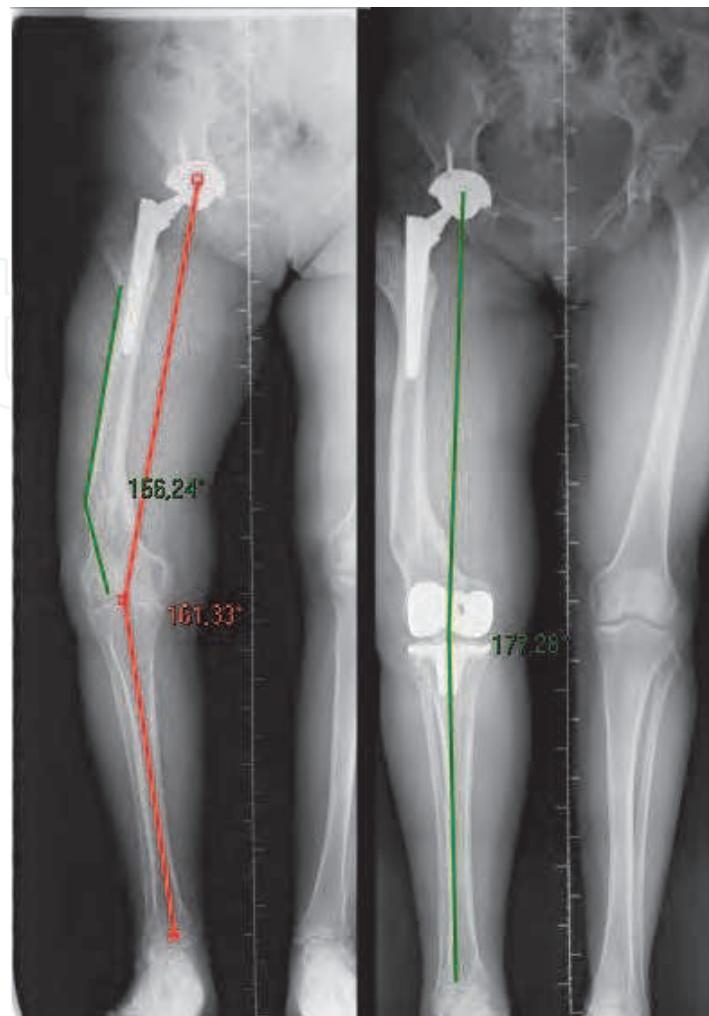


Fig. 8. Knee osteoarthritis with extrarticular femoral post-traumatic deformity(malunion). TKA was performed using computer-assisted technique with intrarticular correction of the deformity.

5. Advantages and disadvantages of CAS

Computer-assisted surgery in TKA offers several advantages against traditional surgery, that can be resumed as follow:

- Better accuracy in bone cutting and positioning of prosthetic components (Martin et al, 2007; Bathis et al, 2004; Aravind et al, 2011). In a study of Martin et al, they found that the mechanical axis of the limb was within 3° varus/valgus in 92% of the patients who had navigated procedures versus 76% of patients who had conventional surgery. The tibial slope showed a rate of inaccuracy of 3° or less for 98 % of the patients in the navigated TKA group versus 80% of the patients in the conventional group (Martin et al, 2007);
- The possibility to do a three-dimensional planning and alignment of the prothesis (Stockl et al, 2004);
- Dynamic assessment of deformity at any angle as opposed to conventional technique where tensioning devices can be used in 0° extension and 90° flexion (Aravind et al, 2011);

- Assessment of soft tissue and collateral tension when gap balancing technique applied (Chauhan et al, 2004);
- Intra-operative range of motion analysis to achieve maximum function, as confirmed by some reports like that of Austin et al, who observed as navigation could be a reliable tool for performing in vivo assessment of range of motion (Austin et al, 2008);
- Decreased incidence of pulmonary embolism in knee surgery, due to using of only extra-medullary guidance (Kalairajah et al, 2005);
- Minimally invasive surgery, which allows lesser blood loss during and after operation, reduces risks at transfusion and decreased hospital admission duration, those gives financial saving (Kalairajah et al, 2005);
- Early rehabilitation and shorter hospital stay, due to improved accuracy in limb alignment and soft tissue balance obtained with computer-assisted TKA (Choong et al, 2009).

Nevertheless, there are some disadvantages by using navigation:

- The surgical time was longer for navigated TKA than for the conventional procedure (Martin et al, 2007);
- Additional incisions for reference pins;
- Increased incidence of fractures or infections related to the pins sites (less than 1% reported complication rate) (Wysocki et al, 2008; Chi-Huan et al, 2008; Manzotti et al, 2008; Bonutti et al, 2008; Jung et al, 2007; Ossendorf et al, 2006). According to literature, larger pins diameter (5 mm), eccentric or repeated drilling and diaphyseal placement may be at greater risk of such complication (Wysocki et al, 2008; Chi-Huan et al, 2008);
- Financial saving by low hospital duration cost effective in health care however is still not realized. Solver et al. applying Moarkov decision model to evaluate the impact of hospital volume on the cost-effectiveness of CAS arthroplasty, have revealed that CAS is less likely to be cost-effective investment in health care improvement in centers with low volume of joint replacements, where its benefit is most likely to be realized; anyway it may be effective in centers with high volume of joint replacements (Solver et al, 2008).

Computer system is very sophisticated and, if used correctly, will improve accuracy. The system enhances the surgeon's perspective but should never replace it. Some pitfalls that can arise by using this technique include:

- Malfunctioning of the navigation system due to: dirty reflectors, camera or rounding errors or dislodgement of the reference pins (low rate of about 0.5%) which is likely due to less secure fixation afforded by unicortical fixation (Richard et al, 2010);
- Stretching against the extensor mechanism by reference pins;
- Inaccurate identification of the anatomic bone landmarks (Robinson et al, 2006);
- Avulsion of the patellae tendon by excessive traction on the patella;
- Inappropriate tibia rotation could be a less frequent pitfall when using imageless systems;
- Data registration inaccuracy; nevertheless causes to this problem must be understood by surgeons who use these devices. At least three potential causes of registration inaccuracy were identified when this image-free navigation system was applied to total knee replacement surgery:
 1. Preoperative deformity and instability related to the original pathology of arthritic knee.
 2. Computer hardware and software inaccuracy.
 3. Surgical technique.

Additional updates of the computer software and surgical hardware are important because they appear to have substantially reduced the registration variations that result from all three causes of this type of inaccuracy in computer-assisted orthopaedic applications.

6. Surgical strategies with CAS

As for standard conventional surgery, two surgical strategies are possible in TKA with CAS (Hungerford et al, 1982): a measured resection approach (Fig. 9), in which bone landmarks are used to guide resections equal to the distal and posterior thickness of the femoral component, or a gap-balancing approach (Fig. 10), in which equal collateral ligament tension in extension and flexion is sought before and as a guide to definitive bone cuts. Both techniques aim to have symmetric flexion and extension gaps in terms of gap size and angular alignment.

In computer aided technique, after the first step of registration and identification of the key anatomic landmarks the computer system will identify the bone position in the space, the pre-requisite for the registration are the trackers which are attached to the bone, thus commonly considered the most fundamental aspect of registration accuracy. After registration process, the computer system kinematically gathers the information regarding joint anatomy, limb alignment, level of bone to be resected and matches knee anatomy with the size and type of the implant. The following implementation and verification step determine cutting blocks position, component to component position and soft tissue balance (Aravind et al, 2011).

Surgical steps in imageless CAS knee arthroplasty, do not require any preoperative plane or image. The initial step is the instrument calibration in passive rigid body systems (Orthosoft- Zimmer®) (Fig. 11), or without calibration in active rigid body systems (Orthopilot®- Aesculap/B-Braun).

This followed by the placement of the femoral and tibial trackers or rigid bodies that should be fixed to bone with precaution, to avoid any injury of adjacent neurovascular structures and the interference with surgical tools. The trackers should be in the field of the infrared camera to remain detectable throughout the procedure. Trackers fixation should be positioned with an angle of almost 90° with respect to diaphysis and on vertical axis 30-45° medially in femur and 45°-60° medially in tibia.

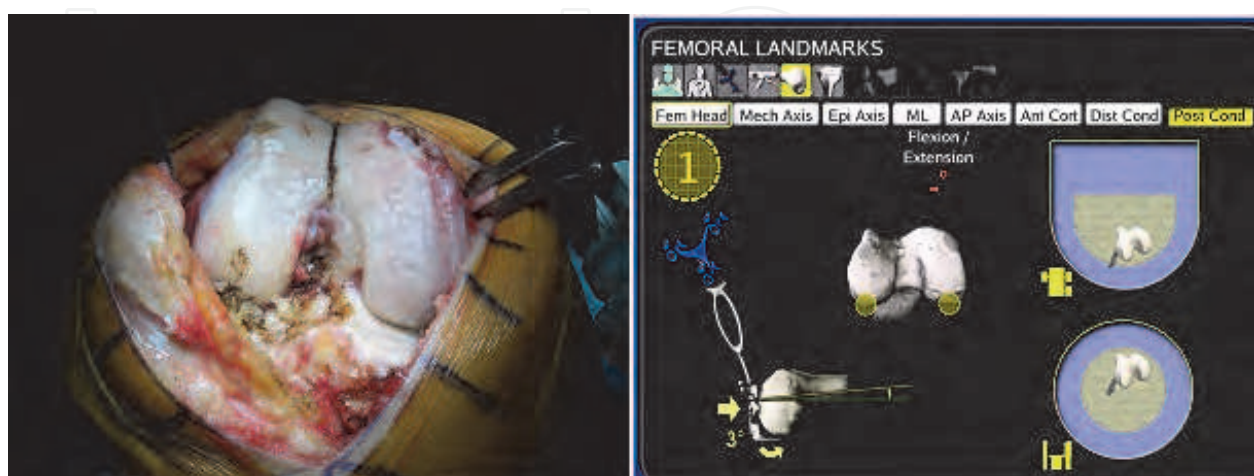

Fig. 9. The measured resection approach, in which bone landmarks are used to guide resections equal to the distal and posterior thickness of the femoral component

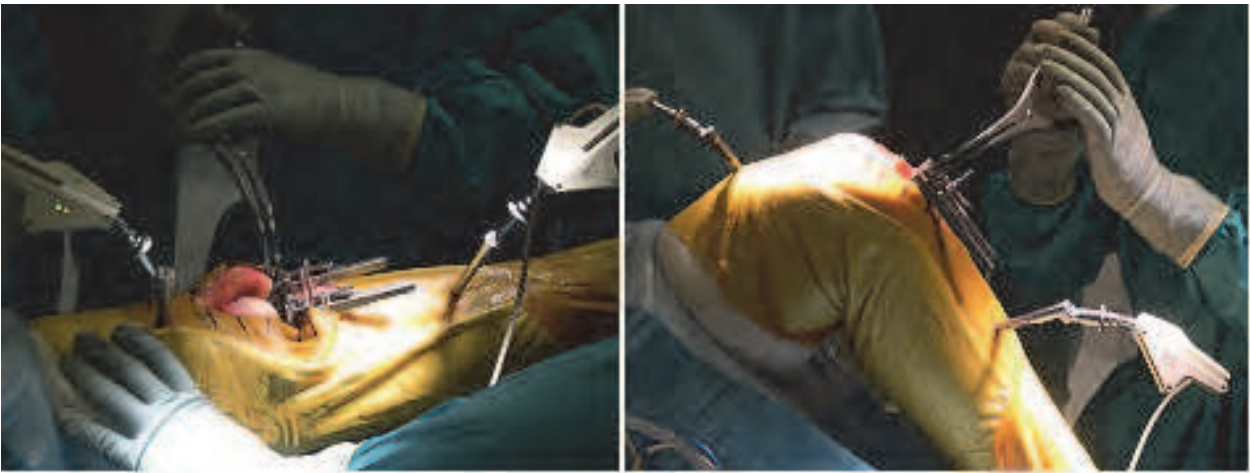

Fig. 10. The gap balancing approach, in which identical collateral ligament tension in extension and flexion is sought before and as a guide to final bone cuts

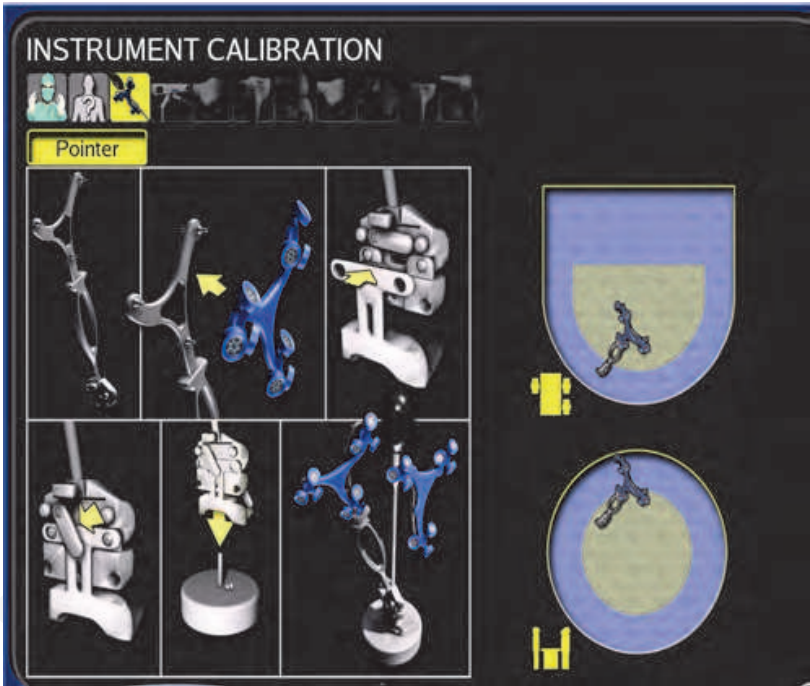


Fig. 11. Passive rigid bodies trackers calibration.

Once the knee is exposed next step consists on registration of the anatomical axis through the localization of the center of the knee, the center of the hip, and the center of the ankle joint using kinematic registration, those visualized on the computer screen (Fig 5). The other anatomical landmarks located with the pointer or special paddle and necessary for the virtual reconstruction of the lower limb axis are the distal, posterior femoral condyles, medial/lateral tibial plateau and anterior tibial eminence. When soft tissues balance technique is used, it can be performed before or after bone resections with the trial spacer in place or using mechanical retractors both in extension and 90° flexion (Fig. 12).

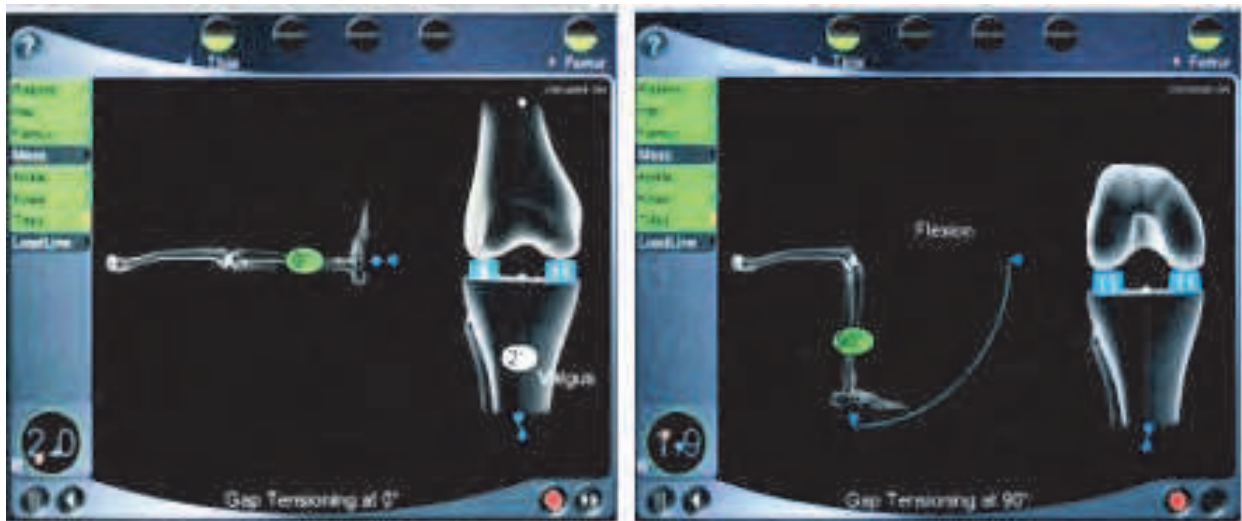

Fig. 12. Visualization of gap after tensioning of soft tissue in extention and flexion.

Now the initial lower limb mechanical axis can be visualized on the screen and in different angles of flexion; in addition the degree of deformity to be corrected by bone cuts, and the initial knee range of motion can be registered. The most important surgical step in navigating TKA is the planning for 3D reconstruction for bone cuts and prosthesis orientation, through the working screen visible on the monitor (Fig. 13). During this step, the surgeon by moving the virtual pointer tip, can target any value on the screen, except for the measured gaps. So that, through this procedure all femur cuts and sizes of the components to be implanted can be planned step by step, as well as the notching and the implant rotation.

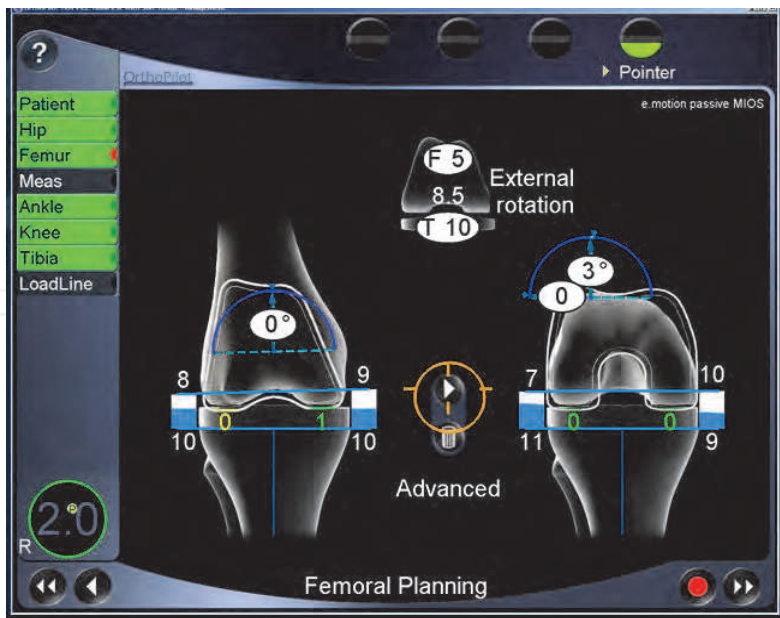


Fig. 13. Planning screen guided by surgeon.

The varus/valgus angle display, resection height display and femoral rotation display can be modified during this step before starting femoral cuts and to achieve equal rectangular gap spaces in both flexion and extension. The tibia display on the screen indicates the gap

remaining after all cuts and after the implantation of all components, assuming possible additional soft tissue release will be carried out. Computer-based alignment systems have been developed to address the limitations inherent in mechanical instrumentation, so that it is recommended that before definitive prosthetic components implantation, the limb axis and the knee range of motion be controlled by CAS monitoring with the trial component in place (Fig. 14).

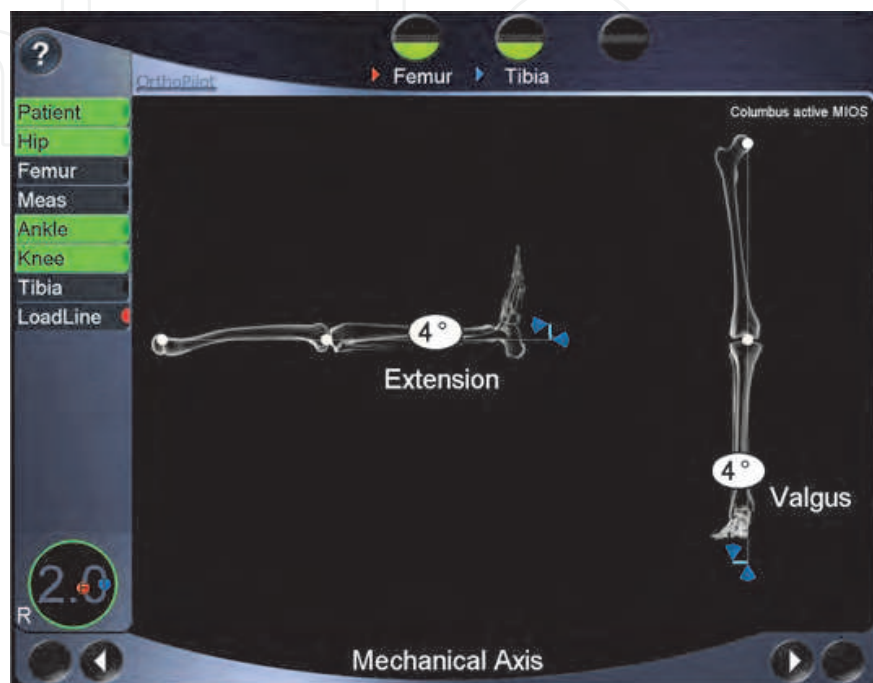


Fig. 14. Limb axis and range of motion controller before component implantation.

7. Conclusions

Total knee prosthetic component implantation using computer aided navigation allows the surgeon to reproduce the mechanical axis measured on full-length of the lower limb radiographs, thus reducing the number of outliers in the alignment of the limb compared with traditional instrument techniques.

Although analysis of alignment and prosthetic component orientation after computer-navigated and conventional implantation shows different results, three recent statistical studies of alignment outcome for computer-assisted knee surgery indicate significant improvement in accuracy of component orientation and mechanical axis restoration (Bauwens et al, 2007; Mason et al, 2007; Tigani et al, 2011).

Furthermore, regarding tibial component orientation, some authors have demonstrated notable improvement in sagittal-tibial component angle (i.e., the tibial slope angle) which can be reconstructed accurately and reproducibly to match the original value of the tibial plateau, although some studies did not find that the alignment in the sagittal plane of the tibial component was improved with navigation guidance (Biasca et al, 2009; Chauhan et al, 2004; Ensini et al, 2007; Matziolis et al, 2007; Stoćkl et al, 2004).

Debate about whether a CAS system improves the rotational alignment of the femoral component still exists and as described in the text, several femoral reference landmarks have

been proposed to establish proper rotational alignment of the femoral components, although there is no consensus about the best landmarks to gauge that. Siston et al (Siston et al, 2005), in a cadaver study, they found high variability in the rotational alignment of the femoral component. This variability may be explained by the surgeon's greater or lesser ability to identify the medial epicondyle intraoperatively and by the ascending learning curve for the surgeon associated with habitual use of navigation devices, they can minimize the errors in the femoral landmark acquisition.

Although, the rotational mismatch between the tibial and femoral components is decreased with the role of CAS in knee replacement, controversy still exists as to whether navigation systems improve the rotational alignment of the tibial component in the axial plane (Chauhan et al, 2004; Siston et al, 2007). One solution to avoid such complication is the technique describe by Dalury (Dalury et al, 2001) and Eckhoff (Eckhoff et al, 1995) in which the orientation of the tibial tray was determined by allowing it to float into position with respect to the femoral component while the knee was placed through a full arc of motion and in a CT scan postoperative study it was documented an accurate alignment of the tibial component (Biasca et al, 2009).

Other certain factors to be faced intraoperatively, even by experienced surgeon is the patient bone status: in severe osteopenic bone the pins placed to hold the trackers may become loose, making all further measurements inaccurate. Therefore, the surgeon must be very careful when handling pins and trackers. Moreover, attempts to cut through sclerotic areas of bone might create resection errors due to forced bending of the saw blade which can occur with conventional instrumentation as well. Such pitfall can be recognized with the computed-assisted navigation only by using the verification plate of the knee computer system, which allows the surgeon to check-out every cutting procedure during the operation and to verify the correct resection level and also of the programmed joint line level.

Although someone argued that CAS is advised for use for inexperienced surgeons, last researches did not support the assumption of an automatic advantage (Yau et al, 2008). The use of computer navigation technology improve the accuracy in recreation of mechanical alignment in TKA when compared with the conventional jig-based technique. Nevertheless the volume of the operations performed by the surgeon, the experience in using computer navigation technology and severity of the preoperative deformity seems to be major contributing factors.

Knee navigation systems are not yet universally accepted, and their cost/benefit ratio remains a matter for further discussion. In fact, there is an absence of high quality studies demonstrating a longer implant survival rate, better clinical outcome, or enhanced postoperative function.

However CAS has an important value and could be more useful in those particular cases in which standard mechanical instrumentation cannot be used: presence of angular deformities, IM sclerosis, long-stemmed hip implants, or hardware within the femoral canal.

8. Acknowledgment

The authors did not receive any outside funding or grants in support of their research for or preparation of this work.

9. References

- Arima J., Whiteside L. A., McCarthy D. S., White S. E. 1995. Femoral rotational alignment, based on the anteroposterior axis, in total knee arthroplasty in a valgus knee. A technical note. *J Bone Joint Surg Am*, Vol.77, No.9 (September 1995), pp. 1331-34, ISSN 1535-1386
- Austin, MD Elie Ghanem, MD Ashish Joshi, MD Rachel Trappler, BS Javad Parvizi, MD, FRCS William J. Hozack, MD. (2008). The Assessment of Intraoperative Prosthetic Knee Range of Motion Using Two Methods. *J Arthroplasty*. Vol.23, No.4, (June 2008), pp.515-21, ISSN:0883-5403
- Bäthis H, Perlick L, Tingart M, Lüring C, Zurakowski D, Grifka J. (2004). Alignment in total knee arthroplasty. A comparison of computer-assisted surgery with the conventional technique. *J Bone Joint Surg Br*, Vol.86, No.5, (July 2004), pp.682-7, ISSN:0301-620X
- Bauwens K, Matthes G, Wich M, Gebhard F, Hanson B, Ekkernkamp A, Stengel D. (2007). Navigated total knee replacement. A meta-analysis. *J Bone Joint Surg Am*, Vol.89, No.2, (February 2007), pp.261-9, ISSN 1535-1386
- Berend ME, Ritter MA, Meding JB, Faris PM, Keating EM, Redelman R, Faris GW, Davis KE. (2004). Tibial component failure mechanisms in total knee arthroplasty. *Clin Orthop Relat Res*, Vol.428, (November 2004), pp.26-34, ISSN 1528-1132
- Berger RA, Crossett L.S, Jacobs J.J, Rubash H.E. Malrotation causing patellofemoral complications after total knee arthroplasty. *Clin Orthop Relat Res*, Vol.356, (November 1998), pp.144-53, ISSN 1528-1132
- Berman AT, Parmet JL, Harding SP, Israelite CL, Chandrasekaran K. (1998). Emboli observed with use of transesophageal echocardiography immediately after tourniquet release during total knee arthroplasty with cement. *J Bone Joint Surg Am*, Vol.80, No.3, (March 1998), pp.389-94, ISSN 1535-1386
- Biasca N, Schneider TO, Bungartz M. (2009). Minimally invasive computer-navigated total knee arthroplasty. *Orthop Clin N Am*, Vol.40, No.4, (October 2009), pp.537-63, ISSN 1059-1516
- Bonutti P, Dethmers D, Stiehl JB. (2008). Femoral shaft fracture resulting from femoral tracker placement in navigated TKA. *Clin Orthop Relat Res*, Vol.466, No.6, (June 2008), pp.1499-502
- Buechel FF. (2002). Long term follow up after mobile-bearing total knee replacement. *Clin Orthop Relat Res*, Vol.404, (November 2002), pp.404:40, ISSN 1528-1132
- Chauchan, RG Scott, W Breidhal. (2004). Computer-assisted knee arthroplasty versus a conventional jig-based technique. A randomised, prospective trial. *J Bone Joint Surg Br*, Vol.86, No.3, (April 2004), pp.372-7, ISSN:0301-620X
- Chauhan SK, Clark GW, Lioryd S, Scott RG, Breidahl W, Sikorski JM. (2004). Computer assisted total knee replacement. A controlled cadaver study using multi-parametric quantitative CT assessment of alignment (the Perth CT protocol). *J Bone Joint Surgery Br*, Vol.86, No.6, (August 2004), pp.818-23, ISSN:0301-620X
- Chi-Huan L, Tain-Hsiung C, Yu-Ping S, Po-Chou S, Kung-Sheng L, Wei-Ming C. (2008). Periprosthetic femoral supracondylar fracture after total knee arthroplasty with navigation system. *J Arthroplasty*, Vol.23, No.2, (February 2008), pp.304-7, ISSN:0883-5403

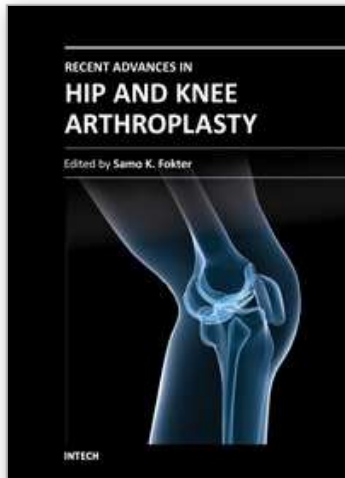
- Chin PL, Yang KY, Yeo SJ, Lo NN. (2005). Randomized control trial comparing radiographic total knee arthroplasty implant placement using computer navigation versus conventional technique. *J Arthroplasty*, Vol.20, No.5, (August 2005), pp.618-26, ISSN:0883-5403
- Choong PF, Dowsey MM, Stoney JD. (2009). Does accurate anatomical alignment result in better function and quality of life? Comparing conventional and computer-assisted total knee arthroplasty. *J Arthroplasty*, Vol.24, No.4, (June 2009), pp.560-569, ISSN:0883-5403
- Clemens U., Miehke R., Jens J. (2001). Computer integrated instrumentation in knee arthroplasty-the first 100 cases with the orthopilot knee navigation system. Poster 6. In: *International CAOS-Symposium*, Davos, 2001
- Dalury DF. (2001). Observations of the proximal tibia in total knee arthroplasty. *Clin Orthop Relat Res*, Vol.389, (August 2001), pp.150-5, ISSN 1528-1132
- Decking R, Markmann Y, Fuchs J, Puhl W, Scharf HP. (2005). Leg axis after computer-navigated total knee arthroplasty: a prospective randomized trial comparing computer-navigated and manual implantation. *J Arthroplasty*, Vol.20, No.3, (April 2005), pp.282-8, ISSN:0883-5403
- Delp SL, Stulberg SD, Davies B, Picard F, Leitner F. (1998). Computer assisted knee replacement. *Clin Orthop Relat Res*, Vol.354, (September 1998), pp.49-56, ISSN 1528-1132
- Desai, Asterios Dramis, Danile Kendoff, Tim N. Board. (2011). Critical review of the current practice for computer assisted navigation in total knee replacement surgery: cost-effectiveness and clinical outcome. *Curr Rev Musculoskelet Med*, Vol.4, No.1, (March 2011), pp.11-15, ISSN 1935-9748
- Eckhoff DG, Metzger RG, Vandewalle MV. (1995). Malrotation associated with implant alignment technique in total knee arthroplasty. *Clin Orthop Relat Res*, Vol.321, (December 1995), pp.28-31, ISSN 1528-1132
- Engh GA, Petersen TL. (1990). Comparative Experience With Intramedullary and Extramedullary Alignment in Total Knee Arthroplasty. *J Arthroplasty*, Vol.5, No.1, (March 1990), pp.1-8, ISSN:0883-5403
- Ensini A, Catani F, Leardini A, Romagnoli M, Giannini S. (2007). Alignments and clinical results in conventional and navigated total knee arthroplasty. *Clin Orthop Relat Res*, Vol.457, (April 2007), pp.156-62, ISSN 1528-1132
- Fehring TK, Mason JB, Moskal J, Pollock DC, Mann J, Williams VJ. (2006). When computer-assisted knee replacement is the best alternative. *Clin Orthop Relat Res*. Vol.452, (November 2006), pp.132-6, ISSN 1528-1132
- Haaker RG, Stockheim M, Hamp M, Proff G, Breitenfelder J, Ottersbach A. (2005). Computer assisted navigation increases precision of component placement in total knee arthroplasty. *Clin Orthop Relat Res*, Vol.433, (April 2005), pp.152-9, ISSN 1528-1132
- Haas S, C Nelson, R Laskin. (2000). Posterior stabilized knee arthroplasty: an assessment of the bone resection. *Knee*, Vol.7, No.1 (January 2000), pp.25-9, ISSN 1873-5800
- Hungerford DS, Kenna RV, Krackow KA. (1982). The porous coated anatomic total knee. *Orthop Clin North Am*, Vol.13, No.1, (January 1982), pp.103-122, ISSN 1558-1373
- Jeffery R, Morris R, Denham R. (1991). Coronal alignment after total knee replacement. *J Bone Joint Surg Br*, Vol.73, No.5, September 1991, pp.709-14, ISSN:0301-620X

- Jenny J, Boeri C. (2001). Image-free computer-assisted total knee prosthesis implantation: A radiological matched-paired comparison with surgeon-controlled instrumentation. Poster 431. In: *American Academy of Orthopaedic Surgeons*, San Francisco, 2001
- Jenny JY, Boeri C. (2001). Navigated implantation of total knee endoprosthesis: a comparative study with conventional instrument. *Z Orthop Ihre Grenzgeb*, Vol.139, No.2, (March-April 2001), pp.117-9, ISSN 0044-3220
- Jung HJ, Jung YB, Song KS, Park SJ, Lee JS. (2007). Fractures associated with computer-navigated total knee arthroplasty. A report of two cases. *J Bone Joint Surg Am*, Vol.89, No.10, (October 2007), pp.2280-4, ISSN 1535-1386
- Kalairajah Y, Simpson D, Cossey AJ, Verrall GM, Spriggins AJ. (2006). Are systemic emboli reduced in computer-assisted knee surgery? A prospective, randomized, clinical trial. *J Bone Joint Surg Br*, Vol.88, No.2, (February 2006), pp.198-202, ISSN:0301-620X
- Katz MA, Beck TD, Silber JS, Seldes RM, Lotke PA (2001). Determining femoral rotational alignment in total knee arthroplasty. Reliability of techniques. *J Arthroplasty*, Vol.16, No.3, (April 2001), pp.301-5, ISSN:0883-5403
- Kiefer H, Langemeyer D, Schmerwitz U, Krause F. (2001). Computer aided knee arthroplasty versus conventional technique. First results. Poster 132. In : *International CAOS-Symposium*, Davos, 2001
- Kim Y.-H, MD, Kim J.-S, MD and Yoon S.-H, MD. (2007). Alignment and orientation of the components in total knee replacement with and without navigation support. *J Bone Joint Surg Br*, Vol.89, No.4, (April 2007), pp.471-476, ISSN:0301-620X
- Lionberger DR. (2006). The attraction of electromagnetic computer-assisted navigation in orthopedic surgery. In: *Navigation and MIS in orthopedic surgery*, Stiehl J, Konermann W, Haaker R, Di Gioia A, (Eds.). pp.44-53, ISBN 978-3-540-36690-4, Springer, Heidelberg
- Lonner JH, Siliski JM, Lotke PA. (2000). Simultaneous femoral osteotomy and total knee arthroplasty for treatment of osteoarthritis associated with severe extra-articular deformity. *J Bone Joint Surg Am*, Vol.82, No.3, (March 2000), pp.342-8, ISSN 1535-1386
- Manzotti A, Confalonieri N, Pullen C. (2008). Intra-operative tibial fracture during computer assisted total knee replacement: A case report. *Knee Surg Sports Traumatol Arthrosc*, Vol.16, No.5, (May 2008), pp.493-6, ISSN 1433-7347
- Martin A, Wohlgenannt O, Prenn M, Prenn M, Oelsch C, von Strempel A. (2007). Imageless navigation for TKA increased implant accuracy. *Clin Orthop Relat Res*, Vol.460, (July 2007), pp.178-84, ISSN 1528-1132
- Mason, TK Fehring, R Estok, YD Banel and K Fahrbach. (2007). Meta-Analysis of Alignment Outcomes in Computer-Assisted Total Knee Arthroplasty Surgery. *J Arthroplasty*, Vol.22, No.8, (December 2007), pp.1097-106, ISSN:0883-5403
- Matziolis G, Krocher D, Weiss U, Tohtz S, Perka C. (2007). A prospective, randomized study of computer-assisted and conventional total knee arthroplasty. *J Bone Joint Surg Am*, Vol.89, No.2, (February 2007), pp.236-43, ISSN 1535-1386
- Mielke. U Clemens, JH Jens, S Kershally. (2001). Navigation in knee endoprosthesis implantation: preliminary experiences and prospective comparative study with conventional implantation technique. *Z Orthop Ihre Grenzgeb*, Vol.139, No.2, (March-April 2001), pp.109-16, ISSN 0044-3220

- Nizard R. (2002). Computer assisted surgery for total knee arthroplasty. *Acta Orthopaedica Belgica*, Vol.68, No.3, (June 2002), pp.215-30, ISSN 0001-6462
- Nizard R. First experience with a computer-assisted surgery system for total knee arthroplasty. In : *Proceedings of the 5th EFORT Meeting*, Rhodes, 2001
- Ossendorf C, Fuchs B, Koch P. (2006). Femoral stress fracture after computer navigated total knee arthroplasty. *Knee* Vol.13, No.5, (October 2006), pp.397-9, ISSN 1873-5800
- Picard F., Moody J., Jaramax B., DiGioia A., Nikou C., LaBarca R. (2001). A classification proposal for computer assisted knee systems. Poster 93. In: *International CAOS-Symposium*, Davos, 2001
- Picard, F Leitner, D Saragaglia, P Cinquin. (1997). Mise en place d'une prothèse totale du genou assistée par ordinateur: A propos de 7 implantations sur cadavre. *Rev Chir Orthop Reparatrice Appar Mot*. Vol.83, Suppl.II, (1997), pp.31, ISSN 1776-2553
- Rand JA, Coventry MB. (1988). Ten years evaluation of geometric total knee arthroplasty. *Clin Orthop Relat Res*, Vol.232, (July 1988), pp.168-73, ISSN 1528-1132
- Richard F., Owens Jr, MD, and Michael L. Swank. (2010). Low incidence of postoperative complications due to pin placement in computer-navigated total knee arthroplasty. *J Arthroplasty*, Vol.25, No.7, (October 2010), pp.1096-1098, ISSN:0883-5403
- Ritter M. A, Faris P.M, Keating E.M, Meding J.B. (1994). Postoperative alignment of total knee replacement. It's effect on survival. *Clin Orthop Relat Res*, Vol.299, (February 1994), pp.153-156, ISSN 1528-1132
- Robertsson O, Knutson K, Lewold S, et al. (2001). The Swedish knee arthroplasty register 1975-1997: an update with special emphasis on 41,223 Knees operated on in 1988-1997. *Acta Orthop Scand*, Vol.72, No.5, (October 2001), pp.503-13, ISSN 0001-6470
- Robinson M, Eckhoff DG, Reinig KD, Bagur MM, Bach JM. (2006). Variability of landmark identification in total knee arthroplasty. *Clin Orthop Relat Res*, Vol.442, (January 2006), pp.57-62, ISSN 1528-1132
- Saragaglia D, Picard F, Chaussard C, Montbarbon E, Leitner F, Cinquin P. (2001). Computer assisted knee arthroplasty: comparison with a conventional procedure. Results of 50 cases in a prospective randomized study. *Rev Chir Orthop Reparatrice Appar Mot*, Vol.87, No.1, (February 2001), pp.18-28, ISSN 1776-2553
- Siston RA, Patel JJ, Goodman SB, Delp SL, Giori NJ. (2005). The variability of femoral rotational alignment in total knee arthroplasty. *J Bone Joint Surg Am*, Vol.87, No.10, (October 2005), pp.2276-80, ISSN 1535-1386
- Siston RA, Giori NJ, Goodman SB, Delp SL. (2007). Surgical navigation for total knee arthroplasty: a perspective. *J Biomech*, Vol.40, No.4, (2007), pp.728-35, ISSN 1873-2380
- Solver JM, Anna N, Tosteson A, Bozic KJ, Rubash HE, Malchau H. (2008). Impact of the hospital volume on economic value of the computer navigation for total knee replacement. *J Bone Joint Surg Am*, Vol.90, No.7, (July 2008), pp.1492-500, ISSN 1535-1386
- Stöckl B, Nogler M, Rosiek R, Fischer M, Krismer M, Kessler O. (2004). Navigation improved accuracy of rotational alignment in total knee arthroplasty. *Clin Orthop Relat Res*, Vol.426, (September 2004), pp.180-6, ISSN 1528-1132
- Stulberg SD, Loan P, Sarin B, Sarin V. Computer-assisted navigation in total knee replacement: Results of an initial experience in thirty-five patients. *J Bone Joint Surg Am*, Vol.84, Suppl 2, (2002), pp.90-8, ISSN 1535-1386

- Stulberg SD, Yaffe MA, Koo SS. (2006). Computer-Assisted Surgery versus Manual Total Knee Arthroplasty: A Case-Controlled Study. *J Bone Joint Surg Am*, Vol.88, Suppl.4, (December 2006), pp.47-54, ISSN 1535-1386
- Tenbusch M., Lahmer A., Wiesel U., Borner M. First results using the Robodoc® system for total knee replacement. Poster 13. In : *International CAOS-Symposium*, Davos, 2001
- Tigani D, Sabbioni G, Ben Ayad R, Filanti M, Rani N, Del Piccolo N. (2010). Comparison between two computer-assisted total knee arthroplasty: gap-balancing versus measured resection technique. *Knee Surg Sports Traumatol Arthrosc*, Vol.18, No.10, (October 2010), pp.1304-1310, ISSN 1433-7347
- Wang JW, Wang CJ. (2002). Total knee arthroplasty for arthritis of the knee with extra-articular deformity. *J Bone Joint Surg Am*, Vol.84-A, No.10, (October 2002), pp.1769-74, ISSN 1535-1386
- Wolff AM, Hungerford DS, Pepe CL. (1991). The effect of extraarticular varus and valgus deformity on total knee arthroplasty. *Clin Orthop Relat Res*, Vol.271, (October 1991), pp.35-51, ISSN 1528-1132
- Wysocki WR, Sheinkop B, Virkus WW, Della Valle CJ. (2008). Femoral fracture through a previous pin site after computer-assisted total knee arthroplasty. *J Arthroplasty*, Vol.23, No.3, (April 2008), pp.462-5, ISSN:0883-5403
- Yau WP, Chiu KY. Cutting errors in total knee replacement: assessment by computer assisted surgery. (2008). *Knee Surg Sports Traumatol Arthrosc*, Vol.16, No.7, (July 2008), pp.670-3, ISSN 1433-7347
- Yau WP, Chiu KY, Zuo JL, Tang WM, and Ng TP. (2008). Computer Navigation Did Not Improve Alignment in a Lower-volume Total Knee Practice. *Clin Orthop Relat Res*, Vol.466, No.4, (April 2008), pp.935-945, ISSN 1528-1132
- Yoshioka Y., Siu D., Scudamore R., Cooke T. (1989). Tibial anatomy and functional axes. *J Orthop Res*, Vol.7, No.1, (1989), pp.132-137, ISSN 1554-527X

IntechOpen



Recent Advances in Hip and Knee Arthroplasty

Edited by Dr. Samo Fokter

ISBN 978-953-307-841-0

Hard cover, 452 pages

Publisher InTech

Published online 27, January, 2012

Published in print edition January, 2012

The purpose of this book is to offer an exhaustive overview of the recent insights into the state-of-the-art in most performed arthroplasties of large joints of lower extremities. The treatment options in degenerative joint disease have evolved very quickly. Many surgical procedures are quite different today than they were only five years ago. In an effort to be comprehensive, this book addresses hip arthroplasty with special emphasis on evolving minimally invasive surgical techniques. Some challenging topics in hip arthroplasty are covered in an additional section. Particular attention is given to different designs of knee endoprostheses and soft tissue balance. Special situations in knee arthroplasty are covered in a special section. Recent advances in computer technology created the possibility for the routine use of navigation in knee arthroplasty and this remarkable success is covered in depth as well. Each chapter includes current philosophies, techniques, and an extensive review of the literature.

How to reference

In order to correctly reference this scholarly work, feel free to copy and paste the following:

M. Fosco, R. Ben Ayad, R. Fantasia, D. Dallari and D. Tigani (2012). Concepts in Computer Assisted Total Knee Replacement Surgery, Recent Advances in Hip and Knee Arthroplasty, Dr. Samo Fokter (Ed.), ISBN: 978-953-307-841-0, InTech, Available from: <http://www.intechopen.com/books/recent-advances-in-hip-and-knee-arthroplasty/concepts-in-computer-assisted-total-knee-replacement-surgery>

INTech
open science | open minds

InTech Europe

University Campus STeP Ri
Slavka Krautzeka 83/A
51000 Rijeka, Croatia
Phone: +385 (51) 770 447
Fax: +385 (51) 686 166
www.intechopen.com

InTech China

Unit 405, Office Block, Hotel Equatorial Shanghai
No.65, Yan An Road (West), Shanghai, 200040, China
中国上海市延安西路65号上海国际贵都大饭店办公楼405单元
Phone: +86-21-62489820
Fax: +86-21-62489821

© 2012 The Author(s). Licensee IntechOpen. This is an open access article distributed under the terms of the [Creative Commons Attribution 3.0 License](https://creativecommons.org/licenses/by/3.0/), which permits unrestricted use, distribution, and reproduction in any medium, provided the original work is properly cited.

IntechOpen

IntechOpen