

We are IntechOpen, the world's leading publisher of Open Access books Built by scientists, for scientists

6,900

Open access books available

185,000

International authors and editors

200M

Downloads

Our authors are among the

154

Countries delivered to

TOP 1%

most cited scientists

12.2%

Contributors from top 500 universities



WEB OF SCIENCE™

Selection of our books indexed in the Book Citation Index
in Web of Science™ Core Collection (BKCI)

Interested in publishing with us?
Contact book.department@intechopen.com

Numbers displayed above are based on latest data collected.
For more information visit www.intechopen.com



Retrograde Stem Removal Techniques in Revision Hip Surgery

Kálmán Tóth

*Department of Orthopaedics, University of Szeged
Hungary*

1. Introduction

Total hip replacement has about a 50 year old past. In recent decades the number of revision hip arthroplasties in developed countries reached 15-20% of primary replacements. The average survival for both cemented and uncemented implants is about 94-95% at ten years. At the end of that period they have to be replaced.

Removal of a well cemented femoral stem in revision total hip arthroplasty is a technically demanding procedure, which requires knowledge and proficiency in the usage of a multitude of surgical techniques and instruments. Experiences with traditional cement removing techniques have been published in numerous publications (Dennis et al., 1987; Ferguson, 1988; Laffargue et al., 2000; Lauer et al., 2002; Stühmer, 1987).

Femoral component failure and fracture is a rarely seen complication, which presents as a difficult problem for the surgical team. Because of stress shielding in the proximal femur, osteolysis is often concentrated to the proximal part of the femur, whilst the distal portion of the stem might be stable and well fixed. This eventually leads to failure of the metal and component fracture. Although removing the proximal loose fragment is relatively straightforward, removing the distal tip is difficult, and often only feasible with techniques that result in weakening of the biomechanical properties of the femur, such as distal fenestration i.e. creating a small or larger window (in the lateral cortex or an extended trochanteric osteotomy (Wagner, 1989).

The Authors use a retrograde technique in the clinical setting, in which removal of cement and stem is performed with the use of a retrograde nail passed through the knee. With this technique, removal of loose stems or broken components is both possible – when the case is appropriate for the technique. Thus further compromise can be avoided to the poor bone stock.

2. Surgical technique

The patients were positioned supine on a radio-lucent table. Using a lateral approach, the scar tissue was excised and the hip joint was exposed. After dislocating the prosthesis, the proximal broken piece of the femoral component was easily removed. The end of the distal part became visible at approximately 4 to 6 cm below the lesser trochanter (Fig. 1.).

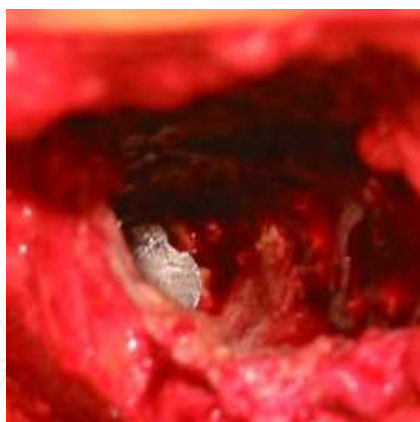


Fig. 1. The proximal end of the distal broken piece of the femoral component - there is no sufficient gap between the broken component and the femur, therefore grasping and pulling it out with a device is not feasible (intraoperative photo).

A 2-3 cm skin incision was required through the centre of the patellar ligament as described by Moed et al. (Moed & Watson, 1995) which is generally performed for osteosynthesis. The optimal entry point for retrograde femoral nailing and defined this spot 12 mm anterior to the femoral origin of the posterior cruciate ligament in sagittal plane and at the centre of the intercondylar sulcus in coronal plane. The intramedullary canal was then opened by the awl.

Under the control of a fluoroscope the 10, 12, 14 mm intramedullary nail is entered into the intramedullary canal. Reaming is not necessary, the tamp that fits best the intramedullary canal is chosen from the series. After entering the rod, it is rotated until the best alignment is obtained to the stem or the cement plug and a stable connection is achieved (Fig. 2.). To avoid deflection or perforation it is particularly important to make sure that the nail is not

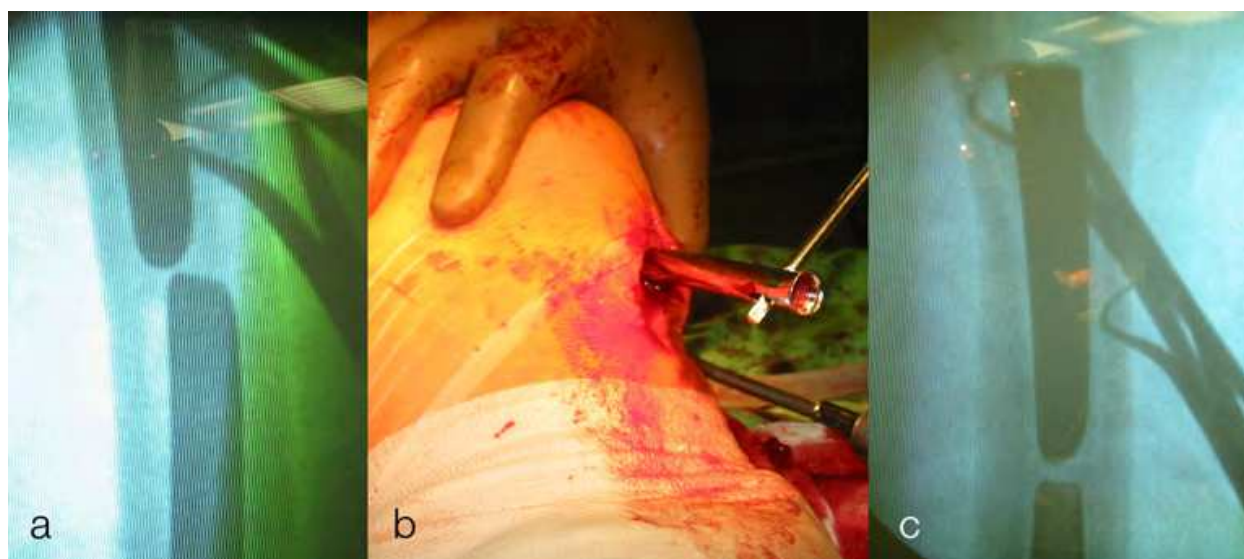


Fig. 2. a: After introducing, the alignment between the nail and the stem is poor, therefore the nail may slip from the tip of the stem causing perforation or fracture (photo taken from the image intensifier). b: Setting the rotation (intraoperative photo). c: After the nail is placed to the tip of the stem the femoral component is removed by gentle hammering (photo taken from the image intensifier).

slipped down from the stem or the distal cement plug. When the required contact between the nail and the distal part of the stem or the cement plug is visualised by the image intensifier, the femoral implant is pushed out in proximal direction by careful hammering.

Following this, the femur was reamed with a cannulated femoral reamer from the proximal end until all the granulation tissue and cement debris was removed. The intramedullary nail was pulled back during reaming without removing it from the distal femur, in order to protect the knee joint from cement particles. After thorough cleaning of the medullary canal the new femoral component was implanted. Using this method, the cortical bone is not weakened and in most cases a normal femoral stem gives sufficient stability for the revision (Fig. 3.).

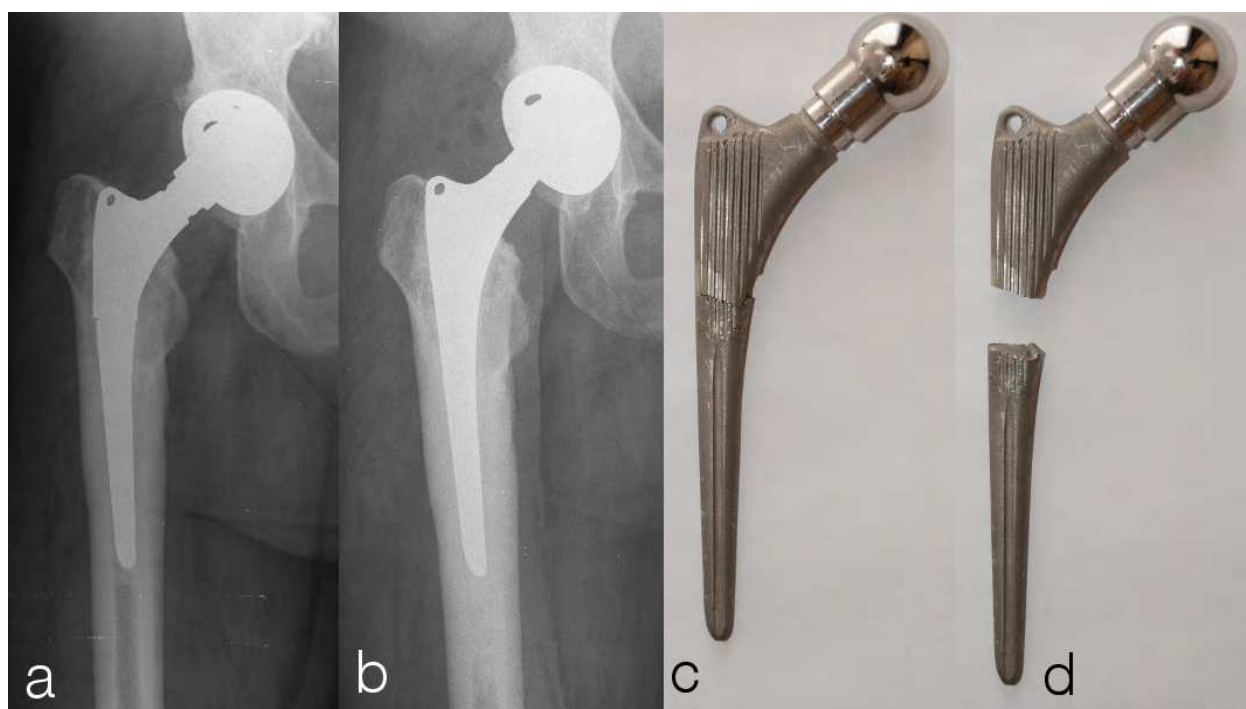


Fig. 3. a: Femoral component failure 14 years following primary surgery. b: Revision with normal femoral component following retrograde removal of broken stem. c and d: Removed, broken component.

The perioperative protocol (thromboprophylaxis, one-shot antibiotic prophylaxis, and applying antibiotic bone cement in case of cemented refixation) does not differ from the routine procedure. Occasional knee swelling occurring in the immediate postoperative period can be treated with local ice packs and applying non-steroidal anti-inflammatory drugs. Physiotherapy and mobilisation does not alter from the routine postoperative protocol.

3. Discussion

When performing revision THR, removal of the distal, often inaccessible cement or a distal fragment of a broken femoral stem is a significant concern (Engh et al., 1999). Whilst intraoperative femoral fracture remains a rare but serious complication during primary

THR, it is a significant problem during revisions (1% of 23,980 primary total hip arthroplasties compared with 7.8% of 6349 revisions in a study by Berry (Berry, 1999)). Subsequent studies have demonstrated similar results (Davis et al., 2003; Egan & Cesare, 1995; Mitchell et al., 2003; Sarvilinna et al., 2004; Taylor et al., 1978).

Farfalli (Farfalli et al., 2007) reported a series of fifty-nine intraoperative fractures that had occurred during revision total hip arthroplasty using impaction bone-grafting. The majority of the fractures (44%) occurred during cement removal.

Various new techniques have been introduced to lower the incidence of perioperative femoral fractures during cement removal, such as ultrasound (Caillouette et al., 1991; Honnart, 1996; Klapper et al., 1992; Schwaller & Elke, 2001), extra-corporal lithotripsy (Braun et al., 1992; Schmidt et al., 1998; Schreurs et al., 1991; Stranne et al., 1992; Weinstein et al., 1988), segmental cement extraction (Chin et al., 1991; Ekelund, 1992; Jingushi et al., 2000; Schurman & Maloney, 1992), application of high-energy shock waves (May et al., 1990), using a ballistically driven chiselling system (Porsch & Schmidt, 2001), or an acoustic emission-controlled milling device (Schmidt & Nordmann, 1994) or even lasers (Sherk et al., 1995). Most of these techniques had not reached widespread usage, and some authors have reported complications (Gardiner et al., 1993).

There have been three clinical studies and one experimental work published about retrograde stem removal (Piatek et al., 2007; Szendroi et al., 2010; Toth et al., 2010; Tóth et al., 2011). Tóth (Toth et al., 2010) and Szendrői (Szendroi et al., 2010) reports successful, uncomplicated application of retrograde removal technique with intact stems and distal fractured components in treatment of elective hip arthroplasty revisions, while Piatek (Piatek et al., 2007) used the technique successfully in case of periprotetic fractures.

The cadaver study compares the biomechanical effects of three different cement removing techniques, the distal fenestration (DF), the transfemoral approach (TFA) and the retrograde stem removal technique (RSR) using an experimental setup (Tóth et al., 2011). 23 paired femora were recovered from similarly aged human cadavers and were frozen. These were later subdivided into 3 groups to provide specimens of similar age and bone quality in each group (DF, TFA, RSR).

The results of the intragroup (comparison between treated and control specimens from the same cadavers from the same groups) analysis were the following: In the TFA group, the force required till fracture was significantly less than in controls ($p=0.0096$). Similar results were found in the DF group ($p=0.068$). There was no difference in the RSR group ($p=0.988$).

Intergroup analysis showed the following:

Femurs in the DF group required significantly less force to fracture than specimens in the RSR ($p=0.043$), whilst there was no difference in there respective controls ($p=0.831$).

Femurs in the TFA group required highly significantly less force to fracture than specimens in the RSR group ($p=0.0001$), whilst there was no difference in there respective controls ($p=0.178$).

That is, the cadaveric study supports the clinical experience that windowing the proximal femur, significantly decreases resistance against compression and rotational forces.

The various windowing techniques described in the literature (Arif et al., 2004; Buehler & Walker, 1998; Cameron, 1990; Hackenbroch, 1979; Kerry et al., 1999; Klein & Rubash, 1993; Moreland et al., 1986; Nelson & Barnes, 1990; Nelson & Weber, 1980; Savvidis & Löer, 1989;

Shepherd & Turnbull, 1989; Stranne et al., 1992; Tyler et al., 1987; Weber, 1981; Witt & Hackenbroch, 1976), and their modifications (Arif et al., 2004; Nelson & Barnes, 1990; Zweymüller et al., 2005) and the new instruments developed for these techniques (Brinckmann & Horst, 1985), all serve one purpose, to decrease the often inevitable weakening of the proximal femoral bone stock, preserving as much intact bone as possible. Although the more conservative windowing techniques tend to preserve more proximal bone, they still inevitably lead to decreased resistance against fracture.

The studies performed by Dennis et al. (Dennis et al., 1987) on cadaveric femora, showed that when femurs without intramedullary support are stressed to failure, fractures occur through the cortical holes 90% of the time, therefore they suggested that long revision femoral stems should be used to bypass the window by at least 2 to 2.5 times the cortical diameter measured at the fenestration level (Fig. 4/b). This has been generally accepted and is widely used in orthopaedic practice (Kerry et al., 1999; Klein & Rubash, 1993; Lotke et al., 1986; Moreland et al., 1986; Nelson & Barnes, 1990; Nelson & Weber, 1980; Savvidis & Löer, 1989; Shepherd & Turnbull, 1989; Tyler et al., 1987).

The disadvantage of using a long stem with proximal opening of the femur instead of the RSR technique and a short stem (Fig. 3a, 3b.), is that long revision stems are more expensive, the necessary exposure requires a longer incision (Fig. 4c), with more soft tissue stripping, surgery is often much longer, blood loss can be extensive, and the local and general complication rate is higher.

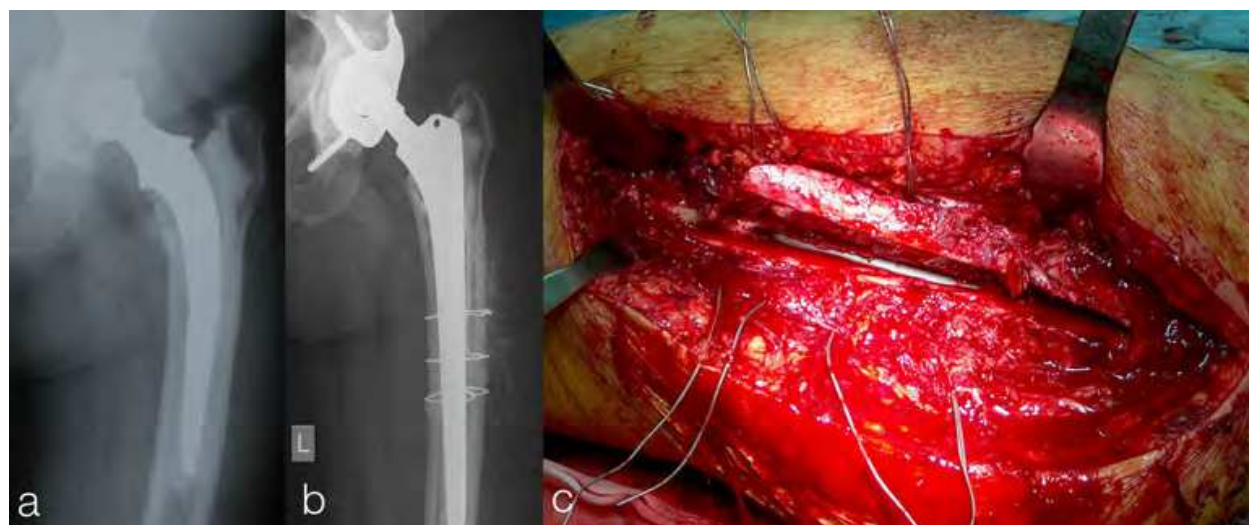


Fig. 4. a: Femoral component failure and acetabular component loosening 17 years following primary surgery. b: Distal fragment of cement and stem are removed through bone window, followed by wire refixation of the window. The long revision femoral stem distally overreaches the window by the length of 2.5 times. c: Major surgical wound with extended osteotomy (intraoperative photo).

The RSR technique cannot always be used, and is absolutely contraindicated in the case of septic loosening or if the knee or the distal femur is affected by primary or metastatic tumours. Large distal cement plugs or the presence of oblique cement at the end of the stem are relative contraindications, because these can force the nail used for removal towards the cortical bone, which can lead to unwanted perforation or even periprosthetic fracture.

In the clinical setting depending on the quality of the proximal femoral bone, both a short a long femoral stem can be used for the revision surgery after RSR. As the cortex is not violated during component removal, a short primary stem (cemented or uncemented) is a valid option and is our preference, if the cortices are not very thin, and at least some peripheral cancellous bone is present, for cement penetration. We like to reserve long stems as a final resort, to allow a possible future revision.

4. Conclusion

Our cadaver experiments clearly confirm the clinical experience, that the window technique significantly weakens resistance of femur against rotation under compression forces. In contrast, with the retrograde cement removal technique this weakening does not occur.

Our experience with retrograde cement removal in elective revisions and periprosthetic fractures shows that - taking into consideration indications and contraindications- retrograde prosthesis removal technique is a viable alternative solution in case of intact as well as failed femoral components. It is associated with less intraoperative complications and faster, safer recovery compared to traditional techniques.

However, longer follow-up time is required to confirm the durability of the observed clinical outcomes.

5. References

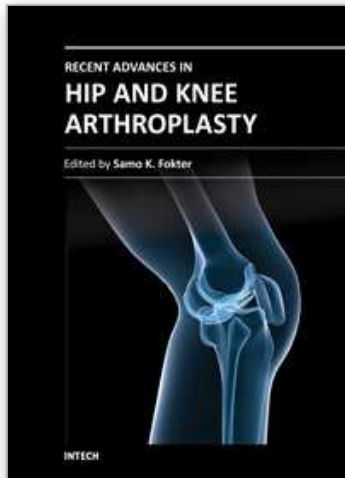
- Arif, M., Sivananthan, S., & Choon, DS. (2004). Revision of total hip arthroplasty using an anterior cortical window, extensive strut allografts, and an impaction graft: follow-up study. *J Orthop Surg (Hong Kong)*, Vol. 12, No. 1, (June, 2004), pp. 25-30, ISSN 1022-5536
- Berry, DJ. (1999). Epidemiology: hip and knee. *Orthop Clin North Am*, Vol. 30, No. 2, (April, 1999), pp. 183-190, ISSN 0030-5898
- Braun, W., Claes, L., Ruter, A., & Paschke, D. (1992). Effect of shock waves on the strength of connection between bone and polymethylmethacrylate. An in vitro study of human femur segments. *Z Orthop Ihre Grenzgeb*, Vol. 130, No. 3, (May-June, 1992), pp. 236-243, ISSN 0044-3220
- Brinckmann, P., & Horst, M. (1985). New instruments for the removal of an artificial hip joint from the shaft. *Z Orthop Ihre Grenzgeb*, Vol. 123, No. 1, (January-February, 1985), pp. 113-114, ISSN 0044-3220
- Buehler, KO., & Walker, RH. (1998). Polymethylmethacrylate removal from the femur using a crescentic window technique. *Orthopedics*, Vol. 21, No. 6, (June, 1998), pp. 697-700, ISSN 0147-7447
- Caillouette, JT., Gorab, RS., Klapper, RC., & Anzel, SH. (1991). Revision arthroplasty facilitated by ultrasonic tool cement removal. Part II: histologic analysis of endosteal bone after cement removal. *Orthop Rev*, Vol. 20, No. 5, (May, 1991), pp. 435-440, ISSN 0094-6591
- Cameron, HU. (1990). Tips of the trade #29. Femoral windows for easy cement removal in hip revision surgery. *Orthop Rev*, Vol. 19, No. 10, (October, 1990), pp. 909-910, 912 ISSN 0094-6591

- Chin, AK., Moll, FH., McColl, MB., Hoffman, KJ., & Wuh, HC. (1991). An improved technique for cement extraction in revision total hip arthroplasty. *Contemp Orthop*, Vol. 22, No. 3, (March, 1991), pp. 255-264, ISSN 0194-8458
- Davis, CM., 3rd, Berry, DJ., & Harmsen, WS. (2003). Cemented revision of failed uncemented femoral components of total hip arthroplasty. *J Bone Joint Surg Am*, Vol. 85-A, No. 7, (July, 2003), pp.1264-1269, ISSN 0021-9355
- Dennis, DA., Dingman, CA., Meglan, DA., O'Leary, JF., Mallory, TH., & Berme, N. (1987). Femoral cement removal in revision total hip arthroplasty. A biomechanical analysis. *Clin Orthop Relat Res*, Vol. 220, No. 7, (July, 1987), pp. 142-147, ISSN 0009-921X
- Egan, KJ., & Di Cesare, PE. (1995). Intraoperative complications of revision hip arthroplasty using a fully porous-coated straight cobalt-chrome femoral stem. *J Arthroplasty*, Vol. 10, Suppl. (November, 1995), pp. 45-51, ISSN 0883-5403
- Ekelund, AL. (1992). Cement removal in revision hip arthroplasty. Experience with bone cement added to the cavity in 20 cases. *Acta Orthop Scand*, Vol. 63, No. 5, (October, 1992), pp. 549-551, ISSN 0001-6470
- Engh, CA., McAuley, JP., & Engh, C. (1999). Surgical approaches for revision total hip replacement surgery: the anterior trochanteric slide and the extended conventional osteotomy. *Instr Course Lect*, Vol. 48, (1999), pp. 3-8, ISSN 0065-6895
- Farfalli, GL., Buttaro, MA., & Piccaluga, F. (2007). Femoral fractures in revision hip surgeries with impacted bone allograft. *Clin Orthop Relat Res*, Vol. 462, No. 9, (September, 2007), pp. 130-136, ISSN 0009-921X
- Ferguson, GM. (1988). Femoral cement removal in revision total hip arthroplasty: a biomechanical analysis. *Clin Orthop Relat Res*, Vol. 234, No. 8, (September, 1998), pp. 307-308, ISSN 0009-921X
- Gardiner, R., Hozack, WJ., Nelson, C., & Keating, EM. (1993). Revision total hip arthroplasty using ultrasonically driven tools. A clinical evaluation *J Arthroplasty*, Vol. 8, No. 5, (October, 1993), pp. 517-521, ISSN 0883-5403
- Hackenbroch, Jr. MH. (1979). Possibilities and limitations of exchange of hip and knee joint prostheses. *Z Orthop Ihre Grenzgeb*, Vol. 117, No. 4, (August, 1979), pp. 457-460, ISSN 0044-3220
- Honnart, F. (1996). Use of ultrasound for the removal of cement in hip prosthesis reoperations. *Rev Chir Orthop Reparatrice Appar Mot*, Vol. 82, No. 2, (1996), pp. 171-174, ISSN 0035-1040
- Jingushi, S., Noguchi, Y., Shuto, T., Nakashima, T., & Iwamoto Y. (2000). A device for removal of femoral distal cement plug during hip revision arthroplasty: a high-powered drill equipped with a centralizer. *J Arthroplasty*, Vol. 15, No. 2, (February, 2000), pp. 231-233, ISSN 0883-5403
- Kerry, RM., Masri, BA., Garbuz, DS., & Duncan, CP. (1999). The vascularized scaphoid window for access to the femoral canal in revision total hip arthroplasty. *Instr Course Lect*, Vol. 48, (1999), pp. 9-11, ISSN 0065-6895
- Klapper, RC., Caillouette, JT., Callaghan, JJ., & Hozack, WJ. (1992). Ultrasonic technology in revision joint arthroplasty. *Clin Orthop*, Vol. 285, No. 12, (December, 1992), pp. 147-154, ISSN 0009-921X
- Klein, AH., & Rubash, HE. (1993). Femoral windows in revision total hip arthroplasty. *Clin Orthop Relat Res*, Vol. 291, No. 6, (June, 1993), pp. 164-170, ISSN 0009-921X

- Laffargue, P., De Lestang, M., Bonnomet, F., Dupart, L., & Havet, E. (2000). Techniques of component and cement removal: osseous pitfalls and approaches. *Rev Chir Orthop Reparatrice Appar Mot*, Vol. 86, No. 9, Suppl. (September, 2000), pp. 51-54, ISSN 0035-1040
- Lauer, W., Neuss, M., Wirtz, DC., & Radermacher, K. (2002). Technical principles for removal of femoral bone cements in hip prosthesis implant revision. *Biomed Tech (Berl)*, Vol. 47, Suppl 1 Pt, (2002), pp. 47-48, ISSN 0013-5585
- Lotke, PA., Wong, RY., & Ecker, ML. (1986). Stress fracture as a cause of chronic pain following revision total hip arthroplasty. Report of two cases. *Clin Orthop Relat Res*, Vol. 206, (May, 1986) pp. 147-150, ISSN 0009-921X
- May, TC., Krause, WR., Preslar, AJ., Smith, MJ., Beaudoin, AJ., & Cardea, JA. (1990). Use of high-energy shock waves for bone cement removal. *J Arthroplasty*, Vol. 5, No. 1, (March, 1990), pp. 19-27, ISSN 0883-5403
- Mitchell, PA., Greidanus, NV., Masri, BA., Garbuz, DS., & Duncan, CP. (2003). The prevention of periprosthetic fractures of the femur during and after total hip arthroplasty. *Instr Course Lect*, Vol. 52, (2003), pp. 301-308, ISSN 0065-6895
- Moed, BR., & Watson JT. (1995). Retrograde intramedullary nailing, without reaming, of fractures of the femoral shaft in multiply injured patient. *J. Bone Joint Surg. Am*, Vol. 75, No.10, (October, 1995), pp. 1520-1527, ISSN 0021-9355
- Moreland, JR., Marder, R., & Anspach, WE Jr. (1986). The window technique for the removal of broken femoral stems in total hip replacement. *Clin Orthop Relat Res*, Vol.212, (November, 1986), pp. 245-249, ISSN 0009-921X
- Nelson, CL., & Weber, MJ. (1981). Technique of windowing the femoral shaft for removal of bone cement. *Clin Orthop Relat Res*, Vol. 154, (January-February, 1981), pp. 336-337, ISSN 0009-921X
- Nelson, CL., & Barnes, CL. (1990). Removal of bone cement from the femoral shaft using a femoral windowing device. *J Arthroplasty*, Vol. 5, No. 1, (March, 1990), pp. 67-69, ISSN 0883-5403
- Piatek, S., Westphal, T., Holmenschlager, F., Becker, R., & Winckler, S. (2007). Retrograde cement removal in periprosthetic fractures following hip arthroplasty. *Arch Orthop Trauma Surg*, Vol. 127, No. 7, (September, 2007), pp. 581-585, ISSN 0936-8051
- Porsch, M., & Schmidt, J. (2001). Cement removal with an endoscopically controlled ballistically driven chiselling system. A new device for cement removal and preliminary clinical results. *Arch Orthop Trauma Surg*, Vol. 121, No. 5, (May, 2001), pp. 274-277, ISSN:0936-8051
- Sarvilinna, R., Huhtala, HS., Sovelius, RT., Halonen, PJ., Nevalainen, JK., & Pajamäki, KJ. (2004). Factors predisposing to periprosthetic fracture after hip arthroplasty: a case (n = 31)-control study. *Acta Orthop Scand*, Vol. 75 No. 1, (February, 2004), pp. 16-20, ISSN 0001-6470
- Savvidis, E., & Löer, F. (1989). Surgical technique for femur shaft fenestration in revisional surgery following total hip replacements – a comparative experimental study. *Z Orthop Ihre Grenzgeb*, Vol. 127, No. 2, (1989), pp. 228-236, ISSN 0044-3220
- Schreurs, BW., Bierkens, AF., Huiskes, R., Hendriks, AJ., & Slooff, TJ. (1991). The effect of the extracorporeal shock wave lithotripter on bone cement. *J Biomed Mater Res*, Vol. 25, No. 2, (February, 1991), pp. 157-164, ISSN 0021-9304

- Schmidt, J., & Nordmann, K. (1994). Removal of bone cement from the femoral canal using an acoustic emission-controlled milling device. *Med Biol Eng Comput*, Vol. 32, No. 3, (May, 1994), pp. 258-260, ISSN 0140-0118
- Schmidt, J., Porsch, M., Hackenbroch, MH., Koebke, J., & Brimmers, P. (1998). ModiWed intracorporeal lithotripsy for cement removal in hip prosthesis exchange operations—experimental principles. *Z Orthop Ihre Grenzgeb*, Vol. 136, No. 1, (January-February, 1998), pp. 44-49, ISSN 0044-3220
- Schurman, DJ., & Maloney, WJ. (1992). Segmental cement extraction at revision total hip arthroplasty. *Clin Orthop*, Vol. 285, (December, 1992), pp. 158-163, ISSN:0009-921X
- Schwaller, CA., & Elke, R. (2001). Cement removal with ultrasound in revision or total hip prosthesis. *Orthopade*, Vol. 30, No. 5, (May, 2001), pp. 310-316, ISSN:0085-4530
- Shepherd, BD., & Turnbull, A. (1989). The fate of femoral windows in revision joint arthroplasty. *J Bone Joint Surg Am*, Vol. 71, No. 5, (June, 1989), pp. 716-718, ISSN 0021-9355
- Sherk, HH., Lane, G., Rhodes, A., & Black, J. (1995). Carbon dioxide laser removal of polymethylmethacrylate. *Clin Orthop*, Vol. 310, (January, 1995), pp. 67-71, ISSN 0009-921X
- Stranne, SK., Callaghan, JJ., Fyda, TM., Fulghum, CS., Glisson, RR., Weinerth, JL., & Seaber, AV. (1992). The effect of extracorporeal shock wave lithotripsy on the prosthesis interface in cementless arthroplasty. Evaluation in a rabbit model. *J Arthroplasty*, Vol. 7, No. 2, (June, 1992), pp. 173-179, ISSN 0883-5403
- Stühmer, K. (1987). Zur Technik der Zemententfernung bei Austauschoperationen von Gelenkendoprothesen. *Aktuel Probl Chir Orthop*, Vol. 31, (1987), pp. 342-346, ISSN 0378-8504
- Szendrói, M., Tóth, K., Kiss, J., Antal, I., & Skaliczki G. (2010). Retrograde genocephalic removal of fractured or immovable femoral stems in revision hip surgery. *Hip Int*. Vol. 20, No. 1, (January-March, 2010), pp. 34-37, ISSN 1120-7000
- Taylor, MM., Meyers, MH., & Harvey, JP Jr. (1978). Intraoperative femur fractures during total hip replacement. *Clin Orthop Relat Res*, Vol. 137, (November-December, 1978), pp. 96-103, ISSN 0009-921X
- Toth, K., Sisak, K., Nagy, J., Mano, S., & Csernatony, Z. (2010). Retrograde stem removal in revision hip surgery: removing a loose or broken femoral component with a retrograde nail. *Archives of Orthopaedic and Trauma Surgery*, Vol. 130, No. 7, (July, 2010), pp. 813-818, ISSN 0936-8051
- Tóth, K., Sisák, K., Wellinger, K., Manó, S., Horváth, G., Szendrői, M., & Csernátony, Z. (2011). Biomechanical comparison of three cemented stem removal techniques in revision hip surgery. *Arch Orthop Trauma Surg*. Vol. 131, No. 7, (July, 2011), pp. 1007-1012, ISSN 0936-8051
- Tyer, HD., Huckstep, RL., & Stalley, PD. (1987). Intraluminal allograft restoration of the upper femur in failed total hip arthroplasty. *Clin Orthop Relat Res*, Vol. 224, (November, 1987), pp. 26-32, ISSN 0009-921X
- Wagner, H. (1989). A revision prosthesis for the hip joint. *Orthopade*, Vol. 18, No. 5, (September, 1989), pp. 438-453, ISSN 0085-4530
- Weber, BG. (1981). Total hip replacement revision surgery: Surgical technique and experience. In: *Hip*, E.A. Salvati, (Ed.), 3-14, Proceedings of the 9th Open Scientific Meeting of the Hip Society, ISBN 0095-7216, St. Louis, Mosby, USA

- Weinstein, JN., Oster, DM., Park, JB., Park, SH., & Loening, S. (1988). The effect of the extracorporeal shock wave lithotripter on the bone-cement interface in dogs. *Clin Orthop*, Vol. 235, (October, 1988), pp. 261-267, ISSN 0009-921X
- Witt, AN., & Hackenbroch, MH. (1976). Therapeutic approaches to implant loosening in total hip arthroplasty. *Z Orthop Ihre Grenzgeb*, Vol. 114, No. 3, (June, 1976), pp. 330-341, ISSN 0044-3220
- Zweymüller, KA., Steindl, M., & Melmer, T. (2005). Anterior windowing of the femur diaphysis for cement removal in revision surgery. *Clin Orthop Relat Res*, Vol. 441, (December, 2005), pp. 227-336, ISSN 0009-921X



Recent Advances in Hip and Knee Arthroplasty

Edited by Dr. Samo Fokter

ISBN 978-953-307-841-0

Hard cover, 452 pages

Publisher InTech

Published online 27, January, 2012

Published in print edition January, 2012

The purpose of this book is to offer an exhaustive overview of the recent insights into the state-of-the-art in most performed arthroplasties of large joints of lower extremities. The treatment options in degenerative joint disease have evolved very quickly. Many surgical procedures are quite different today than they were only five years ago. In an effort to be comprehensive, this book addresses hip arthroplasty with special emphasis on evolving minimally invasive surgical techniques. Some challenging topics in hip arthroplasty are covered in an additional section. Particular attention is given to different designs of knee endoprostheses and soft tissue balance. Special situations in knee arthroplasty are covered in a special section. Recent advances in computer technology created the possibility for the routine use of navigation in knee arthroplasty and this remarkable success is covered in depth as well. Each chapter includes current philosophies, techniques, and an extensive review of the literature.

How to reference

In order to correctly reference this scholarly work, feel free to copy and paste the following:

Kálmán Tóth (2012). Retrograde Stem Removal Techniques in Revision Hip Surgery, Recent Advances in Hip and Knee Arthroplasty, Dr. Samo Fokter (Ed.), ISBN: 978-953-307-841-0, InTech, Available from: <http://www.intechopen.com/books/recent-advances-in-hip-and-knee-arthroplasty/retrograde-stem-removal-techniques-in-revision-hip-surgery>

INTech
open science | open minds

InTech Europe

University Campus STeP Ri
Slavka Krautzeka 83/A
51000 Rijeka, Croatia
Phone: +385 (51) 770 447
Fax: +385 (51) 686 166
www.intechopen.com

InTech China

Unit 405, Office Block, Hotel Equatorial Shanghai
No.65, Yan An Road (West), Shanghai, 200040, China
中国上海市延安西路65号上海国际贵都大饭店办公楼405单元
Phone: +86-21-62489820
Fax: +86-21-62489821

© 2012 The Author(s). Licensee IntechOpen. This is an open access article distributed under the terms of the [Creative Commons Attribution 3.0 License](https://creativecommons.org/licenses/by/3.0/), which permits unrestricted use, distribution, and reproduction in any medium, provided the original work is properly cited.

IntechOpen

IntechOpen