

We are IntechOpen, the world's leading publisher of Open Access books Built by scientists, for scientists

6,900

Open access books available

185,000

International authors and editors

200M

Downloads

Our authors are among the

154

Countries delivered to

TOP 1%

most cited scientists

12.2%

Contributors from top 500 universities



WEB OF SCIENCE™

Selection of our books indexed in the Book Citation Index
in Web of Science™ Core Collection (BKCI)

Interested in publishing with us?
Contact book.department@intechopen.com

Numbers displayed above are based on latest data collected.
For more information visit www.intechopen.com



Planning of Arthroplasty in Dysplastic Hips

Nevzat Selim Gokay¹, Alper Gokce¹, Bulent Alp² and Fahri Erdogan²

¹Namik Kemal University School of Medicine,
Department of Orthopaedics and Traumatology, Tekirdag

²Istanbul University, Cerrahpasa School of Medicine,
Department of Orthopaedics and Traumatology, Istanbul
Turkey

1. Introduction

Hip dysplasia is one of the major conditions leading degenerative hip arthritis in early adulthood. Developmental insufficiency of bony structures yields asymmetric ball and socket formation, which usually associated with trophic changes and instability. Total hip joint replacement has successful results in patients with hip dysplasia in adulthood. The major goal of the treatment is rebuilding of a new stable artificial joint with painless range of motion. There is a need of a meticulous preoperative planning assessing the anatomic severity of the pathology, which is consisted of involved bony and soft tissue components. Limb length discrepancy, quality of bone stock, muscle atrophies, weakness and contractures should be evaluated before surgery. There are several classifications for assessment of acetabular dysplasia. However, we are aware of a combined classification or comprehensive algorithm for assessment of all components of pathology in unison.

Current developments in the field of radiology like Three Dimensional (3d) Computerized Tomography (CT) and Magnetic Resonance Imaging (MRI) allowed assessment of all component of hip dysplasia preoperatively. Metaphyseal and acetabular bone stock and structure, anteversion degrees and soft tissues has to be taken in consideration. The aim of this chapter is to review the present classifications and reported experiences on hip dysplasia and discuss the value of missing parts. The preoperative planning process were also reviewed regarding the role of modern radiologic examination techniques on current surgical and clinical applications.

2. Planning of arthroplasty in dysplastic hips

Patient selection is very important in the treatment of developmental dysplasia of the hip (DDH). In proper and young patients femoral or periacetabular osteotomy should be considered. Nevertheless total hip arthroplasty is often required for most of the patients with dysplasia. The major goal of the treatment is rebuilding of a new stable artificial joint with painless range of motion. To this end, there is a need of a meticulous preoperative planning assessing the anatomic severity of the pathology, which is consisted of involved bony and soft tissue component. The most important thing which should stick in our minds is the complexity of the anatomical abnormality complicating the reconstruction.

The orthopaedic surgeons should display a hard challenge to overcome these deformities. Serious hypoplasia of the acetabulum, femoral head deformity, short femoral neck, excessive anteversion of the neck, narrow and straight medullary canal, totally dislocation, limb leg discrepancy and highly placed trochanter are some of these deformities which makes the surgery difficult. Surgery may be further complicated by the effects of previously performed osteotomies. Therefore, an accurate guide is mandatory to solve this problem in the pre-operative planning.

2.1 An overlook to the basic science of congenital hip disease

Understanding of the embryological development of the hip, epidemiology, pathologic anatomy and the natural history of congenital hip disease (CDH) should help us to conceive the disease with accuracy and improve our skills in surgical area.

2.1.1 Embryology and normal development of the hip

The acetabulum and femoral head develop from the same mesenchymal cells in a cleft at the tenth week of the gestational period (Gardner & Gray, 1950; Strayer, 1943). Hip joint is completely formed at the 11th week of gestation. It is initially deeply set and spherical. It becomes progressively less deeply set and hemispherical until birth. The hip has maximum range of motion at birth as it is shallowest. They thought that this adaptation help the fetus pass through the birth canal. After birth these trends reverse : the acetabulum becomes deeper again and the femoral head more spherical. This process continues throughout childhood. Thus the risk of dislocation is greatest at the prenatal period. (Rális & McKibbin, 1973; Watanabe, 1974; Wedge & Wasylenko, 1978).

It is better to discuss about the normal postnatal development of the hip, before examining the pathologic anatomy of DDH. The outer two thirds of the acetabulum is formed by the acetabular cartilage. This complex is interposed between the ilium, the pubis and the ischium. It is rich from hyaline cartilage cells and contains growth plates on each side which helps the hip socket to expand during growth. (Ponseti, 1978; Watanabe, 1974; Weinstein, 1987). It is known that the concavity of the acetabulum develops in response to the presence of the spherical femoral head (Harrison, 1961; Smith et al., 1958).

2.1.2 Pathologic anatomy of DDH

The term of DDH was started to be used in the last decades, after it was understood that this disease presents in different manners;

1. Dysplasia: The articular relationship between femur and acetabulum isn't broken, consequently Shenton's line is intact. There is inadequate development of the acetabulum.
2. Subluxation: The femoral head migrates laterally and proximally, Shenton's line is broken but femoral head is still in contact with acetabulum.
3. Dislocation: The femoral head is completely out of the acetabulum. The displacement of the femoral head is usually in posterosuperior direction.

It seems that these are the different stages of a disease seen in ages. (Hartofilakidis et al, 2000; Weinstein, 1987)

Therefore the pathological anatomy of the disease differs in a wide spectrum and depends on the stage of the disease. The anatomical pathology in dysplasia is mostly at the acetabular side of the joint. It is shallow than usual and femoroacetabular coverage is not enough.

This entity may cause osteoarthritic changes and femoral head will become deformed in time. Secondary degenerative changes may lead the dysplastic hip convert into a subluxed hip. In subluxation femoral head is proximally and laterally displaced. The major difference between dysplasia and subluxation is the intactness of Shenton's line on the graphies. In these cases bone stock of the acetabulum is less affected, and development of the femur is almost normal. In the otherhand, if a hip is dislocated, there is no relationship between the femoral head and acetabulum, acetabulum is too dysplastic and femoral head articulates to a false acetabulum on the iliac bone. The course of the abductor muscles changes to horizontally instead of lateral and vertical direction. The muscles also shorten in length due to the position of the trochanter major. Affected leg is shortened. Acetabulum is too much hypoplastic and the acetabular bone stock is remarkable diminished which is anteriorly. The bone stock is affected mostly in low dislocation cases due to the growth disruption of the acetabular lateral wall by the compression of the femoral head. Femur is also abnormal; it's hypoplastic, anteverted and femoral canal is narrow than usual. Capsule is elongated and thickened. The course of the nerve and arteries is altered. External rotators are elongated, also.

2.2 Land marks and classification methods of DDH

Various anatomical landmarks on conventional graphies were used to assess the degree of acetabular dysplasia. Center edge angle of Wiberg, acetabular angle of Sharp and femoral head extrusion index are some of these parameters measured using these landmarks (Heyman & Herndon, 1950; Sharp, 1961; Wiberg, 1939).

There are several classifications for the assesment of acetabular dysplasia. The classifications of Crowe and Hartofilakidis are the most used ones in the literature. Crowe et al. described a method to determine degree of dysplasia in 1979 (Crowe et al., 1979). It was based on the degree of proximal femoral migration relative to the acetabulum on an anteroposterior radiograph of the pelvis. The authors differentiated the disease into four classes according to the distance between the teardrop and junction of the femoral neck and head. The amount of the proximal migration of the femoral head was measured as a percentage of the height of the femoral head or the pelvis (Table 1).

The classification of Hartofilakidis et al. classified dysplasia in three groups based on anatomic correlations (Hartofilakidis et al., 1988). The dislocated hip was described in two stages as low and high dislocation (Table 2). The other classification system, which was described by Eftekhari and Kerboul et al., was classified according to the shape of the acetabulum and head, and the side of dislocation respectively (Eftekhari, 1993; Kerboul et al., 1987). Along these most reliable ones are the classifications of Crowe and Hartofilakidis and their classifications have shown a better reproducibility than the systems of Eftekhari and Kerboul et al (Brunner et al., 2008; Decking et al., 2006). However, we are aware of a combined classification or comprehensive algorithm for assesment of all components of this pathology.

There isn't any classification available describing this disease with the all aspects of the deformity. Most of the classifications are focused on the shape and relation between the head of femur and acetabulum. Soft tissue disturbances were excluded during evaluation and the effects of this on the success of the treatment were overlooked. Transversely orientated and poorly developed abductor muscles, and shortened adductors are some of these conditions which complicates the treatment than expected. Also, none of these classifications in use considers the amount of femoral anteversion and metaphyseal

development which results in discrepancy between the stem. These classifications should describe the deformity however they couldn't achieve any idea on the treatment method and the implant type.

Group	Description
I	Subluxation < 50% or proximal dislocation < 0.1% of the pelvic height
II	Subluxation 50% - 75% or proximal dislocation of 0.1% to 0.15 of pelvic height
III	Subluxation 75% - 100% or proximal dislocation of 0.15 to 0.20 of pelvic height
IV	Subluxation > 100% or proximal dislocation of > 0.20% of pelvic height

Table 1. The Classification of Crowe et al.

Type	Description
Dysplasia	The femoral head is not dislocated out of the acetabulum despite the degree of subluxation
Low Dislocation	The femoral head is dislocated and articulates with a false acetabulum which partially covers the true acetabulum to a varying degree
High Dislocation	The femoral head is dislocated and has migrated superiorly and posteriorly with no relation with any part of the true

Table 2. The Classification of Hartofilakidis et al.

2.3 The clinical presentation and indications in developmental hip disease

Most of the DDH patients have symptoms of other joints except the hip joint. The ipsilateral knee tends to be in valgus due to the hyper adductus of the hip. Low back pain may occur in patients with bilateral dislocations though to the hyperlordosis of the lumbar spine (Wedge & Wasylenko, 1978). As a result knee and lowback pain are mostly first symptoms of the disease. Most patients suffer from limping rather than the pain.

The indication of total hip prosthesis surgery in DDH, does not differ from the indications in primer arthrosis. The important point is that surgery in DDH patients is more complicated and the complication rate is higher than the others. So the indication of the surgery may be difficult in patients with minor symptoms. The main symptom for surgery indication should be the pain. Despite the complicity of the disease most of the patients of dislocation have no symptom rather than limping. It may be better to choose other treatment options in patients

which have no or little pain. Limbing only, shouldn't be an indication for total hip arthroplasty.

2.4 Total hip arthroplasty surgery in DDH

Despite the advanced techniques and implants, the total hip arthroplasty in DDH still remains as a hard challenge at the present time. The most difficult part of this challenge is to decide the best technique and optimum implant for each patient. Unfortunately there is no consensus of opinion on the surgical planning of these patients who present in a wide spectrum. The success of the operation mostly depends on the severity of the disease. According to the Crowe classification, the rate of survival at 20 years follow-up, was found as 72.7%, 70.7%, 36.7% and 15.6% for class 1,2,3 and 4, respectively (Chougale et al., 2005). Although total hip surgery is a successful operation in the treatment of dysplastic hips, it may present many problems due to the muscular contractures, abnormal location of the hip center, inadequate bone stock of acetabulum and femur, alterations in the hip anatomy, abductor insufficiency and leg length discrepancy (Charnley & Feagin, 1973; Hartofilakidis et al., 1996; Mulroy & Harris, 1990; Patterson & Brown, 1973; Symeonides et al., 1997).

2.4.1 The preoperative planning of DDH patients

Troelsen et al. drew our attention to the importance of the weight bearing pelvic radiographs and stated that it may allow us to determine the retroversion degree of the acetabulum more accurately (Troelsen et al., 2010). Although Standard Pelvis graphics and Judet graphics may tell us information about the acetabular osseous stock, the complicity of this disease induced the human being in searching new imaging modalities. The evolution in the imaging technologies, gives us the comfort of the understanding the pathology with all details before the surgery. CT has been used in preoperative planning and reported that important data about the morphology of the joint was obtained with the assistance of CT (Xenakis et al., 1996). 3d CT was also reported as an useful device in determining the acetabular anteversion and anterolateral deficiencies (Anda et al., 1991; Nakamura et al., 2000)

2.4.2 The exposure

Most methods of approach to the hip may be appropriate in DDH patients with slight deformity, for instance anterolateral and posterolateral exposures. Cameron et al. used Smith-Peterson approach to Crowe class 3 and 4 hips and they reported perfect results (Cameron et al., 1996). Despite their results they also reported a high rate of nerve complication. The surgical approach may be very dangerous due to the extraordinary anatomy in the highly dislocated patients. Trochanter major may serve as a good guide for the orientation of the surgeon. Transtrochanteric or subtrochanteric approaches are indicated for the highly dislocated patients who require retention of the abductors. Kumar and Shair described an extended iliofemoral approach but found no advantage of this technique besides it results too much muscle dissection (Kumar & Shair, 1997).

2.4.3 The approach to the dysplastic acetabulum

It is without controversy that the approach to the acetabulum and acetabular component placement are the most important part of the reconstruction in DDH. It was reported that the osseous stock is much more at the true acetabular area (Charnley & Feagin, 1973; Dunn

& Hess, 1976; Eftekar, 1978; Mendes et al., 1996). Though the ideal area of acetabular component placement is thought to be the true acetabulum (Linde & Jensen, 1988; Yoder et al., 1988) and restoration of normal hip center of rotation provided good long-term results (Bozic et al., 2004; Yoder et al., 1988). The superior or lateral placement of the acetabular cup was accused of being a risk factor for femoral and acetabular loosening (Doehring et al., 1996; Yoder et al., 1988). Reaming the acetabulum deeply and using porous coated small acetabular implants is usually enough to reconstruct the acetabulum. Although a lower rate of loosening has been reported in conjunction with medialization of the hip center, small prosthetic components require the use of a thin liner which are known to be responsible for polyethylene wear (Saikko, 1995). This is the reason that small cups are not appropriate to use in young and active patients with hip dysplasia (Dudkiewicz et al., 2002). The size of the acetabular component depends mostly on the severity of dislocation (Fletcher et al., 2008). While the size of the acetabular cup used in Crowe 2 is the largest ones, smallest implants usually necessary in Crowe 4 patients. Moreover polyethylene wear found to be related to the cup inclination angle (Perka et al., 2004). Perka, also stated that there was no significant association between wear and the cup size or the thickness of the liner in their series.

The inadequate medialisation of the hip center seems to be an important factor modifying long term results (Kennedy et al., 1998; McQueary et al., 1988). The best position of the femoral head center is thought to be less than 35 mm vertically from the interteardrop line and 25 mm laterally from the teardrop (Hirakawa et al., 2001). Alternatively; controlled acetabular medialisation (Hess & Umber, 1978; Paavilainen et al., 1990), acetabular enlarging and bone graft augmentation (MacKenzie et al., 1996; McQueary & Johnston, 1988) or reinforcement cage reconstruction (Gill et al., 1998) are the other methods which can be used. But these techniques may lead to an excessive bone loss and the usage of long offset femoral heads may be required.

High hip center concept was stated as an issue by Russotti (Russotti et al., 1991). They recommended to place the acetabular component at a more proximal but not more lateral position of the center of the hip in difficult acetabular reconstructions. It was stated that a longer stable fixation, than placement of the acetabular component at the true anatomical position, will be achieved if the latter approach necessitates reliance on large bulk allografts or autogenous grafts to provide most of the structural support. In a series of Dearborn et al., only 4 percent mechanical failure in 46 patients was reported after a mean of 10.4 years of follow-up duration (Dearborn et al., 1999). But, it was suggested that superior positioning of the acetabular component, leads to increased rates of loosening of the femoral and acetabular components (Pagnano, 1996). Also, Doehring reported that superolateral hip center relocation should be avoided and that superior-only relocation may be mechanically acceptable within the confines of the osseous anatomy of the acetabulum (Doehring et al., 1996). An attempt should be made to position the acetabular component in or near the true acetabular region. Hartofilakidis described the necessity of placement of the acetabular component to the true acetabular level, in three entries; 1) The lever arm for body weight is much longer than the abductor lever arm at the level of false acetabulum and it results in an excessive load on the hip joint, 2) Shearing forces acting on the acetabular cup may lead to early loosening at the level of the false acetabulum, 3) The bone stock is usually better at the level of the true acetabulum than it is at more proximal levels ((Hartofilakidis & Karachalios, 2004). The hip center of rotation could be restored in only seventy eight (% 66) of 121 hips in a series of Perka (Perka et al., 2004). Following the elongated capsule is often helpful in the location of the true acetabulum during surgery. However the localising of the normal hip

center during the operation is not always so easy. It leads the acetabular malplacement in an inadequate coverage. To overcome this problem a method of acetabuloplasty was described (Dunn & Hess, 1976; Hartofilakidis et al., 1988; Stamos et al., 1984). They termed this technique as cotyloplasty. In this technique, they created a controlled comminuted fracture of the entire medial wall of the acetabulum with use of a reamer or a chisel after completion of the acetabular reaming. Perforating the internal layer of the periosteum was avoided. After obtaining a large amount of autogenous cancellous graft from femoral head, they placed the graft material over the periosteum of the fractured medial wall. They finally cemented the acetabular component at an angle of 40-45 degrees horizontally and 10 degrees of anteversion. They advised 3 to 4 weeks bed rest postoperatively and didn't allow full weight bearing until the graft is incorporated radiographically, considering the horizontal compressive vectors applied by the muscles of the hip. Hartofilakidis et al. used this technique in 68 total hip operation which they used Charnley implants, and Charnley technique, involves an osteotomy of the greater trochanter (Hartofilakidis et al., 1996). Forty nine of the patients were type 3, 31 were type 2 and 6 were type 1 according to their classification. They found good or excellent results in 94 % of the patients operated in a mean duration of follow-up of seven years.

Various types of implants had been attempted in the reconstruction of the acetabulum. Cemented cups were tended to be use in large series in the past. In a series of Stans et al., aseptic loosening developed in 53% of cemented acetabular components (Stans et al., 1998). They thought that this high loosening rates were related with the acetabular component malplacement in Crowe type III patients. Insertion of the acetabular component without cement may be preferred when the osseous cavity could provide at least 80 % osseous coverage of a cementless cup (Hartofilakidis & Karachalios, 2004).

Perka et al. used a cementless threaded cups in reconstruction of the acetabulum (Perka et al., 2004). They didn't use a bone graft material to reconstruct the superolateral margin and the cup was slightly medialized to achieve stable anchorage of at least one thread in the existing bone. Although it was found that threaded acetabular components had high loosening results in the past (Stan et al., 1998), Perka reported a survival rate of % 97.5 at an average of 9.3 years for threaded cups. Their results were better than the those after implantation of cemented cups.

Flecher et al. reported a survival rate of 94.7% at 12 years, using a cementless press-fit acetabular component with an obturator hook and screws (Flecher et al., 2008). They sustained that this implant combined the principles of a reinforcement ring with those of uncemented acetabular press-fit components.

2.4.4 The usage of bone grafts in the augmentation of acetabular component

A technique of bolting the femoral head to the wing of ilium was developed to support the acetabular component (Harris, 1974). The acetabular cavity was reamed together with into the graft and the host bone. Screws were also used in fixing the autograft. Femoral head allografts became popular in time after the advantages of autografts (Jasty & Harris, 1987). It was reported that this technique worked well for short time follow-up and gave the surgeon the possibility of overcoming with the atrophic acetabulums (Harris et al., 1977). However, a high failure rate of nearly 46% were reported at a follow-up of twenty years with the use of the femoral head as an autograft for augmenting the superolateral aspect of the acetabular rim (Harris, 1993; Mulroy & Harris, 1990). The difficulties in revascularisation and of the large grafts and the forces which the graft is exposed may be the possible reasons for the

failure. Also, the high failure rates of femoral head augmentation in the reconstruction of superolateral acetabulum with cancellous bone fixation was related with mostly proximal placement of the acetabulum (Stans et al., 1998). Only cement augmentation may be an option in reconstructing the acetabulum in Crowe type III patients. It was reported that cement augmentation works well if the initial hip center is within the true acetabular region (Stans et al., 1998).

After the cementless acetabular components began to be used in dysplasia patients, the need to massive grafts in acetabular reconstruction, even at atrophic acetabulums, was diminished (Jasty et al., 1995). It was suggested that lack of osseous reconstruction of the lateral acetabular margin did not have any notable influence on the stability of the cup (Perka et al., 2004). In our personal experiences, if you have press-fit fixation between anterior and posterior wall or sufficient fixation with screws; it is allowed early weight bearing without any problem.

2.4.5 The approach to the deformed femur

The difficulty in reconstructing the femur of dysplastic patients mostly resulted from the alteration in the anatomy of the femur. The femur of the DDH patients were shown to have shorter necks and smaller straighter canals than the normal femurs (Noble et al., 2003). Cemented stems were used in dysplastic patients for a long time with a lesser success than the patients of primer arthrosis. Probably, the biomechanical abnormality of the hip and the persisted limbing after the surgery causes the act of abnormal forces on the cemented component. Consequently early aseptic loosening rates of cemented components increases in DDH patients. In a 20 years follow-up, 5 % aseptic loosening rate was reported with the cemented femoral components (Klapach et al., 2001). Moreover evidence of aseptic loosening was observed in 40% of the femoral components of Crowe type III patients at 20 years duration (Stans et al., 1998).

Cementless femoral stems seem to be more useful in reconstruction of young patients. Furthermore usage of the cementless stems prevent the occupation of excessive thick cement in narrow medullary canals. In a series of Lai et al., 56 patients, who have Crowe type 4 DDH, were operated with cementless stems (Lai et al., 2005). They didn't report any stem revision in a follow-up period of mean 12.3 years.

Cementless Zweymüller stem was used in 121 dysplastic hips and fracture occurred in the proximal part of the femur in seven cases (Perka et al., 2004). They believed that the high rate of femoral fracture was a result of increased anteversion of the femoral neck, the tight medullary space and the altered anatomy in the proximal femur following previous operations. However the survival rate of the stems was not influenced by this complication and it was reported as % 100 at an average follow-up duration of 9.3 years.

The porous coated S-Rom cementless modular stem was also reported as successful in the treatment of Crowe type III and IV hips, at a 10 year follow-up (Biant et al., 2009). They used the prosthesis as an intramedullary fixation device in the patients whom were required femoral shortening, with the benefit of the straight structure of this stem.

The excessive femoral anteversion seems to be an important problem in DDH patients rather than the primer arthrosis patients (Argenson et al., 2005). Compensating for excessive anteversion of the dysplastic femur is easy with the use of cemented stems. If a cementless stem will be used, it may be better to choose a modular or distally fixed component rather than proximally fixed femoral component. The proximally fixed components don't allow you to rotate the stem to compensate the anteversion because of the metaphyseal filling.

Modular stems allow us the regulation of the femoral anteversion unrelated with proximal metaphyseal morphology (Cameron et al., 1996). An other option in overcoming the anteversion problem is the usage of the thin conically stems. The results of Wagner conic prosthesis are also found as successful in a short term period (Ström et al., 2003). Hartofilakidis reported successful results with CDH Charnley prosthesis, a straight thin prosthesis (Hartofilakidis & Karachalios, 2004).

2.4.6 The subtrochanteric femoral shortening osteotomy

The restoration of the acetabulum to the anatomic center of the hip is not always so easy especially in Crowe type 4 patients. Three possible alternative to solve this problem on the dislocated femur were reported; 1) Trochanteric osteotomy may be carried out with metaphyseal shortening and advancement of the trochanter. Cemented stem may be the choice of use in this option, 2) A modular stem may be an option, 3) Subtrochanteric shortening and derotation, combined with an distally fixed cementless stem is the third alternative (Cabenala, 2001). Trial reduction by skeletal or skin traction was performed before the surgery, to assess the potential reduction (Symenoides et al., 1997). They also used a gradual traction technique with the use of an external fixator but pain and nerve palsy was reported in this case. According to us, subtrochanteric femoral shortening osteotomy is the best option to lower the femoral head to its original site instead of soft tissue release without damaging the nerves by stretching. Non-union rates are low with the use of cementless femoral stems, especially in Crowe type 4 dysplasias. Its also useful in aligning the anteversion of the neck in such malrotated femoral metaphyses. There is more than one technique reported for the shortening of the femur (Bruce et al., 2000; Klisic & Jankovic, 1976; Sener et al., 2002; Yagur et al., 1997). Klisic and Jankovic (Klisic & Jankovic, 1976) was first stated the usage of the femoral shortening osteotomies in the treatment of highly dislocated hips and than it was adapted into the total hip replacement operations by Sponseller and MacBeath (Sponseller & McBeath, 1988). Transvers subtrochanteric shortening osteotomy is a successful technique and none neurologic complication was reported in a series of Myung- Sik Park et al. of 24 patients operated with transvers osteotomy (Park et al., 2007). Yalcin et al. reported 79,5 % good and perfect results in 44 total hip replacements accompanied by transvers osteotomy at a meanly 62 months follow-up (Yalcin et al., 2010). In a study of Aeron et al., the patients, whom femurs were shortened, were followed up to mean 4.8 years and preoperative Harris scores found to increase from 43 to 89, postoperatively (Krych et al., 2010).

The short time requirement for bone healing, much bone contact and stability against the torsional forces are the advantages of step-cut osteotomy. Despite of these advantages, Sener et al. reported 2 non-unions after step-cut osteotomy in 28 patients (Sener et al., 2002) while one non-union was reported after transvers osteotomy in 14 hips (Onodera et al., 2006). In an other serie, Masaki Takao et al. combined cementless modular total hip prosthesis with step-cut subtrochanteric shortening osteotomy (Takao et al., 2011). No non-union and nerve palsy were reported. Merle d'Aubigne and Postel hip score increased from 9 to 16 in this 23 cases serie. The operation found to be successful in Crowe type IV patients. Furthermore, Grappiolo et al performed different femoral osteotomy techniques during total hip prosthesis surgery of 128 dysplastic hips (Grappiolo et al., 2007). They thought that subtrochanteric transvers osteotomy was the safest technique, after a 20 years experience.

Also, subtrochanteric transvers osteotomy is the technique which was favoured in our clinic for last 6 and 7 years. It seems to be much easy to perform, rather than the other techniques. The other advantage of this technique is that it gives you the possibility to fix the malrotation of the proximally femur.

In spite of these good results with shortening osteotomy, some authors don't favor shortening of the femoral diaphysis (Hartofilakidis & Karachalios, 2004). Osteotomy of the greater trochanter was performed in all hips except for three with dysplasia in a series of Hartofilakidis, consisted of 223 patients. They shortened the femur with progressive resection of bone from the femoral neck. Although they acquired a limb-lengthening of average 3.5 cm (1 to 7 cm) in the high dislocated patients, they only reported 2 nerve palsy which resolved within six months. They believed that nerve damage can be avoided by cautious handling of the retractors intraoperatively and by the placement of both hip and knee in flexion for three to four days after the operation. Fibrous union was seen 4%, 13% and 22% of the patients in dysplastic, low dislocated and high dislocated groups, respectively. It was stated that all of these fibrous unions were asymptomatic. Non-union and migration of the greater trochanter was observed in 2 and 1 hips in low dislocated and high dislocated groups, respectively.

Kerboull et al., also performed femoral stem mostly without shortening in 118 Crowe type IV hips (Kerboull et al., 2001). Shortening of the femur was needed only in 2 patients. Only 1 transient peroneal nerve palsy was reported although limb was lengthened more than 4 cm in 30 hips. The amount of limb lengthening causing nerve palsy, is not clear in the literature. After the operation, hip and knee flexion may help in reducing the tension in femoral and peroneal nerve, respectively. It was reported that 2.7 cm lengthening increased the risk of peroneal nerve injury, while 4.4 cm lengthening increased the risk of sciatic nerve injury (Edwards et al., 1987). They concluded that the maximal lengthening shouldn't exceed 4 cm. The 30 % of nerve palsy thought to be due to lengthening of the limb (Johanson et al., 1983). However, no correlation was observed between nerve injury and the amount of limb lengthening in a study, recently (Eggli et al, 1999). They found out the relation between nerve injury and the severity of the surgery. All cases who had nerve palsy after the operation, except one, required hard work because of different reasons like; previous operation, the severity of the disease, large acetabular defect, serious flexion deformity of the hip. Direct or indirect mechanical trauma was thought to be responsible in nerve palsy.

2.4.7 The resurfacing arthroplasty in DDH

Although that total hip arthroplasty is known as the golden treatment option in DDH, it was reported that resurfacing arthroplasty would be a successful alternative in Crowe type 1-2 patients (Xu et al., 2008). Amsutz et al. operated 103 hips of 90 patients whom have 94 percent Crowe type 1 dysplasia and reported it as a perfect method in a short and mid term period (Amsutz et al., 2008). It was interesting that the 43% of the femoral heads had a defect of more than 1 cm in their series. The vitality of the femoral head of the patients, whom were operated with Birmingham implants, was examined by fluoride positron emission tomography and found that the femoral head vitality persisted after the operation (Forrest et al., 2006). However, the ALVAL reaction resulted from metal-metal implants is the drawback of this technique, because the age-group of the indicated patients are mostly young.

2.4.8 Difficulties of arthroplasty in previously operated patients

The affect of the previous operations at the childhood on arthroplasty is not clear. Highly complication and revision rates were reported after total hip arthroplasty of the patients with femoral osteotomy (Ferguson et al., 1994). Boos et al. compared the results of the total hip arthroplasty between the patients whom femoral osteomy was performed before and not performed (Boos et al., 1997). There was no difference in peri-operatif complication and revision rates but they stated that the operation time was much longer and the surgical exposure was much difficult in the previously operated group than the other.

Chiari osteotomy was thought to be as an ease in the acetabuler component placement during the arthroplasty operations (Chiari, 1974). Supporters of this opinion attract the attention on the need of long time studies to sustain their theory (Hoffman et al., 1974; Mitchell, 1974; Wedge, 1995). Despite of these supporters, more bleeding was reported in previously operated patients with Chiari technique. And it was also stated that it was time consuming and the morbidity was higher (Minoda et al., 2006). The removal of the implants used during the osteotomy operations seems as a factor increasing the morbidity (Beaupre & Csongradi, 1996; Jago & Hindley, 1998). In our experience, it is hard to secure the primary stability of the acetabulum in patients who had periacetabular osteotomy beforehand.

3. Conclusion

There are several classification systems which may tell us the pathology very well in DDH. However none of them seems to be a candidate to guide for the surgeon in choosing the best technique and prosthesis as well. It is obvious that there is a need for a new classification method in DDH. 3D CT scans may be useful in preoperative planning. The reconstruction in DDH will remain as a challenge which may be overcome in the battle field since a new classification method is reported to help the surgeon.

4. References

- Anda S., Terjesen T., Kvistad K.A. (1991). Computed tomography measurements of the acetabulum in adult dysplastic hips: which level is appropriate? *Skeletal Radiol.* Vol.20, No.4, pp.267-271, ISBN 1853218
- Amstutz HC, Le Duff MJ, Harvey N, Hoberg M. (2008). Improved survivorship of hybrid metal-on-metal hip resurfacing with second-generation techniques for Crowe-I and II developmental dysplasia of the hip. *J Bone Joint Surg Am.* Vol.90, Suppl. 3, (August), pp.12-20, ISBN 18676931
- Argenson JN, Ryembault E, Flecher X, Brassart N, Parratte S, Aubaniac JM. (2005). Three-dimensional anatomy of the hip in osteoarthritis after developmental dysplasia. *J Bone Joint Surg Br.* Vol.87, No.9, (September), pp.1192-1196, ISBN 16129740
- Beaupre G.S., Csongradi J.J. (1996). Refracture risk after plate removal in the forearm. *J Orthop Trauma.* Vol.10, No.2, (February), pp.87-92, ISBN 8932666
- Biant L.C., Bruce W.J., Assini J.B., Walker P.M., Walsh W.R. (2009). Primary total hip arthroplasty in severe developmental dysplasia of the hip. Ten-year results using a cementless modular stem. *J Arthroplasty.* Vol.24, No.1, (January), pp.27-32, ISBN 18977633

- Boos N., Krushell R., Ganz R., Müller M.E. (1997). Total hip arthroplasty after previous proximal femoral osteotomy. *J Bone Joint Surg Br.* Vol.79, No.2, (March), pp.247-253, ISBN 9119851
- Bozic K.J., Freiberg A.A., Harris W.H. (2004). The high hip center. *Clin Orthop Relat Res.* Vol.420, (March), pp.101-105, ISBN 15057084
- Bruce W.J., Rizkallah S.M., Kwon Y.M., Goldberg J.A., Walsh W.R. (2000). A new technique of subtrochanteric shortening in total hip arthroplasty: surgical technique and results of 9 cases. *J Arthroplasty.* Vol.15, No.5, (August), pp.617-626, ISBN 10960001
- Brunner A, Ulmar B, Reichel H, Decking R. (2008). The Eftekhari and Kerboul classifications in assessment of developmental dysplasia of the hip in adult patients. Measurement of inter- and intraobserver reliability. *HSS J.* Vol.4, No.1, (February), pp.25-31, ISBN 18751859
- Cabanela M.E. (2001) Total hip arthroplasty for developmental dysplasia of the hip. *Orthopedics.* Vol.24, No.9, (September) pp.865-866, ISBN 11570460
- Charnley J., Feagin J.A. (1973). Low-friction arthroplasty in congenital subluxation of the hip. *Clin Orthop Relat Res.* Vol.91, (March-April), pp.98-113, ISBN 4574070
- Cameron H.U., Botsford D.J., Park Y.S. (1996). Influence of the Crowe rating on the outcome of total hip arthroplasty in congenital hip dysplasia. *J Arthroplasty.* Vol.11, No.5, (August), pp.582-587, ISBN 8872579
- Chougle A., Hemmady M.V., Hodgkinson J.P. (2005). Severity of hip dysplasia and loosening of the socket in cemented total hip replacement. A long-term follow-up. *J Bone Joint Surg Br.* Vol.87, No.1, (January), pp.16-20, ISBN 15686231
- Chiari K. (1974). Medial displacement osteotomy of the pelvis. *Clin Orthop Relat Res.* Vol.98, (January-February), pp.55-71, ISBN 4817245
- Crowe J.F., Mani V.J., Ranawat C.S. (1979). Total hip replacement in congenital dislocation and dysplasia of the hip. *J Bone Joint Surg Am.* Vol.61, No.1, (January), pp.15-23, ISBN 365863
- Dearborn J.T., Harris W.H. (1999). High placement of an acetabular component inserted without cement in a revision total hip arthroplasty. Results after a mean of ten years. *J Bone Joint Surg Am.* Apr;81(4):469-80, ISBN 10225792
- Decking R, Brunner A, Decking J, Puhl W, Günther KP. (2006). Reliability of the Crowe und Hartofilakidis classifications used in the assessment of the adult dysplastic hip. *Skeletal Radiol.* Vol.35, No.5, (May), pp.282-287, ISBN 16534641
- Doehring T.C., Rubash H.E., Shelley F.J., Schwendeman L.J., Donaldson T.K., Navalgund Y.A. (1996). Effect of superior and superolateral relocations of the hip center on hip joint forces. An experimental and analytical analysis. *J Arthroplasty.* Vol.11, No.6, (September), pp.693-703, ISBN 8884445
- Dudkiewicz I., Salai M., Ganel A., Blankstein A., Chechik A. (2002). Total hip arthroplasty in patients younger than 30 years of age following developmental dysplasia of hip (DDH) in infancy. *Arch Orthop Trauma Surg.* Vol.122, No.3, (April), pp.139-142, ISBN 11927994
- Dunn HK, Hess WE. (1976). Total hip reconstruction in chronically dislocated hips. *J Bone Joint Surg Am.* Vol.58, No.6, (September), pp.838-845, ISBN 956229

- Edwards BN, Tullos HS, Noble PC. (1987). Contributory factors and etiology of sciatic nerve palsy in total hip arthroplasty. *Clin Orthop Relat Res*. Vol.218, (May), pp.136-141, ISBN 3568473
- Eftekhari N. (1978). Principles of total hip arthroplasty. C V Mosby, St. Louis, pp 437-455.
- Eggli S., Hankemayer S., Müller M.E. (1999). Nerve palsy after leg lengthening in total replacement arthroplasty for developmental dysplasia of the hip. *J Bone Joint Surg Br*. Vol.81, No.5, (September), pp.843-845, ISBN 10530847
- Ferguson G.M., Cabanela M.E., Ilstrup D.M. (1994). Total hip arthroplasty after failed intertrochanteric osteotomy. *J Bone Joint Surg Br*. Vol.76, No.2, pp.252-257, ISBN 8113286
- Flecher X., Parratte S., Brassart N., Aubaniac J.M., Argenson J.N. (2008). Evaluation of the hip center in total hip arthroplasty for old developmental dysplasia. *J Arthroplasty*. Vol.23, No.8, (December), pp.1189-1196, ISBN 18534475
- Forrest N., Welch A., Murray AD., Schweiger L., Hutchison J., Ashcroft G.P. (2006). Femoral head viability after Birmingham resurfacing hip arthroplasty: assessment with use of [18F] fluoride positron emission tomography. *J Bone Joint Surg Am*. Vol.88, Suppl.3, (November), pp.84-89, ISBN 17079372
- Gardner E., Gray D.J. (1950). Prenatal development of the human hip joint. *Am J Anat*. Vol.87, No.2, (September), pp.163-211, ISBN 14771010
- Gill T.J., Sledge J.B., Müller M.E. (1998). Total hip arthroplasty with use of an acetabular reinforcement ring in patients who have congenital dysplasia of the hip. Results at five to fifteen years. *J Bone Joint Surg Am*. Vol.80, No.7, (July), pp.969-979, ISBN 9698001
- Grappiolo G., Spotorno L., Burastero G. (2007). Evolution of surgical techniques for the treatment of angular and torsional deviation in DDH: 20 years experience. *Hip Int*. Vol.17, Suppl.5, pp.105-110, ISBN 19197890
- Harris W.H. (1974). Total hip replacement for congenital dysplasia of the hip: Technique. In W.H. Harris (Ed). *The Hip, Proceedings of the 2nd Open Scientific Session of the Hip Society*. St Louis, CV Mosby, pp.251-265
- Harris W.H., Crothers O., Oh I. (1977). Total hip replacement and femoral-head bone-grafting for severe acetabular deficiency in adults. *J Bone Joint Surg Am*. Vol.59, No.6, (September), pp.752-759, ISBN 908698
- Harris W.H. (1993). Management of the deficient acetabulum using cementless fixation without bone grafting. *Orthop Clin North Am*. Vol.24, No.4, (October), pp.663-665, ISBN 8414432
- Harrison T.J. (1961). The influence of the femoral head on pelvic growth and acetabular form in the rat. *J Anat*. Vol.95, (January), pp.12-24, ISBN 13711848
- Hartofilakidis G., Stamos K, Ioannidis T.T. (1988). Low friction arthroplasty for old untreated congenital dislocation of the hip. *J Bone Joint Surg Br*. Vol.70, No.2, (March), pp.182-186, ISBN 3346284
- Hartofilakidis G., Stamos K., Karachalios T., Ioannidis T.T., Zacharakis N. (1996). Congenital hip disease in adults. Classification of acetabular deficiencies and operative treatment with acetabuloplasty combined with total hip arthroplasty. *J Bone Joint Surg Am*. Vol.78, No.5, (May), pp.683-92, ISBN 8642024

- Hartofilakidis G., Karachalios T., Stamos K.G. (2000). Epidemiology, demographics, and natural history of congenital hip disease in adults. *Orthopedics*. Vol.23, No.8, (August), pp.823-7, ISBN 10952045
- Hartofilakidis G., Karachalios T. (2004). Total hip arthroplasty for congenital hip disease. *J Bone Joint Surg Am*. Vol.86-A, No.2, (February), pp.242-250, ISBN 14960667
- Hess W.E., Umber J.S. (1978). Total hip arthroplasty in chronically dislocated hips. Follow-up study on the protrusio socket technique. *J Bone Joint Surg Am*. Vol.60, No.7, (October), pp.948-954, ISBN 701343
- Heyman C.H., Herndon C.H. (1950). Legg-Perthes disease; a method for the measurement of the roentgenographic result. *J Bone Joint Surg Am*. Vol.32, No.A4, (October), pp.767-778, ISBN 14784485
- Hirakawa K., Mitsugi N., Koshino T., Saito T., Hirasawa Y., Kubo T. (2001). Effect of acetabular cup position and orientation in cemented total hip arthroplasty. *Clin Orthop Relat Res*. Vol.388, (July), pp.135-142, ISBN 11451112
- Hoffman D.V., Simmons E.H., Barrington T.W. (1974). The results of the Chiari osteotomy. *Clin Orthop Relat Res*. Vol.98, (January-February), pp.162-170, ISBN 4817226
- Jago E.R., Hindley C.J. (1998). The removal of metalwork in children. *Injury*. Vol.29, No.6, (July), pp.439-441, ISBN 9813700
- Jasty M., Harris W.H. (1990). Salvage total hip reconstruction in patients with major acetabular bone deficiency using structural femoral head allografts. *J Bone Joint Surg Br*. Vol.72, No.1, (January), pp.63-67, ISBN 2298796
- Jasty M., Anderson M.J., Harris W.H. (1995). Total hip replacement for developmental dysplasia of the hip. *Clin Orthop Relat Res*. Vol.311, (February), pp.40-45, ISBN 7634589
- Johanson N.A., Pellicci P.M., Tsairis P., Salvati E.A. (1983). Nerve injury in total hip arthroplasty. *Clin Orthop Relat Res*. Vol.179, (October), pp.214-222, ISBN 6617020
- Kennedy J.G., Rogers W.B., Soffe K.E., Sullivan R.J., Griffen D.G., Sheehan L.J. (1998). Effect of acetabular component orientation on recurrent dislocation, pelvic osteolysis, polyethylene wear, and component migration. *J Arthroplasty*. Vol.13, No.5, (August), pp.530-534, ISBN 9726318
- Kerboul M., Mathieu M., Sauzies P. (1987). Total hip replacement for congenital dislocation of the hip. In: Postel M., Kerboul M., Evrard J., Courpied J.P. (eds) *Total hip replacement*. Springer, Berlin Heidelberg New York, pp 51-66 .
- Kerboul M., Hamadouche M., Kerboul L. (2001). Total hip arthroplasty for Crowe type IV developmental hip dysplasia: a long-term follow-up study. *J Arthroplasty*. Vol.16, No.8, Suppl. 1, (December), pp.170-176, ISBN 11742471
- Klapach A.S., Callaghan J.J., Goetz D.D., Olejniczak J.P., Johnston R.C. (2001). Charnley total hip arthroplasty with use of improved cementing techniques: a minimum twenty-year follow-up study. *J Bone Joint Surg Am*. Vol.83-A, No.12, (December), pp.1840-1848, ISBN 11741064

- Kliscic P., Jankovic L. (1976). Combined procedure of open reduction and shortening of the femur in treatment of congenital dislocation of the hips in older children. *Clin Orthop Relat Res*. Vol.119, (September), pp.60-69, ISBN 954325
- Krych A.J., Howard J.L., Trousdale R.T., Cabanela M.E., Berry D.J. (2010). Total hip arthroplasty with shortening subtrochanteric osteotomy in Crowe type-IV developmental dysplasia: surgical technique. *J Bone Joint Surg Am*. Suppl. 1, Pt. 2, (September), pp.176-187, ISBN 20844173
- Kumar A., Shair A.B. (1997). An extended iliofemoral approach for total arthroplasty in late congenital dislocation of the hip: a case report. *Int Orthop*. Vol.21, No.4, (September), pp.265-266, ISBN 9349966
- Lai K.A., Shen W.J., Huang L.W., Chen M.Y. (2005). Cementless total hip arthroplasty and limb-length equalization in patients with unilateral Crowe type-IV hip dislocation. *J Bone Joint Surg Am*. Vol.87, No.2, (February), pp.339-345, ISBN 15687157
- Linde F., Jensen J. (1988). Socket loosening in arthroplasty for congenital dislocation of the hip. *Acta Orthop Scand*. Vol.59, No.3, (June), pp.254-257, ISBN 3381653
- MacKenzie J.R., Kelley S.S., Johnston R.C. (1996). Total hip replacement for coxarthrosis secondary to congenital dysplasia and dislocation of the hip. Long-term results. *J Bone Joint Surg Am*. Vol.78, No.1, (January), pp.55-61, ISBN 8550680
- McQueary F.G., Johnston R.C. (1988). Coxarthrosis after congenital dysplasia. Treatment by total hip arthroplasty without acetabular bone-grafting. *J Bone Joint Surg Am*. Vol.70, No.8, (September), pp.1140-1144, ISBN 3417699
- Mendes D.G., Said M.S., Aslan K. (1996). Classification of adult congenital hip dysplasia for total hip arthroplasty. *Orthopedics*. Vol.19, No.10, (October), pp. 881-887, ISBN 8905863
- Minoda Y., Kadowaki T., Kim M. (2006). Total hip arthroplasty of dysplastic hip after previous Chiari pelvic osteotomy. *Arch Orthop Trauma Surg*. Vol.126, No.6, (August), pp.394-400, ISBN 16628429
- Mitchell G.P. (1974). Chiari medial displacement osteotomy. *Clin Orthop Relat Res*. Vol.98, (January-February), pp.146-150, ISBN 4817224
- Mulroy R.D. Jr., Harris W.H. (1990). Failure of acetabular autogenous grafts in total hip arthroplasty. Increasing incidence: a follow-up note. *J Bone Joint Surg Am*. Vol.72, No.10, (December), pp.1536-1540, ISBN 2254363
- Nakamura S., Yorikawa J., Otsuka K., Takeshita K., Harasawa A., Matsushita T. (2000). Evaluation of acetabular dysplasia using a top view of the hip on three-dimensional CT. *J Orthop Sci*. Vol.5, No.6, (November), pp.533-539, ISBN 11180914
- Noble P.C., Kamaric E., Sugano N., Matsubara M., Harada Y., Ohzono K., Paravic V. (2003). Three-dimensional shape of the dysplastic femur: implications for THR. *Clin Orthop Relat Res*. Vol.417, (December), pp.27-40, ISBN 14646700
- Onodera S., Majima T., Ito H., Matsuno T., Kishimoto T., Minami A. (2006). Cementless total hip arthroplasty using the modular S-ROM prosthesis combined with corrective proximal femoral osteotomy. *J Arthroplasty*. Vol.21, No.5, (August), pp.664-669, ISBN 16877151

- Paavilainen T., Hoikka V., Solonen K.A. (1990). Cementless total replacement for severely dysplastic or dislocated hips. *J Bone Joint Surg Br.* Vol.72, No.2, (March), pp.205-211, ISBN 2312556
- Pagnano W., Hanssen A.D., Lewallen D.G., Shaughnessy W.J. (1996). The effect of superior placement of the acetabular component on the rate of loosening after total hip arthroplasty. *J Bone Joint Surg Am.* Vol.78, No.7, (July), pp.1004-14, ISBN 8698717
- Park M.S., Kim K.H., Jeong W.C. (2007). Transverse subtrochanteric shortening osteotomy in primary total hip arthroplasty for patients with severe hip developmental dysplasia. *J Arthroplasty.* Vol.22, No.7, (October), pp.1031-1036, ISBN 17920477
- Patterson F.P., Brown C.S. (1972). The McKee-Farrar total hip replacement. Preliminary results and complications of 368 operations performed in five general hospitals. *J Bone Joint Surg Am.* Vol.54, No.2, (March), pp.257-75, ISBN 4631242
- Perka C., Fischer U., Taylor W.R., Matziolis G. (2004). Developmental hip dysplasia treated with total hip arthroplasty with a straight stem and a threaded cup. *J Bone Joint Surg Am.* Vol.86-A, No.2, (February), pp.312-319, ISBN 14960676
- Ponseti I.V. (1978). Growth and development of the acetabulum in the normal child. Anatomical, histological, and roentgenographic studies. *J Bone Joint Surg Am.* Vol.60, No.5, (July), pp.575-585. ISBN 681376
- Rális Z., McKibbin B. (1973). Changes in shape of the human hip joint during its development and their relation to its stability. *J Bone Joint Surg Br.* Vol.55, No.4, (November), pp.780-785, ISBN 4766182
- Russotti G.M., Harris W.H. (1991). Proximal placement of the acetabular component in total hip arthroplasty. A long-term follow-up study. *J Bone Joint Surg Am.* Vol.73, No.4, (April), pp. 587-592, ISBN 2013598
- Sharp I. (1961). Acetabular dysplasia. *J Bone Joint Surg (Br).* Vol.43, pp.268-272.
- Saikko V.O. (1995). Wear of the polyethylene acetabular cup. The effect of head material, head diameter, and cup thickness studied with a hip simulator. *Acta Orthop Scand.* Vol.66, No.6, (December), pp.501-506, ISBN 8553815
- Sener N., Tozun I.R., Asik M. (2002). Femoral shortening and cementless arthroplasty in high congenital dislocation of the hip. *J Arthroplasty.* Vol.17, No.1, (January), pp.41-48, ISBN 11805923
- Smith W.S., Ireton R.J., Coleman C.R. (1958). Sequelae of experimental dislocation of a weight-bearing ball- and socket joint in a young growing animal; gross alterations in bone and cartilage. *J Bone Joint Surg Am.* Vol.40-A, No.5, (October), pp.1121-1127, ISBN 13587581
- Sponseller P.D., McBeath A.A. (1988). Subtrochanteric osteotomy with intramedullary fixation for arthroplasty of the dysplastic hip. A case report. *J Arthroplasty.* Vol.3, No.4, pp.351-354, ISBN 3241173
- Stamos K., Hartofilakidis G., Koroneas A., Xenakis T. Mechanical strength of P.M.M.A bonding to cancellous bone graft. An experimental study in dogs. Read the combined meetings of the Hellenic Association of Orthopaedic Surgery and Traumatology and American Hip Society, Rhodes, May 4, 1984.

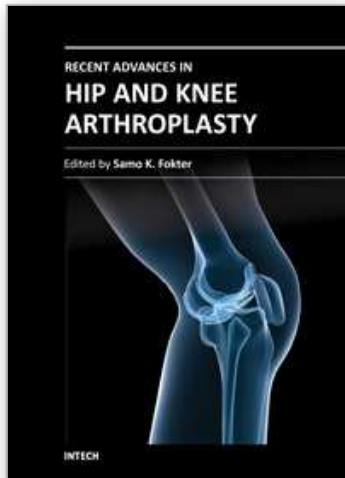
- Stans A.A., Pagnano M.W., Shaughnessy W.J., Hanssen A.D. (1998). Results of total hip arthroplasty for Crowe Type III developmental hip dysplasia. *Clin Orthop Relat Res.* Vol.348, (March), pp.149-157, ISBN 9553547
- Strayer L.M. (1943). The Embryology of the Human Hip Joint. *Yale J Biol Med.* Vol.16, No.1, (October 1943), pp. 13-26.6, ISBN 21434122
- Ström H., Mallmin H., Milbrink J., Petrén-Mallmin M., Nivbrant B., Kolstad K. (2003). The cone hip stem: a prospective study of 13 patients followed for 5 years with RSA. *Acta Orthop Scand.* Vol.74, No.5, (October), pp.525-530, ISBN 14620971
- Symeonides P.P., Pournaras J., Petsatodes G., Christoforides J., Hatzokos I., Pantazis E. (1997). Total hip arthroplasty in neglected congenital dislocation of the hip. *Clin Orthop Relat Res.* Vol.341, (August), pp.55-61, ISBN 9269155
- Takao M., Ohzono K., Nishii T., Miki H., Nakamura N., Sugano N. (2011). Cementless modular total hip arthroplasty with subtrochanteric shortening osteotomy for hips with developmental dysplasia. *J Bone Joint Surg Am.* Vol.93, No.6, (March), pp.548-555, ISBN 21411705
- Troelsen A, Rømer L, Jacobsen S, Ladelund S, Søballe K. (2010). Cranial acetabular retroversion is common in developmental dysplasia of the hip as assessed by the weight bearing position. *Acta Orthop.* Vol.81, No.4, (August), pp.436-441, ISBN 20809742
- Watanabe RS. (1974). Embryology of the Human Hip. *Clin Orthop Relat Res.* Vol.98, (Jan-Feb), pp.8-26, ISBN 4817247
- Wedge J.H. (1995). Osteotomy of the pelvis for the management of hip disease in young adults. *Can J Surg.* Vol.38, Suppl.1, (February), pp.25-32, ISBN 7874625
- Wedge J.H., Wasylenko M.J. (1978). The natural history of congenital dislocation of the hip: a critical review. *Clin Orthop Relat Res.* Vol.137, (Nov-Dec), pp.154-162, ISBN 743823
- Weinstein S.L. (1987). Natural history of congenital hip dislocation (CDH) and hip dysplasia. *Clin Orthop Relat Res.* Vol.225, (December), pp.62-76. ISBN 3315382
- Wiberg G. (1939). Studies on dysplastic acetabula and congenital subluxation of the hip joint. *Acta Orthop Scand.* Vol. 58, No. Suppl, pp.1-132
- Xenakis TA, Gelalis ID, Koukoubis TD, Soucacos PN, Vartziotis K, Kontoyiannis D, Tatsis C. (1996). Neglected congenital dislocation of the hip. Role of computed tomography and computer-aided design for total hip arthroplasty. *J Arthroplasty.* Vol.11, No.8, (December), pp.893-8, ISBN 8986566
- Xu W.D., Li J., Zhou Z.H., Wu Y.S., Li M. (2008). Results of hip resurfacing for developmental dysplasia of the hip of Crowe type I and II. *Chin Med J (Engl).* Vol.121, No.15, (August), pp.1379-1383, ISBN 18959113
- Yalcin N., Kilicarslan K., Karatas F., Mutlu T., Yildirim H. (2010). Cementless total hip arthroplasty with subtrochanteric transverse shortening osteotomy for severely dysplastic or dislocated hips. *Hip Int.* Vol.20, No.1, (January-March), pp.87-93, ISBN 20235079
- Yasgur D.J., Stuchin S.A., Adler E.M., DiCesare P.E. (1997). Subtrochanteric femoral shortening osteotomy in total hip arthroplasty for high-riding developmental

dislocation of the hip. *J Arthroplasty*. Vol.12, No.8, (December), pp.880-888, ISBN 9458253

Yoder S.A., Brand R.A., Pedersen D.R., O'Gorman T.W. (1988). Total hip acetabular component position affects component loosening rates. *Clin Orthop Relat Res*. Vol.228, (March), pp.79-87, ISBN 3342591

IntechOpen

IntechOpen



Recent Advances in Hip and Knee Arthroplasty

Edited by Dr. Samo Fokter

ISBN 978-953-307-841-0

Hard cover, 452 pages

Publisher InTech

Published online 27, January, 2012

Published in print edition January, 2012

The purpose of this book is to offer an exhaustive overview of the recent insights into the state-of-the-art in most performed arthroplasties of large joints of lower extremities. The treatment options in degenerative joint disease have evolved very quickly. Many surgical procedures are quite different today than they were only five years ago. In an effort to be comprehensive, this book addresses hip arthroplasty with special emphasis on evolving minimally invasive surgical techniques. Some challenging topics in hip arthroplasty are covered in an additional section. Particular attention is given to different designs of knee endoprostheses and soft tissue balance. Special situations in knee arthroplasty are covered in a special section. Recent advances in computer technology created the possibility for the routine use of navigation in knee arthroplasty and this remarkable success is covered in depth as well. Each chapter includes current philosophies, techniques, and an extensive review of the literature.

How to reference

In order to correctly reference this scholarly work, feel free to copy and paste the following:

Nevzat Selim Gokay, Alper Gokce, Bulent Alp and Fahri Erdogan (2012). Planning of Arthroplasty in Dysplastic Hips, Recent Advances in Hip and Knee Arthroplasty, Dr. Samo Fokter (Ed.), ISBN: 978-953-307-841-0, InTech, Available from: <http://www.intechopen.com/books/recent-advances-in-hip-and-knee-arthroplasty/planning-of-arthroplasty-in-dysplastic-hips>

INTech
open science | open minds

InTech Europe

University Campus STeP Ri
Slavka Krautzeka 83/A
51000 Rijeka, Croatia
Phone: +385 (51) 770 447
Fax: +385 (51) 686 166
www.intechopen.com

InTech China

Unit 405, Office Block, Hotel Equatorial Shanghai
No.65, Yan An Road (West), Shanghai, 200040, China
中国上海市延安西路65号上海国际贵都大饭店办公楼405单元
Phone: +86-21-62489820
Fax: +86-21-62489821

© 2012 The Author(s). Licensee IntechOpen. This is an open access article distributed under the terms of the [Creative Commons Attribution 3.0 License](#), which permits unrestricted use, distribution, and reproduction in any medium, provided the original work is properly cited.

IntechOpen

IntechOpen