

We are IntechOpen, the world's leading publisher of Open Access books Built by scientists, for scientists

6,900

Open access books available

185,000

International authors and editors

200M

Downloads

Our authors are among the

154

Countries delivered to

TOP 1%

most cited scientists

12.2%

Contributors from top 500 universities



WEB OF SCIENCE™

Selection of our books indexed in the Book Citation Index
in Web of Science™ Core Collection (BKCI)

Interested in publishing with us?
Contact book.department@intechopen.com

Numbers displayed above are based on latest data collected.
For more information visit www.intechopen.com



Degenerative Hip Joint Pain – The Non-Arthroplasty Surgical Options

Ahmed Alghamdi and Martin Lavigne
*Université de Montréal
Canada*

1. Introduction

Degenerative Hip Joint Pain (DHJP) is a major cause of functional limitation in both young active and old sedentary patients. Total hip arthroplasty (THA) is one of the most successful surgical procedures performed in orthopaedics. Sir John Charnley introduced the concept of low friction arthroplasty for end stage hip arthritis. The rewarding result of this procedure makes THA the gold standard for the treatment of end stage degenerative hip disease. In a recent retrospective study to establish the implant survivorship after THA in young patient at 25 years follow up, up to 89% (80%-98%) survivorship was reported among patients who were diagnosed with developmental dysplasia, 85% (77%-93%) in patients diagnosed with rheumatoid arthritis and 74% (61%-87%) in patients group with idiopathic degenerative arthritis of the hip[1]. Despite improved surgical technique, implant biomaterial and prosthesis design, complications such as recurrent dislocation, osteolysis and loosening still exist. Failure of THA may present with particular problems when revision arthroplasty is needed in young patient, which makes hip joint preservation techniques still actual in this population (hip arthroscopy, surgical dislocation with osteochondroplasty, periacetabular osteotomy, proximal femur osteotomy), and put back on track older surgical procedures such as hip fusion or resection arthroplasty for certain rare indications.

2. Evaluation of painful hip joint

Evaluation of painful hip joint starts with history and physical examination followed by imaging study and laboratory investigation, as needed. Patient with DHJP presents with acute or insidious onset pain, usually with a recurring pattern. It is critical to differentiate sources of hip pain originating from intra-articular pathology from those secondary to extra articular pathology. Intra-articular pathology usually causes deep-seated pain, localized in the anterior groin or inguinal region, although pain of intra-articular origin may be felt at any area around the hip joint. Individuals with symptoms secondary to Femoroacetabular impingements (FAI) might indicate the location of pain by gripping the lateral hip, just above the greater trochanter, between the abducted thumb and index finger. This is known as C-sign[2]. Other symptoms of intra-articular pathology include catching, popping and locking, although those symptoms may represent a misinterpretation of extra-articular conditions such as snapping of the psoas tendon or of the tensor fascia lata.

The pain is usually aggravated by weight bearing, going upstairs, and prolonged seating with hip flexion and adduction as in limited seat space, such as a car seat. Extra-articular pathology will cause pain mostly in the pubic area, lateral trochanter region, buttock region, or posterior thigh. Referred pain from spine or vascular claudication should be ruled out. Pelvic pathology and anterior abdominal wall hernia might cause pain in the groin region.

Physical examination starts with inspection of the patient gait while getting into the office. A limp, Trendelenburg lurch and poor trunk balance should be looked for[3]. Inspection may disclose pelvis malposition, joint contractures or limb inequality. The foot progression angle should be observed. The patient should sit for history taking. After history, the patient should lay supine on the examination table. Ligament laxity can be tested. Log roll the limb to elicit any pain secondary to intra-articular pathology by rotating the femoral head in the acetabulum. Bony prominences, muscles and tendons around the hip joint, along with, the sciatic nerve and bursa overlying the greater trochanter are then palpated. Anterior abdominal wall examination and groin hernia test should be done. The spine, sacroiliac joint and the knee should also be examined. A complete neurovascular assessment of the limb involved should then be performed. Ranges of motion should be done both actively and passively (Table 1).

Range of motion	Value
Flexion	110-120
Extension	10-15
Abduction	30-50
Adduction	20-30
External rotation at 90 degree	40-60
Internal rotation at 90 degree	30-40

Table 1. Hip range of motion

Special test:

- **Anterior labral stress test:** while the patient in supine position, takes the patients leg into flexion, adduction, and slight internal rotation to compress the anterior part of the labrum. A positive test has occurred if the pain has been reproduced and implies an anterior superior tear. Other clinical finding to look for would be crepitus, popping, clicking.
- **Posterior labral stress test:** patient lay in a prone position, and then the examiner will take the patients leg into passive hyperextension, abduction and external rotation. If this motion elicits the pain, a positive test has occurred secondary to posterior tear.
- **Anterior impingement test:** Passive combination of flexion, adduction and internal rotation will cause pain in the anterior groin, which may suggest the presence of FAI.
- **Posterior impingement test:** hyperextension and external rotation will cause posterior impingement and pain, although pain in this position might be secondary to instability.
- **Ober’s test:** The patient is positioned in lateral decubitus with the affected side up. The examiner will stabilize the pelvis from the back and hold the leg in neutral rotation and abduction with the knee in 90 degrees of flexion. The hip is then extended and slowly adducted down towards the table. The knee will not reach the examination table because of restricted adduction due to the tight iliotibial band. Lateral knee pain might occur.

- **Snapping test:** Patient can be asked to reproduce the snapping. An audible snap tends to occur more frequently with internal coxa saltans (psoas snapping on the pubic eminence), and can be reproduced when the hip is actively extended from a flexed and abducted hip position. A palpable snapping on the lateral aspect of the hip suggests external coxa saltans (usually tight or thickened iliotibial band sliding over the greater trochanter). Patient can reproduce external snapping while performing cycling move in lateral decubitus. Palpation over the GT may cause tenderness.
- **The Trendelenburg test** should be performed to rule out gluteus medius weakness.
- **Thomas test:** The patient lay supine on the examination table and hold one knee in direction of his chest, while the other leg remains extended. Positive Thomas test occur when the patient cannot keep the opposing leg extended secondary to the hip fixed flexion contraction.

Imaging study: [4]

- *Anteroposterior (AP) pelvis view:* Standard pelvic view can be taken with the patient supine, or preferably standing. The coccyx should be centered 2-3 cm above the symphysis pubis. Both obturator foramina should look symmetrical.

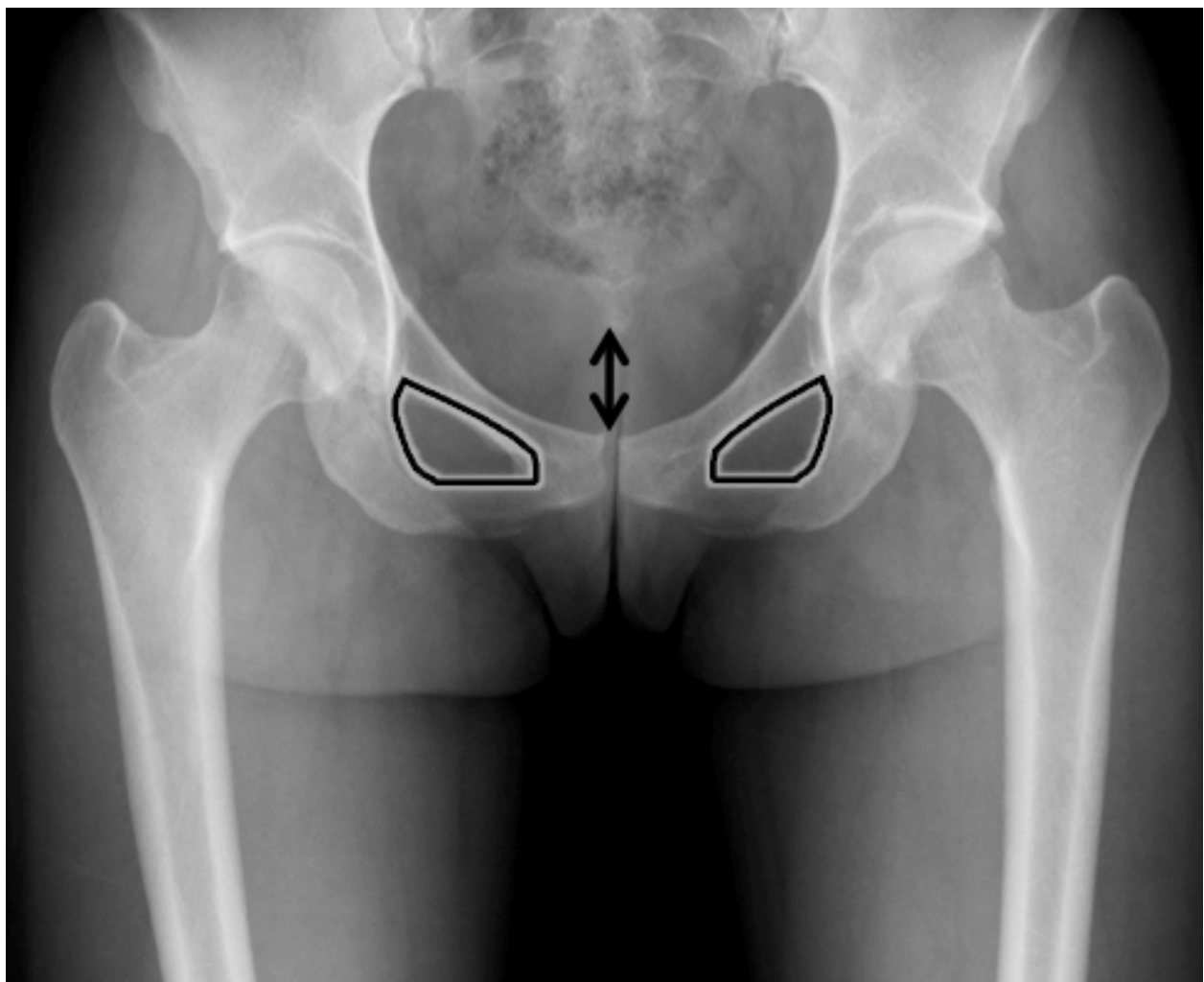


Fig. 1. AP pelvic view, centered view; symmetric obturator foramina, centered coccyx with 2-3 cm distance above the pubic symphysis.

- Lateral views of the hip:
 - *Frog leg lateral*: mostly a view of the proximal femur
 - *Cross table lateral*: view the acetabulum and proximal femur
 - *Dunn 45/90*: specific view of anterior femoral head-neck junction. This view can be taken with the hip at 45 or 90 degree of flexion.
 - *False profile*: for measuring anterior acetabular coverage

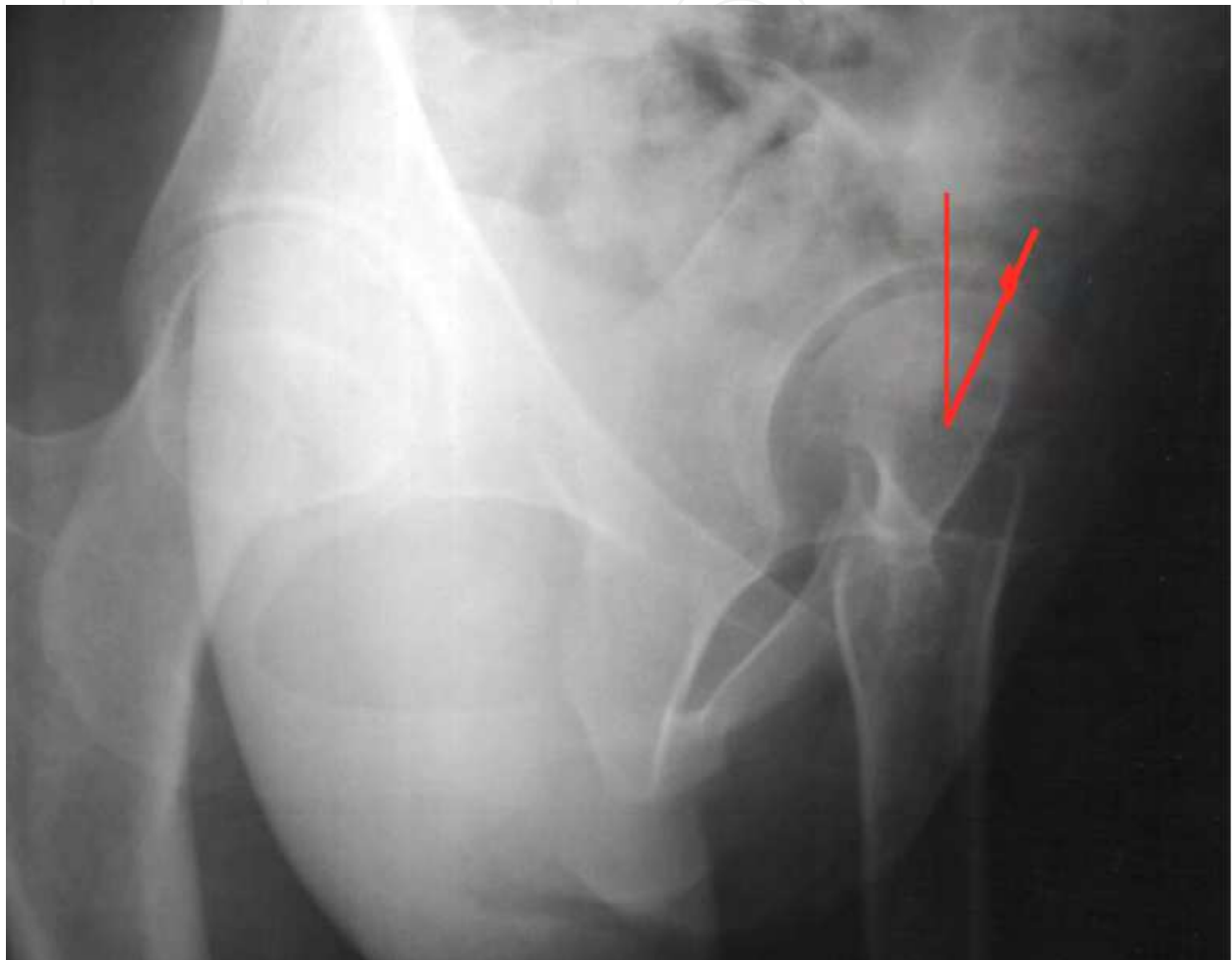


Fig. 2. False-profile view, the anterior centre-edge (VCA) angle quantifies the anterior cover of the femoral head, and angles of less than 20° are considered abnormal.

- *AP hip view*: the x-ray beam is centered on the hip joint. Not reliable for cross over sign.
- *Computer Tomography (CT) scans*: with 3-D reconstruction, can be more accurate for pre-operative impingement evaluation or other deformation of acetabulum or femur.
- *Magnetic resonance imaging (MRI) scan*: good diagnostic tool for both soft tissue and bone structure. Intra-articular contrast injection can be used for further evaluation of labrum. Alpha angle of Notzli was described on a specific MRI view, although it is currently measured on different radiographic modalities[5].
- *Ultrasound scan*: can provide dynamic evaluation. It can be used as therapeutic tool as well[6].
- *Bone scan*: usually non specific
- *Bursography*: can be used for snapping hip.

3. Hip arthroscopy

The first recorded attempt of arthroscopic visualization of the hip joint is attributed to Michael Burman in 1930. The limited indications of hip arthroscopy at that time and the anatomic constraints of the hip joint with suboptimal equipment design have limited the use of hip arthroscopy for long time. However with improved hip arthroscopy tools, the indications for hip arthroscopy continue to evolve. Currently, many clinical issues related to the hip joint and the surrounding tissue can be treated with hip arthroscopy. Degenerative hip conditions that can be treated with hip arthroscopy are listed in Table 2.

Degenerative Indications	Non-Degenerative indications
<ul style="list-style-type: none">• Labral Lesions• Chondral injuries• FAI• Degenerative arthritis	<ul style="list-style-type: none">• Loose bodies (traumatic or synovial chondromatosis)• Sepsis• Synovial disease• Instability• Coxa Sultan (extern or intern)

Table 2. Conditions treated with hip arthroscopy

3.1.1 Labral lesions

The etiology of labral tear is traumatic, degenerative, idiopathic or congenital. Labral pathology can also be classified based on location (anterior, superolateral, posterior). Anterior labral tears are the most common form in the western population, accounting for 90% of cases. Degenerative labral tears are more and more frequently felt to result from FAI and usually starts in the avascular (water-shield) white zone of the labral structure. In this zone, there is low chance of successful healing of the labral tear with conservative treatment. Labral tears may cause pain and microinstability of the hip joint. They also may increase friction within the joint and the strain within the articular cartilage; thereby possibly untreated lesion will result in accelerated degeneration of the joint. In FAI, persisting conflict between femoral neck and acetabulum will lead to chondral delamination and thinning, further the labral tear, paralabral cyst and ultimately, degenerative osteoarthritis

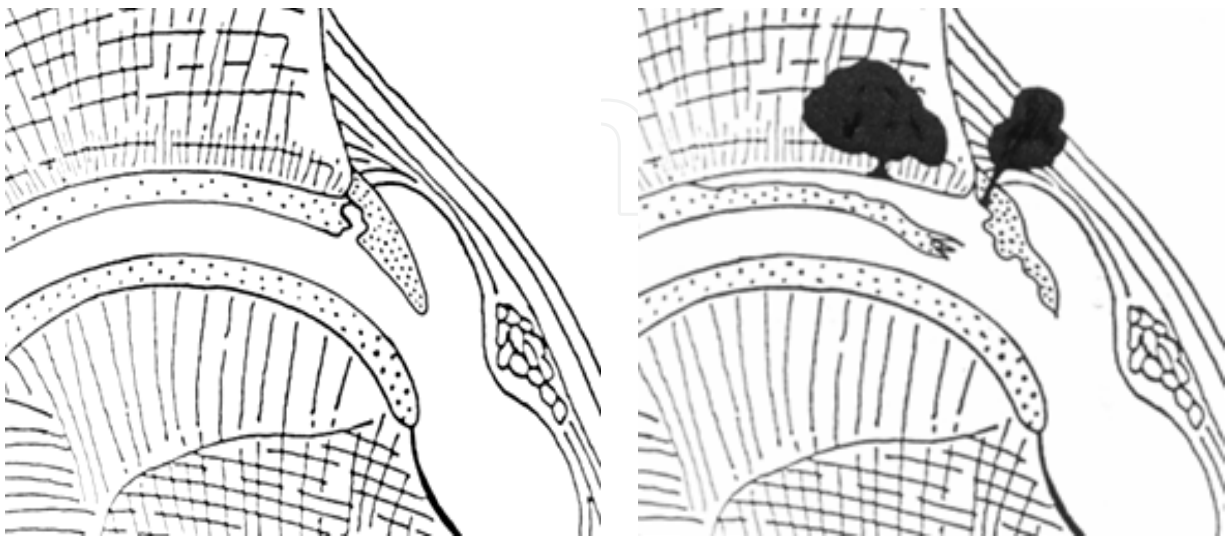


Fig. 3. Labral Tear begins at the articular labral junction, termed the *watershed region*. Progressive labral degenerations result in paralabral cysts and articular cartilage damage.

of the involved joint. With hip arthroscopy, the labrum can be debrided, resected, repaired or reconstructed.

3.1.2 Femoroacetabular impingement (FAI)

This is a descriptive diagnosis characterized by combined clinical features and pathomorphological findings that can result in degenerative changes. The patient's pathomorphology is characterized by either cam lesion, pincer lesion or a combination of both. Mechanical abutment of cam lesion commonly causes pathological changes starting with focal, deep chondral delamination in the anterolateral (superolateral) region of the acetabulum. Separation of the labrum-chondral junction will allow the synovial fluid to extravasate to the subchondral bone or para-labral region creating intra osseous or para-labral cyst (Figure 3). Leverage of head-cam lesion against the acetabulum with extreme range of motion can result in contre-coup lesion in posteroinferior acetabulum [7]. Leading to global degenerative changes.

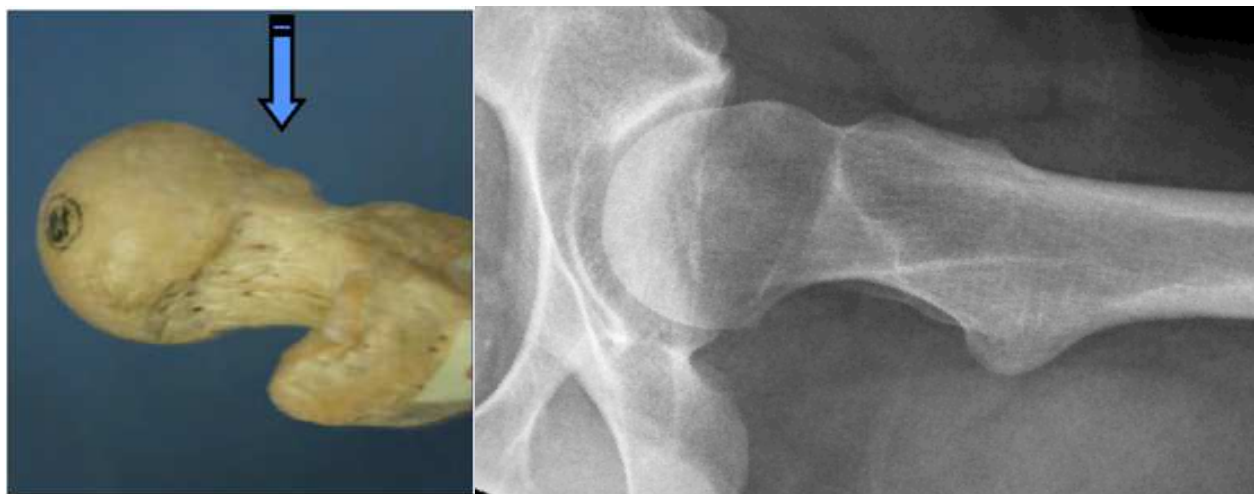

Fig. 4. Cam lesion as seen in skeletonized specimen and frog leg lateral view.

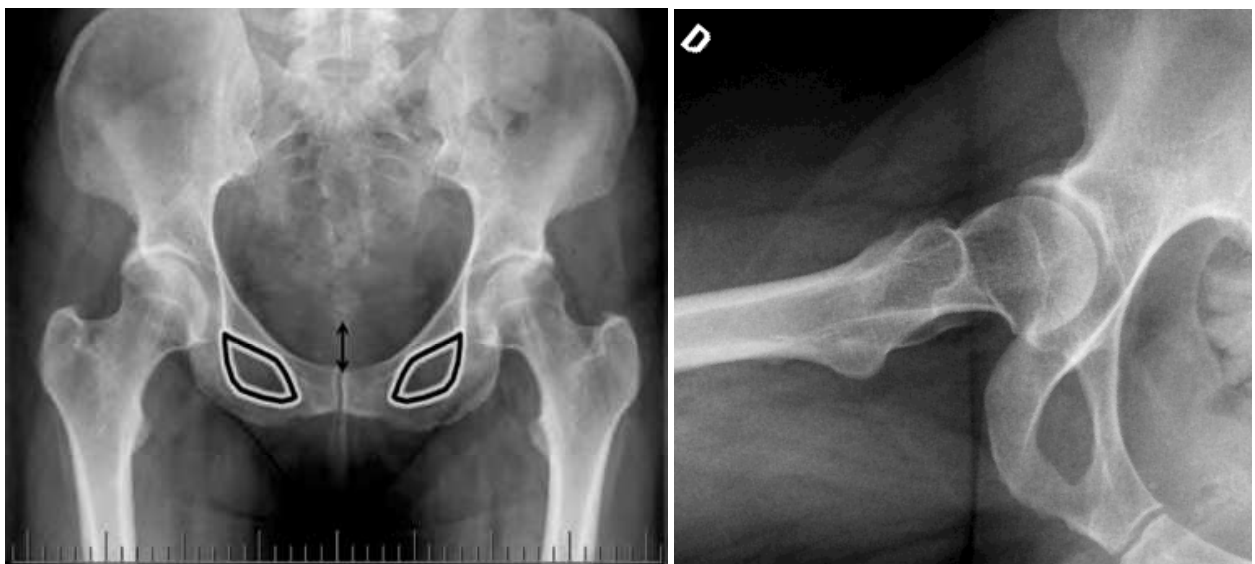


Fig. 5. Pincer Lesion, global over-coverage and labral calcification in 45 years old female. Notice the relatively minor degenerative changes on the anterior femoral head neck junction.

The pincer lesion will cause a crush-type injury of the labrum and progressive degenerative changes with minimal damage to the articular cartilage of the acetabulum.

Indication of hip arthroscopy in this setting is symptomatic FAI with concomitant labral and or cartilage lesion. The labrum is addressed as mentioned in the previous section, while the cartilage damage is addressed by debridement or micro fracture of the underlying subchondral bone. The osseous abnormalities are treated with an osteochondroplasty and acetabuloplasty as needed.

3.1.3 Degenerative arthritis

Arthroscopic intervention in early hip joint degeneration may relieve pain and others associated symptoms (i.e. catching, locking and range of motion limitation). However, as seen with knee arthroscopy, it provides little benefit on the long term and thus represents a limited indication for hip arthroscopy. Hip arthroscopy in this clinical scenario will provide limited role through removal of loose bodies, debridement of degenerative chondral or labral tears and subtotal synovectomy. Capsular release and osteophyte excision might improve the hip range of motion.

Before attempting hip arthroscopy for advance degenerative changes, patient needs to know the limitation of such procedure. The patient are less likely to benefit from hip arthroscopy when joint space is less than 50% of normal, with pain at rest, functionally depleting limitation of hip range of motion or pre-operative Harris Hip Score (HHS) of less than 60.

3.2 Surgical technique

Under general, spinal or combined anesthesia, the patient is positioned supine or in lateral decubitus according to the surgeon's preference. This section will only address the hip arthroscopy while the patient on supine position. A well-padded perineal post will be used to protect the pubis and provide counter traction force during distraction of the hip joint. The foot should also be well-padded before connecting the foot attachments. Distraction of the hip joint is gently performed with the hip slightly flexed in neutral abduction and rotation until approximately 8 mm of joint space is achieved. Multiple portals can be used to visualize both central (articular surfaces) and peripheral (extra articular) compartments of the hip joint. Common portals used are anterior, anterolateral and posterolateral in relation to the Greater Trochanter (GT). Fluoroscopic views should be used during portal preparation to ensure enough joint distraction and to avoid labral penetration. The 70-degree lens is used most of the time. Labral tear, cartilage damage or over coverage can be treated as described above. Inspection of the peripheral compartment and excision of the cam lesion can be done without traction with the use of fluoroscopy x-ray to guide precise cam lesion excision. Dynamic assessment is helpful to assess the relief of FAI.

3.3 Postoperative rehabilitation

After arthroscopic osteochondroplasty and labral debridement, full weight bearing will be permitted, unless micro fractures were performed, in which case toe touch weight bearing is recommended for 6-8 weeks. Aggressive active-passive range of motion and proprioception exercise will be started early post operative. High impact sport is not allowed for 2 months post femoral neck osteoplasty.

3.4 Complications

Complications occur in 0.5% to 5% of patients and are most often related to the required distraction of the hip joint [8]. Sciatic, femoral or pudendal nerve palsy can result from prolonged traction time. Nerve injury tends to be transient neuropraxia, which completely resolve spontaneously in few weeks. A well-padded post should prevent perineal tear and pudendal nerve injury. Bleeding and lateral femoral cutaneous nerve injury can occur during portal placement. Postoperative persistent secondary to trochanteric bursitis, intra-articular capsular adhesion (especially between the capsule and repaired labrum, or between the capsule and anterior neck) may occur. Femoral neck fracture, avascular necrosis of the femoral head, and under or over resections of cam lesion can be a mode of failure. Instrumental breakage rarely happen, but sometimes requires open arthrotomy to remove the broken fragment. Incidence of deep venous thrombosis ranges from 0 to 3.7% in various retrospective clinical reports[9].

3.5 Results of arthroscopic FAI surgery

Hip arthroscopy for the treatment of FAI has only been used recently. Philippon et al studied 45 professional athletes at 1.6 years (6 months to 5.5 years) follow up. 93% of patients returned to professional competition, but only 78% remained active in professional sport at final follow up[10].

Sampson et al analyzed the results of 183 patients (194 hips) with positive impingement sign at preoperative assessment at maximum follow up of 29 months. 95% of the patients showed no sign of impingement at one year after surgery[11].

Byrd et al found an improvement of Harris Hip Score (HHS) from baseline of 20 points (range 17 to 60 point), which was reported in 83% of patients at 1 year follow up[12].

Another study reported by Philippon et al analyzed 112 patients at mean follow up of 2.3 years. The HHS improved from 58 to 84.3 in those patients with FAI associated with labral and chondral pathology. However, 8.9% of the patient underwent THA at mean follow up of 16 months[13].

4. Combined limited open arthrotomy and hip arthroscopy

Combined limited open arthrotomy and hip arthroscopy can be utilized to treat symptomatic anterolateral FAI: the hip arthroscopy will focus on any labral pathology and allow microfracturing for acetabular chondral damage. The limited arthrotomy approach will allow easy access to the pathologic part of the femoral head neck junction.

4.1 Surgical technique

Patient is positioned supine, exactly the same as described in previous section. After arthroscopic treatment of labral and chondral lesions, the traction is released. Anterior or anterolateral approach can be performed. We prefer a modified Watson-Jones approach, which allow better visualization of the anterolateral and posterolateral aspect of head neck junction. The 8-10 cm incision starts 2-3 cm distal and 2-3 cm lateral to the Anterior Superior Iliac Spine (ASIS) directed distally and laterally toward the anterior tip of GT. Subcutaneous dissection is carried down to the fascia lata. The interval between Tensor Fascia Lata (TFL) and Gluteus Medius (GM) muscles can be identified just anterior to the GT after incising the fascia. The GM is retracted posteriorly while the TFL is retracted anteromedially. The rectus femoris tendon is identified and the hip joint capsule exposed. A T-shaped capsulotomy is

performed with care to prevent injury of the labrum. Spiked tip retractors can be placed intracapsular anterior and posterior around the rim of the acetabulum which will allow safe dynamic assessment of the hip joint. We use a high-speed burr to resect the cam lesion on the anterolateral femoral neck then ensure effective resection by using intraoperative fluoroscopy and dynamic assessment of the hip joint. Removing all bone debris and minimizing muscle damage can play significant role in reducing the incidence of Heterotopic Ossification (HO). Capsular and fascia lata closure are performed at the end of the procedure.

4.2 Postoperative care

Weight bearing as tolerated is permitted early post operatively. Contact sport is not allowed for at least 2-3 months. Active and passive range of motion along with unrestricted strengthening is allowed. However, when rectus femoris tendon is violated, then restrictions will be applied on active straight leg raise (SLR) for 6 weeks. Subcutaneous low molecular weight heparin is given for 10 days.

4.3 Complications

1. Deep venous thromboses and thromboembolic disease.
2. Neurovascular injury.
3. Infection.
4. Femoral neck fracture.
5. HO.
6. Femoral head avascular necrosis (AVN)
7. Complications related to hip arthroscopy procedure.

4.4 Results

Lincoln et al reported a significant difference between the mean Harris hip score preoperatively and that at last follow-up (from 63.8 to 76.1) of 16 hips treated using a modified Heuter anterior approach combined with adjunctive hip arthroscopy.

Clohisey et al reported the results of combined arthroscopy and limited open osteochondroplasty for anterior FAI in 35 patients. HHS improved from 63.8 to 87.4 at minimum follow up of 2 years. No fracture of the femoral neck or AVN of the femoral head was reported[14].

Pierannunzii et al found that the mean HHS improved from 74.4 to 85.3 in 8 patients at mean follow up of 10 months[15].

5. Surgical dislocation of the hip joint

5.1 Indications

Surgical dislocation of the hip joint for the treatment of FAI is safe when performed with appropriate understanding of the vascular anatomy of the proximal femur. Surgical dislocation of the hip is considered the gold standard procedure for the treatment of FAI, despite the advance of hip arthroscopy technique and the encouraging results of the limited open surgical procedure. Surgical dislocation of the hip is especially indicated with global or posterior impingement requiring acetabular rim trimming, with severe deformity of the

proximal femur or when chondral lesions of the femoral head have to be addressed. Patient with no more than mild arthrosis (Tonnis ≤ 2) and age less than 50 years are considered the best candidates for such surgical intervention.

5.2 Contraindications

Advance arthrosis, is a contraindication for this procedure.

5.3 Surgical technique

The patient positioned in lateral decubitus under general or combined general and spinal anesthesia. The pelvis should be stabilized in proper orientation to allow proper evaluation of the acetabular version.

The incision is curvilinear, approximately 20-25 cm in length and centered over the GT curving slightly posteriorly at 20 degree angle. The fascia lata is incised and the interval between TFL and Gluteus Maximus (GMax) is developed to avoid violation of the GMax muscle fibers. The peritrochantric bursa is incised and retracted anteriorly. The greater trochanter, short external rotators, gluteus medius and vastus lateralis should be clearly visualized. The leg is positioned in 20-30 degrees of internal rotation and an oscillating saw is used to create a trigastrics sliding trochanteric osteotomy of 1-1.5cm thicknesses. Next the leg is repositioned in neutral rotation and the gluteus minimus is dissected off the hip capsule from posterior to anterior to allow full mobilization of the trochanteric fragment anteriorly for performing a safe Z-shape capsulotomy, the capsular incision starts at the anterior boarder of the GT and is directed proximally in line with the femoral neck with care

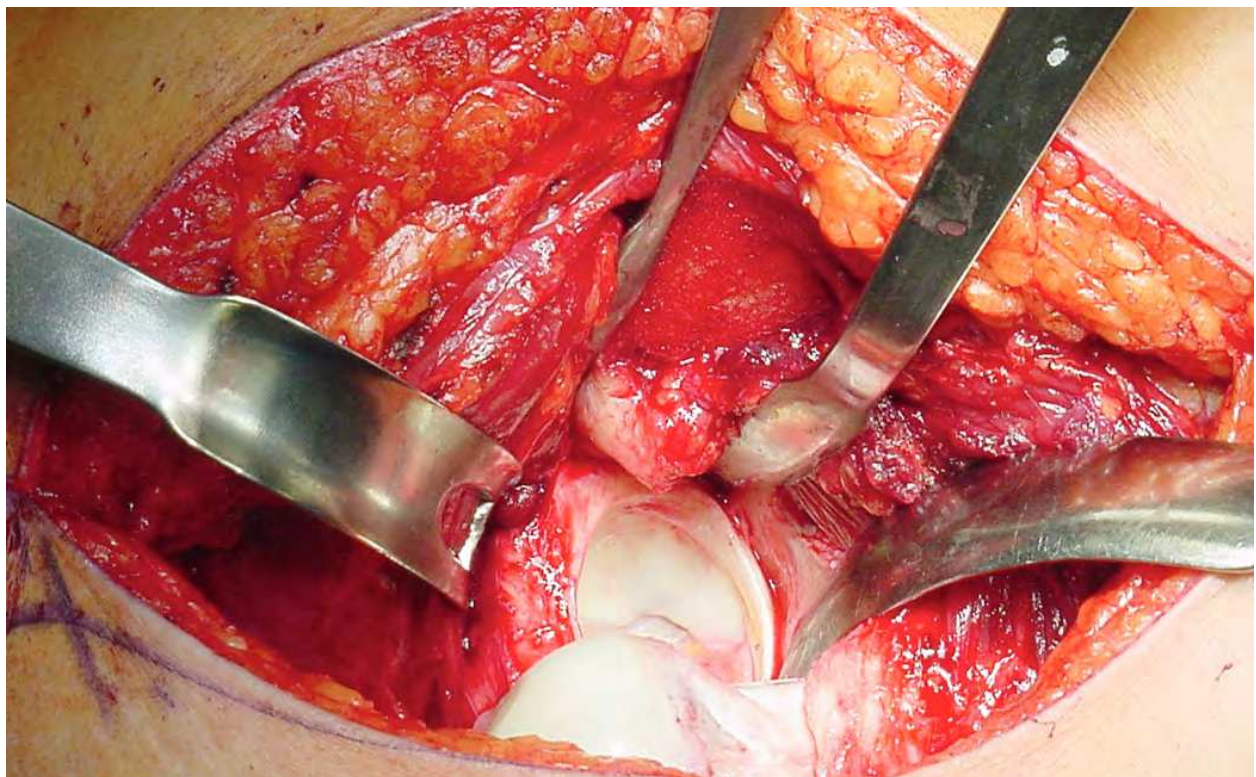


Fig. 6. 360 view provide inspection of the acetabulum, one retractor is impacted above the acetabulum. One retractor hooked on the anterior acetabular rim and a third retractor levers the neck against the incisura acetabuli.

not to injure the labrum. The proximal arm of the capsulotomy runs parallel to the acetabulum posteriorly toward the piriformis tendon, the closest the capsulotomy to the acetabular edge the less likely to risk injuring the lateral epiphyseal branches. The distal arm of the Z-shaped capsulotomy should not extend beyond the lesser trochanter. Distraction force with the use of bone hook with the hip in flexion and external rotation can help dislocating the femoral head. The ligamentum teres can prevent complete dislocation and a curved blunt tip long scissor should be used to cut the ligament if circumferential exposure of the femoral head is required. A straight spiked Hohmann retractor is placed anteriorly around the acetabular rim and a curved Hohmann is placed inferiorly under the transverse ligament to push the femoral head posteriorly. The leg is placed in a sterile bag anteriorly across the table. This will provide 360-degree acetabular exposure for cartilage defects treatment, acetabular rim trimming and labral re-fixation (Figure 6). To treat pathology on the femoral side, the retractors are removed and the head and neck are delivered back into the surgical wound for evaluation and treatment of any head cartilage defect and head-neck junction pathology (Figure 7).

When satisfactory treatment is completed, the femoral head is reduced and the capsule is closed with loose interrupted suture to prevent stretch of retinacular vessels. The greater trochanter fragment should be reduced and fixed with three 3.5mm screws. The fascia lata and overlying skin are closed in layers (Figure 8).

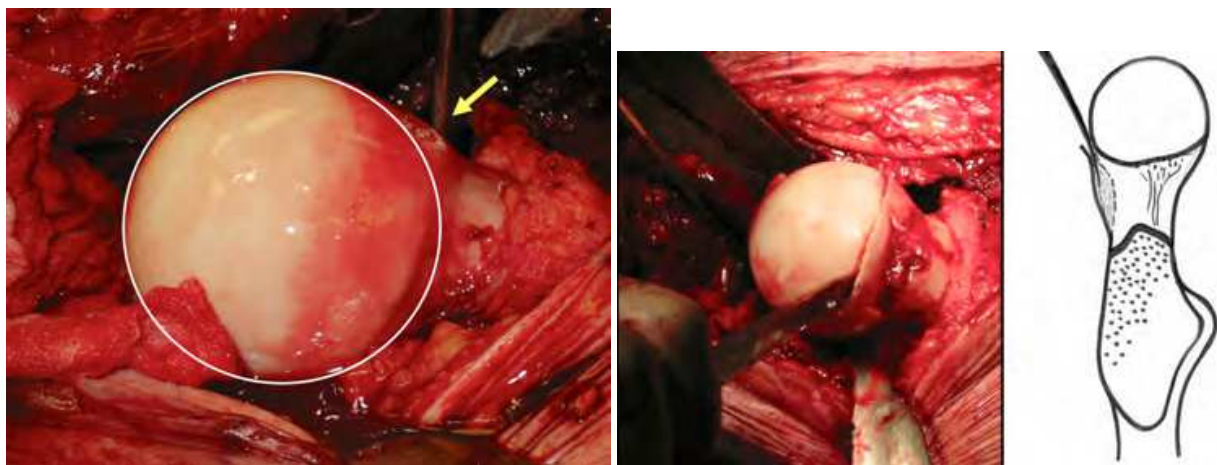


Fig. 7. The hip is flexed, externally rotated and distracted to dislocation of the femoral head. The cam lesion inspected and femoral neck osteoplasty is performed.

5.4 Postoperative care

Patient will be on DVT prophylaxis for 35 days and HO prophylaxis for 2 weeks (Celebrx 200mg twice a day). The patient will be allowed toe touch weight bearing for 6 weeks. Passive range of motion is allowed in all directions, however active abduction and deep flexion beyond 90 degree are not allowed for at least 6 weeks.

5.5 Complications

Complications of the surgical dislocation approach for patients who had had the procedure for multiple differential diagnoses (including Femoroacetabular impingement, Legg-Calve-Perthes disease in a skeletally mature hip, trauma, and deformity following a slipped capital

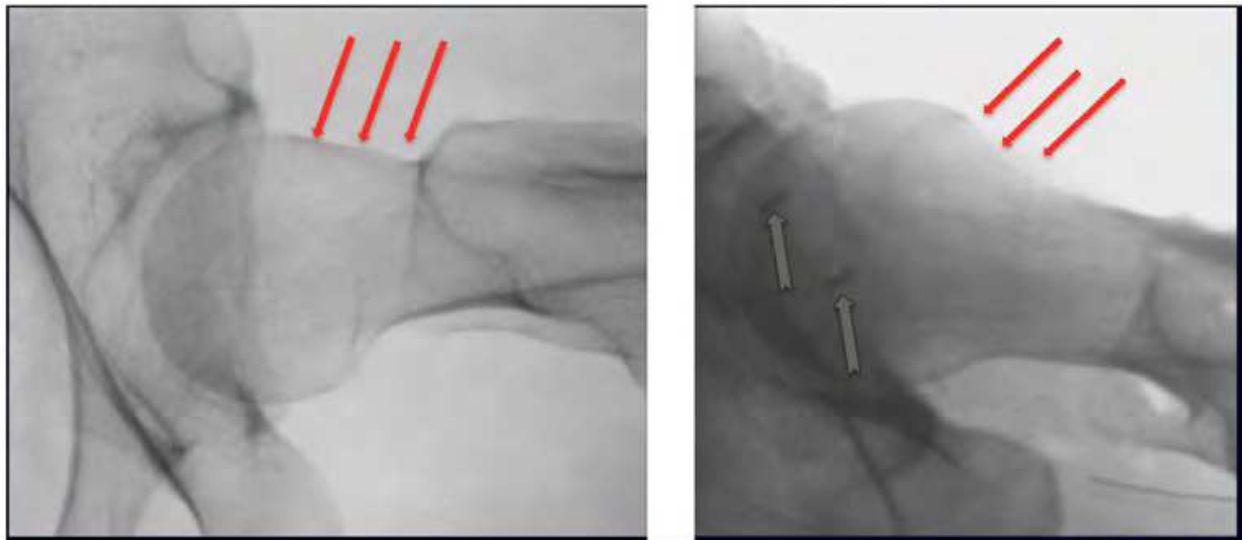


Fig. 8. Preoperative (left) and postoperative (right) lateral views of proximal femur and the acetabulum. Improved head neck offset after excision of the cam lesion. Notice the labral re-fixation after acetabuloplasty.

femoral epiphysis) were reported by different North American centers that participate in the ANCHOR (Academic Network for Conservational Hip Outcomes Research) group[16]. We listed all possible complications might be anticipated with this procedure, however ANCHOR have reported no cases of osteonecrosis, femoral neck fracture, or any complication leading to long-term morbidity, with the exception of the one sciatic nerve injury, which partially resolved.

1. DVT (0.5%)
2. Infection.
3. Neurovascular injury (permanent and complete major nerve palsy was not reported, however partial sciatic nerve palsy occur in one patient eventually recovered partially).
4. Heterotopic ossification (Brooke I & II 5.3%)[17].
5. Trochanteric fragment displacement and delay union (0.5% require no intervention), or nonunion (rate of 1.8 % that required refixation).
6. Femoral neck fracture
7. AVN
8. Hardware complications: breakage, irritation of surrounding soft tissue (trochanteric bursitis, psoas tendon when prominent medially).
9. Under-correction, or over correction of cam and pincer lesion.
10. Capsular adhesion.

5.6 Results

Retrospective reports demonstrate significant improvement in both radiographic and clinical functional scores.

Murphy et al reported on the surgical dislocation approach for FAI treatment in 23 patients with a mean follow up of 62 months. Preoperative hip scores of Merle d'Aubigné scale were average 13.2 (range, 11–15). THA was performed for 7 patients. Of the surviving 15 hips, the hip scores improved significantly to 16.9 ± 1.35 (range 13–18). No case of AVN was reported[18].

Likewise, Peters et al reported improvement in the mean Harris Hip Score from 70 points preoperatively to 87 points at the time of final follow-up in 29 patients [19].

Beaule et al reported the functional outcome of 34 patients (37 hip) following surgical dislocation to treat cam lesion with mean follow up period of 31.4 years. All activity and functional score demonstrated improved outcome (WOMAC score 61.2 to 81.4, UCLA activity scores 4.8 to 7.5, and mean SF-12 46.4 to 51.2). No osteonecrosis was reported and 9 patients required hardware removal [20].

Espinosa et al found less arthrosis at final follow up in 52 patients (60 hips) when labrum was refixed instead of removed after rim trimming for pincer type impingement. The recovery time and the final clinical and radiographic features favored labral re-fixation[21].

Beck et al reported the mid-term results of surgical dislocation of 19 hips and concluded that this procedure was not suitable for patient with advanced degenerative changes[22]. The same conclusion also reported by Murphy et al [18].

6. Periacetabular osteotomy

Developmental dysplasia of the hip can result in structural instability that exacerbates shearing forces across a limited acetabular cartilage surface area. Ultimately, the abnormal force distribution can result in rim failure and progressive degenerative hip disease[23].

The aim of periacetabular osteotomy is to change the acetabular cavity orientation, thus optimizing the joint mechanics through restoration of joint stability and transformation of *shearing forces* on an oblique acetabular roof to *compressive forces* on a reoriented horizontal acetabular roof.

It was found on long term radiographic follow up that patients with a Center Edge Angle (CEA) less than 16 degrees, acetabular index greater than 15 degrees and femoral head uncoverage more than 30% have higher incidence of osteoarthritis by age 60 [24].

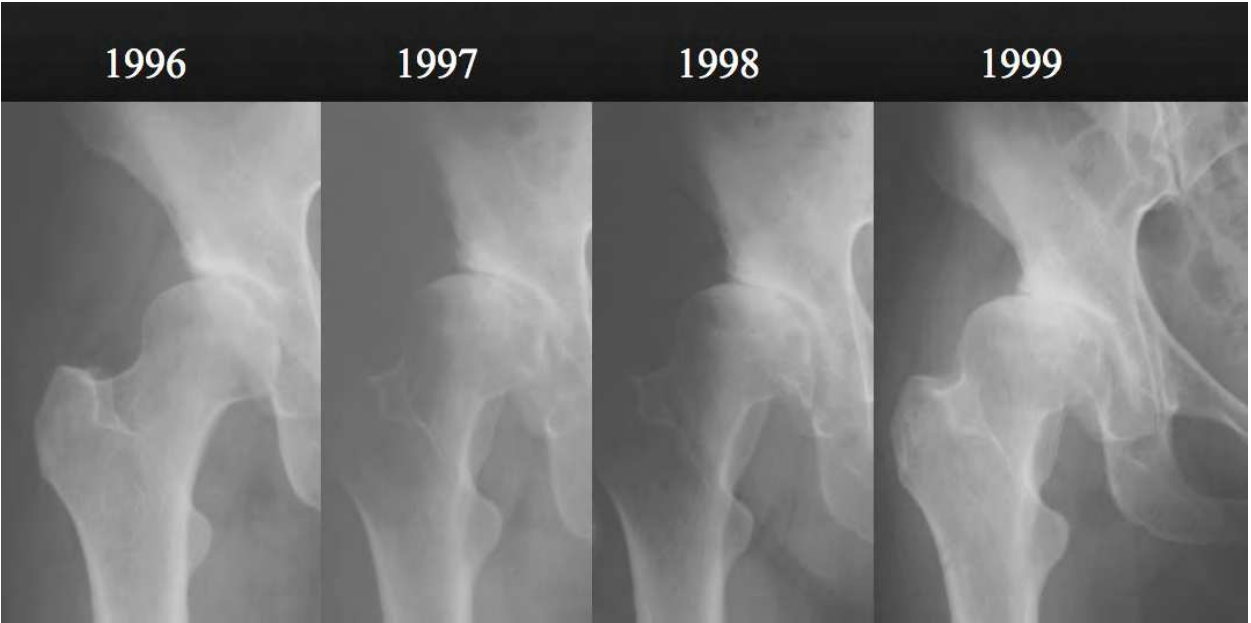


Fig. 9. Natural history of untreated acetabular dysplasia.

Various pelvic osteotomies were proposed to treat symptomatic hip dysplasia. Most of the techniques apply to the infant or adolescents. Salter innominate osteotomy has limited

degree of correction in adult hip dysplasia and it does not solve hip-center lateralization because the acetabular fragment rotation is hinged on a fixed point (symphysis pubis). Double and triple osteotomy provides more freedom for rotation of the osteotomized fragment but since the acetabular fragment is still attached to the sacropelvic ligament, only limited correction angle is possible. This angle of correction can be improved through placing the osteotomy closer to the acetabulum. One disadvantage of this type of osteotomy is the size of acetabular fragment that can cause pelvic narrowing and might interfere with future child bearing in female patient. Spherical periacetabular osteotomy is a highly demanding surgical procedure; it can improve acetabular coverage but can't improve hip-center lateralization because the medial acetabular wall is intact. The osteotomy passes close to the acetabulum capsular attachment, which is considered to be an important source of blood supply to the acetabular bone. Performing a capsulotomy to evaluate intra-articular structure at the remaining time of the osteotomy will jeopardize the acetabular blood supply[25].

Reinhold Ganz initially described Bernese Periacetabular Osteotomy (PAO)[26]. It became widely recognized as an effective osteotomy for the treatment of acetabular dysplasia. Through improved geometric cut around the acetabulum, the polygonal shape acetabular fragment can be reoriented to achieve almost unlimited femoral head coverage and acetabular version as well as allowing control of medialization of the hip-center when needed. The vascular anatomy around the acetabulum is preserved, which allows safe capsulotomy for simultaneous evaluation and treatment of intra-articular pathology.

6.1 Indications

The clinical uses of Bernese PAO in adult patient are indicated in the presence of the following situations:

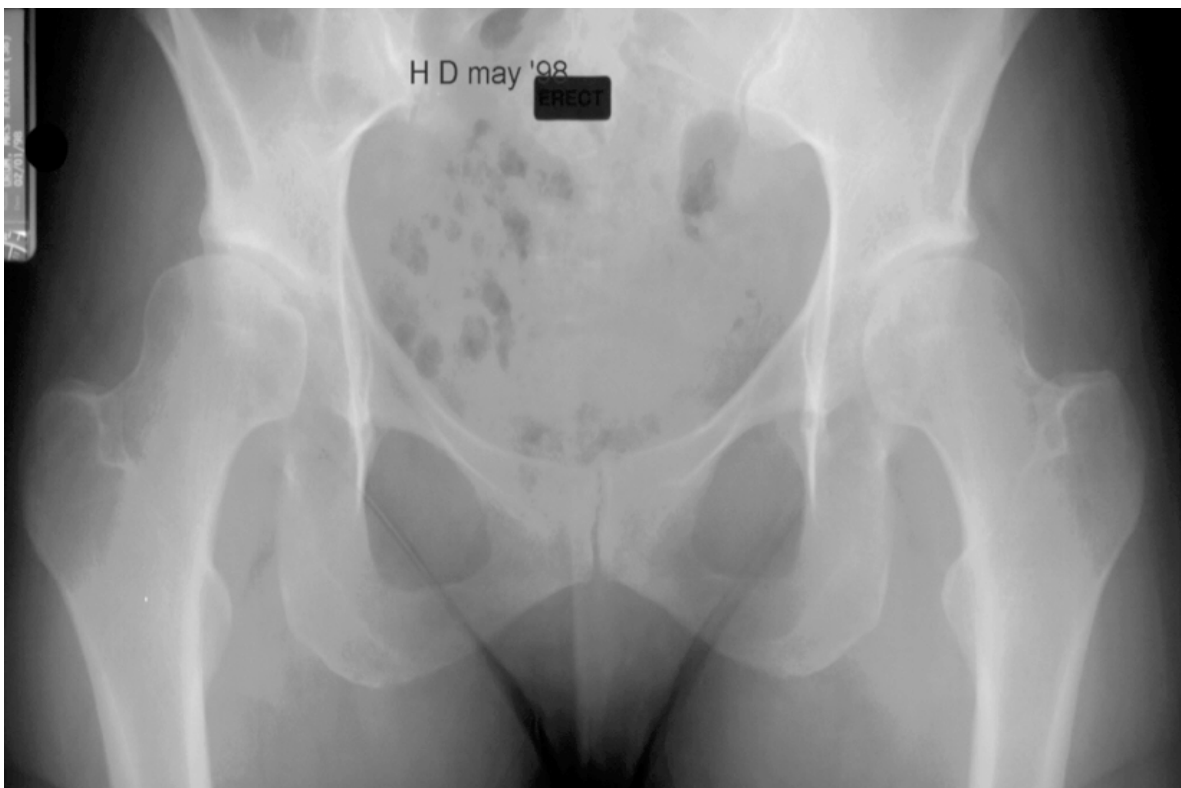

Fig. 10. Bilateral acetabular dysplasia in 17 years old patient.

1. Congruent and symptomatic early hip joint degenerative disease (Tonnis 1).
2. 20-30 degree of hip abduction range of motion.
3. Dysplastic acetabulum with
 - a. CEA <20 degree
 - b. Tonnis angle >10 degree
4. symptomatic acetabular retroversion without dysplasia can be an indication for PAO, it: Acetabular retroversion can be identified on a standard AP pelvis view (symmetrical obturator foramen and coccyx centered 2-3 cm above the symphysis pubis). The patient radiographic finding will be consistent with acetabulum retroversion if the hip center of rotation is lateral to posterior acetabular rim and the patient have both cross-over sign and ischeal spine sings[27, 28].

6.2 Contraindications

1. Open triradiate cartilage
2. Grade II Tonnis changes and more
3. Incongruent joint
4. Age over 40 has been associated with less favorable outcome in some studies[29, 30].

6.3 Surgical technique

Under general anesthesia, the patient is positioned supine and the limb on the dysplastic acetabulum side is prepped and draped free in sterile fashion. Antibiotics are given before incising the skin. A cell saver is used during this procedure.

A curvilinear incision is starting from the gluteal tubercle on the iliac crest and curved lateral to the ASIS distally for approximately 20 cm. Abdominal external oblique muscle is

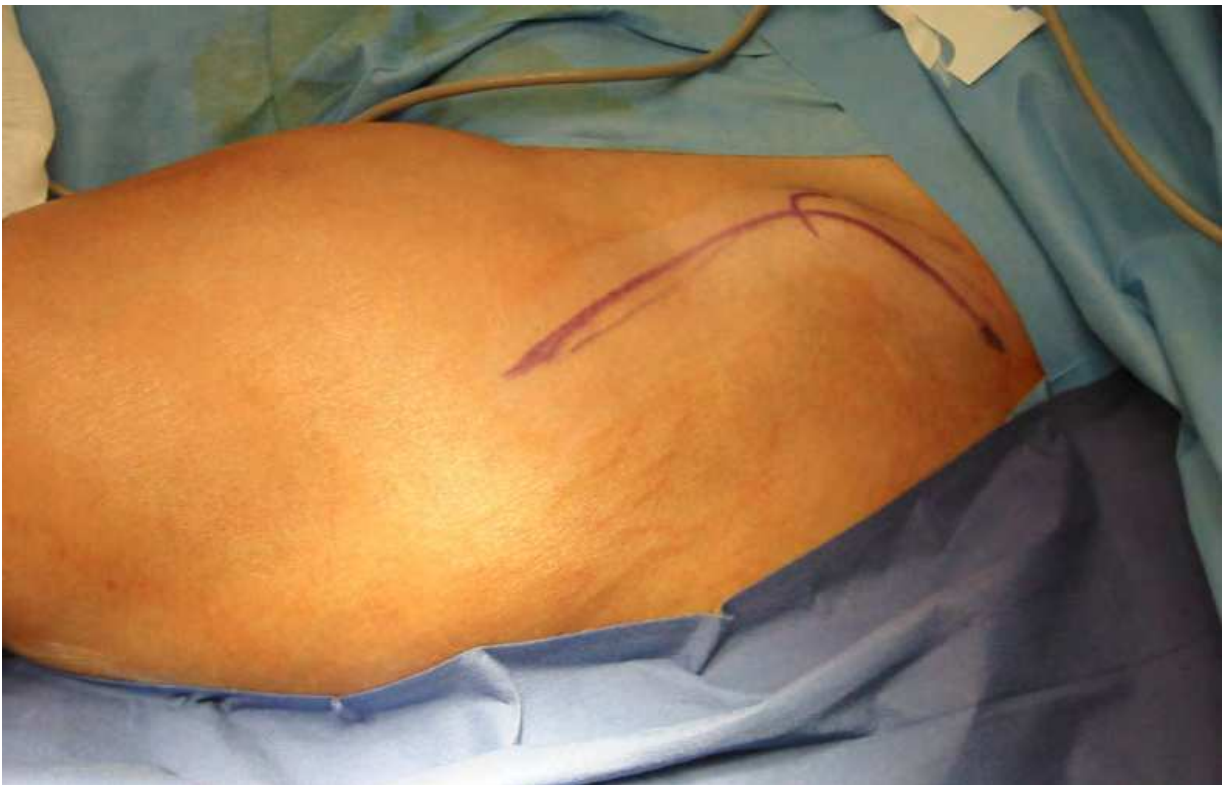

Fig. 11. Curvilinear incision for the anterior approach to perform PAO.

elevated off the internal iliac crest and the interval between TFL and the Sartorius is defined. The ASIS is osteotomized and retracted medially to expose the rectus femoris, which is released from the AIIS. The sartorius and rectus femoris are retracted medially and the TFL is retracted laterally. The iliopectineal muscle is elevated off the anterior capsule. A spiked Hohmann retractor can be slid over the superior pubic ramus 1.5 cm medial to iliopectineal eminence and serves to retract the medial soft tissue including the psoas and the neurovascular bundle. The medial capsular tissue is freed of soft tissue attachment using long blunt and curved scissors. This provides a window to reach the ischeal tubercle and infracotyloid region, which is also freed of soft tissue attachments.

Four bone cuts are performed to create a polygonal acetabular fragment:



Fig. 12. Polygonal cuts around the acetabulum.

1. Partial ischeal cut using curved Ganz osteotome (avoid sciatic nerve injury by abducting the hip joint)
2. Superior pubic ramus cut using straight osteotome starting medial to iliopectineal eminence (avoid penetrating the joint by aiming 45 degrees medial, away from the acetabulum).
3. Iliac bone cut starting just distal to ASIS toward greater sciatic notch using oscillating saw.
4. The posterior column cut is one centimeter thick and done using both straight and curved osteotome starting off the third cut end with an angle of approximately 120 degrees to join the first ischeal cut.

The acetabular fragment should be now free for re-orientation. We use two Schantz screws inserted in the acetabular fragment away from the zone of fixation to accomplish efficient orientation in both abduction and anteversion. Fluoroscopy is used to assess acetabulum version and orientation. The fragment can be allowed to rotate freely around the hip center of rotation. When the desired orientation is achieved, preliminary fixation is obtained with multiple Steinmann pins. True AP pelvic X-ray is done prior final fixation. Multiple screws are used to fix the acetabular fragment. The hip is then taken through full range of motion and if 90-degrees of flexion cannot be achieved, retroversion is corrected or a capsulotomy can be safely done to resolve any intra-articular pathology responsible for impingement.

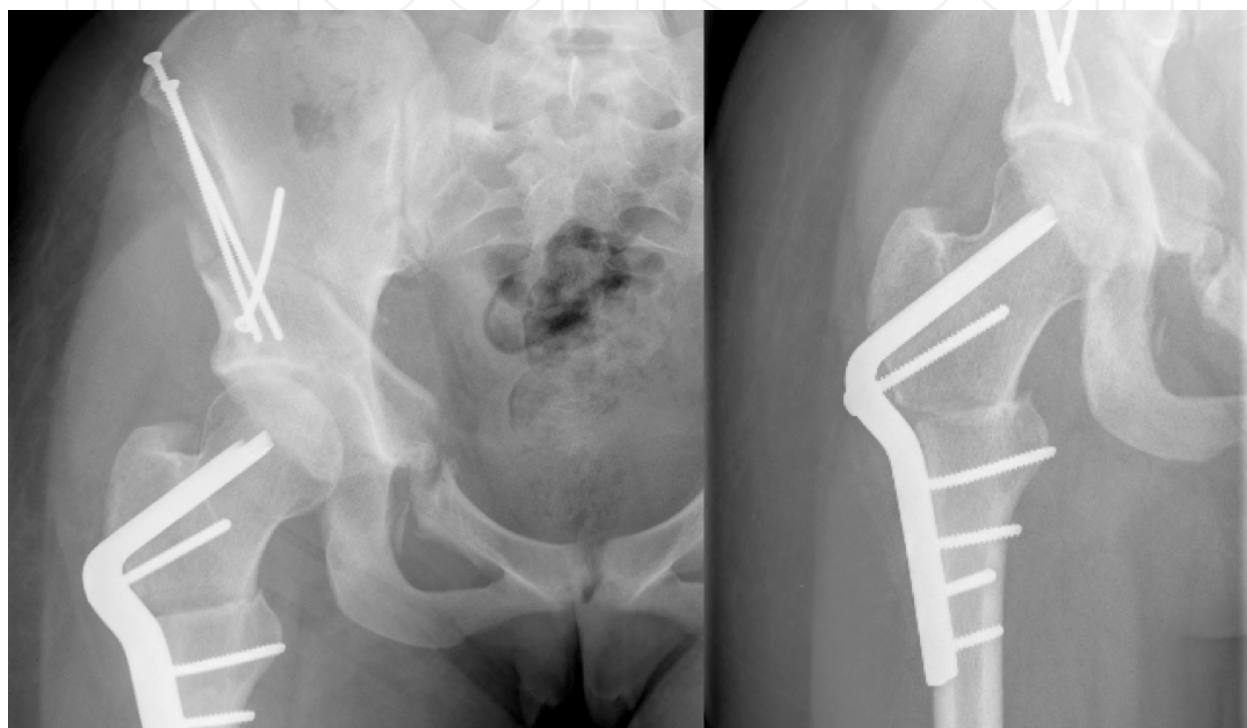


Fig. 13. Postoperative x-ray of the right hip for the same patient presented previously (figure 11) demonstrates combined PAO and proximal femoral osteotomy.

The rectus tendon is reattached to the AIIS using nonabsorbable suture transfixed through drill hole in the iliac bone. The ASIS is fixed with a screw or nonabsorbable suture drilled through the osteotomised fragment. A drain is left in place while closure is performed[31].

6.4 Postoperative care

Patients will be on DVT prophylaxis for 35 days. Non-weight bearing is indicated for 6 weeks, and then progressive weight bearing is started when radiographic evidence of healing of the osteotomy. Straight leg raising exercise is delayed for 6 weeks, and the hip joint can be taken through passive range of motion early postoperative.

6.5 Complications

Minor and major complications can occur when doing Bernese PAO. The complexity of the procedure combined with the surgeon learning curve can affect the overall outcome. It was observed that the major complication rate ranged from 6% to 37%[32]. There was a

statistically significant decrease in major complications from 17% to 2.9% when comparing the first 35 cases with the second 35 cases of periacetabular osteotomy performed by one surgeon[33].

The complications reported in literatures include:

1. *General surgical complications:* such as bleeding, DVT, infection and HO
2. *Technique-related complication:* include nerve traction injury to the femoral nerve. Lateral cutaneous nerves of the thigh are involved commonly but usually recover. Sciatic nerve injury is rare. Femoral artery injury or femoral vein thrombosis can occur.
3. *Acetabular-fragment related complications:* include fracture through the posterior column, intra-articular extension of the osteotomy, under or over correction. Delayed union can happen, but nonunion of the acetabular fragment is rare; although nonunion of the superior pubic ramus osteotomy tends to occur more frequently.
4. *Hardware complications:* include joint penetration, fixation failure secondary to broken or migrated screw. Prominent screw can rub against the surrounding tissue leading to painful bursitis.

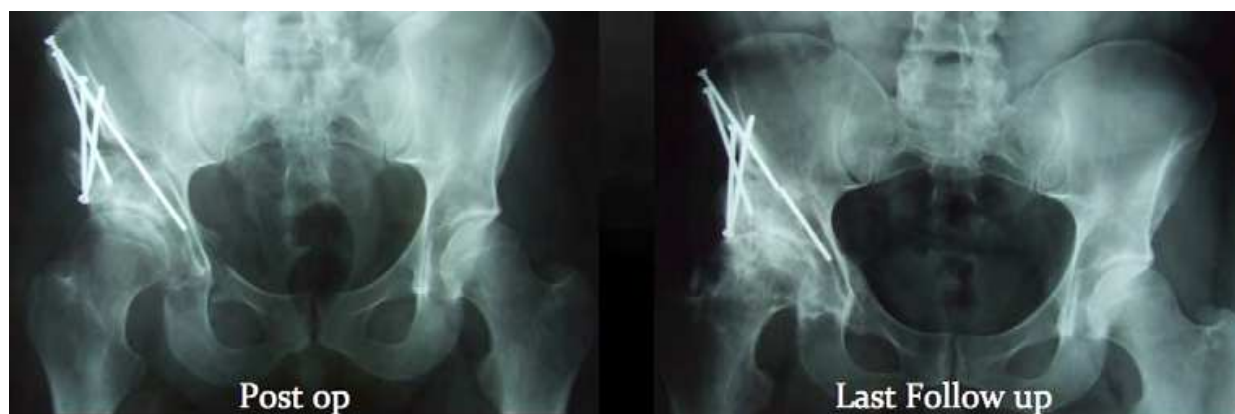

Fig. 14. Progressive degenerative changes lead to failure of PAO.

Ganz et al reported the need for removal of hardware in 17% and HO in 5%, however Trousdale et al reported 33% incidence of HO after PAO. The lateral femorocutaneous nerve is the most commonly injured (30%).[34-36]

6.6 Results

Clohisey et al has made a systematic review of the reported radiographic and clinical results of PAO based on the literatures published up to 2007 with certain inclusion criteria. There were 13 studies with a level of evidence that was generally low (IV). These data derived from various surgeons and institutions indicate PAO can reliably achieve deformity correction. All studies including clinical outcome analysis showed pain relief and improved hip function in the majority of patients at short to midterm follow up. In seven studies, there were correlated between suboptimal clinical results and advanced preoperative osteoarthritis. Failure of the osteotomy and the need to conversion to THA was noted in 0% to 17% of the cases [32].

7. Femoral osteotomy

Various proximal femoral osteotomies were described for different clinical indications. Intertrochanteric Osteotomy (ITO) may be used in adults, although the indications for ITO

nowadays are more limited due to the improved outcome of THA. ITO may be useful to provide containment, congruency, coverage or rotational re-alignment of the hip joint through valgus, varus, flexion, extension, rotation or combination of all of these osteotomies. Post-traumatic deformity, rotational malalignment of the lower extremity, coxa valga, slipped capital femoral epiphysis and Legg-Calvé-Perthes disease are clinical conditions where ITO is commonly used.

7.1 Contraindications

1. Advanced degenerative changes
2. Inflammatory arthritis
3. The impossibility of obtaining a congruent joint on functional radiographic views
4. Limited joint range of motion with marked hip stiffness
5. Other relative contra-indications are advanced age, tobacco smoking and morbid obesity.

7.2 Surgical technique

The pre-requisite for a successfully executed ITO is proper pre-operative planning, adequate range of motion and appropriate choice of the fixation device.

A direct lateral approach to the femur is used. The planned osteotomy is performed under fluoroscopic assistance and defined with Steinman pins. A blade plate is used for fixation and the corresponding chisel is inserted in the desired position. The osteotomy is performed with an oscillating saw and can be fixed under compression with a blade plate or condylar plate.

7.3 Postoperative care

DVT prophylaxis is given for 2 weeks, and weight-bearing protection should be respected for 2 months. Passive and active ranges of motion are permitted.

7.4 Postoperative complications

In addition to common surgical complications, AVN and delayed union or non-union of the osteotomy can occur. Over correction or under correction can be a source of patient dissatisfaction. Hardware failure or soft tissue irritation might require removal after fracture healing.

7.5 Results

Multiple clinical studies on the use of proximal femoral osteotomy are reported in the literatures. Haverkamp et al reported the results of 276 patients that had ITO for various indications. The best clinical results at 10 years were achieved when the osteotomy was performed in young patient with posttraumatic deformity (90% success rate at 10 years). Arthritic changes in association with an idiopathic etiology had the worst results with only 50% success rate at final follow up[37].

8. Salvage procedure for degenerative hip joint pain

Salvage surgery, including the Chiari osteotomy and shelf procedures; do not provide coverage of the femoral head by a surface of hyaline cartilage. The hip capsule is interposed between newly formed acetabular roof and femoral head.

- *Chiari Pelvic Osteotomy*: Chiari medial displacement pelvic osteotomy may be used to treat degenerative hip pain in young patient with incongruent hip joint. The osteotomy is performed at 15 degrees superior inclination within the supracetabular iliac bone and the hip joint is displaced medially to improve superior coverage of the femoral head. Excessively low or too high osteotomy cut can give suboptimal clinical result. Sufficient acetabular fragment medial displacement is critical to provide enough femoral head coverage. The superior capsule is used as the articular surface under the displaced ilium. The posteroinferior aspect of the hip is spared from disease, as seen on the false-profile roentgenogram, and a reconstructive osteotomy can be performed. Furthermore anterior coverage of the head is difficult to obtain with a medial displacement osteotomy. This procedure relies on fibrocartilage metaplasia of the capsule, results in lower functional outcome compared to other periacetabular osteotomies or THA. One advantage of this type of osteotomy is improving future acetabular component bone fixation[38].
- *Shelf Procedure*: Placing a bone graft in the superolateral region of the acetabulum as a shelf can provide containment and coverage of the femoral head, thus preventing lateral or upward migration of the femoral head. The shelf procedure provides greater lateral coverage but the original steep inclination of the acetabulum persists. The technique can be used as a supplemental procedure with other type of osteotomy and can be performed with a limited incision technique[39].

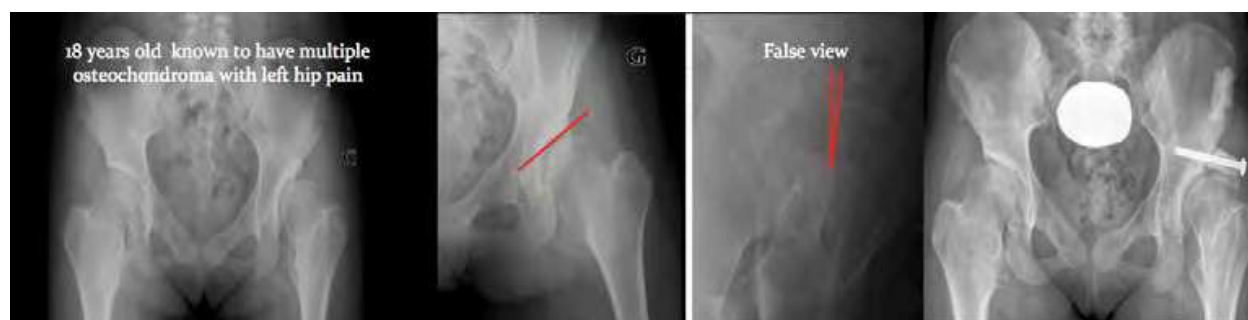

Fig. 15. Shelf procedure.

8.1 Hip fusion (arthrodesis)

Young patients with advanced unilateral degenerative hip changes, secondary to trauma or septic conditions are good candidate for hip fusion. Hip arthrodesis provides better clinical results in young (less than 35) active patient with normal contralateral hip, no pathology in the ipsilateral knee or lower spine and when the hip fusion technique preserves the abductor muscles integrity. Although a valuable option, it has many drawbacks including loss of motion, shortening of the extremity, increased expenditure of energy during walking, and increased stress on the low back and the ipsilateral knee[40].

Several techniques have been described. The femoral head and the acetabulum are denuded of cartilage and the hip is positioned in approximately 30 degrees of flexion, 0 to 5 degrees of adduction and 10 degrees of external rotation. The fixation can be intra articular (screws through the femoral head to the iliac bone), or extra articular (side plate, cobra plate, anterior plate). A trochanteric osteotomy is advisable to preserve the abductor function for future conversion of hip fusion to THA when side plate or cobra plate is used.

The reported clinical results of THA after hip fusion demonstrate a wide spectrum of clinical outcome. Hamadouche et al studies 45 THA performed after hip fusion at a mean follow up of 8.5 years. He reported 91% survival with walking improvement up to 2-3 years after surgery, however, 50% of patients required a cane for walking[41]. Joshi et al found that 79% of the patients had minimal pain with a 96% 10 years survival. The complications reported for the 208 fused hips converted to THA were 8 sciatic nerve and 7 femoral nerve palsies, 28 cases of HO, 5 dislocations and 3 infections[42].

9. Resection arthroplasty

Gathome Girdlestone described the surgical technique of resection arthroplasty of the hip joint to palliate hip condition secondary to chronic infection (i.e. tuberculosis hip infection). This procedure has been widely used to relieve pain or to improve the hip range of motion in conditions such as advanced hip degeneration and chronic hip joint infection. Improvement in the treatment of infection, fracture fixation technique and the introduction of prosthetic hip replacement has significantly limited the role of hip resection arthroplasty. The current indications for resection arthroplasty are nonambulatory patient with significant cognitive or neuromuscular condition or patient with chronic prosthesis infection and significant comorbidity that cannot go through complex surgical procedure. After the Girdlestone procedure, patients have significant functional limitations secondary to weak abductor and limb length inequality[43].

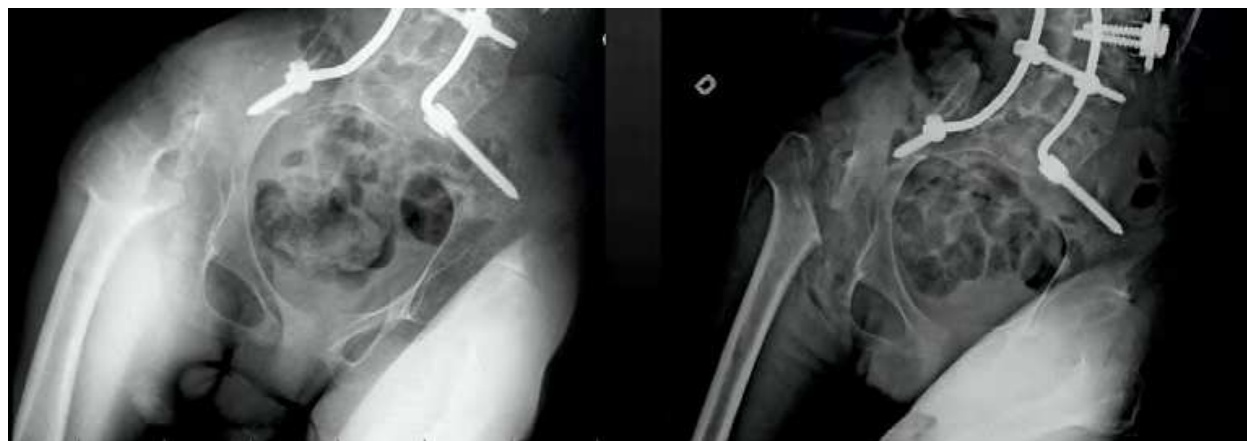

Fig. 16. 21 years old male patient (cerebral palsy patient), his health care provider notice increasing difficulty with perineal hygiene and increasing irritability when diaper changes are attempted. Intertrochanteric resection was performed to improve his hip range of motion and to alleviate his symptoms.

10. Summary

Non-arthroplasty surgical options for treating painful degenerative hip joint conditions are well established surgical procedures. Patient selection and proper preoperative evaluation is critical for successful long-term result. Understanding the indications and the contraindications as well as the limitations and the expected outcome of each procedure is critical during pre operative counseling of the patient about nonarthroplasty surgical option.

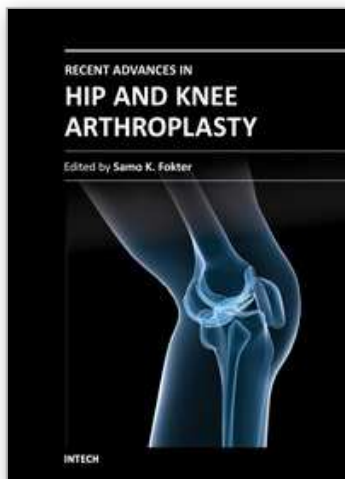
11. References

- [1] Sochart, D.H. and M.L. Porter, *The long-term results of Charnley low-friction arthroplasty in young patients who have congenital dislocation, degenerative osteoarthritis, or rheumatoid arthritis*. J Bone Joint Surg Am, 1997. 79(11): p. 1599-617.
- [2] Dooley, P.J., *Femoroacetabular impingement syndrome: Nonarthritic hip pain in young adults*. Can Fam Physician, 2008. 54(1): p. 42-7.
- [3] Van Iersel, M. and G. Mulley, *What is a waddling gait?* Disability & Rehabilitation, 2004. 26(11): p. 678-82.
- [4] Clohisy, J.C., et al., *A systematic approach to the plain radiographic evaluation of the young adult hip*. J Bone Joint Surg Am, 2008. 90 Suppl 4: p. 47-66.
- [5] Notzli, H.P., et al., *The contour of the femoral head-neck junction as a predictor for the risk of anterior impingement*. Journal of Bone & Joint Surgery - British Volume, 2002. 84(4): p. 556-60.
- [6] De Pellegrin, M.P., W.G. Mackenzie, and H.T. Harcke, *Ultrasonographic evaluation of hip morphology in osteochondrodysplasias*. Journal of Pediatric Orthopedics, 2000. 20(5): p. 588-93.
- [7] Beck, M., et al., *Hip morphology influences the pattern of damage to the acetabular cartilage: femoroacetabular impingement as a cause of early osteoarthritis of the hip*. Journal of Bone & Joint Surgery - British Volume, 2005. 87(7): p. 1012-8.
- [8] McCarthy, J.C. and J.A. Lee, *Hip arthroscopy: indications, outcomes, and complications*. Instructional Course Lectures, 2006. 55: p. 301-8.
- [9] Salvo, J.P., C.R. Troxell, and D.P. Duggan, *Incidence of venous thromboembolic disease following hip arthroscopy*. Orthopedics, 2010. 33(9): p. 664.
- [10] Philippon, M., et al., *Femoroacetabular impingement in 45 professional athletes: associated pathologies and return to sport following arthroscopic decompression*. Knee Surg Sports Traumatol Arthrosc, 2007. 15(7): p. 908-14.
- [11] Sampson, T.G., *Arthroscopic treatment of femoroacetabular impingement: a proposed technique with clinical experience*. Instr Course Lect, 2006. 55: p. 337-46.
- [12] Byrd, J.W. and K.S. Jones, *Arthroscopic femoroplasty in the management of cam-type femoroacetabular impingement*. Clin Orthop Relat Res, 2009. 467(3): p. 739-46.
- [13] Philippon, M.J., et al., *Outcomes following hip arthroscopy for femoroacetabular impingement with associated chondrolabral dysfunction: minimum two-year follow-up*. J Bone Joint Surg Br, 2009. 91(1): p. 16-23.
- [14] Clohisy, J.C., et al., *Combined hip arthroscopy and limited open osteochondroplasty for anterior femoroacetabular impingement*. J Bone Joint Surg Am, 2010. 92(8): p. 1697-706.
- [15] Pierannunzii, L. and M. d'Imporzano, *Treatment of femoroacetabular impingement: a modified resection osteoplasty technique through an anterior approach*. Orthopedics, 2007. 30(2): p. 96-102.
- [16] Sink, E.L., et al., *Multicenter Study of Complications Following Surgical Dislocation of the Hip*. J Bone Joint Surg Am, 2011.
- [17] Brooker, A.F., et al., *Ectopic ossification following total hip replacement. Incidence and a method of classification*. J Bone Joint Surg Am, 1973. 55(8): p. 1629-32.
- [18] Murphy, S., et al., *Debridement of the adult hip for femoroacetabular impingement: indications and preliminary clinical results*. Clin Orthop Relat Res, 2004(429): p. 178-81.

- [19] Peters, C.L. and J.A. Erickson, Treatment of femoro-acetabular impingement with surgical dislocation and debridement in young adults. *J Bone Joint Surg Am*, 2006. 88(8): p. 1735-41.
- [20] Beaulé, P.E., M.J. Le Duff, and E. Zaragoza, Quality of life following femoral head-neck osteochondroplasty for femoroacetabular impingement. *J Bone Joint Surg Am*, 2007. 89(4): p. 773-9.
- [21] Espinosa, N., et al., Treatment of femoro-acetabular impingement: preliminary results of labral refixation. *J Bone Joint Surg Am*, 2006. 88(5): p. 925-35.
- [22] Beck, M., et al., Anterior femoroacetabular impingement: part II. Midterm results of surgical treatment. *Clin Orthop Relat Res*, 2004(418): p. 67-73.
- [23] Klaue, K., C.W. Durnin, and R. Ganz, *The acetabular rim syndrome. A clinical presentation of dysplasia of the hip*. *Journal of Bone & Joint Surgery - British Volume*, 1991. 73(3): p. 423-9.
- [24] Murphy, S.B., R. Ganz, and M.E. Muller, *The prognosis in untreated dysplasia of the hip. A study of radiographic factors that predict the outcome*. *Journal of Bone & Joint Surgery - American Volume*, 1995. 77(7): p. 985-9.
- [25] Schramm, M., et al., *The Wagner spherical osteotomy of the acetabulum. Surgical technique*. *Journal of Bone & Joint Surgery - American Volume*, 2004. 86-A Suppl 1: p. 73-80.
- [26] Ganz, R., et al., A new periacetabular osteotomy for the treatment of hip dysplasias. Technique and preliminary results. *Clin Orthop Relat Res*, 1988(232): p. 26-36.
- [27] Reynolds, D., J. Lucas, and K. Klaue, *Retroversion of the acetabulum. A cause of hip pain*. *Journal of Bone & Joint Surgery - British Volume*, 1999. 81(2): p. 281-8.
- [28] Jamali, A.A., et al., Anteroposterior pelvic radiographs to assess acetabular retroversion: high validity of the "cross-over-sign". *Journal of Orthopaedic Research*, 2007. 25(6): p. 758-65.
- [29] Matheney, T., et al., Intermediate to long-term results following the Bernese periacetabular osteotomy and predictors of clinical outcome. *J Bone Joint Surg Am*, 2009. 91(9): p. 2113-23.
- [30] Garbuz, D.S., M.A. Awwad, and C.P. Duncan, *Periacetabular osteotomy and total hip arthroplasty in patients older than 40 years*. *Journal of Arthroplasty*, 2008. 23(7): p. 960-3.
- [31] Matheney, T., et al., Intermediate to long-term results following the bernese periacetabular osteotomy and predictors of clinical outcome: surgical technique. *J Bone Joint Surg Am*, 2010. 92 Suppl 1 Pt 2: p. 115-29.
- [32] Clohisy, J.C., et al., *Periacetabular osteotomy: a systematic literature review*. *Clin Orthop Relat Res*, 2009. 467(8): p. 2041-52.
- [33] Davey, J.P. and R.F. Santore, *Complications of periacetabular osteotomy*. *Clin Orthop Relat Res*, 1999(363): p. 33-7.
- [34] Ganz, R., et al., A new periacetabular osteotomy for the treatment of hip dysplasias. Technique and preliminary results. *Clinical Orthopaedics & Related Research*, 1988(232): p. 26-36.
- [35] Trousdale, R.T., et al., Periacetabular and intertrochanteric osteotomy for the treatment of osteoarthritis in dysplastic hips. *J Bone Joint Surg Am*, 1995. 77(1): p. 73-85.
- [36] Peters, C.L., J.A. Erickson, and J.L. Hines, Early results of the Bernese periacetabular osteotomy: the learning curve at an academic medical center. *J Bone Joint Surg Am*, 2006. 88(9): p. 1920-6.

- [37] Haverkamp, D. and R.K. Marti, Intertrochanteric osteotomy combined with acetabular shelfplasty in young patients with severe deformity of the femoral head and secondary osteoarthritis. A long-term follow-up study. *J Bone Joint Surg Br*, 2005. 87(1): p. 25-31.
- [38] Chiari, K., *Medial displacement osteotomy of the pelvis*. *Clin Orthop Relat Res*, 1974(98): p. 55-71.
- [39] Love, B.R., P.M. Stevens, and P.F. Williams, *A long-term review of shelf arthroplasty*. *J Bone Joint Surg Br*, 1980. 62(3): p. 321-5.
- [40] Callaghan, J.J., R.A. Brand, and D.R. Pedersen, *Hip arthrodesis. A long-term follow-up*. *Journal of Bone & Joint Surgery - American Volume*, 1985. 67(9): p. 1328-35.
- [41] Hamadouche, M., et al., Total hip arthroplasty for the treatment of ankylosed hips : a five to twenty-one-year follow-up study. *J Bone Joint Surg Am*, 2001. 83-A(7): p. 992-8.
- [42] Joshi, A.B., et al., *Conversion of a fused hip to total hip arthroplasty*. *J Bone Joint Surg Am*, 2002. 84-A(8): p. 1335-41.
- [43] Bittar, E.S. and W. Petty, *Girdlestone arthroplasty for infected total hip arthroplasty*. *Clin Orthop Relat Res*, 1982(170): p. 83-7.

IntechOpen



Recent Advances in Hip and Knee Arthroplasty

Edited by Dr. Samo Fokter

ISBN 978-953-307-841-0

Hard cover, 452 pages

Publisher InTech

Published online 27, January, 2012

Published in print edition January, 2012

The purpose of this book is to offer an exhaustive overview of the recent insights into the state-of-the-art in most performed arthroplasties of large joints of lower extremities. The treatment options in degenerative joint disease have evolved very quickly. Many surgical procedures are quite different today than they were only five years ago. In an effort to be comprehensive, this book addresses hip arthroplasty with special emphasis on evolving minimally invasive surgical techniques. Some challenging topics in hip arthroplasty are covered in an additional section. Particular attention is given to different designs of knee endoprostheses and soft tissue balance. Special situations in knee arthroplasty are covered in a special section. Recent advances in computer technology created the possibility for the routine use of navigation in knee arthroplasty and this remarkable success is covered in depth as well. Each chapter includes current philosophies, techniques, and an extensive review of the literature.

How to reference

In order to correctly reference this scholarly work, feel free to copy and paste the following:

Ahmed Alghamdi and Martin Lavigne (2012). Degenerative Hip Joint Pain – The Non-Arthroplasty Surgical Options, Recent Advances in Hip and Knee Arthroplasty, Dr. Samo Fokter (Ed.), ISBN: 978-953-307-841-0, InTech, Available from: <http://www.intechopen.com/books/recent-advances-in-hip-and-knee-arthroplasty/degenerative-hip-joint-pain-the-non-arthroplasty-surgical-options>

INTECH
open science | open minds

InTech Europe

University Campus STeP Ri
Slavka Krautzeka 83/A
51000 Rijeka, Croatia
Phone: +385 (51) 770 447
Fax: +385 (51) 686 166
www.intechopen.com

InTech China

Unit 405, Office Block, Hotel Equatorial Shanghai
No.65, Yan An Road (West), Shanghai, 200040, China
中国上海市延安西路65号上海国际贵都大饭店办公楼405单元
Phone: +86-21-62489820
Fax: +86-21-62489821

© 2012 The Author(s). Licensee IntechOpen. This is an open access article distributed under the terms of the [Creative Commons Attribution 3.0 License](https://creativecommons.org/licenses/by/3.0/), which permits unrestricted use, distribution, and reproduction in any medium, provided the original work is properly cited.

IntechOpen

IntechOpen