

We are IntechOpen, the world's leading publisher of Open Access books Built by scientists, for scientists

6,900

Open access books available

186,000

International authors and editors

200M

Downloads

Our authors are among the

154

Countries delivered to

TOP 1%

most cited scientists

12.2%

Contributors from top 500 universities



WEB OF SCIENCE™

Selection of our books indexed in the Book Citation Index
in Web of Science™ Core Collection (BKCI)

Interested in publishing with us?
Contact book.department@intechopen.com

Numbers displayed above are based on latest data collected.
For more information visit www.intechopen.com



Development of Proprioception After Shoulder Arthroplasty

Michael W. Maier¹ and Philip Kasten²

¹*Department of Orthopedics, Trauma Surgery and Paraplegiology,
University of Heidelberg, Heidelberg*

²*Carl-Gustav Carus University of Dresden, Dresden
Germany*

1. Introduction

Since the introduction of shoulder arthroplasty in 1893 by the French surgeon Jule-Émile Péan [18], the indications for shoulder replacement have expanded. Today shoulder arthroplasty is a common treatment for glenohumeral osteoarthritis [2]. Shoulder arthroplasty can significantly improve the function of osteoarthritic shoulders [7, 13, 19, 27]. Comparing the results, TSR offers better short- and mid-term results, but has the risk of long-term problems as the glenoid loosening [2]. In our practice patients with glenohumeral osteoarthritis will receive a total shoulder arthroplasty. As an exception patients with osteoarthritis which is limited to the humeral head without eccentric erosion of a stable sclerotic glenoid (Typ A1 glenoid according to Walch [28]) can be treated with hemiarthroplasty (HA). If the glenoid shows eccentric posterior wear ($> A1$), a TSR is recommended.

The use of total shoulder replacement in the setting of rotator cuff-tear arthropathy (CTA) has led to poor outcomes because of early glenoid implant failure [17]. These failures were the result of early glenoid loosening caused by altered biomechanics in the cuff-deficient shoulder. The treatment of choice for most used to be hemiarthroplasty. Although good relief from pain has usually been obtained, most patients with CTA and subsequent hemiarthroplasty had a limited range of movement, leading to difficulties with the activities of daily living. These poor results led to the development of the reverse shoulder prosthesis, as a new method for treating CTA. Using the reverse prosthesis in CTA, favorable outcomes have been reported [15, 17].

In order to use the replaced shoulder for ADLs the concerted function of the active stabilizers and the passive restraints of the replaced shoulder joint is necessary.

2. Shoulder proprioception

In 1906, Charles Scott Sherrington published his work about proprioception [26]. He defined the term proprioception as the awareness of movement derived from muscular, tendon, and articular sources. Since then physiologists and anatomists are searching for specialized nerve endings that transmit data on joint capsule and muscle tension [11, 30]. It is known that joint proprioception plays a considerable role in stabilization of the normal healthy

shoulder by helping to control muscular action [1]. However, there is little data available about proprioception of the replaced shoulder before and after surgery [6, 12, 16]. Parameters routinely examined in previous studies include pain, satisfaction, range of motion, and strength [5].

3. Proprioception after shoulder arthroplasty

By reason that the shoulder joint is balanced and centered by the rotator cuff and the glenohumeral ligaments, it can be postulated that proprioception plays an important role in the postoperative outcome and rehabilitation. However, to date there are only three studies analyzing proprioception after shoulder replacement [6, 12, 16]. Two of these studies [6, 12] have a short follow-up period, in both cases six months. Cuomo et al. [6] performed a passive and guided angle-reproduction test in 20 patients with shoulder osteoarthritis before and six months after total shoulder arthroplasty (TSA) with only one degree of freedom at a time and reported improvement of proprioception [6]. Kasten et al. [12] found out, six months after shoulder arthroplasty, proprioception remained unchanged or deteriorated, as assessed by an active and unlimited angle-reproduction test with 3D motion analysis [12]. It was assumed that this finding was most likely attributable to the relatively short rehabilitation period of six months. Therefore, the purpose of the third study by Maier et al. [16] was to examine the patients from the study described by Kasten et al. [12, 14] again three years postoperatively to find out whether proprioception changes after a longer rehabilitation period of three years. In the present study, the same active and unlimited angle-reproduction test with 3D motion analysis was used as described before [12]. The present study firstly describes the results of proprioception development in a cohort of different shoulder arthroplasties, including patients with reverse prosthesis.

4. Measurement of proprioception

Because proprioception is a complex system that relies on central integration of various afferent and efferent elements, it is difficult to measure proprioceptive performance. Up to now, there is no consensus on how proprioception should be measured because the different components of proprioception are difficult to examine at the same time. For clinical purposes, most authors differentiate between static proprioception and dynamic proprioception [21]. Static proprioception is usually defined as the position sense, what means conscious perception of the orientation of different parts of the body with respect to another. Dynamic proprioception is defined as kinesthesia and the sense of rates of movement [11].

4.1 Joint angle analysis with the Heidelberg Upper Extremity Model (HUX)

In our studies [12, 16], we used the Heidelberg Upper Extremity Model (HUX) to measure joint angles as described before [23]: Therefore a twelve-camera motion analysis system (Vicon 612; Vicon, Lake Forest, USA) working at 120 Hz was used to monitor the patients' movements. The spatial resolution of the system was approximately 1 mm. The underlying model consisted of seven segments: thorax, clavicles, upper arms, and forearms. The sternoclavicular joint and the glenohumeral joint were treated as a ball-and-socket joint, whereas the elbow was treated as a hinge joint. Translational degrees of freedom were not considered in any of these joints.

For the measurement, the patients were prepared with four markers placed on the trunk as recommended by the International Society of Biomechanics [31]. Four markers were placed on each forearm: one at the radial and one at the ulnar styloid process of the wrist and two, connected with a wand, on the ulna close to the elbow joint. One marker was placed laterally on the upper arm and one on the acromion. After a static trial, the patient was asked to perform isolated movements of elbow flexion/ extension, shoulder flexion/ extension and shoulder abduction/ adduction to determine the shoulder joint position and the location of the elbow joint axis. Specifically, in these shoulder calibration trials the sternoclavicular joint was treated as a cardan joint. Technical coordinate systems for the ulna/ forearm, humerus, clavicle, and thorax were not deduced by optimization methods as was done for marker clusters [3]. Instead, they were based directly on marker trajectories, i.e. the direction vectors between them, using cross-products as reviewed by Chiari et al. [4]. The technical coordinate system of the clavicle was based on the four thorax markers and the shoulder marker. This coordinate system was used only for dynamic calibration movements, which were limited to a range of shoulder motion of 0-40° flexion and abduction to assume constant glenohumeral movement and exclude skin motion artefacts. Constraint least squares optimization according to Gamage et al. was then used for joint centre determination [9].

The anatomical co-ordinate system for the ulna/ forearm, humerus, and thorax were based on the technical coordinate systems of these segments and on the joint axes and joint centers previously determined. A static trial was used to define the neutral position of the thorax. Angles of flexion and abduction were expressed as projection angles relative to the proximal anatomical coordinate system, while internal/ external rotation was defined according to the globe convention [8]. Elbow flexion was defined as the projected angle to the elbow axis. Custom software written in Java (Sun Microsystems, USA) was used to calculate each joint angle in each trial of the angle-reproduction tasks.

The system and biomechanical model was validated with the manual goniometer and intraclass correlation coefficients of 0.989 for intrasubject variability, 0.996 for intersubject variability, and 0.998 for intertester variability were found [22]. Differences of more than 10° between the two methods were found for shoulder flexion of more than 160° [22, 23].

4.2 Active angle reproduction test

As described before [12, 16], our study group used an active angle reproduction test to measure proprioception: Test person sat on a chair with the arm hanging in 0° abduction and rotation. They were blindfolded to eliminate visual clues and wore sleeveless shirts. We ensured that the arm did not touch the trunk and, consequently, skin contact was minimized. The arm was moved to the desired position by the examiner with visual control of a manual handheld goniometer. In detail, the positions were 30° and 60° abduction, 30° and 60° flexion, and 30° external (and afterwards 30° internal rotation) in 30° abduction (total six joint positions). In the target position the subjects were told to maintain the position for ten seconds, and then the initial position with the arm hanging was resumed. Afterwards, the subject was asked to move the arm back into the target position and the mean value of the joint position was measured. Standardized instructions were given to all subjects, and a test trial was conducted to acquaint them with each test condition. All tests were randomized for side and movement. Two test trials were performed at each angle, and the mean value was used for further analysis. The total proprioception performance (total)

was defined as the mean value of all single measurements (six joint positions) to have one quality to compare proprioceptive ability.

5. Patients and controls

Patients receiving three different types of shoulder arthroplasties in 2007 were examined from 2007 to 2010:

- i. Ten consecutive patients underwent third-generation total shoulder arthroplasty (TSA) (Aequalis Shoulder; Tournier, Lyon, France) for degenerative osteoarthritis of the humeral head and glenoid with a mean age of 75 years (standard deviation [SD] 4.7 years). There were seven women and three men (mean height 167.0 cm [SD 11.0]; mean weight 81.0 kg [SD 15.9]), with four right shoulders and six left shoulders. In all cases the deltopectoral approach was used with detachment of the subscapularis tendon and release of all three glenohumeral ligaments. At the end of the surgery the subscapularis was reattached to the humeral bone. Primary osteoarthritis was found in eight cases and secondary posttraumatic osteoarthritis in two cases. The dominant side was involved in eight cases.
- ii. Eleven consecutive patients underwent hemiarthroplasty (HEMI) for degenerative changes limited to the humeral head and a stable/ minimally deformed glenoid of type A1 or A2 according to Walch [29]. There were nine women and two men, with five right shoulders and six left shoulders, four on the dominant sides and seven non-dominant sides. In all cases the deltopectoral approach was used as described above. Osteoarthritis was primary in nine cases and post-traumatic in two cases. The mean age was 64 years (SD 13.8), mean height was 167.0 cm (SD 8.1), and the mean weight was 79.0 kg (SD 18.8).
- iii. In five patients a reversed prosthesis was implanted for cuff tear arthropathy (REVERSE). All were women, their mean age was 73 years (SD 4.6), mean height was 160 cm (SD 7.3), and mean weight was 73.6 kg (SD 7.4). In all cases the dominant right shoulder was treated. For all patients the anterior lateral approach was used with partial detachment of the anteriorlateral deltoid muscle and refixation in the end of the surgery. The subscapularis tendon and the glenohumeral ligaments at the glenoid were released. Consecutive patients were enrolled in the study which resulted in uneven numbers in the different groups of arthroplasties implanted. The main focus and outcome measure were not on comparing the groups (especially no comparison with the REVERSE group), but to monitor proprioception over time within the groups.
- iv. A matched control group consisted of five women and five men. Matched controls (n=10; NORM) had a mean age of 64.5 years (SD 7.3). The mean height was 170.3 cm (SD 9.3), and the mean weight was 78.2 kg (SD 11.6). All controls were right-hand dominant, healthy, and had normal shoulders according to medical history, physical examination and radiographs. In this group the test persons were also examined twice, over the period of three years.

6. Statistics

The statistical analysis was performed using SPSS Version 16.0 (SPSS Inc., Chicago, IL, USA). Group mean values (MV) and standard deviations (SD) were calculated. P values <0.05 were considered significant. The distribution of the data was checked with the

Shapiro-Wilk test, and the homogeneity of variance was assessed using the Levene test. The angle between the long axis of the humerus and the trunk position was determined. Differences in shoulder joint angles between target and reproduced position were compared between the pre- and postoperative examination with a Wilcoxon-test for the groups TSA, HEMI, and REVERSE. Afterwards as a second outcome measure differences among these groups and the controls were examined by a Mann-Whitney *U* test.

7. Results of proprioception measurement three years after shoulder arthroplasty

The hemioarthroplasty (HEMI) subgroup revealed significant lower AAR at 30° of external rotation before surgery with 3.1° [SD 3.5] as compared to three years after surgery 12.8° [SD 10.7]; ($p=0.031$) (fig. 1). By trend, in the TSA subgroup the AAR deteriorated from 7.1° [SD

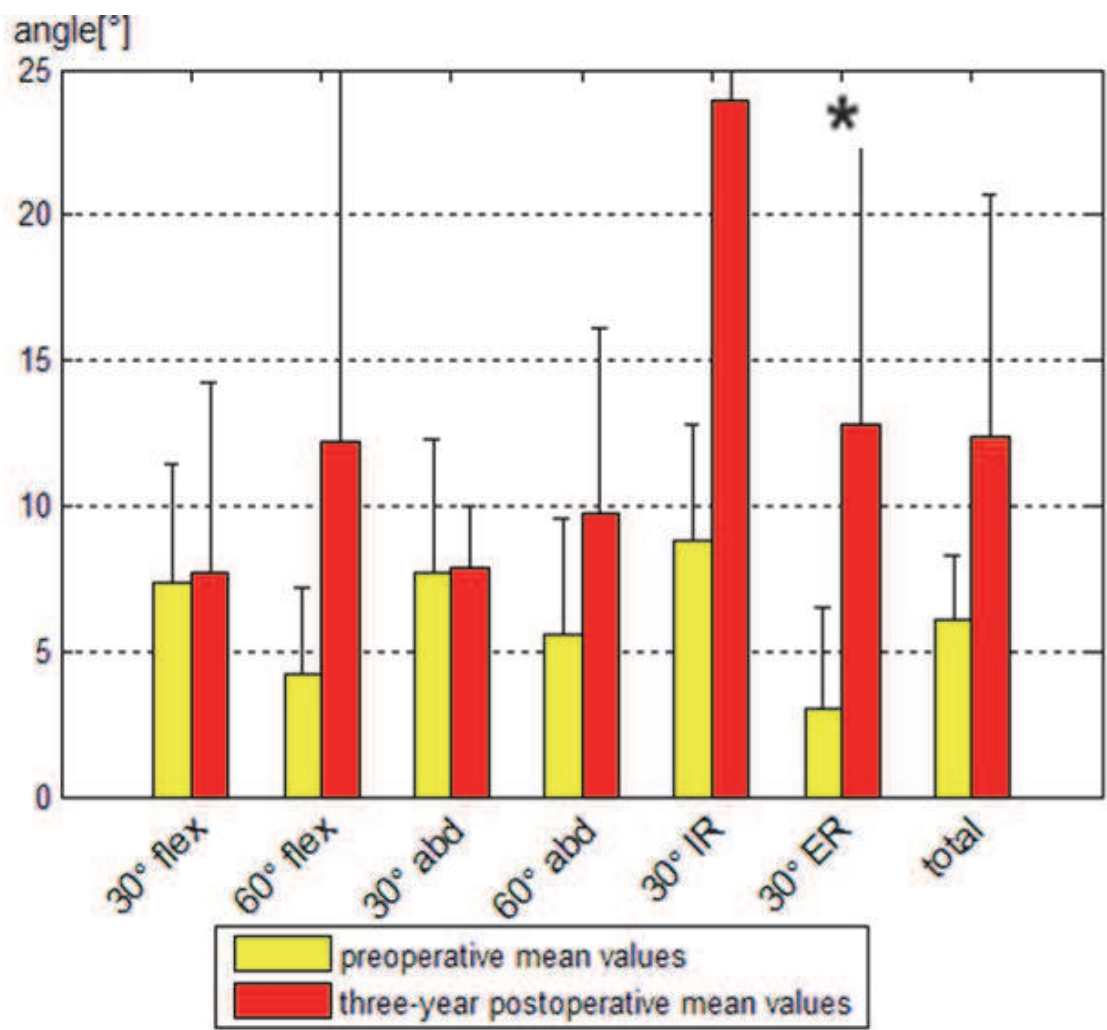


Fig. 1. The hemioarthroplasty (HEMI) group showed significant lower AAR at 30° of external rotation three years after surgery (3.1° [SD 3.5] vs. 12.8° [SD 10.7]; ($p=0.031$)). Otherwise there were no significances between pre- and postoperative AAR, although the total proprioception performance (total) almost reached significance ($p=0.063$). Graphically, there is a deterioration in all movements.

3.1] to 8.6° [SD 1.4] (fig. 2), in the HEMI subgroup from 6.1° [SD 2.1] to 12.4° [SD 8.3] (fig. 1) and in the reversed subgroup from 8.1° [SD 4.8] to 9.9° [SD 1.8] (fig. 3). Although there are different underlying concepts and biomechanics between the TSA, HEMI and REVERSE group, the results were included in a combined analysis to get a general impression of the intervention of implantation of an arthroplasty: in all groups three years after shoulder arthroplasty the total proprioception performance (total) measured by the AAR deteriorated significantly (from 6.9° [SD 3.4] to 10.3° [SD 5.2]; $p=0.018$) (table 1). The internal rotation deteriorated significantly from 7.9° [SD 5.7] to 17.6° [SD 21.1] ($p=0.039$) (table 2). The comparison between the controls (NORM) and the three years postoperative values of all arthroplasty groups (TSA, HEMI and REVERSE) reveals a significant worse AAR in the arthroplasty group three years after shoulder arthroplasty (10.3° [SD 5.2] vs. 7.8° [SD 2.3]; $p=0.030$) (fig. 4).

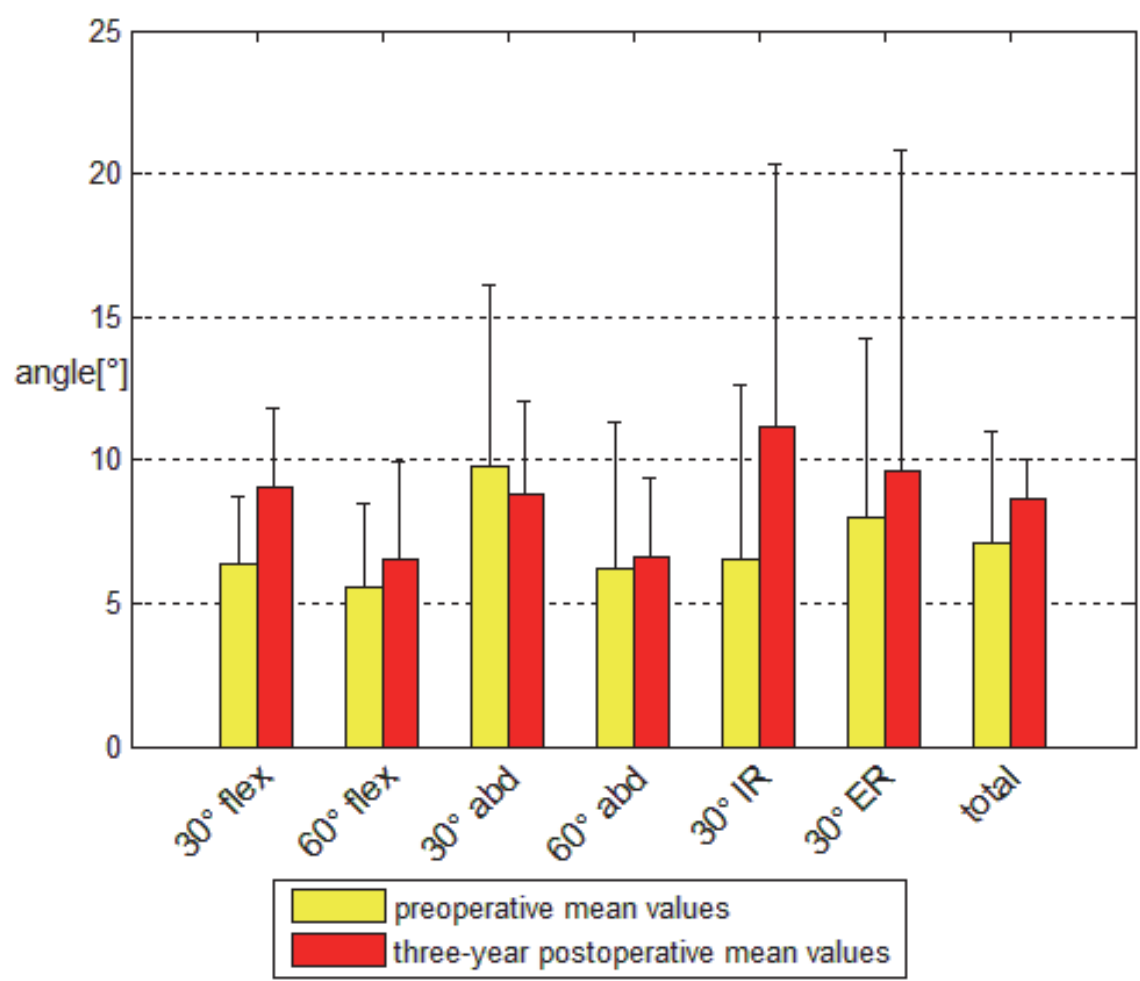


Fig. 2. The comparison pre- to postoperative values after implantation of a total shoulder arthroplasty (TSA) showed no significant differences between pre- and postoperative AAR. By trend, there is a deterioration of proprioception three years after surgery. The total proprioception performance (total) deteriorated by trend from 7.1° [SD 3.1] to 8.6° [SD 1.4].

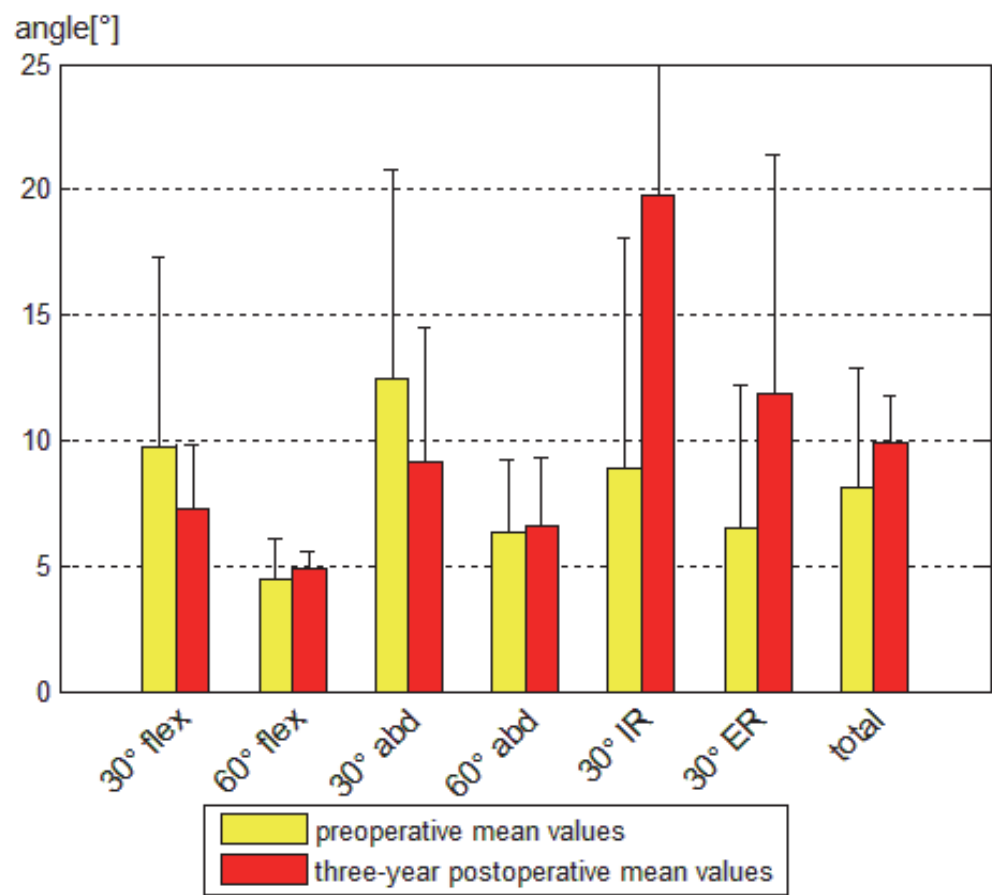


Fig. 3. The reversed shoulder arthroplasty (REVERSE) group graphically showed an improvement of the AAR at 30° of flexion and 30° of abduction. However, there is a deterioration for the other movements. The total proprioception performance (total) deteriorated by trend from 8.1° [SD 4.8] to 9.9° [SD 1.8].

Movement	Preoperatively		Three years postoperatively		P value
	Mean [°]	SD [°]	Mean [°]	SD [°]	
30° of flexion	7.4	± 4.1	8.2	± 4.3	0.669
60° of flexion	4.8	± 2.7	8.4	± 8.7	0.211
30° of abduction	9.5	± 5.7	8.5	± 3.1	0.562
60° of abduction	6.1	± 4.1	7.8	± 4.5	0.144
30° of external rotation	5.7	± 5.4	11.2	± 10.1	0.065
30° of internal rotation	7.9	± 5.7	17.6	± 21.1	0.039
Total	6.9	± 3.4	10.3	± 5.2	0.018

TSA total shoulder arthroplasty, Hemi hemiarthroplasty, REVERSE reversed arthroplasty, SD standard deviation;

Table 1. Active angle reproduction test (AAR) in all groups (TSA, HEMI and REVERSE) before operation and three years thereafter

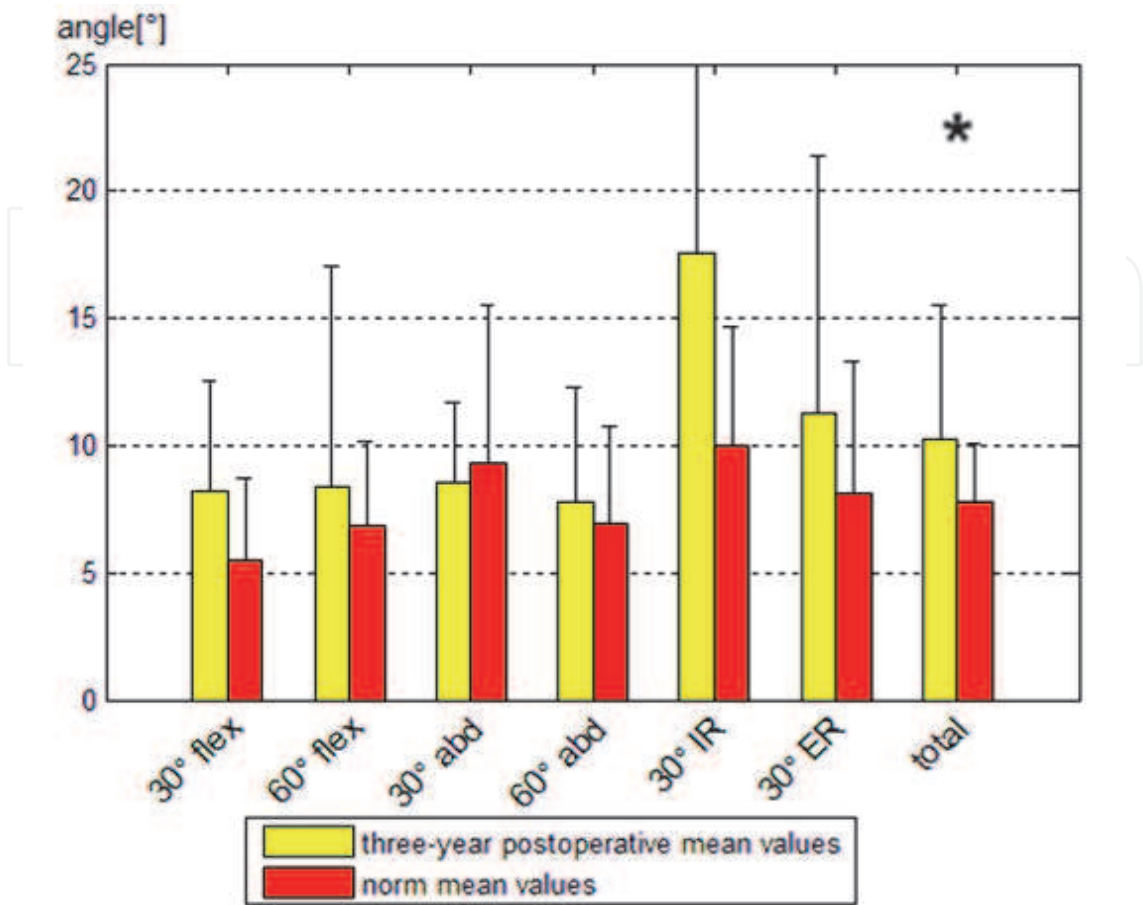


Fig. 4. The comparison between the controls and the three years postoperative values of all arthroplasty groups (TSA, HEMI and REVERSE) shows significantly better total proprioception performance (total) in the control (NORM) than in the arthroplasty group (10.3° [SD 5.2] vs. 7.8° [SD 2.3]; p=0.030).

8. Discussion of our findings with the literature

To our knowledge there are only three studies analyzing proprioception after shoulder arthroplasty [6, 12, 16]. Two are short-term studies with a six months follow-up [12, 16] and one is a middle-term follow up study [16]: Cuomo et al. [6] performed a prospective analysis of 20 consecutive patients with unilateral advanced glenohumeral arthritis who underwent total shoulder arthroplasty (TSA). Shoulder proprioception testing for passive position sense and detection of motion was performed one week before surgery and six months after TSA. Six months after TSA, position sense and the sensitivity of detection of motion were significantly improved (p<0.05) and did not differ significantly from the contralateral shoulder or the controls. Cuomo concluded that in patients with advanced glenohumeral arthritis after TSA there was a marked improvement in proprioception. In our study group, Kasten et al. [12] assessed proprioception six months after shoulder arthroplasty by an *active* and unguided angle-reproduction test with 3D motion analysis. In contrast to Cuomo we found out that six months after surgery proprioception remained unchanged or deteriorated. Due to the fact that this is completely the different result as

Cuomo et. al., it was concluded, that this is either due to the different measurement methods (active versus passive) or the relatively short rehabilitation period of six months. Maybe an improvement would also be found in the mid-term follow-up. That's why we investigated the same patients three years after shoulder arthroplasty by the same active angle reproduction test to measure the development of proprioception [16]. The middle-term follow-up showed no improvement but rather a deterioration of proprioception over the course of three years after shoulder arthroplasty. How can we explain that?

Cuomo et al. used a hydraulic machine that passively moved the arm. The patient had to indicate when he or she noted movement ("detection of motion") and, in a separate approach, when he or she passively reassumed a joint position that was previously defined ("passive position sense"). Cuomo and colleagues thus measured two entities of proprioception separately. The outcome of the AAR test, used in our setting, can be influenced by some elements: The test person has to actively move the arm and is therefore not limited regarding the direction of movement. Consequently, a more comprehensive concept of proprioception is tested, comprising the elements of position sense, motion sense, and the muscle strength that is necessary to reassume the position.

9. Proprioception in shoulder instability

The AAR has been used to assess shoulder proprioception before, for example, in shoulder instability. Pötzl and colleagues examined the proprioceptive capabilities of 14 patients with recurrent anterior shoulder instability preoperatively and at least five years postoperatively using the AAR test [20]. In their series the joint position sense improved significantly in abduction, flexion, and rotation ($p < 0.05$). They concluded that five years after surgical restoration of shoulder instability the joint position sense improved significantly to the same level as normal healthy shoulders. Having these results in mind we have to ask why proprioception measured with a comparable AAR deteriorates after shoulder arthroplasty, whereas it improves after surgery of shoulder instability?

10. Possible reasons why proprioception deteriorates after shoulder arthroplasty

In shoulder arthroplasty, the operative approach for implantation of a TSA and hemiarthroplasty includes the cutting (and subsequent repair) of the subscapularis muscle and usually release of all glenohumeral ligaments. In cuff tear arthropathy the subscapularis is damaged from the beginning or released during surgery in our technique. However, these structures contain afferent and efferent structures important for proprioception. Therefore, concerning the influence on proprioceptive structures, the surgical procedures for shoulder instability and shoulder replacement are distinct. Since the approach in TSA and hemiarthroplasty is identical, a comparison seems to be valid. The different approach and the lack of the rotator cuff in cuff tear arthropathy limits a direct comparison with the other groups. However, the aim of this study was not the comparison of different types of implants that were implanted for different indications. The aim of this study was to assess proprioception changes three years after shoulder arthroplasty within the three groups. What we observed in our study is that nociceptors may also play an important role. During the repeat postoperative measurement, the patients mentioned that they were lacking the information input of pain sensation that they had usually during motion of the arm before

surgery. The lacking of this afferent input might adversely influence the postoperative proprioception performance with the AAR.

11. What can we do to avoid postoperative deterioration of proprioception?

Another issue is how we could diminish the loss of proprioception after shoulder replacement. Certainly we have to take a look at the surgical procedure. In the cases of TSA and HEP the deltopectoral approach was used with detachment of the subscapularis tendon and release of all glenohumeral ligaments. In shoulder replacement different procedures exist for detachment of the subscapularis tendon. If the external rotation is $> 20^\circ$, according to our concept the subscapularis tendon is divided 5-10 mm medial to its insertion at the lesser tuberosity. The lateral tendon stump will permit an end-to-end suture at the end of surgery. If the external rotation is $< 20^\circ$, the detachment of the subscapularis tendon from the lesser tuberosity is recommended, because this allows to gain length by medializing the tendon insertion after implantation of the prosthesis. At the end of the surgery, the subscapularis tendon is repaired in slight abduction and external rotation of the arm either with an end-to-end suture or, in the presence of joint contracture, reattached with the help of previously mounted transosseous sutures [10, 24]. This refixation is important, because otherwise it carries the risk of a later anterior instability of the prosthesis and loss of shoulder function.

This intraoperative soft tissue management could play an important role for the proprioceptive outcome according to a recently published study by Rokito et al. [25]. They investigated the degree to which surgical approach affects recovery of strength and proprioception. The recovery of strength and proprioception after open surgery for recurrent anterior glenohumeral instability was compared for two surgical procedures. Group 1 underwent an open inferior capsular shift with detachment of the subscapularis, and group 2 underwent an anterior capsulolabral reconstruction without detachment of the subscapularis. In group 1 the subscapularis was split horizontally at the junction of its upper two-third and lower one-third, and a glenoid-sided capsular shift was performed, followed by reapproximation of the split. At 6 months after surgery in group 1 patients there were still significant deficits in mean position sense and strength values. Rokito concluded that detachment of the subscapularis delays recovery of strength and proprioception. These findings can explain the deterioration of proprioceptive outcome in shoulder arthroplasty which usually implies the detachment of the subscapularis muscle. Another important issue is the release of the glenohumeral ligaments that play an important role in proprioception of the shoulder. Postoperative management with immobilizing in a Gilchrist sling or an abduction pillow, physiotherapy management including a temporary avoidance for rotational movements to allow for healing of the subscapularis muscle as well as proprioceptive neuromuscular facilitation exercises might play an important role for the individual proprioceptive outcome.

Performing shoulder arthroplasty did negatively affect one component of shoulder proprioception that was measured by the active angle-reproduction test. This might be related to the surgical approach that includes division of the subscapularis muscle and the glenohumeral ligaments. In order to be able to diminish negative influences on postoperative proprioception further prospective studies will have to evaluate pre- and intraoperative variables to improve proprioception after shoulder replacement. Although proprioception does not improve three years after implantation of shoulder arthroplasty, a

pain free increase of range of motion in activities of daily living, as we described in a previous study [13], is the main improvement for the patient after surgery.

Summary sentence

Shoulder proprioception deteriorates after shoulder arthroplasty.

Disclosures

All authors, their immediate family, and any research foundation with which they are affiliated did not receive any financial payments or other benefits from any commercial entity related to the subject of this article.

Source of funding

Research fund of the Department of Orthopaedic and Trauma Surgery of the Hospital of the University of Heidelberg.

The local ethics committee approved the study (S-305/2007) and all patients consented to the study.

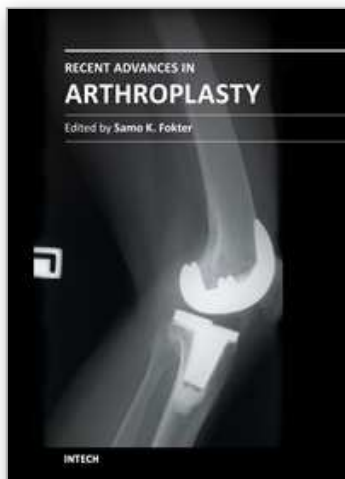
12. Acknowledgements

We thank the research fund of the Department of Orthopaedic and Trauma Surgery of the Hospital of the University of Heidelberg for the financial support of the study. Furthermore, we would like to thank the motion analysis team of the University of Heidelberg, especially Petra Armbrust and Waltraud Schuster, for the practical support during the study.[Level of Evidence : Level III, Case-Control Study, Treatment Study.

13. References

- [1] Blasier, R.B., J.E. Carpenter, and L.J. Huston, *Shoulder proprioception. Effect of joint laxity, joint position, and direction of motion.* Orthop.Rev., 1994. 23(1): p. 45-50.
- [2] Boileau, P., et al., *Arthroplasty of the shoulder.* J.Bone Joint Surg.Br., 2006. 88(5): p. 562-575.
- [3] Carman, A.B. and P.D. Milburn, *Determining rigid body transformation parameters from ill-conditioned spatial marker co-ordinates.* J Biomech, 2006. 39(10): p. 1778-86.
- [4] Chiari, L., et al., *Human movement analysis using stereophotogrammetry. Part 2: instrumental errors.* Gait Posture, 2005. 21(2): p. 197-211.
- [5] Constant, C.R. and A.H. Murley, *A clinical method of functional assessment of the shoulder.* Clin Orthop Relat Res., 1987(214): p. 160-164.
- [6] Cuomo, F., M.G. Birdzell, and J.D. Zuckerman, *The effect of degenerative arthritis and prosthetic arthroplasty on shoulder proprioception.* J Shoulder Elbow Surg, 2005. 14(4): p. 345-348.
- [7] Deshmukh, A.V., et al., *Total shoulder arthroplasty: long-term survivorship, functional outcome, and quality of life.* J Shoulder Elbow Surg, 2005. 14(5): p. 471-9.
- [8] Doorenbosch, C.A., J. Harlaar, and D.H. Veeger, *The globe system: an unambiguous description of shoulder positions in daily life movements.* J Rehabil Res Dev, 2003. 40(2): p. 147-55.
- [9] Gamage, S.S. and J. Lasenby, *New least squares solutions for estimating the average centre of rotation and the axis of rotation.* J Biomech, 2002. 35(1): p. 87-93.

- [10] Habermeyer, P. and G. Engel, *Surgical technique for total shoulder arthroplasty*. Operat Orthop Traumatol, 2004. 16: p. 339-364.
- [11] Jerosch, J. and M. Prymka, *Proprioception and joint stability*. Knee.Surg.Sports Traumatol.Arthrosc., 1996. 4(3): p. 171-179.
- [12] Kasten, P., et al., *Proprioception in total, hemi- and reverse shoulder arthroplasty in 3D motion analyses: a prospective study*. Int Orthop, 2009. 33(6): p. 1641-7.
- [13] Kasten, P., et al., *Can shoulder arthroplasty restore the range of motion in activities of daily living? A prospective 3D video motion analysis study*. J Shoulder Elbow Surg, 2010. 19(2 Suppl): p. 59-65.
- [14] Kasten, P., et al., *Three-dimensional motion analysis of compensatory movements in patients with radioulnar synostosis performing activities of daily living*. J Orthop Sci, 2009. 14(3): p. 307-12.
- [15] Loew, M., et al., *[Shoulder arthroplasty following rotator cuff tear: acquired arthropathy of the shoulder]*. Orthopade, 2007. 36(11): p. 988-95.
- [16] Maier, M.W., et al., *Proprioception three years after shoulder arthroplasty in 3D motion analysis: a prospective study*. submitted to Int Orthop, 2011.
- [17] Matsen, F.A., 3rd, et al., *The reverse total shoulder arthroplasty*. J Bone Joint Surg Am, 2007. 89(3): p. 660-7.
- [18] Nyffeler, R.W., et al., *Influence of humeral prosthesis height on biomechanics of glenohumeral abduction. An in vitro study*. J Bone Joint Surg Am, 2004. 86-A(3): p. 575-80.
- [19] Orfaly, R.M., et al., *A prospective functional outcome study of shoulder arthroplasty for osteoarthritis with an intact rotator cuff*. J Shoulder Elbow Surg, 2003. 12(3): p. 214-21.
- [20] Potzl, W., et al., *Proprioception of the shoulder joint after surgical repair for Instability: a long-term follow-up study*. Am.J.Sports Med., 2004. 32(2): p. 425-430.
- [21] Proske, U. and S.C. Gandevia, *The kinaesthetic senses*. J Physiol, 2009. 587(Pt 17): p. 4139-46.
- [22] Raiss, P., et al., *[Range of motion of shoulder and elbow in activities of daily life in 3D motion analysis]*. Z.Orthop.Unfall., 2007. 145(4): p. 493-498.
- [23] Rettig, O., et al., *A new kinematic model of the upper extremity based on functional joint parameter determination for shoulder and elbow*. Gait Posture, 2009. 30(4): p. 469-76.
- [24] Rockwood, C.A., Jr., *The technique of total shoulder arthroplasty*. Instr Course Lect, 1990. 39: p. 437-47.
- [25] Rokito, A.S., et al., *Recovery of shoulder strength and proprioception after open surgery for recurrent anterior instability: a comparison of two surgical techniques*. J Shoulder Elbow Surg, 2010. 19(4): p. 564-9.
- [26] Sherrington, C.S., *On the proprioceptive system, especially in its reflex aspect*. Brain, 1906. 29: p. 1-28.
- [27] van de Sande, M.A., R. Brand, and P.M. Rozing, *Indications, complications, and results of shoulder arthroplasty*. Scand J Rheumatol, 2006. 35(6): p. 426-34.
- [28] Walch, G., P. Boileau, and P. Pozzi, *Glenoid resurfacing in shoulder arthroplasty*. In: Walch G, Boileau P, eds.: Shoulder arthroplasty. Berlin, Heidelberg, New York, Tokio: Springer, 1999: p. 177-181.
- [29] Walch, G., et al., *Primary glenohumeral osteoarthritis: clinical and radiographic classification. The Aequalis Group*. Acta Orthop.Belg., 1998. 64 Suppl 2: p. 46-52.
- [30] Warner, J.J., et al., *Static capsuloligamentous restraints to superior-inferior translation of the glenohumeral joint*. Am.J.Sports Med., 1992. 20(6): p. 675-685.
- [31] Wu, G., et al., *ISB recommendation on definitions of joint coordinate systems of various joints for the reporting of human joint motion--Part II: shoulder, elbow, wrist and hand*. J Biomech, 2005. 38(5): p. 981-992.



Recent Advances in Arthroplasty

Edited by Dr. Samo Fokter

ISBN 978-953-307-990-5

Hard cover, 614 pages

Publisher InTech

Published online 27, January, 2012

Published in print edition January, 2012

The purpose of this book was to offer an overview of recent insights into the current state of arthroplasty. The tremendous long term success of Sir Charnley's total hip arthroplasty has encouraged many researchers to treat pain, improve function and create solutions for higher quality of life. Indeed and as described in a special chapter of this book, arthroplasty is an emerging field in the joints of upper extremity and spine. However, there are inborn complications in any foreign design brought to the human body. First, in the chapter on infections we endeavor to provide a comprehensive, up-to-date analysis and description of the management of this difficult problem. Second, the immune system is faced with a strange material coming in huge amounts of micro-particles from the tribology code. Therefore, great attention to the problem of aseptic loosening has been addressed in special chapters on loosening and on materials currently available for arthroplasty.

How to reference

In order to correctly reference this scholarly work, feel free to copy and paste the following:

Michael W. Maier and Philip Kasten (2012). Development of Proprioception After Shoulder Arthroplasty, Recent Advances in Arthroplasty, Dr. Samo Fokter (Ed.), ISBN: 978-953-307-990-5, InTech, Available from: <http://www.intechopen.com/books/recent-advances-in-arthroplasty/development-of-proprioception-after-shoulder-arthroplasty>

INTech
open science | open minds

InTech Europe

University Campus STeP Ri
Slavka Krautzeka 83/A
51000 Rijeka, Croatia
Phone: +385 (51) 770 447
Fax: +385 (51) 686 166
www.intechopen.com

InTech China

Unit 405, Office Block, Hotel Equatorial Shanghai
No.65, Yan An Road (West), Shanghai, 200040, China
中国上海市延安西路65号上海国际贵都大饭店办公楼405单元
Phone: +86-21-62489820
Fax: +86-21-62489821

© 2012 The Author(s). Licensee IntechOpen. This is an open access article distributed under the terms of the [Creative Commons Attribution 3.0 License](https://creativecommons.org/licenses/by/3.0/), which permits unrestricted use, distribution, and reproduction in any medium, provided the original work is properly cited.

IntechOpen

IntechOpen