

We are IntechOpen, the world's leading publisher of Open Access books Built by scientists, for scientists

6,900

Open access books available

186,000

International authors and editors

200M

Downloads

Our authors are among the

154

Countries delivered to

TOP 1%

most cited scientists

12.2%

Contributors from top 500 universities



WEB OF SCIENCE™

Selection of our books indexed in the Book Citation Index
in Web of Science™ Core Collection (BKCI)

Interested in publishing with us?
Contact book.department@intechopen.com

Numbers displayed above are based on latest data collected.
For more information visit www.intechopen.com



Humeral Hemiarthroplasty with Spherical Glenoid Reaming: Theory and Technique of The Ream and Run Procedure

Moby Parsons

Seacoast Orthopedics and Sports Medicine

Somersworth, NH

USA

1. Introduction

Despite improvements in glenoid prosthesis design, materials and surgical techniques, complications related to the glenoid component continue to be a leading cause of failure after total shoulder arthroplasty. Although previously felt to be of little clinical significance, radiolucent lines around the glenoid prosthesis are now recognized as a sign of impending mid and long term fixation problems. While much attention in shoulder prosthesis design has focused on anatomical reconstruction of the humerus through increasing modularity, comparatively little progress has been made in solving the problems of glenoid wear and fixation failure. Resolving these issues on the socket side of the equation remains a challenge for the shoulder arthroplasty surgeon as the population ages, as young patients present with terminal shoulder arthritis and as patients demand higher performance from their implant.

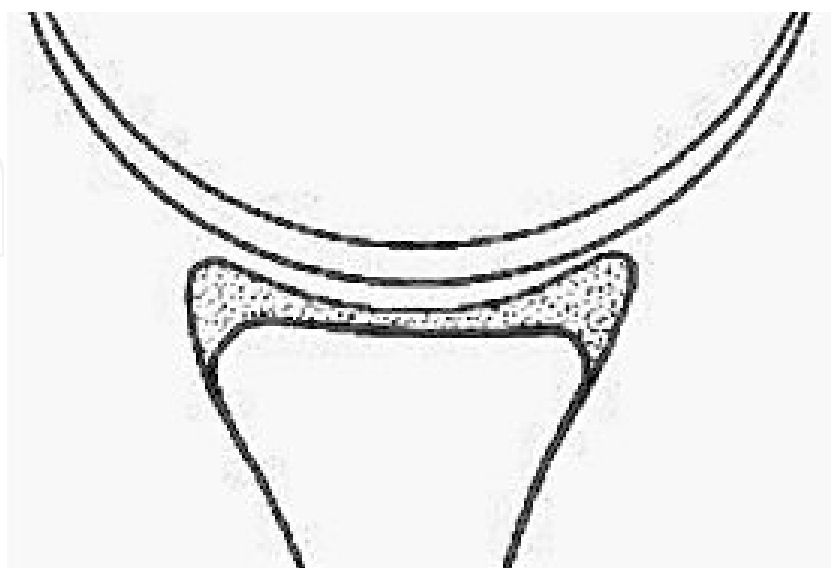


Fig. 1. In the normal glenohumeral joint, the compliance of the articular cartilage and the labrum provide for conforming surfaces which optimize stability and load distribution.

In the normal shoulder, the compliance of the articular cartilage and labrum allow the mating surfaces to conform under applied loads throughout a wide range of motion (Figure 1). Thus, normal, physiological glenohumeral translations can occur between congruent surfaces without introducing a kinematic conflict caused by excessive constraint. Because polyethylene glenoids are not compliant, they cannot instantly deform to remain congruent as normal translations occur. To resolve the potential conflict between conformity and constraint, total shoulder systems have introduced mismatch between the radii of curvature of the head and glenoid to permit small translations that increase range of motion and resolve some of the stresses transmitted to the fixation interface.

While mismatch has proven to reduce earlier fixation failure, it also facilitates eccentric loading by allowing the center of rotation of the humerus to translate away from the center of the glenoid concavity. As the contact point on the prosthetic glenoid surface changes, there are corresponding marked changes in the cement mantle stress that ultimately result in micromotion at the bone cement interface.¹ Oosterom and colleagues performed biomechanical studies looking at the effect of varying degrees of conformity on rim loading and found that mismatch increases rim displacement.² Furthermore, mismatch results in abrasive wear at the prosthetic surface and a higher likelihood of material failure under eccentric loading conditions.³ Retrieval studies of failed glenoids that have radial mismatch, have repeatedly shown characteristic changes in the prosthetic surface including edge deformation, rim fracture, broad surface irregularity and wear to conformity (Figure 2).^{4,5}

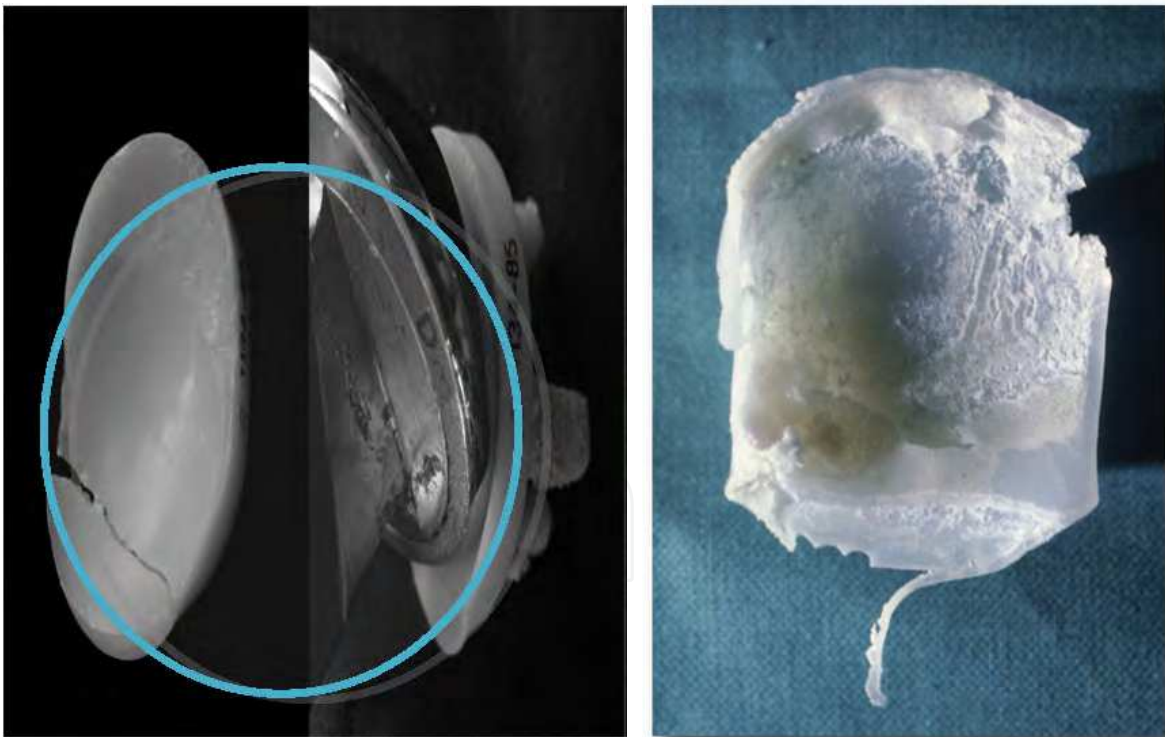


Fig. 2. Wear to conformity (left), broad surface abrasion and rim wear (right).

Modes of damage have been found most commonly in the inferior quadrant suggesting calcar impingement with the humerus.⁶ Braman et al further showed that alterations in the surface geometry of the damaged prosthesis compromised its intrinsic stability, thus exacerbating the pathomechanics that result in surface damage to begin with.⁴

Several studies have looked at glenoid prosthesis design parameters and at cementation and bone preparation techniques seeking to optimize fixation to the host bone and resist tensile stresses imparted by eccentric loading conditions.⁸⁻¹⁰ There is general consensus that pegged glenoid components tend to outperform keeled components and that third generation cementation techniques have reduced the incidence of early radiolucent lines. While most outcome studies show survivorship of the prosthesis at midterm, clinical outcome studies demonstrate deterioration in glenoid component longevity as the time interval from surgery increases. Walch and colleagues in a multicenter study of 333 shoulder arthroplasties performed with the same cemented convex-backed glenoid component showed that nearly 50% were radiographically loose at 10 years.¹¹ The need to eccentrically ream the glenoid to correct posterior erosion was associated with a higher rate of loosening. Young et al performed a similar multicenter study looking at long-term survivorship of a cemented flat-backed, keeled all-polyethylene glenoids and found radiographic loosening of 20% at 10 years and 67% at 15 years.¹² Kasten et al similarly noted a 9% rate of loosening at 5 years, which increased to 33% at 9 years. Radiolucent lines were noted to progress over time.¹³ As with arthroplasty of other joints that rely on cement fixation, progressive radiolucency is an "at risk" sign for eventual loosening and though mid-term data show little correlation between lucency and revision, it is expected that longer follow-up will bear out eventual clinical failure. Bartelt et al followed a cohort of patients younger than age 55 years who underwent total shoulder arthroplasty and found a 30% rate of radiographic loosening at a mean of 6.6 years.¹⁴ The implant survival rate in this group was only 92% at 10 years.

In light of these sobering data, there have been historical and resurging attempts to improve fixation durability by capitalizing on the proven success of bone ingrowth into porous metal surfaces. However, experience with early metal-backed designs demonstrated failure rates much higher than for cemented polyethylene components.¹⁵ Taunton et al reported on revision or radiographic failure for a metal-backed, bone-growth glenoid of 20% at 5 years and 48% at 10 years.¹⁶ Unacceptably high rates of radiographic failure have also been reported for cemented metal-backed glenoid components.¹⁷ Although some cases of fibrous ingrowth have been documented, many of these failures were not related to fixation problems between the metal and the bone, rather to excessive polyethylene wear, locking mechanism problems and severe osteolysis.¹⁸ Tensile stress seems to be transferred to the fixation between the polyethylene and metal baseplates leading to the potential for excessive wear, fracture and dissociation of the components. While much of this experience is based on implants used in the 1980's to 1990's, there is renewed interest in metal-backed designs given the success of metal base plates in reverse shoulder arthroplasty and the desire to have modularity on the glenoid side facilitating conversion between primary and reverse shoulder replacement. Clinical outcome studies on newer designs have yet to prove their merit versus their historical counterparts and the current standard set by cemented all polyethylene designs, albeit a fair standard compared to survivorship data for hip and knee arthroplasty.

These data are alarming considering the growing epidemic of degenerative conditions in younger patients, the higher expectations of patients who wish to remain physically active into their older years and the general aging of the population. The conclusion one can draw from the current clinical and basic science literature is that modern prosthetic glenoid components are destined to fail by wear and loosening with repeated eccentric loading. Thus, for younger patients or those whose life-expectancy is greater than 15 years there is a

high likelihood that revision surgery will be necessary to address glenoid component failure. In many of these cases, reimplantation of a glenoid component is not possible due to structural deficiency of the remaining glenoid vault, and functional outcomes are often uncertain.^{19,20} Studies on structural grafting of bone deficits have shown a high rate of short-term reconstitution but long-term subsidence indicating that durable and reliable solutions for the failed glenoid are not yet available for this growing cohort of patients.^{21,22}

To address the need for surgical options to treat shoulder arthritis in younger patients, biological resurfacing procedures using a number of different interposition materials have been evaluated with largely varying short and mid-term success. Autogenous fascia lata, Achilles tendon²³⁻²⁴ and glenohumeral capsule,^{25,26} allograft lateral meniscus^{27,28} and dermal scaffolds,²⁹ and xenographic tissues patches³⁰ have all been used to resurface the worn glenoid. Both arthroscopic and open techniques have been reported and techniques have included humeral chondroplasty, humeral prosthetic surface replacement versus stemmed humeral hemiarthroplasty.²³ While some of these reports demonstrate initial improvement in pain and function, progressive joint space narrowing and glenoid erosion are common and consequent eventual revision to definitive arthroplasty. Gerber has nicely summarized the literature on this field, stating "Biologic resurfacing of the glenoid has hitherto failed to adequately restore the geometry and biology of the glenoid."³¹ It is fair to say that lesser invasive approaches such as the arthroscopic techniques can be used as an interval step to delay arthroplasty but durable long-term results from these procedures seem to be the exception rather than the rule.

Hemiarthroplasty without glenoid resurfacing or reshaping is yet another alternative to total shoulder replacement which avoids the risk of glenoid failure. There has been extensive comparison between hemiarthroplasty and total shoulder arthroplasty in the literature looking at comparative outcomes. It is fairly well-established based on these studies including a meta-analysis of the existing literature, that total shoulder arthroplasty provides superior pain relief and range of motion over time.³²⁻³⁴ Nevertheless, some series do show comparable outcomes recognizing that some patients with progressive glenoid erosion do require conversion to total shoulder arthroplasty.³⁵ Levine et al have shown that results of hemiarthroplasty are inferior if preoperative glenoid erosion or posterior wear exists.³⁶ This highlights the importance of recentring the humeral head and restoring proper load-bearing mechanics at the glenohumeral joint after prosthetic reconstruction. Sperling and colleagues studied long-term results of hemiarthroplasty versus total shoulder in patients 50 years or younger.³³ While glenoid wear after hemiarthroplasty was present in 72% of cases, radiolucencies around the glenoid prosthesis were present in 76% of patients. The risk of painful glenoid erosion necessitating revision glenoid replacement lead to the conclusion that patients with total shoulder replacement have superior clinical outcomes. The authors also concluded however based on survivorship of total shoulders in this cohort that "great care must be exercised, and alternative methods of treatment considered before either hemiarthroplasty or total shoulder arthroplasty is offered to patients aged 50 years or younger."

Based on this background, a definitive treatment option for young and physically demanding patients with end-stage shoulder arthritis remains both a need and a challenge. Experience with the failure modes of both hemiarthroplasty and total shoulder arthroplasty, along with a better understanding of glenohumeral biomechanics have laid a foundation on which such a treatment must be based to provided a lasting solution that withstands the

rigors in which many of these patients wish to engage. In 1992, Frederick A. Matsen, III, MD began investigating the technique of humeral hemiarthroplasty with spherical glenoid reaming to restore a concavity to the glenoid and to reorient the worn glenoid perpendicular to the centerline of the scapular body. This technique has hence become known as the Ream and Run procedure. As follows is an in-depth description of basic science and clinical support for this technique, the principles of its application, patient selection, surgical technique, recovery and results.

2. Basic science and clinical support

According to Matsen, "glenoid components fail as a result of their inability to replicate essential properties of the normal glenoid articular surface to achieve durable fixation to the underlying bone, to withstand repeated eccentric loads and glenohumeral translation, and to resist wear and deformation."³⁷ The Ream and Run seeks to address these deficiencies by stimulating a biological response at the glenoid surface that can adapt to the applied stress through the process of healing and remodeling. Interest in this potential came from observations on retrieval studies of mold arthroplasty of the hip. Observations on this historical technique showed that the reamed acetabular bone was often covered with a smooth fibrous tissue layer that amounted to a biological resurfacing.³⁸ In addition, histologic studies demonstrated a relatively normal subchondral bony architecture that had remodeled according to the loads born on the surface.^{39, 40} Failure of this technique was often due to loosening and bone resorption on the femoral side.⁴¹ These results suggest that reamed bone has a regenerative potential to yield a durable joint surface when articulating with a convex metallic prosthesis.

Laboratory studies were then undertaken to determine if the reamed glenoid concavity was comparatively stable to either the native or a prosthetic glenoid. Weldon et al, using a cadaveric model, demonstrated that the intrinsic glenoid stability was compromised by loss of articular cartilage and that this stability could be restored to levels comparable to a prosthetic glenoid through spherical reaming.⁴² In other words, the surface geometry of the bone predicts its influence on glenohumeral kinematics. To further characterize the healing process that occurs at the reamed glenoid surface, Matsen and colleagues performed histologic analysis of retrieved glenoids at serial follow-up intervals in a canine model of the Ream and Run.⁴³ At 24 weeks post-surgery specimens consistently showed growth of a thick fibrocartilaginous tissue covering and firmly attached to the glenoid surface.(Figure 3) This progressive maturation between 3 and 6 months and remained congruent with the articulating humeral hemiarthroplasty.

The implication of these findings are: 1) healing and remodeling of the reamed bone is a progressive process demonstrating continued biological activity in response to the mechanical environment; and 2) progressive maturation of the regenerative surface suggests its ability to withstand its mechanical environment.

Based on this background, the Ream and Run procedure been in clinical application now for well over a decade, and its indications and techniques have been refined with increasing experience. As the length of follow-up continues for these patients, the foundations for sustained positive outcomes and the modes of failure have become clearer. These foundations are anchored in the principles behind this technique all of which relate to replicating the anatomical relationships of the glenohumeral joint and the biomechanical properties these relationships engender.

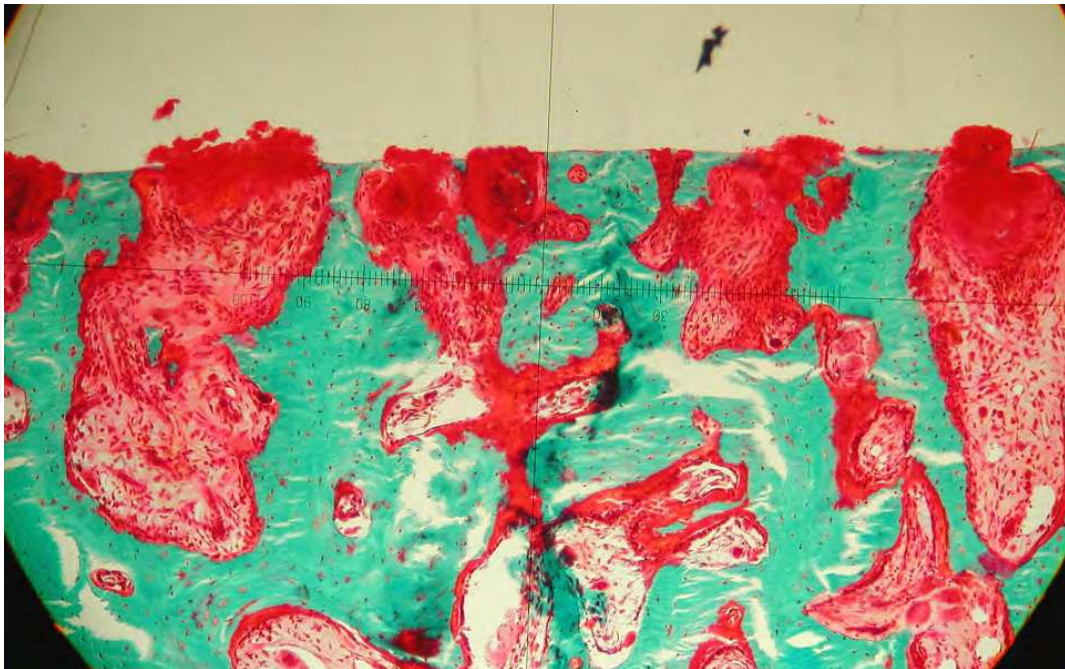


Fig. 3. Fibrocartilage growth between reamed bony trabeculae.

3. Principles

The key principles behind the Ream and Run which the surgeon must consider in reestablishing a lasting articulation that can withstand wear can be remembered as the 4 Cs: concavity, conformity, centerline and center of rotation. These are further discussed as follows.

3.1 Concavity

Stability of the glenohumeral joint in the midrange relies on dynamic centering of the humeral head into the glenoid concavity by the force couples generated by the rotator cuff. Coordination between the rotator cuff and periscapular stabilizing muscles ensures that the net reaction force at the glenohumeral joint is directed within the confines of the glenoid concavity. The depth and shape of this concavity can affect stability by altering the glenoid's ability to contain the resultant force from shoulder motion. This can be measured as the balance stability angle (BSA) – the maximal angle the net humeral reaction force vector can make with the glenoid centerline before the head dislocates.⁴² Both the width and the depth of the glenoid factor into the intrinsic stability and these, in turn, can be affected both by pathologic changes from arthritis as well as by corrective reaming.

Reestablishing a smooth concavity with sufficient depth and surface area is a central goal of the successful Ream and Run. Because reaming affects both depth and width, depending on the degree of necessary correction to recenter the humeral head, careful attention must be paid through preoperative planning and precise surgical technique to restore a sufficient concavity without compromising other principles as will be subsequently discussed. In cases where there is severe posterior glenoid wear, as can occur from capsulorrhaphy arthropathy, corrective reaming to restore glenoid version may sacrifice too much surface area in order to restore a sufficient concavity thus obviating the benefit of this procedure. Prosthetic glenoid resurfacing may be necessary in such cases despite the inherent risks of eventual failure.

3.2 Conformity

Although the bony anatomy is not conforming between the humeral head and glenoid concavity, the compliance afforded by the articular cartilage and glenoid labrum provide for conformity and congruency as the humeral head is centered and compressed. It is this conformity and compliance that permits load distribution over the glenoid face. Because bone and polyethylene are not as compliant as cartilage and labrum, some degree of mismatch between the diameter of curvature of the humeral head and glenoid has become a convention in total shoulder arthroplasty to avoid excessive constraint and allow physiologic translations. While historically mismatch seems to improve the longevity of prosthetic glenoid fixation, translations also allow eccentric glenoid loading, which contributes to eventual fixation failure. Mismatch also affects load distribution by concentrating loads over a smaller surface area on the glenoid surface.

In principle, the Ream and Run procedure must respect the biomechanical principles on which glenohumeral stability and load transfer are based while simultaneously reconciling the kinematic conflict that occurs between conformity and constraint as is seen with prosthetic glenoids. Stability is afforded by creation of a concavity into which the head can be centered after appropriate releases have been performed. Preservation of the labrum further deepens the socket and improves congruency between the ball and socket. Load distribution is optimized by choosing a mismatch of 2mm, which reduces point contact but allows some forgiveness in terms of constraint. It also provides some forgiveness in allowing the prosthetic humeral head to choose a centering point about which adaptive remodeling of the glenoid surface can define the final shape that optimizes joint kinematics and load transfer.

3.3 Centerline

In the normal shoulder, the glenoid is retroverted on average 10 degrees. The glenoid centerline (the line perpendicular to the glenoid face) thus normally points 10 degrees posterior to the axis of the scapular body. This line exits the scapula anteriorly at the base of the glenoid vault between the superior and inferior subscapularis crurae. Recentering the humeral head within the glenoid concavity is essential for shoulder mobility, stability and load transfer. The pathomechanics of primary and secondary arthritis often lead to posterior subluxation of the humerus and consequent posterior glenoid wear and erosion. These pathologic changes must be corrected to optimize load-bearing mechanics at the joint after prosthetic reconstruction. As will be discussed later, careful planning is necessary to determine the amount of correction that will restore the orientation of the glenoid. (Figure 4) Reorientation of the glenoid concavity through corrective reaming can diminish the surface area of the articulation because the glenoid vault narrows as one moves medially. In addition, corrective reaming to "bring down the high side" may result in significant penetration of the subchondral bone, which is softer and less tolerant of bearing significant loads when articulating with a convex metal prosthesis. Medialization of the glenoid may also increase the reaction force at the glenohumeral joint by reducing the lever arm of the rotator cuff muscles and may result in secondary impingement by bringing the tuberosity underneath the lateral acromion. Thus, preoperative planning must assess the degree of necessary correction and whether this will exceed the anatomical parameters necessary to achieve the other principles and goals of the Ream and Run.

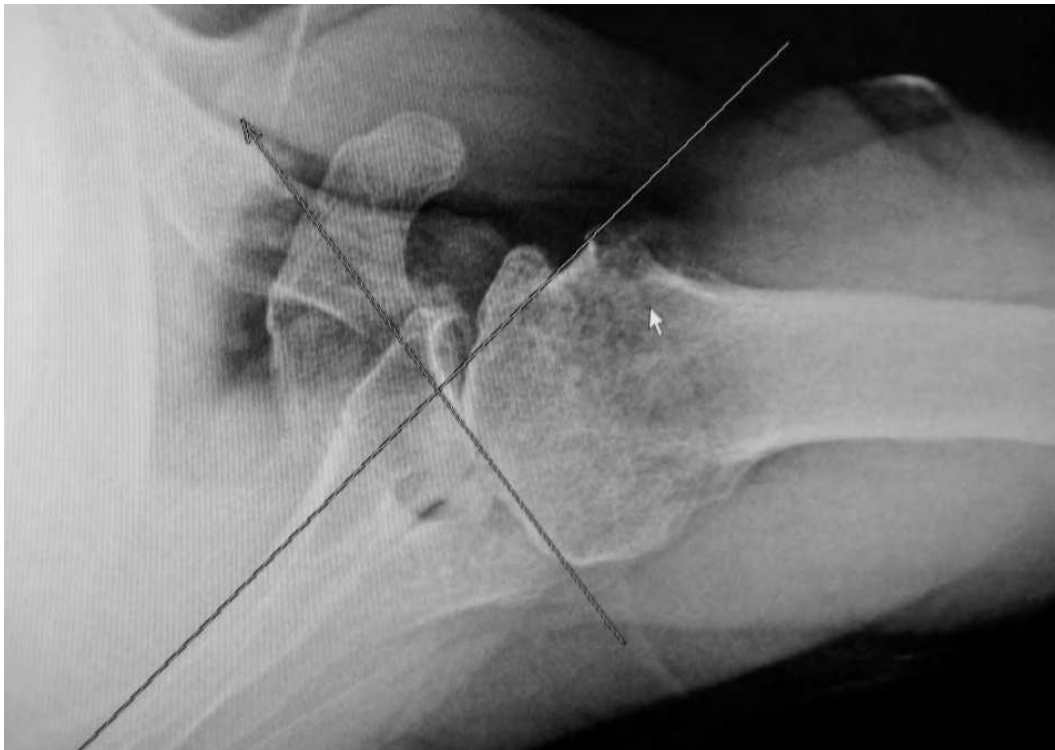

Fig. 4. Axillary lateral radiograph showing double concavity, posterior glenoid erosion and posterior humeral subluxation. Preoperative planning can determine the degree of corrective reaming needed to restore proper glenoid orientation relative to the axis of the scapula

In cases where significant correction is required, precontouring the glenoid with a burr and then using a relatively flatter conventional reamer to start may allow reorientation without as much medialization and subchondral penetration. Some surgeons have advocated under correction of the posterior erosion to maximize the articular surface area of the reamed glenoid.⁴⁴ While undercorrection risks recurrent posterior instability and consequent wear, excessive reaming risks reduced surface area for load distribution. Ultimately, the surgeon needs to make a judgment call intraoperatively after corrective reaming as to whether the concavity can sufficiently replicate the mechanical properties of a normal glenoid to provide lasting pain relief, stability and unrestricted function.

3.4 Center of rotation

Because the humeral head is nearly spherical, it has a center of rotation, which is slightly medially and posteriorly offset from the axis of the humeral shaft. In the normal shoulder this rotation center is aligned with center of the glenoid concavity. This phenomenon has been termed glenohumeral register.⁴⁴ This center of rotation actually exists within a larger arc of a sphere created by the coracoacromial arch and coracoid process – a boundary which partially constrains glenohumeral motion and helps define the path of rotation.(Figure 5) The motion of the humeral articular surface on the glenoid face can actually be described as slippage of the surfaces relative to one another. The centering point on the glenoid can thus be thought of as a slippage point. In the normal shoulder, this point is slightly inferior and anterior to the midpoint of Saller's line which bisects the glenoid along its superior to inferior axis.

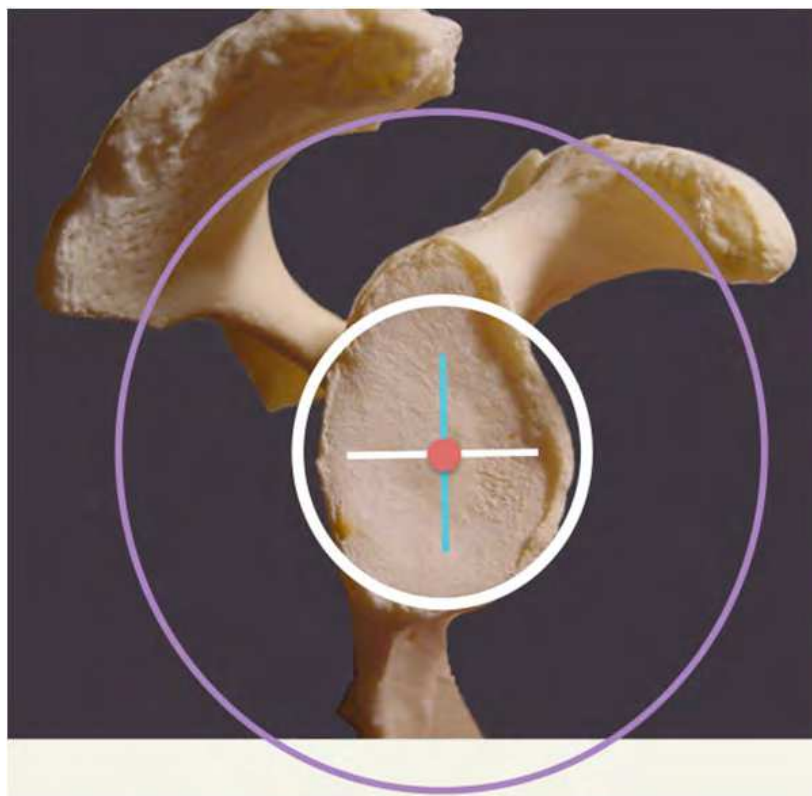


Fig. 5. The centering point on the glenoid is defined by the larger sphere created by the coracoacromial arch. The point is slightly inferior to the center of a line connecting the superior and inferior margins of the glenoid.

Anatomical reconstruction of the proximal humerus seeks to reestablish the head to tuberosity and head to shaft relationships and to replace a head of similar diameter and thickness. In a perfect world, this should restore the proper center of rotation though prior studies have shown that there can be significant displacement of the rotation center depending on how the chosen system fits relative to a given patient's anatomy.^{45, 46} (Figure 6) This displacement has the potential to affect the location of the slippage point on the glenoid face and how the motion of the glenohumeral joint is defined by its location with fornx humeri.

When the glenoid is spherically reamed, the surgeon is effectively choosing a centering point for slippage of the humeral prosthesis. Much of the time in conventional shoulder arthroplasty, this point is chosen by looking at what appears to be the deepest point of the existing concavity. Current techniques and technology do not allow the reconstructed center of rotation of the humerus to chose it's proper slippage point that the surgeon can then use as the centering point for the reaming. The finding on failed glenoid retrievals that wear to conformity occurs at a point other than the geometric center of the prosthetic glenoid concavity, suggests that the humeral head is seeking ball and socket kinematics as defined by placement of the reconstructed humeral rotation center within the fornx humeri. Thus, one can presume that optimal registration between the rotation center of the humeral arthroplasty and the center of the reamed glenoid concavity would result in a blend of kinematics, stability and load distribution that would lend itself to long-term maintenance of pain relief and function.

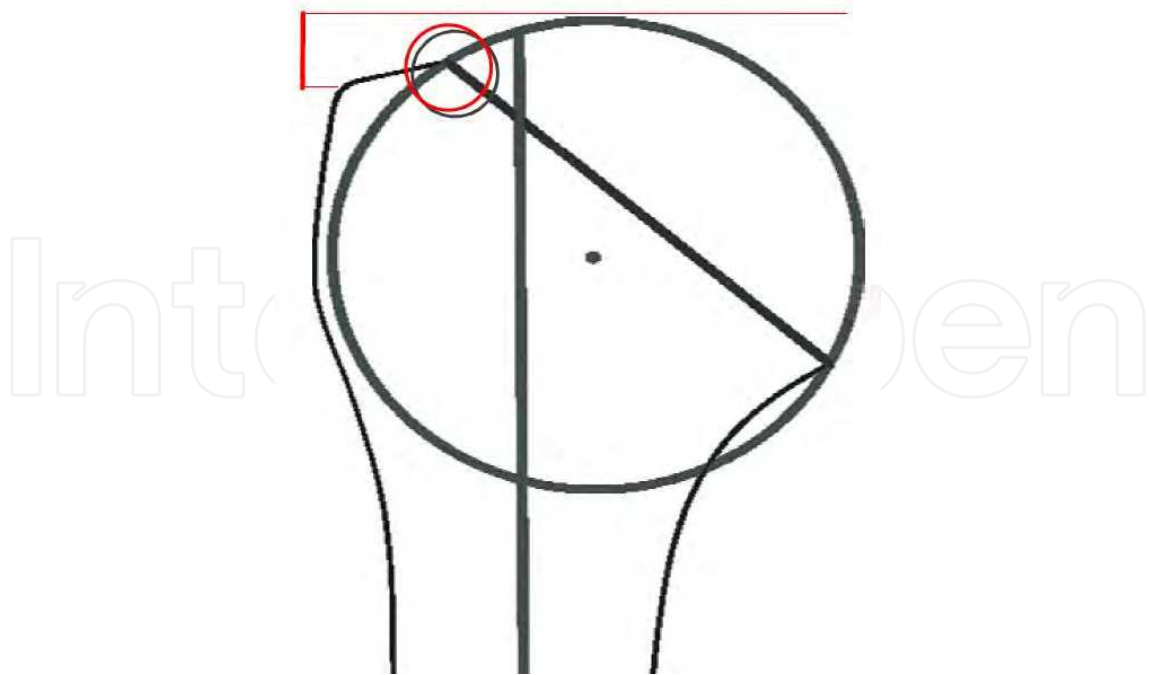


Fig. 6. Anatomical prosthetic reconstruction of the proximal humerus should seek to restore the center of rotation relative to the axis of the humeral shaft and the transition between the superior articular surface of the head with the insertion of the articular side of the rotator cuff on the greater tuberosity

In the absence of a scientific method to register the humeral reconstruction with the slippage point on the reamed glenoid, the shoulder arthroplasty surgeon must resort to preoperative planning, intraoperative observation, precise surgical technique and perhaps a bit of good fortune. While the reamed glenoid bone is not as compliant as articular cartilage, it does have the capacity to adapt and remodel according to its mechanical environment and thus, over time there may be some forgiveness to a small margin of error through a process of bedding-in wear.

4. Indications

Proper patient selection is critical to achieving desired results after this procedure. Selection is based both on anatomical and physiological considerations as well as emotional and social aspects of the patient. Foremost, patients with inflammatory arthritis are not candidates for this technique as the absence of a prosthetic glenoid will result in continued glenoid erosion following humeral hemiarthroplasty. Female patients also tend to have less predictable results. This likely relates to having lower bone density and its effect on the potential for continued glenoid pain after reaming and humeral resurfacing. For male patients with osteoarthritis, the following selection criteria must be carefully considered for optimal results:

4.1 Patient factors

1. *Age:* there are no strict age limitations. This technique is ideally suited for younger patients whose age and activity level predict glenoid failure relative to their average life expectancy. For patients older than 65 years, standard total shoulder arthroplasty is more likely to yield a predictable good to excellent result and is the preferred operation

- unless patients specifically request to forgo glenoid resurfacing after discussion of the options. For the occasional older patient in this category who remains physically very active and engaged in “at risk” activities, non-prosthetic glenoid arthroplasty may be an option if other criteria are met.
2. *General Health Status*: optimal health is critical to good results after any procedure but particularly the Ream and Run. Patients with multiple comorbidities, especially those that may impair tissue healing are likely not suitable candidates for this procedure. Poorly controlled diabetes, poor nutritional status and medical problems that require the use of immunosuppressive drugs are contraindications. If there is concern about general health and nutritional status, blood work including absolute lymphocyte count (<1500 cells/mm³), serum transferrin level (<200 mg/dL) and albumin level (<3.5 g/dL) can be used to screen patients who may benefit from further optimization or consultation with a nutritionist prior to the procedure. For patients with diabetes the glycosylated hemoglobin (HgA1C) can be used to screen for glycemic control, which correlates with risk for infection and healing potential. Ideally this value should be below 7.0 for optimal healing potential. If patients are well above this mark, surgery should be delayed until their diabetes can be better controlled throughout the perioperative period
 3. *Expectations*: experience has shown that recovery after this procedure generally takes longer than for a standard shoulder arthroplasty as healing of the reamed bone may progress and mature for 6 months or more and range of motion can improve for up to a year in motivated individuals. Achieving good range of motion is critical to outcomes for the Ream and Run as residual stiffness can lead to altered glenohumeral kinematics due to obligate capsular mediated translations – similar to the pathomechanics of primary shoulder osteoarthritis. Thus, patients who wish to pursue this alternative must be willing to accept a more prolonged recovery and must be sufficiently motivated to comply with the rehabilitation program including maintenance home exercises. Patients should also have exhausted all conservative measures and demonstrate sufficient pain, disability and joint degeneration to justify arthroplasty.
 4. *Social History*:
 - a. *Smoking*: the dystrophic effect of smoking on tissue healing makes this a contraindication to the Ream and Run. Patients who wish to undergo this operation must be in optimal physical and nutritional health. Serum cotinine levels can be used as a method to ensure smoking cessation.
 - b. *History of narcotic habituation or chronic pain*: patients with a history of heavy regular use of narcotic medications are less likely to have a desirable outcome after the Ream and Run due to the potential for a more prolonged recovery process. These patients need to be appropriately counseled and advance and provisions should be made in advance of surgery to enlist a pain management specialist who can help steadily wean patients from narcotics as the healing progresses.
 - c. *Worker's Compensation claim or litigation*: as has been documented with many other conditions and surgeries, patients involved in a compensation claim or those litigating an injury invariably have worse outcomes after a surgical procedure. To the extent that the salvage of a failed Ream and Run requires prosthetic glenoid resurfacing, the results which are itself inferior in the revision setting, primary total shoulder arthroplasty or other surgical alternatives should be considered.

5. *Emotional History*: patients with ongoing poorly controlled mental health issues are not optimal candidates for this procedure. If patients have symptoms and disability out of proportion to the clinical scenario, have fibromyalgia or a significant poorly defined myofascial component to their pain or if patients have fallen victim to the disease construct of their condition, they are not likely to fair well with the Ream and Run procedure. The optimal patient has demonstrated a balanced self-management approach to their condition, has continued to remain active and engaged despite their physical limitation, and has demonstrated the emotional capacity to deal with the pain and life-altering nature of their diagnosis. Self-assessment scores can sometimes provide a useful window on a patient's emotional state. For instance, those patients who circle "No" on all 12 questions of the Simple Shoulder Score have a self-perceived disability that likely supersedes their actual physical limitation and their outcome after the Ream and Run will be uncertain. If a patient enters a "12" on a 0-10 Visual Analog Pain Scale, one should be concerned about the potential success of the Ream and Run.

4.2 Anatomy factors

1. *Glenoid Erosion and Morphology*: the success of Ream and Run hinges on the ability of the surgeon to achieve a smooth concavity that is oriented perpendicular to the native glenoid centerline. Preservation of subchondral bone leads to more predictable outcomes. In cases with preoperative posterior glenoid erosion, double concavity and/or posterior humeral subluxation, careful preoperative templating must be performed based on CT imaging to determine whether corrective reaming will compromise the aforementioned goals. Moderate correction often results in medialization of the glenoid, which not only reduces the surface area of the concavity but also may penetrate into the cancellous bone of the glenoid vault. In such cases, placement of a prosthetic glenoid component is recommended as hemiarthroplasty alone may result in postoperative erosion into the softer bone with consequent persistent glenoid pain. Patients noted to have decentering of the humeral head with glenoid erosion must be counseled preoperatively about the possible need for standard total shoulder arthroplasty pending the appearance of the glenoid after corrective reaming.
2. *Soft-tissue balance*: because younger patients with glenohumeral arthritis may have a variety of different arthritis types including post-traumatic and post-capsulorrhaphy arthropathy, there may be alteration of the soft-tissue anatomy from prior anatomy altering surgery. This is particularly the case for patients who may have undergone a prior Bristow or Latarjet type coracoid transfer in whom there can be significant scarring in the subscapularis and conjoint tendon region. If surgical releases are not able to result in a balanced soft tissue envelope that permits a wide range of motion, persistent postoperative stiffness may result in obligate translations that cause recurrent eccentric glenoid wear. Thus, a careful understanding the patients pre-operative anatomy and prior surgical history is critical to forecasting the success of the Ream and Run.
3. *Proximal humeral anatomy*: achieving an anatomical reconstruction of the proximal humerus is equally important to recentering the humeral head into a properly oriented and shaped concavity. A modern arthroplasty system that allows accurate and reliable reproduction of the native shoulder anatomy is essential and care must be taken to restore the proper relationships between the head, tuberosities and shaft in terms of the joint center of rotation and cuff insertion. A resurfacing cap may be used as an

alternative if surgeons are capable of achieving adequate glenoid exposure without humeral head osteotomy. If sequelae of prior trauma have resulted in alteration of the normal proximal humeral anatomy, specifically the head-tuberosity relationship, the surgeon must understand through appropriate imaging how this may affect the goal of achieving an anatomical reconstruction in terms of the position of the arc of the humeral convexity, center of rotation and soft-tissue balance.

5. Necessary equipment

In order to restore proper load bearing mechanics at the glenohumeral articulation, the reamed glenoid must be sufficiently concave to ensure stability, and sufficiently conforming to avoid load concentration over a small area. Thus, custom-made reamers are necessary so that there is a corresponding reamer for each humeral head diameter. (Figure 7) In order to avoid too much constraint and permit physiological glenohumeral translations, a 2mm mismatch between head diameter and reamer diameter has become the convention, as previously discussed. Thus, if the chosen head size is 52mm, a custom reamer with a diameter of curvature of 54mm is used for glenoid reaming. These reamers should enlarge in circumference as their diameter enlarges in order to contact the surface area of the native glenoid. Cannulated reamers are preferable in that they can follow a pre-drilled K-wire oriented along the glenoid centerline. This greatly improves the accuracy of the reaming process when correction is needed. An open blade reamer design is also beneficial since it allows the surgeon to see the area of bone that has been reamed during version correction.




Fig. 7. Custom reamers are necessary for the Ream and Run. They should have incremental increases in the diameter of curvature by 2mm and should increase in size to cover a larger area of the glenoid face as the diameter increases. Open blade reamers are helpful in following the degree of correction during the reaming process.

An arthroplasty system of the surgeon's choice can be used with the stipulation that the chosen system allows reliable and reproducible anatomical reconstruction of proximal humeral anatomy. The author currently uses the Synthes EPOCA shoulder system (Synthes,

Westchester, PA), which includes press-fit and cemented stem options and a dual eccentricity design that allows precise placement of the humeral head on the humeral osteotomy surface. This precision improves the accuracy of restoring the humeral center of rotation and head-tuberosity relationship, which is critical in defining soft-tissue balance and proper rotator cuff function.

6. Surgical technique

The patient is positioned in a low beach chair position with the head supported in a cerebellar headrest. The body is shifted toward the operative side so the arm can be extended over the edge of the bed for humeral exposure. A rolled towel is placed beneath the medial scapular border to help orient the glenoid toward the operative field. Unless contraindicated, sterile preparation of the field should employ Choraprep solution, which has demonstrated superior bacteriocidal efficacy relative to other preparations. In addition, circumferential biodrape should be used to occlude the axillary region and cover all exposed skin. Receipt of prophylactic antibiotics must be ensured along with availability of necessary instruments and implants and confirmation of the correct patient, procedure and side.

A standard deltopectoral incision is used though some surgeons prefer a more vertical Bankart type incision in Langer's lines. The cephalic vein is taken laterally with the deltoid and the interval is developed from the clavicle to the pectoralis tendon. We do not routinely take down the pectoralis tendon unless necessary for exposure. The deltoid should be reflected off the coracoacromial ligament to facilitate exposure. The claviopectoral fascia should be excised en bloc from the inferior edge of the CA ligament superiorly to the superior edge of the pectoralis major tendon inferiorly and from the lateral border the conjoint tendon medially to the medial border of the anterior deltoid laterally. This opens the humeroscapular motion interface. A curved deltoid retractor such as a Browne's or delta Fukuda is placed behind the humeral head and a right-angle retractor such as Army Navy beneath the conjoint tendon.

The bicipital groove is opened and the biceps is sutured to the traversing pectoralis major tendon to maintain proper length and tension. It is then tenotomized in the rotator interval. The superior and inferior borders of the subscapularis are then dissected out, cauterizing or ligating the circumflex vessels. The author prefers a lesser tuberosity osteotomy for management of the subscapularis. This is done with a broad curved osteotome and started at the deepest portion of the bicipital groove. The tendon-bone fragment is tagged with suture. A curved blunt Hohman retractor is then placed along the anterior inferior humeral head and this is used to tension the humeral insertion of the inferior glenohumeral capsule-ligamentous complex. This is then released subperiosteally with progressive external rotation, and this release can be follow around to the humeral bare area posteriorly. This release greatly facilitates surgical dislocation of the humeral head.

Prior to dislocation of the humeral head, a lamina spreader type instrument can be used to distract the glenohumeral joint. This tensions the posterior capsule allowing superior visibility for thorough capsulotomy along the length of the posterior glenoid. A thorough release of the posterior capsule facilitates posterior humeral subluxation during glenoid exposure. Although some surgeons advocate selective capsular releases depending on the degree of preoperative humeral posterior subluxation, the author does not feel that capsular tissues play a role in glenohumeral stability except during the extremes of range of motion provided an adequate concavity is restored along the axis of the scapula and proper

humeral retrotorsion is selected. In the author's personal series, circumferential capsular releases have never resulted in postoperative posterior instability but do improve range of motion during the early recovery. If there is a concern about posterior laxity, the rotator interval can be closed slightly more medially to provide a checkrein against posterior translation at the conclusion of the case.

The humeral osteotomy is then made along the anatomical neck generally in 25-30 degrees of retrotorsion. It is critical that this cut is flush with the articular-sided insertion of the supraspinatus tendon fibers so the anatomical reconstruction of the head-tuberosity relationship can be properly achieved. (Figure 8) Once the cut is made and refined, osteophytes around the margins of the anatomical neck can be removed, particularly those inferiorly which can cause calcar impingement with the inferior glenoid if not cleared out. A head diameter that best covers the osteotomy surface is then chosen. It is best to err toward the smaller size assuming there will be no uncovered bone that would impinge during glenohumeral rotation.

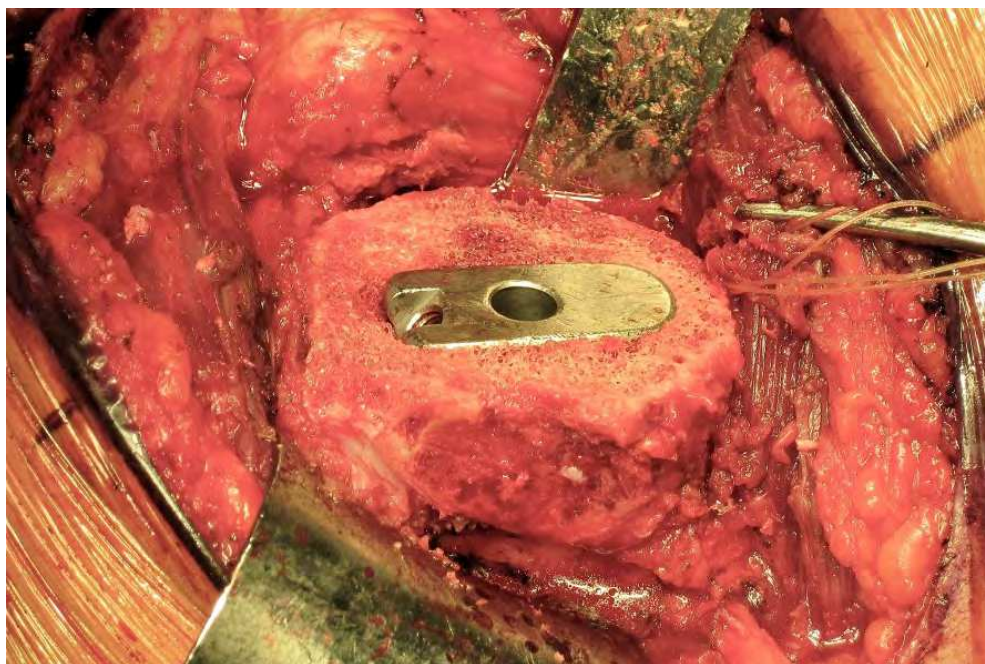


Fig. 8. The humeral osteotomy should be flush with the insertion of the supraspinatus tendon to restore the head-tuberosity relationship. The trial stem should be positioned to restore humeral retrotorsion of approximately 25-30 degrees.

If a stemmed arthroplasty is to be used, the humeral canal can then be prepped via the conventions of the given system and a trial stem placed. If a cap prosthesis is chosen, then the head can be reamed and the cap sized according to the system's technique.

The humerus is then sublaxed posteriorly using a Fukuda or similar retractor. A complete circumferential release of the subscapularis can now safely be performed. The interval between the anterior capsule and inferior muscular fibers of the subscapularis is developed with Metzenbaum scissors allowing safe release of the anterior capsular from the glenoid rim and release of adhesions to the coracoid base. All adhesions should be released so that external rotation can be restored. The surgeon should feel a soft bounce when the subscapularis is pulled laterally. A blunt Hohman or spiked ribbon retractor can then be placed medially within the subscapularis fossa with the tendon and lesser tuberosity tucked medially behind it. This should allow full visualization down the anterior face of the scapular body, which is critical for restoring orientation of the glenoid concavity.

The inferior capsule is then release sharply in an extra labral fashion keeping the knife parallel to and against bone. Care should be taken to completely release the insertion of the anterior inferior and posterior inferior glenohumeral ligament from its glenoid-sided insertion. The author believes that selective capsular releases are never indicated assuming that the glenoid version is properly corrected and an adequate concavity is restored. The Fukuda retractor ring can be twisted off of the inferior glenoid rim to facilitate release of the posterior inferior capsule. Once a sufficient release has been performed, adequate glenoid exposure should permit insertion of the glenoid reamers. Internal rotation (rather than the conventional external rotation) can sometimes facilitate posterior humeral subluxation. Release of the coracohumeral ligament is sometimes necessary to improve glenoid exposure by further allowing the humerus to translate posteriorly.

The center of the existing glenoid concavity is then determined. The author uses a curved backed drill guide to help find the centering or slippage point. If there is a double concavity present, or if there is significant posterior glenoid erosion, the centering point often needs to be shifted somewhat anteriorly to properly restore glenoid version by reaming the high side. Any central ridges can be burred in advance to provisionally restore a concavity. In cases of significant posterior glenoid wear or double concavity, a flatter reamer can be used for provisional reshaping prior to definitive reestablishment of the concavity.

Once the centering point has been determined, a threaded-tipped Steinmann pin is drilled parallel to the glenoid centerline.(Figure 9) Because the scapular is a curved structure, this pin

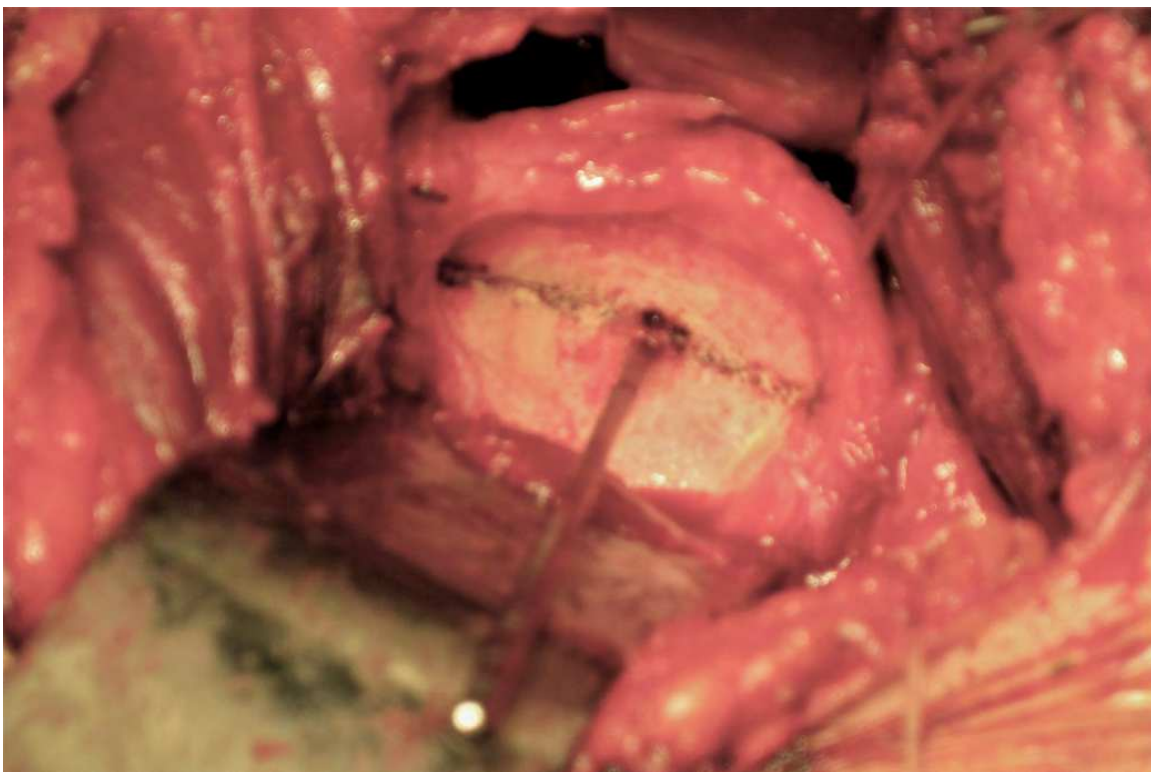


Fig. 9. The glenoid labrum is preserved during glenoid exposure and capsular releases. The centering point for the is determined and a threaded-tipped Steinmann pin is drilled to reorient the glenoid so that it is retroverted roughly 10 degrees relative to the axis of the scapular body.

should exit the anterior glenoid neck between the upper and lower crurae of the subscapularis fossa. The author uses the convention of being able to palpate the pin tip when the PIP joint of the index finger is placed against the anterior glenoid rim. If it exists too anteriorly then reaming will result in persistent retroversion that can lead to posterior instability.

Once the pin is properly positioned, the cannulated reamer can be introduced. The blades should be spinning prior to contact with the bone and the glenoid should be progressively reamed until circumferential contact occurs and a full concavity is achieved. (Figure 10) The goals of reaming are: 1) to restore glenoid version; and 2) to restore a smooth concavity. Once these goals are achieved, the surgeon must inspect the glenoid surface, the bone quality, the surface area and the degree of medialization that occurs from correction. If corrective reaming results in significant medialization, exposure of cancellous bone within the glenoid vault or loss of surface area as the glenoid narrows, placement of a glenoid prosthesis may be necessary. Ideally, there should be firm subchondral bone to support the humeral prosthesis.

Next a small drill is used to make multiple perforations in the reamed glenoid face. This serves two purposes.(Figure 11) Firstly, it decompresses the venous congestion than can occur in arthritic bone, which may improve pain relief. Secondly, it permits egress of bone marrow stem cells to help reform a fibro-cartilaginous coating on the reamed glenoid face.

The final humeral prosthesis is then inserted according to the specifications of the system. It is critical that the humeral head be optimally positioned to restore the center of rotation of the joint and to restore the proper head-tuberosity relationship.(Figure 12)

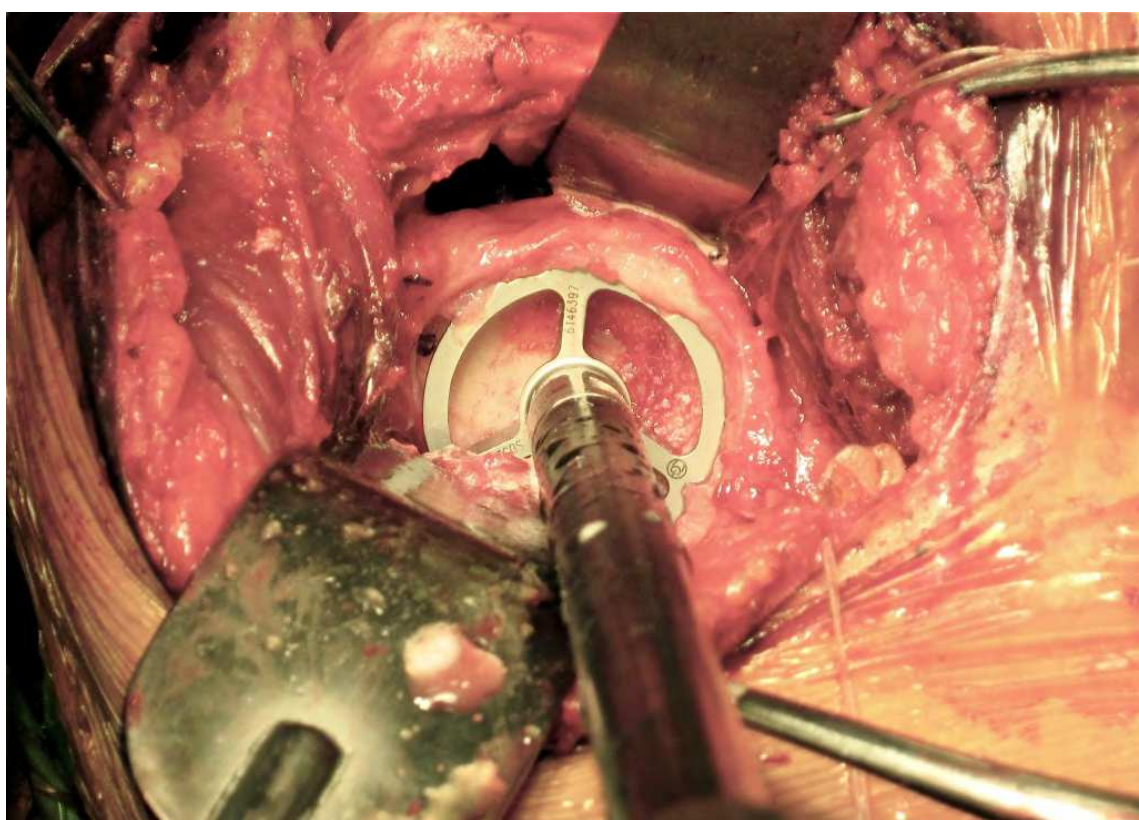


Fig. 10. The chosen reamer is introduced and the glenoid reamed until a smooth concavity is achieved.

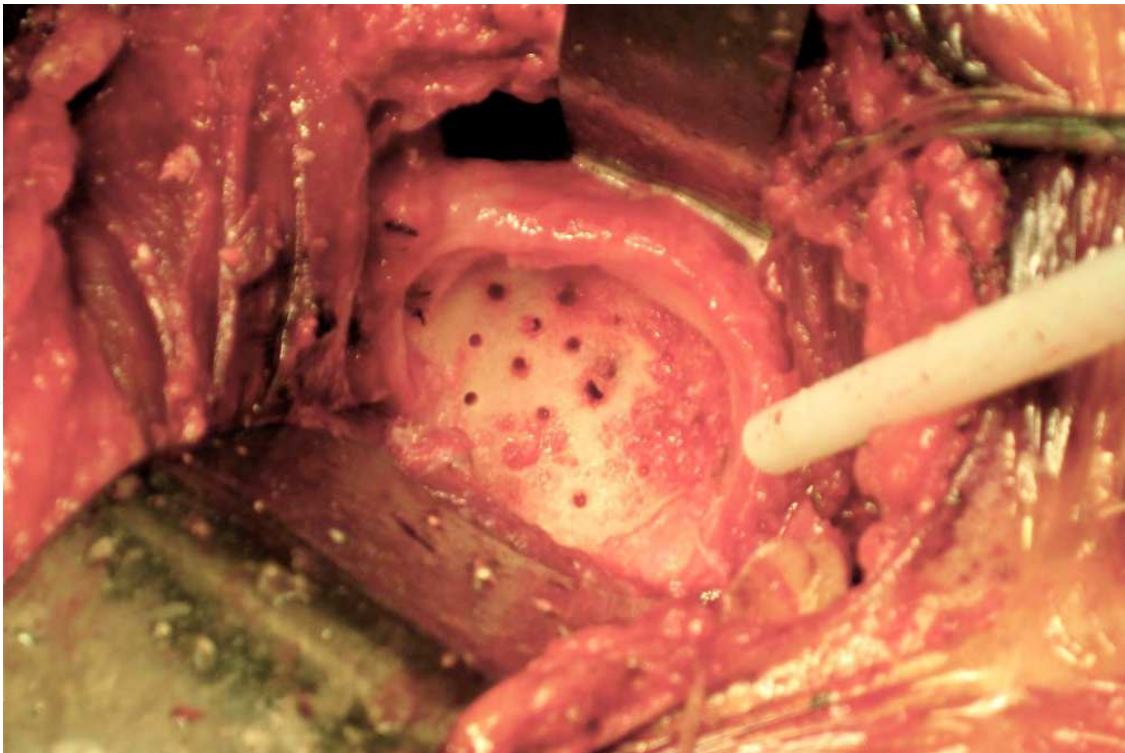


Fig. 11. Multiple holes are drilled into the reamed glenoid to decompress venous congestion and promote egress of stem cells to promote fibrocartilage formation.

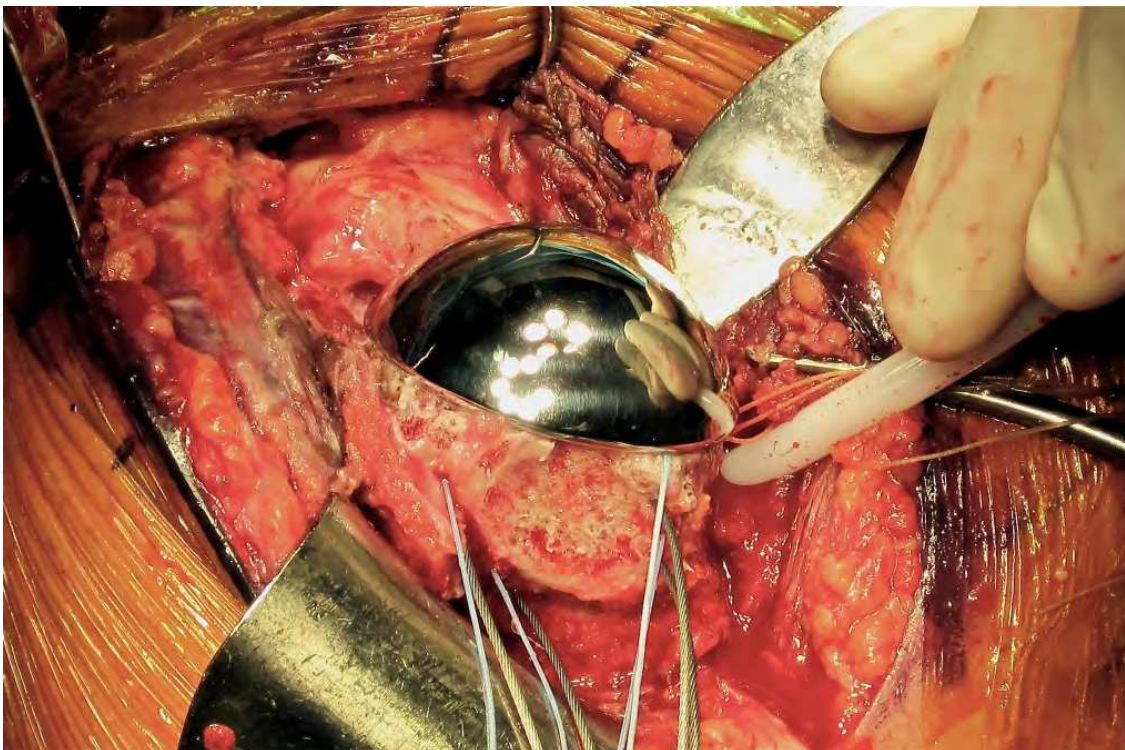


Fig. 12. The humeral head must achieve anatomical reconstruction with regard to coverage of the osteotomy and restoration of the head-shaft and head-tuberosity relationship. The head should have an anatomical height that does not overstuff the joint.

Excess anterior and posterior overhang must be avoided and there should be smooth transition at the calcar that prevents bony impingement in this region. A head thickness that corresponds to normal anatomy should be chosen. If the system used provides 3 offset options for each diameter, it is best to choose the middle size to prevent over or under stuffing of the joint. Conventional on-table measurements of passive translation are not helpful in determining proper soft tissue tension as they do not correlate with dynamic stability in the mid range of motion after surgery. It is best to err toward the looser side with the Ream and Run as it facilitates recovery of motion which is critical to outcomes and it does not correlate with postoperative instability assuming the glenoid has been properly corrected.

A secure subscapularis repair is essential to permit early range of motion. The author currently uses the technique described by Millett et al using cerclage sutures looped around the humeral stem.⁴⁷ If a porous ingrowth stem is used, the author uses two 1mm cables instead because micromotion of the sutures against the stem coating will result in suture rupture. (Figure 13) These cables are supplemented by a suture tension band construct tied over a cortical button lateral to the bicipital groove. If cables are used, the crimps are positioned in the bicipital groove and covered over by the biceps tendon to prevent soft-tissue irritation. The lateral part of the rotator interval is then closed. If there is concern about posterior instability, additional interval sutures can be placed more medially though this may compromise external rotation and potentially decentralize the humeral head.

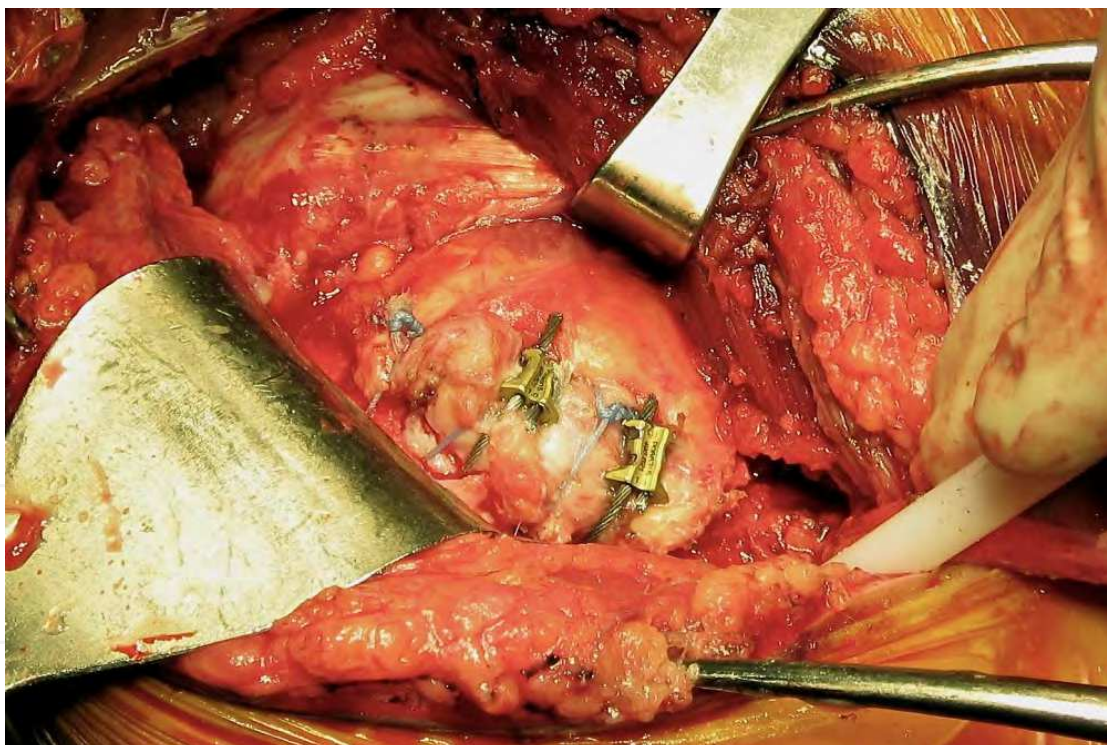

Fig. 13. A secure repair of the subscapularis is essential regardless of the technique. In this picture, horizontal cerclage cables have been used to compress the lesser tuberosity fragment to its osteotomy bed.

7. Post-operative protocol

Immediate range of motion exercises are begun under the supervision of the therapist. Forward elevation to 140 degree and external rotation to 40 degree is allowed along with

external rotation isometrics, scapular pinches and cervical and elbow range of motion. Patients are instructed on how to perform active-assisted range of motion exercises and encouraged to do so several times daily. Positional exercises, such as placing the arm on the rest of a couch are also permitted. This holds a static position of stretch for a period of time that does not jeopardize the repair. Most patients are discharged from the hospital with home services and transition to outpatient therapy after their first postoperative visit around 10-14 days.

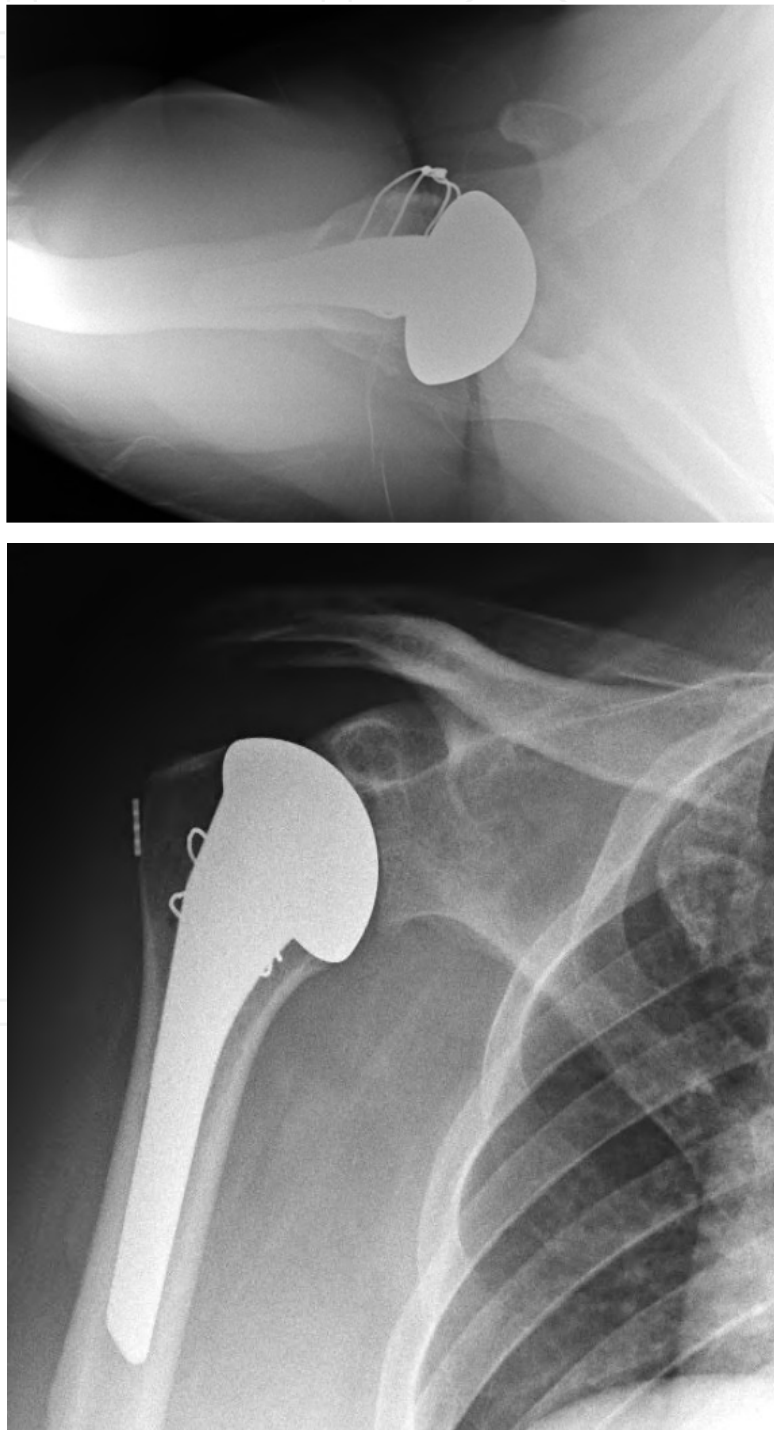


Fig. 14. A and B: Postoperative AP and axillary lateral radiographs demonstrating anatomical reconstruction of the humerus with creation of a smooth concavity.

Around 4 weeks, progressive return to maximal range of motion is permitted and exercises such as wall walks can be added. Active internal rotation is discouraged to protect the subscapularis. Patients are instructed to still limit use of the arm for physical activities and focus on flexibility.

At 8 weeks, the focus continues on maximizing range of motion. The subscapularis repair must still be protected from active internal rotation but patients can begin some posterior capsular stretching and light deltoid, trapezius and periscapular strengthening.

Assuming adequate progress and a negative belly-press test at 12 weeks, patients can start internal rotation strengthening and progressive use of the arm for normal daily activities. Return to physically demanding activities and sports requires at least 4 or more months to ensure and adequately healed subscapularis

In the author's experience in trying to accelerate the rehabilitation protocol, the subscapularis must be protected at all costs. Rupture can occur all the way out to three months despite what appears to be a very durable repair at the time of surgery. Rupture tends to occur from overzealous therapy or patient non-compliance and thus both parties must be educated about realistic goals and expectations during the early recovery.

By six months after surgery a full range of activities are permitted as tolerated by the patient's comfort and demands. Given the absence of concern about failure of a prosthetic glenoid, no specific restrictions are placed on patients activities. Maintenance stretching and strengthening exercises are strongly encouraged for up to 2 years as pain relief, motion and function seem to go hand-in-hand in their potential to improve throughout this prolonged interval.

8. Complications

Complications of shoulder arthroplasty are well-documented and the Ream and Run is no exception to the conventional and well-accepted adversities that can occur from any open shoulder surgery such as infection and axillary nerve injury. The following discussion will focus on complications that are particularly pertinent though not exclusive to the Ream and Run procedure.

8.1 Glenoid wear and erosion

As has been previously discussed, overzealous reaming or the need for excessive glenoid version correction can result in penetration of the subchondral plate and exposure of cancellous bone in the glenoid vault. It can also result in narrowing of the anterior-posterior dimensions of the glenoid concavity, which reduces the overall surface area for contact stress distribution and predisposes to instability. In these situations, patients will continue to experience pain following humeral hemiarthroplasty and may demonstrate recurrent glenoid erosion both medially and posteriorly. Thus patient selection and work-up are critical to predicting who is the ideal candidate likely to have a good outcome and all patients must be counseled about the potential need for glenoid replacement if the principles and goals of non-prosthetic glenoid arthroplasty cannot be met intraoperatively. Rhee and colleagues have shown that the results of salvage glenoid replacement after failed hemiarthroplasty are inferior to primary total shoulder arthroplasty.⁴⁸ This highlights the importance of doing the right operation the first time around.

8.2 Subscapularis rupture

Despite the added security afforded by lesser tuberosity osteotomy, failure can still occur if undue stress is placed on the repair. While the contention maintains that lesser tuberosity

osteotomy allows bone to bone healing, this is not guaranteed in all cases. Micromotion at the repair site may stimulate a fibrous union, and release of the subscapularis intraoperatively may disrupt the blood supply to this fragment resulting in avascular necrosis of the lesser tuberosity and inability to heal directly by bony union. While this has not been previously reported in the literature, the author has had occasion to explore 4 cases in which the lesser tuberosity repair ruptured after surgery as detected clinically and radiographically. In all cases, the bone was sclerotic and devoid of any bleeding when drilled at the time of re-repair. Future studies will need to better determine the biology of lesser tuberosity healing but until more is known about how to optimize this process, erring on the side of caution is the safest route to avoid the devastating complication of subscapularis failure. This fact is true regardless of the method of tendon repair used. Because these patients tend to be more active and aggressive in terms of lifestyle pursuits, they need to be educated in terms of recovery expectations so that their ambitions do not compromise their compliance with the recovery protocol.

8.3 Stiffness

Recovery of range of motion is critical to outcomes after the Ream and Run procedure. Residual stiffness will result in obligate, capsular-mediated translations that equate to the same pathomechanics resulting in posterior humeral subluxation and glenoid erosion. The author believes that in all cases, aggressive circumferential capsular releases are necessary to restore motion and selective releases for fear of instability are never indicated. Capsular-mediated stability only occurs at the terminal range of motion, which is never a concern in the first 3 months after surgery when the capsule is reforming around the prosthetic joint. Stability in the mid-range is a function of a properly oriented glenoid concavity of sufficient area and a functional rotator cuff. Surgeons should not rely on intraoperative tests of joint stability that measure capsular tension as they are largely irrelevant assuming a properly performed reconstruction.

Given the prior discussion about subscapularis failure, range of motion exercises must be a graduated process that focuses more on frequency than exertion for the first several weeks. Patients must take an active but responsible and educated role in their own recovery and they must understand the potential consequences of noncompliance. This is a delicate balance that requires pre and postoperative education from both the surgeon and therapist. The author has also found it invaluable to identify one or two therapists who take an interest in shoulder arthroplasty and have a better understanding of how to achieve desired results. As with any discipline, frequency, volume and practice beget experience and results in this regard.

9. Results

When patient selection is combined with surgical technique that achieves the principles of Ream and Run, outcomes can be comparable to total shoulder arthroplasty in terms of pain relief, range of motion and function. Given that no specific restrictions are placed on patients postoperatively, results in terms of return to physically demanding leisure time physical activities can be outstanding. Patients have returned to sports such as water skiing, weight lifting, competitive tennis, and other outdoor pursuits. As many of these patients previously engaged in activities that may have contributed to early glenohumeral degenerative disease, the ability to return to similar activities, albeit in a modified setting, is a significant improvement in their health-related quality of life.

The author currently performs the Ream and Run procedures in roughly 8% of all arthroplasty cases. Generally, it is reserved for male patients aged 65 or less who meet the criteria previously discussed and who understand and accept the longer recovery in favor of the absence of restrictions. Between 2004-2010, 55 Ream and Run cases have been performed in 52 patients ranging in age from 42-68 years (average 56 years). This series has included 50 males and 2 females. Although formal outcome measures have not been performed on this consecutive series, 5 patients have required additional surgery. Two patients underwent revision glenoid resurfacing for recalcitrant pain with recurrent posterior erosion at 16 and 26 months after the index procedure. One of these patients was female. The other was subsequently determined to have inflammatory osteoarthritis. Two patients underwent repair of a partial subscapularis rupture both of whom were noted to have a smooth, remodeled concavity with rests of fibrocartilage at the time of exploration 3 and 47 months postoperatively. One patient underwent explantation of the humeral prosthesis due to deep infection with *Staph. Epidermidis*. This patient was subsequently revised to a standard total shoulder arthroplasty after interval placement of an antibiotic cement spacer and parenteral antimicrobial treatment. Two additional patients have complained of persistent pain but have elected not to undergo further surgery. Neither of these patients has demonstrated significant glenoid erosion to suggest that the cause of pain is in fact due to wear at the articulation.

Lynch et al have reported on outcomes of the Ream and Run procedure at mid-term follow-up. In the initial report, 32 of 35 patients demonstrated improved function regaining an average of 4.5 functions on the Simple Shoulder Test (SST).⁴⁹ Overall average SST score improved from 4.7 to 9.4 at 2-4 years follow-up. Sequential improvement in function was noted all the way up to 36 months after surgery. Patients who had radiographic evidence of a joint space on postoperative x-rays had better outcomes indicating that presumed formation of a fibrocartilage interface correlates with better pain relief and improvement in function. Clinton et al in a similar series demonstrated outcomes comparable to a matched set of patients undergoing total shoulder arthroplasty.⁵⁰ Again, functional outcomes for those patients undergoing the Ream and Run were noted to improve sequentially out to 3 years postoperatively.

Recently, Saltzman et al reported on outcomes of the Ream and Run in patients aged 55 years or younger. In terms of pre versus postoperative comparative SST, 53 of 56 patients were improved to a degree comparable to patients who underwent a total shoulder arthroplasty by the same surgeon.⁵¹ Patients with mild preoperative glenoid erosion did not demonstrate progression while one patient with moderate erosion progressed to severe erosion. Average medial glenoid erosion measured 1.1 mm at an average of 44 months with the worst case measuring 6.3mm. Nine of 65 shoulders required revision including 4 (6%) conversions to a total shoulder for painful glenoid wear. Patients who underwent revision surgery tended to have a more complicated preoperative course including more severe functional deficits to overcome and a higher incidence of multiple prior surgeries.

Collectively, these results are comparable or superior to previously discussed literature looking at hemiarthroplasty alone or biological resurfacing techniques in this age cohort.^{23, 25, 29, 33, 52} As our experience with this technique grows, patient selection criteria, indications and techniques have been refined to reflect potential modes of failure and their risk factors. As with all of orthopedics, the right operation for the right problem in the right patient is the key to success. The shoulder arthroplasty surgeon must carefully evaluate each candidate clinically, radiographically and in terms of compliance and expectations. When proper surgical technique is applied to right clinical setting the results of the Ream and Run can be

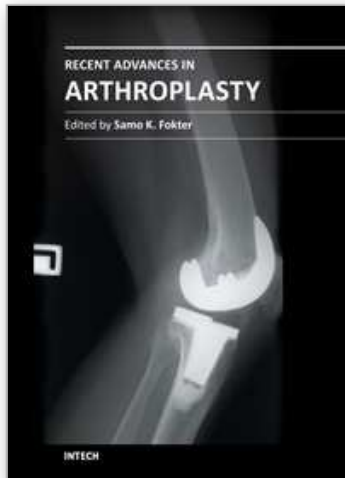
both impressive and lasting and should be a tool in the shoulder surgeons armamentarium for management of advanced arthritis in the young and active patient.

10. References

- [1] Farron A, Terrier A, Buchler P. Risks of loosening of a prosthetic glenoid implanted in retroversion. *J Shoulder Elbow Surg.* 2006;15:521-526.
- [2] Oosterom R, Rozing PM, Verdonschot N, Bersee HE. Effect of joint conformity on glenoid component fixation in total shoulder arthroplasty. *Proc Inst Mech Eng H.* 2004;218:339-347.
- [3] Hopkins AR, Hansen UN, Amis AA et al. Wear in the prosthetic shoulder: association with design parameters. *J Biomech Eng.* 2007;129:223-230.
- [4] Braman JP, Falicov A, Boorman R, Matsen FAR. Alterations in surface geometry in retrieved polyethylene glenoid component. *J Orthop Res.* 2006;24:1249-1260.
- [5] Hertel R, Ballmer FT. Observations on retrieved glenoid components. *J Arthroplasty.* 2003;18:361-366.
- [6] Nho SJ, Nam D, Ala OL, Craig EV, Warren RF, Wright TM. Observations on retrieved glenoid components from total shoulder arthroplasty. *J Shoulder Elbow Surg.* 2009;18:371-378.
- [7] Arnold RM, High RR, Grosshans KT, Walker CW, Fehringer EV. Bone presence between the central peg's radial fins of a partially cemented pegged all poly glenoid component suggest few radiolucencies. *J Shoulder Elbow Surg.* 2011;20:315-321.
- [8] Barwood S, Setter KJ, Blaine TA, Bigliani LU. The incidence of early radiolucencies about a pegged glenoid component using cement pressurization. *J Shoulder Elbow Surg.* 2008;17:703-708.
- [9] Churchill RS, Zellmer C, Zimmers HJ, Ruggero R. Clinical and radiographic analysis of a partially cemented glenoid implant: five-year minimum follow-up. *J Shoulder Elbow Surg.* 2010;19:1091-1097.
- [10] Groh GI. Survival and radiographic analysis of a glenoid component with a cementless fluted central peg. *J Shoulder Elbow Surg.* 2010;19:1265-1268.
- [11] Walch G, Young AA, Melis B, Gazielly D, Loew M, Boileau P. Results of a convex-back cemented keeled glenoid component in primary osteoarthritis: multicenter study with a follow-up greater than 5 years. *J Shoulder Elbow Surg.* 2011;20:385-394.
- [12] Young A, Walch G, Boileau P et al. A multicentre study of the long-term results of using a flat-back polyethylene glenoid component in shoulder replacement for primary osteoarthritis. *J Bone Joint Surg Br.* 2011;93:210-216.
- [13] Kasten P, Pape G, Raiss P et al. Mid-term survivorship analysis of a shoulder replacement with a keeled glenoid and a modern cementing technique. *J Bone Joint Surg Br.* 2010;92:387-392.
- [14] Bartelt R, Sperling JW, Schleck CD, Cofield RH. Shoulder arthroplasty in patients aged fifty-five years or younger with osteoarthritis. *J Shoulder Elbow Surg.* 2011;20:123-130.
- [15] Fox TJ, Cil A, Sperling JW, Sanchez-Sotelo J, Schleck CD, Cofield RH. Survival of the glenoid component in shoulder arthroplasty. *J Shoulder Elbow Surg.* 2009;18:859-863.
- [16] Taunton MJ, McIntosh AL, Sperling JW, Cofield RH. Total shoulder arthroplasty with a metal-backed, bone-ingrowth glenoid component. Medium to long-term results. *J Bone Joint Surg Am.* 2008;90:2180-2188.
- [17] Tammachote N, Sperling JW, Vathana T, Cofield RH, Harmsen WS, Schleck CD. Long-term results of cemented metal-backed glenoid components for osteoarthritis of the shoulder. *J Bone Joint Surg Am.* 2009;91:160-166.

- [18] Boileau P, Avidor C, Krishnan SG, Walch G, Kempf JF, Mole D. Cemented polyethylene versus uncemented metal-backed glenoid components in total shoulder arthroplasty: a prospective, double-blind, randomized study. *J Shoulder Elbow Surg.* 2002;11:351-359.
- [19] Cheung EV, Sperling JW, Cofield RH. Reimplantation of a glenoid component following component removal and allogenic bone-grafting. *J Bone Joint Surg Am.* 2007;89:1777-1783.
- [20] Cheung EV, Sperling JW, Cofield RH. Revision shoulder arthroplasty for glenoid component loosening. *J Shoulder Elbow Surg.* 2008;17:371-375.
- [21] Neyton L, Walch G, Nove-Josserand L, Edwards TB. Glenoid corticocancellous bone grafting after glenoid component removal in the treatment of glenoid loosening. *J Shoulder Elbow Surg.* 2006;15:173-179.
- [22] Phipatanakul WP, Norris TR. Treatment of glenoid loosening and bone loss due to osteolysis with glenoid bone grafting. *J Shoulder Elbow Surg.* 2006;15:84-87.
- [23] Burkhead WZJ, Hutton KS. Biologic resurfacing of the glenoid with hemiarthroplasty of the shoulder. *J Shoulder Elbow Surg.* 1995;4:263-270.
- [24] Burkhead WZJ, Krishnan SG, Lin KC. Biologic resurfacing of the arthritic glenohumeral joint: Historical review and current applications. *J Shoulder Elbow Surg.* 2007;16:S248-53.
- [25] Elhassan B, Ozbaydar M, Diller D, Higgins LD, Warner JJ. Soft-tissue resurfacing of the glenoid in the treatment of glenohumeral arthritis in active patients less than fifty years old. *J Bone Joint Surg Am.* 2009;91:419-424.
- [26] Lee KT, Bell S, Salmon J. Cementless surface replacement arthroplasty of the shoulder with biologic resurfacing of the glenoid. *J Shoulder Elbow Surg.* 2009;18:915-919.
- [27] Wirth MA. Humeral head arthroplasty and meniscal allograft resurfacing of the glenoid. *J Bone Joint Surg Am.* 2009;91:1109-1119.
- [28] Nicholson GP, Goldstein JL, Romeo AA et al. Lateral meniscus allograft biologic glenoid arthroplasty in total shoulder arthroplasty for young shoulders with degenerative joint disease. *J Shoulder Elbow Surg.* 2007;16:S261-6.
- [29] de Beer JF, Bhatia DN, van Rooyen KS, Du Toit DF. Arthroscopic debridement and biological resurfacing of the glenoid in glenohumeral arthritis. *Knee Surg Sports Traumatol Arthrosc.* 2010;18:1767-1773.
- [30] Savoie FHR, Brislin KJ, Argo D. Arthroscopic glenoid resurfacing as a surgical treatment for glenohumeral arthritis in the young patient: midterm results. *Arthroscopy.* 2009;25:864-871.
- [31] Gerber C, Snedeker JG, Krause AS, Appenzeller A, Farshad M. Osteochondral glenoid allograft for biologic resurfacing of the glenoid: biomechanical comparison of novel design concepts. *J Shoulder Elbow Surg.* 2011
- [32] Bryant D, Litchfield R, Sandow M, Gartsman GM, Guyatt G, Kirkley A. A comparison of pain, strength, range of motion, and functional outcomes after hemiarthroplasty and total shoulder arthroplasty in patients with osteoarthritis of the shoulder. A systematic review and meta-analysis. *J Bone Joint Surg Am.* 2005;87:1947-1956.
- [33] Sperling JW, Cofield RH, Rowland CM. Minimum fifteen-year follow-up of Neer hemiarthroplasty and total shoulder arthroplasty in patients aged fifty years or younger. *J Shoulder Elbow Surg.* 2004;13:604-613.
- [34] Edwards TB, Kadakia NR, Boulahia A et al. A comparison of hemiarthroplasty and total shoulder arthroplasty in the treatment of primary glenohumeral osteoarthritis: results of a multicenter study. *J Shoulder Elbow Surg.* 2003;12:207-213.

- [35] Lo IK, Litchfield RB, Griffin S, Faber K, Patterson SD, Kirkley A. Quality-of-life outcome following hemiarthroplasty or total shoulder arthroplasty in patients with osteoarthritis. A prospective, randomized trial. *J Bone Joint Surg Am.* 2005;87:2178-2185.
- [36] Levine WN, Djurasovic M, Glasson JM, Pollock RG, Flatow EL, Bigliani LU. Hemiarthroplasty for glenohumeral osteoarthritis: results correlated to degree of glenoid wear. *J Shoulder Elbow Surg.* 1997;6:449-454.
- [37] Matsen FAr, Clinton J, Lynch J, Bertelsen A, Richardson ML. Glenoid component failure in total shoulder arthroplasty. *J Bone Joint Surg Am.* 2008;90:885-896.
- [38] Milgram JW, Rana NA. Pathologic evaluation of the failed cup arthroplasty: a review of 32 cases. *Clin Orthop Relat Res.* 1981;158-179.
- [39] Milgram JW, Rana NA. Roentgenologic and clinical evaluation of vitallium mold arthroplasty of the hip. *Surg Gynecol Obstet.* 1968;127:1042-1050.
- [40] Enneking WF, Singesen ET. Pathologic changes in the idiopathic painful cup arthroplasty. *Clin Orthop Relat Res.* 1974;236-253.
- [41] D'Ambrosia RD, McClain EJ, Wissinger HA, Riggins RS. Resorption of the femoral head beneath the vitallium mold. *Surg Forum.* 1972;23:465-467.
- [42] Weldon EJr, Boorman RS, Smith KL, Matsen FAr. Optimizing the glenoid contribution to the stability of a humeral hemiarthroplasty without a prosthetic glenoid. *J Bone Joint Surg Am.* 2004;86-A:2022-2029.
- [43] Matsen FAr, Clark JM, Titelman RM et al. Healing of reamed glenoid bone articulating with a metal humeral hemiarthroplasty: a canine model. *J Orthop Res.* 2005;23:18-26.
- [44] Clinton J, Warne WJ, Lynch JR, Lippitt SB, Matsen FAr. Shoulder hemiarthroplasty with nonprosthetic glenoid arthroplasty: The Ream and Run. *Techniques in Shoulder and Elbow Surgery.* 2009;10:43-52.
- [45] Pearl ML, Kurutz S. Geometric analysis of commonly used prosthetic systems for proximal humeral replacement. *J Bone Joint Surg Am.* 1999;81:660-671.
- [46] Pearl ML, Kurutz S, Postachini R. Geometric variables in anatomic replacement of the proximal humerus: how much prosthetic geometry is necessary? *J Shoulder Elbow Surg.* 2009;18:366-370.
- [47] Ponce BA, Ahluwalia RS, Mazzocca AD, Gobezie RG, Warner JJ, Millett PJ. Biomechanical and clinical evaluation of a novel lesser tuberosity repair technique in total shoulder arthroplasty. *J Bone Joint Surg Am.* 2005;87 Suppl 2:1-8.
- [48] Rhee PC, Sassoon AA, Schleck CD, Harmsen WS, Sperling JW, Cofield RH. Revision total shoulder arthroplasty for painful glenoid arthrosis after humeral head replacement: the posttraumatic shoulder. *J Shoulder Elbow Surg.* 2011
- [49] Lynch JR, Franta AK, Montgomery WHJ, Lenters TR, Mounce D, Matsen FAr. Self-assessed outcome at two to four years after shoulder hemiarthroplasty with concentric glenoid reaming. *J Bone Joint Surg Am.* 2007;89:1284-1292.
- [50] Clinton J, Franta AK, Lenters TR, Mounce D, Matsen FAr. Nonprosthetic glenoid arthroplasty with humeral hemiarthroplasty and total shoulder arthroplasty yield similar self-assessed outcomes in the management of comparable patients with glenohumeral arthritis. *J Shoulder Elbow Surg.* 2007;16:534-538.
- [51] Saltzman MD, Chamberlain AM, Mercer DM, Warne WJ, Bertelsen AL, Matsen FAr. Shoulder hemiarthroplasty with concentric glenoid reaming in patients 55 years old or less. *J Shoulder Elbow Surg.* 2011;20:609-615.
- [52] Krishnan SG, Reineck JR, Nowinski RJ, Harrison D, Burkhead WZ. Humeral hemiarthroplasty with biologic resurfacing of the glenoid for glenohumeral arthritis. Surgical technique. *J Bone Joint Surg Am.* 2008;90 Suppl 2 Pt 1:9-19.



Recent Advances in Arthroplasty

Edited by Dr. Samo Fokter

ISBN 978-953-307-990-5

Hard cover, 614 pages

Publisher InTech

Published online 27, January, 2012

Published in print edition January, 2012

The purpose of this book was to offer an overview of recent insights into the current state of arthroplasty. The tremendous long term success of Sir Charnley's total hip arthroplasty has encouraged many researchers to treat pain, improve function and create solutions for higher quality of life. Indeed and as described in a special chapter of this book, arthroplasty is an emerging field in the joints of upper extremity and spine. However, there are inborn complications in any foreign design brought to the human body. First, in the chapter on infections we endeavor to provide a comprehensive, up-to-date analysis and description of the management of this difficult problem. Second, the immune system is faced with a strange material coming in huge amounts of micro-particles from the tribology code. Therefore, great attention to the problem of aseptic loosening has been addressed in special chapters on loosening and on materials currently available for arthroplasty.

How to reference

In order to correctly reference this scholarly work, feel free to copy and paste the following:

Moby Parsons (2012). Humeral Hemiarthroplasty with Spherical Glenoid Reaming: Theory and Technique of The Ream and Run Procedure, Recent Advances in Arthroplasty, Dr. Samo Fokter (Ed.), ISBN: 978-953-307-990-5, InTech, Available from: <http://www.intechopen.com/books/recent-advances-in-arthroplasty/humeral-hemiarthroplasty-with-spherical-glenoid-reaming-theory-and-technique-of-the-ream-and-run-pro>

INTECH
open science | open minds

InTech Europe

University Campus STeP Ri
Slavka Krautzeka 83/A
51000 Rijeka, Croatia
Phone: +385 (51) 770 447
Fax: +385 (51) 686 166
www.intechopen.com

InTech China

Unit 405, Office Block, Hotel Equatorial Shanghai
No.65, Yan An Road (West), Shanghai, 200040, China
中国上海市延安西路65号上海国际贵都大饭店办公楼405单元
Phone: +86-21-62489820
Fax: +86-21-62489821

© 2012 The Author(s). Licensee IntechOpen. This is an open access article distributed under the terms of the [Creative Commons Attribution 3.0 License](#), which permits unrestricted use, distribution, and reproduction in any medium, provided the original work is properly cited.

IntechOpen

IntechOpen