

# We are IntechOpen, the world's leading publisher of Open Access books Built by scientists, for scientists

6,900

Open access books available

185,000

International authors and editors

200M

Downloads

Our authors are among the

154

Countries delivered to

TOP 1%

most cited scientists

12.2%

Contributors from top 500 universities



WEB OF SCIENCE™

Selection of our books indexed in the Book Citation Index  
in Web of Science™ Core Collection (BKCI)

Interested in publishing with us?  
Contact [book.department@intechopen.com](mailto:book.department@intechopen.com)

Numbers displayed above are based on latest data collected.  
For more information visit [www.intechopen.com](http://www.intechopen.com)



## Cervical Disc Arthroplasty

Bruce V. Darden

*OrthoCarolina Spine Center, Charlotte  
USA*

### 1. Introduction

For more than 50 years, anterior cervical discectomy and fusion (ACDF) has been the workhorse procedure for cervical degenerative pathology. (Bailey & Badgely, 1960; Cloward, 1961; Robinson & Smith, 1955) The procedure has yielded successful results clinically in multiple large series. (Bohlman et al, 1993; Gore & Sepic, 1984) Advances in allograft and cage techniques as well as the use of anterior plating systems have diminished complications in ACDF. However, concerns about adjacent segment degeneration (ASD) have tempered some enthusiasm for the procedure. Gore et al (Gore & Sepic, 1998) reviewed a series of 50 ACDF patients followed long term. Almost universally, the patients developed ASD. One-third of the cohort developed recurrent pain with half of the symptomatic group requiring additional surgery. Hilibrand et al (Hilibrand et al, 1999) evaluated a group of 374 patients undergoing ACDF. They showed a 2.9% per year risk of development of symptomatic ASD, with two thirds of the symptomatic patients requiring additional surgery. Goffin et al (Goffin et al, 1995) prospectively followed a series of ACDF patients who underwent the procedure for either a degenerative or traumatic condition. Follow-up was for five to nine years. Sixty percent of the patients developed ASD, equally distributed between the older degenerative population and the younger traumatic population, providing evidence that fusion may accelerate degenerative changes. Goffin et al (Goffin et al, 2004) reviewed a larger series of ACDF patients followed for an average of 8.3 years. In this group, 92% of the patients developed ASD, though they had a much lower rate of additional surgical procedures, 6.1% for the entire length of follow-up, distinctly lower than Hilibrand et al. Numerous cadaveric biomechanical studies (Eck et al, 2002; Pospiech et al, 1999) evaluating adjacent level intradiscal pressures and range of motion in simulated fusion models have shown that both increase after fusion. These altered biomechanics may thus accelerate ASD.

Against this background, centers began experimenting with cervical disc arthroplasty in the 1980s. Cummins and collaborators at the Frenchay Hospital, Bristol, England developed a metal-on-metal ball and socket arthroplasty and implanted it on a small series of patients in the 1990s. (Cummins et al, 1998) The arthroplasty underwent a number of design changes and is now known as Prestige. Bryan, in the US, developed a one piece metal-on-polymer device called the Bryan Cervical Disc Replacement, initially evaluated clinically in Europe. (Goffin et al, 2002) ProDisc-C arthroplasty is a metal-on-polyethylene implant adopted from the ProDisc-L lumbar disc arthroplasty developed by Thierry Marnay. (Delamarter & Pradhan, 2004) Since

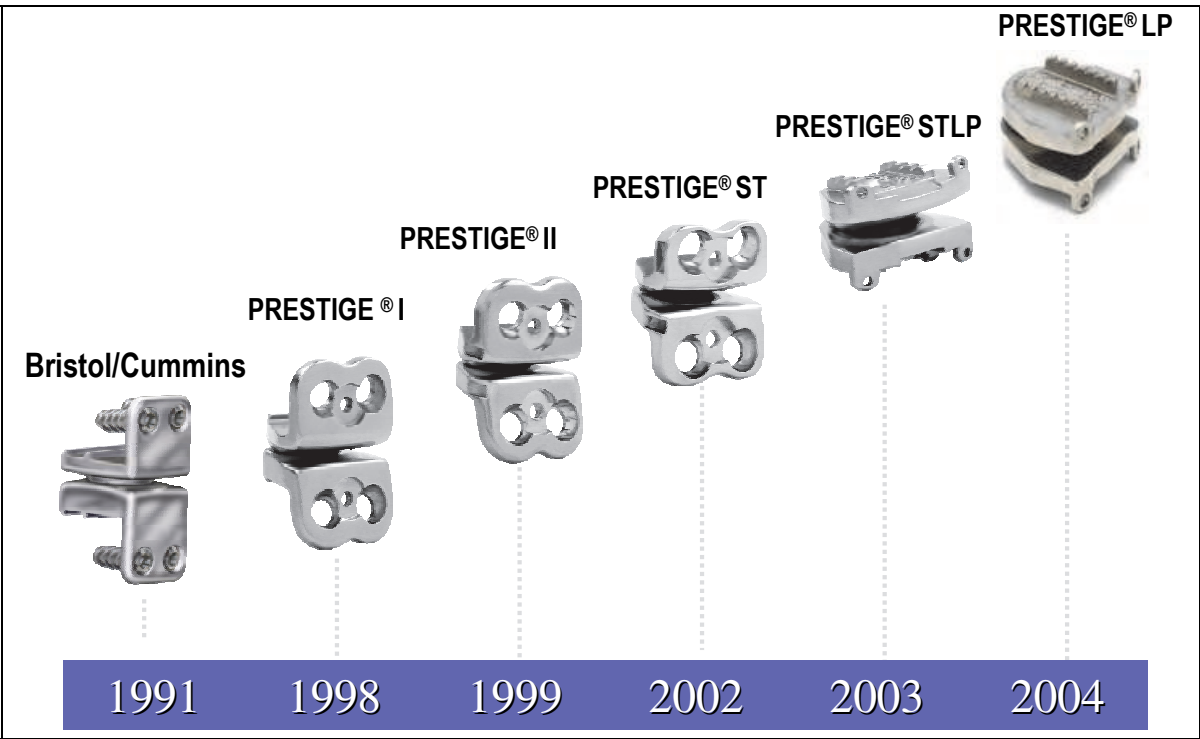
these first three devices have been developed, the number of cervical disc arthroplasties has proliferated. The literature in this nascent field is limited, but growing each year.

2. Types of cervical disc arthroplasty

It is beyond the scope of this chapter to catalogue all of the cervical disc arthroplasties available; the devices with the most clinical experience will be discussed.

2.1 Prestige

The technology from the early designs of Cummins et al was acquired by Medtronic Sofamor Danek (Memphis, Tennessee) and rebadged Prestige. With Prestige I, the initial ball and socket design which was entirely fabricated from stainless steel, was converted to a ball and trough design, allowing limited translation. The anterior flanges were diminished in size and a locking screw added to prevent bone screw backout. Prestige II was further modified by again reducing the anterior flange and modifying the endplates to allow bone ingrowth. Prestige ST was the design evaluated in the United States as part of the Food and Drug Administration (FDA) investigational device evaluational (IDE) study. This arthroplasty incorporates the features of Prestige II with further shortened anterior flanges. The final design is Prestige LP, a major change from its predecessors. Instead of stainless steel, the Prestige LP is made from a titanium ceramic composite, preserving the ball and trough bearing design. It has a titanium plasma spray on the endplates for bone ingrowth, as well as two pairs of rails allowing immediate fixation. The flange and locking bone screws have been removed. The Prestige LP, being made of titanium, has a better compatibility than stainless steel in MRI imaging. (Figure 1)

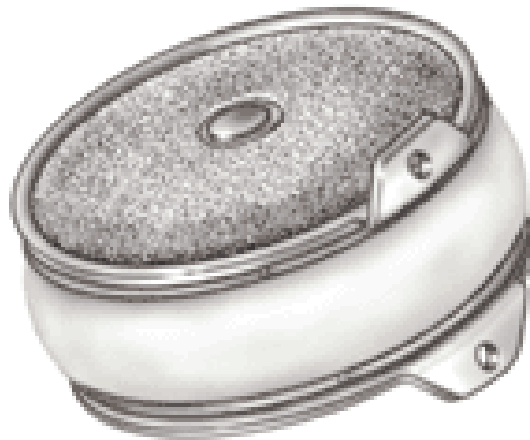

(Courtesy of Medtronic Sofamor Danek, Memphis, Tennessee)

Fig. 1. Prestige Cervical Disc evolution

## 2.2 Bryan Cervical Disc Prosthesis

Bryan Cervical Disc Prosthesis (Medtronic Sofamor Danek, Memphis, Tennessee) consists of a nucleus made of polyurethane between two titanium alloy endplates in a clamshell configuration. (Figure 2) There are two bearing surfaces in the arthroplasty at the interfaces between the nucleus and the endplates. A polyurethane sheath attaches to the endplates and surrounds the nucleus. Sterile saline is injected between the outer sheath and the nucleus as lubricant. The endplates have a titanium porous coating for bone ingrowth and a small flange anteriorly to prevent posterior migration.



(Courtesy of Medtronic Sofamor Danek, Memphis, Tennessee)

Fig. 2. Bryan Cervical Disc Prosthesis

## 2.3 ProDisc-C

ProDisc-C Cervical Disc Prosthesis (Synthes, West Chester, Pennsylvania) has a ball and socket design, with endplates made of a cobalt-chrome alloy. The endplates have keels for immediate fixation and titanium plasma spray backing for bone ingrowth. The bearing surface has an articulating dome of ultra high molecular weight polyethylene (UHMWPE) attached to the inferior endplate and a concave polished socket integral to the superior endplate. (Figure 3)



(Courtesy of Synthes, West Chester, Pennsylvania)

Fig. 3. ProDisc-C Cervical Disc

### 2.4 Porous-Coated Motion (PCM) Cervical Arthroplasty

The Porous-Coated Motion (PCM) Cervical Arthroplasty (Cervitech, Rockaway, New Jersey) consists of two cobalt-chrome-molybdenum (CoCrMo) endplates that have a titanium calcium phosphate porous coated backing for bone ingrowth. The device is inserted by a “press-fit” method, but the endplates have transverse serrated rows of teeth that resist migration. The bearing surface is an ultra high molecular weight polyethylene (UHMWPE) convex insert of large radius of curvature attached to the inferior endplate which articulates with the polished CoCrMo concave surface of the superior endplate. (Figure 4)



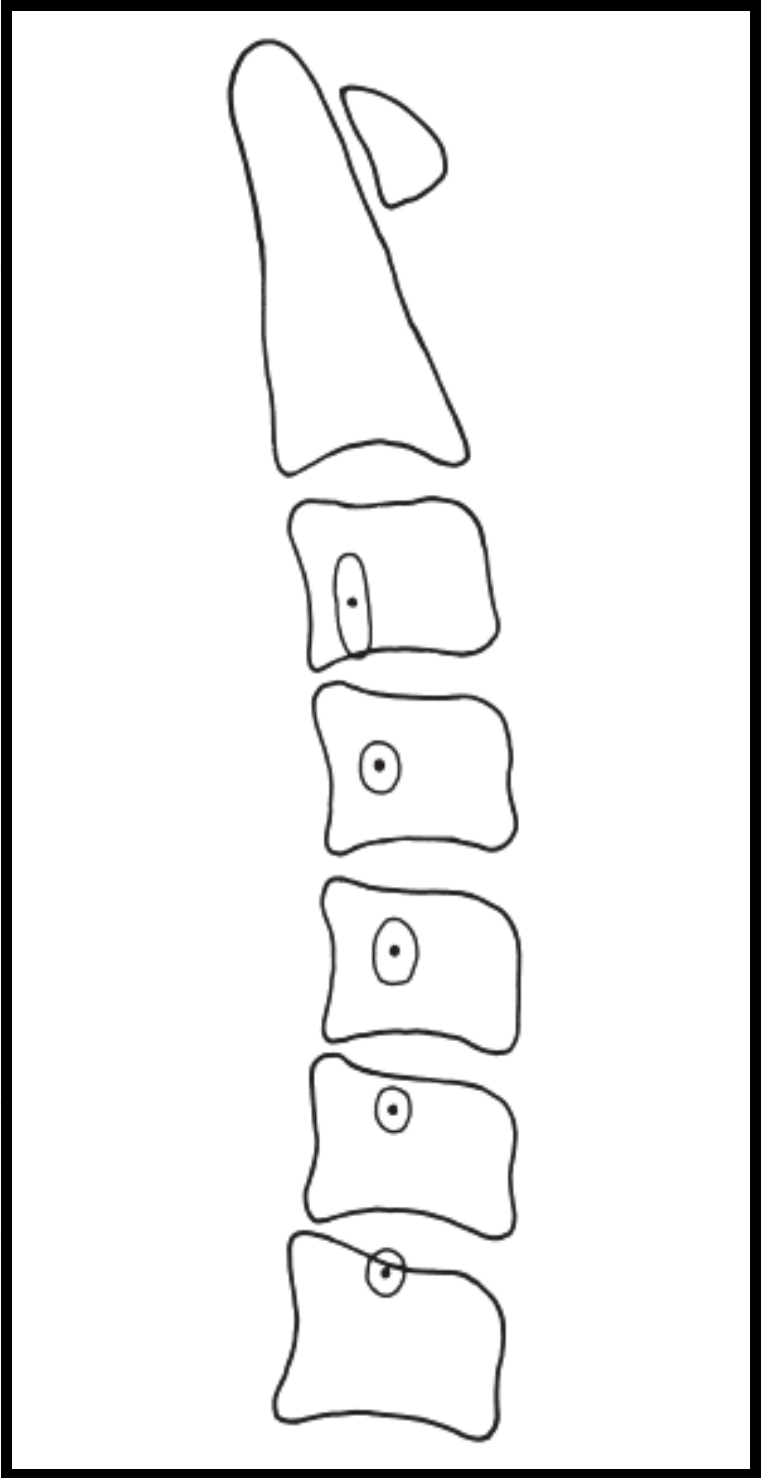
(Courtesy of Paul McAfee, MD)

Fig. 4. Porous Coated Motion (PCM) Cervical Arthroplasty

## 3. Biomechanics

Cervical disc arthroplasty attempts to replicate the normal kinematics of the subaxial cervical spine, defined as the segments from C3 to C7. The subaxial cervical spine contributes 60% of the flexion/extension motion of the cervical spine with each segment accounting for between 14 to 22 degrees of motion (Dvorak et al, 1993; Dvorak et al, 1991; Penning, 1978). The flexion/extension arc, together with translational movements due to slight relative facet motion, results in coupled motions. Coupled motions also occur with lateral bending and thus axial rotation. These coupled motions result in differences in the center of rotation of each motion segment. Since the center of rotation is not fixed, there are instantaneous centers of rotation. (ICR) Penning (Penning, 1978) established normalized ICR for each segment, which were further defined by Amevo et al (Amevo et al, 1991) The normalized ICR for each segment are shown in figure 5 (Bogduk & Mercer, 2000) and are grossly posterior and inferior to the center of the caudal vertebral endplate. Arthroplasty designs with a ball and socket articulation have a predetermined center of rotation (ie: ProDisc-C). These more constrained designs have to be implanted more precisely to match

the physiologic center of rotation to avoid increased strain on the facet joints. (Darden & Raposo, pending)



(Reprinted from: Bogduk N, Mercer S. Clin Biomechanics, 2000)

Fig. 5. Mean instantaneous axes of rotation for each motion segment of the cervical spine depicted with a dot. Two standard deviation range of distribution is located within the enclosed circles shown.

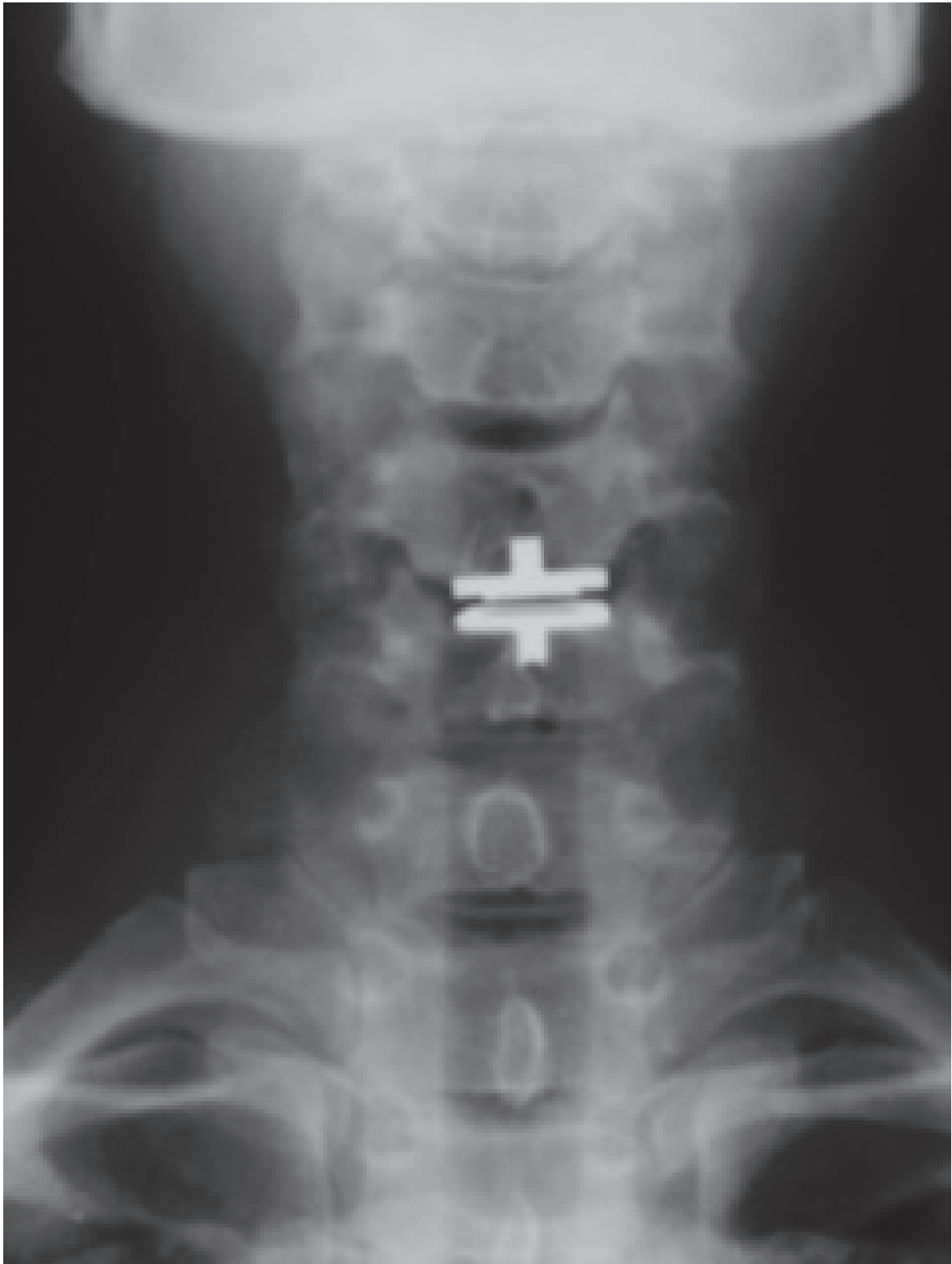

Fig. 6-A.

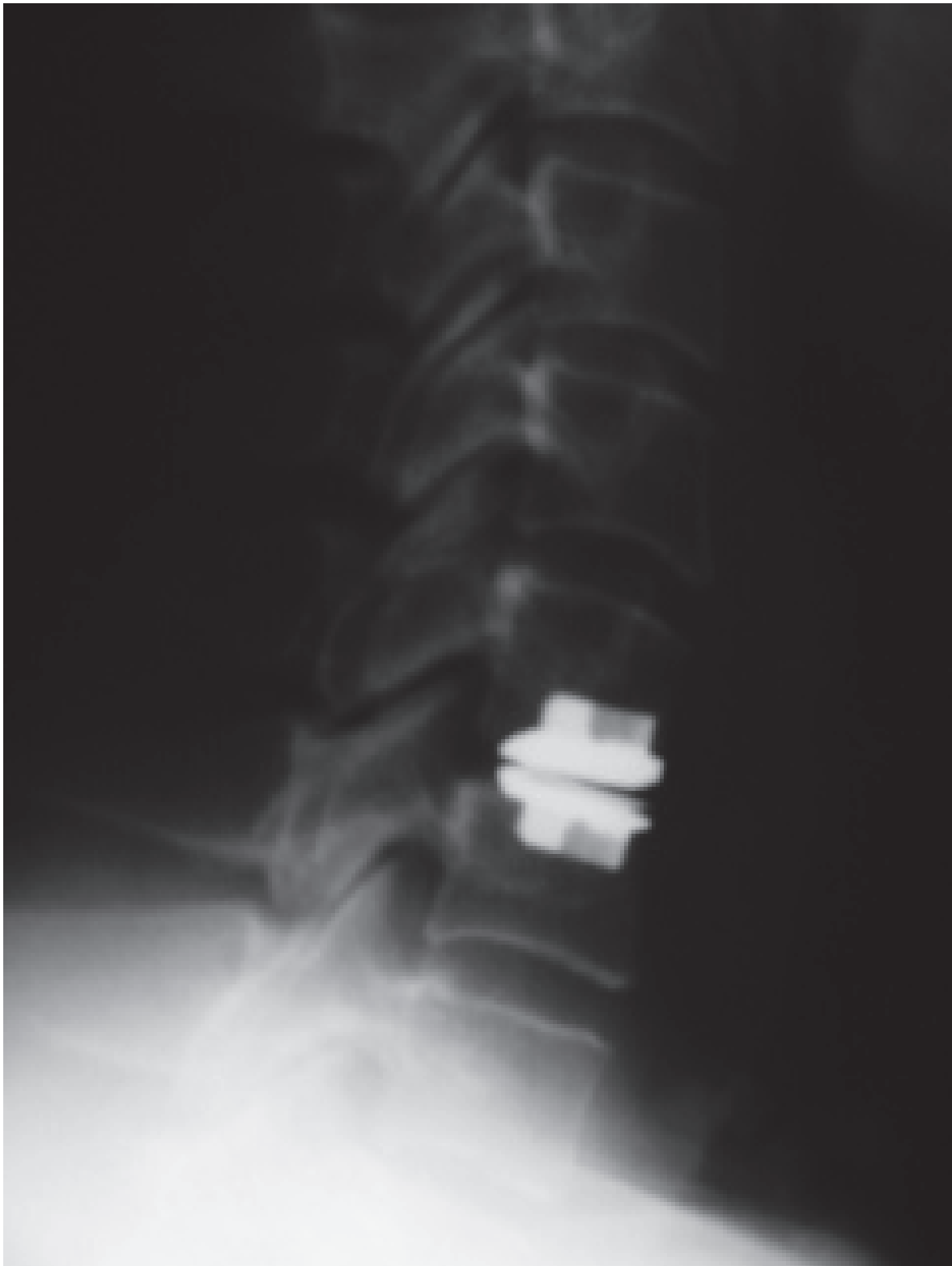

Fig. 6-B.

Fig. 6-A, B. AP and lateral radiographs of ProDisc-C

In the cervical spine, the dominant plane of motion is sagittal. Constraint is therefore defined as limitation of anterior-posterior translational motion. (Huang et al, 2003) An



unconstrained arthroplasty would allow unrestricted motion while a fully constrained arthroplasty would allow only flexion/extension without any anterior-posterior translation. However, compared to large joints, the differences in constraint in cervical disc arthroplasties are limited. (Darden & Raposo, pending) (Table 1)





				
Implant	Bryan®	Prestige ST®	Prodisc-C®	PCM-V®
Manufacturer	Medtronic Sofamor Danek,	Medtronic Sofamor Danek	Synthes	Cervitech
Bearing surface materials	Metal-on-poly; Titanium end plates, polycarbonate urethane nucleus	Metal-on-metal; Stainless steel	Metal-on-poly; Chrome cobalt, UHMWPE	Metal-on-poly; chrome cobalt, UHMWPE
Bearing surface geometry	Biconvex nucleus articulating with upper and lower endplates	Ball and trough design	Ball and socket design	Ball and socket design (shallow sphere)
Primary (immediate) fixation	Milling technique creates concave endplate surfaces to fit convex endplates of the device.	Anterior flanges with screws	Keels	LP: Press-fit, ridges
Degree of constraint	Unconstrained	Semi-constrained	Semi-constrained	Semi-constrained
Relative constraint	Least	Less	Most	Less
Implant center or rotation	Variable; lies at center of the mobile nucleus	Variable; superior to disc space	Fixed; inferior to disc space	Variable; inferior to disc space

Table 1. Summary of implant features and design characteristics.

A number of arthroplasties have been evaluated biomechanically versus simulated fusion in human cadaveric models. These routinely show increased adjacent segment motion and increased adjacent segment disc pressures in the fusion simulations compared to cervical disc arthroplasty. (DiAngelo et al, 2003; Dmitriev et al, 2005)

4. Clinical results

As a result of the US FDA IDE studies, there have been a number of thorough clinical evaluations of cervical disc arthroplasty. These trials have been designed as non-inferiority studies, comparing cervical disc arthroplasty to ACDF. The Prestige ST results at two years follow-up were reported by Mummaneni et al. (Mummaneni et al, 2007) The study, similar to all of the FDA IDE studies, was a prospective, randomized, multicenter trial comparing Prestige ST cervical disc arthroplasty to ACDF for one level pathology. Five hundred forty-one patients were enrolled with 1:1 randomization; over 75% of patients were available for two-year follow-up. There were no statistically significant differences in the revision

surgeries at the index level (3.4% ACDF, 1.9% Prestige ST). However, the rate of surgery at adjacent levels was statistically higher for ACDF (3.4% versus 1.1%,  $p=0.0492$ ). Neurological success, defined as maintenance or improvement in the neurological exam, was better with Prestige ST (92.8%) than ACDF (84.3%). Clinically, the patients were evaluated by Short-form 36 (SF-36), Visual Analogue Scale (VAS) and the Neck Disability Index (NDI). While both groups improved significantly from the preoperative state, there was no statistically significant difference between the groups at final follow-up. Overall success was defined as an NDI improvement  $\geq 15$  points, maintenance of the neurological status and the absence of implant-related adverse events. The arthroplasty group showed overall success in 79.3% of the patients compared to 67.8% in the ACDF group. As a sidebar, the Prestige ST patients were able to return to work on average at 45 days postoperatively, compared to 61 days for the ACDF patients.

A small prospective study compared results for Prestige LP and ACDF at a minimum of two years follow-up. Single and multilevel procedures were evaluated by VAS, NDI, SF-36 and Japanese Orthopedic Association scores. Clinically, while both groups improved significantly, there was no statistical difference between them. Motion was preserved in the Prestige LP group at a mean of  $13.9^\circ$  on flexion/extension lateral radiographs of two years. (Peng et al, 2011)

For the Bryan Cervical Disc Replacement, Goffin et al reported on the European experience, a multicenter, prospective, nonrandomized study, including both single-level and multi-level implants. Ninety-eight patients were evaluated at the 4 to 6 year follow-up point, 89 single-level patients and 9 two-level patients. The patients maintained improvement clinically at all evaluation periods. Approximately 90% of the patients had good or excellent results by Odum's criteria. The success rate for the arthroplasties, estimated by Kaplan-Meier analysis was 94% at 7 years postoperatively. One patient had removal of the arthroplasty for progressive spinal cord compression due to posterior osteophytes. (Goffin et al, 2010)

The Bryan FDA IDE study results at two years were published by Heller et al (Heller et al, 2009). Four hundred sixty-three patients enrolled, with 242 having a single-level Bryan Cervical Disc Replacement and 221 having single-level ACDF. The Bryan patients had statistically significantly improved NDI and VAS scores compared to the ACDF group at two years follow-up. Other clinical parameters improved equally between the two groups. Overall success at final follow-up was better in the Bryan patients (82.6%) versus the ACDF controls (72.7%), ( $p=0.010$ ). As with the Prestige IDE patients, the Bryan patients returned to work sooner than did the ACDF patients.

Riew et al (Riew et al, 2008) evaluated a subset of patients enrolled in the Prestige ST or Bryan IDE studies that were determined to have a cervical myelopathy, defined as being hyperreflexic, having clonus or having a Nurick grade  $\geq 1$ . In most of the patients, the cause of the myelopathy was a disc herniation. Because of enrollment criteria, multilevel cervical disease or patients with ossification of the posterior longitudinal ligament (OPLL) were excluded. A total of 107 patients in both studies were deemed myelopathic and underwent cervical disc arthroplasty. Compared to the ACDF patients, arthroplasty patients with myelopathy showed similar clinical improvement. There were no arthroplasty patients who deteriorated neurologically, suggesting that myelopathy confined to a single disc level without OPLL or retrovertebral osteophytes can be treated successfully with cervical disc arthroplasty.

Murrey et al (Murrey et al, 2009) published the two year ProDisc-C IDE study. The study was structured similarly to the Prestige ST and Bryan studies, with 209 patients enrolled, 103 who underwent ProDisc-C arthroplasty and 106 who had an ACDF. Both groups showed improvement by all clinical after parameters; NDI, SF-36, VAS arm and neck pain scores and neurological success. A significant difference was in the rate of re-operation: 8.5% in the ACDF group versus 1.8% in the ProDisc-C group ( $p=0.033$ ).

Delamarter et al further evaluated the ProDisc-C IDE patients as well as 136 patients who received ProDisc-C in the continued access phase of the study, with a minimum of four years follow-up. (Delamarter et al, 2010) Demographic data remained similar between the arthroplasty and ACDF groups. All clinical parameters improved equally in both groups at all follow-up periods ( $p<0.0001$ ). A significant difference in the study was the rate of secondary surgical procedures. At the four year follow-up point, 12 (11.3%) of the ACDF patients had additional surgery, while only three (2.9%) of the ProDisc-C patients required further procedures ( $p=0.0292$ ). The ACDF patients primarily required additional surgery for pseudoarthrosis at the index level; however, six (5.6%) ACDF patients had surgery at an adjacent level. Three ProDisc-C patients were converted to fusion for axial pain. No ProDisc-C patients had to have surgery at adjacent levels. In the continued access arm of the study, one ProDisc-C patient required additional surgery to reposition the implant and two were converted to fusion for axial neck pain.

Pimenta et al (Pimenta et al, 2007) prospectively evaluated patients undergoing the PCM cervical disc replacement. Seventy-one single-level and 69 multi-level arthroplasties were performed. While both groups improved, the multi-level patients showed improved scores compared to the single-level patients. The mean NDI improvement was better in the multi-level PCM group ( $p=0.021$ ). While the overall IDE results have yet to be reported, Phillips et al (Phillips et al, 2009) showed in a small set of the IDE patients that arthroplasty was viable at levels adjacent to a prior fusion.

## 5. Radiographic results

Heterotopic ossification (HO) has initially been reported in the Bryan Cervical Disc Replacement (Bartels & Donk, 2005; Leung et al 2005; Solas et al, 2005) but as the literature expands, no disc arthroplasty has proven immune to this problem. (Figure 7) McAfee et al characterized the severity of HO with a simple scale, modified from lumbar disc arthroplasty findings. The scale ranged from grade 0 (no HO) to grade IV -(complete ankylosis). (McAfee et al, 2003) (Table 2) Delamarter et al described three patients that developed grade IV HO in the ProDisc-C IDE study by 24 months, with two additional patients developing grade IV HO by 48 months. Non-steroidal anti-inflammatory drugs (NSAIDs) were not part of the study protocol. Interestingly in the continued access arm of the study, in which NSAIDs were more commonly used, no patients developed ankylosis at the index level. (Delamarter et al, 2010) Mehren et al (Mehren et al, 2006) evaluated the rate of HO at two centers performing cervical disc arthroplasty. Approximately one third of patients postoperatively showed no sign of HO, while almost 20% of patients had HO that lead to restrictions in motion. Nine percent of the patients had grade IV HO, with most of the patients having had multilevel procedures. There was a difference in the overall rate of grade IV HO between the two centers, 12.8% versus 5.2%. The center with the lower HO

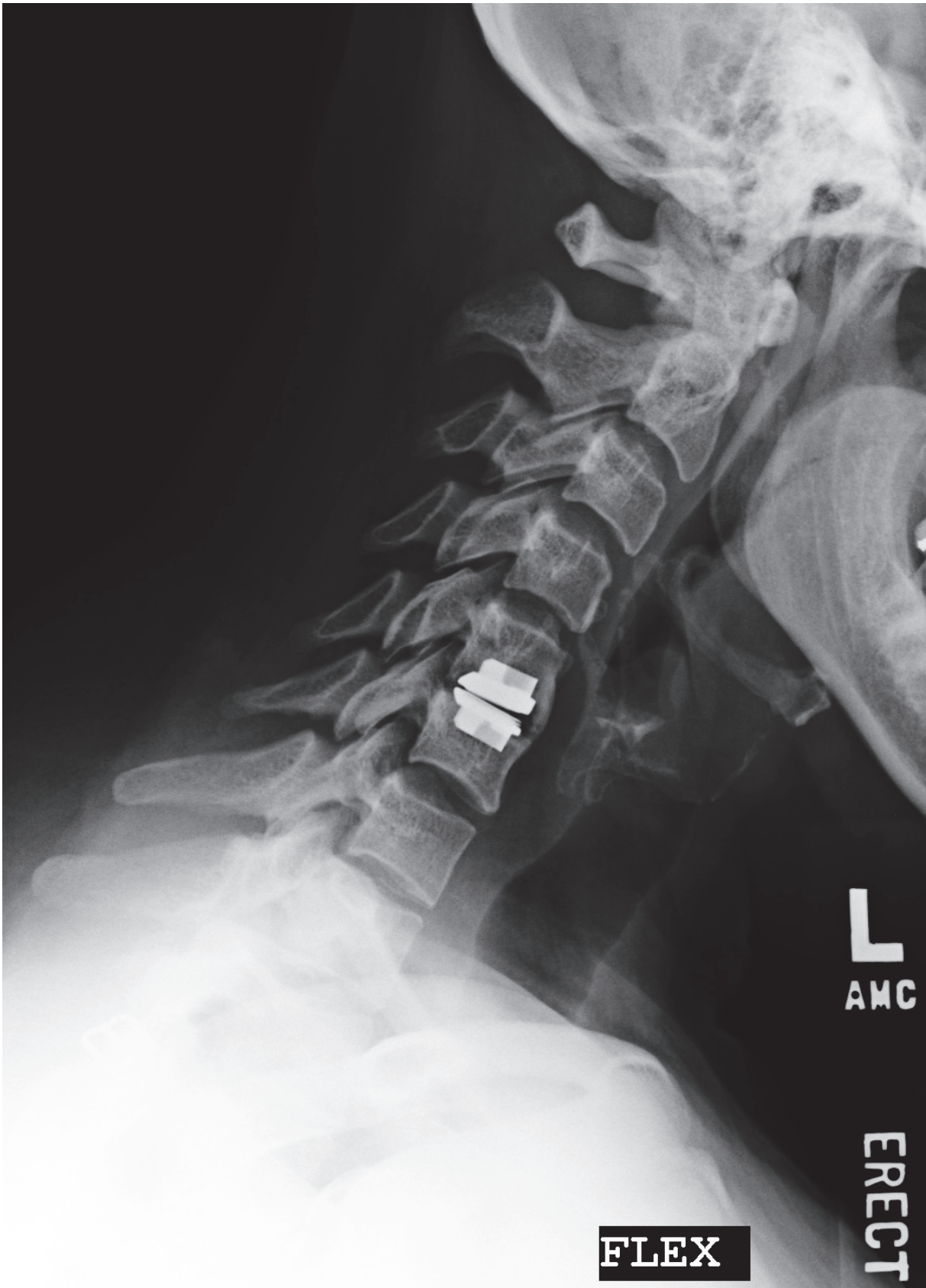

Fig. 7. Lateral flexion radiography- implanted ProDisc-C with heterotopic ossification, preserved motion.



rate routinely prescribed NSAID use postoperatively. Yi et al (Yi et al, 2010) studied the rate of HO according to the arthroplasty type. They found the following HO rates: Bryan 21.0%, Mobi-C (LDR Medical, Troyes, France) 52.5% and ProDisc-C 71.4%. The only two patients that developed grade IV HO were in the Bryan group. All patients routinely received postoperative NSAIDs.

---

Grade 0	No HO present
Grade I	HO is detectable in front of the vertebral body but not in the anatomic interdiscal space
Grade II	HO is growing in to the disc space. Possible affection of the function of the prosthesis
Grade III	Bridging ossifications which still allow movement of the prosthesis
Grade IV	Complete fusion of the treated segment without movement in flexion/extension

---

HO indicates Heterotopic ossification

---

(modified from McAfee et al, 2003)

Table 2. Characterisation of the Different Grades of Heterotopic Ossification (HO) in Total Cervical Disc Replacement

In all the clinical studies evaluating cervical disc arthroplasty and HO, there has been no correlation between the development of HO and the clinical results. Barbargallo et al (Barbargallo et al, 2010) specifically looked at this aspect of cervical disc arthroplasty. They found an overall rate of HO development of 42% and no difference in the functional scores in patients with or without HO. Segmental range of motion of  $\geq 3^\circ$  was preserved in 93.8% of patients with HO.

6. Complications

All of the large clinical series published on cervical disc arthroplasty have not reported any severe neurological injuries, such as quadriplegia. The rate of revision surgery at the index level has been acceptably low. None of the cervical disc arthroplasty series have had implants removed for infection.

Concerns of wear debris and local and remote inflammatory changes in cervical disc arthroplasty have been expressed. *In vitro* wear tests have been submitted to the United States FDA as part of the clinical approval process. Generally, wear debris volume has been in the range of 10% of that produced by large joint arthroplasties. Anderson et al (Anderson et al 2004) published *in vitro* wear testing on the Bryan Cervical Disc Replacement using a custom cervical spine simulator on six disc assemblies. At 10 million cycles, the mean mass loss was 1.76% and a mean height loss of 0.75%. At 40 million cycles there was an 18% mass loss. Wear particles were elliptical in shape and larger than

typical particles in large joint arthroplasties. Anderson studied local and remote wear debris and the subsequent inflammatory response using an *in vivo* caprine model with implanted Bryan arthroplasties. Sacrificed animals at up to twelve months showed an increase in extracellular wear debris. No apparent inflammatory response was seen locally or distally in these animals.

Clinically, there have been scattered case reports of osteolysis after cervical disc arthroplasty implantation. Tumialan and Gluf reported on a 30-year-old man who underwent a ProDisc-C arthroplasty at C5-6. (Tumialan & Gluf, 2011) He had an uneventful postoperative course until he developed worsening neck pain at nine months. Repeat imaging studies by 15 months showed a progressive osteolysis process in the vicinity of the superior endplate and keel. Work-up for infection was negative. The patient underwent explantation of the arthroplasty and conversion to a fusion. The implant was studied after removal and no defects or unusual wear was noted. The authors hypothesized that the most likely cause of the osteolysis was an immune mediated process. Longer study periods are needed to determine the significance of wear changes and the rate of osteolysis of cervical disc arthroplasty.

## 7. Conclusions

Cervical disc arthroplasty has been one of the most closely scrutinized surgical procedures in the last decade. Short-term prospective clinical studies show cervical disc arthroplasty to be at least the equivalent of ACDF for degenerative pathology. There is some evidence that cervical disc arthroplasty may play a role in diminishing adjacent segment disease. However, the long-term efficacy and safety of cervical disc arthroplasty await further clinical studies.

## 8. References

- [1] Amevo B, Worth D, Bogduk N. (1991) Instantaneous axis of rotation of the typical cervical motion segments: a study in normal volunteers. *Clinical Biomechanics* Vol. 6: pp. 111-117
- [2] Anderson PA, Sasso RC, Rouleau JP et al. (2004) The Bryan Cervical Disc: wear properties and early clinical results. *Spine Journal*, 4(6): 5303-5309
- [3] Bailey R, Badgely C. (1960) Stabilization of the cervical spine by anterior fusion. *Journal of Bone and Joint Surgery Am*, 42(4): 565-594
- [4] Barbargallo GM, Corbino LA, Olindo G, et al. (2010) Heterotopic ossification in cervical disc arthroplasty: Is it clinically relevant? *Evidence-Based Spine Care Journal*, 1(1):15-20
- [5] Bartels RH, Donk R. (2005) Fusion around cervical disc prosthesis: Case report. *Neurosurgery*, 57:E194
- [6] Bogduk N, Mercer S. (2000) *Clinical Biomechanics*, 15(9): 633-648
- [7] Bohlman HH, Emery SE, Goodfellow DB, et al. (1993) Robinson anterior cervical discectomy and arthrodesis for cervical radiculopathy: long term follow-up of one hundred and twenty-two patients. *Journal of Bone and Joint Surgery Am*, 75: 1298-1307

- [8] Cloward RD. (1961) Treatment of acute fractures and fracture dislocations of cervical spine by vertebral body fusion: a report of cases. *Journal of Neurosurgery*, 118: 205-209
- [9] Cummins BH, Robertson JT, Gill SS. (1998) Surgical experience with an implanted artificial cervical joint. *Journal of Neurosurgery*, 88: 943-948
- [10] Delamarter RB, Pradhan BB. (2004) Indications for cervical spine prostheses, early experiences with ProDisc-C in the USA. *Spine Art*, 1:7-9
- [11] Delamarter RB, Murrey D, Janssen MI et al. (2010) Results of 24 months from the prospective, randomized, multicenter investigation device exemption trial of ProDisc-C versus anterior cervical discectomy and fusion with 4-year follow-up and continued access patients. *SAS Journal*, 4: 122-128
- [12] DiAngelo DJ, Robertson JT, Metcalf NH et al. (2003) Biomechanical testing of an artificial cervical joint and an anterior cervical plate. *Journal of Spinal Disorders and Tech*, 16(4): 314-323
- [13] Dmitriev AE, Cunningham BW, Hu N et al. (2005) Adjacent level intradiscal pressure and segmental kinematics following a cervical total disc arthroplasty: An in vitro human cadaveric model. *Spine*, 30: 1165-1172
- [14] Dvorak J, Panjabi MM, Grob D et al. (1993) Clinical validation of functional flexion/extension radiographs of the cervical spine. *Spine*, 18:120-127
- [15] Dvorak J, Panjabi MM, Novotny JE et al. (1991) In vivo flexion/extension of the normal cervical spine. *Journal of Orthop Res*, 9: 828-834
- [16] Eck JC, Humphreys SC, Lim T, et al. (2002) Biomechanical study on the effect of cervical spine fusion on adjacent level intradiscal pressure and segment motion. *Spine*, 27: 2431-2434
- [17] Goffin J, VanLoo J, VanCalenbergh F et al. (2010) A clinical analysis of 4-6 year follow-up results after cervical disc replacement using the Bryan Cervical Disc Prosthesis. *J Neurosurgery Spine*, 12 (3) 261-9
- [18] Goffin J, Geusens E, Vantomme N, et al. (2004) Long-term follow-up after interbody fusion of the cervical spine. *Journal of Spinal Disorders and Techniques*, 17(2) 79-85
- [19] Goffin J, Casey A, Kehr P, et al. (2002) Preliminary clinical experience with the Bryan cervical disc prosthesis. *Neurosurgery*, 51(3) 840-845.
- [20] Goffin J, Van Loon J, VanCalenbergh F, et al. (1995) Long-term results after anterior cervical fusion and osteosynthetic stabilization for fractures and/or dislocation of the cervical spine. *Journal of Spinal Disorders and Techniques*, 8: 500-508
- [21] Gore DR, Sepic SB. (1998) Anterior discectomy and fusion for painful cervical disc disease: a report of 50 patients with an average follow-up of 21 years. *Spine*, 23: 2047-2051
- [22] Gore DR, Sepic SB. (1984) Anterior cervical fusion for degenerated or protruded discs: A review of one hundred forty-six patients. *Spine*, 9:667-71
- [23] Heller JG, Sasso RC, Papadopoulos SM, Anderson PA, Fessler RG et al. (2009) Comparison of Bryan Cervical Disc Arthroplasty with anterior cervical decompression and fusion. *Spine*, 34(2) 101- 107

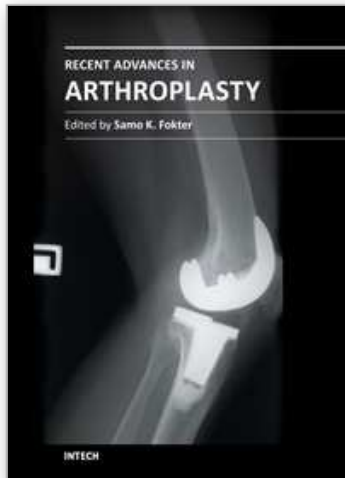
- [24] Huang RC, Girardi FP, Cammisa FP et al. (2003) The implications of constraint in lumbar total disc replacement. *Journal of Spinal Disorders and Techniques*, 16(4): 412-417
- [25] Hilibrand AS, Carlson GD, Palumbo MA, et al. (1999) Radiculopathy and myelopathy at segments adjacent to the site of a previous anterior cervical arthrodesis. *Journal of Bone and Joint Surgery Am*, 81: 519-528
- [26] Mehren, Suchomel et al. (2006) Heterotopic ossification in total cervical artificial disc replacement. *Spine*, 31(24) 2802-2806
- [27] Leung C, Casey et al. (2005) Clinical significance of Heterotopic ossification in cervical disc replacement: a prospective multi-center clinical trial. *Neurosurgery*, 57:759-631 discussion 763
- [28] McAfee, Cunningham et al. (2003) Classification of Heterotopic ossification (HO) in artificial disk replacement. *Journal of Spinal Disorders and Techniques* 16: 384-9
- [29] Mummaneni et al. Clinical and radiographic analysis of cervical disc arthroplasty compared with allograft fusion: A randomized controlled trial. *Journal of Neurosurgery -Spine*, Vol. 6, pp 198-209
- [30] Murrey et al. (2009) Results of the prospective, randomized, controlled Food and Drug Administration Investigational Device Exemption Study of the ProDisc-C total disc replacement versus anterior discectomy and fusion for the treatment of one level symptomatic cervical disc disease. *Spine Journal*, Vol. 9, pp 275-286
- [31] Peng CW, Yue WM, Abdul B et al. (2011) Intermediate results of the Prestige LP cervical disc replacement: clinical and radiological analysis with minimum two-year follow-up. *Spine*, 36 (2): E 105-111
- [32] Pospiech J, Stolke D, Wilke HJ et al. (1999) Intradiscal pressure recordings in the cervical spine. *Neurosurgery*, 44: 379-384.
- [33] Phillips FM, Allen TR, Regen JJ, et al. (2009) Cervical disc replacement in patients with and without previous adjacent level fusion surgery: A prospective study. *Spine*, 34 (6) 556-565
- [34] Pimenta L, McAfee PC, Cappuccino A, et al. (2007) Superiority of multilevel cervical arthroplasty outcomes versus single level outcomes: 229 consecutive PCM prostheses. *Spine*, 32 (12) 1337-1344
- [35] Penning L. (1978) Normal movements of the cervical spine. *Am J Roentgenol*, 130: 317-326
- [36] Raposo J, Darden BV. (publication pending) Biomechanics of cervical disc arthroplasty. *The Cervical Spine*, 5<sup>th</sup> Edition. Editor Edward Benzel, Lippincott, Williams and Wilkins
- [37] Riew KD, Buchowski JM, Sasso R, Zdeblick T, Metcalf NH, Anderson PA. (2008) Cervical disc arthroplasty compared with arthrodesis for the treatment of myelopathy. *Journal of Bone and Joint-A*, Vol. 90: pp 2354-2364
- [38] Robinson R, Smith G. (1955): Anterolateral cervical disc removal and interbody fusion for cervical disc syndrome. *Bull. John Hopkins Hospital*, 96:223-224
- [39] Sola S, Hebecker R, Knoop M et al. (2005 suppl) Bryan cervical disc prosthesis- three years follow-up. *European Spine Journal*, 14:38
- [40] Tumialan LM and Gluf, Wm. (2011) Progressive vertebral body osteolysis after cervical arthroplasty. *Spine*, 36(14):973-8



- [41] Yi S, Kim KN, Yang MS, et al. (2010) Difference in occurrence of Heterotopic ossification according to prosthesis type in the cervical artificial disc replacement. *Spine*, 35(16):1556-1561

IntechOpen

IntechOpen



## **Recent Advances in Arthroplasty**

Edited by Dr. Samo Fokter

ISBN 978-953-307-990-5

Hard cover, 614 pages

**Publisher** InTech

**Published online** 27, January, 2012

**Published in print edition** January, 2012

The purpose of this book was to offer an overview of recent insights into the current state of arthroplasty. The tremendous long term success of Sir Charnley's total hip arthroplasty has encouraged many researchers to treat pain, improve function and create solutions for higher quality of life. Indeed and as described in a special chapter of this book, arthroplasty is an emerging field in the joints of upper extremity and spine. However, there are inborn complications in any foreign design brought to the human body. First, in the chapter on infections we endeavor to provide a comprehensive, up-to-date analysis and description of the management of this difficult problem. Second, the immune system is faced with a strange material coming in huge amounts of micro-particles from the tribology code. Therefore, great attention to the problem of aseptic loosening has been addressed in special chapters on loosening and on materials currently available for arthroplasty.

### **How to reference**

In order to correctly reference this scholarly work, feel free to copy and paste the following:

Bruce V. Darden (2012). Cervical Disc Arthroplasty, Recent Advances in Arthroplasty, Dr. Samo Fokter (Ed.), ISBN: 978-953-307-990-5, InTech, Available from: <http://www.intechopen.com/books/recent-advances-in-arthroplasty/cervical-disc-arthroplasty>

**INTech**  
open science | open minds

### **InTech Europe**

University Campus STeP Ri  
Slavka Krautzeka 83/A  
51000 Rijeka, Croatia  
Phone: +385 (51) 770 447  
Fax: +385 (51) 686 166  
[www.intechopen.com](http://www.intechopen.com)

### **InTech China**

Unit 405, Office Block, Hotel Equatorial Shanghai  
No.65, Yan An Road (West), Shanghai, 200040, China  
中国上海市延安西路65号上海国际贵都大饭店办公楼405单元  
Phone: +86-21-62489820  
Fax: +86-21-62489821

© 2012 The Author(s). Licensee IntechOpen. This is an open access article distributed under the terms of the [Creative Commons Attribution 3.0 License](https://creativecommons.org/licenses/by/3.0/), which permits unrestricted use, distribution, and reproduction in any medium, provided the original work is properly cited.

IntechOpen

IntechOpen