

We are IntechOpen, the world's leading publisher of Open Access books Built by scientists, for scientists

6,900

Open access books available

186,000

International authors and editors

200M

Downloads

Our authors are among the

154

Countries delivered to

TOP 1%

most cited scientists

12.2%

Contributors from top 500 universities



WEB OF SCIENCE™

Selection of our books indexed in the Book Citation Index
in Web of Science™ Core Collection (BKCI)

Interested in publishing with us?
Contact book.department@intechopen.com

Numbers displayed above are based on latest data collected.
For more information visit www.intechopen.com



Infection in Primary Hip and Knee Arthroplasty

Michelle M. Dowsey, Trisha N. Peel and Peter F.M. Choong
University of Melbourne, Department of Surgery, St. Vincent's Hospital Melbourne
Department of Orthopaedics, St. Vincent's Hospital Melbourne
Australia

1. Introduction

Since the advent of prosthetic joint replacement, patients suffering from bone and joint pathology have benefited from significant improvements in mobility and pain relief. In Australia 39,200 hip replacements and 39,500 knee replacements were performed in 2009 (Australian Orthopaedic Association National Joint Replacement Registry [AOA NJRR]) (Graves, et al. 2010). With an ageing population, the number of patients undergoing these procedures is projected to increase significantly over time. Data from the United States of America predicts that by 2030, the number of patients undergoing primary hip and knee replacement will increase by 174% and 673% respectively (Kurtz, et al. 2007). The major complication of such techniques is infection of the prosthetic device, which is associated with significant costs to individual patients and to the public health system. Significant morbidity is associated with prosthetic joint infections including the need for further operative procedures, long-term antibiotic therapy, and prolonged hospitalisation. Thereafter, the mortality rate from prosthetic joint infection is estimated to be between 1.0 to 2.7 percent (Ahnfelt, et al. 1990, Zimmerli 2006, Zimmerli, et al. 2004). Aside from the effects on the individual patient, the financial cost to the health system is considerable. The estimated hospital costs is \$ 96 166 (US) per patient requiring revision arthroplasty for infection, which is 4.8 times the cost of a primary arthroplasty (Bozic & Ries 2005). This chapter examines the underlying epidemiology, diagnosis, treatment and challenges in managing this problem.

2. Epidemiology

2.1 Incidence

Identification of prosthetic joint infection currently relies on diagnostic criteria, which include: histopathologic evidence of acute inflammation of periprosthetic tissue, presence of a sinus tract, macroscopic purulence surrounding the prosthesis observed intraoperatively or two or more positive microbiological cultures with the same organism isolated from the prosthetic joint fluid or tissue (Berbari, et al. 1998). We report a rate of prosthetic joint infection between 1.0 – 2.0% in primary lower limb arthroplasty and this is congruent with current literature (Dowsey & Choong 2008, 2009, Swan, et al. 2011). In the United States the rate of infection in knee and hip arthroplasty was 0.92% and 0.88% respectively in a recent review of Medicare data. (Kurtz, et al. 2008). The majority of arthroplasty infections occur in

the two years following prosthetic joint surgery. The incidence of knee arthroplasty infection within 2 years was 1.55% decreasing to 0.46% in the subsequent 8 years. Corresponding data in the hip arthroplasty population showed an incidence of 1.63% within 2 years and 0.59% between two to ten years (Kurtz, et al. 2010, Ong, et al. 2009)

2.2 Risk factors

A number of preoperative risk factors for prosthetic joint infection have been identified and these include pre-existing patient co-morbidities such as obesity, diabetes mellitus, rheumatoid arthritis and a history of prior malignancy. Body mass index (BMI) greater than 40kg/m² has been associated with a 9 fold increased risk of knee infection in our series (Dowsey & Choong 2009). Similar studies have shown that for every 1 kg/m² increase in body mass index, there was an associated 8% increase in the risk of deep prosthetic joint infection. The association between obesity and deep prosthetic infections is particularly marked in the hip arthroplasty population with the risk of infection increasing from 0.9% in patients within the normal weight range, to 9.1% in morbidly obese (Choong, et al. 2007, Dowsey & Choong 2008). Diabetes mellitus also predisposes patients to deep prosthetic joint infection with 5.3% of diabetic patients developing a prosthetic joint infection in one study (Dowsey & Choong 2009, Yang, et al. 2001). Postulated mechanisms for the increased risk include impaired leucocyte function and impaired wound healing in diabetic patients. Rheumatoid arthritis has been associated with a higher risk of deep prosthetic joint infections. Patients with rheumatoid arthritis have been reported to have a greater than 2.5 fold increase in the risk of arthroplasty infection compared to patients with osteoarthritis (Bengtson & Knutson 1991, Poss, et al. 1984). Whether this is due to impaired immunity secondary to the underlying disease or whether it is a reflection of the increased use of immunosuppressive medications in this cohort remains unclear (Berbari, et al. 2006b). A diagnosis of malignancy not involving the index joint has been identified as a risk factor for the subsequent development of prosthetic joint infection (Berbari, et al. 1998).

Operative risk factors associated with deep prosthetic joint infection include higher American Society of Anaesthesiologists' (ASA) and National Nosocomial Infections Surveillance (NNIS) scores, bilateral surgery, knee arthroplasty, arthroplasty type and operating room conditions. Berbari et al showed that increasing NNIS score was associated with increasing risk of deep prosthetic joint infection; NNIS score 1 was associated with a 1.7 fold increase, increasing to 3.9 with a NNIS score of 2 (Berbari, et al. 1998). The ASA score, a component of the NNIS score, was also associated with an increased risk of arthroplasty infections (Pulido, et al. 2008). Pulido et al identified close to a six-fold increase in risk of prosthetic joint infection in patients undergoing simultaneous bilateral arthroplasty surgery. In the same study, knee arthroplasty, when compared to hip arthroplasty, was independently associated with a higher risk of developing deep prosthetic joint infection (Pulido, et al. 2008). The type of prosthesis used also appears to influence the risk of infection. A 20-fold increased risk of infection with metal hinged prosthetic knee joints compared to metal-to-plastic prostheses has been reported (Poss, et al. 1984).

A number of postoperative risk factors for prosthetic joint infection have also been identified. The most important of these appears to be postoperative wound complications including the presence of superficial infection and/or wound discharge (Bengtson & Knutson 1991, Surin, et al. 1983, Wymenga, et al. 1992). Superficial infection, occurs within 30 days of the operative procedure, only involves the superficial structures and additionally

includes one of the following features: purulent discharge, isolation of micro-organisms through aseptic sampling techniques or clinical features of infection (Horan, et al. 1992). Applying this definition, patients with a postoperative surgical site infection had around a 36 fold increase in the risk of the subsequent development of a deep prosthetic wound in one study (Berbari, et al. 1998). Similarly, in another study examining patients with deep prosthetic infections acquired in the perioperative period, 25 of the 26 patients described preceding wound complications, which included; the persistent drainage of fluid from the wound, development of a haematoma under the wound, a superficial infection or a stitch abscesses (Poss, et al. 1984). Of note we have demonstrated that the use of closed suction drainage in total knee arthroplasty is protective of prosthetic knee infection and this may be due the role of a drainage tube in minimizing haematoma formation (Dowsey & Choong 2009). Early post-operative persistent discharge of fluid from the wound has been associated with a 3.2 times higher risk of deep prosthetic joint infection. Often in these cases the same pathogenic organisms isolated from the discharging fluid is later recovered at time of reoperation on the infected hip (Surin, et al. 1983).

Postoperative medical complications including atrial fibrillation and myocardial infarction have also been implicated as risk factors for deep prosthetic joint infection, with a 6-fold and 20-fold respective increase reported (Pulido, et al. 2008). One postulated mechanism to account for this association is that standard management of these medical conditions includes anticoagulation. In the postoperative period this may increase the risk of bleeding and haematoma formation near the wound, which in itself may increase the risk of infection. Secondly, these medical complications may necessitate longer inpatient hospital stay, which may be associated with nosocomial acquisition of infection. Allogenic blood transfusion was also identified as conferring a twofold increased risk of prosthetic infection, again the risk may be via an association with bleeding and haematoma formation near the wound, or possibly as a marker of complications and prolonged hospitalisation (Pulido, et al. 2008).

Nosocomial infections, particularly urinary tract infections have also been identified as risk factors for deep prosthetic joint infections. Surin et al demonstrated that patients with remote infections in the postoperative period were three times more likely to develop deep infections. Over three quarters of these infections were urinary tract infections. Interestingly however, there was no correlation between causative agents of the nosocomial infection and the micro-organism ultimately isolated from the infected prosthesis (Surin, et al. 1983). These results have been confirmed by other studies (Pulido, et al. 2008, Wilson, et al. 1990). Bengtson et al highlighted the significance of skin infections in haematogenous seeding of the prosthesis. One third of patients with haematogenous seeding in this cohort had concurrent or preceding skin infections that were identified as the probable primary focus for the bacteraemia (Bengtson & Knutson 1991).

2.3 Microbiology

Staphylococcus species account for approximately half of all prosthetic joint infections; this includes *Staphylococcus aureus* and coagulase negative Staphylococcus species, both methicillin sensitive and resistant. Gram-negative bacilli infections and polymicrobial infections are the two next most common groups of pathogens described. Other gram-positive bacteria such as Streptococcus and Enterococcus species occur less commonly (Bengtson & Knutson 1991, Berbari, et al. 1998, Fitzgerald, et al. 1977, Moran, et al. 2007, Pandey, et al. 2000, Pulido, et al. 2008, Steckelberg & Osmon 2000). Importantly, in all series,

a small number of cases meet the definition for prosthetic joint infection, and yet remain culture negative on standard microbiologic techniques.

Reference	1	2	3	4	5	6	7	8	9	
Total number of isolates	112	248	81	578	63	462	357	42	112	
Coagulase negative Staphylococcus	13	31	48	30	21	19	17	24	33	27.3
Staphylococcus aureus	23	21	14	23	38	22	42	19	17	23.8
Streptococcus spp	5	7	10	9	13	9	6	12	10.7	9.4
Enterococcus spp	3	6	7	3	0	1	3	10	6.3	4.6
Diptheroids	2	4	4	0.5	2	0.6	1	0	5.4	2.6
Gram-negative bacilli	6	28	0	6	11	8	5	29	16.1	12.7
Propionibacterium	0	0.4	3	1.5	0	0	0.3	2	0.9	0.9
Polymicrobial	33	0	12	12	6	19	15	0	0	9.7
Anaerobes	3	2	0	2	0	6	2	2	6.3	3.0
Other	1	4	0	2	0	3	0.3	19	2.7	3.5
Culture negative	5	0	0	11	10	12	8	2	1.8	5.2

1. (Moran, et al. 2007), 2. (Sharma, et al. 2008), 3. (Pandey, et al. 2000), 4. (Steckelberg & Osmon 2000), 5. (Pulido, et al. 2008), 6. (Berbari, et al. 1998), 7. (Bengtson & Knutson 1991), 8. (Fitzgerald, et al. 1977), 9. (McDonald, et al. 1989)

Table 1. Microbiological isolates in reported literature (percent)

3. Pathogenesis

3.1 Acquisition of infection

Acquisition of prosthetic joint infection occurs by two mechanisms: direct inoculation and haematogenous seeding. Direct inoculation of the prosthesis may occur at the time of implantation or with manipulation of the arthroplasty and is thought to be the predominant mechanism of infection. In a study by Southwood et al the 50% infective dose (ID₅₀) of *Staphylococcus aureus* required to induce infection with direct inoculation of the prosthesis was just 50 organisms. This compared to an intravenous inoculum dose of 100 000 organisms at the time of operation for bacteraemic seeding and infection of the prosthesis to occur. Southwood also demonstrated that three weeks after implantation of the prosthesis, the likelihood of bacteraemic seeding of the prosthesis was significantly reduced. In fact, in the rabbit model, the inoculum of intravenous bacteria required was near to the lethal dose(Southwood, et al. 1985). Nevertheless, haematogenous seeding remains an important cause of arthroplasty infections and it has been reported that up to 34% of patients with prosthetic joints in-situ developed deep infection of that prosthesis following an intercurrent episode of *Staphylococcus aureus* bacteraemia (Murdoch, et al. 2001).

Whilst theoretically distinct, clinically there is significant overlap between both mechanisms of infection. The simplified view is that infection resulting from inoculation occurs within the first year of implantation whilst haematogenous infections occur later. However the clinical presentation of prosthetic joint infections acquired during the original operation

may be much more delayed, particularly with low virulence organisms such as coagulase negative staphylococcus species (Steckelberg & Osmon 2000). Furthermore, up to 50% of suspected prosthetic joint infections of haematogenous origin present within the first two years (Deacon, et al. 1996). However it is important to note that distinguishing between whether an episode of bacteraemia led to haematogenous seeding of a prosthetic joint or whether the primary source of the bacteraemia was a subclinical prosthetic joint infection can be problematic.

3.2 The role of biofilms

The pathogenesis of prosthetic joint infections is intimately connected to the property of biofilm formation by microorganisms. The presence of this biofilm can have a critical effect on the likely success of treatment for a number of reasons. Bacteria can exist in two unique forms; the free living or planktonic forms characterised by rapid cellular division, and the stationary or sessile forms characterised by slower cellular division (Costerton 1999, Costerton, et al. 1995).

The sessile bacteria secrete an extracellular matrix or slime. Together the microorganisms and this matrix comprise what is known as 'the biofilm'. The abiotic matrix performs a number of functions including provision of anchorage onto structures to support the sessile colonies (Donlan & Costerton 2002). It also facilitates communication between bacteria within the biofilm. This communication termed 'quorum sensing', is analogous to the paracrine signalling in multicellular organisms and enables the bacteria to regulate their gene synthesis (Gristina & Costerton 2009). Importantly, the matrix can provide bacteria with protection from antimicrobial chemicals and from host defense mechanisms. This impairment of host defense mechanisms has been demonstrated in a number of in vitro models. For example, the extracellular slime produced by *Staphylococcus epidermidis* can inhibit the phagocytic activity of neutrophils (Shiau & Wu 1998).

The concentration of antibiotic required to inhibit the growth of bacteria in biofilms is higher than that required to kill free-living bacteria. The mean inhibitory concentration (MIC) of many antibiotics is higher with the sessile forms than corresponding planktonic forms. Studies have demonstrated up to a 1000 fold increase in the MIC to particular antibiotics for bacteria moving from the planktonic to the sessile phenotype (Amorena, et al. 1999, Jones, et al. 2001, Rose & Poppens 2009, Schwank, et al. 1998, Souli & Giamarellou 1998, Stewart & Costerton 2001). This poses a major challenge for clinicians interpreting the reported antibiotic susceptibility results of bacteria, as our standard laboratory antibiotic susceptibility testing uses only the planktonic forms of bacteria. Newer technologies including the Calgary Biofilm Device can enable antibiotic susceptibility testing of the sessile phenotype of bacteria, but at present these are limited to a research setting and are not widely available (Ceri, et al. 1999).

There are a number of postulated mechanisms for the apparent resistance of biofilm residing bacteria to the effects of antibiotics. Firstly, the antibiotic may be deactivated at the surface of the biofilm. Secondly, the altered nutritional and biochemical environment within the biofilm may alter the activity of the antibiotics. Thirdly, antibiotics, particular cell wall active antibiotics such as betalactam antibiotics, rely on rapid growth and reproduction of the microorganism for their effect. These antibiotics are effective against the planktonic phenotype but have limited efficacy against the sessile phenotype as cellular turnover is greatly reduced. Finally the sessile forms act as 'spore-like' structures, which may act as a

nidus for later relapse of infection (Costerton 1999, Stewart & Costerton 2001, Trampuz, et al. 2003, Zimmerli 2006).

The properties of the biofilm alter with time; with age many biofilms become increasingly resistant to antibiotics. Monzon et al demonstrated the efficacy of vancomycin against *Staphylococcus epidermidis* decreased as a biofilm aged. This phenomenon was not consistent with all antibiotics; the activity of rifampicin and tetracyclines was not altered (Monzon, et al. 2002). Using Ribosomal RNA Fluorescence In Situ Hybridization studies, Poulsen et al assessed the growth rate of biofilms and demonstrated that the cellular turnover was significantly higher in younger biofilms compared to established biofilms (Poulsen, et al. 1993). This finding could account for the difference to antimicrobial susceptibility observed. Implant factors are also recognised to play a role in the pathogenesis of infection. Biochemical properties of prosthetic material influences bacterial adhesion and may impair host immune responses. For example, methyl methacrylate cement has been shown to inhibit complement and lymphocyte activity (Panush & Petty 1978, Petty 1978).

4. Diagnosis

4.1 Clinical features

The clinical diagnosis of prosthetic joints is challenging. Many typical symptoms of infection are often absent. Pain is the predominant symptom of prosthetic joint infections and is present in 90 to 100% of patients. The presence of fever is variable with 9 to 43% of patients in most case series having documented elevated temperatures (Canner, et al. 1984, Inman, et al. 1984, McDonald, et al. 1989, Miley, et al. 1982, Morrey, et al. 1989, Windsor, et al. 1990). In acute infections, erythema and swelling of the joint are often present, but are less common in more chronic infections (Del Pozo & Patel 2009, Miley, et al. 1982, Zimmerli, et al. 2004). A discharging sinus is associated with chronic, indolent presentations (Del Pozo & Patel 2009).

Zimmerli et al classifies arthroplasty infections as: Early (developing in the first three months after surgery), Delayed (occurring three to 24 months after surgery) and Late (greater than 24 months). This classification roughly correlates to important observed differences in the causative pathogens; with virulent organisms such as *Staphylococcus aureus* characteristically presenting earlier and more indolent pathogens such as coagulase negative *Staphylococcus* usually presenting later (Zimmerli, et al. 2004).

4.2 Laboratory studies

Peripheral blood leucocytosis is a poor predictor of infected arthroplasty; less than 10% of patients with an infected prosthesis have an elevated white cell count in most series (Canner, et al. 1984, Inman, et al. 1984, Zimmerli, et al. 2004). Other biochemical tests, such as the erythrocyte sedimentation rate (ESR) and C-reactive protein (CRP) are more useful diagnostic tests for these infections. For patients with proven infection of knee or hip arthroplasty, the ESR had a sensitivity of 81-92% and a specificity of 90-96%, while the CRP had a sensitivity of 84-89% and a specificity of 83-96% (Bottner, et al. 2007, Spangehl, et al. 1999). There are however, limitations to the diagnostic utility of the ESR and CRP. These markers are normally elevated after primary uncomplicated arthroplasty; the ESR peaks in the first week and may remain elevated for up to a year, while the CRP peaks at

day 2 and may remain elevated for 3 weeks (Aalto, et al. 1984, Larsson, et al. 1992, Shih, et al. 1987).

The search for other biochemical markers of infection has included interleukin 6 (Il-6), tumour necrosis factor α (TNF- α) and procalcitonin C. Il-6 and TNF- α are cytokines released by monocytes and macrophages in the setting of infection (Bottner, et al. 2007). Procalcitonin is a precursor of calcitonin, and has been shown to be a specific marker of bacterial sepsis (Fernandez Lopez, et al. 2003). In a review by Bottner et al of 78 patients undergoing revision arthroplasties Il-6, TNF- α and procalcitonin were all significantly elevated in patients with confirmed septic loosening. The sensitivity and specificity respectively of Il-6 was 95% and 87%, TNF- α 43% and 94% and procalcitonin 33% and 98%. (Bottner, et al. 2007). Il-6 is elevated in the post-operative period for primary arthroplasty however, in a study by Shah et al, Il-6 was shown to return to normal levels within 2 days of the operation. Therefore there is potential diagnostic utility of Il-6 over CRP and ESR in the early post-operative period if infection is suspected, particularly in the first 21 days (Shah, et al. 2009).

Synovial fluid characteristics can be used to assist in diagnosis of prosthetic joint infections. In a study by Trampuz and colleagues, the leucocyte count was significantly higher in patients with prosthetic joint infection with a median of $18.9 \times 10^3/\mu\text{L}$ (range, 0.3 to $178 \times 10^3/\mu\text{L}$) compared to a median leucocyte count of $0.3 \times 10^3/\mu\text{L}$ (range, 0.1 to $16 \times 10^3/\mu\text{L}$) in patients with aseptic loosening. Using receiver operating characteristic (ROC) curves the authors found a synovial total white cell count $1.7 \times 10^3/\mu\text{L}$ and a leucocyte differential of greater than 65% neutrophils had a sensitivity and specificity of 94%, 88% and 97%, 98% respectively (Trampuz, et al. 2004).

4.3 Radiological studies

Plain radiographs lack sensitivity and specificity in diagnosing septic arthroplasty. Findings such as lucency around the prosthesis can be noted in both septic and aseptic loosening situations (Figure 1 A-D). In early infection plain radiographs are frequently normal (Miller 2005).

Technetium-Methylene Diphosphonate (MDP) bone scintigraphy is a sensitive test for prosthetic joint infection (Figure 1 E-G), but lacks specificity, as it does not differentiate between aseptic and septic loosening (Ghanem, et al. 2009). The bone scan can also remain positive for a year following primary arthroplasty. Bone scan does have a high negative predictive value therefore bone scans potentially can be used to exclude infection in the setting of a painful prosthetic joint (Smith, et al. 2001). Similar findings have been documented with newer modalities such as ^{18}F -Fluoro-deoxyglucose positron emission tomography (FDG-PET) (Delank, et al. 2006, Zoccali, et al. 2009). A recent meta-analysis of FDG-PET reported a sensitivity of 82.1% and specificity of 86.6% for the presence of prosthetic joint infection, and hence this may be a useful test if available (Kwee, et al. 2008).

Computer tomography (CT) and magnetic resonance imaging are not considered useful imaging modalities due to artefact from the metal prosthesis interfering with interpretation of imaging findings. However newer CT scanners can minimise this effect and may be useful in detecting abnormalities of the soft tissues in periprosthetic infections (Figure 2 A-E) but do not diagnose periprosthetic bone abnormalities well (Cyteval, et al. 2002)

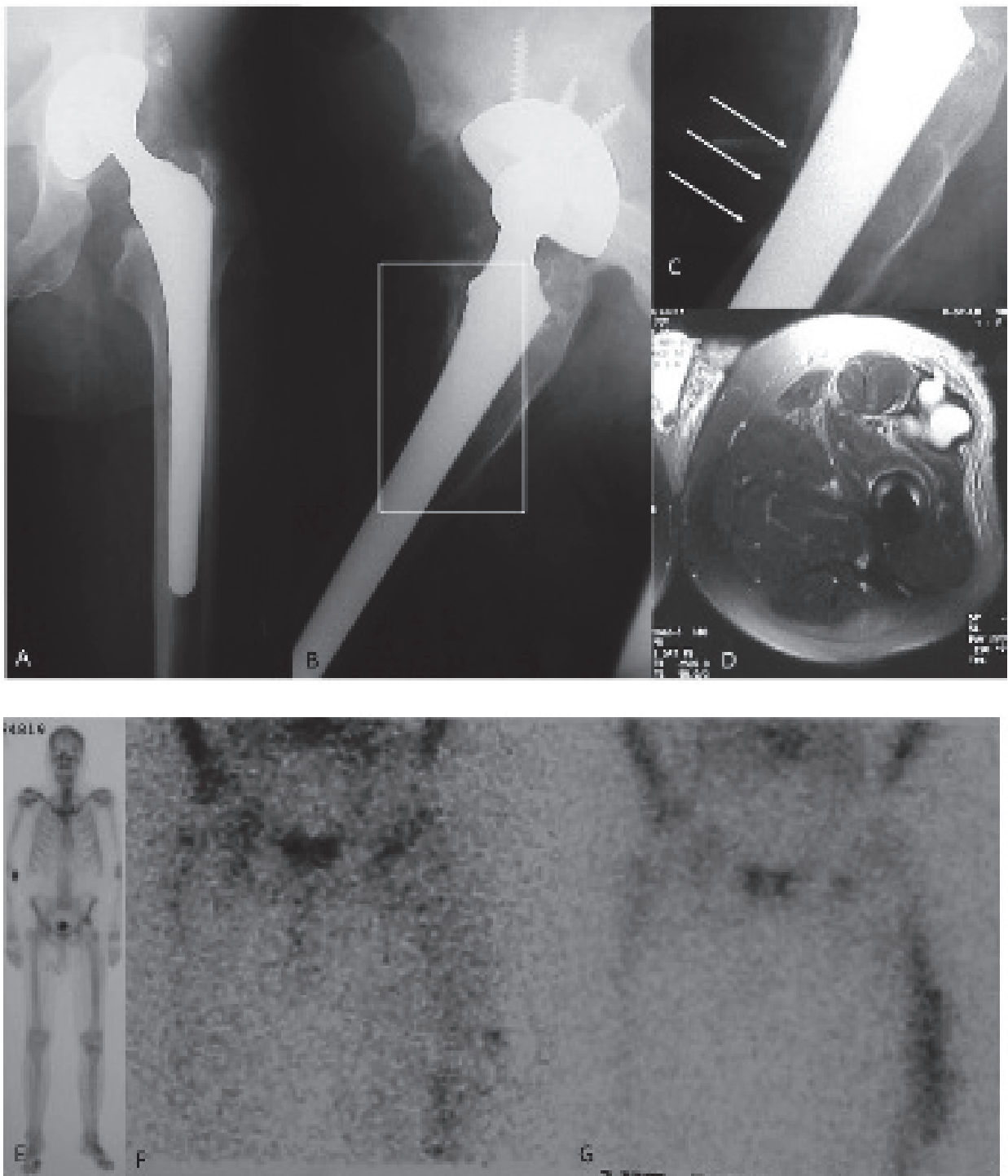


Fig. 1. (A) Painful (left) cementless hip prosthesis in situ. (B) Note extrinsic scalloping of anterior cortex of femoral diaphysis (box). (C) Magnified image of anterior femoral cortex with extrinsic scalloping (arrows) caused by soft tissue abscess (D). (E) Nuclear bone scan (TcMDP) demonstrating mild uptake over left proximal femur. Indium white cell scan at (F) 4 hours and (G) showing marked retention of nuclear tracer at 20 hours.

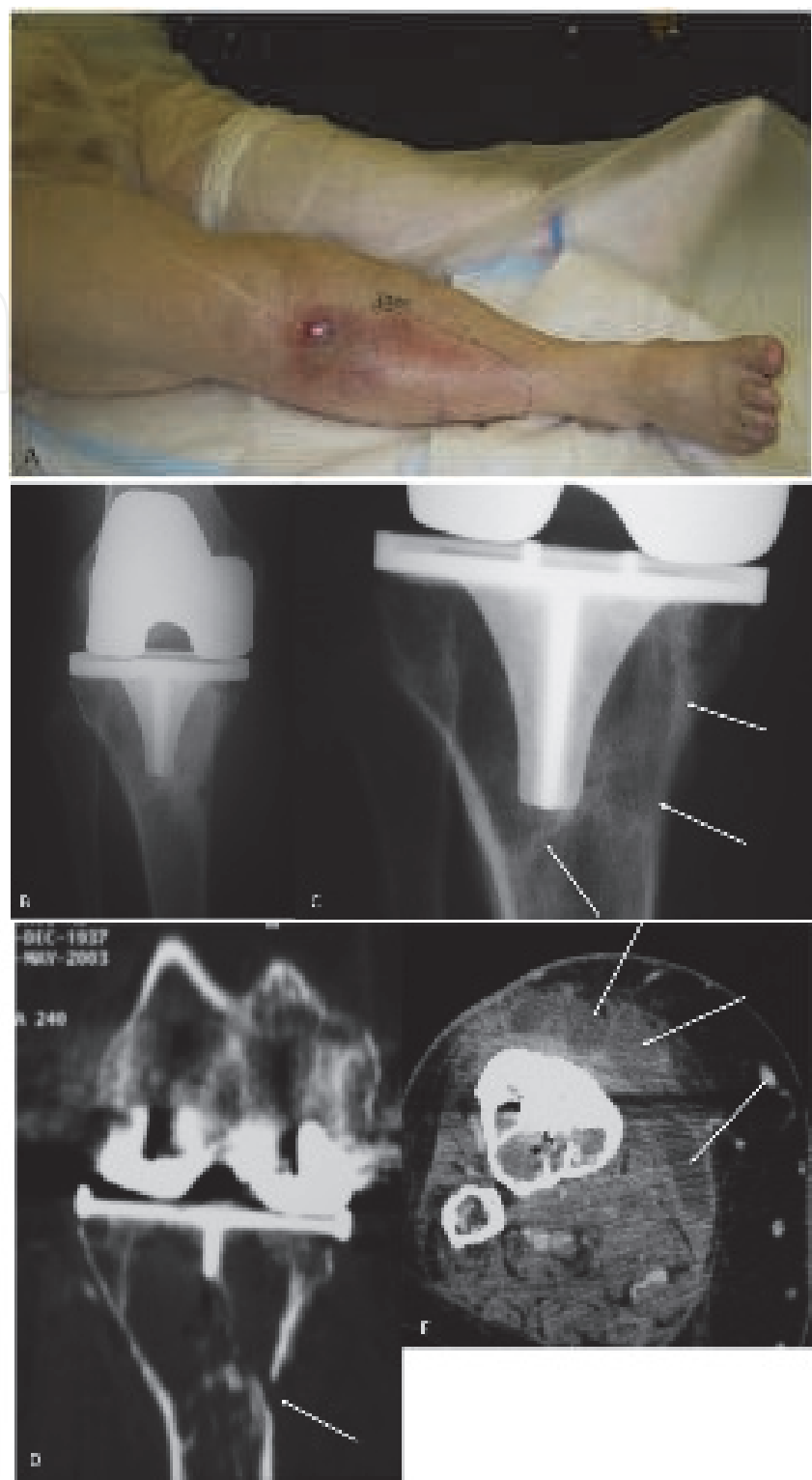


Fig. 2. (A) Localised infective sinus at the centre of incision used for total knee joint replacement. (B) plain radiograph showing periprosthetic sclerosis and lysis under the tibial component. (C) Magnified image showing obvious periprosthetic lysis (arrows). (D) Computer tomogram showing lysis under tibial component extending through medial cortex as cloaca (arrow). (E) Computer tomogram demonstrating soft tissue abscess formation (arrows) in continuity with intramedullary suppuration.

4.4 Histopathology diagnosis

Intraoperative frozen section histopathologic studies of periprosthetic tissue can be used as an adjunctive test for the diagnosis of prosthetic joint infections. An early paper showed a correlation between the polymorphonuclear leucocyte (PMN) count in tissue on histopathologic examination and the diagnosis of infection (Mirra, et al. 1976). Subsequent studies using frozen section histopathology for revision arthroplasty (using a PMN count of five to ten cells per high power field to diagnose infection) had a sensitivity of 50-93% and sensitivity of 77-100% (Bori, et al. 2006, Frances Borrego, et al. 2007, Ko, et al. 2005, Nunez, et al. 2007). It should be noted that inflammatory conditions such as rheumatoid arthritis may also cause a high PMN count, hence lowering specificity (Mirra, et al. 1976).

4.5 Microbiology diagnosis

The identification of the causative pathogen in a prosthetic device infection is of paramount importance. It allows for the institution of appropriate management strategies for infection including selection of the most appropriate antibiotic to target the pathogen, while minimising unnecessary antibiotic overuse, thus decreasing the incidence of drug toxicity and generally permitting simpler drug regimens to improve patient adherence.

It has earlier been noted that culture negative prosthetic joint infections continue to occur. Recent studies have focused on methods to increase the sensitivity of microbiological diagnostic techniques to address this problem. In a prospective study, which aimed to establish microbiological criteria for the diagnosis of prosthetic joint infection in revision arthroplasty, Atkins et al found that the isolation of indistinguishable microorganisms from three or more periprosthetic tissue samples has a sensitivity of 65% and a specificity of 99.6% for prosthetic joint infection. Utilising mathematical modelling the authors recommended that five to six intraoperative specimens of periprosthetic tissue be obtained to optimise the likelihood of a microbiologic diagnosis in prosthetic joint infection. They also noted that routine gram staining of periprosthetic tissue at revision arthroplasty had a very low sensitivity (12%) and the authors recommended that gram stain should be abandoned in revision arthroplasty cases, instead relying on culture (Atkins, et al. 1998).

Prolonged cultures may also help to improve the diagnostic yield. An increase in positive culture results of 24.6% when culture incubation of periprosthetic tissue samples was increased from 3 to fourteen days has been reported and in particular the isolation of fastidious organisms, such as *Propionibacterium* species was increased (Schafer, et al. 2008).

A number of techniques have been developed in an attempt to disrupt the biofilm and increase the yield of microbiological cultures. One such technique is ultrasonification whereby the explanted prosthesis is placed in a sterile polyethylene bag then in a sterile anaerobic jar, Ringer's solution is added and sonification is performed. The sonicate fluid is cultured aerobically and anaerobically. One study comparing sonification to standard tissue culture involving 331 patients of whom 79 had prosthetic joint infections; sonification yielded an additional 14 microbiological diagnosis with a reported sensitivity of 78.5% and specificity of 98.8%. The authors noted that sonification was particularly useful in cases where patients had received antibiotics perioperatively (Trampuz, et al. 2007).

4.6 Molecular techniques

Newer molecular techniques have been applied to prosthetic joint infections to increase the diagnostic yield including polymerase chain reaction (PCR), fluorescent in situ

hybridization (FISH) and immunofluorescent microscopy (IFM). Both PCR and FISH target specific regions of bacterial genetic material, commonly bacterial ribosomal RNA (rRNA). The advantage of using rRNA is that it is highly conserved in bacterial species compared to most protein encoding genes. Both methods can use broad range oligonucleotide primers or more targeted primers including genus and species specific primers (Amann & Fuchs 2008).

A number of studies investigating the role of bacterial 16s rRNA PCR have been performed. Sensitivities of this technique ranged from 63-100% in detecting bacteria involved in prosthetic joint infection (De Man, et al. 2009, Hoeffel, et al. 1999, Mariani, et al. 1996, Moojen, et al. 2007). In a study by Mariani et al 50 patients with symptoms following total knee arthroplasty underwent synovial fluid and intraoperative tissue sampling for culture and PCR; cultures were positive in fifteen specimens compared to 32 specimens when PCR was applied (Mariani, et al. 1996). Likewise Tunney et al used PCR in a study of 120 patients undergoing prosthetic hip joint revision. The explanted prosthesis underwent ultrasonification and this fluid was cultured and underwent 16s DNA PCR. Standard microbiologic cultures were positive in 22% of patients, compared to 72% of patients with positive results from PCR (Tunney, et al. 1999). The limitation of these studies was a paucity of correlation with clinical or histological features of infection. In a review of 34 patients with confirmed prosthetic joint infection Vandercam et al found that PCR was positive in 31 of 34 patients (91.2%), compared to positive microbiological culture in 22 of 34 patients (64.7%). Of import, eight of the nine patients with positive PCR but negative culture results had received antibiotic therapy in the prior ten days (Vandercam, et al. 2008). Despite these promising results, the weakness of 16s ribosomal RNA PCR techniques is the low specificity and high false positive rate. In a study by Clarke et al 29% of the patients without septic arthritis (on the basis of clinical, radiological, biochemical, intraoperative findings, culture and histology) had positive PCR results, this was particularly pronounced in the cohort undergoing revision arthroplasty for aseptic loosening where 46% of patients had positive PCR (Clarke, et al. 2004). The high false positive rate may be due to a number of factors including contamination of specimen or the reagents and detection of necrotic bacterial DNA (Bauer, et al. 2006). Importantly though, many patients labelled as having aseptic loosening may in fact have had low grade chronic infection contributing to prosthesis loosening. Given that there is no gold standard to define prosthetic joint infection, the specificity of PCR remains difficult to judge.

FISH is a technique that uses labelled oligonucleotide probes that hybridise to specific genetic regions on bacteria and are subsequently visualised using fluorescent microscopy or flow cytometry (Amann & Fuchs 2008, Moter & Gobel 2000). Probes to detect bacterial rRNA or other genetic targets are available and these include species specific probes, therefore allowing identification and simultaneous observation of the different bacteria. FISH also allows an appreciation of the architectural arrangement of the organisms within the biofilm which can assist in differentiating true infections from contamination (McDowell & Patrick 2005, Moter & Gobel 2000). In orthopaedic infections it has been demonstrated that *Staphylococcus aureus* and *Staphylococcus epidermidis* could be visualised and differentiated in an experimental biofilm. Additionally, in a clinical case of septic loosening of a hip prosthesis, *Staphylococcus epidermidis* was visualised using FISH techniques in periprosthetic tissue samples (Krimmer, et al. 1999). FISH has otherwise not yet been widely applied to prosthetic joint infections in a clinical setting.

Immunofluorescence microscopy (IFM) is another novel nonculture technique for diagnosing prosthetic joint infections. In immunofluorescence microscopy, samples are mixed with monoclonal antibodies (MAb) to specific antigens on bacterial cell walls. Samples are then incubated with a second antibody conjugated with a fluorescent dye. The bacteria are then visualised using fluorescence microscopy (Tunney, et al. 1999). As with FISH, IFM can be used to assess the biofilm structure and can detect multiple pathogens (McDowell & Patrick 2005, Tunney, et al. 1999). In the study by Tunney et al IFM was performed on the sonicate fluid from explanted prostheses using Mab for both *Propionibacterium* and *Staphylococcus* species. (Tunney, et al. 1999).

5. Treatment

5.1 Treatment goal

Optimal treatment of prosthetic joint infections involves the eradication of infection whilst maintaining function of the joint and patient quality of life (Zimmerli, et al. 2004). However there are no large, multi-centred, randomised prospective studies of treatment strategies to guide recommendations. The successful treatment of prosthetic joints is contingent on the elimination of the biofilm dwelling microorganism. The two mainstay methods of achieving this are through either surgical removal of the prosthesis or through use of biofilm active antibiotics in conjunction with surgical debridement and retention of the prosthesis.

The surgical strategies used to treat arthroplasty infections include: resection arthroplasty, one-stage or two-stage exchange procedures, amputation and debridement and retention. Resection arthroplasty entails the removal of all foreign material including cement, resection of devitalised tissue and bone and may or may not involve arthrodesis. Exchange procedures involve resection arthroplasty with reimplantation of a new joint prosthesis performed at the time of removal of the infected prosthesis (one-stage exchange); or delayed by a variable period of time while antibiotic therapy is administered (two-stage exchange). Debridement and retention of the prosthesis usually involves open arthrotomy, removal of all infected and necrotic bone, exchange of liners and lavage of the joint (Giulieri, et al. 2004, Matthews, et al. 2009, Rand, et al. 1986, Steckelberg & Osmon 2000, Trampuz & Zimmerli 2008, Zimmerli, et al. 2004).

A number of factors influence the surgical approach selected for an individual patient, these include a patient's general health and fitness for anaesthesia, condition of the prosthesis and bone stock, the causative agent, the timing of the infection relative to the prosthesis insertion, the availability of effective antibiotics and clinicians' and patient preference.

5.2 Systemic antibiotic therapy without surgical debridement

Administration of antibiotic therapy without surgical management is not routinely recommended, as it is rarely associated with successful cure. Early studies of antibiotic therapy alone for prosthetic joint infections had disappointing results with successful outcomes in as little as 8-15% of patients (Bengtson, et al. 1989, Canner, et al. 1984). The confounding factor when analysing these poor results is that biofilm active antibiotics, were not used. Treatment with biofilm active antibiotics alone including rifampicin and ciprofloxacin for three to six months has yielded successful outcomes in highly selected patients; those presenting with early infections (less than one year following implant),

infection due to *Staphylococcus aureus*, absence of implant loosening and strict adherence to treatment (Trebse, et al. 2005). However, antibiotic suppression alone is generally reserved for patients with significant comorbidities in whom surgery is contraindicated, who are without evidence of systemic infection and where tolerable oral antibiotics are available. Given the low likelihood of cure, many clinicians view this as long term, often lifelong suppressive therapy, embarked upon without curative intent (Steckelberg & Osmon 2000, Zimmerli, et al. 2004).

5.3 Exchange arthroplasty

Interpretation of the current literature describing the outcomes of patients having one- and two-stage exchange procedures is challenging owing to the heterogeneity of the patient populations, the causative organisms and the surgical techniques (including use of antibiotic impregnated cement), the differences in the duration of patient follow up and probable publication bias. The greatest concern with one-stage exchange procedures is the implantation of the prosthesis into an infected field with subsequent reinfection of the revised arthroplasty. In one-stage exchange, reported success rates range from 38-100%; but there is significant variability in the definition of success which includes freedom from infection, freedom from pain or simply the presence of a functional joint (Callaghan, et al. 1999, Jansen, et al. 2009, Steckelberg & Osman 2000). In examination of the outcomes of one-stage exchange revision hip arthroplasty, 80% (range 57-92%) of patients have been reported to remain infection free after one-stage exchange without the use of antibiotic cement (Steckelberg & Osman 2000). When antibiotic impregnated cement was used, 88% (range 76-100%) of patients have been reported to remain infection free at follow up (Callaghan, et al. 1999, Jackson & Schmalzried 2000, Langlais 2003, Steckelberg & Osman 2000). Results for one-stage exchange in knee arthroplasty revision are in general worse than for hips, with only 65% (range 57-100%) of patients remaining free of recurrence of infection at follow up (Steckelberg & Osmon 2000). On the basis of these results, one-stage exchange of an infected prosthesis is rarely advised for prosthetic knee infections (Trampuz & Zimmerli 2008, Zimmerli, et al. 2004). There are, however some advantages with one-stage exchange; patients undergo a single operation and generally require a shorter period of hospitalisation in total.

Consensus recommendations for one-stage exchange suggest that it should only be considered where there is minimal soft tissue damage and where less virulent organisms are involved (Hirakawa, et al. 1998, Jackson & Schmalzried 2000, Miley, et al. 1982, Trampuz & Zimmerli 2008, Zimmerli, et al. 2004). The presence of sinus tract is considered a relative contraindication for one-stage exchange. Ideally the causative agent should be known prior to resection arthroplasty and treatment commenced preoperatively (Zimmerli, et al. 2004).

In two-stage exchange procedures, reimplantation is delayed for a variable length of time from 2 weeks to several months. Spacers impregnated with antibiotic are commonly inserted to maintain limb length and improve patient mobility during that interval (Leunig, et al. 1998). Antibiotics with activity against the isolated pathogen are administered for at least 6 weeks. Tissue samples are often routinely taken from the periprosthetic tissue at the time of reimplantation for microbiological culture to assess the efficacy of the interim treatment (Insall, et al. 1983, Wilson, et al. 1990, Windsor, et al. 1990). In infections with

difficult-to-treat micro-organisms such as MRSA, resistant enterococci and fungi, current consensus guidelines recommends prolonged interval between removal and reimplantation without the use of a spacer (Trampuz & Zimmerli 2008, Zimmerli, et al. 2004)

Two-stage exchange, in general, has a higher success rate compared to one-stage with rates of 63-100% (Colyer & Capello 1994, Haleem, et al. 2004, Jansen, et al. 2009, Woods, et al. 1983). In hip arthroplasty two-stage exchange without the use of antibiotic impregnated cement, 81% of patients (range 53-100%) remain free of recurrent infection increasing to 93% (73-100%) when antibiotic cement is used (Laffer, et al. 2006, Langlais, et al. 2006, Steckelberg & Osman 2000). In knee arthroplasty infections, 84% (38-100%) of patients in whom antibiotic cement is not used, and 88% (63-100%) of patients in whom antibiotic impregnated cement is used remain infection free following two stage exchange (Bengtson, et al. 1989, Grogan, et al. 1986, Hanssen, et al. 1994, Insall, et al. 1983, Morrey, et al. 1989, Rand, et al. 1986, Wang & Chen 1997, Wasielewski, et al. 1996, Wilson, et al. 1990, Windsor, et al. 1990, Woods, et al. 1983).

A number of factors potentially influence treatment outcomes in two-stage exchange procedures. Polymicrobial infection, infection with virulent organisms including *Staphylococcus aureus* and methicillin resistant coagulase negative *Staphylococcus* species, the presence of rheumatoid arthritis and a history of prior multiple revisions have all been shown to associated with lower rates of success in two-stage exchanges (Hirakawa, et al. 1998, Lim, et al. 2009, Mittal, et al. 2007). Current consensus guidelines recommend two-stage exchange in chronic infections with moderately or severely damaged tissue or if a sinus tract is present (Trampuz & Zimmerli 2008, Zimmerli, et al. 2004).

5.4 Resection arthroplasty

Resection arthroplasty and amputation are generally reserved for patients with refractory infections particularly where there is severe loss of bone stock or where functional improvement following revision is unlikely (Trampuz & Zimmerli 2008, Zimmerli, et al. 2004). Whilst rates of recurrence of infection are low, patients have worse functional outcomes and up to 80% of patients report residual pain following resection (Morrey, et al. 1989).

5.5 Debridement and retention of the prosthesis

Debridement and retention of the prosthesis is an attractive treatment option for many patients given that it is the least invasive, with a lower surgical morbidity, and is generally associated with good functional outcomes (Trampuz & Zimmerli 2008, Zimmerli, et al. 2004). Open arthrotomy and debridement is recommended when attempting retention of the prosthesis as poorer results are reported with arthroscopic 'washout' compared to open 'washout' (Laffer, et al. 2006). Following debridement, patients should receive biofilm active antibiotics generally for a longer duration than with surgical exchange or resection.

Early studies of debridement and prosthesis retention strategies to treat prosthetic joint infection were disappointing with recurrence of infection at 2 years reported in 69% of patients (Brandt, et al. 1997). Poor outcomes have been reported when symptoms are present greater than 8 days, when a sinus tract is present and with late chronic infections; In some instances all patients with late infection experienced treatment failure (Berbari, et al.

2006a, Crockarell, et al. 1998, Marculescu, et al. 2006b). High failure rates have also observed with specific organisms, only 12% of patients with *Staphylococcus aureus* infection experiencing successful treatment outcomes (Deirmengian, et al. 2003, Marculescu, et al. 2006a). Gram-negative infections, polymicrobial infections and culture negative prosthetic joint infections were also associated with higher rates of recurrence of infection following debridement and retention (Berbari, et al. 2007, Hsieh, et al. 2009a, Marculescu & Cantey 2008). However, successful outcomes have been reported in the setting of early or haematogenous infections (Morrey, et al. 1989, Wasielewski, et al. 1996). Tsuyakama et al reported a successful outcome in 71% of patients with early infections treated with debridement of the prosthetic joint followed by four weeks of parenteral antibiotics with an average follow up of 3.8 years (Tsukayama, et al. 1996).

Newer treatment strategies evolved as understanding of the role of biofilm in the pathogenesis of prosthetic joint infections increased. In vivo studies using guinea pig tissue-cage animal model by Widmer et al demonstrated the clinical utility of rifampicin in chronic biofilm infections (Widmer, et al. 1990). Further studies also identified that quinolones retained activity in the presence of biofilms (Schwank, et al. 1998, Widmer, et al. 1991).

The addition of rifampicin to antimicrobial regimens has led to a significant improvement in success rates reported in the treatment of gram-positive prosthetic joint infection; in many instances comparable to that reported for two-stage exchange. In our experience combination treatment including rifampicin has resulted in successful treatment in up to 90% of patients (Aboltins, et al. 2007); however successful outcomes are associated with several factors. Higher success rates are reported where the causative organism is a staphylococcus species and when antibiotic therapy is continued for a protracted period; 12 months or greater, (Choong, et al. 2007, Widmer, et al. 1992). In contrast the rate of success is significantly diminished when a fistula is present, particularly in knee arthroplasty where successful outcomes have been reported in only 45-69% of patients. (Drancourt, et al. 1993).

The only randomised double-blinded control trial examining the role of rifampicin in the treatment of prosthetic device staphylococcal infections was conducted from 1992 through 1997. The study involved 33 patients with orthopaedic device infections and duration of symptoms less than one year. Patients were randomised to receive rifampicin 450mg and ciprofloxacin 750mg (twice daily) or ciprofloxacin and placebo. Rifampicin/ciprofloxacin combination was successful in all patients compared to 58% of patients who received ciprofloxacin alone (Zimmerli, et al. 1998). Subsequent studies corroborated these results with success rates of greater than 85% of patients treated with debridement and retention and rifampicin containing antibiotic treatment (Berdal, et al. 2005, Byren, et al. 2009, Rao, et al. 2003). The main limitations with the use of rifampicin are the high likelihood of generation of resistance when used without a second antibiotic and the hepatic and gastrointestinal toxicities (John, et al. 2009, Widmer, et al. 1990). Therefore careful, regular follow up of patients is necessary and the management these antibiotics should involve collaboration between Infectious Diseases Physicians and Orthopaedic Surgeons.

The investigation of newer agents for the treatment of prosthetic joint infection is ongoing. In guinea pig foreign-body infection model, John et al assessed the activity of newer agents including linezolid and daptomycin, alone and in combination with rifampicin. In this study

neither daptomycin nor linezolid had activity against adherent MRSA when used as monotherapy. When used in combination with rifampicin, daptomycin at a dose of 30mg/kg (corresponding to a dose of 6mg/kg in humans) cured 67% of cage infections. At this dose, no cases of rifampicin resistance emerged. Results were less encouraging for linezolid; even in combination with rifampicin, linezolid failed to cure any cage infection. Resistance to rifampicin emerged in 8% of cage infections treated with rifampicin-linezolid combinations (John, et al. 2009).

For gram-negative infections, ciprofloxacin has been shown to be effective in guinea pig tissue cage models (Widmer, et al. 1991). In a study of 28 patients with bone and joint infections secondary to gram-negative bacilli combination therapy with cefepime and fluoroquinolone obtained a cure in 79% of patients. However only 5 patients in this cohort had a prosthetic joint infection, two were treated with debridement and retention and only one of which was cured (the second patient died from a cause unrelated to the infection) (Legout, et al. 2006). In prosthetic joint infection secondary to gram negative bacilli, debridement and retention has yielded a success rate as low as 27% (Hsieh, et al. 2009b). This contrasts with our results where by infection free survival at 2 years was 94% in gram-negative infections when fluoroquinolone was used in conjunction with debridement and retention (Aboltins, et al. 2011). Again this is in the setting of short duration of symptoms (median 7 days) and prolonged oral antibiotic treatment (median 12 months).

The duration of antibiotic after debridement and retention varies in reported clinical studies ranging from six months to greater than 4 years. In a study by Laffer et al there was no difference in outcome in patients receiving three to six months of antibiotics compared with greater than six months (91% v 87% success). In this study patients were followed up for a median duration of 28 (range, 2–193) months and 55% of infections were caused by *Staphylococcus* species (Laffer, et al. 2006). In accordance with consensus guidelines, debridement and retention of the prosthetic joint should be considered in patients with a short duration of symptoms in the absence of implant loosening and soft tissue damage where antibiotics with biofilm activity are available (Laffer, et al. 2006, Matthews, et al. 2009, Trampuz & Zimmerli 2008, Zimmerli, et al. 2004).

6. Conclusion

Prosthetic joint infections involve a complex interplay between the biofilm forming microorganisms, host responses and the implant. These infections are an uncommon but devastating complication of arthroplasty. However with given the ageing population the number of patients requiring arthroplasty is set to increase exponentially. Clinical investigation is imperative to increase understanding, improve diagnosis, optimise treatment and ultimately prevent prosthetic joint infections. While 2-stage exchanges remains the most reliable and consistent treatment option in terms of successful outcomes, the advent of more accurate diagnostic tools and combining the use of newer antibiotic agents with debridement and retention of the prosthetic joint should be considered a viable treatment option rather than an alternative. However this works best where a clear treatment protocol has been established, that targets patients at the earliest onset of symptoms, where debridement is aggressive and treatment involves is a combined

approach between infectious Diseases Physicians and Orthopaedic Surgeons. Results at our institution attest to the success of such a protocol.

7. References

- Aalto, K., Osterman, K., Peltola, H. & Rasanen, J. Change in Erythrocyte sedimentation rate and c-reactive protein after total hip arthroplasty. *Clinical Orthopaedics and Related Research* 184, 118-120 (1984).
- Aboltins, C.A., Dowsey, M.M., Buising, K.L., Peel, T.N., Daffy, J.R., Choong, P.F. & Stanley, P.A. Gram-negative prosthetic joint infection treated with debridement, prosthesis retention and antibiotic regimens including a fluoroquinolone. *Clin Microbiol Infect* 17, 862-867 (2011).
- Aboltins, C.A., Page, M.A., Buising, K.L., Jenney, A.W.J., Daffy, J.R. & Choong, P.F.M. Treatment of staphylococcal prosthetic joint infections with debridement, prosthesis retention and oral rifampicin and fusidic acid. *Clinical Microbiology and Infection* 13, 586-591 (2007).
- Ahnfelt, L., Herberts, P., Malchau, H. & Andersson, G.B.J. Prognosis of total hip replacement. *Acta Orthopaedica Scandinavica* 61, 2-26 (1990).
- Amann, R. & Fuchs, B.M. Single-cell identification in microbial communities by improved fluorescence in situ hybridization techniques. *Nature Reviews Microbiology* 6, 339-348 (2008).
- Amorena, B., Gracia, E., Monzon, M., Leiva, J., Oteiza, C., Perez, M., Alabart, J.L. & Hernandez-Yago, J. Antibiotic susceptibility assay for *Staphylococcus aureus* in biofilms developed in vitro. *Journal of Antimicrobial Chemotherapy* 44, 43-55 (1999).
- Atkins, B.L., Athanasou, N., Deeks, J.J., Crook, D.W.M., Simpson, H., Peto, T.E.A., Lardysmith, P.M.C. & Berendt, A.R. Prospective Evaluation of Criteria for Microbiological Diagnosis of Prosthetic-Joint Infection at Revision Arthroplasty. *Journal of Clinical Microbiology* 36, 2932-2939 (1998).
- Bauer, T.W., Parvizi, J., Kobayashi, N. & Krebs, V. Diagnosis of periprosthetic infection. *J Bone Joint Surg Am* 88-A, 869-882 (2006).
- Bengtson, S. & Knutson, K. The infected knee arthroplasty. *Acta Orthopaedica Scandinavica* 62, 301-311 (1991).
- Bengtson, S., Knutson, K. & Lidgren, L. Treatment of Infected Knee Arthroplasty. *Clinical Orthopaedics and Related Research* 245, 173-178 (1989).
- Berbari, E.F., Hanssen, A.D., Duffy, M.C., Steckelberg, J.M., Ilstrup, D.M., Harmsen, W.S. & Osmon, D.R. Risk factors for prosthetic joint infection: case-control study. *Clin Infect Dis* 27, 1247-1254 (1998).
- Berbari, E.F., Marculescu, C., Sia, I., Lahr, B.D., Hanssen, A.D., Steckelberg, J.M., Gullerud, R. & Osmon, D.R. Culture-negative prosthetic joint infection. *Clinical Infectious Diseases* 45, 1113-1119 (2007).
- Berbari, E.F., Osmon, D.R., Duffy, M.C., Harmsen, R.N., Mandrekar, J.N., Hanssen, A.D. & Steckelberg, J.M. Outcome of prosthetic joint infection in patients with rheumatoid arthritis: the impact of medical and surgical therapy in 200 episodes. *Clinical Infectious Diseases* 42, 216-223 (2006a).

- Berbari, E.F., Osmon, D.R., Duffy, M.C.T., Harmssen, R.N.W., Mandrekar, J.N., Hanssen, A.D. & Steckelberg, J.M. Outcome of prosthetic joint infection in patients with rheumatoid arthritis: the impact of medical and surgical therapy in 200 episodes. *Clinical Infectious Diseases* 42, 216-223 (2006b).
- Berdal, J.E., Skramm, I., Mowinckel, P., Gulbrandsen, P. & Bjornholt, J.V. Use of rifampicin and ciprofloxacin combination therapy after surgical debridement in the treatment of early manifestation prosthetic joint infections. *Clinical Microbiology and Infection* 11, 843-845 (2005).
- Bori, G., Soriano, A., Garc a, S.n., Gallart, X., Casanova, L., Mallofre, C., Almela, M., Mart nez, J.a., Riba, J. & Mensa, J. Low sensitivity of histology to predict the presence of microorganisms in suspected aseptic loosening of a joint prosthesis. *Modern Pathology* 19, 874-877 (2006).
- Bottner, F., Wegner, a., Winkelmann, W., Becker, K., Erren, M. & Gotze, C. Interleukin-6, procalcitonin and TNF-alpha: markers of peri-prosthetic infection following total joint replacement. *J Bone Joint Surg Am* 89-Br, 94-99 (2007).
- Bozic, K.J. & Ries, M.D. The impact of infection after total hip arthroplasty on hospital and surgeon resource utilization. *J Bone Joint Surg Am* 87-A, 1746-1751 (2005).
- Brandt, C.M., Sistrunk, W.W., Duffy, M.C., Hanssen, a.D., Steckelberg, J.M., Ilstrup, D.M. & Osmon, D.R. Staphylococcus aureus prosthetic joint infection treated with debridement and prosthesis retention. *Clinical Infectious Diseases* 24, 914-919 (1997).
- Byren, I., Bejon, P., Atkins, B.L., Angus, B., Masters, S., McLardy-Smith, P., Gundle, R. & Berendt, a. One hundred and twelve infected arthroplasties treated with 'DAIR' (debridement, antibiotics and implant retention): antibiotic duration and outcome. *Journal of Antimicrobial Chemotherapy* 63, 1264-1271 (2009).
- Callaghan, J.J., Katz, R.P. & Johnston, R.C. One-Stage Revision Surgery of the Infected Hip. *Clinical Orthopaedics and Related Research* 369, 139-143 (1999).
- Canner, G.C., Steinberg, M.E., Heppenstall, R.B. & Balderston, R. The infected hip after total hip arthroplasty. *J Bone Joint Surg Am* 66-A, 1393-1399 (1984).
- Ceri, H., Olson, M.E., Stremick, C., Read, R.R. & Morck, D. The Calgary Biofilm Device : New Technology for Rapid Determination of Antibiotic Susceptibilities of Bacterial Biofilms. *Journal of Clinical Microbiology* 37, 1771-1776 (1999).
- Choong, P.F., Dowsey, M.M., Carr, D., Daffy, J. & Stanley, P. Risk factors associated with acute hip prosthetic joint infections and outcome of treatment with a rifampinbased regimen. *Acta Orthop* 78, 755-765 (2007).
- Clarke, M.T., Roberts, C.P., Lee, P.T.H., Gray, J., Keene, G.S. & Rushton, N. Polymerase Chain Reaction Can Detect Bacterial DNA in Aseptically Loose Total Hip Arthroplasties. *Clinical Orthopaedics and Related Research* 427, 132-137 (2004).
- Colyer, R.a. & Capello, W.N. Surgical Treatment of the Infected Hip Implant. *Clinical Orthopaedics and Related Research* 298, 75-79 (1994).
- Costerton, J.W. Bacterial Biofilms: A Common Cause of Persistent Infections. *Science* 284, 1318-1322 (1999).
- Costerton, J.W., Lewandowski, Z., Caldwell, D.E., Korber, D.R. & Lappin-scott, H.M. Microbial biofilms. *Annual Reviews of Microbiology* 49, 711-745 (1995).
- Crockarell, J.R., Hanssen, A.D., Osmon, D.R. & Morrey, B.F. Treatment of Infection with Debridement and Retention of the Components following Hip Arthroplasty

- Treatment of Infection with Debridement and Retention of the Components following Hip Arthroplasty. *J Bone Joint Surg Am* 80-A, 1306-1313 (1998).
- Cyteval, C., Hamm, V., Sarrabere, M.P., Lopez, F.M., Maury, P. & Taourel, P. Painful infection at the site of hip prosthesis: CT imaging. *Radiology* 224, 477-483 (2002).
- De Man, F.H.R., Graber, P., Luem, M., Zimmerli, W., Ochsner, P.E. & Sendi, P. Broad-range PCR in selected episodes of prosthetic joint infection. *Infection* 37, 292-294 (2009).
- Deacon, J.M., Pagliaro, A.J., Zelicof, S.B. & Horowitz, H.W. Current concepts review. Prophylactic use of antibiotics for procedures after total joint replacement. *J Bone Joint Surg Am* 78-A, 1755-1770 (1996).
- Deirmengian, C., Greenbaum, J., Lotke, P.A., Booth, R.E. & Lonner, J.H. Limited Success with Open Debridement and Retention of Components in the Treatment of Acute Staphylococcus Aureus Infections After Total Knee Arthroplasty. *Journal of Arthroplasty* 18, 22-26 (2003).
- Del Pozo, J.L. & Patel, R. Infection Associated with Prosthetic Joints. *New England Journal of Medicine* 361, 787-794 (2009).
- Delank, K.S., Schmidt, M., Michael, J.W.P., Dietlein, M., Schicha, H. & Eysel, P. The implications of 18F-FDG PET for the diagnosis of endoprosthetic loosening and infection in hip and knee arthroplasty: results from a prospective, blinded study. *BMC Musculoskeletal Disorders* 7, 20-20 (2006).
- Donlan, R.M. & Costerton, J.W. Biofilms : Survival Mechanisms of Clinically Relevant Microorganisms. *Clinical Microbiology and Infection* 15, 167-193 (2002).
- Dowsey, M.M. & Choong, P.F. Obesity is a major risk factor for prosthetic infection after primary hip arthroplasty. *Clin Orthop Relat Res* 466, 153-158 (2008).
- Dowsey, M.M. & Choong, P.F. Obese diabetic patients are at substantial risk for deep infection after primary TKA. *Clin Orthop Relat Res* 467, 1577-1581 (2009).
- Drancourt, M., Stein, A., Argenson, J.N., Zannier, A., Curvale, G. & Raoult, D. Oral rifampin plus ofloxacin for treatment of Staphylococcus-infected orthopedic implants. *Antimicrobial Agents and Chemotherapy* 37, 1214-1218 (1993).
- Fernandez Lopez, A., Luaces Cubells, C., García Garcia, J.J. & Fernandez Pou, J. Procalcitonin in pediatric emergency departments for the early diagnosis of invasive bacterial infections in febrile infants: results of a multicenter study and utility of a rapid qualitative test for this marker. *The Pediatric Infectious Disease Journal* 22, 895-903 (2003).
- Fitzgerald, R.H., Nolan, D.R., Ilstrup, D.M., E., R., Washington, J.A. & Coventry, M.B. Deep wound sepsis following total hip arthroplasty. *J Bone Joint Surg Am* 59-A, 847-847 (1977).
- Frances Borrego, A., Martinez, F.M., Cebrian Parra, J.L., Graneda, D.S., Crespo, R.G. & Lopez-Duran Stern, L. Diagnosis of infection in hip and knee revision surgery: intraoperative frozen section analysis. *International Orthopaedics* 31, 33-37 (2007).
- Ghanem, E., Antoci, V., Jr., Pulido, L., Joshi, A., Hozack, W. & Parvizi, J. The use of receiver operating characteristics analysis in determining erythrocyte sedimentation rate and C-reactive protein levels in diagnosing periprosthetic infection prior to revision total hip arthroplasty. *Int J Infect Dis* 13, e444-449 (2009).

- Giulieri, S.G., Graber, P., Ochsner, P.E. & Zimmerli, W. Management of infection associated with total hip arthroplasty according to a treatment algorithm. *Infection* 32, 222-228 (2004).
- Graves, S., Davidson D, de Steiger R & A., T. Australian Orthopaedic Association National Joint Replacement Registry. Annual Report 2009. Adelaide: Australian Orthopaedic Association. (Adelaide, 2010).
- Gristina, A.G. & Costerton, J.W. Bacterial adherence to biomaterials and tissue . The significance of its role in clinical sepsis to Biomaterials. *J Bone Joint Surg Am* 67-A, 264-273 (2009).
- Grogan, T.J., Dorey, F., Rollins, J. & Amstutz, H.C. Deep sepsis following total knee arthroplasty. Ten-year experience at the University of California at Los Angeles Medical Center. *J Bone Joint Surg Am* 68-A, 226-234 (1986).
- Haleem, A.A., Berry, D.J. & Hanssen, A.D. Mid-Term to Long-Term Followup of Two-stage Reimplantation for Infected Total Knee Arthroplasty. *Clinical Orthopaedics and Related Research* 428, 35-39 (2004).
- Hanssen, A.D., Rand, J.A. & Osmon, D.R. Treatment of the infected total knee arthroplasty with insertion of another prosthesis: the effect of antibiotic-impregnated bone cement. *Clinical Orthopaedics and Related Research*, 44-55 (1994).
- Hirakawa, K., Stulberg, B.N., Wilde, A.H., Bauer, T.W. & Secic, M. Results of 2-stage reimplantation for infected total knee arthroplasty. *Journal of Arthroplasty* 13, 22-28 (1998).
- Hoeffel, D.P., Hinrichs, S.H. & Garvin, K.L. Molecular diagnostics for the detection of musculoskeletal infection. *Clinical Orthopaedics and Related Research*, 37-46 (1999).
- Horan, T.C., Gaynes, R.P., Martone, W.J., Jarvis, W.R. & Emori, G.T. CDC Definitions of Nosocomial Surgical Site Infections, 1992: A Modification of CDC Definitions of Surgical Wound Infections. *Infection Control and Hospital Epidemiology* 13, 606-608 (1992).
- Hsieh, P.-H., Lee, M.S., Hsu, K.-Y., Chang, Y.-H., Shih, H.-N. & Ueng, S.W. Gram-negative prosthetic joint infections: risk factors and outcome of treatment. *Clinical Infectious Diseases* 49, 1036-1043 (2009a).
- Hsieh, P.H., Lee, M.S., Hsu, K.Y., Chang, Y.H., Shih, H.N. & Ueng, S.W. Gram-negative prosthetic joint infections: risk factors and outcome of treatment. *Clin Infect Dis* 49, 1036-1043 (2009b).
- Inman, R.D., Gallegos, K.V., Brause, B.D., Redecha, P.B. & Christian, C.L. Clinical and microbial features of prosthetic joint infection. *American Journal of Medicine* 77, 47-53 (1984).
- Insall, J.N., Thompson, F.M. & Brause, B.D. Two-stage reimplantation for the salvage of infected total knee arthroplasty. *J Bone Joint Surg Am* 65-A, 1087-1087 (1983).
- Jackson, W.O. & Schmalzried, T.P. Limited role of direct exchange arthroplasty in the treatment of infected total hip replacements. *Clinical Orthopaedics and Related Research* 381, 101-105 (2000).
- Jansen, E., Stogiannidis, I., Malmivaara, A., Pajamaki, J., Puolakka, T. & Konttinen, Y. Outcome of prosthesis exchange for infected knee arthroplasty: the effect of treatment approach. *Acta Orthopaedica* 80, 67-77 (2009).

- John, A.-K., Baldoni, D., Haschke, M., Rentsch, K., Schaerli, P., Zimmerli, W. & Trampuz, A. Efficacy of daptomycin in implant-associated infection due to methicillin-resistant *Staphylococcus aureus*: importance of combination with rifampin. *Antimicrobial Agents and Chemotherapy* 53, 2719-2724 (2009).
- Jones, S.M., Morgan, M., Humphrey, T.J. & Lappin-Scott, H. Effect of vancomycin and rifampicin on methicillin-resistant *Staphylococcus aureus* biofilms. *Lancet* 357, 40-41 (2001).
- Ko, P., Ip, D., Chow, K., Cheung, F., Lee, O. & Lam, J. The Role of Intraoperative Frozen Section in Decision Making in Revision Hip and Knee Arthroplasties in a Local Community Hospital. *Journal of Arthroplasty* 20, 189-195 (2005).
- Krimmer, V., Merkert, H., von Eiff, C., Frosch, M., Eulert, J., Lohr, J.F., Hacker, J. & Ziebuhr, W. Detection of *Staphylococcus aureus* and *Staphylococcus epidermidis* in clinical Samples by 16S rRNA-Directed In Site Hybridization. *Journal of Clinical Microbiology* 37, 2667-2673 (1999).
- Kurtz, S., Ong, K., Lau, E., Mowat, F. & Halpern, M. Projections of primary and revision hip and knee arthroplasty in the United States from 2005 to 2030. *J Bone Joint Surg Am* 89-A, 780-785 (2007).
- Kurtz, S.M., Lau, E., Schmier, J., Ong, K.L., Zhao, K. & Parvizi, J. Infection burden for hip and knee arthroplasty in the United States. *Journal of Arthroplasty* 23, 984-991 (2008).
- Kurtz, S.M., Ong, K.L., Lau, E., Bozic, K.J., Berry, D. & Parvizi, J. Prosthetic joint infection risk after TKA in the Medicare population. *Clinical Orthopaedics and Related Research* 468, 52-56 (2010).
- Kwee, T.C., Kwee, R.M. & Alavi, A. FDG-PET for diagnosing prosthetic joint infection: systematic review and metaanalysis. *European Journal of Nuclear Medicine and Molecular Imaging* 35, 2122-2132 (2008).
- Laffer, R.R., Graber, P., Ochsner, P.E. & Zimmerli, W. Outcome of prosthetic knee-associated infection: evaluation of 40 consecutive episodes at a single centre. *Clin Microbiol Infect* 12, 433-439 (2006).
- Langlais, F. Can we improve the results of revision arthroplasty for infected total hip replacement? *J Bone Joint Surg Am* 85-Br, 637-640 (2003).
- Langlais, F., Belot, N., Ropars, M., Thomazeau, H., Lambotte, J.C. & Cathelineau, G. Antibiotic cements in articular prostheses: current orthopaedic concepts. *International Journal of Antimicrobial Agents* 28, 84-89 (2006).
- Larsson, S., Thelander, U.L.F. & Friberg, S. C-reactive protein (CRP) levels after elective orthopedic surgery. *Clinical Orthopaedics and Related Research* 275, 237-242 (1992).
- Legout, L., Senneville, E., Stern, R., Yazdanpanah, Y., Savage, C., Roussel-Delvalet, M., Rosele, B., Migaud, H. & Mouton, Y. Treatment of Bone and Joint Infections Caused by Gram-Negative Bacilli with a Cefepime-Fluoroquinolone Combination. *Clinical Microbiology and Infection* 12, 1030-1033 (2006).
- Leunig, M., Chosa, E., Speck, M. & Ganz, R. A cement spacer for two-stage revision of infected implants of the hip joint. *International Orthopaedics* 22, 209-214 (1998).
- Lim, S.-j., Park, J.-c., Moon, Y.-w. & Park, Y.-s. Treatment of Periprosthetic Hip Infection Caused by Resistant Microorganisms Using 2-Stage Reimplantation Protocol. *Journal of Arthroplasty* 24, 1264-1269 (2009).

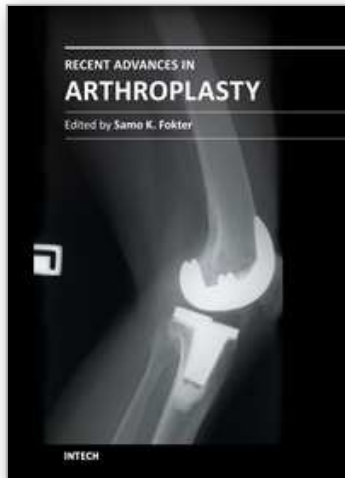
- Marculescu, C.E., Berbari, E.F., Hanssen, A.D., Steckelberg, J.M., Harmsen, S.W., Mandrekar, J.N. & Osmon, D.R. Outcome of prosthetic joint infections treated with debridement and retention of components. *Clinical Infectious Diseases* 42, 471-478 (2006a).
- Marculescu, C.E., Berbari, E.F., Hanssen, A.D., Steckelberg, J.M., Harmsen, S.W., Mandrekar, J.N. & Osmon, D.R. Outcome of prosthetic joint infections treated with debridement and retention of components. *Clinical Infectious Diseases* 42, 471-478 (2006b).
- Marculescu, C.E. & Cantey, J.R. Polymicrobial Prosthetic Joint Infections. *Clinical Orthopaedics and Related Research* 466, 1397-1404 (2008).
- Mariani, B.D., Martin, D.S., Levine, M.J., Booth, R.E. & Tuan, R.S. The Coventry Award. Polymerase chain reaction detection of bacterial infection in total knee arthroplasty. *Clinical Orthopaedics and Related Research*, 11-22 (1996).
- Matthews, P.C., Berendt, a.R., McNally, M.a. & Byren, I. Diagnosis and management of prosthetic joint infection. *British Medical Journal* 338, b1773-b1773 (2009).
- McDonald, D.J., Fitzgerald, R.H. & Ilstrup, D.M. Two-stage reconstruction of a total hip arthroplasty because of infection. *J Bone Joint Surg Am* 71-A, 828-834 (1989).
- McDowell, A. & Patrick, S. Evaluation of Nonculture Methods for the Detection of Prosthetic Hip Biofilms. *Clinical Orthopaedics and Related Research* 437, 74-82 (2005).
- Miley, G.B., Scheller, A.D. & Turner, R.H. Medical and surgical treatment of the septic hip with one-stage revision arthroplasty. *Clinical Orthopaedics and Related Research* 170, 76-76 (1982).
- Miller, T.T. Imaging of knee arthroplasty. *European Journal of Radiology* 54, 164-177 (2005).
- Mirra, J.M., Amstutz, H.C., Matos, M. & Gold, R. The pathology of the joint tissues and its clinical relevance in prosthesis failure. *Clinical Orthopaedics and Related Research* 117, 221-240 (1976).
- Mittal, Y., Fehring, T.K., Hanssen, A., Marculescu, C., Odum, S.M. & Osmon, D. Two-stage reimplantation for periprosthetic knee infection involving resistant organisms. *J Bone Joint Surg Am* 89-A, 1227-1231 (2007).
- Monzon, M., Oteiza, C., Leiva, J., Lamata, M. & Amorena, B. Biofilm testing of *Staphylococcus epidermidis* clinical isolates: low performance of vancomycin in relation to other antibiotics. *Diagnostic Microbiology and Infectious Disease* 44, 319-324 (2002).
- Moojen, D.J.F., Spijkers, S.N.M., Schot, C.S., Nijhof, M.W., Vogely, H.C., Fleer, A., Verbout, A.J., Castelein, R.M., Dhert, W.J.a. & Schouls, L.M. Identification of orthopaedic infections using broad-range polymerase chain reaction and reverse line blot hybridization. *J Bone Joint Surg Am* 89-A, 1298-1305 (2007).
- Moran, E., Masters, S., Berendt, A.R., McLardy-Smith, P., Byren, I. & Atkins, B.L. Guiding empirical antibiotic therapy in orthopaedics: The microbiology of prosthetic joint infection managed by debridement, irrigation and prosthesis retention. *Journal of Infection* 55, 1-7 (2007).
- Morrey, B.F., Westholm, F., Schoifet, S., Rand, J.A. & Bryan, R.S. Long-Term Results of Various Treatment Options for Infected Total Knee Arthroplasty. *Clinical Orthopaedics and Related Research* 248 120-128 (1989).

- Moter, A. & Gobel, U.B. Fluorescence in situ hybridization (FISH) for direct visualization of microorganisms. *Journal of Microbiological Methods* 41, 85-112 (2000).
- Murdoch, D.R., Roberts, S.a., G., V., Shah, M.a., Taylor, S.L., Morris, a.J. & Corey, G.R. Infection of orthopedic prostheses after *Staphylococcus aureus* bacteremia. *Clinical Infectious Diseases* 32, 647-649 (2001).
- Nunez, L.V., Buttaro, M.a., Morandi, A., Pusso, R. & Piccaluga, F. Frozen sections of samples taken intraoperatively for diagnosis of infection in revision hip surgery. *Acta Orthopaedica* 78, 226-230 (2007).
- Ong, K.L., Kurtz, S.M., Lau, E., Bozic, K.J., Berry, D.J. & Parvizi, J. Prosthetic joint infection risk after total hip arthroplasty in the Medicare population. *Journal of Arthroplasty* 24, 105-109 (2009).
- Pandey, R., Berendt, A.R. & Athanasou, N.A. Histological and microbiological findings in non-infected and infected revision arthroplasty tissues. *Archives of Orthopaedic and Trauma Surgery* 120, 570-574 (2000).
- Panush, R.S. & Petty, R.W. Inhibition of human lymphocyte responses by methylmethacrylate. *Clinical Orthopaedics and Related Research* 134, 356-356 (1978).
- Petty, W. The effect of methylmethacrylate on the bacterial inhibiting properties of normal human serum. *Clinical Orthopaedics and Related Research*, 266-278 (1978).
- Poss, R., Thornhill, T.S., Ewald, F.C., Thomas, W.H., Batte, N.J. & Sledge, C.B. Factors influencing the incidence and outcome of infection following total joint arthroplasty. *Clinical Orthopaedics and Related Research* 182, 117-126 (1984).
- Poulsen, L.K., Ballard, G. & Stahl, D.a. Use of rRNA fluorescence in situ hybridization for measuring the activity of single cells in young and established biofilms. *Applied and Environmental Microbiology* 59, 1354-1360 (1993).
- Pulido, L., Ghanem, E., Joshi, A., Purtill, J.J. & Parvizi, J. Periprosthetic joint infection: the incidence, timing, and predisposing factors. *Clinical Orthopaedics and Related Research* 466, 1710-1715 (2008).
- Rand, J.A., Bryan, R., Morrey, B. & Westholm, F. Management of Infected Total Knee Arthroplasty. *Clinical Orthopaedics and Related Research* 205, 75-85 (1986).
- Rao, N., Crossett, L.S., Sinha, R.K. & L., J. Long-term suppression of infection in total joint arthroplasty. *Clinical Orthopaedics and Related Research* 414, 55-60 (2003).
- Rose, W.E. & Poppens, P.T. Impact of biofilm on the in vitro activity of vancomycin alone and in combination with tigecycline and rifampicin against *Staphylococcus aureus*. *Journal of Antimicrobial Chemotherapy* 63, 485-488 (2009).
- Schafer, P., Fink, B., Sandow, D., Margull, A., Berger, I. & Frommelt, L. Prolonged bacterial culture to identify late periprosthetic joint infection: a promising strategy. *Clinical Infectious Diseases* 47, 1403-1409 (2008).
- Schwank, S., Rajacic, Z., Zimmerli, W. & Blaser, J. Impact of bacterial biofilm formation on in vitro and in vivo activities of antibiotics. *Antimicrobial Agents and Chemotherapy* 42, 895-898 (1998).
- Shah, K., Mohammed, A., Patil, S., McFadyen, A. & Meek, R.M.D. Circulating cytokines after hip and knee arthroplasty: a preliminary study. *Clinical Orthopaedics and Related Research* 467, 946-951 (2009).

- Sharma, D., Douglas, J., Coulter, C., Weinrauch, P. & Crawford, R. Microbiology of infected arthroplasty: implications for empiric peri-operative antibiotics. *Journal of Orthopaedic Surgery (Hong Kong)* 16, 339-342 (2008).
- Shiau, a.L. & Wu, C.L. The inhibitory effect of Staphylococcus epidermidis slime on the phagocytosis of murine peritoneal macrophages is interferon-independent. *Microbiology and Immunology* 42, 33-40 (1998).
- Shih, L.-Y., Wu, J.-J. & Yanc, D.-J. Erythrocyte Sedimentation Rate and C-reactive Protein Values in Patients with Total Hip Arthroplasty. *Clinical Orthopaedics and Related Research* 225, 238-246 (1987).
- Smith, S.L., Wastie, M.L. & Forster, I. Radionuclide bone scintigraphy in the detection of significant complications after total knee joint replacement. *Clinical radiology* 56, 221-224 (2001).
- Souli, M. & Giamarellou, H. Effects of Slime Produced by Clinical Isolates of Coagulase-Negative Staphylococci on Activities of Various Antimicrobial Agents. *Antimicrobial Agents and Chemotherapy* 42, 939-941 (1998).
- Southwood, R.T., Rice, J.L., McDonald, P.J., Hakendorf, P.H. & Rozenbils, M.A. Infection in experimental hip arthroplasties. *J Bone Joint Surg Am* 67-Br, 229-231 (1985).
- Spangehl, M.J., Masri, B.A., Connell, J.X.O. & Duncan, C.P. Prospective Analysis of Preoperative and Intraoperative Investigations for the Diagnosis of Infection at the Sites of Two Hundred and Two Revision Total Hip Arthroplasties. *J Bone Joint Surg Am* 81-A, 672-683 (1999).
- Steckelberg, J.M. & Osman, D.R. Prosthetic Joint Infections. in *Infections Associated with Indwelling Medical Devices*, 3rd ed. (eds. Waldvogel, F.A. & Bisno, A.L.) 173-209 ASM Press, 1-55581-177-9, Washington D.C, 2000.
- Steckelberg, J.M. & Osmon, D.R. Prosthetic Joint Infections. in *Infections Associated with Indwelling Medical Devices* (eds. Waldvogel, F.A. & Bisno, A.L.) 173-209 ASM Press, Washington DC, 2000.
- Stewart, P.S. & Costerton, J.W. Antibiotic resistance of bacteria in biofilms. *Lancet* 358, 135-138 (2001).
- Surin, V.V., Sundholm, K. & Backman, L. Infection After Total Hip Replacement. *Journal of Bone and Joint Surgery: British Volume* 65, 412-418 (1983).
- Swan, J., Dowsey, M., Babazadeh, S., Mandaleson, A. & Choong, P.F. Significance of sentinel infective events in haematogenous prosthetic knee infections. *ANZ J Surg* 81, 40-45 (2011).
- Trampuz, A., Hanssen, A.D., Osmon, D.R., Mandrekar, J., Steckelberg, J.M. & Patel, R. Synovial fluid leukocyte count and differential for the diagnosis of prosthetic knee infection. *American Journal of Medicine* 117, 556-562 (2004).
- Trampuz, A., Osmon, D.R., Hanssen, A.D., Steckelberg, J.M. & Patel, R. Molecular and antibiofilm approaches to prosthetic joint infection. *Clinical Orthopaedics and Related Research*, 69-88 (2003).
- Trampuz, A., Piper, K.E., Jacobson, M.J., Hanssen, A.D., Unni, K.K., Osmon, D.R., Mandrekar, J.N., Cockerill, F.R., Steckelberg, J.M., Greenleaf, J.F. & Patel, R. Sonication of removed hip and knee prostheses for diagnosis of infection. *New England Journal of Medicine* 357, 654-663 (2007).

- Trampuz, A. & Zimmerli, W. Diagnosis and treatment of implant-associated septic arthritis and osteomyelitis. *Current Infectious Disease Reports* 10, 394-403 (2008).
- Trebse, R., Pisot, V. & Trampuz, A. Treatment of infected retained implants. *J Bone Joint Surg Am* 87-Br, 249-256 (2005).
- Tsukayama, D.T., Estrada, R. & Gustilo, R.B. Infection after total hip arthroplasty. A study of the treatment of one hundred and six infections. *J Bone Joint Surg Am* 78-A, 512-523 (1996).
- Tunney, M.M., Patrick, S., Curran, M.D., Ramage, G., Hanna, D., Nixon, J.R., Gorman, S.P., Davis, R.I. & And, N. Detection of prosthetic hip infection at revision arthroplasty by immunofluorescence microscopy and PCR amplification of the bacterial 16S rRNA gene. *Journal of Clinical Microbiology* 37, 3281-3290 (1999).
- Vandercam, B., Jeumont, S., Cornu, O., Yombi, J.-C., Lecouvet, F.d.r., Lef vre, P., Ireng , L.o.M. & Gala, J.-L. Amplification-based DNA analysis in the diagnosis of prosthetic joint infection. *Journal of Molecular Diagnostics* 10, 537-543 (2008).
- Wang, J.W. & Chen, C.E. Reimplantation of infected hip arthroplasties using bone allografts. *Clinical Orthopaedics and Related Research* 335, 202-202 (1997).
- Wasielowski, R.C., Barden, R.M. & Rosenberg, A.G. Results of different surgical procedures on total knee arthroplasty infections. *Journal of Arthroplasty* 11, 931-938 (1996).
- Widmer, A.F., Frei, R., Rajacic, Z. & Zimmerli, W. Correlation between In Vivo and In Vitro Efficacy of Antimicrobial Agents against Foreign Body Infections. *Journal of Infectious Diseases* 162, 96-102 (1990).
- Widmer, A.F., Gaechter, A., Ochsner, P.E. & Zimmerli, W. Antimicrobial treatment of orthopedic implant-related infections with rifampin combinations. *Clinical Infectious Diseases* 14, 1251-1253 (1992).
- Widmer, A.F., Wiestner, A., Frei, R. & Zimmerli, W. Killing of Nongrowing and Adherent *Escherichia coli* Determines Drug Efficacy in Device-Related Infections. *Antimicrobial Agents and Chemotherapy* 35, 741-746 (1991).
- Wilson, M.G., Kelley, K. & Thornhill, T.S. Infection as a complication of total knee-replacement arthroplasty. Risk factors and treatment in sixty-seven cases. *J Bone Joint Surg Am* 72-A, 878-883 (1990).
- Windsor, R.E., Insall, J.N., Urs, W.K., Miller, D.V. & Brause, B.D. Two-stage reimplantation for the salvage of total knee arthroplasty complicated by infection. Further follow-up and refinement of indications. *J Bone Joint Surg Am* 72-A, 272-278 (1990).
- Woods, G.W., Lionberger, D.R. & Tullos, H.S. Failed total knee arthroplasty: Revision and arthrodesis for infection and noninfectious complications. *Clinical Orthopaedics and Related Research* 173, 184-184 (1983).
- Wymenga, A.B., van Horn, J.R., Theeuwes, A., Muytjens, H.L. & Slooff, T.J. Perioperative factors associated with septic arthritis after arthroplasty. Prospective multicenter study of 362 knee and 2,651 hip operations. *Acta Orthopaedica Scandinavica* 63, 665-671 (1992).
- Yang, K., Yeo, S.J., Lee, B.P. & Lo, N.N. Total knee arthroplasty in diabetic patients: a study of 109 consecutive cases. *Journal of Arthroplasty* 16, 102-106 (2001).
- Zimmerli, W. Prosthetic-joint-associated infections. *Best Practice and Research Clinical Rheumatology* 20, 1045-1063 (2006).

- Zimmerli, W., Trampuz, A. & Ochsner, P.E. Prosthetic-joint infections. *New England Journal of Medicine* 351, 1645-1654 (2004).
- Zimmerli, W., Widmer, A.F., Blatter, M., Frei, R. & Ochsner, P.E. Role of rifampin for treatment of orthopedic implant-related staphylococcal infections: a randomized controlled trial. *Journal of the American Medical Association* 279, 1537-1541 (1998).
- Zoccali, C., Teori, G. & Salducca, N. The role of FDG-PET in distinguishing between septic and aseptic loosening in hip prosthesis: a review of literature. *International Orthopaedics* 33, 1-5 (2009).



Recent Advances in Arthroplasty

Edited by Dr. Samo Fokter

ISBN 978-953-307-990-5

Hard cover, 614 pages

Publisher InTech

Published online 27, January, 2012

Published in print edition January, 2012

The purpose of this book was to offer an overview of recent insights into the current state of arthroplasty. The tremendous long term success of Sir Charnley's total hip arthroplasty has encouraged many researchers to treat pain, improve function and create solutions for higher quality of life. Indeed and as described in a special chapter of this book, arthroplasty is an emerging field in the joints of upper extremity and spine. However, there are inborn complications in any foreign design brought to the human body. First, in the chapter on infections we endeavor to provide a comprehensive, up-to-date analysis and description of the management of this difficult problem. Second, the immune system is faced with a strange material coming in huge amounts of micro-particles from the tribology code. Therefore, great attention to the problem of aseptic loosening has been addressed in special chapters on loosening and on materials currently available for arthroplasty.

How to reference

In order to correctly reference this scholarly work, feel free to copy and paste the following:

Michelle M. Dowsey, Trisha N. Peel and Peter F.M. Choong (2012). Infection in Primary Hip and Knee Arthroplasty, Recent Advances in Arthroplasty, Dr. Samo Fokter (Ed.), ISBN: 978-953-307-990-5, InTech, Available from: <http://www.intechopen.com/books/recent-advances-in-arthroplasty/infection-in-primary-hip-and-knee-arthroplasty>

INTeCH
open science | open minds

InTech Europe

University Campus STeP Ri
Slavka Krautzeka 83/A
51000 Rijeka, Croatia
Phone: +385 (51) 770 447
Fax: +385 (51) 686 166
www.intechopen.com

InTech China

Unit 405, Office Block, Hotel Equatorial Shanghai
No.65, Yan An Road (West), Shanghai, 200040, China
中国上海市延安西路65号上海国际贵都大饭店办公楼405单元
Phone: +86-21-62489820
Fax: +86-21-62489821

© 2012 The Author(s). Licensee IntechOpen. This is an open access article distributed under the terms of the [Creative Commons Attribution 3.0 License](https://creativecommons.org/licenses/by/3.0/), which permits unrestricted use, distribution, and reproduction in any medium, provided the original work is properly cited.

IntechOpen

IntechOpen