

We are IntechOpen, the world's leading publisher of Open Access books Built by scientists, for scientists

6,900

Open access books available

186,000

International authors and editors

200M

Downloads

Our authors are among the

154

Countries delivered to

TOP 1%

most cited scientists

12.2%

Contributors from top 500 universities



WEB OF SCIENCE™

Selection of our books indexed in the Book Citation Index
in Web of Science™ Core Collection (BKCI)

Interested in publishing with us?
Contact book.department@intechopen.com

Numbers displayed above are based on latest data collected.
For more information visit www.intechopen.com



Treatments of Dry AMD

George C. Y. Chiou
Institute of Ocular Pharmacology
College of Medicine
Texas A&M Health Science Center
College Station, TX
USA

1. Introduction

Age-related macular degeneration (AMD) is the most common cause of legal blindness among those over 65 years of age in the United States (Mitchell et al., 1995; Klein et al., 1992). It is also a debilitating disease on central vision in patients over 50 years old (Ambati et al., 2003). As the baby boom generation ages, the incidence of AMD is expected to triple by the year 2025. It was first described in the medical literature as symmetrical central choroidoretinal disease occurring in senile persons (Hutchison 1875). It was not until 1980 that AMD was regenerated to be a significant cause of blindness in the United States (Leibowitz et al., 1980). Even though the prevalence of AMD is highest among Caucasians in western countries, Asians are as high as Caucasians in the development of AMD (Wang et al, 2010). In 2004, WHO estimated that there are 14 million persons worldwide suffering from blindness or severely impaired vision because of AMD. As the population in the Western World is growing older, the morbidity of losing the ability to read and drive resulting from AMD is becoming increasingly apparent (Klein, 1997). A 2004 analysis reported that among Americans over the age of 40, AMD and/or geographic atrophy were present in at least one eye in 1.47% of the population (Friedman et al., 2004). By the year 2020, there may be a 50% increase in the incidence of AMD. The study predicted that as a result of the rising prevalence of AMD, the number of blind people in the U.S. could increase by as much as 70% by 2020 (Congdon et al., 2004). Because of the enormous impact of AMD on the aging population, much public attention and research has been focused on this condition in the past decade.

The therapy that could treat patients at the dry AMD stage and prevent its progression have a huge impact in reducing the incidence of blindness, improving the quality of life and reducing the social costs of AMD, which equals to approximately \$30 B in GDP annually in the year 2003.

AMD occurs initially in a “dry” form with pathological changes in the retinal pigment epithelium (RPE) and drusen accumulation and can progress to geographic atrophy (GA) (90%) and/or “wet” form of AMD (10%) with choroidal neovascularization (CNV) (Klein, 1997). The breakdown of Bruch’s membrane under RPE serves as an entrance for new and immature choroid vessels to grow into the subretinal space that leads to the formation of

CNV (Klein, 1997; Lin and Chiou, 2008; Algveve and Seregard, 2002; Jousen, 2004). CNV can leak fluid as well as hemorrhage in the subretinal space resulting in blurry vision, visual distortion and sudden loss of vision (Nowak, 2006). If left untreated, these lesions progress to form an organized fibrous scar, termed diciform scar, which results in irreversible central vision loss.

The precise etiology is poorly understood despite intensive researches. Thus, we have limited choices of treatment for this kind of disease. Available treatment can be grouped into two major categories: physical and pharmacological (chemical) therapies. The former received extensive attention with little success whereas the latter attract new attention with great hope of success.

2. Etiology and pathogenesis of dry AMD

Drusen is a typical clinicopathologic entity in dry AMD, which causes the changes of retinal pigment epithelium (RPE) and Bruch's membrane (BRM). Drusen is deposited in between the basement membrane of RPE and BRM or external to BRM (Hope et al., 1992). The prevalence and severity of drusen formation in the eyes are linearly related to the progression of AMD. Oxydative stress has long been linked to age-related degenerative diseases and is implicated in the pathogenesis of AMD. The oxidative damage is likely to be the photo reactive pigments which accumulate progressively and constitute the lipofuscin of RPE cells (Imamura et al., 2006; Zhou et al, 2006).

The two major carotenoids in the human macula and retina are lutein and zeaxanthin. Lutein and zeaxanthin are deposited at an up to 5 fold higher content in the macular region of the retina as compared to the peripheral retina. Several functions of these pigments have been hypothesized and these include limitation of the damaging photo-oxidative effects of blue light through its absorption, reduction of the effects of light scatter and chromatic aberration on visual performance, and protection against the adverse effects of photochemical reactions because of the anti-oxidant properties of the carotenoids. So it has been further hypothesized that dietary supplementation with lutein and/or zeaxanthin might protect the retina and/or delay the progression of AMD (Mozaffarieh et al., 2003). Data from the Age-Related Eye Disease Study (AREDS) suggests that supplements that contain carotenoids, anti-oxidant vitamins A, C, and E, and minerals, such as zinc, showed a 25% decrease in the rate of progression to aggressive AMD among high risk patients (AREDS Report, 2001). The findings of the Lutein Anti-oxidant Supplementation Trial (LAST), a prospective, 12-month, randomized, double-masked, placebo-controlled trial, also support a possible therapeutic role of lutein in AMD (Richer et al., 2004). However, the controversial evidence also exists. The information available provides an indication that the carotenoids, lutein and zeaxanthin, may play a role in modulating the course of AMD, yet critical evidence of the beneficial effect has not been found, and crucial information for the most effective design of clinical trials is needed.

Similar to drusen, basal laminar deposit (BLD) is another typical sign of AMD development and led by extracellular deposit. BLD is located between the cell membrane of RPE and its basement membrane (Green and Enger, 1993; Kliffen et al., 1997). The pathogenesis of BLD could be enhanced by a high fat/cholesterol (HFC) diet. The accumulation of lipid particles in BRM is often associated with vascular endothelial growth factor (VEGF) expression and eventual development of CNV in wet AMD (Rudolf et al., 2005).

VEGF has a high degree of selectivity to endothelial cells, reciprocal oxygen regulation, diffusible to its target through extracellular secretion, and affecting multiple components of angiogenesis (endothelial cell proliferation, survival and migration) as well as vascular permeability (Ambati et al., 2003b). There is a lot of evidence showing a putative role of VEGF in CNV formation. Intravitreal injection of an anti-VEGF pegylated aptamer, a synthetic RNA compound specifically designed to bind to extracellular VEGF, stabilized or improved vision in 87.5% of patients with subfoveal CNV 3mo after treatment. However, elimination of VEGF threatens the normal survival of choriocapillaries, which is the trigger of the AMD to begin with. Thus, VEGF inhibitors are double blade swords, which make the control of VEGF levels during the treatment of AMD rather difficult. Inflammation and compromised immune systems are also implicated in the pathogenesis of dry AMD. As a result, anti-inflammatory agents, such as steroids, are frequently tried for the treatment of dry AMD. More specifically, complement components such as C3 and C5 are constituents of drusen in AMD patients (Ambati et al., 2003a). Others, such as interleukin-1, interleukin-6, and tumor necrosis factor (TNF) are implicated to develop dry AMD as well. Thus, interleukin-1 blockers have been tried in the dry AMD animal models as well.

The anti-angiogenic effect of corticosteroids has a dual mechanism. Not only do corticosteroids inhibit inflammation, but they also affect vascular endothelial cell extracellular matrix (ECM) turnover (Kaven, et al., 2001; Danis, et al., 2000). Similarly, corticosteroids decrease RPE cellular migration and proliferation by effecting a diminished enzymatic degradation of ECM components.

Invasion and migration of endothelial cells through the extracellular matrix during angiogenesis are orchestrated by the integrin family of cell adhesion molecules. They facilitate migration by interacting with adhesion proteins in the ECM, such as collagen, fibronectin, fibrinogen, laminin, vitronectin and von Willebrand factor. The process of interacting with adhesion proteins was potentiated by the secretion of matrix metalloproteinases (MMPs), a family of proteolytic enzymes that degrade basement membrane and extracellular matrix proteins, modulated by tissue inhibitors of metalloproteinases (TIMPs) (Ambati, et al., 2003b).

Drugs, which can change the construction of ECM or change the balance of MMPs and TIMPs, may have effects on angiogenesis process. Integrin $\alpha(v)\beta3$ is predominately expressed on endothelial cells in choroidal neovascularization (CNV). N-Biphenyl sulfonyl-phenylalanine hydroxamic acid (BPHA) is a synthetic, selective inhibitor of matrix metalloproteinase (MMP)-2, -9, -14. Oral administration of BPHA can reduce experimental laser-induced choroidal neovascularization (Kohri, et al., 2003). The binding of urokinase plasminogen activator (uPA) and its receptor (uPAR) triggers twin cascades of events during cancer research, the first of which is destruction of the extracellular matrix, and the second is intracellular signaling to program gene expression leading to cell migration, cell invasion, metasis, and angiogenesis. Overexpression of uPA/uPAR system has been shown in surgically excised CNV, and in laser-induced CNV. The octapeptide A6 is derived from the non-receptor-binding regulation of uPA. Subretinal injection of adenoviral or adeno-associated viral vectors have been used to transform the RPE into a factory for sustained local delivery of a drug or gene in experimental models of CNV. Angiostatin (act as a VEGF scavenger), TIMP-3. PEDF has been tested and showed inhibition of development of CNV in animal models (Ambati, et al., 2003b). An antiangiogenic activity that may last for several

months after a single intravitreal injection of doses greater than 10(8) pfu of AdPEDF. 11 have been reported. This study showed that adenoviral vector-mediated ocular gene transfer is a viable approach for the treatment of neovascular AMD (Rasmussen et al., 2001; Campochiaro et al., 2006).

In addition to age, high fat diet, light oxidation, and inflammation, the factors of smoke, alcohol, and gene are frequently questioned. Cigarette smoke has been indicated by epidemiologic studies that it is the single greatest environmental risk factor for both dry and wet AMD (Evans, 2001). Mice experiments with inhaled cigarette smoke resulted in the formation of such-RPE deposits, thickening of BRM and accumulation of deposits, within BRM's membrane (Marin-Castano et al., 2006). On another experiment, mice were fed with nicotine in drinking water, the results showed nicotine increased the size and severity of experimental CNV formation (Suner, 2004).

The influence of alcohol on the development of CNV in wet AMD was studied by Bora et al (2006). The results showed that the activity of fatty acid ethyl ester synthase (FAEES) activity increased 4-fold in the choroid of alcohol treated rats as compared to controls. Further, the amount of ethylesters produced in the choroid was 10-fold higher in alcohol fed rats than the controls. The size of the CNV formation induced by laser treatment increased by 28% due to alcohol treatment.

In addition to environmental factors, gene also plays an important role in the development of dry AMD. Thus, some animal models used for AMD studies are transgenic mice treated with blue-green light (Espinosa-Heldmann et al., 2004).

There are some diseases which are similar to AMD. They include Stargardt macular dystrophy (STGD) and Sorsby's fundus dystrophy (SFD). STGD is characterized as dry AMD by accumulation of high level of lipofuscin in the RPE. It precedes to degeneration of photoreceptors in the macula and atrophy of RPE (Karan et al., 2005; Raz-Prag et al., 2006). SFD is a rare autosomal dominant disorder that results in degeneration of the macular region, which leads to rapid loss of central vision like wet AMD (Li et al., 2005).

Most importantly, the choroidal blood flow of dry AMD and STGD is compromised and significantly lower than in normal eyes. (Grunwald et al., 2003, 2005) As a result, all metabolic wastes produced from oxidation, inflammation, aging, complement components, cytokines, cigarette smoke, nicotine, high lipid, alcohol and anything else are accumulated in RPE cells and BRM which trigger dry AMD and eventually wet AMD or GA. On the opposite direction, nutrient supply to BRM, RPE and photoreceptors at macula are markedly reduced which facilitate the worsening of dry AMD (Jiang and Chiou, 2007).

It is noteworthy that choroidal blood flow is found to be impaired by every method used to quantify it in the aging eye and in age-related macular degeneration: fluorescein and indocyanine green angiography, color Doppler imaging, laser Doppler flowmetry, and pulsatile ocular blood flow (Freidman, 2000). The vascular model of AMD suggests that the elevation of intravascular pressure is the crucial hemodynamic factor in age-related macular degeneration. AMD is the result of the accumulation of lipids in the sclera and in Bruch's membrane, progressively increasing the stiffness of these tissues, and increasing the postcapillary resistance of the choroidal vasculature. In addition to decreasing choroidal blood flow, the increase in resistance tends to elevate the hydrostatic pressure of the

choriocapillaries, enhancing leakage and deposition of extracellular proteins and lipids, particularly in the posterior pole. These deposits take the form of basal deposits within Bruch's membrane and of drusen, which can comprise the overlying retinal pigment epithelium and cause geographic atrophy of RPE. The progressive deposition of lipid in Bruch's membrane results in the degeneration of elastin and collagen, and ultimately calcification. The combination of elevated choriocapillary pressure, vascular endothelial growth factor, and a break in a calcified Bruch's membrane causes choroidal neovascularization in the neovascular form of AMD. Drusen, as well as the decrease in choroidal blood flow may be epiphenomena (Friedman, 2000; 2004). Vasoactive agents that selectively decrease postcapillary choroidal resistance may prevent the development of CNV. Drugs working in this field may provide a new way for AMD treatment.

3. Treatment of dry AMD with physical means

Treatment of AMD was initially focused in wet AMD and dry AMD was left untreated because no effective method was available then. Drusen is a marker for dry AMD as the size and number of drusen are proportionally related to the progression of the disease. However it was not clear whether it had a role in the pathogenesis of the disease until 2006 (CAPT) when laser therapy was applied to treat more than 1,000 patients in one eye and the other eye serving as the control. It was found that laser therapy had neither beneficial nor harmful effect for these patients, if any. The laser's energy can disrupt Bruch's membrane which loses the ability to prevent the growth of CNV under the retina, thus converting dry AMD to wet AMD (CAPT, 2006). On the other hand, laser therapy seems to delay the development of CNV by 6 months in studies, including patients with unilateral advanced AMD (Owen et al., 2006; Friker et al., 2006). In conclusion, presence and/or elimination of drusen with laser treatment did not affect the visual acuity, indicating that dry AMD cannot be treated with physical means at the present time.

4. Treatment of dry AMD with pharmacological agents

Most research and developments of dry AMD are focused on the prevention of metabolic wastes production with limited success. This is mainly because the production of metabolic wastes comes from numerous sources, including oxidation, aging, complement components, cytokines, inflammations, PEDF, VEGF, ECM turnover and the like. Thus, a complete inhibition of one branch of all pathogens can suppress the progression of dry AMD at only around 20% at best, which falls to the borderline efficacy only. Besides, metabolic wastes are normal products of physiological procedures of the body and complete inhibition of normal metabolism could result in other various pathological side effects. Further, visual acuity does NOT change significantly during the progression of dry AMD, thus, selection of proper end points to evaluate drug efficacy in the clinical trials are very difficult if not impossible.

4.1 Choroidal blood flow facilitators

Although fruitful progress has been made in the treatment of wet AMD, the treatment of dry AMD is still in the desert stage. There is no single drug available in the whole world for the treatment of dry AMD. Since 90% of AMD patient population is in the dry stage, there is active research carried out at the present time at different stages of research and development (Zou and Chiou, 2005).

A novel idea to solve the problem has been developed recently by Chiou in Texas A&M Health Science Center. He based on the risk factor of dry AMD as a reduction of choroidal blood flow (Friedman, 2000; Grundwald et al., 2003; 2005; Xu et al., 2010; Figueroa et al., 2006; Metelitsina et al., 2006), which lead to the accumulation of all waste products regardless of where they came from, including aging, oxidation, inflammation, complement components, VEGF, PEDF, cytokines and the like. Thus, instead of solving problems individually by using inhibiting/blocking agents of aging, oxidation, inflammation, complement components, VEGF, PEDF and cytokines, all waste products will be eliminated by improved choroidal circulation. Further, nutrients will be replenished to BRM, RPE, and photoreceptors via improved choroidal circulation in macula to improve the vision.

In order to prove the concept that the disease severity of dry AMD is inversely proportional to choroidal blood flow (CBF), drugs that can facilitate CBF were identified with ocular hypertensive rabbits. The CBF was measured precisely with colored microsphere method. Drugs which can increase CBF were then administered to AMD rat models, including NaIO_3 -induced and laser-induced AMD models. The former was used to prevent/reverse degeneration of RPE by drugs, representing the treatments of dry AMD. The latter was used to show the prevention of conversion of dry to wet AMD after the Bruch's membrane was broken down by laser treatment. It was interesting to note that those agents which can facilitate CBF can prevent/reverse AMD induced by NaIO_3 and/or laser beam. Those agents which did not improve CBF showed no effect on the AMD development. All drugs were administered with eye drops without preservatives in the ophthalmic solution. Phase I clinical trials and proof of the concept of MC1101 (MacuClear) in human patients had been carried out with encouraging results showing no major side effects observed and the drug can reach the back of the eye to facilitate CBF. If preclinical animal data are good indicators, it would most likely show drug efficacy in preventing/reversing the progression of dry AMD with these agents.

Numerous agents that can increase choroidal blood flow in rabbit eyes have been tested in dry AMD animal models. Among them, some were found to be quite efficacious in inhibiting the development of dry AMD. They include, but are not limited to, hydralazine (Jiang and Chiou, 2008; Jiang et al., 2008; Cheng and Chiou, 2008), tetramethylpyrazine (Zou et al., 2007; Shen et al., 2010a), flavone (Zhuang et al., 2010a; 2010b), naringenin (Lin and Chiou, 2008; Shen et al., 2010b), apigenin (Zou and Chiou, 2006), quercetin (Zhuang et al., 2011), guanabenz (Shen et al., 2011), interleukin-1 blockers (Zou et al., 2006) and D-timolol (Xu et al., 2005).

Reduction in choroidal blood flow causes deposition of extracellular proteins, lipids and metabolic wastes in the form of basal deposits within BRM and drusen in between BRM and RPE. The progressive deposition of lipid in BRM results in the degeneration of elastin and collagen, and ultimately calcification. The combination of elevated choriocapillary pressure, expansion of VEGF and break in the calcified BRM causes development of CNV and wet AMD. Vasoactive agents, which can facilitate choroidal blood flow are believed to prevent the progression of dry AMD and is the major focus of the research at the present time (Zou and Chiou, 2005).

4.2 Anti-oxidants

Antioxidants are the agents most extensively studied. Lutein and zeaxanthin are two major carotenoids in the human macula and retina. They are deposited at an up to 5-fold higher

content in the macular region as compared to the peripheral retina. Because of antioxidant properties of carotenoids, lutein and zeaxanthin are considered to be able to protect and/or delay the progression of dry AMD (Mozaffarieh et al., 2003).

Age-related Eye Disease Study (AREDS, 2001) reported that food supplements that contain carotenoids, anti-oxidants vitamins A, C, and E, plus minerals, such as zinc, showed a 25% decrease in the rate of progression to aggressive AMD among high risk patients. The findings of Lutein Anti-oxidant Supplementation Trial (LAST) (Richer et al., 2004) also support a possible therapeutic role of Lutein in AMD treatment. However, the critical evidence of therapeutic efficacy has not been established.

In order to improve the initial success, AREDS-2 has been initiated with a new formulation for a six-year, multicenter, randomized trial. The new formula contains higher doses of lutein and zeaxanthin and/or Omega-3 fatty acids known as DHA and EPA. It also lowers the zinc from 80mg to 25mg and deletes β -carotene. Four thousand participants at ages 50 to 85 have been enrolled and the trial will last six years. The results should come out sometime in the near future (Karmel, 2011).

All agents, including hydralazine, tetramethylpyrazine, flavone, naringenin, apigenin, quercetin and guanabenz (Cheng and Chiou, 2008; Zou et al., 2006; 2007; Shen et al., 2010a; 2010b; 2011; Zhuang et al., 2010a; 2010b; 2011; Lin and Chiou, 2008) presented in section 4.1 as choroidal blood flow facilitators produce potent anti-oxidating actions as well. They can antagonize oxidation induced injuries on human RPE cells induced by H_2O_2 , $NaIO_3$, t-BHP, and the like.

OT-551 is a piperidine derivative converted by ocular esterases to the actual metabolite, TEMPOL-H (TP-H) which serves as a potent free radical scavenger. It is a small molecule which can be administered as local eye drops (Tanito et al., 2007), OT-551 also possesses anti-inflammatory and antiangiogenic properties. OT-551 users are being investigated for the therapy of geographic atrophy in AMD. Unfortunately, the phase II trials failed to produce efficacy in preventing the enlargement rate of GA in AMD (OT-551, 2007).

4.3 Anti-inflammatory agents

Genetic association studies have shown that inflammation appears to be related to AMD (Patel and Chan, 2008). Further, complement factor H (CFH) was associated with an increased risk of developing AMD (Edwards et al., 2005; Hageman et al., 2005; Haines et al., 2005; Klein et al., 2005). Later studies linked AMD to even more complicated complement system. These studies indicated that inhibition of complement activation would be a reasonable strategy for the treatment of AMD. However, after a life-long damage on complement system, such a strategy might have little benefit on the AMD progression later in life (Arons, 2009).

Regardless, active investigation was carried out and numerous complement inhibitors were derived for clinical trials. Among them, POT-4 (Potentia Pharmaceuticals) was developed as a C3 inhibitor for wet AMD. Eculizumab (Soliris, Alexion Pharmaceuticals) was developed as a C5 antibody for the treatment of dry AMD. Since eculizumab is a monoclonal antibody, it has to be administered via intravenous infusion to patients with GA or high risk drusen. ARC-1905 (Ophthotech) is an anti-C5 aptamer administrated via intravitreal injection for

dry and wet AMD. Another drug, anti-Complement Factor D antibody Fab (FCFD4514S) (Genetech/Roche) is in a phase II trial.

For preclinical R&D, JPE (Jerin: Ophthalmic) is developed with peptidomimetic molecular antagonist against C5a receptor. Interleukin-1 blockers (MacuClear) are also under investigation as eye drops for treatment of dry AMD.

For non-specific immune suppression for the treatment of dry AMD, subcutaneous glatiramer acetate (Copaxane, Teva Pharmaceuticals), intravitreal fluocinolone acetonide (Iluvein implant, Alimera Science) and subcutaneous sirolimus (Rapamycin, MacuSight) are under investigation (Arons, 2009).

4.4 Miscellaneous agents

Fenretinide (ST-602, Sirion Therapeutics) is an oral compound developed to slow down the progression of GA in AMD. It aims to reduce the accumulation of toxins which are end products of retinol (Vitamin A) related biochemical process. These toxins are accumulated in the form of lipofuscin when the elimination process is reduced such as in dry AMD and Stargardt's disease (Radu et al., 2005; Study of Fenretinide, 2007). Instead of slowing down the toxins productions, MC1101 (MacuClear) aims to facilitate the excretion of toxins by increasing the choroidal circulation (See Section 4.1).

Ciliary neurotrophic factors (CNTF, Neurotech Pharmaceuticals) have been developed to retard the progression of neurodegenerative diseases (A Phase II study, 2007). CNTF has been shown to reduce motor neuron loss in mouse and ciliary ganglion neurons in chick eyes. CNTF is delivered by genetically engineered cells that are housed in a patented delivery system called Encapsulated Cell Technology (ECT). They are surgically implanted through the pars plana into the vitreous and anchored to the sclera. It is designed to bypass the blood retinal barrier to reach the back of the eye (NTC201) (ECT Technology, 2007).

Drugs which can change the construction of extra cellular matrix (ECM) or change the balance of matrix metalloproteinases (MMPs) and tissue inhibitors of metalloproteinases (TIMPs) may have an effect on angiogenesis process as well (Berglin et al., 2003). These drugs are called ECM modifiers and are still in the experimental stage of development.

5. Clinical protocols for anti-dry AMD drug studies

There are at least two major obstacles which hinder the development of drugs for the treatment of dry AMD. First, the long time period that is required to observe progression of the disease (Csaky et al., 2008; AREDSRG, 2001), which discourages researchers as well as investors to get involved. Second, the clinical endpoints to show drug efficacy other than visual acuity are difficult to be determined. There are several promising methods under consideration and if approved by FDA, they can facilitate the drug evaluation and development in the future (FDA, 2008a; 2008b).

Dry AMD is an unique chronic disease whose visual acuity does not change much during the early stage of the progression of the disease. Its change does not parallel to the worsening of visual acuity until the late stage of the disease. Consequently, the efficacy of drug action to treat dry AMD is impossible to be assessed based on the changes in visual

acuity. This is very different from the assessment of wet AMD drug actions, as the progression of wet AMD is parallel to the loss of visual acuity. Prolongation of dark adaptation is closely correlated to the severity of AMD (Jackson and Edward, 2008; Owsley et al., 2006; Jackson et al., 2002). Dark adaptation is strongly impacted in AMD long before there is any significant loss of visual acuity (Jackson and Edward, 2008). Thus, measurement of dark adaptation is one of the workable ways to measure the drug efficacy for the treatment of dry AMD. The commercially available prototype dark adaptometer (AdaptRx, Apeliotus Technologies Inc, Atlanta, GA) is now available.

It has been found that rod photoreceptor degeneration precedes cone degeneration in early AMD (Owsley et al., 2001; Curcio et al., 1996; Steinmetz et al., 1993; Chen et al., 2004; Jackson et al., 2004) and rod dysfunction may contribute to the later degeneration of cones because of their inter-dependence (Mohand-Said et al., 2001; 1998; Hicks and Sahel, 1999). A ten-item night vision questionnaire (NVQ-10) has been developed by Ying et al (2008). Analysis of NVQ-10 implies that the wet AMD and GA may derive from two different disease physiological processes. Because of the ease of assessment, as compared to dark adaptation measurement with machine, assessing night vision symptoms may be useful in identifying patients with early or intermediate AMD at relatively high risk of progression (Ying et al., 2008).

Accumulation of the number and size of drusen is another parameter used to measure the progression of dry AMD. Since the change in drusen deposits is very slow and difficult to note subjectively, Matched Flicker (EyelC.com) has been developed to record the changes objectively and precisely. Basically, the precise high-tech use in the space science to record minute changes occurred in the sky at any time period has been applied to measure the changes of drusen occurred in the fundus of the same eye. Basically, two retinal images of the same eye from virtually any source can be loaded into Matched Flicker and the changes can be brought to life and observed as easy-to-detect motion. Since very minute change in drusen accumulation can be detected with the machine precisely and objectively, it allows to shorten the time to detect changes in drusen deposits as compared to inaccurate subjective observation with naked eyes in the past. As a result, clinical study of drug efficacy in slowing down the rate of drusen accumulation can be accomplished easily.

Optical Coherence Tomography (OCT) is an advanced technology that allows researchers to measure the increase in volume and area of drusen over time (Yehoshua et al., 2009; OCT, 2011). Information of detailed theory and selected application is available (OCT, 2011) and Spectral Domain OCT (SD-OCT) is particularly useful for monitoring drusen changes in volume and area which can be related to the progression of dry AMD (Yehoshua et al., 2009). This can be used as a novel clinical trial end point for investigation therapies of dry AMD.

RPE are critical cells to maintain healthy function of Bruch's membrane and photoreceptors. The degeneration of RPE can be detected by measurement of the c-wave of ERG (Jiang and Chiou, 2007; Peachey et al., 2002). The suppression of c-wave is proportionally related to the deterioration of RPE in dry AMD.

A useful tool for determining patients' vision related function has been developed (Kokame, 2008) to allow the improved sensitivity for detection of even a slight change in visual activity in the stage of early and intermediate stages of dry AMD. The device is called NEI

VFQ-25 (National Eye Institute Visual Function Questionnaire-25) which is responsive to changes in patients' visual activity and is able to differentiate between patients who are responders and those who are not.

Although NEI VFQ-25 measures patients' subjective evaluation of their visual function and how impairment in vision affects their lives, it is reliable, valid and responsive as compared to standard measure of vision used in clinical trials such as BCVA using standardized ETDRS (Early Treatment of diabetic retinopathy study) vision protocols (Kokame, 2008). The NEI VFQ-25 showed a large separation between the groups with improved BCVA (gained >15 letters) stable BCVA (gain or lost 15 < letters) and worse BCVA (lost \geq 15 letters). It may also provide a more broad assessment of the visual function on life style and vision dependent activities than BCVA alone. On average, the 25-letter or better improvement in BCVA corresponds to an increase in the NEI VFQ-25 score of 8.2 in the MARINA Trial (Minimally Classic/Occult Trial of Anti-VEGF Antibody Ranibizumab in the Treatment of Neovascular AMD).

Although not all dry AMD would develop into wet AMD, 10-15% of dry AMD would eventually be converted into wet AMD. Thus, prevention of dry AMD to be converted into wet AMD is also a measurement of drug action to suppress the progression of dry to wet AMD. Since only 10-15% of dry AMD would be converted into wet AMD, a large number of patients are needed for this study to see the difference in drug treatment. In short, ideal clinical endpoints are urgently needed for the measurement of the efficacy of new drugs for the treatment of dry AMD. If approved by FDA, it can shorten the measurement of drug efficacy to save time, effort and funds.

6. Conclusions

Great deals of efforts have been poured in, in order to elucidate the etiology and pathogenesis of the dreadful disease, age-related macular degeneration, with a hope to develop an effective means of treatment and/or prevention of the disease. Although the etiology and pathogenesis have been largely revealed, its treatment with physical means has since failed and receded to the second line of treatment options. Fortunately, pharmacological agents are now available for the treatment of wet AMD. However, wet AMD is the very late stage of AMD and is too late to save the eyesight for normal daily function. Besides, wet AMD consists of only 10-15% of total AMD patients. Thus, developing efficacious drugs for dry AMD is most urgently needed. The key stage of the treatment of AMD is obviously at the early stage or dry phase of the disease. There are numerous groups of scientists working very hard to develop an efficacious drug yet none have succeeded as of yet.

The major obstacles for the development of ideal drugs for dry AMD are at least two folds. First, AMD is a long term chronic disease with little worsening of visual acuity until the very late stage of the disease. Thus, the clinical end point to measure improvement of visual acuity by drugs at early or even middle stages of the disease is very difficult. The agents for improving the choroidal circulation are under investigation. Alternative end points to measure visual functions have been developed including the measurement of dark adaptation for rod cell functions, the determination of c-wave of ERG for RPE cell functions and macular stress test for cone cell function in the macula. Secondly, the pathogenesis of

the disease is closely related to numerous normal physiological functions, such as oxidation, aging, VEGF and PEDF expression, extracellular matrix modifications and the like. Thus, complete suppression of these normal functions is not only unrealistic and even detrimental to induce further devastating side effects. Since these factors are numerous, suppression of one of them can improve the disease only partially to bring it to the borderline, marginal improvement of the disease. The novel idea to solve the problem at the root of the disease is to improve the choroidal circulation which can eliminate all normal metabolic wastes from photoreceptors, Bruch's membrane and RPE cells and to furnish nutrients to these critical tissues. This way, the macular function will go back to normal and the AMD would be reversed or suppressed without further development.

7. References

- A phase II study of implants of encapsulated human NTC-201 cells releasing ciliary neurotrophic factor (CNTF) in participants with visual activity impairment associated with atrophic macular degeneration. ClinicalTrials.gov Web site. <http://www.clinicaltrials.gov/ct/show/NCT00277134?order=2>. Accessed on October 3, 2007.
- AREDSRG (Age-related Eye Disease Study Research Group). A randomized, placebo-controlled, clinical trial of high-dose supplementation with vitamins C and E, beta carotene, and zinc for age-related macular degeneration and vision loss. *Archives of Ophthalmology*, 2001; 119:1417-1436
- Algvere, P.V., Seregard, S. Age-related maculopathy: pathogenetic features and new treatment modalities. *Acta Ophthalmol Scand*, 2002; 80:136-143
- Ambati, J., Ambati, B.K., Yoo, S.H., Ianchulev, S., Adamis, A.P. Age-related macular degeneration: etiology, pathogenesis, and therapeutic strategies. *Surv Ophthalmol*, 2003; 48:257-293
- AREDS report No. 8. A randomized, placebo-controlled, clinical trial of high-dose supplementation with vitamins C and E, beta carotene, and zinc for age-related macular degeneration and vision loss. *Arch Ophthalmol*, 2001; 119:1417-1436
- Arons, I. AMD update 6: An overview of new treatments for dry AMD. <http://www.irvaronsjournal.blogspot.com/2009/12>
- Berglin, L., Sarman, S., van der Ploeg, I., Steen, B., Ming, Y., Itohara, S., Seregard, S., Kvanta, A. Reduced choroidal neovascular membrane formation in matrix metalloproteinase-2-deficient mice [J]. *Invest Ophthalmol Vis Sci*, 2003; 44:403-408
- Bora, P.S., Kaliappan, S., Xu, Q., Kumar, S., Wang, Y., Kaplan, H.J., Bora, N.S. Alcohol linked to enhanced angiogenesis in rat model of choroidal neovascularization. *Fed Eur Biochem Soc J*, 2006; 273: 1403-1414
- Campochiaro, P.A., Nguyen QD, Shah SM, Klein ML, Holz E, Frank RN, Saperstein DA, Gupta A, Stout JT, Macko J, DiBartolomeo R and Wei LL. Adenoviral vector-delivered pigment epithelium-deprived factor for neovascular age-related macular degeneration: results of phase I clinical trial. *Hum. Gene Ther.* 2006. 17:167-176
- CAPT (Complications of Age-Related Macular Degeneration Prevention Trial Research Group) Laser treatment in patients with bilateral large drusen: the complications of age-related macular degeneration prevention trial. *Ophthalmology*. 2006;113:1974-1986.

- Cheng, Y.W., Chiou, G.C.Y. Antioxidant effect of hydralazine on retinal pigment epithelial cells and its potential use in the therapy of age-related macular degeneration. *International J. Ophthalmol.* 2008; 8:1059-1064
- Congdon, N., O'Colmain, B., Klaver, C.C., Klein, R., Munoz, B., Friedman, D.S., Kempen, J., Taylor, H.R., Mitchell, P. Causes and prevalence of visual impairment among adults in the United States. *Arch Ophthalmol* 2004; 122 (4) :477-485
- Csaky, K.G., Richman, E.A., Ferris, F.L. 3rd. Report from the NEI/FDA Ophthalmic Clinical Trial Design and Endpoints Symposium. *Invest Ophthalmol Vis Sci.* Feb 2008; 49(2):479-489
- Danis, R.P., Ciulla, T.A., Pratt, L.M. Intravitreal triamcinolone acetonide in exudative age-related macular degeneration [J]. *Retina*, 2000;20:244-250
- ECT Technology. Neurotech Website. http://www.neurotechusa.com/product_tech.asp. Accessed on October 3, 2007
- Edwards AO, Ritter R, 3rd, Abel KJ, et al. Complement factor H polymorphism and age-related macular degeneration. *Science*. 2005;308:421-424
- Espinosa- Heidmann, D.G., Sall, J., Hernandez, E.P., Cousins, S.W. Basal Laminar deposit formation in APO B100 transgenic Mice: Complex interactions between dietary fat, blue light, and vitamin E. *Invest Ophthalmol Vis Sci*, 2004; 45(1) :260-266
- Evans, J.R. Risk factors for age-related macular degeneration. *Prog Retin Eye Res*, 2001; 20:227-253
- Figueroa M, Schocket LS, DuPont J, Metelitsina TI, and Grunwald JE. Long-term effect of laser treatment for dry age-related macular degeneration on choroidal hemodynamics. *Am J Ophthalmol*. 2006, 141:863-867
- Food and Drug Administration. Critical Path Initiative. <http://www.fda.gov/oc/initiatives/criticalpath/>. Accessed August 1, 2008a
- Food and Drug Administration. Critical Path Opportunity Report. http://www.fda.gov/oc/initiatives/criticalpath/reports/opp_report.pdf. Accessed August 1, 2008b
- Friberg TR, Musch DC, Lim JJ, et al. Prophylactic treatment of age-related macular degeneration report number 1: 810-nanometer laser to eyes with drusen. Unilaterally eligible patients. *Ophthalmology*. 2006;113:612-622.
- Friedman, D.S., O'Colmain, B.J., Munoz, B., Tomany, S.C., McCarty, C., de Jong P.T., Nemesure, B., Mitchell, P., Kempen, J. Prevalence of age-related macular degeneration in the United States. *Arch Ophthalmol* 2004; 122 (4):564-572
- Friedman, E. The role of the atherosclerotic process in the pathogenesis of age-related macular degeneration [J]. *Am J Ophthalmol*, 2000 ;130:658-663
- Green, W.R., Enger, C. Age-related macular degeneration histopathologic studies. The 1992 Lorenz E. Zimmerman Lecture. *Ophthalmology*, 1993; 100:1519-1535
- Grunwald, J.E., Metelitsina, T.I., DuPont, J.C., Ying, G.S., Maguire, M.G. Reduced foveolar choroidal blood flow in eyes with increasing AMD severity. *Inv Ophthalmol Vis Sci* 2005; 46: 1033-1038
- Grunwald, J.E., Metelitsina, T.I., Niknam, R.M. , DuPont, J.C. Foveolar choroidal blood flow in patients with AMD that have CNV in the fellow eye *Inv Ophthalmol Vis Sci*. 2003. 44: E-Abstract 4989

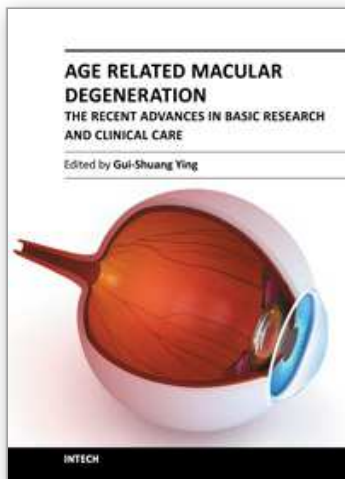
- Hageman GS, Anderson DH, Johnson LV, et al. A common haplotype in the complement regulatory gene factor H (HF1/CFH) predisposes individuals to age-related macular degeneration. *Proc Natl Acad Sci USA*. 2005;102:7227-7232.
- Haines JL, Hauser, MA, Schmidt S, et al. Complement factor H variant increases the risk of age-related macular degeneration. *Science*. 2005;308:419-421.
- Hope, G.M., Dawson, W.W., Engel, H.M., Ulshafer, R.J., Kessler, M.J., Sherwood, M.B. A primate model for age related macular drusen. *Br J Ophthalmol*, 1992; 76 (1):11-16
- Hutchison, W.T. Symmetrical central choroidretinal disease occurring in senile persons, R. Lond. Ophthal. Hosp. Rep. 1875; 8: 231-244
- Imamura, Y., Noda, S., Hashizume, K., Shinoda, K., Yamaguchi, M., Uchiyama, S., Shimizu, T., Mizushima, Y., Shirasawa, T., Tsubota, K. Drusen, choroidal neovascularization, and retinal pigment epithelium dysfunction in SOD1-deficient Mice: A model of age-related macular degeneration. *Proc Natl Acad Sci*, 2006; 103 (30):11282-11287
- Jackson, G.R., Edwards, J.G. A short-duration dark adaptation protocol for the assessment of age-related maculopathy. *J Occul Biol Dis Inform*. 2008. DOI 10. 1007/s12177-008-9002-6
- Jackson G.R., Owsley, C., Curio, C.A. Photoreceptor degeneration and dysfunction in aging and age-related maculopathy. *Ageing Research Reviews*. 2002; 1:381-386
- Jiang, W., Chiou, G.C.Y. Effects of hydralazine on ocular blood flow and laser-induced choroidal neovascularization in vivo and endothelial cells in vitro. *International J. Ophthalmol*. 2008;8: 2359-2363
- Jiang, W., Chiou, G.C.Y. The development of AMD experimental models. *International J. Ophthalmol*. 2007; 7:585-589
- Jiang, W., Zhang, W.Y., Chiou, G.C.Y. Effects of hydralazine on sodium iodate-induced rat retinal pigment epithelium degeneration. *International J. Ophthalmol*, 2008; 8:1504-1510
- Joussen, A.M. Cell transplantation in age related macular degeneration: current concepts and future hopes. *Graefes Arch Clin Exp Ophthalmol*, 2004; 242: 1-2
- Karan, G., Lillo, C., Yang, Z., Cameron, D.J., Locke, K.G., Zhao, Y. Thirumalaichary S, Li C, Birch DG, Vollmer- Snarr HR Williams DS, Zhang K. Lipofuscin accumulation, abnormal electrophysiology, and photoreceptor degeneration in mutant ELOVL4 transgenic mice: A model for macular degeneration. *Proc Natl Acad Sci*, 2005; 102(11) :4164-4169
- Karmel M. The other AMD; Dry but drawing research attention *Eye Net. Amer. Academy Ophthalmol*. 2011. www.aao.org/publications/eyenet/200702/retina.cfm.
- Kaven, C., Spraul, C.W., Zavazava, N., Lang, G.K., Lang, G.E.. Thalidomide and prednisolone inhibit growth factor-induced human retinal pigment epithelium cell proliferation *in vitro*]]. *Ophthalmologica* , 2001;215:284-289
- Klein, R. The five-year incidence and progression of age-related maculopathy: The Beaver Dam Eye Study. *Ophthalmology* 1997; 104:7-21
- Klein, R., Klein, B.E., Linton, K.L. Prevalence of age-related maculopathy. The Beaver Dam Eye Study. *Ophthalmology* 1992; 99:933-943
- Klein RJ, Zeiss C, Chew EY, et al. Complement factor H polymorphism in age-related macular degeneration. *Science*. 2005;308:385-389
- Kliffen, M., vd Schaft, T.L., Mooy, C.M., d Jong, P.T.V.M. Morphologic changes in age-related maculopathy. *Microsc Res Tech*, 1997; 36:106-122

- Kohri, T., Moriwaki, M., Nakajima, M., Tabuchi, H., Shiraki, K. Reduction of experimental laser-induced choroidal neovascularization by orally administered BPHA, a selective metalloproteinase inhibitor [J]. *Graefes Arch Clin Exp Ophthalmol*, 2003;241(11):943-952
- Kokame, G.T. NEI VFG-25, useful tool for determining patients vision-related function. *Retina Today* Nov/ Dec. 2008:27-29
- Leibowitz, H.M., Krueger, D.A., Maunders, R.A. An ophthalmological study of cataract, glaucoma, diabetic retinopathy, macular degeneration and visual acuity in a general population of 2631 adults 1973-1975. *Surv Ophthalmol* 1980; 24 (Suppl):335-610
- Li, Z., Clarke, M.P., Barker, M.D., McKie, N. TIMP3 mutation in Sorsby's fundus dystrophy: molecular insights. *Expert Rev Mol Med*, 2005; 31;7(24): 1-15
- Lin, B.Q., Chiou, G.C.Y. Antioxidant activity of naringenin on various oxidants induced damages in ARPE-19 cells and HUVEC. *International J. Ophthalmol*, 2008; 10:1963-1967
- Marin-Castaño, M.E., Striker, G.E., Alcazar, O., Catanuto, P., Espinosa-Heidmann, D.G., Cousins, S.W. Repetitive nonlethal oxidant injury to retinal pigment epithelium decreased extracellular matrix turnover in vitro and induced sub-RPE deposits in vivo. *Invest Ophthalmol Vis Sci*, 2006; 47(9):4098-4112
- Metelitsina TI, Grunwald JE, DuPont JC, Ying GS. Effect of systemic hypertension on foveolar choroidal blood flow in age-related macular degeneration. *Br. J. Ophthalmol*. 2006;90:342-346
- Mitchell, P., Smith, W., Attebo, K., Wang, J.J. Prevalence of age-related maculopathy in Australia. The Blue Mountains Eye Study. *Ophthalmology* 1995; 102:1450-1460
- Mozaffarieh, M., Sacu, S., Wedrich, A. The role of the carotenoids, lutein and zeaxanthin, in protecting against age-related macular degeneration: a review based on controversial evidence [J]. *Nutr J*, 2003; 2:20
- Nowak, J.Z. Age-related macular degeneration (AMD): pathogenesis and therapy. *Pharmacol Rep* 2006; 58: 353-363
- OCT, Optical coherence tomography.
en.wikipedia.org/wiki/optical_coherence_tomography , 2001
- OT-551 antioxidant eye drops to treat geographic atrophy in age-related macular degeneration. ClinicalTrials.gov Web site.
<http://www.clinicaltrials.gov/ct/show/NCT00306488?order=1>.
Accessed on October 3, 2007.
- Owen SL, Bunce C, Brannon AJ, et al. Prophylactic laser treatment hastens choroidal neovascularization in unilateral age-related maculopathy: final results of the drusen laser study. *Am J Ophthalmol*. 2006;141:276-281.
- Owsley, C., McGwin, G., Jackson, G.R., et al. Effect of short-term, high-dose retinol on dark adaptation in aging and early age-related maculopathy. *Invest Ophthalmol Vis Sci*. Apr 2006; 47(4):1310-1318
- Patel M and Chan C.C. Immunological aspects of age related macular degeneration. *Semi Immunopathol*. 2008;30:97-110
- Peachey, NS., Staton, J.B. And Marmorstein, AD. Non-invasive recording and response characteristics of the rat dC-ERG. *Vis Neurosci*. 2002;19:693-701.

- Radu RA, Han Y, Bui TV, et al. Reductions in serum vitamin A arrest accumulation of toxic retinal fluorophores: a potential therapy for treatment of lipofuscin based retinal diseases. *Invest Ophthalmol. Vis. Sci.* 2005;46:4393-4401
- Rasmussen, H., Chu, K.W., Campochiaro, P., Gehlbach, P.L., Haller, J.A., Handa, J.T., Nguyen, Q.D., Sung, J.U. Clinical protocol. An open-label, phase I, single administration, dose-escalation study of ADGVPEDF.11D (ADPEDF) in neovascular age-related macular degeneration (AMD) [J]. *Hum Gene Ther*, 2001;12(16):2029-2032
- Raz-Prag, D., Ayyagari, R., Fariss, R.N., Mandal, M.N.A, Vasireddy, V., Majchrzak, S., Webber, A.L., Bush, R.A., Salem, N. Jr, Petrukhin, K., Sieving, P.A. Haploinsufficiency is not the key mechanism of pathogenesis in a heterozygous Elov14 knockout mouse model of STGD3 disease. *Invest Ophthalmol Vis Sci*, 2006; 47(8): 3603-3611
- Rechtman, E., Danis, R.P., Pratt, L.M., Harris, A. Intravitreal triamcinolone with photodynamic therapy for subfoveal choroidal neovascularization in age-related macular degeneration [J]. *Br J Ophthalmol*, 2004; 88:344-347
- Richer, S., Stiles, W., Statkute, L., Pulido, J., Frankowski, J., Rudy, D., Pei, K., Tsipursky, M., Nyland, J. Double-masked, placebo-controlled, randomized trial of lutein and antioxidant supplementation in the intervention of atrophic age-related macular degeneration: the Veterans LAST Study (Lutein Antioxidant Supplementation Trial) [J]. *Optometry*, 2004; 75(4):216-230
- Rudolf, M., Winkler, B., Aherrahou, Z., Doebling, L.C., Kaczmarek, P., Schmidt-Erfurth, U. Increased expression of vascular endothelial growth factor associated with accumulation of lipids in Bruch's membrane of LDL receptor knockout mice. *Br J Ophthalmol*, 2005; 89:1627-1630
- Schachat, AP Safety issues related to the long-term use of VEGF inhibitors DSN SuperSite June, 2007
- Shen, Y., Zhang W.Y., Chiou G.C.Y. Effects of naringenin on NaIO₃-induced retinal pigment epithelium degeneration and laser-induced choroidal neovascularization in rats. *International J. Ophthalmol*, 2010a; 10:1-4
- Shen, Y., Zhuang, P., Zhang, W.Y., Chiou, G.C.Y. Effects of guanabenz on rat AMD models and rabbit choroidal blood flow. *The Open Ophthalmol. J.*, 2011; 5:27-31
- Shen, Y., Zhuang, P., Zhang, W.Y., Chiou, G.C.Y. Effects of tetramethylpyrazine on RPE degeneration, choroidal blood flow and oxidative stress of RPE cells. *International J. Ophthalmol*, 2010b; 10:1843-1847
- Study of Fenretinide in the treatment of geographic atrophy associated with age-related macular degeneration. ClinicalTrials.gov Website. <http://www.clinicaltrials.gov/ct/show/NCT00429936?order=1>. Accessed on October 3, 2007.
- Suñer, I.J., Espinosa-Heidmann, D.G., Marin-Castaño, M.E., Hernandez, E.P., Pereira-Simon, S., Cousins, S.W. Nicotine increases size and severity of experimental choroidal neovascularization. *Invest Ophthalmol Vis Sci*, 2004;45 (1) :311-317
- Tanito M, Li F, Elliott WH, et al. Protective effect of TEMPOL derivatives against light-induced retinal damage in rats. *Invest Ophthalmol. Vis. Sci.* 2007;48:1900-1905
- Wang, T.Y, Loon, S-C, Saw, S-M. The epidemiology of age related eye diseases in Asia *Brit J. Ophthalmol*, 2006; 90:506-511

- Xu, W, Grunwald JE, Metelitsina TI, DuPont JC, Ying GS, Martin ER, Dunaief JL and Brucker AJ. Association of risk factors for choroidal neovascularization in age-related macular degeneration with decreased foveolar choroidal circulation. *Amer J. Ophthalmol.* 2010, 150:40-47
- Xu, X.R. Zhou, Y.H., Chiou, G.C.Y. The effect of D-timolol and L-timolol on rat experimental choroidal neovascularization (CNV) in vivo and endothelial cells culture in vitro. *International J. Ophthalmol.*, 2005; 5:831-835
- Yehoshua Z, Wang F, Rosenfield PJ, Penha FM, Feuer WJ and Gregori, G. Natural history of drusen morphology in age-related macular degeneration using spectral domain optical coherence tomography. www.ophsource.org/periodicals/article 2009.
- Zhou, J.L., Gao, X.Q., Cai, B., Sparrow, J.R. Indirect antioxidant protection against photooxidative processes initiated in retinal pigment epithelial cells by a lipofuscin pigment. *Rejuvenation Res*, 2006; 9(2):256-263
- Zhuang, P., Shen, Y., Chiou, G.C.Y. Effects of flavone on ocular blood flow and formation of choroidal neovascularization. *International J. Ophthalmol*, 2010a; 10:1455-58
- Zhuang, P., Shen, Y., and Chiou, G.C.Y. Effects of flavone on oxidation-induced injury of retinal pigment epithelium cells. *International J. Ophthalmol*, 2010b; 10:1641-1644
- Zhuang, P., Shen, Y., Lin, B.Q., Zhang, W.Y. and Chiou, G.C.Y. Effect of quercetin on formation of choroidal neovascularization (CNV) in age-related macular degeneration (AMD) *Eye Sci.* 2011;26:23-29
- Zou, Y.H., Chiou, G.C.Y. Apigenin inhibits laser-induced choroidal neovascularization and regulates endothelial cell function. *J. Ocular Pharmacol. Therap.* 2006; 22:425-430
- Zou, Y.H., Chiou, G.C.Y. Pharmacological therapy in AMD. *International J Ophthalmol*, 2005; 5:8-18
- Zou, Y.H., Jiang, W., Chiou, G.C.Y. Affect of tetramethylpyrazine on rat experimental choroidal neovascularization in vivo and endothelial cell culture in vitro. *Current Eye Res*, 2007; 32:71-75
- Zou, Y.H., Xu X.R., Chiou, G.C.Y. Effort of interleukin-1 blockers, CK112 and CK116 on rat experimental choroidal neovascularization (CNV) in vivo and endothelial cells culture in vitro. *J. Ocular Pharmacol. Therap.* 2006; 22:19-25

IntechOpen



Age Related Macular Degeneration - The Recent Advances in Basic Research and Clinical Care

Edited by Dr. Gui-Shuang Ying

ISBN 978-953-307-864-9

Hard cover, 300 pages

Publisher InTech

Published online 20, January, 2012

Published in print edition January, 2012

Age-related Macular Degeneration (AMD) is the leading cause of vision loss and blindness in the developed countries. In the past decade, great progress has been made in understanding the pathobiology and genetics of this blinding disease, as well as in finding new therapies for its treatment. These include the discovery of several genes that are associated with the risk of AMD, new anti-VEGF treatments for wet AMD and new imaging techniques to diagnose and monitor the AMD. All chapters in this book were contributed by outstanding research scientists and clinicians in the area of AMD. I hope this timely book will provide the basic scientists and clinicians with an opportunity to learn about the recent advances in the field of AMD.

How to reference

In order to correctly reference this scholarly work, feel free to copy and paste the following:

George C. Y. Chiou (2012). Treatments of Dry AMD, Age Related Macular Degeneration - The Recent Advances in Basic Research and Clinical Care, Dr. Gui-Shuang Ying (Ed.), ISBN: 978-953-307-864-9, InTech, Available from: <http://www.intechopen.com/books/age-related-macular-degeneration-the-recent-advances-in-basic-research-and-clinical-care/novel-drug-therapy-of-dry-age-related-macular-degeneration>

INTECH
open science | open minds

InTech Europe

University Campus STeP Ri
Slavka Krautzeka 83/A
51000 Rijeka, Croatia
Phone: +385 (51) 770 447
Fax: +385 (51) 686 166
www.intechopen.com

InTech China

Unit 405, Office Block, Hotel Equatorial Shanghai
No.65, Yan An Road (West), Shanghai, 200040, China
中国上海市延安西路65号上海国际贵都大饭店办公楼405单元
Phone: +86-21-62489820
Fax: +86-21-62489821

© 2012 The Author(s). Licensee IntechOpen. This is an open access article distributed under the terms of the [Creative Commons Attribution 3.0 License](https://creativecommons.org/licenses/by/3.0/), which permits unrestricted use, distribution, and reproduction in any medium, provided the original work is properly cited.

IntechOpen

IntechOpen