

We are IntechOpen, the world's leading publisher of Open Access books Built by scientists, for scientists

6,900

Open access books available

186,000

International authors and editors

200M

Downloads

Our authors are among the

154

Countries delivered to

TOP 1%

most cited scientists

12.2%

Contributors from top 500 universities



WEB OF SCIENCE™

Selection of our books indexed in the Book Citation Index
in Web of Science™ Core Collection (BKCI)

Interested in publishing with us?
Contact book.department@intechopen.com

Numbers displayed above are based on latest data collected.
For more information visit www.intechopen.com



Pulmonary Venous Flow Pattern and Atrial Fibrillation: Fact and Controversy

Toru Maruyama¹, Yousuke Kokawa², Hisataka Nakamura²,
Mitsuhiro Fukata², Shioto Yasuda², Keita Odashiro² and Koichi Akashi²

¹*Institute of Health Science and*

²*Department of Medicine, Kyushu University, Fukuoka
Japan*

1. Introduction

The role of echocardiography in patients with atrial fibrillation (AF) has been changing gradually according with recent advance in echocardiographic instruments and better understanding for AF. Historically, M-mode echocardiography applied to AF patients has focused on the diagnosis of underlying organic heart diseases and on the detection of left atrial (LA) thrombi. These are not surprising because AF had been the highest risk of ischemic stroke in the era of incomplete anticoagulation therapy. Thereafter, LA size, volume and functions have been foci assessed by echocardiography. These echocardiographic procedures have been conducted for prediction and prevention of recurrence of AF paroxysms (Barbier et al, 1994; Verdecchia et al, 2003; Vasan et al, 2003). Spontaneous echo contrast has also been an established B-mode echocardiographic finding with highly predictive value of ischemic stroke. After the development of Doppler echocardiography, pulmonary venous flow (PVF) evaluation is a routine laboratory investigation for patients with and without AF. The usefulness of PVF evaluation is not limited to assess LA or left ventricular (LV) functions, but has expanded to investigation of various aspects of AF (Tabata et al., 2003). PVF recording increases its usefulness when it is combined with recordings of Doppler LV inflow pattern. This article reviews the established usefulness of PVF estimation in patients with permanent AF, and then focuses on the potential usefulness of PVF assessment in AF progression, i.e., during sinus rhythm (i.e., interval of paroxysms of AF), during ongoing paroxysmal AF, and further during the long-term AF management.

2. Clinical Perspectives of AF

AF is one of the most common sustained arrhythmias in daily clinical practice. There has been a great advance in the exploration of the etiologies of AF. These are the subject of several overlapping schemes of individual pathogenesis, i.e., atrial overload and stretch, myocardial ischemia and inflammation, degeneration and subsequent fibrosis of atrial myocardium, neurohumoral or metabolic factors, and other unknown factors. Therefore, clinical presentations of AF are very broad. This arrhythmia occurs in a variety of clinical

settings such as valvular heart diseases, postoperative conditions, heart failure, hypertension, metabolic syndrome, thyrotoxicosis, and so on (**Fig. 1**). Since valvular heart diseases were historically a main etiology of AF, echocardiographic attention to AF patients was mainly rheumatic valvular lesions and detection of LA thrombi or spontaneous echo contrast which is based on the local hemostatic changes due to rheologic abnormalities (Kwaan et al, 2004; Topaloglu et al, 2007). In relation to thrombus formation, LA appendage function was highlighted in that impaired appendage function leads to thrombus formation and high risk of embolic event (Donal et al, 2005). According to an increased prevalence of coronary artery diseases, AF has been encountered in acute myocardial infarction, after coronary artery bypass grafting surgery and chronic phase of ischemic heart disease and subsequent heart failure. On the other hand, AF is often observed in patients with another kind of arrhythmias (e.g., preexcitation syndrome) or noncardiac disorders (e.g., thyrotoxicosis, chronic obstructive pulmonary disease). AF is often encountered in subjects without systemic or organic heart diseases (so-called 'lone' AF). According with relative decline of rheumatic valvular diseases, terminology of 'nonvalvular' or 'nonrheumatic' AF becomes familiar. Wide spectrum in clinical features of AF sometimes makes the therapeutic decision-making difficult (Wyse & Gersh, 2004).

AF is classified by the duration in which this arrhythmia sustains (e.g., paroxysmal, persistent and permanent). Paroxysmal AF is characterized as rare or repetitive paroxysms of short-lasting AF, which often undergoes spontaneous conversion to sinus rhythm, but rhythm-control treatment is required depending on symptom and hemodynamic deterioration. Persistent AF has the possibility of termination either by antiarrhythmic drugs or by electrical defibrillation. Permanent AF does not restore to sinus rhythm spontaneously, and hence conservative therapeutic option is the rate-control strategy. AF is not only responsible for substantial morbidity and mortality, but also impairs quality of life by limited capacities of physical activity and heart rate regulation. To date, the most effective treatment for drug-refractory AF is radiofrequency catheter ablation. Pulmonary vein (PV) isolation by circumferential ablation of PV-LA junction is a promising technique to terminate AF. Despite the introduction of novel and sophisticated ablation techniques such as irrigation catheters, pericardial approach and ganglionated plexi ablation, periprocedural complications are not negligible.

AF is characterized to date as an age-dependent, progressive disease, i.e., AF prevalence increases steeply from 0.5% at age 50 to 59 years to 9.0% at age 80 to 89 years (Kannel et al., 1998). Progressive nature of this arrhythmia is evident in that AF becomes refractory to pharmacologic treatment and electrical defibrillation in proportion with the duration of sustaining AF. This is the main feature that distinguishes AF from many other kinds of clinical arrhythmia (Wijffels et al., 1995). In a few decades, the mechanisms of such progression of AF have been clarified by many basic experiments using AF animal models and clinical studies of AF patients. Remodeling of LA plays an important role in the genesis, maintenance and perpetuation of AF. LA remodeling is a concept including electrical, contractile and structural aspects. Electrical remodeling induces abbreviated and dispersed electrical refractoriness and inhomogeneous slow conduction of electrical impulse. These are considered to be an arrhythmogenic substrate, prerequisite of AF development. Electrocardiograms (ECG) in patients with AF demonstrate characteristic fibrillation (f) waves that are evident in right precordial leads. According to the progression of AF,

characteristic f-waves become gradually small in amplitude and high in frequency. On the other hand, contractile remodeling provides poor LA contraction and structural remodeling causes LA dilatation. Histologically, LA myocardium in patients with AF shows infiltration of inflammatory cells, interstitial fibrosis and loss of contractile myocytes, leading to slow, fragmented and fibrillatory conduction and poor dyssynchronous LA contractions.

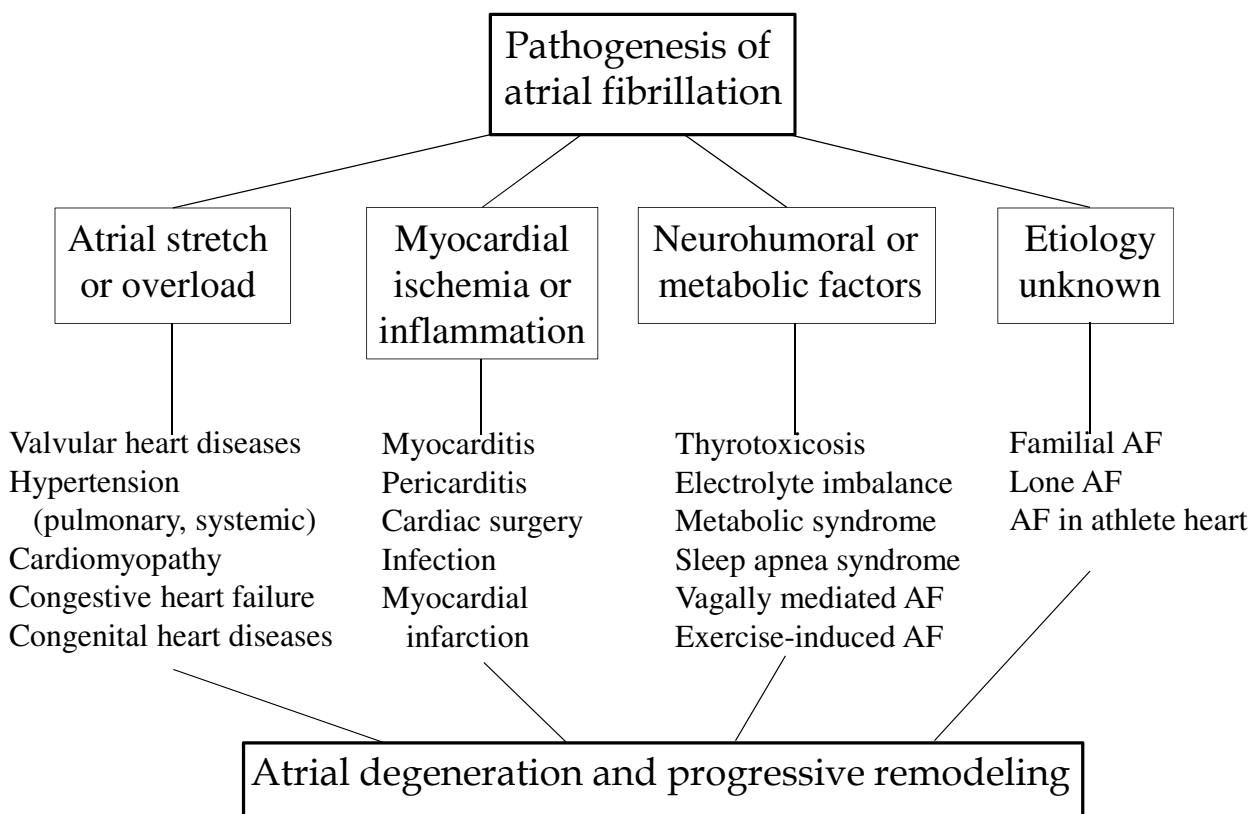


Fig. 1. Mechanisms favoring atrial fibrillation (AF).

3. Physiology of PVF

PVF recording is feasible not only by transesophageal echocardiography (TEE) but also by transthoracic echocardiography (TTE). According with the prevalence of PVF estimation by TTE, there have been investigations comparing the PVF recorded by TTE with that recorded by TEE. To date, TTE estimation of PVF is reported to provide reliable quantitation of PVF recorded by TEE in patients with and without organic heart diseases (Masuyama et al., 1995). **Fig. 2** is an actual Doppler PVF pattern during an entire cardiac cycle recorded by TTE. When ultrasound probe is positioned at the apex of chest wall, a four-chamber apical view is obtained. Then color jet is visualized in the upper LA of real-time, B-mode image. This color image is forward blood flow signals in right superior PV (**Fig. 2**, upper). After overall color Doppler interrogation, Doppler velocimetry is obtained by positioning the sampling gate 2-3 cm distal from the orifice of right superior PV (**Fig. 2**, lower).

The PVF profile is characterized as forward flows during LV systolic (**S**) and early diastolic (**D**) phases, and as reversed flow during late diastole when LA contracts (**Ar**). There are strictly two components within the **S** wave of PVF, i.e., **S₁** is caused by active LA relaxation

and S_2 is ascribed to passive LA wall stretching caused by vigorous LV contraction toward apical direction. Peak velocity and velocity-time integral of the **S** wave are usually greater than those of the **D** wave. Gentile et al (1997) investigated Doppler PVF parameters in 143 healthy individuals aged from 20 to 80 years by TTE. Age-dependent Doppler parameters are reported to be as follows; peak amplitude and time integral of both **S** and **D** waves, and **S/D** peak amplitude and integral ratios, whereas **Ar** wave is reported to be age-independent. These findings indicate the possibility of **Ar** wave as a diagnostic tool of various hemodynamic abnormalities in a wide range of patients' age.

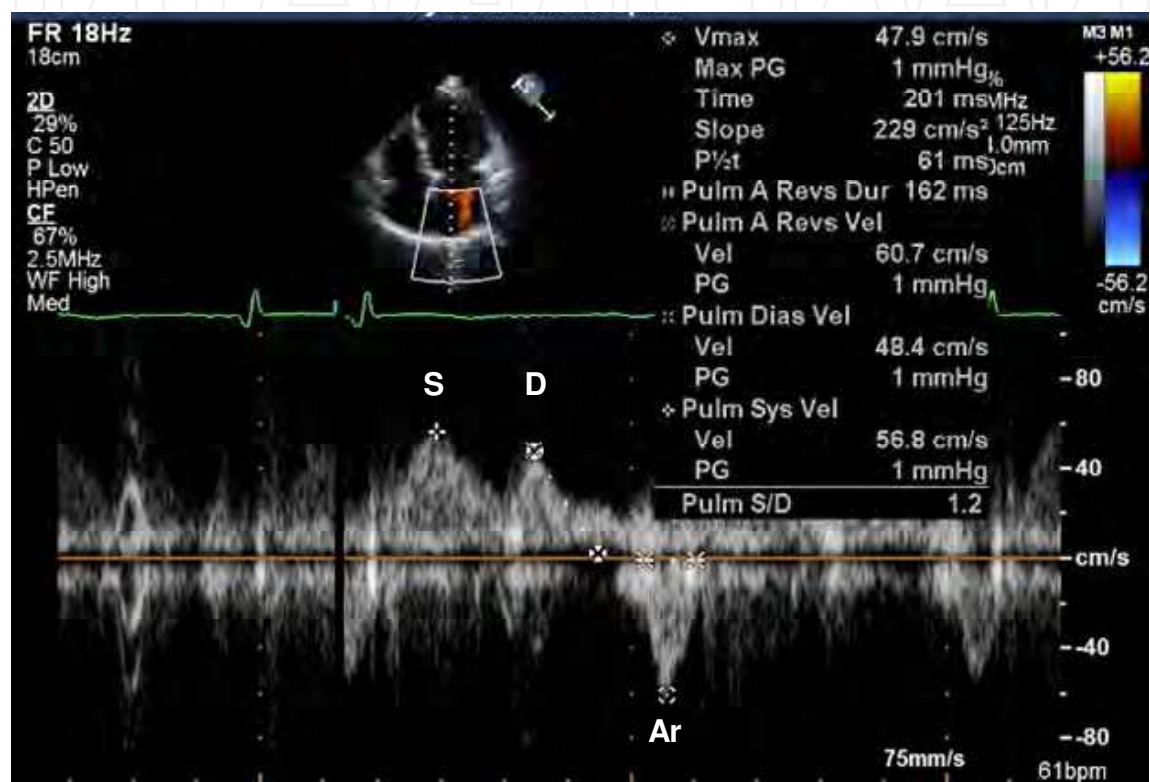


Fig. 2. Representative Doppler imaging of transthoracic echocardiography applied to a patient with hypertension. Upper image is an apical four chamber view with color flow indicating blood flow returning from right superior pulmonary vein (PV) into left atrium (LA). Middle is an ECG tracing (standard limb lead II). Lower is a continuous-wave Doppler PV flow velocimetry during an entire cardiac cycle. Upward direction indicates forward flow, whereas downward direction means reverse flow.

LA plays three different roles periodically in an entire cardiac cycle, i.e., LA acts as a 'booster pump' when LA contracts in late LV diastole, then as a 'reservoir' during LV systole, and finally as a 'conduit' during early LV diastole (**Fig. 3**). These three kinds of LA functions correspond with **Ar**, **S** and **D** waves respectively, and are estimated also by LA volume curve during an entire cardiac cycle using automatic boundary detection (Zhang et al, 1998), manual tracking (Ogawa et al, 2009), and speckle tracking techniques (Mori et al, 2011). The PVF pattern, especially **S** and **D** wave components, is influenced originally by many physiologic factors such as age, heart rate, respiration, LV function and loading conditions (Bollmann, 2007). These factors should be taken into account when evaluating PVF recording.

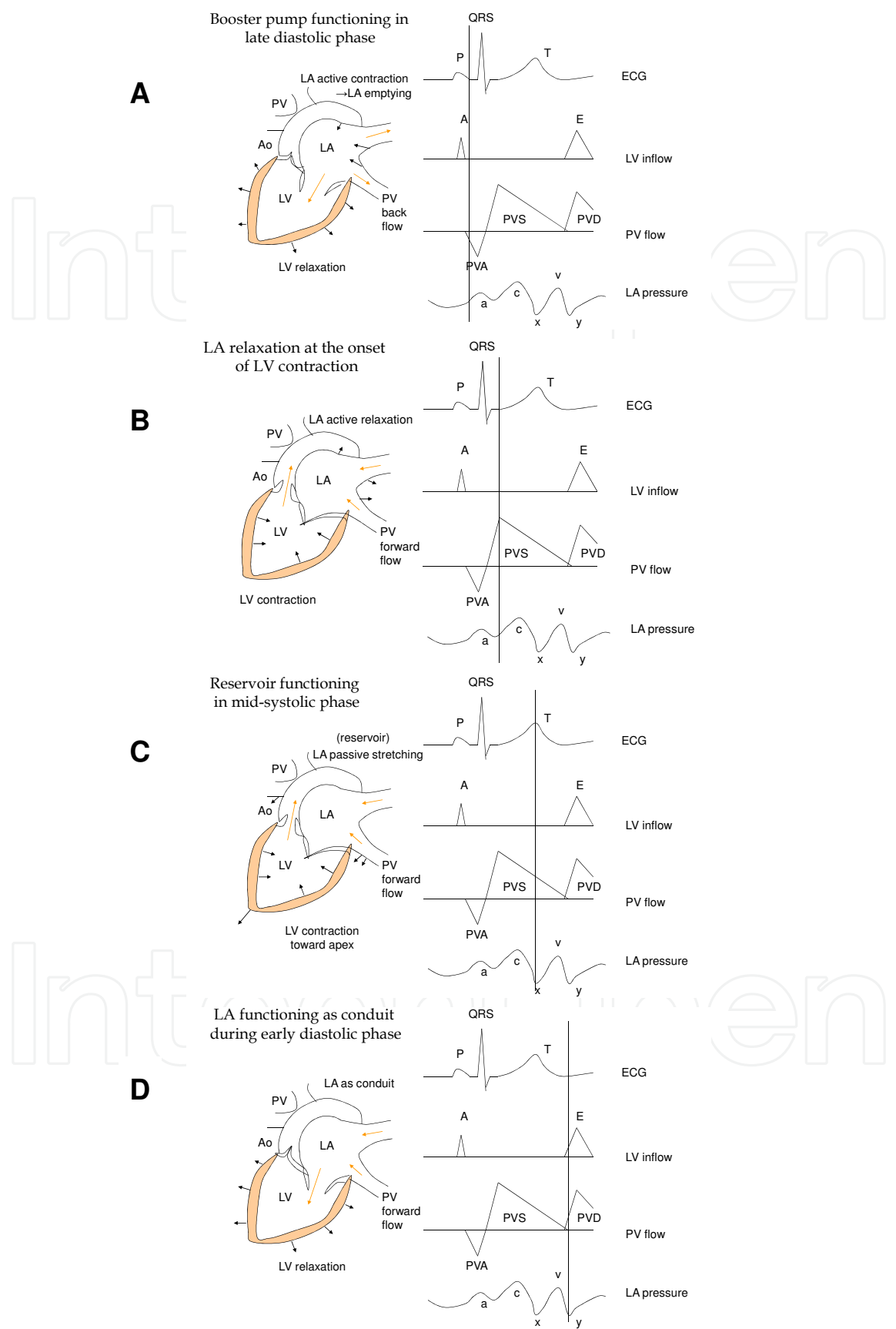


Fig. 3. Illustration of normal blood flow pattern in PV and LA during an entire cardiac cycle.

4. Myocardial sleeves in PV

In the PVF profile, **Ar** wave reflects physiologic PV regurgitation during LA contraction due to the absence of an anatomic valve at the PV-LA junction. Interestingly, PV wall contains myocardial sleeves instead of anatomic valve. **Fig. 4** is a schematic illustration of human atria and adjacent great veins. Posterior LA wall contains complicated myocardial layers for myocardial sleeves running longitudinally, cross-sectionally and obliquely within the PV walls. Histologically, myocardial sleeves exist in the mid-layer of PV walls (**Fig. 5A**). The myocardial sleeves are, therefore, considered to function as a 'sphincter', which minimizes the PV regurgitation caused by LA contraction. PV contraction is actually confirmed, and this phenomenon is mainly due to the presence of myocardial sleeves contracting synchronously with LA myocardium. This is validated by radiofrequency catheter ablation, i.e., perfect PV isolation (e.g., electrical disconnection of PV-LA junction) is reported to abolish the PV contraction (Atwater et al, 2011). These sleeves also function as 'throttle' valve that regulates cardiac output for systemic circulation (Burch & Romney, 1954). The myocardial sleeves show characteristic electrophysiological properties prone to yield spontaneous repetitive firings which propagate to LA and cause frequent ectopic beats. **Fig. 5B** is the microelectrode recording of the intracellular potentials of guinea-pig LA and myocardial sleeve in PV. Resting membrane potential in myocardial sleeve is less negative relative to that of LA. Moreover, myocardial sleeve in PV show the tendency of spontaneous electrical activity leading to the abnormal automaticity initiating AF. These arrhythmogenic foci act as a 'driver' to trigger and maintain paroxysms of AF. Highly compliant PV wall allows own cyclic stretching due to physiological PV regurgitation. This phenomenon is considered to accentuate intracellular Ca^{2+} dynamics mediated by stretch-activated ion channels, which is a prerequisite of repetitive electrical firing (de Bakker et al., 2002; Honjo et al., 2003; Chou et al., 2005, Takahara et al, 2011). Moreover, the myocardial sleeves within PV show a complicated anisotropic orientation of myocardial fibers separated by fibrotic tissues causing impaired electrotonic interactions, which accentuates intrinsic spontaneous firing and triggered activity (Nathan & Eliakim, 1966).

Since Haïssaguerre et al (1998) demonstrated the ectopic and spontaneous electrical activities in the myocardial sleeves located in PV responsible for triggering AF, main stream of the AF research has been changed over the past decade, in that recent AF study focused on many areas which had not been given much attention. Importance of the myocardial sleeves as arrhythmogenic foci in AF is confirmed also in the human postmortem studies. Tagawa et al (2001) investigated myocardial sleeve distribution in patients with AF or without AF. They showed that the significantly longer distance of sleeves extending to the peripheral end of PV in AF patients relative to the distance in control patients was confirmed in inferior but not superior PV. In addition, myocytes in PV of AF patients were not uniform and surrounded by fibrous tissues compared with those in controls. Moreover, Steiner et al (2006) reported that amyloid deposition and scarring in myocardial sleeves tended to be observed more frequently in AF patients relative to control patients. Interestingly, the incidence of atrial myocardium extending beyond the PV-LA junction up to the PV periphery in all the examined PV specimens is commonly reported to be 88 to 89% (Tagawa et al, 2001; Steiner et al, 2006).

According with an advance of immunohistochemical techniques, autonomic nervous innervation in PV has been elucidated. Ganglionated plexi are reported to be abundant around the great vessels of the human heart including PV (Armour et al, 1997).

Furthermore, both cholinergic and adrenergic nerve endings are found together within a single neural plexus of PV, and nerve density is highest in the PV antrum (Tan et al, 2006). The physiological meaning of these ganglionated plexi remains to be speculative. Considering the ‘throttle’ valve function of myocardial sleeves, ganglionated plexi located in PV-LA junctions may play a role of neural control of cardiac output by regulating proximal PV tonus. Elevated PV tonus associated with pathological condition such as heart failure (e.g., ganglionated plexi out of neural control) may lead to the occasion of acute pulmonary edema leading to severe dyspnea or orthopnea. AF *per se* also shows potential autonomic influence (**Fig. 1**). The correlations between the neural aspect of AF and the ganglionated plexi possibly influencing PV tonus or contraction are the subjects of future study.

5. PVF during ongoing AF

PVF is visualized by Doppler echocardiography not only in sinus rhythm but also during AF. AF is characterized by electrophysiological and mechanical properties such as rapid, irregular and fragmented electrical activities and absence of complete LA contraction and relaxation. Therefore, PVF during AF is known as loss of Ar wave, blunted S wave and relatively dominant D wave. Loss of synchronous LA contraction is reflected by disappearance of Ar wave. Similarly, loss of complete LA relaxation causes a delayed onset of S wave.

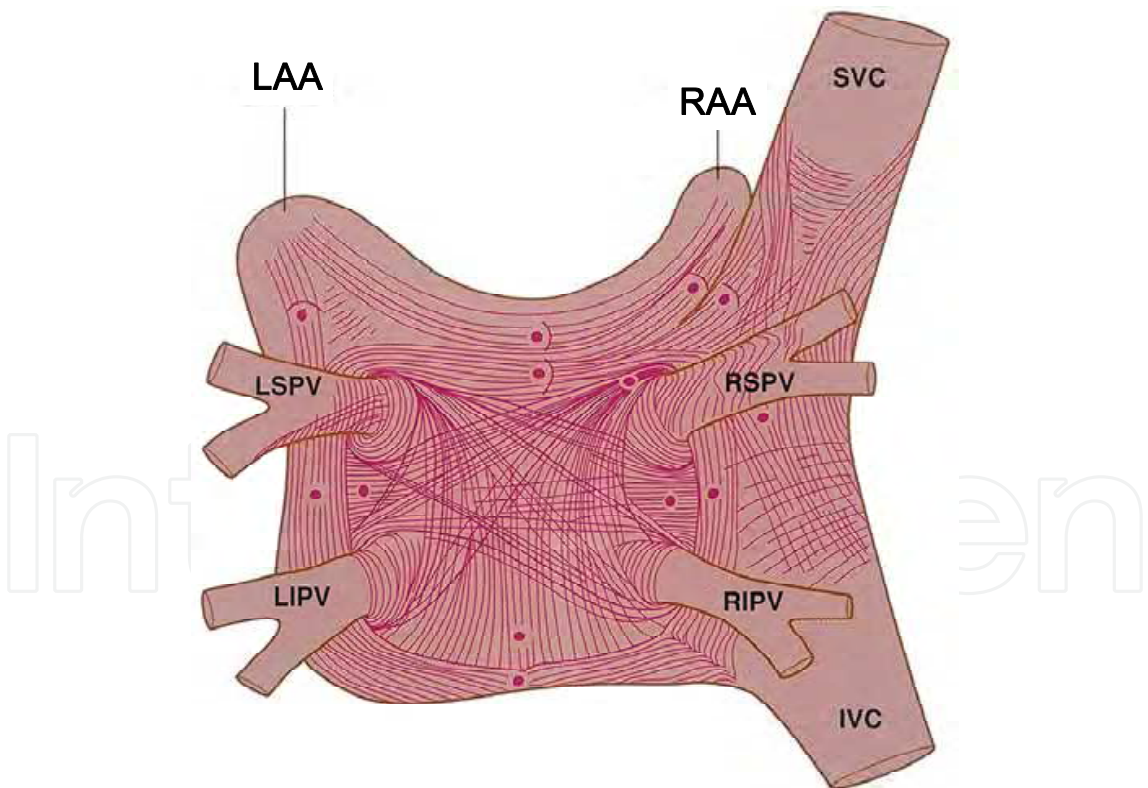


Fig. 4. Schematic illustration of human atria and adjacent great veins. Myocardial sleeves run in PV wall longitudinally, obliquely and cross-sectionally. Myocardial sleeve in superior PV is usually longer than that in inferior PV. IVC, inferior vena cava; LAA, left atrial appendage; LIPV, left inferior PV; LSPV, left superior PV; RAA, right atrial appendage; RIPV, right inferior PV; RSPV, right superior PV; SVC, superior vena cava.

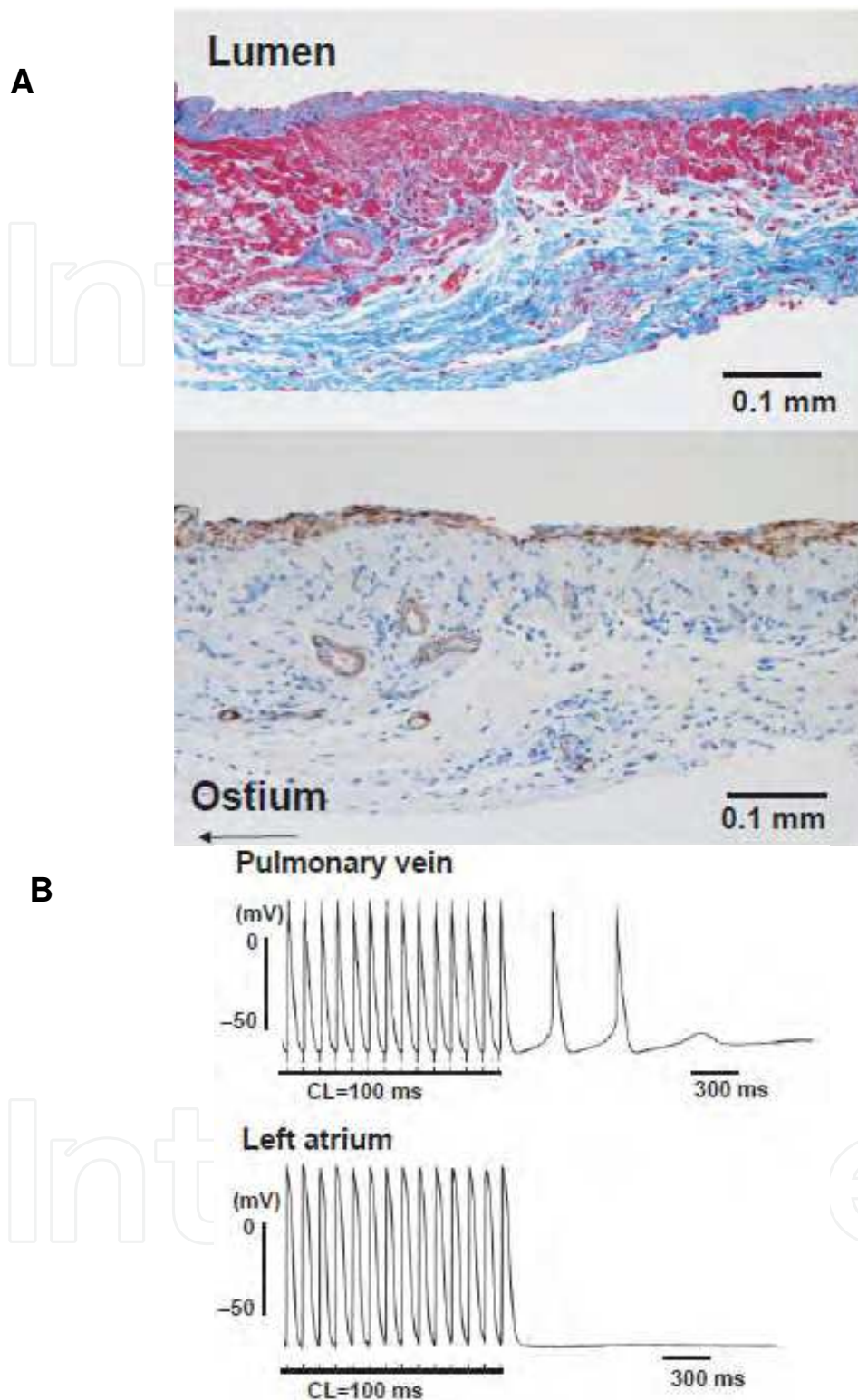


Fig. 5. **A:** Microscopic findings of PV obtained from guinea pig (upper: masson trichrome staining, lower: immunostaining for α -smooth muscle actin). **B:** Electrophysiological characteristics of PV and LA. (From Takahara, A.; Sugimoto, T.; Kitamura, T.; Takeda, K.; Tsuneoka, Y.; Namekata, I. & Tanaka, H. Electrophysiological and pharmacological characteristics of triggered activity elicited in guinea-pig pulmonary vein myocardium. *Journal of Pharmacological Science* Vol. 115, No. 2, 2011, pp. 176-181, with permission.)

This phenomenon is due to loss of S_1 wave that reflects forward PV flow under the active LA relaxation. Moreover, early systolic reversed PVF is sometimes observed (Tabata et al., 2003; Bollmann, 2007). This is reflected by reversed PV-LA pressure gradient at this moment of the early systolic phase. S_2 *per se* is also blunted under the increased LA stiffness during AF. LA functions of 'reservoir' and 'booster pump' are impaired profoundly under the presence of AF. Impaired LA functions result in the reduction of stroke volume by 38% even in AF patients without organic heart diseases (Alboni et al., 1995). Therefore, only the 'conduit' function of LA remains, which leads to the greater D wave relative to S_2 wave (Chao et al., 2000). These echocardiographic findings are important predictors of progressive LA remodeling.

6. PVF during sinus rhythm in AF patients

AF is a progressive disease showing electrical, contractile and structural LA remodeling (Wijffels et al., 1995). It is well known that paroxysms of AF gradually become refractory to pharmacologic treatment and electrical defibrillation. Accordingly, paroxysmal AF becomes persistent AF, and finally converts to permanent AF, although individual difference in such time course exists. For sonographers and cardiologists, one of the greatest echocardiographic interests during sinus rhythm in AF patients is to predict future paroxysms and progression of AF. Conventionally, prediction of AF progression is based mainly on LA size, volume, and functions (Barbier et al., 1994; Verdecchia et al., 2003; Vasan et al., 2003). Such evaluations have been performed historically by various echocardiographic techniques such as M-mode measurement, LV inflow Doppler velocimetry, strain-rate imaging, three-dimensional echocardiography speckle tracking technique and so on. Two-dimensional speckle tracking echocardiography monitors LA volume curve during an entire cardiac cycle, which enables accurate evaluations of aforementioned three kinds of LA functions (e.g., 'reservoir', 'conduit' and 'booster pump' functions). This technique showed reduced 'reservoir' and 'booster pump' functions in patients with paroxysmal AF (Mori et al., 2011).

PVF recording in sinus rhythm of AF patients has been receiving increasing attention, because 'focal' AF originates predominantly from PV (Haïssaguerre et al., 1998), and wide spectrum of paroxysmal to persistent AF associated with and without organic heart diseases shows similar characteristics of 'focal' AF. PV orifice morphologies in conjunction with AF progression have been investigated over the years by various modalities such as TEE (Knackstedt et al., 2003), magnetic resonance (MR) imaging (Tsao et al., 2001; Takase et al., 2004) and multislice computed tomography (Scharf et al., 2003). These investigations have been conducted under the uniform hypothesis that largest PV is the main source of ectopic electrical activities triggering and sustaining AF. **Fig. 6** demonstrates the PV images obtained by MR angiography applied to the patients with paroxysmal (**Fig. 6A**) or permanent (**Fig. 6B**) AF and with sinus rhythm (**Fig. 6C**). Four PV diameters are reported to be greater in the order of patients with permanent AF > those with paroxysmal AF > those with sinus rhythm (Takase et al., 2004). Moreover, PV branching pattern observed in AF patients is complicated compared with that of patients with sinus rhythm. These indicate that most permanent and paroxysmal AF stems from 'focal' AF, and that progressive structural remodeling caused by AF affects both LA and PV. With respect to the PV/LA diameter ratio, there has been a controversy, i.e., this ratio in patients with AF tended to be

greater than that of patients without AF (Knackstedt et al, 2003), whereas this ratio was the same among the patient groups of paroxysmal AF, permanent AF and sinus rhythm (Tsao et al, 2001). These discrepant results may be attributed in part to the different imaging modalities and AF patients' enrollment.

In spite of accumulated morphological investigations of PV-LA junction in AF patients, there have been controversies in echocardiographic PVF patterns during sinus rhythm in patients susceptible to AF. Kosmala et al (2006) reported that an abnormal PVF pattern was observed in patients with AF, i.e., abbreviated acceleration time and prolonged deceleration time in **S** wave, indicating impaired LA relaxation and compliance. Similarly, Lindgren et al (2003) reported the reduced **S** wave amplitude as a predictor of AF progression. These are compatible to the findings reported by two-dimensional speckle tracking method (Mori et al, 2011). On the other hand, increased **Ar** wave amplitude in sinus rhythm is reported to be a potential marker of AF progression in hypertensive patients in our laboratory (**Fig. 7**). **Ar** amplitude and velocity-time integral of **Ar** wave are supposed to be linked closely to the sphincter function of myocardial sleeves located in PV (**Fig. 4**, **Fig. 5A**), i.e., impaired sphincter function theoretically allows more PV regurgitation and **Ar** wave augmentation. Surprisingly, increased **Ar** amplitude is associated with reduced, but not increased, LA contractility in our study (Maruyama et al, 2008). These findings imply that PV sphincter dysfunction is linked to the contractile LA remodeling responsible for AF progression. LA contractile performance is usually quantified as LA fractional shortening (LAFS), which is calculated by the following equation (**Fig. 8**),

$$\text{LAFS} = (\text{LADa} - \text{LADd}) / \text{LADa} \quad (1)$$

where, LADa is an LA diameter at the beginning of LA contraction, and LADd is a minimum LA diameter during active LA contraction (Barbier et al, 1994). This is a simple measure of LA contractility obtained by M-mode echocardiography, although it is a parameter estimated only in the anteroposterior LA direction. **Ar** wave augmentation is associated with reduced LAFS, and predictive values of PV regurgitation (e.g., peak PV backflow velocity: PVBV), LA contractile function (e.g., LAFS) and LA size (e.g., LADd) for AF progression are assessed. Consequently, receiver-operating curve (ROC) indicated that the amplitude of age-independent **Ar** wave (e.g., PVBV) showed the greatest predictive value for the perpetuation of AF (**Fig. 9**). So far, the reason for discrepant results showing the importance of impaired forward flow (**S** wave) vs. augmented backward flow (**Ar** wave) in AF progression is unknown. PV regurgitation reflected by augmented **Ar** wave amplitude (e.g., PVBV) is determined by LA-PV pressure gradient (e.g., balance between LA contractile function and PV 'sphincter' function). These structures are under the influence of continuous remodeling according to the AF progression, which differs in individual AF patient. There are so many echocardiographic indices with different sensitivities and specificities. Echocardiography recorded during sinus rhythm at different stages of long-term AF progression may have resulted in such discrepant outcomes. Therefore, in personal opinion, it seems uncertain whether or not such comparisons of echocardiographic investigations are meaningful or fruitful.

Ar wave augmentation indicating an extent of PV regurgitation is considered to be a PV remodeling based on the impaired 'sphincter' function of the myocardial sleeves

surrounding the PV-LA junction (Fig. 4, Fig. 5A). This is considered to be due to the histological, electrical and mechanical abnormalities of the myocardial sleeves. On the other hand, reduced LAFS means the contractile LA remodeling, and increased LADd reflects

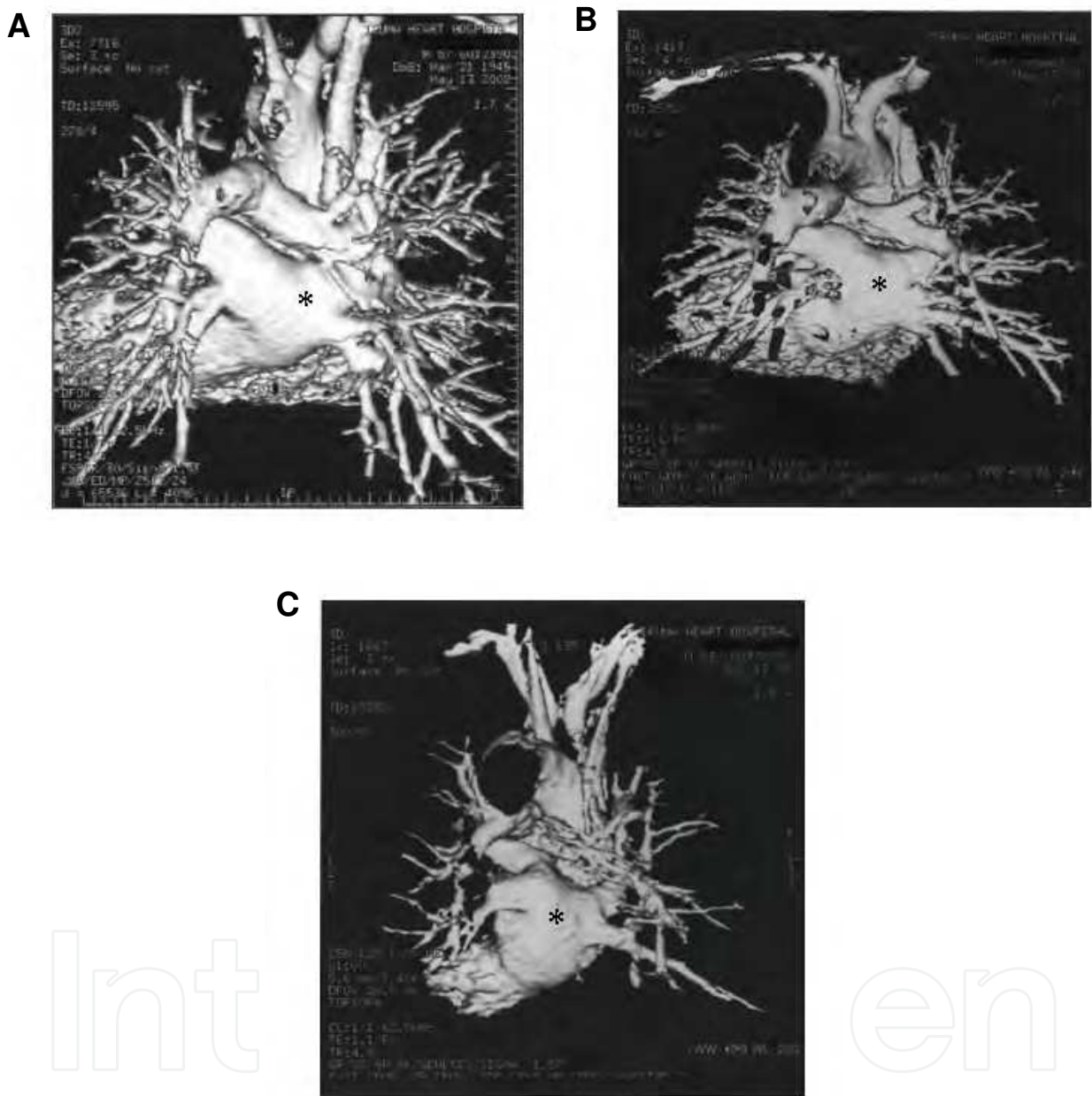


Fig. 6. Representative magnetic resonance angiography of patients with paroxysmal (A) or permanent (B) AF and with sinus rhythm (C). Diameters of pulmonary veins in AF patients are greater than those in patients with sinus rhythm. Landmark (*) showing the center of posterior wall of left atrium was indicated. (From Takase, B.; Nagata, M.; Matsui, T.; Kihara, T.; Kameyama, A.; Hamabe, A.; Noya, K.; Satomura, K.; Ishihara, M.; Kurita, A. & Ohsuzu, F. Pulmonary vein dimensions and variation of branching pattern in patients with paroxysmal atrial fibrillation using magnetic resonance angiography. *Japanese Heart Journal* Vol. 45, No. 1, 2004, pp. 81-92, with permission.)

in part the structural LA remodeling. It is, therefore, of interest which part of remodeling shows the greatest influence on the AF progression and perpetuation. In our study, PV remodeling demonstrated the greatest influence on the perpetuation of AF by the ROC analysis (**Fig. 9**). Knackstedt et al (2003) reported no correlation between PV diameter and LA size in patients with or without AF. Considering their TEE study, PV remodeling (e.g., dilation and regurgitation) plays a key role in AF progression (Scharf et al, 2003), although it is uncertain whether PV remodeling is a cause or a consequence of AF progression. PV wall is relatively more compliant and hence more susceptible to hemodynamics altered by paroxysms of AF than LA wall. Therefore, in personal opinion, these vessel properties of PV relates to susceptibility to AF-induced remodeling.

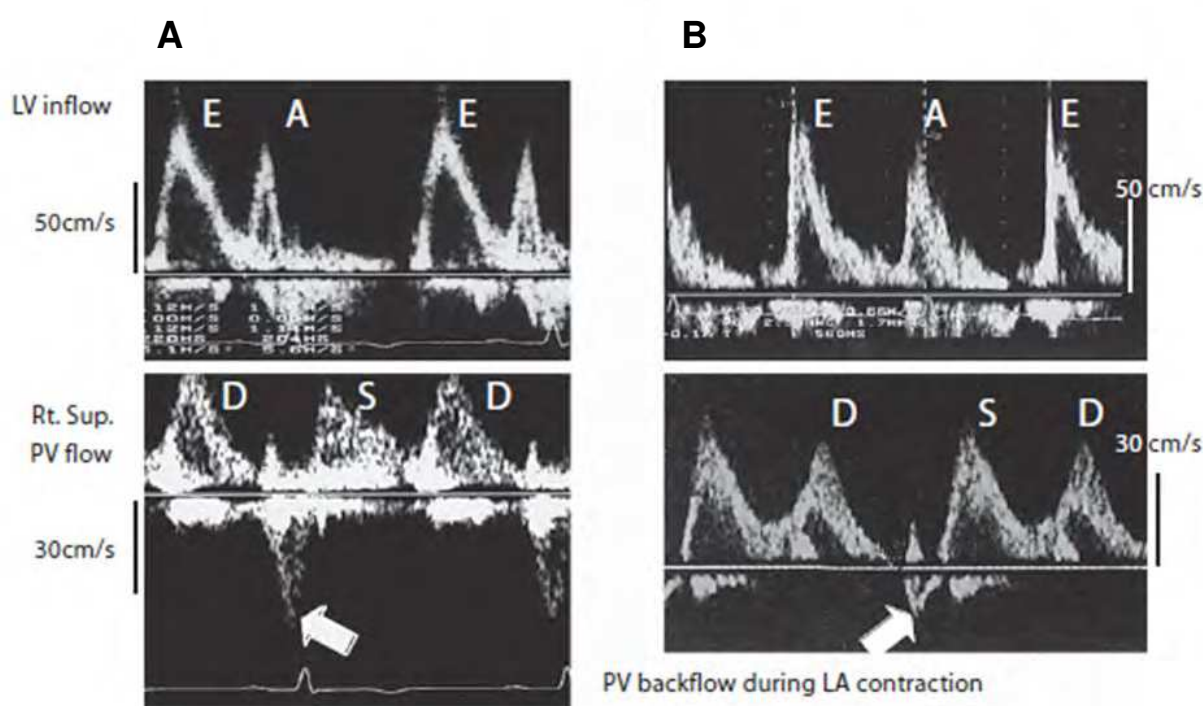


Fig. 7. Representative pulsed-wave Doppler findings of time-matched LV inflow (upper) and right superior pulmonary vein (PV) flow patterns (lower) during sinus rhythm in patients with AF which became permanent (**A**) or remained paroxysmal (**B**). Peak velocity of PV backflow (**Ar** wave) during left atrial (LA) contraction in **A** (left white arrow) was obviously greater than that in **B** (right white arrow). Time-integral of PV backflow in **A** is also greater than that in **B**. Note that scale in LV inflow is different from that in PV flow. (From Maruyama, T.; Kishikawa, T.; Ito, H.; Kaji, Y.; Sasaki, Y. & Ishihara, Y. Augmentation of pulmonary vein backflow velocity during left atrial contraction: a novel phenomenon responsible for progression of atrial fibrillation in hypertensive patients. *Cardiology* Vol. 109, No. 1, 2008, pp. 33-40, with permission.)

After the termination of AF episode, LA contractile function is briefly impaired. This impairment is gradually restored, and this reversible phenomenon is well known as LA stunning. One of the main causes of this stunning is considered to be based on the intracellular handling of cytosolic Ca^{2+} , which is important in cardiac performance but disturbed during AF. The aspects of atrial cardiomyopathy induced by tachycardia and atrial hibernation or fibrosis are also involved in the genesis of LA stunning (Khan, 2003). Recovery from LA

stunning depends on the duration of AF, mode of defibrillation, and LA size, i.e., AF lasting 10 to 20 minutes does not cause observable stunning (Sparks et al, 1999) and recovery of LA contractile function is early in the order of spontaneous conversion to sinus rhythm > pharmacological defibrillation > electrical defibrillation. AF patients with normal LA size are also apt to show earlier LA functional recovery (Mattioli et al, 1998; Khan, 2003).

Thromboembolic event is a major complication of AF. This complication after defibrillation has been attributed to the dislodgement of LA thrombi during the recovery from LA stunning. Therefore, serial echocardiographic investigation and optimal anticoagulation treatment are necessary during this period. LA stunning is observed also in the case of AF treated with radiofrequency catheter ablation. Stavrakis et al (2011) investigated the acute changes of LA function and PVF pattern following PV isolation associated with ganglionated plexi ablation by TEE. They reported augmentation of both **D** and **S** waves, decrease of **S/D** ratio, and trend toward an increase in LA appendage emptying velocities after the ablation. LA appendage emptying velocity closely relates to LA stunning, and reduced **S/D** ratio reflects impaired LA relaxation in the postablative period. These TEE findings are consistent with those reported by Lindgren et al (2003) in the paroxysmal interval of AF patients.

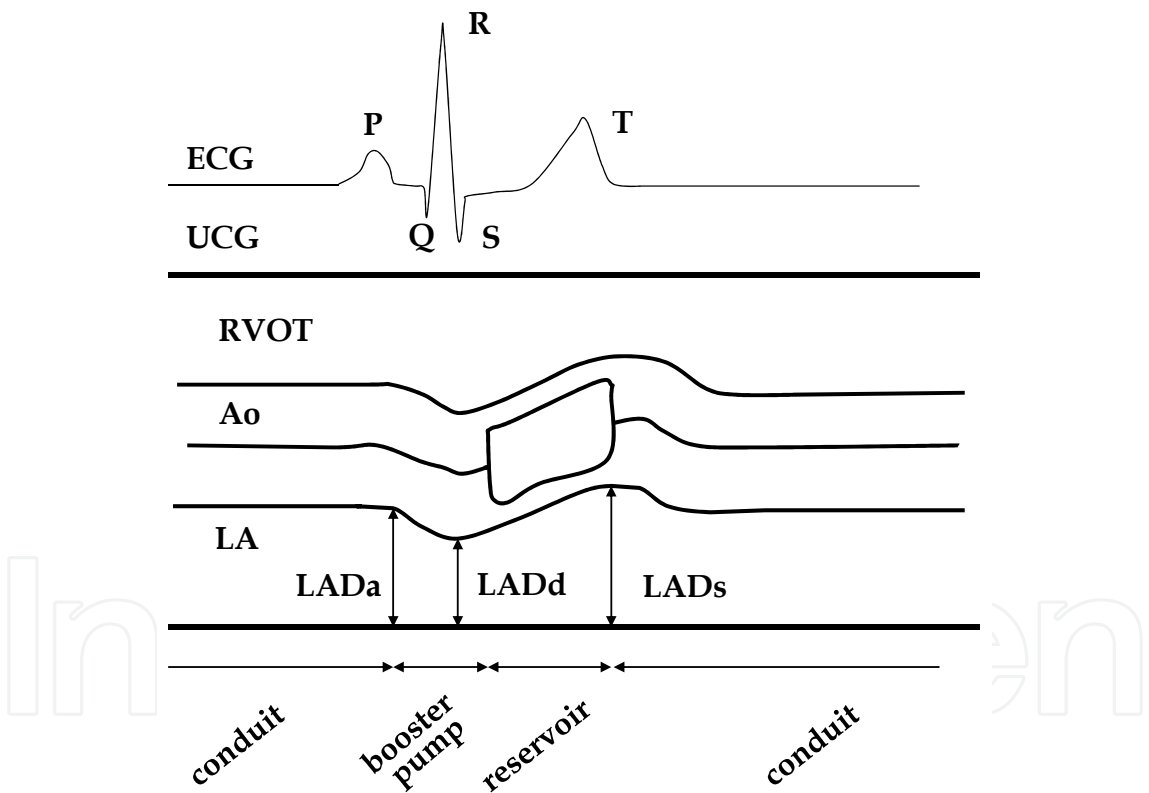


Fig. 8. Schematic illustration of the M-mode estimation of left atrial (LA) contractile function. LA dimension is variable depending on cardiac cycle. LADa, LA dimension immediately prior to the onset of LA contraction; LADd, minimal LA dimension at the end of the active LA contraction; LADs, maximal LA dimension at the end-systole. LA fractional shortening (LAFS) is calculated by equation (1) in the text. LA plays three kinds of hemodynamic function during an entire cardiac cycle (text). Aortic valve opening time corresponds to the left ventricular ejection period. Ao, aortic root; ECG, electrocardiogram; RVOT, right ventricular outflow tract; UCG, ultrasound cardiogram.

7. PVF in AF management

Pharmacological AF management is mainly divided into rhythm control and rate control strategies, both of which show equivalent outcomes in long-term prognosis of AF patients provided that appropriate anticoagulation therapy is conducted (Wyse, 2005). However, choice of better strategy based only on electrophysiologic or electrocardiographic perspectives seems insufficient. PVF evaluation has the potential to play a role in this decision-making process, i.e., PVF recording enables evaluation of contractile LA and PV functions, which vary during the long period of AF remodeling affecting both LA and PV. For AF management, it is important to assess the stage of AF progression in individual AF patient with different clinical background. For this purpose, assessment of LA stiffness or contractility and severity of PV regurgitation by PVF profile is important for AF management in individual patient.

Radiofrequency catheter ablation is widely conducted in many electrophysiologic laboratories. It is a first line therapy for ‘focal’ AF originating from PV, and is currently applied not only to paroxysmal AF but also to persistent AF. Remodeling makes AF drug-refractory. Moreover, antiarrhythmic drugs often suppress cardiac performance (negative inotropism) and are sometimes arrhythmogenic (proarrhythmic effects). The main

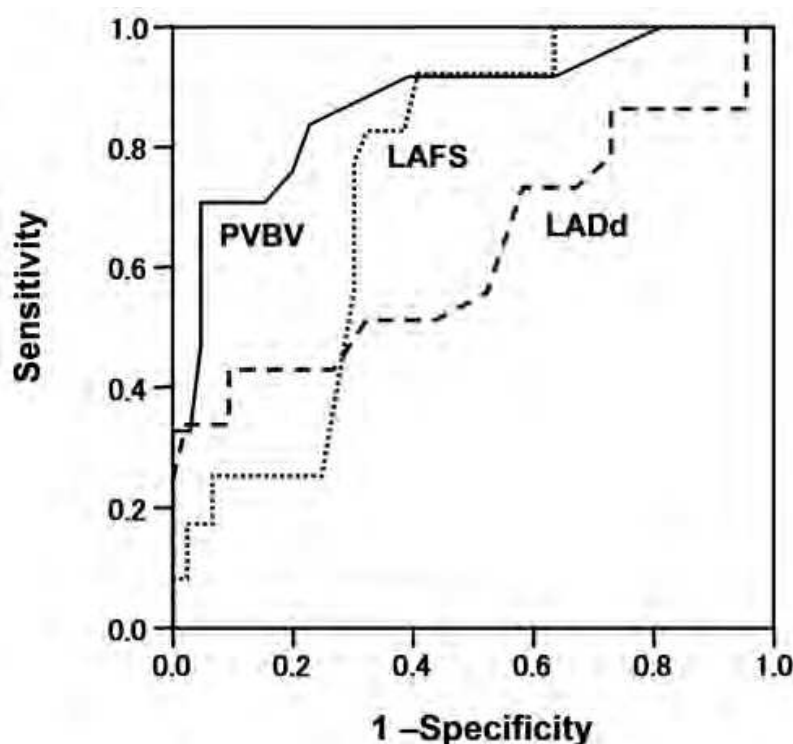


Fig. 9. Receiver-operating curve (ROC) discriminated PV backflow velocity (PVBV) as the best predictor of the progression of AF. Areas under the ROC for PVBV, left atrial fractional shortening (LAFS) and left atrial diameter at end-diastole (LADd) are 0.873, 0.740 and 0.623, respectively. Cut-off PVBV for predicting future AF perpetuation is 21.8 cm/sec (sensitivity 84.6%, specificity 78.3%). LAFS is calculated by equation (1) in the text. (From Maruyama, T.; Kishikawa, T.; Ito, H.; Kaji, Y.; Sasaki, Y. & Ishihara, Y. Augmentation of pulmonary vein backflow velocity during left atrial contraction: a novel phenomenon responsible for progression of atrial fibrillation in hypertensive patients. *Cardiology* Vol. 109, No. 1, 2008, pp. 33-40, with permission.)

procedure for ablation is electrical isolation of PV-LA junctions, i.e., disconnection of arrhythmogenic PV and adjacent antrum. Although recent advance in navigation system and new catheter device have enabled safe and effective PV isolation, PV stenosis remains a major complication especially of circumferential PV isolation. Pulmonary veno-occlusive syndrome associated with secondary pulmonary hypertension is a serious late-onset complication. During this procedure, mild-to-moderate forward PVF (e.g., **S** and **D** waves) acceleration is recorded, but this acceleration is transient and well tolerated (Ren et al., 2002). PVF monitoring is a practical and cost-effective method for early detection of this serious complication (Tabata et al., 2003; Bollmann 2007). When considering PVF is influenced by heart rate and autonomic tone (Ren et al., 2004), computed tomography or MR imaging is required to determine the therapeutic indication for balloon dilatation of PV stenosis.

8. PVF and AF progression

All the components of PVF have the potential role to evaluate AF progression, i.e., **S** wave attenuation and consequent relative **D** wave augmentation indicate impaired LA relaxation and compliance. Considering increased **D** and **Ar** wave amplitudes during sinus rhythm in AF patients, PVF increases exclusively during LV diastole, whichever PVF direction is forward (e.g., **D** wave) or backward (e.g., **Ar** wave). If ectopic beats originating from PV are mechanically triggered, these echocardiographic findings indicate that ectopic beats are prone to occur during diastole. Therefore, repetitive PV ectopic beats easily capture ventricles that are out of refractory period, and induce rapid ventricular response during ‘focal’ AF. This is important because rapid AF is easy to promote electrical remodeling (Wijffels et al., 1995).

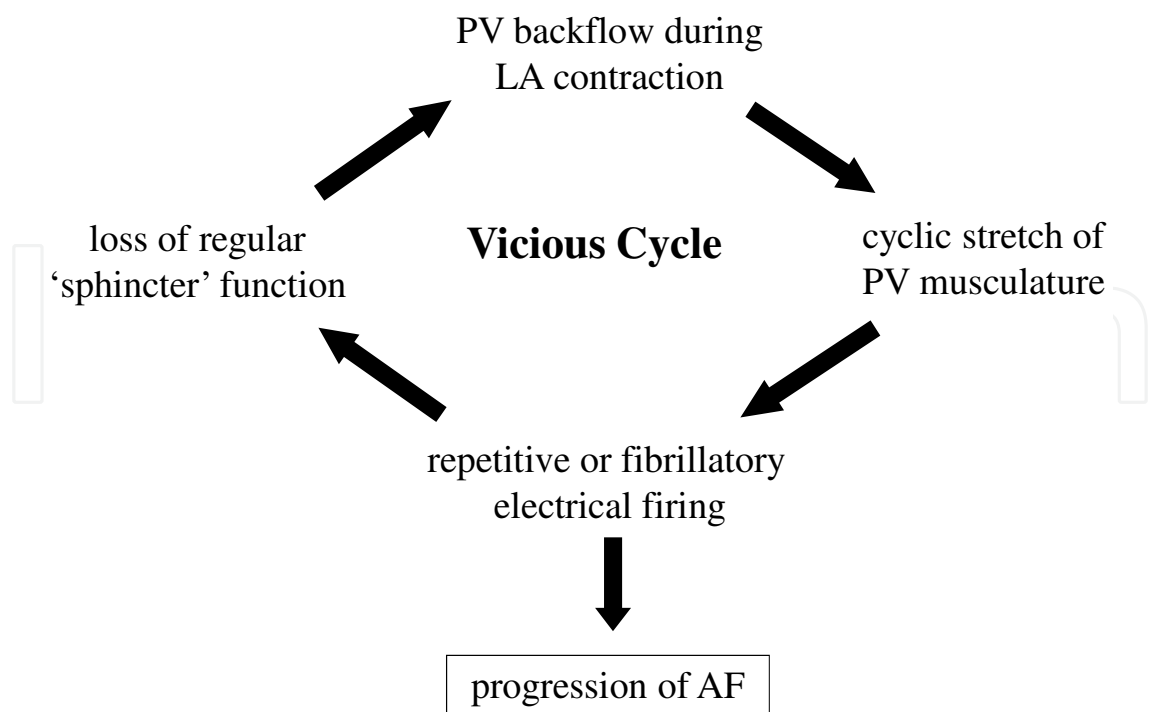


Fig. 10. Possible mechanisms of reversed PV flow (**Ar** wave) augmentation contributing to the AF progression.

AF progression is reported to be associated with greater PV diameter (Knackstedt et al., 2003; Tsao et al., 2001) as a consequence of PV remodeling (Scharf et al., 2003). Although the relation of AF and PV contraction remains to be fully investigated, augmentation of **Ar** wave (e.g., PVBV) may cause cyclic stretching of highly compliant myocardial sleeves in PV, repetitive ectopic beats and loss of 'sphincter' function, which underlie further PV regurgitation. Therefore, **D** and **Ar** waves augmentation, PV myocardial sleeve stretching and ectopic beats form a vicious cycle leading to PV remodeling. A possible mechanism by which PV characteristics contribute to AF progression is demonstrated in **Fig. 10**.

9. Conclusion

AF is the most common clinical arrhythmia showing progressive features. There has been evidence to suggest PV as a source of abnormal electrical activities initiating and sustaining AF. Currently, PVF recording is feasible in routine Doppler echocardiography, and is essential for evaluation of LA functioning three roles during an entire cardiac cycle such as 'booster pump', 'reservoir' and 'conduit'. This flow pattern recognition is of clinical importance not only in assessing global cardiac performance but also for obtaining considerable information with respect to the pathophysiology and management of AF. There has been a consensus with respect to the PVF pattern during ongoing AF or in patients with permanent AF. However, there has been a controversy concerning PVF profile during sinus rhythm in patients with paroxysmal AF. This indicates the anatomical and pathophysiological complexities of PV-LA junction and AF itself. Time-dependent recovery of LA contractile function (LA stunning) and neuroanatomical modification of PV-LA junction by radiofrequency catheter ablation make this controversy further complicated. In spite of such controversy and complexity, PVF recording has potential benefits to assess various stages of long-term AF progression and to manage the AF patients.

10. Acknowledgements

The authors thank the echocardiographic laboratory staff in Kyushu University Hospital, Fukuoka, Japan for contribution to this work.

11. References

- Alboni, P.; Scarfò, S.; Fucà, G.; Paparella, N. & Yannacopulu, P. (1995). Hemodynamics of idiopathic paroxysmal atrial fibrillation. *Pacing and Clinical Electrophysiology* Vol. 18. No. 5 (Pt 1), (May 1995), pp. 980-985, ISSN 0147-8389
- Armour, JA.; Murphy, DA.; Yuan, BX.; Macdonald, S. & Hopkins, DA. (1997). Gross and microscopic anatomy of the human intrinsic cardiac nervous system. *The Anatomical Record* Vol. 247, No. 2, (February 1997), pp. 289-298, ISSN 1932-8494
- Atwater, BD.; Wallace, TW.; Kim, HW.; Hranitzky, PM.; Bahnson, TD.; Hegland, DD. & Daubert, JP. (2011). Pulmonary vein contraction before and after radiofrequency ablation for atrial fibrillation. *Journal of Cardiovascular Electrophysiology* Vol. 22, No. 2, (February 2011), pp. 169-174, ISSN 1540-8167
- Barbier, P.; Alioto, G. & Guazzi, MD. (1994). Left atrial function and ventricular filling in hypertensive patients with paroxysmal atrial fibrillation. *Journal of the American College of Cardiology* Vol. 24, No. 1, (July 1994), pp. 165-170, ISSN 0735-1097


- Bollmann, A. (2007). Pulmonary venous flow assessed by Doppler echocardiography in the management of atrial fibrillation (Review). *Echocardiography* Vol. 24, No. 4, (April 2007), pp. 430-435, ISSN 1540-8175
- Burch, GE. & Romney, RB. (1954). Functional anatomy and throttle valve action on the pulmonary veins. *American Heart Journal* Vol. 47, No. 1, (January 1954), pp. 58-66, ISSN 0002-8703
- Chao, TH.; Tsai, LM.; Tsai, WC.; Li, YH.; Lin, LJ. & Chen, JH. (2000). Effects of atrial fibrillation on pulmonary venous flow patterns assessed by Doppler transesophageal echocardiography. *Chest* Vol. 117, No. 6, (June 2000), pp. 1546-1550, ISSN 0012-3692
- Chou, CC.; Nihei, M.; Zhou, S.; Tan, S.; Kawase, A.; Macias, ES.; Fishbein, MC.; Lin, SF. & Chen, PS. (2005). Intracellular calcium dynamics and anisotropic reentry in isolated canine pulmonary veins and left atrium. *Circulation* Vol. 111, No. 22, (June 2005), pp. 2889-2897, ISSN 0009-7322
- de Bakker, JMT.; Ho, SY. & Hocini, M. (2002). Basic and clinical electrophysiology of pulmonary vein ectopy (Review). *Cardiovascular Research* Vol. 54, No. 2, (May 2002), pp. 287-294, ISSN 0008-6363
- Donal, E.; Yamada, H.; Leclercq, C. & Herpin, D. (2005). The left atrial appendage, a small, blind-ended structure: a review of its echocardiographic evaluation and its clinical role (Review). *Chest* Vol. 128, No. 3, (September 2005), pp. 1853-1862, ISSN 0012-3692
- Gentile, F.; Mantero, A.; Lippolis, A.; Ornaghi, M.; Azzollini, M.; Barbier, P.; Beretta, L.; Casazza, F.; Corno, R.; Faletra, F.; Giagnoni, E.; Gualtierotti, C.; Lombroso, S.; Mattioli, R.; Morabito, A.; Pegi, M.; Todd, S. & Pezzano, A. (1997). Pulmonary venous flow velocity patterns in 143 normal subjects aged 20 to 80 years old: an echo 2D colour Doppler cooperative study. *European Heart Journal* Vol. 18, No. 1, (January 1997), pp. 148-164, ISSN 0195-668X
- Haïssaguerre, M.; Jaïs, P.; Shah, DC.; Takahashi, A.; Hocini, M.; Quiniou, G.; Garrigue, S.; Le Mouroux, A.; Le Metayer, P. & Clémenty, J. (1998). Spontaneous initiation of atrial fibrillation by ectopic beats originating in the pulmonary veins. *New England Journal of Medicine* Vol. 339, No. 10, (September 1998), pp. 659-666, ISSN 0028-4793
- Honjo, H.; Boyett, MR.; Niwa, R.; Inada, S.; Yamamoto, M.; Mitsui, K.; Horiuchi, T.; Shibata, N.; Kamiya, K. & Kodama, I. (2003). Pacing-induced spontaneous activity in myocardial sleeves of pulmonary veins after treatment with ryanodine. *Circulation* Vol. 107, No. 14, (April 2003), pp. 1937-1943, ISSN 0009-7322
- Kannel, WB.; Wolf, PA.; Benjamin, EJ. & Levy, D. (1998). Prevalence, incidence, prognosis, and predisposing conditions for atrial fibrillation: population-based estimates. *American Journal of Cardiology* Vol. 82, Supplement 8A, (October 1998), pp. 2N-9N, ISSN 0002-9149
- Khan, IA. (2003). Atrial stunning: determinants and cellular mechanisms. *American Heart Journal* Vol. 145, No. 5, (May 2003), pp. 787-794, ISSN 0002-8703
- Knackstedt, C.; Visser, L.; Plisene, J.; Zarse, M.; Waldmann, M.; Mischke, K.; Koch, KC.; Hoffmann, R.; Franke, A.; Hanrath, P. & Schauerte, P. (2003). Dilatation of the pulmonary veins in atrial fibrillation: a transesophageal echocardiographic evaluation. *Pacing and Clinical Electrophysiology* Vol. 26, No. 6, (June 2003), pp. 1371-1378, ISSN 0147-8389

- Kosmala, W.; Przewlocka-Kosmala, M. & Mazurek, W. (2006). Abnormalities of pulmonary venous flow in patients with lone atrial fibrillation. *Europace* Vol. 8, No. 2, (February 2006), pp.102-106, ISSN 1099-5129
- Kwaan, HC.; Sakurai, S. & Wang, J. (2003). Rheological abnormalities and thromboembolic complications in heart disease: spontaneous echo contrast and red cell aggregation (Review). *Seminars in Thrombosis and Hemostasis* Vol. 29, No. 5, (October 2003), pp. 529-534, ISSN 0094-6176
- Lindgren, KS.; Pekka Raatikainen, MJ.; Juhani Airaksinen, KE. & Huikuri, HV. (2003). Relationship between the frequency of paroxysmal episodes of atrial fibrillation and pulmonary venous flow pattern. *Europace* Vol. 5, No. 1, (January 2003), pp. 17-23, ISSN 1099-5129
- Maruyama, T.; Kishikawa, T.; Ito, H.; Kaji, Y.; Sasaki, Y. & Ishihara, Y. (2008). Augmentation of pulmonary vein backflow velocity during left atrial contraction: a novel phenomenon responsible for progression of atrial fibrillation in hypertensive patients. *Cardiology* Vol. 109, No. 1, (January 2008), pp. 33-40, ISSN 0008-6312
- Masuyama, T.; Nagano, R.; Nariyama, K.; Lee, JM.; Yamamoto, K.; Naito, J.; Mano, T.; Kondo, H.; Hori, M. & Kamada, T. (1995). Transthoracic Doppler echocardiographic measurements of pulmonary venous flow velocity patterns: comparison with transesophageal measurements. *Journal of the American Society of Echocardiography* Vol. 8, No. 1, (January-February 1995), pp. 61-69, ISSN 0894-7317
- Mattioli, AV.; Castelli, A.; Andria, A. & Mattioli, G. (1998). Clinical and echocardiographic features influencing recovery of atrial function after cardioversion of atrial fibrillation. *American Journal of Cardiology* Vol. 82, No. 11, (December 1998), pp. 1368-1371, ISSN 0002-9149
- Mori, M.; Kanzaki, H.; Amaki, M.; Ohara, T.; Hasegawa, T.; Takahama, H.; Hashimura, K.; Konno, T.; Hayashi, K.; Yamagishi, M. & Kitakaze, M. (2011). Impact of reduced left atrial functions on diagnosis of paroxysmal atrial fibrillation: results from analysis of time-left atrial volume curve determined by two-dimensional speckle tracking. *Journal of Cardiology* Vol. 57, No. 1, (January 2011), pp. 89-94, ISSN 0914-5087
- Nathan, H. & Eliakim, M. (1966). The junction between the left atrium and the pulmonary veins: an anatomic study of human hearts. *Circulation* Vol. 34, No. 3, (September 1966), pp. 412-422, ISSN 0009-7322
- Ogawa, K.; Hozumi, T.; Sugioka, K.; Iwata, S.; Otsuka, R.; Takagi, Y.; Yoshitani, H.; Yoshiyama, M. & Yoshikawa, J. (2009). Automated assessment of left atrial function from time-left atrial volume curves using a novel speckle tracking imaging method. *Journal of the American Society of Echocardiography* Vol. 22, No. 1, (January 2009), pp. 63-69, ISSN 0894-7317
- Ren, JF.; Marchlinski, FE.; Callans, DJ. & Zado, ES. (2002). Intracardiac Doppler echocardiographic quantification of pulmonary vein flow velocity: an effective technique for monitoring pulmonary vein ostia narrowing during focal atrial fibrillation ablation. *Journal of Cardiovascular Electrophysiology* Vol. 13, No. 11, (November 2002), pp. 1076-1081, ISSN 1540-8167
- Ren, JF.; Marchlinski, FE. & Callans, DJ. (2004). Effect of heart rate and isoproterenol on pulmonary vein flow velocity following radiofrequency ablation: a Doppler color flow imaging study. *Journal of Interventional Cardiac Electrophysiology* Vol. 10, No. 3, (June 2004), pp. 265-269, ISSN 1383-875X

- Scharf, C.; Sneider, M.; Case, I.; Chugh, A.; Lai, SW.; Pelosi, F.; Knight, BP.; Kazerooni, E.; Morady, F. & Oral, H. (2003). Anatomy of the pulmonary veins in patients with atrial fibrillation and effects of segmental ostial ablation analyzed by computed tomography. *Journal of Cardiovascular Electrophysiology* Vol. 14, No. 2, (February 2003), pp. 150-155, ISSN 1540-8167
- Sparks, PB.; Jayaprakash, S.; Mond, HG.; Vohra, JK.; Grigg, LE. & Kalman, JM. (1999). Left atrial mechanical function after brief duration atrial fibrillation. *Journal of the American College of Cardiology* Vol. 33, No. 2, (February 1999), pp. 342-349, ISSN 0735-1097
- Stavrakis, S.; Madden, G.; Pokharel, D.; Po, SS.; Nakagawa, H.; Jackman, WM. & Sivaram, CA. (2011). Transesophageal echocardiographic assessment of pulmonary veins and left atrium in patients undergoing atrial fibrillation ablation. *Echocardiography* Vol. 28, No. 7, (August 2011), pp. 775-781, ISSN 1540-8175
- Steiner, I.; Hájková, P.; Kvasnička, J. & Kholová, I. (2006). Myocardial sleeves of pulmonary veins and atrial fibrillation: a postmortem histopathological study of 100 subjects. *Virchows Archiv* Vol. 449, No. 1, (July 2006), pp. 88-95, ISSN 0945-6317
- Tabata, T.; Thomas, JD. & Klein, AL. (2003). Pulmonary venous flow by Doppler echocardiography: revisited 12 years later. *Journal of the American College of Cardiology* Vol. 41, No. 8, (April 2003), pp. 1243-1250, ISSN 0735-1097
- Tagawa, M.; Higuchi, K.; Chinushi, M.; Washizuka, T.; Ushiki, T.; Ishihara, N. & Aizawa, Y. (2001). Myocardium extending from the left atrium onto the pulmonary veins: a comparison between subjects with and without atrial fibrillation. *Pacing and Clinical Electrophysiology* Vol. 24, No. 10, (October 2001), pp. 1459-1463, ISSN 0147-8389
- Takahara, A.; Sugimoto, T.; Kitamura, T.; Takeda, K.; Tsuneoka, Y.; Namekata, I. & Tanaka, H. (2011). Electrophysiological and pharmacological characteristics of triggered activity elicited in guinea-pig pulmonary vein myocardium. *Journal of Pharmacological Science* Vol. 115, No. 2, (February 2011), pp. 176-181, ISSN 1347-8613
- Takase, B.; Nagata, M.; Matsui, T.; Kihara, T.; Kameyama, A.; Hamabe, A.; Noya, K.; Satomura, K.; Ishihara, M.; Kurita, A. & Ohsuzu, F. (2004). Pulmonary vein dimensions and variation of branching pattern in patients with paroxysmal atrial fibrillation using magnetic resonance angiography. *Japanese Heart Journal* Vol. 45, No. 1, (January 2004), pp. 81-92, ISSN 0021-4868
- Tan, AY.; Li, H.; Wachsmann-Hogiu, S.; Chen, LS.; Chen, PS. & Fishbein, MC. (2006). Autonomic innervation and segmental muscular disconnections at the human pulmonary vein-atrial junction: implications for catheter ablation of atrial-pulmonary vein junction. *Journal of the American College of Cardiology* Vol. 48, No. 1, (July 2006), pp. 132-143, ISSN 0735-1097
- Topaloglu, S.; Boyaci, A.; Ayaz, S.; Yilmaz, S.; Yanik, O.; Ozdemir, O.; Soylu, M.; Demir, AD.; Aras, D.; Kisacik, HL. & Korkmaz, S. (2007). Coagulation, fibrinolytic system activation and endothelial dysfunction in patients with mitral stenosis and sinus rhythm. *Angiology* Vol. 58, No. 1, (February-March 2007), pp. 85-91, ISSN 0003-3197
- Tsao, HM.; Yu, WC.; Cheng, HC.; Wu, MH.; Tai, CT.; Lin, WS.; Ding, YA.; Chang, MS. & Chen, SA. (2001). Pulmonary vein dilatation in patients with atrial fibrillation: detection by magnetic resonance imaging. *Journal of Cardiovascular Electrophysiology* Vol. 12, No. 7, (July 2001), pp. 809-813, ISSN 1540-8167

- Vasan, RS.; Larson, MG.; Levy, D.; Galderisi, M.; Wolf, PA. & Benjamin, EJ. (2003). Doppler transmitral flow indexes and risk of atrial fibrillation (the Framingham Heart Study). *American Journal of Cardiology* Vol. 91, No. 9, (May 2003), pp. 1079-1083, ISSN 0002-9149
- Verdecchia, P.; Reboldi, G.; Gattobigio, R.; Bentivoglio, M.; Borgioni, C.; Angeli, F.; Carluccio, E.; Sardone, MG. & Porcellati, C. (2003). Atrial fibrillation in hypertension: predictors and outcome. *Hypertension* Vol. 41, No. 2, (February 2003), pp. 218-223, ISSN 0194-911X
- Wijffels, MC.; Kirchhof, CJ.; Dorland, R. & Allessie, MA. (1995). Atrial fibrillation begets atrial fibrillation: a study in awake chronically instrumented goats. *Circulation* Vol. 92, No. 7, (October 1995), pp. 1954-1968, ISSN 0009-7322
- Wyse, DG. (2005). Rate control vs. rhythm control strategies in atrial fibrillation. *Progress in Cardiovascular Diseases* Vol. 48, No. 2, (September-October 2005), pp. 125-138, ISSN 0033-0620
- Wyse, DG. & Gersh, BJ. (2004). Atrial fibrillation: a perspective: thinking inside and outside the box. *Circulation* Vol. 109, No. 25, (June 2004), pp. 3089-3095, ISSN 0009-7322
- Zhang, GC.; Tsukada, T.; Nakatani, S.; Uematsu, M.; Yasumura, Y.; Tanaka, N.; Masuda, Y.; Miyatake, K. & Yamagishi, M. (1998). Comparison of automatic boundary detection and manual tracking technique in echocardiographic determination of left atrial volume. *Japanese Circulation Journal* Vol. 62, No. 10, (October 1998), pp. 755-759, ISSN 1346-9843

IntechOpen



Echocardiography - In Specific Diseases

Edited by Prof. Gani Bajraktari

ISBN 978-953-307-977-6

Hard cover, 160 pages

Publisher InTech

Published online 18, January, 2012

Published in print edition January, 2012

The book "Echocardiography - In Specific Diseases" brings together contributions from well-known researchers from around the world, some of them specialized in imaging science in their clinical orientation, but also representatives from academic medical centers. Each chapter is structured and written to be accessible to those with a basic knowledge of echocardiography but also to be stimulating and informative to experts and researchers in the field of echocardiography. This book is primarily aimed at cardiology fellows during their basic echocardiography rotation, fellows of internal medicine, radiology and emergency medicine, but also experts in echocardiography. During the past few decades technological advancements in echocardiography have been developing rapidly, leading to improved echocardiographic imaging using new techniques. The authors of this book tried to explain the role of echocardiography in several special pathologies, which the readers may find in different chapters of the book.

How to reference

In order to correctly reference this scholarly work, feel free to copy and paste the following:

Toru Maruyama, Yousuke Kokawa, Hisataka Nakamura, Mitsuhiro Fukata, Shioto Yasuda, Keita Odashiro and Koichi Akashi (2012). Pulmonary Venous Flow Pattern and Atrial Fibrillation: Fact and Controversy, Echocardiography - In Specific Diseases, Prof. Gani Bajraktari (Ed.), ISBN: 978-953-307-977-6, InTech, Available from: <http://www.intechopen.com/books/echocardiography-in-specific-diseases/pulmonary-venous-flow-pattern-and-atrial-fibrillation-fact-and-controversy>

INTECH
open science | open minds

InTech Europe

University Campus STeP Ri
Slavka Krautzeka 83/A
51000 Rijeka, Croatia
Phone: +385 (51) 770 447
Fax: +385 (51) 686 166
www.intechopen.com

InTech China

Unit 405, Office Block, Hotel Equatorial Shanghai
No.65, Yan An Road (West), Shanghai, 200040, China
中国上海市延安西路65号上海国际贵都大饭店办公楼405单元
Phone: +86-21-62489820
Fax: +86-21-62489821

© 2012 The Author(s). Licensee IntechOpen. This is an open access article distributed under the terms of the [Creative Commons Attribution 3.0 License](https://creativecommons.org/licenses/by/3.0/), which permits unrestricted use, distribution, and reproduction in any medium, provided the original work is properly cited.

IntechOpen

IntechOpen