

We are IntechOpen, the world's leading publisher of Open Access books Built by scientists, for scientists

6,900

Open access books available

185,000

International authors and editors

200M

Downloads

Our authors are among the

154

Countries delivered to

TOP 1%

most cited scientists

12.2%

Contributors from top 500 universities



WEB OF SCIENCE™

Selection of our books indexed in the Book Citation Index
in Web of Science™ Core Collection (BKCI)

Interested in publishing with us?
Contact book.department@intechopen.com

Numbers displayed above are based on latest data collected.
For more information visit www.intechopen.com



Role of Transthoracic Echocardiography in Visualization of the Coronary Arteries and Assessment of Coronary Flow Reserve

Yasser Baghdady, Hussein Hishmat and Heba Farook
Cairo University
Egypt

1. Introduction

Visualization of the epicardial coronary arteries by echocardiography is technically challenging. The physical nature of ultrasound waves prevents them from delineating the coronary tree because of multiple factors. The resolution of transthoracic echo using a 2.5-3.5MHz probe is only 2mm while the diameter of the epicardial coronary arteries ranges from 1.5 to 4mm. The epicardial coronaries are relatively superficial in the chest, so they lie in the near field of the ultrasound waves. The translational and rotational motion of the coronary arteries in the AV grooves poses a challenge in obtaining stable Doppler signals. The relatively low velocity of coronary flow compared to the flow velocity in the ventricles makes color signals hard to discern. Finally, the tomographic nature of the echocardiographic study makes differentiation between adjacent vessels e.g. the LAD and the diagonal branches extremely difficult. Despite these difficulties, the need for a non-invasive bedside tool that could allow inference of the coronary arteries pushed towards more efforts in using echo for that aspect. Using dedicated high-frequency probes made assessment of the left main coronary, the LAD and even the posterior descending branch of the RCA feasible in a large proportion of patients (Hozumi et al., 1998). Transthoracic and transesophageal echo can provide data regarding coronary patency, the presence of coronary stenosis or coronary ectasia (Iliceto S, et al., 1991, Kozakova M, et al., 1997, Lambertz et al., 2000).

2. Coronary flow and Doppler analysis

Normal antegrade coronary flow is predominant diastolic with a small systolic component (Heinz Lambertz et al., 2004). Systolic flow is less important and is a less stable measure as it can be even retrograde. It may be difficult to record both diastolic and systolic flow in the same cardiac cycle in all patients, because of cardiac motion that displaces the coronary artery from the ultrasound beam in systole. Diastolic flow is antegrade in both epicardial and intramural vessels, whereas systolic flow is antegrade in epicardial but retrograde in intramural vessels, because blood is squeezed backwards by myocardial contraction (Vernon Anderson H et al., 2000). As a result of the two opposite forces, the magnitude of systolic flow velocity may change along the coronary tree and close to the origin of a

perforator there might be a watershed area with stagnation of systolic flow. Therefore, the epicardial anterograde systolic flow is mainly a capacitance, rather than a nutrient flow, and may not reflect myocardial perfusion.

2.1 The parameters that can be assessed by coronary Doppler imaging include

- Diastolic flow velocity
- Systolic flow velocity
- Diastolic Deceleration time
- Coronary flow reserve

The baseline coronary flow velocity may change from one beat to the other of even 5–10 cm/s. Elevated resting flow velocities may occur in tachycardia, anaemia, hyperthyroidism, severe left ventricular hypertrophy etc (Czernin J et al, 1993, Voci P et al., 2004). Coronary vasodilators increase the diameter of the epicardial artery and reduce baseline flow velocity. Analysis of the coronary Doppler waveform can provide useful information about vessel patency and the presence of severe stenosis or moderate stenosis. Noninvasive Doppler has some alleged advantages over IVUS/FFR. Echocardiography avoids contact with the coronary artery, which may be reactive during myocardial infarction. Echo also measuring velocities in regions inaccessible to IVUS such as the septal perforators. The most important limitation of transthoracic Doppler measurement is the difficulty of obtaining accurate adjustment of the Doppler beam parallel to the coronary flow. If the angle between the Doppler beam and the coronary artery is $>60^\circ$, diastolic flow velocity could be underestimated.

3. Visualization of different coronary artery segments by Echo-Doppler

3.1 Transthoracic echocardiography

In general, assessment of coronary blood flow differs in different coronary arteries. The LAD blood flow can be assessed by using high frequency transducers due to the proximity of this vessel to the chest wall. However, this technique is not suitable for imaging peripheral RCA flow because of the distance between the transducer and the basal inferior cardiac wall (7–10cm). Therefore a lower frequency transducer is required to overcome the problem of inadequate penetration depth of a high frequency transducer. Individual coronary anatomy shows considerable patient to patient variability. Therefore it is not possible to visualize a segment of the right coronary artery in the posterior interventricular groove in every patient (Lethen H et al., 2003, Meimoun P et al., 2004, 2005, Tokai K et al., 2003, Ueno Y et al., 2002, 2003). Recording an accurate systolic-diastolic pulsed wave Doppler signal is often hampered by respiratory movements and lateral as well as vertical motion of the basal inferior cardiac wall during the cardiac cycle. This problem can partially be resolved by obtaining Doppler signals in apnea.

3.2 LMT and proximal segments of the left and right coronary arteries

The proximal portion of the left coronary artery can be visualized from a modified high parasternal short axis view. First obtain the classic parasternal short axis view at the level of

the aortic valve. Then make slight clockwise rotation and anterior tilt of the transducer to visualize the left main trunk as seen in the figure below.

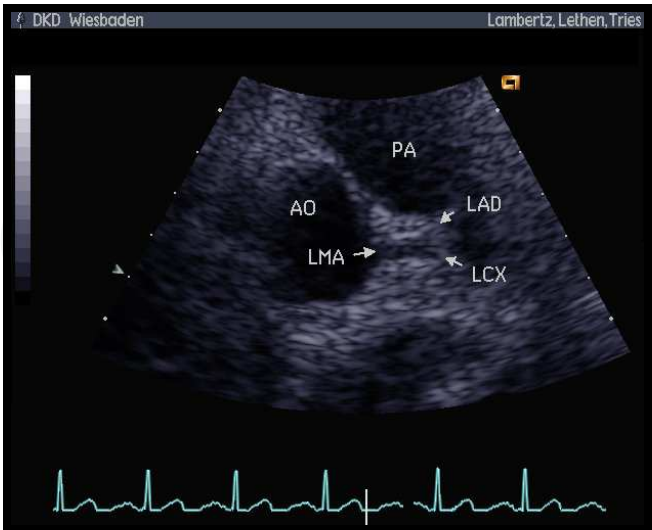

Fig. 1. Parasternal short axis view showing left main stem and its bifurcation into LAD and LCX branches (Heinz Lambertz et al., 2004).

Color Doppler imaging of the coronary flow in the proximal portion of the left coronary artery is technically difficult for two reasons: First, the almost orthogonal alignment of coronary flow to the ultrasound beam and second, the interposition of the right ventricular outflow tract and pulmonary artery. The left main coronary artery can also be imaged from an apical transducer position. From the classical five chamber view, the transducer is carefully angled more anteriorly until the ascending aorta is visualized. With slight tilting and rotation of the transducer, the left and the right coronary arteries can be recorded in one imaging plane: The orifice of the left coronary artery is located approximately three O'clock. The orifice of the RCA can be detected at approximately ten O'clock.

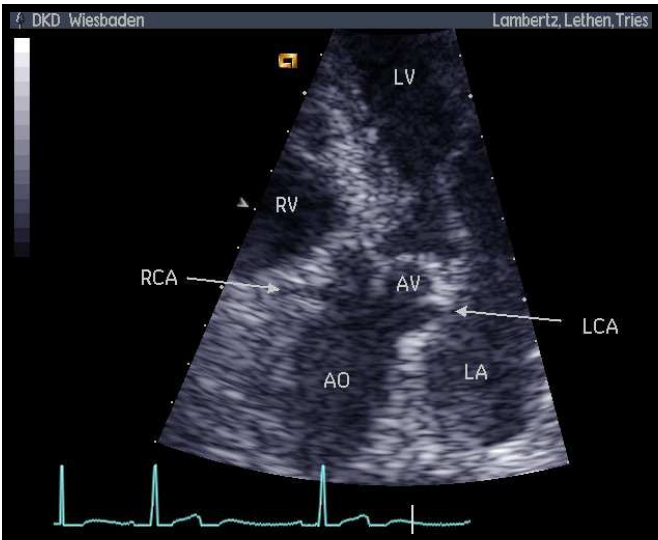


Fig. 2. Modified apical five-chamber view illustrating the origin of the left and right coronary artery from the aortic bulbus (Heinz Lambertz et al., 2004).

3.3 Visualization of the middle segment of the LAD

The middle and distal portion of the left anterior descending artery lies in the anterior ventricular groove close to the anterior chest wall. Due to the proximity of the middle and distal left anterior descending artery to a precordially located transducer, these coronary segments are ideal for transthoracic echocardiographic examination. From the classic parasternal short axis view at the level of the papillary muscles, a lateral displacement of the transducer by 2-3cm allows the visualization of the anterior interventricular groove. With caudal displacement of the transducer of 1-2 intercostal spaces, Color Doppler is used to identify the coronary flow in the anterior groove. Once a predominant diastolic flow signal is detected from a vessel within the anterior interventricular groove, activate the zoom mode while keeping the Doppler box small with adjustment of the velocity range at 12-24cm/s. From the previous view, the transducer is rotated 70 to 90° to obtain the best LAD long axis view. For measurement of the coronary flow velocity, pulsed wave Doppler is used with a sample size of 3mm and care should be taken to avoid an angle exceeding 35 to 45°.

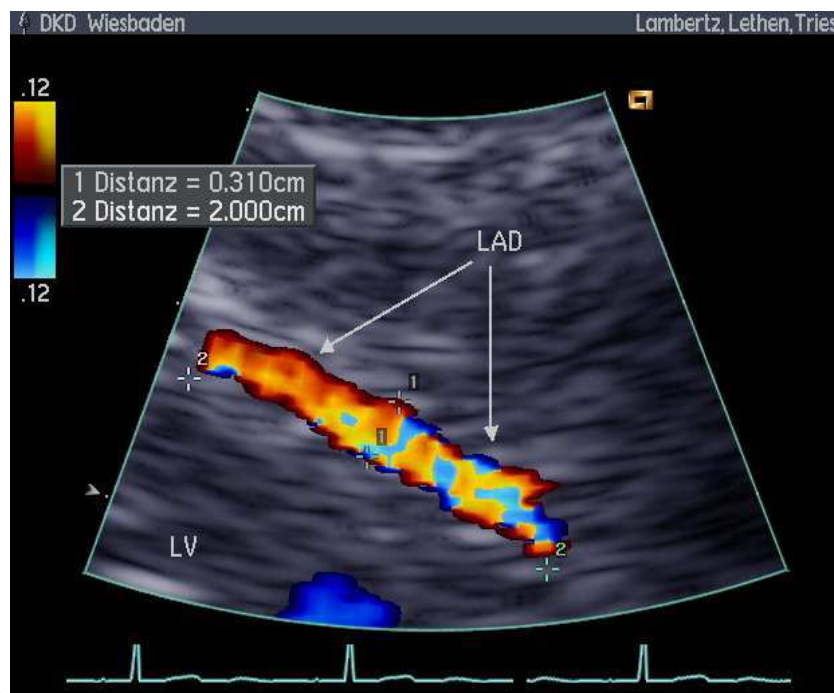


Fig. 3. Modified PLAX view allowing color Doppler assessment of coronary blood flow in the mid segment of the LAD (Heinz Lambertz et al., 2004).

3.4 Visualization of the distal segment of the LAD

The distal part of the left anterior descending artery can be recorded in a modified foreshortened three-chamber view from an apical window. From the conventional apical 2 chamber view the transducer is rotated anti-clockwise to obtain an apical long axis view, showing the left ventricle and left ventricular outflow tract. Using the color Doppler, the distal segment of the LAD, located in the apical part of the interventricular groove can be detected close to the apex of the left ventricle. From this view, the transducer is shifted 1 to 2 intercostal spaces cranially with anterior tilt to visualize the peripheral epicardial segments of the LAD.

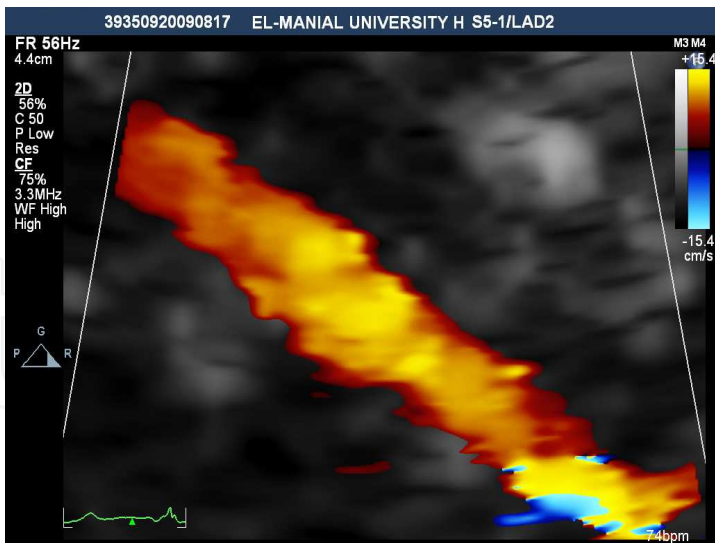


Fig. 4. Modified apical view showing the distal segment of the LAD (H. Farouk, et al., 2010).

3.5 Visualization of the RCA

To visualize the posterior descending branch of the RCA, the left ventricle is first imaged in a conventional apical two-chamber view. From this position, the transducer is slightly rotated anti-clockwise and carefully tilted anteriorly. Using color Doppler, coronary blood flow in the posterior interventricular groove can be identified.

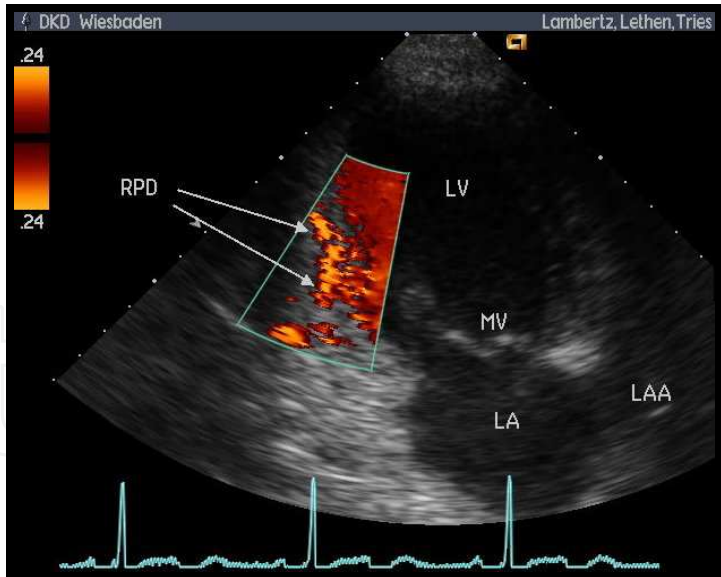


Fig. 5. Modified apical two-chamber view. Color Doppler flow map showing the proximal part of the posterior interventricular branch in the posterior interventricular groove (Heinz Lambertz et al., 2004).

After detection of the characteristic predominant diastolic blood flow in the basal part of the posterior interventricular groove, the sample volume (2.0-3.5mm) is positioned for spectral Doppler analysis of coronary blood flow.

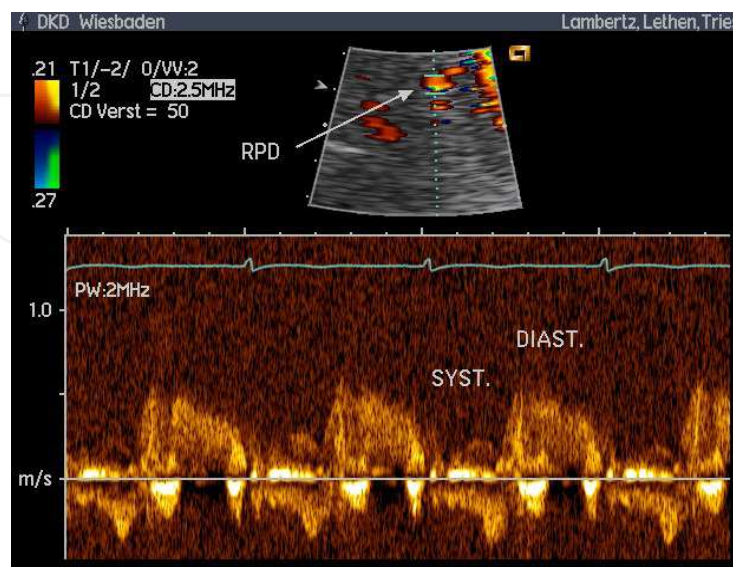


Fig. 6. Characteristic biphasic spectral Doppler recording of coronary blood flow velocity in the distal RCA (Heinz Lambertz et al., 2004).

The modified apical two-chamber view used for assessment of the right coronary artery blood flow allows alignment of the ultrasound beam roughly parallel to the course of the posterior descending artery, thus, unlike assessment of the flow of the left anterior descending artery, provide an adequate registration of the coronary flow velocity.

3.6 Detection of the left circumflex artery by TTE

The proximal third of the LCX can be examined using an apical or parasternal short axis view approach. To assess the distal left circumflex artery, we use the apical 5 chamber view with the transducer is rotated clockwise to direct the imaging plane posteriorly and inferiorly. The direction of the CBF of the circumflex artery is not parallel to the ultrasound beam. Because the success rate in visualizing the flow in the mid and distal circumflex is limited, assessment of the coronary flow reserve is of limited clinical significance in cases of suspected left circumflex artery disease (Heinz Lambertz et al., 2004)

3.7 Detection of the left internal mammary artery

The proximal mammary artery is best visualized from a supraclavicular view using high frequency transducer (8 MHz linear transducer). A patent mammary artery graft is recognized by its typical baseline spectral Doppler flow profile, showing considerably higher diastolic blood flow velocity compared to the other vessels originating in close proximity to the subclavian artery.

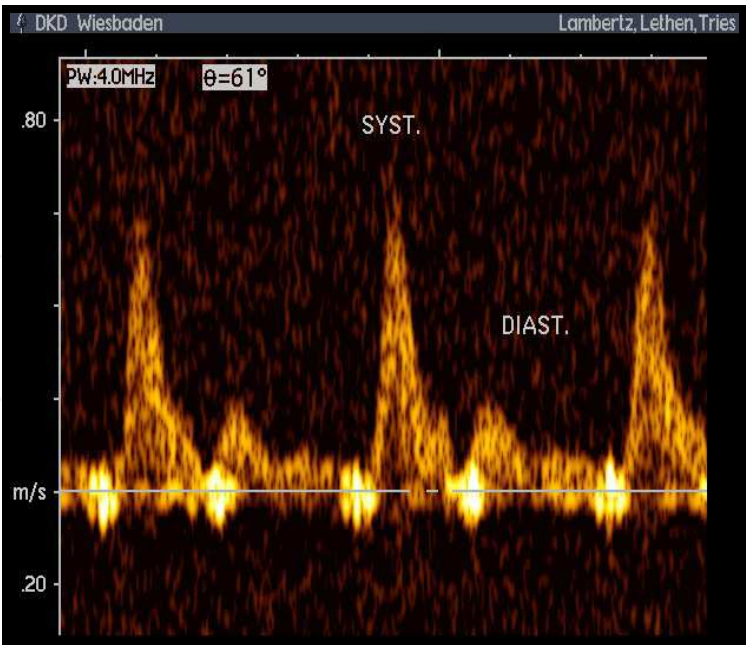


Fig. 7. Pulsed wave Doppler profile of mammary artery. The systolic flow velocity is typically higher than the diastolic (Heinz Lambertz et al., 2004).

3.8 Detection of the septal branches of the LAD by TTE

In immediate proximity of the mid and distal portion of the left anterior descending artery, septal side branches with varying caliber can be seen by color Doppler analysis. Frequently, the vessel course can be followed over a longer distance within the ventricular septum. Diagonal branches or a dominant intermediate branch can't always be clearly differentiated from the left anterior descending artery, as they may have approximately the same diameter and an almost parallel course.

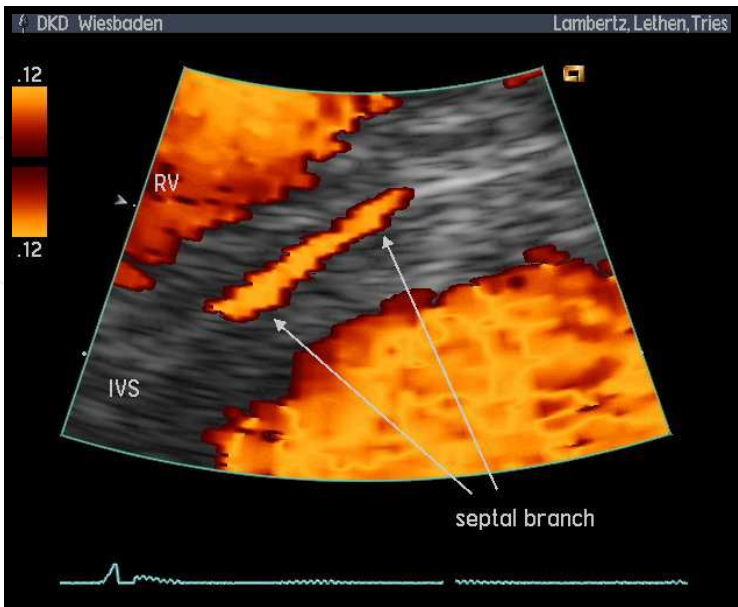


Fig. 8. Parasternal short axis view illustrating a perforator branch in the mid septum (Heinz Lambertz et al., 2004).

3.9 Transesophageal echocardiography

The best way to image the proximal segment of the coronary artery is a transesophageal short axis view at the level of the aortic bulb with a slight anteflexion of the probe. From this view the left main stem and the proximal LAD can be visualized in about 70 to 90% of patients. The success rate in imaging the proximal segment of the left circumflex is even higher (75 to 90%). The best way to visualize the ostium of the right coronary artery is a sagittal scanning plane showing the ascending aorta in a long axis (Lambertz H et al., 2000). With a slight clockwise rotation of the probe, a short segment of the right coronary artery originating from the aortic bulb can be imaged from the majority of patients.

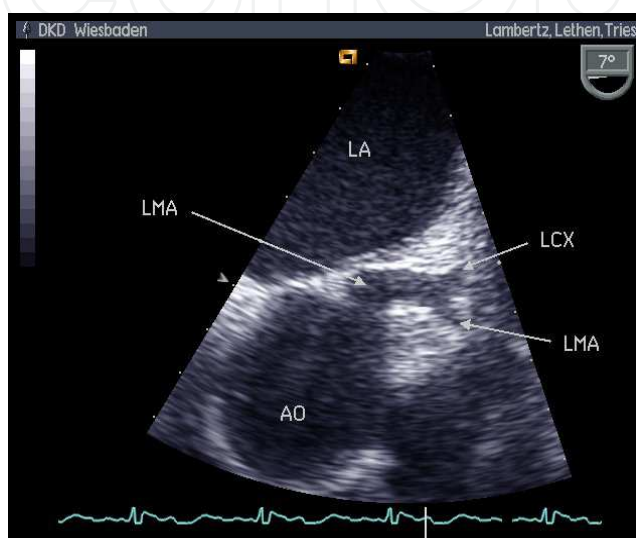


Fig. 9. Transesophageal echocardiography illustrating the left main stem and its bifurcation into LAD and LCX ((Heinz Lambertz et al., 2004).

With a pulsed wave Doppler, sample volume positioned in the proximal portion of the left anterior descending coronary artery, systolic as well as diastolic flow can be recorded (Illiceto S, et al. , 1991)

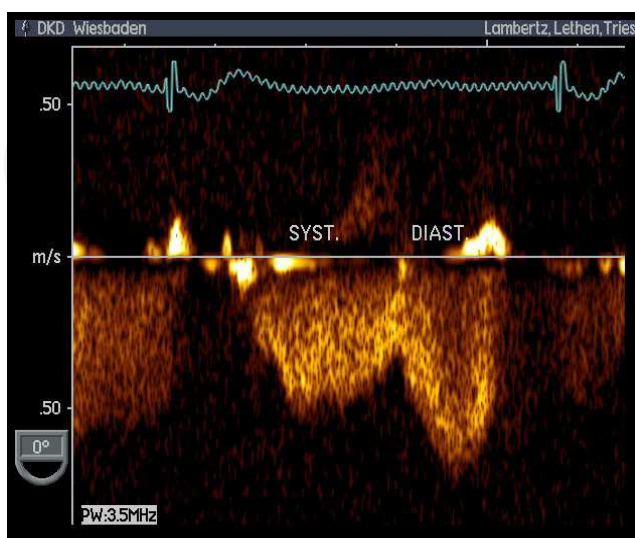


Fig. 10. TEE recording from a normal LAD.CBF occurs systolic-diastolic with the highest velocity during diastole (Heinz Lambertz et al., 2004).

In contrast to the transthoracic approach, TEE imaging allows a reliable Doppler flow analysis in the proximal left anterior descending artery, because the ultrasound beam can be aligned almost parallel to the anatomical course of the vessel. However, due to motion artifacts caused by respiratory excursions and ventricular contraction, adequate recording of the coronary blood flow can be obtained more easily during a short period of apnea.

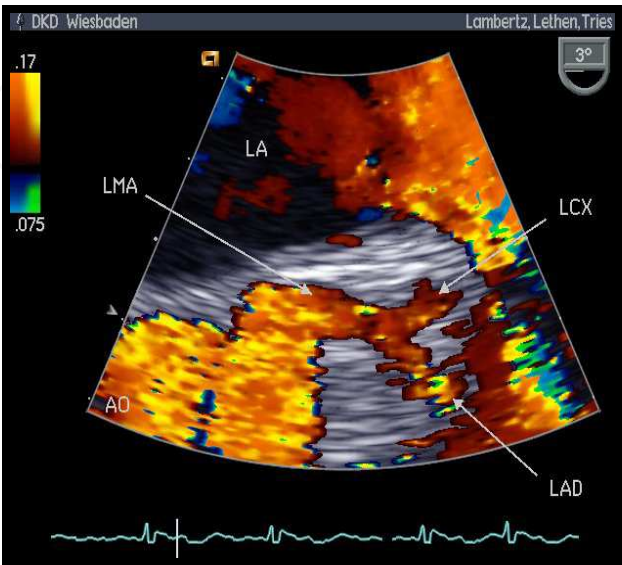


Fig. 11. Color Doppler illustrating normal coronary blood flow within the left main artery and its bifurcation into LAD and LCX (Heinz Lambertz et al., 2004).

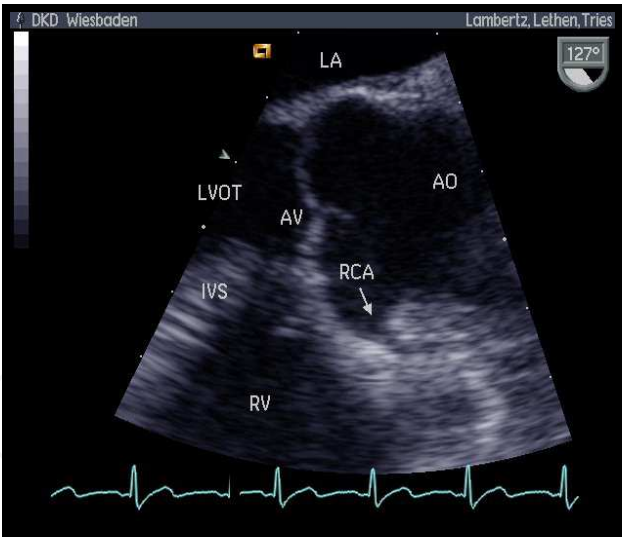


Fig. 12. Orifice of the right coronary artery. The TEE scanning plane is aligned roughly parallel to a long axis of the ascending aorta ((Heinz Lambertz et al., 2004)

Transesophageal echocardiography, with or without contrast, is a low cost method and easily repeatable, which can be used to evaluate coronary circulation in selected patients. However, this approach has less clinical importance in evaluating the hemodynamic relevance of a left anterior descending artery stenosis. This is based on the fact that most of the left anterior descending artery stenoses are located distal to those left anterior descending artery segments that can be visualized by Transesophageal echocardiography.

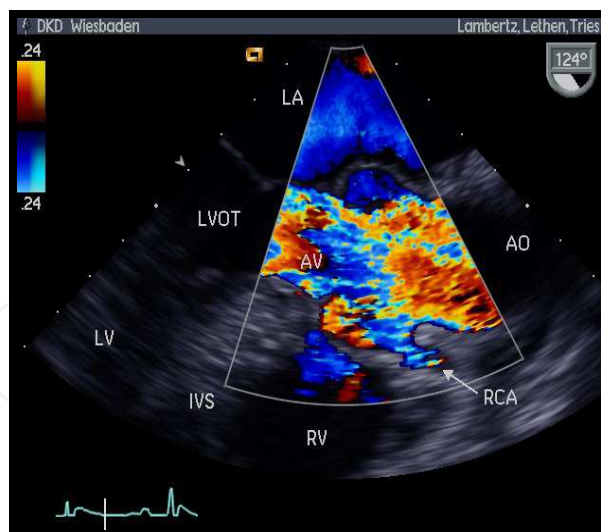


Fig. 13. Visualization of the coronary blood flow in the proximal right coronary artery (Heinz Lambertz et al., 2004).

It has to be taken also into consideration that approximately 20% to 30% of the patients cannot be investigated by Doppler because of respiration, obesity, chest deformity and emphysema, acute changes in cardiac volume, or inadequately stable position of the Doppler signal. Flow in the branches could be erroneously interpreted as the flow in the main trunk. In particular, this could happen for LAD in the two-chamber or in the short axis view, where a long diagonal branch or the first septal perforator might also be visualized.

4. Clinical utilization of echocardiographic coronary imaging

4.1 Coronary artery patency

In the particular situation of acute myocardial infarction, a non-invasive way to visualize the LAD should be of great help to diagnose the success of reperfusion. In this setting, the sensitivity, specificity, positive predictive value, negative predictive value and accuracy of the transthoracic echo Doppler in the noninvasive assessment of the LAD reperfusion with 2.5MHz transducer were 81.6%, 64%, 90.7%, 54% and 78% respectively (H. Farouk et al., 2010). Detection of the distal LAD flow by TTDE was significantly correlated with the reperfusion as assessed by coronary angiography.

Epicardial coronary flow is not always synonymous with cellular myocardial perfusion as seen in the no-reflow phenomenon. Visualization of septal perforator flow can be a more reliable marker of reperfusion. Voci et al (Voci P et al., 2004) considered a myocardial segment to be reperfused when at least two of the predicted four to five perforators could be visualized by transthoracic echo after acute MI. A recanalization score (RS) of 1 to 4 was used – where 1 = LAD closed, no perforators; 2 = LAD open, no perforators; 3 = LAD open, 1 to 2 segments with perforators; 4 = LAD open, 3 to 4 segments with perforators. RS discriminated recovery of ventricular function better than TIMI flow. The RS was the best single multivariate predictor ($p < 0.0001$) of percent changes in wall motion score index and the ejection fraction.

Antti Saraste et al, (Saraste M et al., 2005) found that diastolic deceleration time of the LAD flow velocity correlated with myocardial fluorodeoxyglucose uptake in the LAD territory.

Diastolic deceleration time was markedly longer in patients with viable myocardium than partially viable or non-viable myocardium. A DDT <190ms is always associated with non-viable myocardium. However, this finding was not consistent among different studies.

4.2 Coronary artery occlusion

Coronary flow can be measured by transthoracic coronary Doppler ultrasound in occluded coronary arteries receiving collateral flow. Reverse diastolic flow at rest, reflecting retrograde filling of the artery by collaterals, is a very specific marker of coronary occlusion but it unfortunately has a low sensitivity, since collaterals may perfuse the vessel either retrogradely or anterogradely.

4.3 Severe coronary stenosis

Coronary artery stenosis could be identified with color Doppler as local spot of turbulence. An abnormal maximal-to-prestenotic blood flow velocity ratio greater than 2.0 would signify a critical stenosis. These findings have an overall sensitivity of 82% and specificity of 92%. The sensitivity and specificity were, respectively, 73% and 92% for left anterior descending coronary artery, 63% and 96% for right coronary artery, and 38% and 99% for left circumflex coronary artery stenoses. For left main coronary stenosis, echo showed a 92% sensitivity and 62% specificity to identify IVUS significant (MLA < 6 mm²) left main stenosis if taking a peak diastolic velocity cut off of 112 cm/sec (Gerken U, et al., 1989, Samdarshi TE et al., 1990)

4.4 Moderate coronary stenosis

The assessment of moderate-severity coronary stenosis by angiography has limitations related to the "lumenographic" nature of angiography (Topol EJ, et al., 1995). The concept of coronary flow reserve performed by Doppler intracoronary wire during coronary angiography can be also performed by echocardiography. The major advantages of coronary flow assessment by TTDE are that it is completely non-invasive, relatively inexpensive, and gives objective and accurate information on the physiological significance both in epicardial native coronary stenosis as well as in detecting coronary restenosis following coronary percutaneous interventions (Caiati C et al., 1999, 1999, Hozumi T et al., 1998). Another important value of TTDE study of CFVR is the assessment of microvascular coronary circulation.

4.5 Coronary flow reserve

Coronary flow reserve is defined as the maximal increase in coronary blood flow (by using a strong coronary vasodilator) above its basal level for a given perfusion pressure. So, it is a ratio of maximal (stimulated) to baseline (resting) coronary blood flow. The best sampling site of the coronary flow, for assessing the functional significance of a stenosis, is the distal tract of the vessel which could be easily obtained with TDE. Proximal to the stenosis CFR may be normal as there are side branches between the sampling site and the stenosis, which reflects perfusion in normal territories (Voci P et al., 2004). The angle correction is redundant given that CFR is the ratio between hyperemic and baseline flow velocity, and it is not affected by the actual flow velocity. However, the angle has to be kept as small as possible. Blood flow velocity measurements are performed offline by contouring the spectral Doppler signals, using the integrated software package of the ultrasound system. Final values of flow velocity represent

an average of three cardiac cycles. TDE-CFR is defined as hyperemic diastolic mean (or peak) flow velocity divided by baseline flow velocity. It is important to underscore that during administration of the vasodilating agent, the transducer probe is in the same position as baseline, and machine settings including size of sample volume and velocity scale are not changed. The mean time required to complete a CFR test is around 10–15 min.

Adenosine is the most commonly used vasodilator to assess TDE-CFR. It is a potent vasodilator producing maximal coronary vasodilatation within 40–50 seconds. Given its short half life (10s) and rapid onset of action, it allows CFR measurements more rapidly than other vasodilators. Furthermore, Adenosine acts mainly at the level of the microcirculation and does not alter significantly the diameter of the coronary artery. Adenosine is administered intravenously (0.140 mg/kg/min) for 5 minutes (Lapeyre AC III et al., 2004, Sudhir K et al., 1993, Verani MS, 1991, Wilson R et al., 1990). The normal range of CFVR for both men and women is ≥ 2.7 . The cut-off value of 2 of CFR for detecting significant epicardial coronary stenosis or to predict ischemia in the underlying territory has been demonstrated in various studies (Kern MJ et al., 1996, Matsumura Y et al., 2003).

The feasibility of TDE-CFR for LAD artery is very high, with more than 90% in experienced hands, and nearly 100% with the use of intravenous contrast agents (Caiati C et al., 1999). The feasibility is less in the PDA artery, between 54 and 86% due to technical limitations (Hozumi T et al., 1998, Lethen H et al., 2003, Ueno Y et al., 2002). The measurements of TDE-CFR, in the LAD as in the PDA arteries, are closely correlated with invasive measurements using a Doppler flow wire. The feasibility of TDE-CFR in the circumflex artery is more challenging given the particular anatomy of this artery and the poor resolution of the lateral wall.

4.6 Kawasaki disease and congenital coronary anomalies

In the pediatric population, visualization of the proximal portions of the left and the right coronaries by transthoracic echo is achievable in almost all cases. Therefore, it is routine to comment on the origin and the course of the proximal left and right coronary arteries in all pediatric studies. The aneurysms of the proximal RCA and proximal LAD in Kawasaki disease provide the diagnosis in infants with febrile illness and the classic rash and can be useful in follow up of this condition (Satomi G et al., 1984, Yoshikawa J et al., 1979). Also, failure of visualization of one of the coronary arteries in children with cardiomyopathy should prompt excluding the diagnosis of anomalous origin of the coronary from the pulmonary artery. Also anomalous origin of the right coronary from the left sinus of valsalva which poses a threat of sudden cardiac death can be readily diagnosed in children by transthoracic echo.

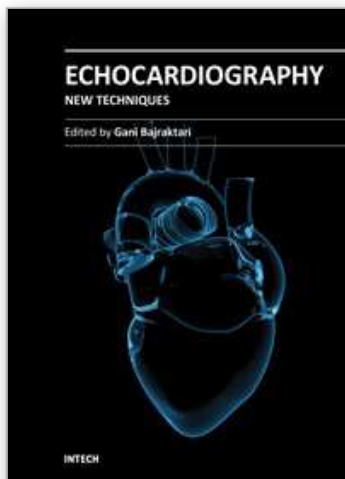
5. Conclusion

Echocardiography can be used to visualize the epicardial coronary arteries directly in a large proportion of patients. The success is greatest in children, ostia of the left and right coronary arteries and in the LAD. However, it is unlikely, at least in the near future, that echo can provide complete anatomical assessment of the coronary tree. X-ray bases modalities, namely angiography and CT are still superior in providing anatomical details. Nevertheless, in some clinical situations, echo can provide very useful data regarding coronary patency, severe stenosis, moderate coronary lesions, the state of the microcirculation and congenital coronary anomalies.

6. References

- Caiati C, Montaldo C, Zedda N, Bina A, Iliceto S. A new noninvasive method for coronary flow reserve assessment: contrast-enhanced transthoracic second harmonic echo Doppler. *Circulation* 1999; 99: 771-778.
- Caiati C, Montaldo C, Zedda N, Montisci R, Ruscazio M, Lai G et al. Validation of a non-invasive method (contrast enhanced transthoracic second harmonic echo Doppler) for the evaluation of coronary flow reserve: comparison with intracoronary Doppler flow wire. *J Am Coll Cardiol* 1999;34:1193 - 200.
- Caiati C, Zedda N, Montaldo C, Montisci R, Iliceto S. Contrast-enhanced transthoracic second harmonic echoDoppler with adenosine. A noninvasive, rapid and effective method for coronary flow reserve assessment. *JACC* 1999; 34:122-130
- Czernin J, Muller P, Chan S, Brunken RC, Porenta G, Krivokapitch J et al. Influence of age and hemodynamics on myocardial blood flow and flow reserve. *Circulation* 1993;88:62 - 9.
- Gerken U, et al. detection of proximal coronary artery stenosis by transesophageal echocardiography. *Eur Heart J*. 1989; 10:121
- Heba F. Saleh, Hussien Heshmat, Y.Baghdady, K. Sorour. Faculty of medicine, Cairo University.
- Heinz Lambertz, Hans-Peter Tries, Harald Lethen. Coronary flow reserve: a practical echocardiographic approach. Second edition. 2004.
- Hozumi T, Yoshida K, Akasaka T et al. Noninvasive assessment of coronary flow velocity and coronary flow velocity reserve in the left anterior descending coronary artery by Doppler echocardiography: comparison with invasive technique. *J Am Coll Cardiol* 1998; 32: 1251-1259.
- Hozumi T, Yoshida K, Akasaka T et al. Noninvasive assessment of coronary flow velocity and coronary flow velocity reserve in the left anterior descending coronary artery by Doppler echocardiography: comparison with invasive technique. *J Am Coll Cardiol* 1998; 32: 1251-1259.
- Iliceto S. Transesophageal Doppler echocardiography evaluation of coronary flow velocity in baseline conditions and during dipyridamole-induced coronary vasodilation. *Circulation* 83:61-69, 1991.
- Kern MJ, Bach RG, Mechem CJ, et al. Variations in normal coronary vasodilatory reserve stratified by artery, gender, heart transplantation and coronary artery disease. *J Am Coll Cardiol*. 1996;28:1154-1160.
- Kozakova M. Mechanisms of coronary flow impairments in human hypertension. *Hypertension* 29:551-559, 1997.
- Lambertz H, Lethen H. *Lehratlas der transösophagealen Echokardiographie*, 2000; Thieme Verlag Stuttgart, New York 1-273.
- Lapeyre AC III, Goraya TY, Johnston DL, Gibbons RJ. The impact of caffeine on vasodilator stress perfusion studies. *J Nucl Cardiol*. 2004;11:506-511.
- Lethen H, Tries HP, Kersting S, Lambertz H. Validation of noninvasive assessment of coronary flow velocity reserve in the right coronary artery: a comparison of transthoracic echocardiographic results with intracoronary Doppler flow wire measurements. *Eur Heart J* 2003;24:1567 - 75.
- Matsumara Y, Hozumi T, Watanabe H, Fujimoto K, Sugioka K, Takemoto Y et al. Cut-off value of coronary flow velocity reserve by transthoracic Doppler echocardiography for diagnosis of significant left anterior descending artery stenosis in patients with coronary risk factors. *Am J Cardiol* 2003;92:1389 - 93.

- Meimoun P, Benali T, Sayah S, Luycx-Bore A, Boulanger J, Zemir H et al. Evaluation of left anterior descending coronary artery stenosis of intermediate severity using transthoracic coronary flow reserve and dobutamine stress echocardiography. *J Am Soc Echocardiogr* 2005;12:1233 – 40.
- Meimoun P, Sayah S, Maitre B, Luycx-Bore A, Benali T, Beausoleil M et al. Measurement of coronary flow reserve with transthoracic echocardiography: an old concept, a new tool, a lot of applications. *Ann Cardiol Angiol* 2004;53:325 – 34.
- Samdarshi TE et al. Transesophageal color Doppler echocardiography in assessing proximal coronary artery stenosis. *J Am Coll Cardiol*. 1990; 15:93
- Saraste M, Vesalainen RK, Ylitalo A, Saraste A, Koskenvuo JW, Toikka JO, Vaittinen MA, Hartiala JJ, Airaksinen KE: Transthoracic Doppler echocardiography as a noninvasive tool to assess coronary artery stenoses-a comparison with quantitative coronary angiography. *J Am Soc Echocardiogr* 2005, 18:679-85.
- Satomi G, Nakamura K, Narai S, et al. Systematic visualization of coronary arteries by two-dimensional echocardiography in children and infants: evaluation in Kawasaki's disease and coronary arteriovenous fistulas. *Am Heart J* 107:497-505, 1984.
- Sudhir K, MacGregor JS, Barbant SD, Foster E, Fitzgerald PJ, Chatterjee K et al. Assessment of coronary conductance and resistance vessel reactivity in response to nitroglycerin, ergonovine, and adenosine: in vivo studies with simultaneous intravascular two-dimensional and Doppler ultrasound. *J Am Coll Cardiol* 1993;21:1261 – 8.
- Tokai K, Watanabe H, Hirata K, Otsuka R, Muro T, Yamagishi H et al. Noninvasive assessment of myocardial ischemia in the left ventricular inferior regions by coronary flow reserve measurement using transthoracic Doppler echocardiography. *J Am Soc Echocardiogr* 2003;16:1252 – 7.
- Topol EJ, Nissen SE. Our preoccupation with coronary luminology. The dissociation between clinical and angiographic findings in ischemic heart disease. *Circulation* 1995; 92: 2333-2342.
- Ueno Y, Nakamura Y, Kinoshita M, Fujita T, Sakamoto T, Okamura H. Noninvasive assessment of significant right coronary artery stenosis based on coronary flow velocity reserve in the right coronary artery by transthoracic Doppler echocardiography. *Echocardiography* 2003;20:495 – 501.
- Ueno Y, Nakamura Y, Takashima H, Kinoshita M, Soma A. Noninvasive assessment of coronary flow velocity and coronary flow velocity reserve in the right coronary artery by transthoracic Doppler echocardiography: comparison with intracoronary Doppler guidewire. *J Am Soc Echocardiogr* 2002;15:1074 – 9.
- Verani MS. Adenosine thallium-201 myocardial perfusion scintigraphy. *Am Heart J*. 1991;122:269-278.
- Vernon Anderson H, Stockes MJ, Leon M, Abu-Hawala SA, Stuart Y, Kireeide RL. Coronary artery flow velocity is related to lumen area and regional left ventricular mass. *Circulation* 2000;102:48 – 54.89.
- Voci P, Pizzuto F, Romeo F. Coronary flow: a new asset for the echo lab? *Eur Heart J* 2004;25:1867-79.
- Wilson R, Wyche K, Christensen BV, Zimmer S, Laxson DD. Effects of adenosine on human coronary arterial circulation. *Circulation* 1990;82: 1595 – 606.
- Yoshikawa J, Yanagihara K, Owaki T, et al. Cross-sectional echocardiographic diagnosis of coronary artery aneurysms in patients with mucocutaneous lymph node syndrome. *Circulation* 59:133-9, 1979.



Echocardiography - New Techniques

Edited by Prof. Gani Bajraktari

ISBN 978-953-307-762-8

Hard cover, 218 pages

Publisher InTech

Published online 18, January, 2012

Published in print edition January, 2012

The book "Echocardiography - New Techniques" brings worldwide contributions from highly acclaimed clinical and imaging science investigators, and representatives from academic medical centers. Each chapter is designed and written to be accessible to those with a basic knowledge of echocardiography. Additionally, the chapters are meant to be stimulating and educational to the experts and investigators in the field of echocardiography. This book is aimed primarily at cardiology fellows on their basic echocardiography rotation, fellows in general internal medicine, radiology and emergency medicine, and experts in the arena of echocardiography. Over the last few decades, the rate of technological advancements has developed dramatically, resulting in new techniques and improved echocardiographic imaging. The authors of this book focused on presenting the most advanced techniques useful in today's research and in daily clinical practice. These advanced techniques are utilized in the detection of different cardiac pathologies in patients, in contributing to their clinical decision, as well as follow-up and outcome predictions. In addition to the advanced techniques covered, this book expounds upon several special pathologies with respect to the functions of echocardiography.

How to reference

In order to correctly reference this scholarly work, feel free to copy and paste the following:

Yasser Baghdady, Hussein Hishmat and Heba Farook (2012). Role of Transthoracic Echocardiography in Visualization of the Coronary Arteries and Assessment of Coronary Flow Reserve, Echocardiography - New Techniques, Prof. Gani Bajraktari (Ed.), ISBN: 978-953-307-762-8, InTech, Available from: <http://www.intechopen.com/books/echocardiography-new-techniques/role-of-transthoracic-echocardiography-in-visualization-of-the-coronary-arteries-and-assessment-of-c>

INTech
open science | open minds

InTech Europe

University Campus STeP Ri
Slavka Krautzeka 83/A
51000 Rijeka, Croatia
Phone: +385 (51) 770 447
Fax: +385 (51) 686 166
www.intechopen.com

InTech China

Unit 405, Office Block, Hotel Equatorial Shanghai
No.65, Yan An Road (West), Shanghai, 200040, China
中国上海市延安西路65号上海国际贵都大饭店办公楼405单元
Phone: +86-21-62489820
Fax: +86-21-62489821

© 2012 The Author(s). Licensee IntechOpen. This is an open access article distributed under the terms of the [Creative Commons Attribution 3.0 License](https://creativecommons.org/licenses/by/3.0/), which permits unrestricted use, distribution, and reproduction in any medium, provided the original work is properly cited.

IntechOpen

IntechOpen