

# We are IntechOpen, the world's leading publisher of Open Access books Built by scientists, for scientists

6,900

Open access books available

186,000

International authors and editors

200M

Downloads

Our authors are among the

154

Countries delivered to

TOP 1%

most cited scientists

12.2%

Contributors from top 500 universities



WEB OF SCIENCE™

Selection of our books indexed in the Book Citation Index  
in Web of Science™ Core Collection (BKCI)

Interested in publishing with us?  
Contact [book.department@intechopen.com](mailto:book.department@intechopen.com)

Numbers displayed above are based on latest data collected.  
For more information visit [www.intechopen.com](http://www.intechopen.com)



# Pamidronate Treatment in Charcot Neuro-Osteoarthropathy: Change in Biochemical Markers of Bone Turnover and Radiographic Outcome After Treatment

Ivonne Vázquez, Mireia Moreno and Marta Larrosa  
*Hospital of Sabadell, Corporació Sanitària i Universitària Parc Taulí (UAB),  
 Rheumatology Service  
 Spain*

## 1. Introduction

Charcot neuro-osteoarthropathy (CNO) is a disabling, rapidly progressive destructive arthropathy and a devastating condition in patients with sensitive neuropathy secondary to different diseases such as diabetes mellitus, syringomyelia, polyomyelitis, multiple sclerosis or leprosy (Storey, 2004). Diabetes is nowadays the most common cause of neuroarthropathy, with the joints of foot being most frequently affected (Shae & Boulton, 1995). The reported incidence and prevalence of CNO varies between 0,1-0,4% of diabetic population, but the real prevalence of CNO in patients with diabetes mellitus is unknown because many cases are undiagnosed due to a lack of recognition of the clinical symptoms of acute presentation (Bailer & Root, 1947; Fabrin et al., 2000; Klenerman, 1996; Rajbhandari et al., 2002; Sinha et al., 1972). Both type 1 and type 2 diabetic patients are at risk. The majority of patients with CNO are between the fifth and sixth decades although type 1 diabetes present CNO at a younger age and most patients have had diabetes for at least 10 years (Clouse et al., 1974; Cofield et al., 1983; Petrova et al., 2004). Bilateral involvement has been described in up to 30% of patients with CNO affecting the feet (Shae & Boulton, 1995). The basic physiopathologic mechanism of CNO is poorly understood although repetitive trauma and autonomic nervous dysfunction are probably implicated (the neurotraumatic and neurovascular theories). Probably there is a triggering factor including trauma or infection which triggers the onset of an inflammatory cascade which leads to an increased osteoclastic activity in some predisposed patients.

Although there is no clear evidence, the RANK/RANKL/OPG system may play an important role in the osteolysis seen in the acute CNO. The initial trigger leads to a production of proinflammatory cytokines, including tumor necrosis factor alpha (TNF $\alpha$ ) and interleukin-1 $\beta$ (IL-1 $\beta$ ). The expression of these cytokines could increase the expression of receptor activator of nuclear factor- $\kappa$ B (RANKL), the ligand of receptor activator of NF- $\kappa$ B (RANK), that when activated, stimulates the production of nuclear transcription factor NF- $\kappa$ B (NF- $\kappa$ B). When NF- $\kappa$ B is expressed in osteoclast precursors cells, it leads to their differentiation to mature osteoclasts and, in consequence, bone resorption (Jeffcoate et al.,

2005; Jeffcoate, 2008; Molines et al., 2010). In this sense, Mabillean et al. studied isolated peripheral blood monocytes from diabetic Charcot patients, diabetic controls and healthy controls and demonstrated that resorption in acute CNO is related to an increase in RANKL-mediated osteoclastic activity (Mabillean et al., 2008).

The usual initial presentation of acute CNO is a swelling, tender and warm involved joint and there is usually a temperature difference greater than 2°C when compared with the contralateral joint (Jude & Boulton, 2001; Petrova & Edmonds, 2008). The whole clinical picture can simulate an infection in its appearance. The chronic CNO is painless, without a temperature difference and characterized by established deformity.

The aim of this chapter is to review the usefulness of biochemical bone markers and the image features for both diagnosis and for follow-up after treatment of CNO with bisphosphonates (pamidronate).

2. Imaging and biochemical markers of turnover in diagnosis of Charcot neuro-osteoarthropathy

Although the diagnostic is based on clinical findings, conventional radiography, radionuclide scintigraphy and magnetic resonance imaging (MRI) are the more common modalities used for helping to the diagnosis of CNO.

2.1 Plain radiography

X-plain radiographs are usually the first exam used and they are useful for anatomical information. However they are neither sensitive nor specific to differentiate acute CNO changes from osteomyelitis.

In early stages, the presence of effusion with minimal subluxation and fracture-bone fragmentation should alert to the physician to the possibility of CNO. These initial changes may progress to collapse, resorption and subchondral bone fragmentation, bone proliferation with sclerosis and osteophytosis, intra-articular bone fragments, complete subluxation, massive soft tissue enlargement and effusion and fracture of neighboring bones (Resnick & Niwayama).

The Eichenholtz classification (Eichenholtz, 1966) modified by Shibata et al. (Shibata et al., 1990) describe a correlation between clinical findings and radiographic features (table 1).

Stage 0	early phase	acute symptoms	no changes
Stage 1	development stage	acute symptoms	osteopenia, bone destruction, debris formation, fragmentation of the subchondral bone , capsular distention, subluxations ,dislocations
Stage 2	coalescence stage	decreased symptoms	resorption of debris, bony sclerosis , fusion of bone fragments
Stage 3	reconstruction stage	resolved	bony remodeling, rounding of fragments

Table 1. Eichenholtz classification modified by Shibata.

Medical literature focused on radiology findings describe two patterns of CNO: a hypertrophic pattern characterized by joint destruction and bone fragmentation, debris formation, sclerosis and osteophytosis, such as osteoarthritis and an atrophic pattern showing osseous resorption and joint disorganization that may appear similar to septic arthritis, so, differential diagnosis between atrophic CNO and septic arthritis may be difficult. Frequently, patients present a combination of hypertrophic and atrophic patterns (Aliadabi et al., 2003; Jones et al., 2000).

In the diabetic population, destructive or resorptive bony abnormalities can predominate depending on the location of CNO. At the mid-foot or tarsometatarsal joints (Lisfranc) [the most common localization representing about 60% (Brodsky)], bone fragmentation, sclerosis with fracture-dislocation and complete disintegration of one or more tarsal bone are frequently found. This may lead to a collapse of the longitudinal arch and increased load bearing on the cuboid, resulting in a “rocker-bottom” deformity. If the metatarsophalangeal joints are affected, bone resorption is the predominant feature, leading to a disappearance, partial or complete, of the metatarsal heads and proximal phalanges. Finally, the hindfoot and ankle, although less frequent, it may be affected with fragmentation, eburnation and dislocation of the affected bones.

In summary, the five D’s describe the radiological features of CNO: joint distension, dislocations, debris, disorganization and increased density (Rajbhandari et al., 2002), being the presence of multiples fractures the most suggestive radiologic pattern of CNO.

## 2.2 Radionuclide scintigraphy

Three imaging phases <sup>99</sup>Technetium bone scan (<sup>99</sup>Tc-scan) are highly sensitive (91%) for osseous pathology but lacks specificity (54%) for the diagnosis of CNO (Aliadabi et al., 2003; Sella, 2009; Schauwecker et al., 1988). The scintigraphy is positive in all 3 phases, reflecting an increased bone turnover, a similar situation to that found in other conditions such as osteomyelitis. In these cases, in order to improve the specificity of the test to rule out infection the labeled white cell scans (<sup>99</sup>Tc-WBC, HMPAO, <sup>111</sup>In-WBC) can be used. These scintigraphy techniques show increased activity at the site of infection, reaching a specificity of 60-86% depending on the studies and on the radiotracer used to label white cells (Sella, 2009).

A fourth phase or 24-hour phase image <sup>99</sup>Tc-scan can be used to improve the localization of the affected site when there is too much background activity.

The <sup>67</sup>Ga/bone imaging study is not reliable for diagnosing osteomyelitis because <sup>67</sup>Ga also accumulates in sterile CNO (Glynn, 1981; Knight et al. 1988).

Given its high sensitivity, the scintigraphy may be useful in early diagnosis although can not rule out the presence of a coexisting infection. However it has two major limitations: sometimes may not differentiate bone infection from that of adjacent soft tissues due to low resolution, and the presence of peripheral ischemia can limit sensitivity.

## 2.3 Magnetic resonance imaging

The role of MRI for diagnostic imaging of the diabetic foot is increasing due to its advantages over scintigraphy and radiographs but its use is still unclear. The T<sub>1</sub>-weighted

sequences show anatomical references, both normal or abnormal, while T<sub>2</sub>- and STIR- (short tau inversion recovery) weighted sequences are better to demonstrate edema and inflammatory changes in the soft tissues and bone.

Some possible algorithms have been proposed (Giurato & Uccioli, 2006) but it is usually considered that MRI is not necessary in patients with evidence of CNO on plain radiographs and no clinical signs of infection (Giurato & Uccioli, 2006; Marcus et al., 1996).

CNO may present with two types of changes on MRI, depending on the evolution time of the process. Acute CNO shows a low signal intensity within bone marrow on T<sub>1</sub>-weighted sequences and high signal intensity on T<sub>2</sub>- and STIR-weighted sequences, findings that are similar to those observed in osteomyelitis. In a chronic CNO, besides cortical fragmentation, joint deformity and dislocation, typically appears a low signal intensity in the bone marrow on both T<sub>1</sub>- and T<sub>2</sub>-weighted sequences consistent with osteosclerosis on plain radiography. Another finding in chronic CNO is cyst-like lesions in the bone marrow which appear as well-defined clearly margined low signal lesions on T<sub>1</sub>-weighted images and as high signal intensity on T<sub>2</sub>-weighted images (Beltran et al. 1990; Marcus et al., 1996).

MRI may also be useful to early diagnosis when patients present acute symptoms and no changes in plain radiographs can be detected (stage 0 of Eichenholtz classification). In these cases, MRI may detect early events, such as bone edema, occult fractures and joint effusion (Chantelau & Poll, 2006; Edmonds et al., 2006; Greenstein et al., 2002).

Bone and soft tissue infection involving the foot is particularly common in patients with diabetes mellitus, and in these patients, CNO often coexists. The differentiation between these two entities is difficult. There are some MRI features that help to differentiate acute CNO from osteomyelitis: bone marrow signal damage and edema pattern, distribution of the changes, presence of deformity and soft tissue changes (ulcers, abscess or sinus tracts) (Lederman & Morrison, 2005; Lederman et al., 2002; Tan & Teh, 2007). Ahmadi et al., in a retrospective review of contrast-enhanced MRI study of 128 neuropathic feet joints in 63 diabetic patients with a suspicion of osteomyelitis, found that the presence of sinus tract, the presence of soft-tissue fluid collection and extensive bone marrow abnormality were MRI features commonly present in a superimposed infection (Ahmadi et al., 2006) (table 2).

Several studies demonstrate that MRI has a high sensitivity (77-100%) and specificity (80-100%) for osteomyelitis. Furthermore, in osteomyelitis MRI has a positive predictive power of 93% and almost a negative predictive power of 100% according to studies that compared MRI results to bone biopsy, which is considered the gold standard for diagnosing osteomyelitis (Levine et al., 1994; Marcus et al., 1996). However there are no studies assessing neither the sensitivity nor specificity of MRI detecting osteomyelitis in CNO patients.

The use of gadolinium in CNO is controversial (Marcus et al., 1996; Morrison et al., 1993) although may be useful to complete the soft tissue study (abscesses, sinus tracts, cellulitis).

In summary, MRI is a useful, non-invasive tool for the early diagnosis of CNO and may have utility for detecting a superimposed infection, being the soft tissue alteration the most specific finding.



Osteomyelitis		Charcot Neuro-osteoarthropathy	
Bone features			
Bone marrow	Low intensity T <sub>1</sub> - High intensity T <sub>2</sub> - and STIR-	Acute CNO	Chronic CNO
		Low intensity T <sub>1</sub> - High intensity T <sub>2</sub> - and STIR-	Low intensity T <sub>1</sub> - Low intensity T <sub>2</sub> - and STIR-
	Diffuse edema	Periarticular and subcondral edema	
Distribution	Focal bone involvement Weight bearing regions	Several bone affected Predominant midfoot involvement	
Deformity	Not common	Common	
Soft tissue features			
	Frequently involved: sinus tracts, cellulitis, abscess	Infrequently involved	

Table 2. Differential MRI patterns between osteomyelitis and Charcot neuro-osteoarthropathy.

2.4 Biochemical markers of bone turnover

Biochemical markers of bone turnover are often altered in CNO. There are few studies done, most of them evaluating the changes of these markers after treatment, mainly bisphosphonates. Some studies on bone turnover markers show an increase of these parameters in acute CNO, indicating an unspecific increased in bone activity. Gough et al. measured the pyridoline cross-linked carboxy-terminal telopeptide domain of type 1 collagen (1CTP) and carboxy-terminal propeptide of type 1 collagen (P1CP), both validated as markers of bone resorption and formation respectively, in diabetic patients with acute CNO, chronic CNO, diabetic controls and non-diabetic controls subjects (Gough et al., 1997). Serum 1CTP was significantly raised in the dorsal venous arch of the acute CNO feet compared to chronic CNO, diabetic controls and non-diabetic controls. The authors did not find any significant difference in serum P1CP levels in any group. These levels of 1CTP and P1CP suggest an increase in osteoclastic activity without concomitant increase of osteoblastic function. Selby et al. found an increase in bone-specific alkaline phosphatase (bone formation marker) with no significant changes among the others biochemical parameters studied: osteocalcin, urinary hydroxyproline, urinary desoxypyridinoline ( Selby et al., 1998). Increased levels of urinary cross-linked N-telopeptides of type 1 collagen (NTX) have been also demonstrated in CNO patients (Edelson et al., 1996).

In summary, there are few studies focused on bone markers in CNO. The data suggest an increase of them in acute CNO especially of resorption parameters. However, it seems that the role of bone markers for the diagnosis is yet to be determined.

3. Imaging and biochemical markers of bone turnover after medical treatment of Charcot neuro-osteoarthropathy

Although the cornerstone of treatment of CNO is immobilization, there are some studies that demonstrate the clinical benefit of bisphosphonates. The improvement with bisphosphonates appears to be sooner compared to patients with conventional therapy

(immobilization) (Anderson et al., 2004). Most studies use pamidronate, although alendronate has been demonstrated to be useful in one study (Pitocco et al., 2005). The optimal treatment regimen of pamidronate remains to be defined. Multiple observational studies have been published using different doses and duration, and all of them have demonstrated some clinical improvement (Navqi et al., 2008; Selby et al., 1994; Young, 1999). Furthermore, some reports have also shown an improvement in radiological changes (Guis et al., 1999) and/or decrease of biochemical bone turnover markers.

Jude et al. published the first trial of pharmacologic treatment, a randomized, double-blinded, placebo-controlled study in 39 active CNO patients (Jude et al., 2001). Twenty-one patients received a single infusion of 90 mg of pamidronate and this group showed a significant reduction in all biochemical markers analyzed (bone-specific alkaline phosphatase (BSAP) and urine deoxypyridoline cross-linked (D-pyr)) that persisted until 24 weeks in the case of BSAP. However, after 12 months follow-up, both biomarkers rose toward baseline levels.

Comparable results were obtained in 11 patients during treatment with alendronate 70 mg once a week over 6 months, in a randomized controlled double blind study. A clinical improvement was observed and, 1CTP and urinary hydroxyproline levels, as indicators of bone resorption, showed a significant decrease in the treated group after treatment (Pitocco et al., 2005).

Some case reports have demonstrated healing or stabilization of changes on plain radiography after intravenous pamidronate (Guis et al., 1999; Naqvi et al., 2008; Young, 1999).

In a short communication, McGill et al. reported that bone uptake scintigraphy and skin temperature improved over 12 months with immobilization (McGill et al., 2000), but there are no studies evaluating changes in neither MRI nor bone scintigraphy after bisphosphonate treatment.

Bem and collages determined quantitative bone scan parameters (ratio of foot and whole-body uptake and blood flow velocity) and markers of bone turnover (1CTP and BSAP) in 42 CNO patients (21 with acute and 21 with non-acute CNO) (Bem et al., 2010). The authors observed that there was a significant correlation between bone scintigraphy parameters and bone turnover markers. In addition, in acute CNO, there was a significant reduction of both scintigraphy parameters and levels of 1CTP and BSAP after treatment with calcitonin.

Schlossbauer and col. published the first report on quantitative assessment of signal alterations on contrast-enhanced MRI in CNO stage 0, before and after treatment with pressure-relieving means (Schlossbauer et al., 2008). In this study they analyzed the clinical symptoms of 13 patients with acute CNO and compared with MRI findings at baseline and after 4-month follow-up. They found a significant correlation between bone marrow edema and soft tissue edema and pain, with a significant decrease of these parameters after treatment. Thus, they concluded that MRI in early stage of CNO provides valuable information on the activity of the disease.

Our group published an open, prospective therapeutic study with a 12-month follow-up including 7 consecutive patients (four diabetic, two with syringomyelia and one with an autonomic neuropathy) with active CNO seen over a period of 3 years (Moreno et al., 2007).

Patients included in this protocol received three intravenous infusions of pamidronate at 0, 2 and 4 months and traditional immobilization methods. Two diabetic patients had a concomitant septic arthritis in the affected joint and they received also antibiotic treatment. Biochemical markers of bone remodeling, radiological exam and <sup>99</sup>Tc-scan were performed before and after 12 months treatment. The bone remodeling markers study included blood alkaline phosphatase (ALP) and BSAP, urinary crosslinks NTX, pyridoline (pyr) and D-pyr. Clinical symptoms improved after the first infusion. Although in most cases the bone basal remodeling markers were within normal range values, a clear decrease in almost all of these remodeling markers was observed after treatment in all patients, reaching statistical significance for NTX and urinary pyr, suggesting that the blocking of the osteoclastic activity may play an important role in the physiopathology of CNO, as observed in previous studies. All patients, except one with a siringomyelia, showed signs of radiological healing with a marked sclerosis and reconstruction of the cortical bone (figure 1). In one case pamidronate was administered very early, avoiding the progression and preventing the occurrence of radiological changes during the follow-up period (figure 2). Quantitative scintigraphy was performed only in 3 cases, showing a decrease in radiotracer uptake after treatment although it did not become completely normal. In agreement with previous studies, pamidronate improved not only clinical signs but also stopped the progression of disease in most cases.

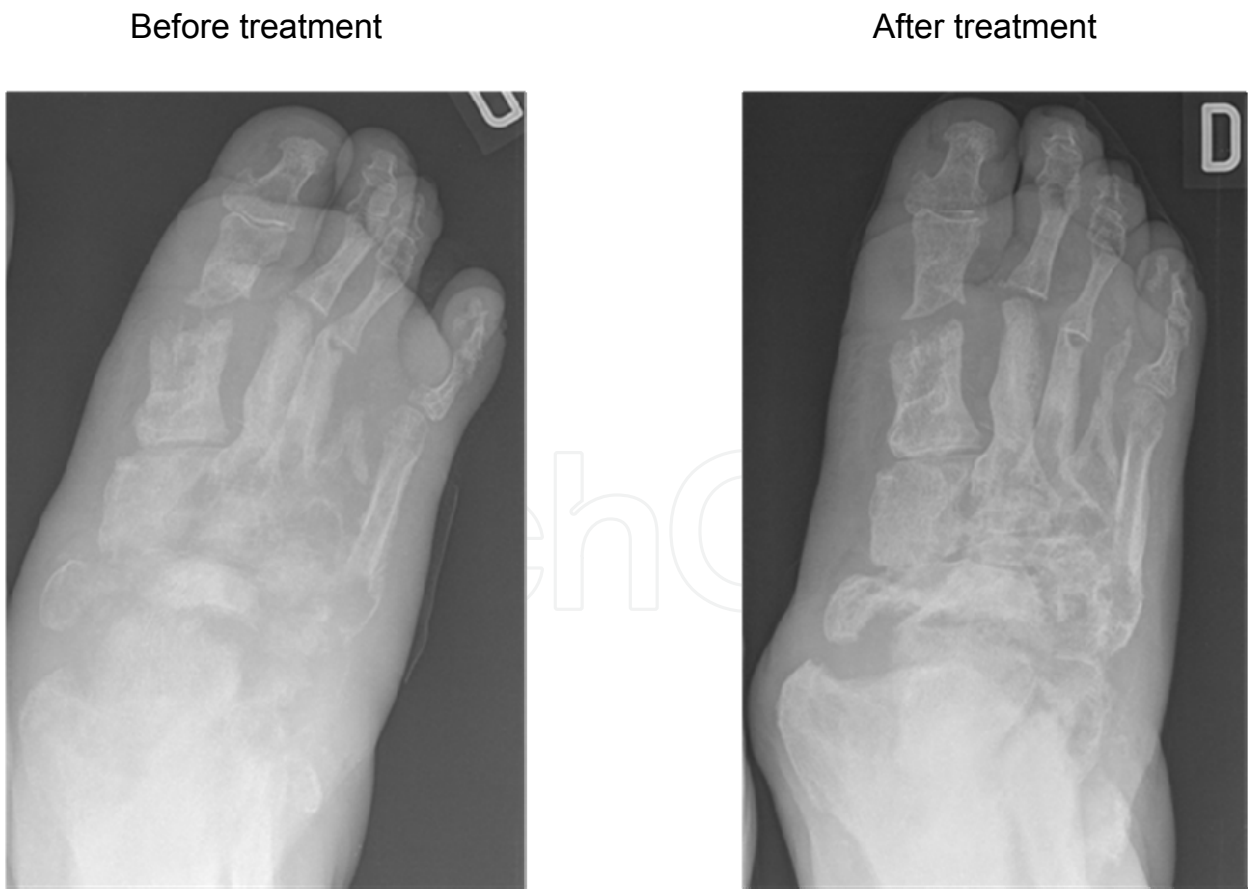


Fig. 1. Patient with a Charcot foot and concomitant septic arthritis. Note before pamidronate treatment the presence of bone fragmentation, subluxation, loss of defined contours and eburnation and after 6-months treatment sclerosis and defined contours.



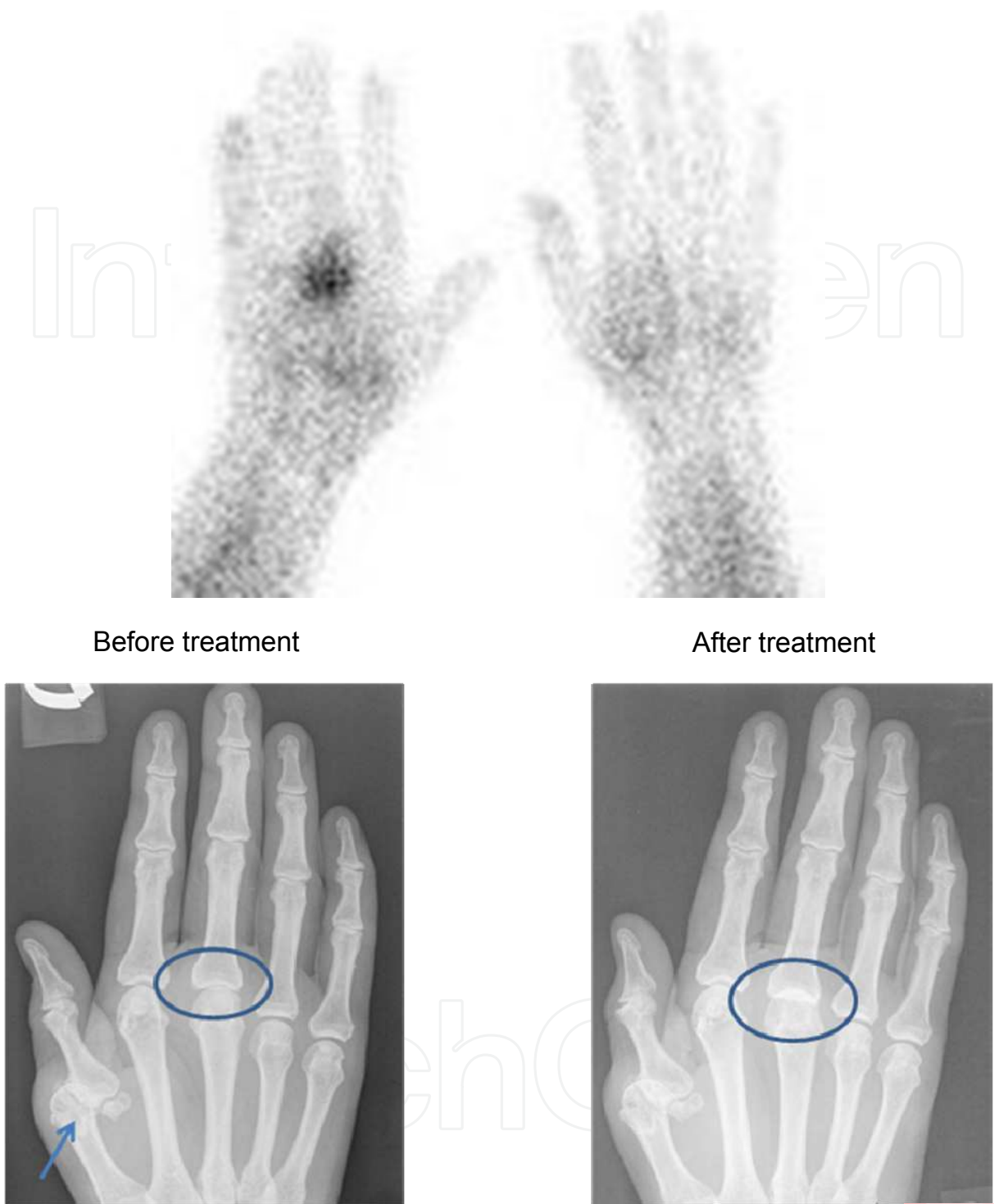


Fig. 2. Patient with a known CNO secondary to syringomyelia involving 1<sup>st</sup> right MCP (arrow). She developed a 3<sup>rd</sup> MCP swelling joint, early detected with scintigraphy. Initial radiography did not show any changes. Treatment was administered very early avoiding established deformities.

4. Conclusions

- early diagnosis in CNO is difficult and needs a high index of suspicion

- $^{99}\text{Tc}$  bone scan scintigraphy and MRI are useful in order to establish early diagnosis
- $^{99}\text{Tc}$  bone scan scintigraphy and MRI can help to detect superimposed infection, a condition quite common in diabetic patients
- biomarkers of bone turnover are increased in acute phase, especially resorptive ones. However, their utility for monitoring treatment response remains to be established
- bisphosphonate treatment appears to be effective not only for clinical improvement but also for disease outcome
- early diagnosis and treatment may be important to avoid late structural damage

## 5. References

- Ahmadi ME, Morrison WB, Carrino JA, Schweitzer ME, Raikin SM & Ledermann HP. (2006). Neuropathic arthropathy of the foot with and without superimposed osteomyelitis: MR imaging characteristics. *Radiology*, Vol. 238, No. 2, (February), pp. 622-631.
- Aliabadi P, Nikpoor N & Alparslan L. (2003). Imaging of neuropathic arthropathy. *Seminars Musculoskelet Radiol*, Vol. 7, No. 3, (September), pp. 217-225.
- Anderson JJ, Woelffer KE, Holtzman JJ & Jacobs AM. (2004). Bisphosphonates for the treatment of Charcot neuroarthropathy. *J Foot Ankle Surg*, Vol. 43, No. 5, (September-October), pp. 285-289.
- Bailer CC & Root HF. (1947). Neuropathic foot lesions in diabetes mellitus. *N Engl J Med*, 13, Vol. 236, No. 11. (March), pp. 397-401.
- Beltran J, Campanini DS, Knight C & McCalla M. (1990). The diabetic foot: magnetic resonance imaging evaluation. *Skeletal Radiol*, Vol. 19, No. 1, pp. 37-41.
- Bem R, Jirkovská A, Dubsky M, Fejfavorá V, Buncová M, Skibová J & Jude EB. (2010). Role of quantitative bone scanning in the assessment of bone turnover in patients with Charcot foot. *Diabetes Care*, Vol. 33, No. 2, (February), pp. 348-349.
- Brodsky JW. The diabetic foot. In MJ Coughlin, RA Mann and Saltzman CL (Eds). *Surgery of the foot and ankle*, 1281-1368.
- Chantelau E, & Poll LW. (2006). Evaluation of the diabetic Charcot foot by MR imaging or plain radiography-an observational study. *Exp Clin Endocrinol Diabetes*, Vol. 114, No. 8, (September), pp. 428-431.
- Clouse ME, Gramm HF, Legg M & Flood T. (1974). Diabetic osteoarthropathy. Clinical and roentgenographic observations in 90 cases. *Am J Roentgenol Radium Ther Nucl Med*, Vol. 121, (May) pp. 22-34.
- Cofield RH, Morrison MJ & Beabout JW. (1983). Diabetic neuroarthropathy in the foot: patient characteristics and patterns of radiographic change. *Foot Ankle Int*, Vol. 4, (July-August), pp. 15-22.
- Eichenholtz S (1966). *Charcot Joints*. Springfield, IL: Charles C Thomas.
- Edelson GW, Jensen JL & Kaczynski R. (1996). Identifying acute Charcot arthropathy through urinary cross-linked N-telopeptides. *Diabetes*, Vol. 45 (suppl. 2), abstract 108A.
- Edmonds ME, Petrova NL, Edmonds A et al. (2006). What happens to the initial bone marrow oedema in the natural history of Charcot osteoarthropathy (abstract)? *Diabetologia*, Vol. 49 (suppl.), pp. 684.


- Fabrin J, Larsen K & Holstein PE. (2000). Long-term follow up in diabetic Charcot feet with spontaneous onset. *Diabetes Care*, Vol. 23, No. 6, (June), pp. 796-800.
- Giurato L & Uccioli L. (2006) The diabetic foot: Charcot joint and osteomyelitis. *Nucl Med Commun*, Vol. 27, No. 9, (September), pp. 745-749.
- Glynn TP jr. (1981). Marked gallium accumulation in neurogenic arthropathy. *J Nucl Med*, Vol. 22, No. 11, (November) pp. 1016-1017.
- Gough A, Abraha H, Li F, Purewal TS, Foster AVM, Watkins PJ, Moniz C & Edmonds ME. (1997). Mesurement of markers of osteoclast and osteoblast activity in patients with acute and chronic diabetic charcot neuroarthropathy. *Diabet Med*, Vol. 14, No. 7, pp. 527-531.
- Greenstein AS, Marzo-Ortega H, Emery P, O'Connor P & McGonagle D. (2002). Magnetic resonance imaging as a predictor of progressive joint destruction in neuropathic joint disease. *Arthritis Rheum*, Vol. 46, No. 10, (October), pp. 2814-2815.
- Guis S, Pellissier JF, Arniaud D, Turck F, Witjas T, Roux H & Mattei JP. (1999). Healing of Charcot's joint by pamidronate infusion. *J Rheumatol*, Vol. 26, No. 8, (August), pp. 1843-1845.
- Jeffcoate WJ, Game F & Cavanagh PR. (2005). The role of proinflammatory cytokines in the cause of neuropathic osteoarthropathy (acute Charcot foot) in diabetes. *Lancet*, Vol. 366, (December) pp. 2058-2061.
- Jeffcoate WJ. (2008). The causes of the Charcot Syndrome. *Clin Podiatr Med Surg*, Vol. 25, No. 1, (January), pp. 29-42.
- Jones EA, Manster BJ, May DA & Disler DG. (2000). Neuropathic osteoarthropahty: diagnostic dilemmas and differential diagnosis. *Radiographics*, Vol. 20, (October), pp. S279-293.
- Jude EB & Boulton AJM. (2001). Update on Charcot neuroarthropathy. *Curr Diab Rep*, Vol. 1, No. 3 (December) pp. 228-232.
- Jude EB, Selby PL, Burgess J, Lilleystone P, Mawer EB, Page SR, Donohoe M, Foster AVM, Edmonds ME & Boulton AJM. (2001). Bisphosphonates in the treatment of Charcot neuroarthropathy: a double-blind randomised controlled trial. *Diabetologia*, Vol. 44, No. 11, (November), pp. 2032-2037.
- Klenerman L. (1996). The Charcot neuroarthropathy joint in diabetes. *Diabet Med*, Vol. 13, pp. S52-S54.
- Knight D, Gray HW, McKillop JH & Bessent RG. (1988). Imaging for infection: caution required with the Charcot joint. *Eur J Nucl Med*, Vol. 13, No. 10, pp 523-526.
- Ledermann HP, Morrison WB & Schweitzer ME. (2002). MR image analysis of pedal osteomyelitis: distribution, patterns of spread, and frequency of associated ulcerations and septic arhtiritis. *Radiology*, Vol. 223, No. 3, (June), pp. 747-755.
- Ledermann HP & Morrison WB. (2005). Differential diagnosis of pedal osteomyelitis and diabetic neuroarthropathy: MR imaging. *Semin Musculoskelet Radiol*, Vol. 9, No. 3, (September), pp. 272-283.
- Levine SE, Neagle CE, Esterhai JL, Wright DG & Dalinka MK. (1994). Magnetic resonance imaging for diagnosis of osteomyelitis in the diabetic patient with a foot ulcer. *Foot Ankle Int*, Vol. 15, No. 3, (March), pp. 151-156.
- Mabilleau G, Petrova NL, Edmonds ME & Sabokbar A. (2008). Increased osteoclastic activity in acute Charcot's osteoarthropathy: the role of receptor activator of nuclear factor-kappa B ligand. *Diabetologia*, Vol. 51, (June), pp. 1035-1040.

- Marcus CD, Ladam-Marcus VJ, Leone J, Malgrange D, Bonnet-Gausserand FM & Menanteau BP. (1996). MR Imaging of osteomyelitis and neuropathic osteoarthropathy in the feet of diabetics. *Radiographics*, Vol. 16, No. 6, (November), pp. 1337-1348.
- McGill M, Molyneaux L, Bolton T, Ioannou K, Uren R & Yue DK. (2000). Response of Charcot's arthropathy to contact casting: assessment by quantitative techniques. *Diabetologia*, Vol. 43, No 4, (April), pp. 481-84.
- Molines L, Darmon P & Raccach D. (2010). Charcot's foot: newest findings on its pathophysiology, diagnosis and treatment. *Diabetes Metab*, Vol. 31, (September), pp. 251-255.
- Moreno M, Gratacós J, Casado E, Galisteo C, Orellana C & Larrosa M. (2007). Utilidad del pamidronato en el tratamiento de la artropatía de Charcot. *Reumatol Clin*, Vol. 3, No. 6, pp. 257-261.
- Morrison WB, Schweitzer ME, Bock GW, Mitchell DG, Hume EL, Pathria MN & Resnick D. (1993). Diagnosis of osteomyelitis: utility of fat-suppressed contrast-enhanced MR imaging. *Radiology*, Vol. 189, No. 1, (October), pp. 251-257.
- Naqvi A, Cuchacovich R, Saketkoo L & Espinoza LR. (2008). Acute Charcot arthropathy successfully treated with pamidronate: long-term follow-up. *Am J Med Sci*, Vol. 335, No. 2, (February), pp. 145-148.
- Petrova NL, Foster AVN & Edmonds ME. (2004). Difference in presentation of Charcot osteoarthropathy in type 1 compared with type 2 diabetes. *Diabetes Care*, Vol. 27, No. 5, (May) pp. 1235-1236.
- Petrova NL & Edmonds ME. (2008). Charcot neuro-osteoarthropathy current standards. *Diabetes Metab Res Rev*, Vol. 24 (supl 1), (May-June), pp. S58-61.
- Pitocco D, Ruotolo V, Caputo S, Mancini L, Collina CM, Manto A, Caradonna P & Ghirlanda G. (2005). Six-months treatment with alendronate in acute Charcot neuroarthropathy: a randomized controlled trial. *Diabetes care*, Vol. 28, (May), pp. 1214-1215.
- Rajbhandari SM, Jenkins RC, Davies C & Tesfaye S. (2002). Charcot neuroarthropathy in diabetes mellitus. *Diabetologia*, Vol. 45, No. 10, (August) pp. 85-96.
- Resnick D, Niwayama G (1988). *Diagnosis of bone and joint disorders*, (second edition). Volume 5. W. B. Saunders Company, 0-7216-1482-5, United States of America.
- Schlossbauer T, Mioc T, Sommerey S, Kessler SB, Reiser MF & Peifer KJ. (2008). Magnetic resonance imaging in early stage charcot arthropathy: correlation of imaging findings and clinical symptoms. *Eur J Med Res*, Vol. 22, No. 13(9), (September), pp. 409-414.
- Selby PL, Young MJ & Boulton AJM. (1994). Bisphosphonates: a new treatment for diabetic Charcot neuroarthropathy? *Diabet Med*, Vol. 11, No. 1, pp. 28-31.
- Selby PL, Jude EB & Burgess J, Page S, Edmonds ME, Foster A, Mawer EB, Adams JE & Boulton AJM. (1998). Bone turnover markers in acute Charcot neuroarthropathy. *Diabetologia*, Vol. 41 (supl1): A 275.
- Sella EJ. (2009). Current concepts review: diagnostic imaging of the diabetic foot. *Foot Ankle Int*, Vol. 30, No. 6, (June) pp. 568-576.
- Schauwecker DS, Park HM, Burt RW, Mock BH & Wellman HN. (1988). Combined bone scintigraphy and indium-111 leucocyte scans in neuropathic foot disease. *J Nucl Med*, Vol. 29, No. 10, (October), pp. 1651-1655.

- Shaw JE & Boulton AJM. (1995). The Charcot foot. *Foot*, Vol. 5, pp. 65-70.
- Shibata T, Tada K & Hashizume C. (1990). The results of arthrodesis of the ankle for leprotic neuroarthropathy. *J Bone Joint Surg Am*, Vol. 72, No. 5, (June), pp. 749-756.
- Sinha SB, Munichoodappa CS & Kozak GP. (1972). Neuroarthropathy (Charcot joints) in diabetes mellitus. Clinical study of 101 cases. *Medicine (Baltimore)*, Vol. 51, pp. 191-210.
- Storey G. (1964). Charcot Joints. *Brit J. Vener Dis*, Vol. 49, (June), pp. 90-117.
- Tan PL & Teh J. (2007). MRI of the diabetic foot: differentiation of infection from neuropathic change. *Br J Radiol*, Vol. 80, No. 959, (November), pp. 939-948.
- Young MJ. (1999). The management of neurogenic arthropathy: a tale of two charcots. *Diabetes Metab Res Rev*, Vol. 15, No. 1, (January-February), pp. 59-64.

IntechOpen





## **Insights and Perspectives in Rheumatology**

Edited by Dr. Andrew Harrison

ISBN 978-953-307-846-5

Hard cover, 274 pages

**Publisher** InTech

**Published online** 13, January, 2012

**Published in print edition** January, 2012

This book offers a range of perspectives on pathogenesis, clinical features and treatment of different rheumatic diseases, with a particular focus on some of the interesting aspects of Sjögren's syndrome. It contains detailed and thorough reviews by international experts, with a diverse range of academic backgrounds. It will also serve as a useful source of information for anyone with a passive interest in rheumatology, from the genetic and molecular level, through to the psychological impact of pain and disability.

### **How to reference**

In order to correctly reference this scholarly work, feel free to copy and paste the following:

Ivonne Vázquez, Mireia Moreno and Marta Larrosa (2012). Pamidronate Treatment in Charcot Neuro-Osteoarthropathy: Change in Biochemical Markers of Bone Turnover and Radiographic Outcome After Treatment, *Insights and Perspectives in Rheumatology*, Dr. Andrew Harrison (Ed.), ISBN: 978-953-307-846-5, InTech, Available from: <http://www.intechopen.com/books/insights-and-perspectives-in-rheumatology/pamidronate-treatment-in-charcot-neuro-osteoarthropathy-change-in-biochemical-markers-of-bone-turnov>

**INTECH**  
open science | open minds

### **InTech Europe**

University Campus STeP Ri  
Slavka Krautzeka 83/A  
51000 Rijeka, Croatia  
Phone: +385 (51) 770 447  
Fax: +385 (51) 686 166  
[www.intechopen.com](http://www.intechopen.com)

### **InTech China**

Unit 405, Office Block, Hotel Equatorial Shanghai  
No.65, Yan An Road (West), Shanghai, 200040, China  
中国上海市延安西路65号上海国际贵都大饭店办公楼405单元  
Phone: +86-21-62489820  
Fax: +86-21-62489821

© 2012 The Author(s). Licensee IntechOpen. This is an open access article distributed under the terms of the [Creative Commons Attribution 3.0 License](https://creativecommons.org/licenses/by/3.0/), which permits unrestricted use, distribution, and reproduction in any medium, provided the original work is properly cited.

IntechOpen

IntechOpen