

We are IntechOpen, the world's leading publisher of Open Access books Built by scientists, for scientists

6,900

Open access books available

186,000

International authors and editors

200M

Downloads

Our authors are among the

154

Countries delivered to

TOP 1%

most cited scientists

12.2%

Contributors from top 500 universities



WEB OF SCIENCE™

Selection of our books indexed in the Book Citation Index
in Web of Science™ Core Collection (BKCI)

Interested in publishing with us?
Contact book.department@intechopen.com

Numbers displayed above are based on latest data collected.
For more information visit www.intechopen.com



Noninvasive Monitoring of Breathing and Swallowing Interaction

N. Terzi^{1,2}, D. Orlikowski^{2,3}, H. Prigent^{2,4},
Pierre Denise⁶, H. Normand⁶ and F. Lofaso^{2,4,5}

¹INSERM, ERI27, Caen; Univ Caen, Caen; CHRU Caen
Service de Réanimation Médicale, Caen

²Centre d'Investigation Clinique - Innovations Technologiques, Hôpital Raymond
Poincaré, AP-HP; Université de Versailles-Saint Quentin en Yvelines, Garches

³Centre d'Investigation Clinique - Innovations Technologiques 805, Service de
Réanimation et Unité de Ventilation à Domicile, Hôpital Raymond Poincaré, AP-HP

⁴Services de Physiologie - Explorations Fonctionnelles
Hôpital Raymond Poincaré, AP-HP

⁵INSERM, U 955, Créteil

⁶INSERM, ERI27, Caen, Univ Caen; CHRU Caen
Service d'Explorations Fonctionnelles, Caen

France

1. Introduction

The evaluation of swallowing parameters and of interactions between breathing and swallowing is crucial to optimise the management of patients with chronic respiratory failure, as swallowing must occur in precise coordination with breathing. Various techniques have been used to study the physiology and biomechanics of the oral and pharyngeal stages of swallowing. Among them, the two most commonly used, videofluoroscopy and videoendoscopy, provide information on the motion of anatomic structures during swallowing. The determination of muscle activation patterns is best achieved with electromyography (EMG). Most of the initial EMG studies of swallowing used needle electrodes to record intramuscular EMG activity (Doty and Bosma 1956; Perlman, Palmer et al. 1999). Ertekin *et al.* (Ertekin, Pehlivan et al. 1995) were the first to describe an electrophysiological method for investigating swallowing in humans.

Recent advances in the management of respiratory failure have considerably improved the survival of patients with neuromuscular disease (Finder, Birnkrant et al. 2004). For example, the introduction in the 1990s of mechanical ventilation (MV) improved the survival of patients with Duchenne muscular dystrophy (DMD) from about 15 years in the 1960s to more than 30 years now. Quality of life, however, declines over time as the disease progresses. Malnutrition is common: in one study, for instance, 44% of patients had malnutrition (Willig, Bach et al. 1995). The main causes of malnutrition are prolonged swallowing, respiratory failure, and dysphagia, which jeopardize the patient's ability to meet intake needs. Feeding difficulties often develop insidiously, being frequently underestimated by family members and healthcare professionals (Hill, Hughes et al. 2004).

Aspiration is another important consequence of impaired swallowing that becomes increasingly common as the disease progresses (Finder, Birnkrant et al. 2004).

Studies have demonstrated that swallowing dysfunction is closely associated with impaired inspiratory muscle strength (Terzi, Orlikowski et al. 2007; Orlikowski, Terzi et al. 2009) and improve with tracheostomy and mechanical ventilation (Terzi, Prigent et al.; Terzi, Orlikowski et al. 2007). Swallowing and inspiratory muscle strength are being evaluated in patients with acute exacerbations of chronic obstructive pulmonary disease (COPD) requiring noninvasive ventilation.

Noninvasive methods for evaluating swallowing are useful to investigate various disorders and the interactions between breathing and swallowing. Here, after a review of swallowing physiology to explain the EMG evaluation and a discussion of interactions between breathing and swallowing, we describe the most commonly used electrophysiological method, which is noninvasive and easy to perform at the bedside. We do not address methods requiring the connection of measurement devices directly to the airway.

2. Physiology of swallowing

Swallowing is a complex physiological function that was generally investigated using videofluoroscopy, videoendoscopy, manometric methods, or invasive methods providing information on a single pair of muscles involved in swallowing. Swallowing was usually divided into three phases: an initial oral phase; a pharyngeal phase; and an esophageal phase (Dodds 1989). These phases of swallowing involve different innervation patterns. Thus, the oral phase is usually described as voluntary, the pharyngeal phase as a reflex response, and the esophageal phase as controlled by both the somatic and the autonomic nervous system (Doty and Bosma 1956; Miller 1982).

2.1 Oral phase

The oral phase is mainly voluntary and highly variable in duration depending in humans on taste, environment, hunger, motivation, and consciousness. First, the tongue presses the bolus against the hard palate and initiates displacement of the bolus to the posterior part of the tongue and toward the oropharynx. This stage ends with the triggering of the pharyngeal phase of swallowing.

When the volume swallowed is small (1-2 ml, e.g., saliva), there is no preparatory phase and the oral and pharyngeal phases occur in sequence. In contrast, with large liquid boluses, the oral and pharyngeal phases overlap (Logemann, Kahrilas et al. 1992; Ertekin, Celik et al. 2000). The size of the bolus does not alter the sequence of events during oropharyngeal swallowing but modulates the timing of each phase of the swallow. As volume size increases, pharyngeal transit time increases, as do laryngeal closure and elevation (Ertekin, Aydogdu et al. 1997).

When 20 ml of water is placed in the mouth, normal individuals tend to divide the water into two or more parts, which are swallowed in sequence (Ertekin, Aydogdu et al. 1996). This phenomenon is called piecemeal deglutition.

From this stage to the end of the swallow, breathing is inhibited.

2.2 Pharyngeal phase

The pharyngeal phase is closely related to the oral phase, and the distinction between the two is often unclear. This intimate relationship is expressed by the widespread use of the terms oropharynx and oropharyngeal swallowing.

When the movement of the bolus from the oral cavity to the pharyngeal space triggers the swallowing reflex or response, several closely coordinated events occur in rapid overlapping sequence, transporting the bolus from the oropharynx to the esophagus without allowing aspiration. Coordination of these events may be chiefly under the control of the central pattern generator (CPG) in the brainstem (Miller 1982; Jean 2001). These events are as follows: (i) several reflexes governed by the CPG protect the nasal, laryngeal, and tracheal airways and support laryngeal closure; (ii) the tongue moves backward to push the bolus through the pharynx; (iii) and the upper esophageal sphincter relaxes and opens, allowing the bolus to descend into the esophagus.

Once the pharyngeal phase is initiated, the chain of events is irreversible. The entire oropharyngeal sequence takes only 0.6 to 1.0 second, and this duration is remarkably constant in humans (Ertekin, Pehlivan et al. 1995).

2.3 Esophageal phase

In comparison with the extraordinary complexity and rapidity of the oropharyngeal phase, the esophageal phase of swallowing is simpler and slower. It consists of a peristaltic wave of contraction of the striated and smooth muscles, which propagates to the stomach.

2.4 Neurological control of swallowing

The process of swallowing is an ordered sequence of sensory and motor events. Swallowing is a fundamental motor activity, since it serves two vital functions: by propelling food into the stomach, swallowing subserves the alimentary function; and the swallowing reflex protects the upper respiratory tract, thus preventing aspiration of food particles into the lungs (Miller 1982). Swallowing can occur voluntarily via cerebral cortex activation and/or as a reflex under brainstem control.

The central neural control of swallowing is also divided between the cortex and brainstem. Cortical centers in conjunction with afferent feedback from the musculature initiate and modulate the volitional swallow (Sumi 1969; Car and Roman 1970; Martin and Sessle 1993), whereas the brainstem swallowing CPG generates the sequence of reflex swallowing via the nuclei of the Vth, IXth, and XIIth cranial nerves. Normal swallowing requires coordinated interactions among these outputs. Any disruption in the process of coordination leads to swallowing dysfunction.

The importance of suprabulbar influences in regulating swallowing has been established in animal models in which cortical swallowing regions are disrupted by lesion induction, anesthesia, or cooling (Sumi 1969; Martin and Sessle 1993). In humans, the development of functional magnetic resonance imaging (fMRI) has allowed the identification of the cortical regions involved in voluntary swallowing. The primary motor and sensory areas are consistently active in healthy adults during swallowing. The anterior cingulate cortex is also activated during swallowing (Hamdy, Mikulis et al. 1999; Humbert and Robbins 2007).

There is convincing evidence that the sequential and rhythmic patterns of swallowing are formed and organized by a central pattern generator (CPG) located within the medulla oblongata (Jean 2001). The CPG was first described as a swallowing center that can be subdivided into three systems: an afferent system composed of the central and peripheral inputs to the center; an efferent system composed of outputs from the center to various motor neuron pools involved in swallowing; and an organizing system composed of interneuronal networks that program the motor pattern.

Although the central regulation of swallowing is chiefly dependent on the brainstem, which receives sensory input from the oropharynx and esophagus, the initiation of swallowing is a voluntary action that requires the integrity of sensorimotor areas of the cerebral cortex. Therefore, both the brainstem and cortex must be intact to ensure normal swallowing.

3. Interaction between respiration and swallowing

The temporal coordination of pharyngeal and laryngeal swallowing events with breathing is essential to prevent aspiration of oropharyngeal contents into the lungs. Indeed, both breathing and swallowing occur continually, although at different frequencies. As the upper airway is used for both breathing and swallowing, the motor pattern generators for these two activities must work in tight coordination to prevent aspiration and to ensure clearance of lower airway secretions (Feroah, Forster et al. 2002).

The swallowing CPG may play a crucial role in coordinating swallowing and breathing. Within this CPG, some of the premotor and motor neurons can be involved in at least two different tasks, such as swallowing and breathing, swallowing and mastication, and swallowing and phonation (Jean 2001).

During swallowing, mechanisms that protect the airways include adduction of the vocal cords, inversion of the epiglottis, and the upward and forward movement of the larynx away from the flow of the bolus. Respiratory control during swallowing contributes to airway protection.

In 1985, Nishino et al. clarified the effects of swallowing on the pattern of continuous breathing in humans. In adults, approximately 80% of spontaneous or water-induced swallows occurred during the expiratory phase. Furthermore, breathing resumed at the point of the expiratory phase where the interruption had taken place (Nishino, Yonezawa et al. 1985). A striking finding was that most of the water-induced swallows occurred during expiration although the timing of water administration was determined at random. The mechanisms underlying these findings are unclear but may involve reflex-mediated responses, as all the study participants reported being unaware of the breathing phase during which their swallows occurred. One of the main hypotheses is that the timing of swallows is not entirely independent from volitional control. The effects of swallowing on the pattern of continuous breathing were analyzed in detail in this study. Spontaneous (automatic) and volitional (water-induced) swallows occurring during expiration were followed by a small increase in the duration of the interrupted expiration. As the time from expiration onset to swallowing increased, the duration of the expiration increased. Swallows that interrupted the inspiratory phase were followed by short expirations. Thus, swallowing was followed by resetting of the respiratory cycling with a return to the functional residual capacity before the initiation of a new inspiration. This alteration in the breathing pattern may help to clear the airway of secretions and foreign material before the next inspiration, thus contributing to prevent aspiration (Nishino, Yonezawa et al. 1985).

Breathing-swallowing interactions and the underlying mechanisms have been studied in healthy volunteers by measuring a variety of parameters including the duration of deglutition apnea (Nishino, Yonezawa et al. 1985; Selley, Flack et al. 1989; Martin, Logemann et al. 1994; Klahn and Perlman 1999) and the timing of breathing events relative to swallows (Perlman, Schultz et al. 1993; Martin, Logemann et al. 1994; Paydarfar, Gilbert et al. 1995; Klahn and Perlman 1999). Several factors that influence breathing-swallowing

interactions were identified. Interestingly, many studies showed that breathing-swallowing coordination was influenced by neurological disorders affecting the brain, spinal cord, or peripheral nerves.

Studies in unconscious patients demonstrated that several mechanisms integrating breathing and swallowing remained operative, leading to changes in the breathing pattern during repeated swallows. These findings are consistent with a role for brainstem control (Nishino and Hiraga 1991), especially as both the respiratory center and the swallowing CPG are located in the same area of the brainstem. In contrast, other studies demonstrated that the cortex influences breathing-swallowing interactions in unconscious patients (Hadjikoutis, Pickersgill et al. 2000).

In the other direction, alterations in breathing patterns and ventilation may influence the coordination of swallowing and breathing. This effect is of particular importance in patients with chronic respiratory failure, in whom close breathing-swallowing coordination is essential to maintain adequate ventilation despite the limited ventilatory capacity. Alterations in breathing-swallowing coordination have been reported in patients with chronic obstructive pulmonary disease (COPD) (Shaker, Li et al. 1992) and in awake healthy volunteers subjected to added respiratory loads (Kijima, Isono et al. 1999). Tachypnea and lung volume have also been demonstrated to influence breathing-swallowing coordination.

Alterations in breathing-swallowing coordination chiefly affect temporal coordination. When temporal coordination is disrupted, most swallows are followed by an inspiration, which significantly increases the risk of aspiration.

4. Breathing-swallowing interaction in neuromuscular patients

Elucidation of breathing-swallowing interactions in patients with specific neuromuscular diseases is of considerable interest. Patients with neuromuscular disease have achieved substantial survival gains in recent years as a result of advances in the management of respiratory failure (Finder, Birnkrant et al. 2004). The introduction of mechanical ventilation (MV) in the 1990s improved survival in patients with Duchenne muscular dystrophy (DMD) from about 15 years in the 1960s to more than 30 years now. Quality of life, however, declines over time as the disease progresses. Malnutrition is common: in one study, for instance, 44% of patients had malnutrition (Willig, Bach et al. 1995; Finder, Birnkrant et al. 2004). The main causes of malnutrition are prolonged swallowing, respiratory failure, and dysphagia, which jeopardize the patient's ability to meet intake needs. Feeding difficulties often develop insidiously, being frequently underestimated by family members and healthcare professionals (Hill, Hughes et al. 2004). Aspiration is another important consequence of impaired swallowing that becomes increasingly common as the disease progresses (Finder, Birnkrant et al. 2004).

To the best of our knowledge, breathing-swallowing interactions initially received little research attention (Hadjikoutis, Pickersgill et al. 2000). Moreover, improvements in the management of chronic respiratory failure translate into differences in breathing conditions across patients and over time, and this variability is likely to complicate the evaluation of breathing-swallowing interactions. These breathing conditions are now well defined and include spontaneous breathing (SB), (Raphael, Chevret et al. 1994), noninvasive mechanical ventilation (NIV) (Bach, Alba et al. 1993; 1999; Mehta and Hill 2001; Annane, Orlikowski et

al. 2007), tracheostomy with SB (Bach and Alba 1990; Chadda, Louis et al. 2002), and tracheostomy with MV (Bach and Alba 1990; Bach 1993; Simonds 2003).

In contrast to spontaneously breathing patients, tracheostomized patients receiving assist-control MV cannot prolong their expiratory phase. Consequently, the ventilator determines whether expiration or inspiration occurs after swallowing. Under normal breathing conditions, swallows are nearly always followed by expiration (Nishino, Yonezawa et al. 1985; Smith, Wolkove et al. 1989; Paydarfar, Gilbert et al. 1995), which may contribute to prevent aspiration.

In studies of breathing-swallowing interactions in neuromuscular patients with chronic respiratory failure, we found that SB was associated with piecemeal deglutition leading to an increase in the time needed to swallow a water bolus, as well as with inspiration after nearly half the swallows. These abnormalities may contribute to feeding difficulties. They correlated with the reduction in respiratory muscle performance, suggesting a relationship between breathing-muscle performance and swallowing-muscle performance. Accordingly, tongue strength and indices of global and respiratory strength varied in parallel throughout the course of Guillain-Barré syndrome (Orlikowski, Terzi et al. 2009). Tongue strength can be considered representative of the strength of the various muscles involved in swallowing. Another hypothesis is that respiratory failure alone may alter breathing-swallowing coordination. In keeping with this possibility, breathing-swallowing abnormalities were documented in COPD patients with respiratory failure but no upper-airway muscle-strength abnormalities. These findings indicated a need for evaluating the positive impact of MV on breathing-swallowing interactions in patients with respiratory failure.

First, in tracheostomized NM patients who were able to breathe spontaneously, we demonstrated that MV decreased both piecemeal deglutition and swallowing time per bolus (Terzi, Orlikowski et al. 2007).

Second, we evaluated the impact of tracheostomy with MV on swallowing performance in patients with DMD. To this end, we assessed swallowing performance and breathing-swallowing coordination before and after tracheostomy in the same patients. Piecemeal deglutition over several breathing cycles occurred in all patients. Before tracheostomy, half the swallows were followed by inspirations. Tracheostomy was associated with significant decreases in total bolus swallowing time and number of swallows per bolus, compared to the values before tracheostomy. These findings indicated that invasive ventilation via a tracheostomy improved swallowing. Several hypotheses can be put forward to explain this effect. Breathing and swallowing use the same initial pathway and, therefore, competition occurs between these two functions. Under physiological conditions, this competition is well controlled via close coordination of breathing and swallowing. Respiratory failure exacerbates the competition, giving preference to breathing over swallowing and altering the coordination between these two activities. Our results suggest that, by reversing the respiratory failure and separating the breathing and swallowing pathways, invasive MV may have a positive impact on swallowing in patients with respiratory failure.

The question is now whether treating the respiratory failure without separating the breathing and swallowing pathways, e.g., by using NIV, improves swallowing performance in patients with respiratory failure. We are currently studying the impact of NIV on swallowing in patients with chronic obstructive pulmonary disease (COPD) admitted to the

intensive care unit for acute respiratory failure. The first results strongly support a beneficial effect of NIV on swallowing performance.

All these studies underline the clinical usefulness of noninvasive dynamic evaluations of breathing-swallowing interactions in order to detect patients at risk for swallowing dysfunction due to respiratory failure. All our studies were done using a previously described noninvasive method (see below).

5. From bench to the bedside

EMG can be used to demonstrate the sequential and orderly activity of the muscles involved in swallowing and breathing. The anatomical components of the swallowing apparatus include the bony and cartilaginous support structures, striated and smooth muscles, and neural elements.

The muscles involved in swallowing have been studied in experimental animals and, to some extent, in humans. In dogs, the pattern of EMG activity was studied in the oral and pharyngeal muscles during swallowing elicited reflexively by electrical and mechanical stimuli (Doty and Bosma 1956). Needle electrodes were used to record intramuscular EMG activity during swallowing from a large complex of oral, pharyngeal, and laryngeal muscles in anesthetized animals. Descriptive studies based on this technique consistently found that the nonvolitional component of swallowing was controlled by a CPG (Miller 1972; Suzuki, Tokuriki et al. 1977; Kobara-Mates, Logemann et al. 1995). In humans, most of the intramuscular EMG studies of the pharyngeal phase of swallowing focused on a single muscle or muscle pair (Basmajian and Dutta 1961; Perlman, Luschei et al. 1989). Such studies can shed valuable light on the properties of the muscle of interest. However, they provide no information on the dynamics of swallowing.

To evaluate the dynamics of swallowing, researchers used quantitative surface EMG of the submental complex (SM) composed of submandibular/suprahyoid muscles including the mylohyoid, genohyoid, and anterior digastric muscles. All the muscles in this complex contract simultaneously to initiate a swallow and function as laryngeal elevators (Miller 1982). Consequently, submental surface EMG activity provides considerable information about the onset and duration of the oropharyngeal swallowing phase, as contraction of the SM complex pulls the hyoid bone into an anterosuperior position, thereby elevating the larynx and initiating the other reflexive changes that constitute the pharyngeal phase of swallowing (Donner, Bosma et al. 1985; Dodds, Logemann et al. 1990; Ertekin, Pehlivan et al. 1995). However, pharyngeal and laryngeal EMG recording during swallowing was difficult to perform noninvasively and usually required the insertion of a needle electrode. However, laryngeal motion can be detected fairly easily using a mechanical sensor.

To evaluate swallowing, we used a method previously described by Ertekin et al. (Ertekin, Aydogdu et al. 1998). Skin-surface electrodes are placed on the chin to record submental muscle activity and a piezo-electric sensor is placed between the cricoid and thyroid cartilages on the midline to detect laryngeal motion (Figure 1) (Terzi, Orlikowski et al. 2007). Breathing-swallowing coordination is assessed by using respiratory inductive plethysmography to record thoracic and abdominal movements. All signals are digitized and recorded on a personal computer equipped with an MP 150 data acquisition system (Biopac Systems, Goleta, CA, USA). The system software (AcqKnowledge) is configured to display the EMG signals, laryngeal movements, thoracic and abdominal movements simultaneously on separate channels.

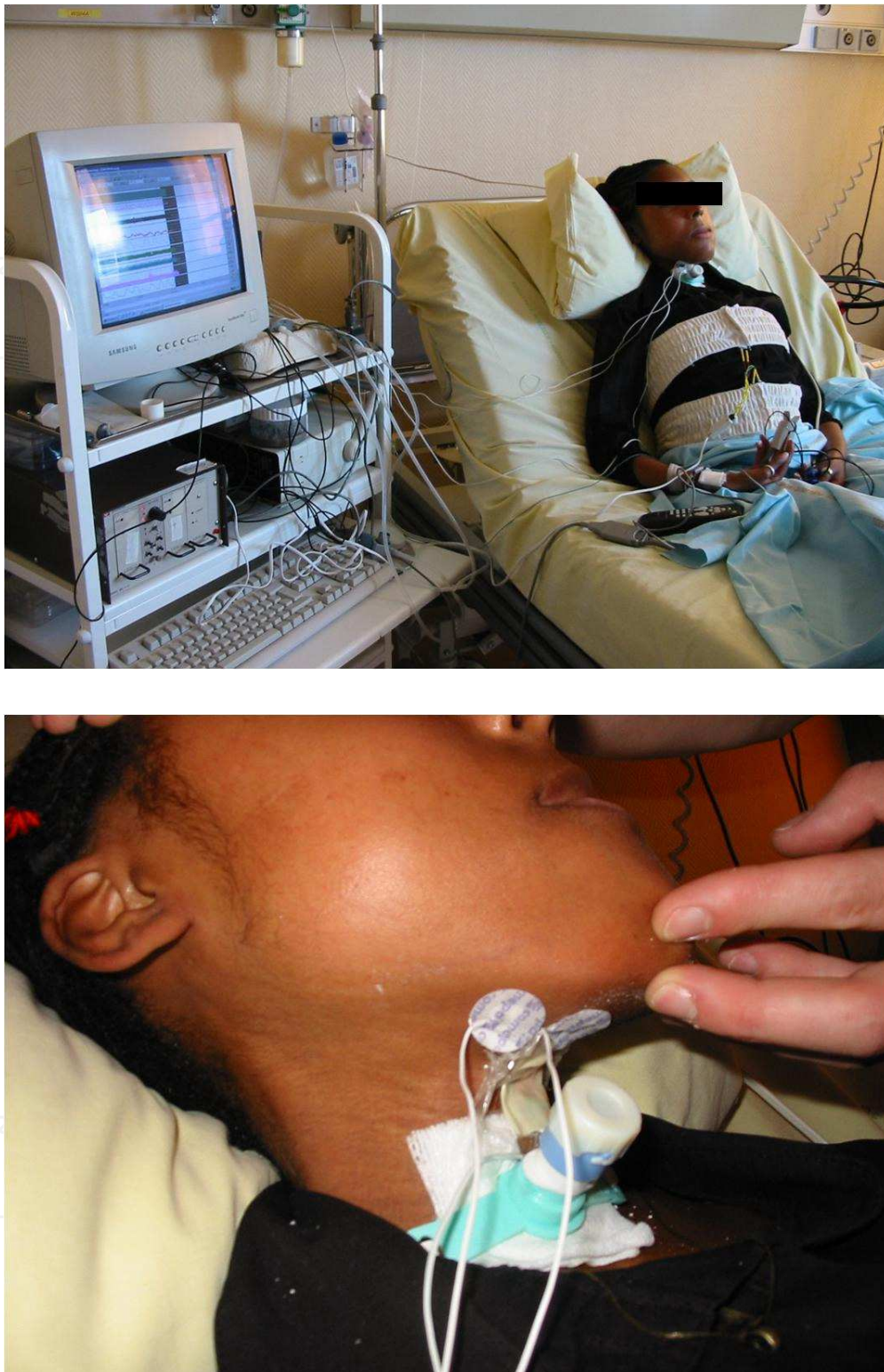


Fig. 1. Noninvasive monitoring. Extracted from Terzi et al. (Terzi, Orlikowski et al. 2007)

First, using this method we have demonstrated that the breathing-swallowing interaction was associated with piecemeal deglutition in neuromuscular patients, contrary to healthy subjects (Figure 2).

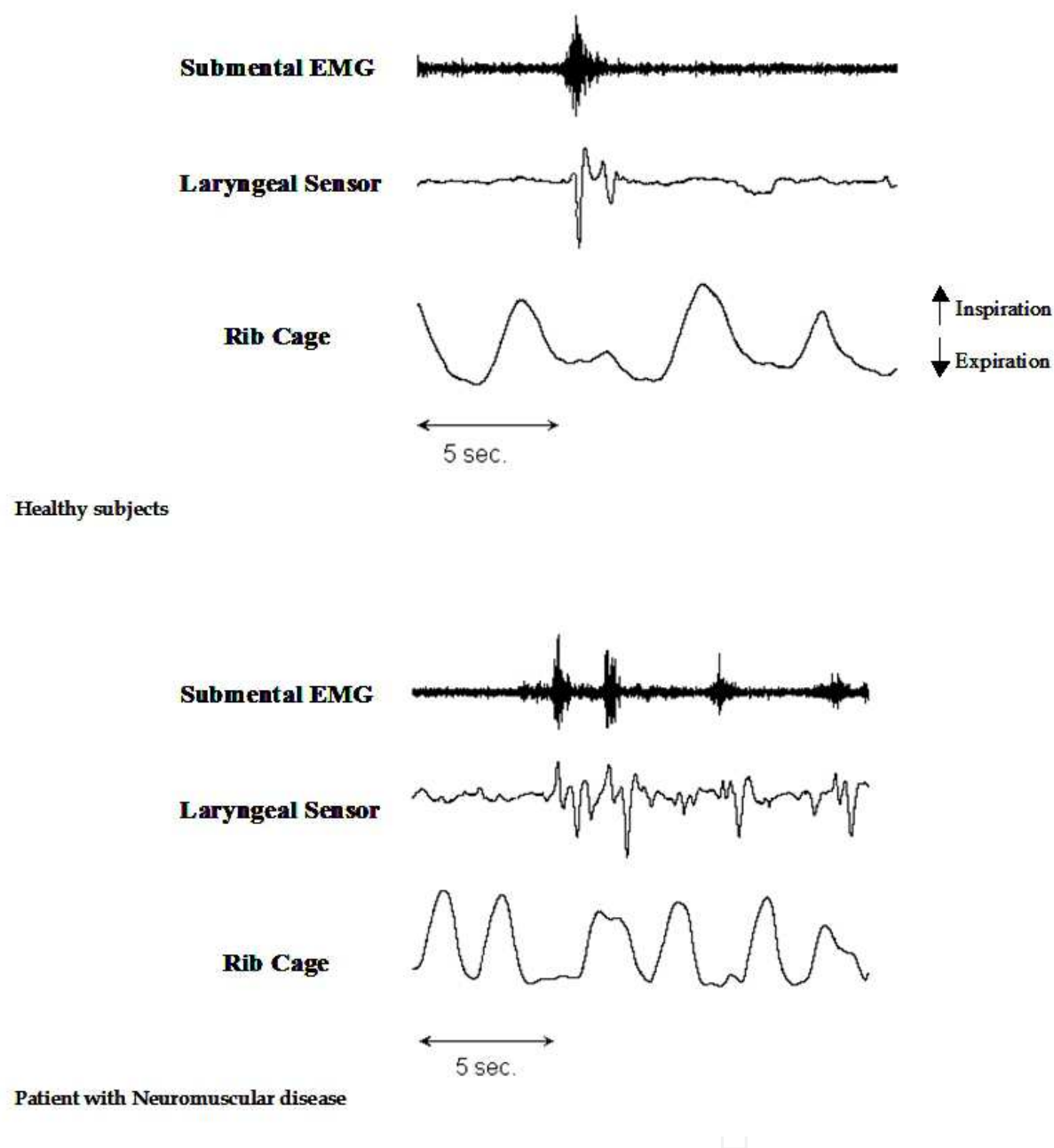


Fig. 2. Example of recordings in healthy subjects, and in patient with neuromuscular disorder. Extracted from Terzi et al. (Terzi, Orlikowski et al. 2007).

Piecemeal deglutition and breathing-swallowing anomalies were also demonstrated when neuromuscular patients were tracheostomized, however swallowing performance improved with mechanical ventilation (Figure 3).

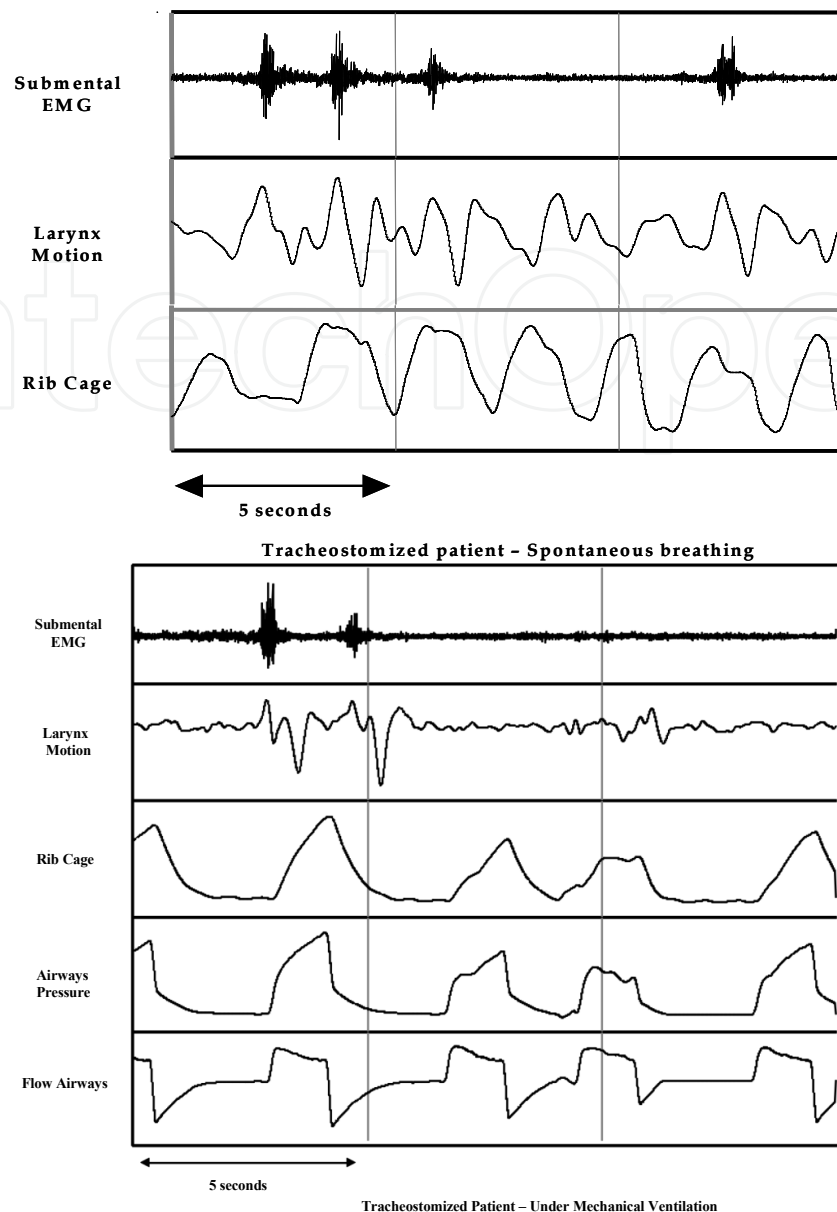



Fig. 3. Example of recordings with or without mechanical ventilation. Swallowing performance was improved by mechanical ventilation.

6. References

- (1999). "Clinical indications for noninvasive positive pressure ventilation in chronic respiratory failure due to restrictive lung disease, COPD, and nocturnal hypoventilation--a consensus conference report." *Chest* 116(2): 521-534.
- Annane, D., D. Orlikowski, et al. (2007). "Nocturnal mechanical ventilation for chronic hypoventilation in patients with neuromuscular and chest wall disorders." *Cochrane Database Syst Rev*(4): CD001941.
- Bach, J. R. (1993). "A comparison of long-term ventilatory support alternatives from the perspective of the patient and care giver." *Chest* 104(6): 1702-1706.
- Bach, J. R. and A. S. Alba (1990). "Tracheostomy ventilation. A study of efficacy with deflated cuffs and cuffless tubes." *Chest* 97(3): 679-683.

- Bach, J. R., A. S. Alba, et al. (1993). "Intermittent positive pressure ventilation via the mouth as an alternative to tracheostomy for 257 ventilator users." *Chest* 103(1): 174-182.
- Basmajian, J. V. and C. R. Dutta (1961). "Electromyography of the pharyngeal constrictors and levator palati in man." *Anat Rec* 139: 561-563.
- Car, A. and C. Roman (1970). "[Deglutitions and oesophageal reflex contractions induced by electrical stimulation of the medulla oblongata]." *Exp Brain Res* 11(1): 75-92.
- Chadda, K., B. Louis, et al. (2002). "Physiological effects of decannulation in tracheostomized patients." *Intensive Care Med* 28(12): 1761-1767.
- Dodds, W. J. (1989). "Physiology of swallowing." *Dysphagia* 3(4): 171-178.
- Dodds, W. J., J. A. Logemann, et al. (1990). "Radiologic assessment of abnormal oral and pharyngeal phases of swallowing." *AJR Am J Roentgenol* 154(5): 965-974.
- Donner, M. W., J. F. Bosma, et al. (1985). "Anatomy and physiology of the pharynx." *Gastrointest Radiol* 10(3): 196-212.
- Doty, R. W. and J. F. Bosma (1956). "An electromyographic analysis of reflex deglutition." *J Neurophysiol* 19(1): 44-60.
- Ertekin, C., I. Aydogdu, et al. (1996). "Piecemeal deglutition and dysphagia limit in normal subjects and in patients with swallowing disorders." *J Neurol Neurosurg Psychiatry* 61(5): 491-496.
- Ertekin, C., I. Aydogdu, et al. (1997). "Effects of bolus volume on oropharyngeal swallowing: an electrophysiologic study in man." *Am J Gastroenterol* 92(11): 2049-2053.
- Ertekin, C., I. Aydogdu, et al. (1998). "Electrodiagnostic methods for neurogenic dysphagia." *Electroencephalogr Clin Neurophysiol* 109(4): 331-340.
- Ertekin, C., M. Celik, et al. (2000). "The electromyographic behavior of the thyroarytenoid muscle during swallowing." *J Clin Gastroenterol* 30(3): 274-280.
- Ertekin, C., M. Pehlivan, et al. (1995). "An electrophysiological investigation of deglutition in man." *Muscle Nerve* 18(10): 1177-1186.
- Feroah, T. R., H. V. Forster, et al. (2002). "Effects of spontaneous swallows on breathing in awake goats." *J Appl Physiol* 92(5): 1923-1935.
- Finder, J. D., D. Birnkrant, et al. (2004). "Respiratory care of the patient with Duchenne muscular dystrophy: ATS consensus statement." *Am J Respir Crit Care Med* 170(4): 456-465.
- Hadjikoutis, S., T. P. Pickersgill, et al. (2000). "Abnormal patterns of breathing during swallowing in neurological disorders." *Brain* 123 (Pt 9): 1863-1873.
- Hamdy, S., D. J. Mikulis, et al. (1999). "Cortical activation during human volitional swallowing: an event-related fMRI study." *Am J Physiol* 277(1 Pt 1): G219-225.
- Hill, M., T. Hughes, et al. (2004). "Treatment for swallowing difficulties (dysphagia) in chronic muscle disease." *Cochrane Database Syst Rev*(2): CD004303.
- Humbert, I. A. and J. Robbins (2007). "Normal swallowing and functional magnetic resonance imaging: a systematic review." *Dysphagia* 22(3): 266-275.
- Jean, A. (2001). "Brain stem control of swallowing: neuronal network and cellular mechanisms." *Physiol Rev* 81(2): 929-969.
- Kijima, M., S. Isono, et al. (1999). "Coordination of swallowing and phases of respiration during added respiratory loads in awake subjects." *Am J Respir Crit Care Med* 159(6): 1898-1902.
- Klahn, M. S. and A. L. Perlman (1999). "Temporal and durational patterns associating respiration and swallowing." *Dysphagia* 14(3): 131-138.
- Kobara-Mates, M., J. A. Logemann, et al. (1995). "Physiology of oropharyngeal swallow in the cat: a videofluoroscopic and electromyographic study." *Am J Physiol* 268(2 Pt 1): G232-241.

- Logemann, J. A., P. J. Kahrilas, et al. (1992). "Closure mechanisms of laryngeal vestibule during swallow." *Am J Physiol* 262(2 Pt 1): G338-344.
- Martin, B. J., J. A. Logemann, et al. (1994). "Coordination between respiration and swallowing: respiratory phase relationships and temporal integration." *J Appl Physiol* 76(2): 714-723.
- Martin, R. E. and B. J. Sessle (1993). "The role of the cerebral cortex in swallowing." *Dysphagia* 8(3): 195-202.
- Mehta, S. and N. S. Hill (2001). "Noninvasive ventilation." *Am J Respir Crit Care Med* 163(2): 540-577.
- Miller, A. J. (1972). "Significance of sensory inflow to the swallowing reflex." *Brain Res* 43(1): 147-159.
- Miller, A. J. (1982). "Deglutition." *Physiol Rev* 62(1): 129-184.
- Nishino, T. and K. Hiraga (1991). "Coordination of swallowing and respiration in unconscious subjects." *J Appl Physiol* 70(3): 988-993.
- Nishino, T., T. Yonezawa, et al. (1985). "Effects of swallowing on the pattern of continuous respiration in human adults." *Am Rev Respir Dis* 132(6): 1219-1222.
- Orlikowski, D., N. Terzi, et al. (2009). "Tongue weakness is associated with respiratory failure in patients with severe Guillain-Barre syndrome." *Acta Neurol Scand* 119(6): 364-370.
- Paydarfar, D., R. J. Gilbert, et al. (1995). "Respiratory phase resetting and airflow changes induced by swallowing in humans." *J Physiol* 483 (Pt 1): 273-288.
- Perlman, A. L., E. S. Luschei, et al. (1989). "Electrical activity from the superior pharyngeal constrictor during reflexive and nonreflexive tasks." *J Speech Hear Res* 32(4): 749-754.
- Perlman, A. L., P. M. Palmer, et al. (1999). "Electromyographic activity from human laryngeal, pharyngeal, and submental muscles during swallowing." *J Appl Physiol* 86(5): 1663-1669.
- Perlman, A. L., J. G. Schultz, et al. (1993). "Effects of age, gender, bolus volume, and bolus viscosity on oropharyngeal pressure during swallowing." *J Appl Physiol* 75(1): 33-37.
- Raphael, J. C., S. Chevret, et al. (1994). "Randomised trial of preventive nasal ventilation in Duchenne muscular dystrophy. French Multicentre Cooperative Group on Home Mechanical Ventilation Assistance in Duchenne de Boulogne Muscular Dystrophy." *Lancet* 343(8913): 1600-1604.
- Selley, W. G., F. C. Flack, et al. (1989). "Respiratory patterns associated with swallowing: Part 1. The normal adult pattern and changes with age." *Age Ageing* 18(3): 168-172.
- Shaker, R., Q. Li, et al. (1992). "Coordination of deglutition and phases of respiration: effect of aging, tachypnea, bolus volume, and chronic obstructive pulmonary disease." *Am J Physiol* 263(5 Pt 1): G750-755.
- Simonds, A. K. (2003). "Home ventilation." *Eur Respir J Suppl* 47: 38s-46s.
- Smith, J., N. Wolkove, et al. (1989). "Coordination of eating, drinking and breathing in adults." *Chest* 96(3): 578-582.
- Sumi, T. (1969). "Some properties of cortically-evoked swallowing and chewing in rabbits." *Brain Res* 15(1): 107-120.
- Suzuki, M., M. Tokuriki, et al. (1977). "Electromyographic studies on the deglutition movement in the goat." *Nippon Juigaku Zasshi* 39(3): 243-253.
- Terzi, N., D. Orlikowski, et al. (2007). "Breathing-swallowing interaction in neuromuscular patients: a physiological evaluation." *Am J Respir Crit Care Med* 175(3): 269-276.
- Terzi, N., H. Prigent, et al. "Impact of tracheostomy on swallowing performance in Duchenne muscular dystrophy." *Neuromuscul Disord* 20(8): 493-498.
- Willig, T. N., J. R. Bach, et al. (1995). "Nutritional rehabilitation in neuromuscular disorders." *Semin Neurol* 15(1): 18-23.



EMG Methods for Evaluating Muscle and Nerve Function

Edited by Mr. Mark Schwartz

ISBN 978-953-307-793-2

Hard cover, 532 pages

Publisher InTech

Published online 11, January, 2012

Published in print edition January, 2012

This first of two volumes on EMG (Electromyography) covers a wide range of subjects, from Principles and Methods, Signal Processing, Diagnostics, Evoked Potentials, to EMG in combination with other technologies and New Frontiers in Research and Technology. The authors vary in their approach to their subjects, from reviews of the field, to experimental studies with exciting new findings. The authors review the literature related to the use of surface electromyography (SEMG) parameters for measuring muscle function and fatigue to the limitations of different analysis and processing techniques. The final section on new frontiers in research and technology describes new applications where electromyography is employed as a means for humans to control electromechanical systems, water surface electromyography, scanning electromyography, EMG measures in orthodontic appliances, and in the ophthalmological field. These original approaches to the use of EMG measurement provide a bridge to the second volume on clinical applications of EMG.

How to reference

In order to correctly reference this scholarly work, feel free to copy and paste the following:

N. Terzi, D. Orlikowski, H. Prigent, Pierre Denise, H. Normand and F. Lofaso (2012). Noninvasive Monitoring of Breathing and Swallowing Interaction, EMG Methods for Evaluating Muscle and Nerve Function, Mr. Mark Schwartz (Ed.), ISBN: 978-953-307-793-2, InTech, Available from: <http://www.intechopen.com/books/emg-methods-for-evaluating-muscle-and-nerve-function/noninvasive-monitoring-of-breathing-and-swallowing-interaction>

INTeCH
open science | open minds

InTech Europe

University Campus STeP Ri
Slavka Krautzeka 83/A
51000 Rijeka, Croatia
Phone: +385 (51) 770 447
Fax: +385 (51) 686 166
www.intechopen.com

InTech China

Unit 405, Office Block, Hotel Equatorial Shanghai
No.65, Yan An Road (West), Shanghai, 200040, China
中国上海市延安西路65号上海国际贵都大饭店办公楼405单元
Phone: +86-21-62489820
Fax: +86-21-62489821

© 2012 The Author(s). Licensee IntechOpen. This is an open access article distributed under the terms of the [Creative Commons Attribution 3.0 License](https://creativecommons.org/licenses/by/3.0/), which permits unrestricted use, distribution, and reproduction in any medium, provided the original work is properly cited.

IntechOpen

IntechOpen